SYPHILIS AND PREGNANCY:

A Study of Congenital Syphilis based upon the Examination of the Wassermann Reaction in over 3,500 specimens of Maternal, Placental and Infantile Blood: upon an Analysis of the Clinical Records of 1000 Parturient Women and their Infants: and upon the Post-Mortem Examination of 139 Infants.

A Thesis presented for the Degree of M.D. in the University of Glasgow. by

John Norman Cruickshank, M.C.,
M.B., Ch.B. (Glasg.)

May, 1923.

C O N T E N T S.

VOL. 1.

PART 1.

PART 1. (contd.)

PART 11.

PART 111.

VOL. 11.

Appendix - Clinical Histories of 1000 Cases.

PART 1.

1. Introduction.

The following study was made with the object of investigating the part played by Congenital Syphilis in the etiology of pre-natal and neo-natal death. It is based upon the examination of the Wassermann Reaction[1] of over 3,500 specimens of serum, of which 1,881 were obtained from women during pregnancy or immediately after delivery, 1,350 were taken at birth from the placental end of the cord of the infant, and the remainder were from infants and their mothers at varying periods after birth. In order to eliminate as far as possible the element of selection, the cases are taken in series as they were dealt with, so that the material on which the study is based may be considered as having been obtained entirely without reference to the clinical condition of the patients from whom it was removed. The series is to be regarded, accordingly, as giving a true indication of the incidence of a positive Wassermann reaction in the section of the population from which the material was taken and of the relation of the disease to the various conditions with which this investigation is concerned.

Originally it was intended to test the Wassermann reaction on the blood of every woman admitted to The Glasgow Royal Maternity and Women's Hospital, but there

---

[1]The letters " W.R." below to indicate the words " Wassermann Reaction" .

were at the time certain practical difficulties in carrying out so extensive an investigation, and instead as many cases as it was possible to deal with were taken without reference to or knowledge of their clinical condition. Most of the women were admitted to the wards of the Hospital during the winter of 1920-21, but a few attended only at the Ante-natal Dispensary. On looking into the clinical records of many of the patients it was found that the information available was too incomplete to allow of an analytical study being made, and it was therefore decided to limit the more detailed part of the investigation to one thousand cases of which fuller notes could be obtained. The clinical histories of the thousand cases included in this detailed analysis will be found in Appendix i. They were extracted in most instances from the Hospital records, but in every case an attempt has been made to get in touch with the patient. A considerable number of the women and their infants have been examined at varying periods after dismissal from the Hospital, and the information obtained from the Ward Journals has thus been supplemented. In a large number, however, it has been impossible to do so, and the after-histories are not as full as one would have wished. The number of patients whom it has been possible to follow up is nevertheless sufficient to give an indication of the incidence of infant mortality in the various groups into which the cases are divided.

2. Object of the Investigation.

This study has been carried out with the object of determining:-

1. The incidence of syphilis in women of the "Hospital class" in Glasgow.
2. The incidence of congenital syphilis in the infants of these women.
3. The effects of syphilis on the incidence of abortion, premature birth and still-birth.
4. The relation between the presence of syphilis in the mother and the mortality in live-born infants.
5. The relation, if any, between syphilis in the mother and the occurrence of ante-partum and post-partum haemorrhage.
6. The relation between syphilis in the mother and the occurrence of eclampsia.

3. Scope of the Investigation.

To what extent the results of this study represent the true incidence of syphilis in the class of patient investigated depends in large measure upon the view which is taken with regard to the value of the Wassermann reaction. When, as in the present instance, one can

exclude the presence of such tropical diseases as malaria and yaws, and such acute infections as scarlet fever, it is generally agreed that a positive W.R., obtained under carefully controlled conditions, indicates in the adult at least that syphilis is or has been present. It may be taken, then, that all the mothers in the present series of cases who gave a positive W.R. are or were syphilitic. On the question of the value of the Wassermann reaction in the blood of the infant, and still more so in the placental blood, opinion is somewhat divided. This point is discussed below more fully (p. 17).

The significance of a negative Wassermann reaction in the adult is less certain than that of a positive reaction, but the general opinion of those who have worked on the subject is that in the great majority of cases a negative Wassermann reaction excludes the presence of syphilis. A number of writers hold the view that the finding of a negative reaction in a single specimen only is not sufficient evidence to enable syphilis to be excluded in making a diagnosis.

Fildes and Parnell (p. 280) examined a series of 1,414 cases of syphilis or suspected syphilis and obtained a positive W.R. in 81.8 per cent of them. Of the 18 per cent of cases which gave a negative reaction 12.8 per cent showed signs of syphilis clinically. Such figures as these, taken without their context, give quite an erroneous impression, for the series of cases on which they are based contained a considerable proportion of very early cases and a number of the patients had been given anti-syphilitic treatment.

The work carried out by Turnbull (ii,p.280) in comparing the results of the Wassermann reaction with the subsequent post-mortem findings is of the greatest value as evidence of the significance of the test. After examination of material obtained at autopsy, combined with carefully controlled serological examination, he concluded that in only three per cent of a series of 98 cases was there a wrong diagnosis in the sense that syphilis was not diagnosed during life, although certainly or probably present as shown by the post-mortem findings.

In estimating the prevalence of syphilis by means of the Wassermann reaction alone it would appear, then, that in any given series of cases we obtain the minimum incidence of the disease, but that the actual incidence in the series is not much greater than that indicated by the number of positive reactions. Having thus decided upon the value of the results of the Wassermann reaction in the blood of the adult, one is next concerned with the selection of material.

4. Methods employed.

The blood was obtained in the case of the mothers from an arm vein. As a rule, the specimen was taken off within a day or two of delivery, but women who attended the Ante-natal Department were generally examined some time before delivery.

The tests were performed in batches twice a week. In no case had a longer interval than seven days elapsed between the drawing off of the blood and its examination, and in most instances the serum was kept for a much shorter period. The technique employed for the test was that of Harrison - the "Rochester Row" method - as

described in detail in the Medical Research Council's Special Report Series No. 14. Incubation was carried on in an incubator for one hour at 37°C. instead of half-an-hour in a water bath, but as the reagents were standardised for this modification there can be no objection to its use.

In reading the results of the test the following simple notation was employed. Three tubes were used for each serum - the first containing 3 m.h.d. of complement, the second 5 m.h.d., and the third being the serum control with 3 m.h.d. of complement but without antigen. Complete lysis in all tubes was read as a clear negative, complete inhibition of lysis in the first and second tubes as strongly positive, complete inhibition in the first tube only as positive, and varying degrees of incomplete inhibition as " doubtfully positive" and " doubtfully negative" . In the great majority of cases in this series the reaction, if not a clear negative, was of the strongly positive type (3+5+) and in only a few was the reaction of the " positive" type - fully inhibiting three but not five doses of complement.

The antigen employed was a cholesterin + heart-extract one prepared in accordance with the method described by Harrison (loc. cit.). Each sample of antigen was titrated at least twice before being taken into use. One or more known positive and negative sera were put up as controls with each batch of tests, and

as an additional precaution, positive and negative control sera were sent every six weeks or so to Professor Teacher's laboratory at the Royal Infirmary for a confirmatory test.

To gain an estimate of the incidence of syphilis in the population generally is a matter of considerable difficulty, as it is seldom possible to obtain an unselected series of cases except from among hospital patients, and one thus estimates the incidence of syphilis in one particular class and not in the population as a whole. It was clearly demonstrated by Browning and Watson (pp.279 & 283) that the percentage of positive cases varies to a considerable degree according to the class from which a series of cases is selected. In the latter's investigation the incidence of syphilis was shown to be very much greater, for example, in the " vagrant class" than in a series of patients from a general hospital.

An attempt to obtain a true " cross section" of the community was made in America by Day and McNitt (p. 280) who made an investigation of the Wassermann reaction in four groups of cases:- (1) Private Pavilion cases, (2) " Pay Ward" cases, (3) White " Free Ward" cases, (4) Coloured " Free Ward" cases. In these four groups the estimated incidence of syphilis was respectively 6.3 per cent, 13.6 per cent, 19.8 per cent, and 30 per cent. The actual figures are high - due in part, I think, to the technique employed in carrying out the tests (a very sensitive antigen was used), but the variations in the incidence in different social classes is well illustrated.

The same point is brought out by Jeans and Cooke (p. 281) who, in making a study of the incidence of congenital syphilis in St. Louis, took their material from private and hospital patients in almost equal proportions. They found an incidence of 9.6 per cent of positive cases in hospital patients (5.8 per cent for White and 14.4 per cent for Negro cases) and an incidence of only 1.6 per cent in private cases.

The present investigation - based entirely on hospital cases - does not attempt to estimate the prevalence of syphilis in the population generally, or to compare the incidence in the various social classes in the city. Its aims are rather to demonstrate the extent to which one important section of the community is infected with syphilis, to study the effects of syphilis as a factor in the production of the high ante-natal and neo-natal death rates in that section of the population, and to suggest methods of dealing with this cause of wastage of infant life.

5. Incidence of Syphilis in Mothers.

In the present series of 1,881 unselected mothers the blood was found to give a positive Wassermann reaction in 9.03 per cent of cases, while of the one thousand of which a more detailed study was made a positive reaction was obtained in 9.4 per cent. In round figures, one may say that between nine and ten per cent of the women examined gave a positive Wassermann reaction. It

may be of interest to note in passing that of the 94 women, in the series of 1,000 cases, whose blood gave a positive reaction, 70 were married and 24 were unmarried, while of the women whose blood gave a negative W.R. 705 were married and 184 were single. The incidence rate of syphilis, as shown by the Wassermann reaction, was 8.91 per cent in married mothers and 11.16 per cent in unmarried mothers. These figures agree with the findings of a number of other workers on similar lines.

Within recent years there have been published a considerable number of studies of the incidence of syphilis in the adult population generally. The most striking features of the results is the extent to which they vary. Such variations appear to depend largely upon the type of material selected for investigation - a point to which reference has already been made. Without attempting to give a complete bibliography, a selection of some of the published results of such investigations has been made, and they are shown diagramatically in figure 1.

The number of studies made with the object of determining the incidence of syphilis in pregnant women is much smaller, but here again there is a certain amount of variation in the results. As many of these as were available to the present writer have been summarised below, and figure 2 shows the findings diagramatically.

Fig. 1.

Incidence of Positive Wassermann Reaction in Adults.



Fig. 2.

Incidence of Positive Wassermann Reaction in Pregnant Women.

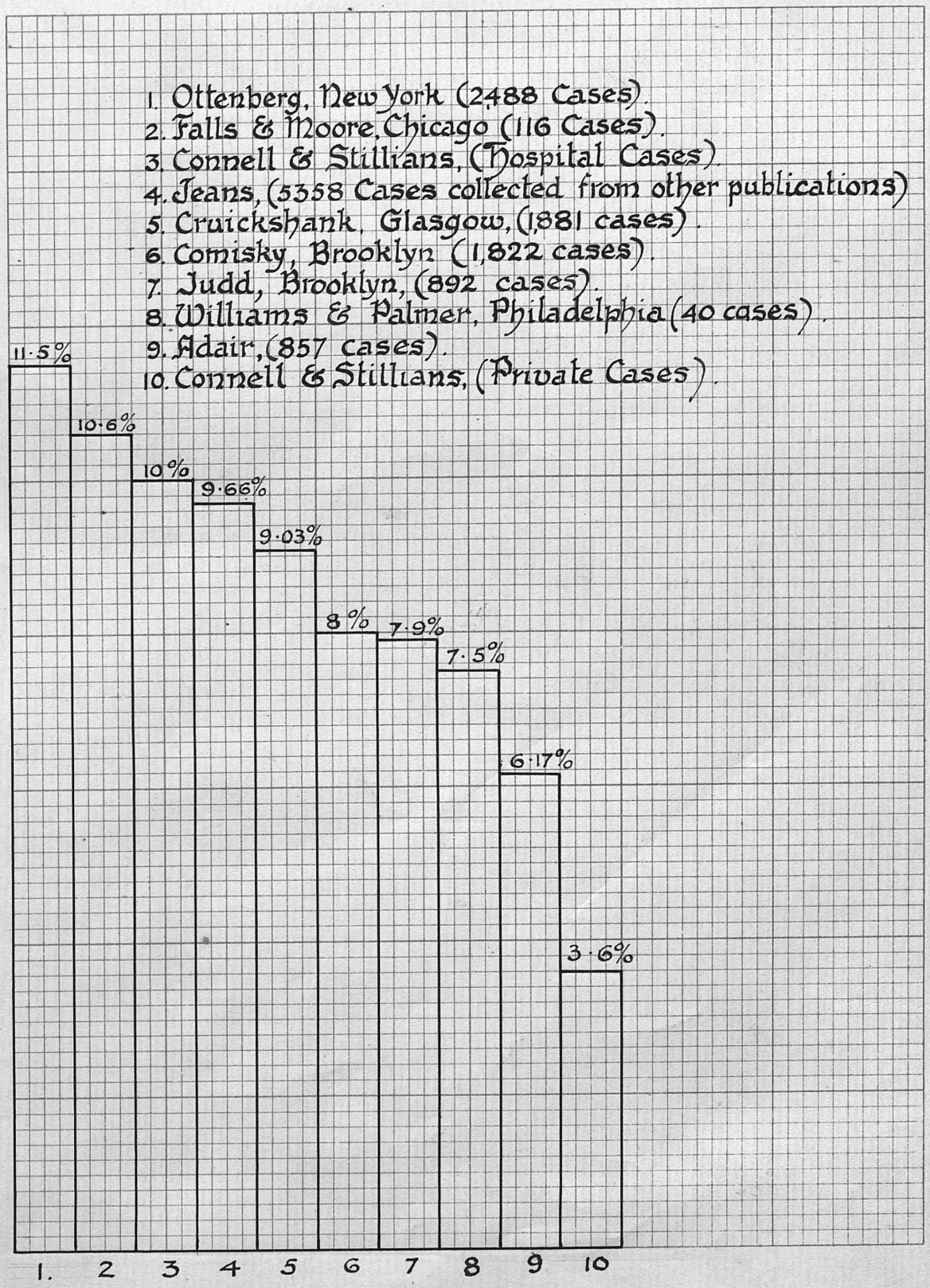

Jeans, P.C. (Am. J. of Syphilis, 1919, iii, 1701, 114) in a paper on syphilis and its relation to infant mortality, points out the necessity for considering not only the infant born with syphilis, but all infected individuals within the procreating age. He, therefore, examines the evidence as to the incidence of syphilis in adults, and remarks upon the lack of accurate statistics concerning the prevalence of the disease in a true cross-section of the community - most of the statistics available being drawn from the poorer classes. He concludes, nevertheless, that a minimum of ten per cent of the adult males in the United States are syphilitic, and that " the commonly accepted figure of twenty per cent" is probably nearer the truth. Statistics for unmarried women, he points out, generally show a low incidence of syphilis (3.4 per cent), but after marriage the incidence rises and closely approximates the figure for adult males (9.6 per cent). Jeans also examined a series of statistics taken from the work of five authors in America, and from these figures he concluded that 9.66 per cent of pregnant women are syphilitic - as indicated by the Wassermann reaction. These statistics were based on the records of 15,264 Wassermann tests performed on the blood of hospital patients other than those attending venereal disease centres. Since the cases were not examined with the prime object of ascertaining the incidence rate of syphilis, but were simply the routine Wassermann tests of a number of hospitals, there were probably included many cases in which the reaction was performed to confirm a clinical diagnosis of syphilis. It may be reasonably objected that the figure 9.66 per cent is too high. Nevertheless, it closely approximates that found by the present writer in the entirely unselected series of pregnant women.

Adair, (Am. J. of Obstetrics, 1918, Nov., 678) examined the blood of 857 unselected pregnant women and found that the Wassermann reaction was positive in 6.17 per cent of the series.

Louise McIlroy and Watson are quoted by Browning (Brit. Med. J., 1914, i. 77) as having found that in a series of 39 cases " of indefinite origin" attending the Gynaecological Department of the Glasgow Royal Infirmary as out-patients, 46 per cent gave a positive W.R., and in another series of 37 cases they found the incidence of syphilis to be 59 per cent. These figures are much higher than those given by any other workers, however, and it does not seem possible to accept them as an indication of the prevalence of syphilis in the population of Glasgow.

Connell, L.L. and Stillians, A.W. (J. Am. Med. Assocn. lxxii, 551) in an attempt to assess the value of the Wassermann reaction in pregnancy examined a series of patients in private practice, and found that the reaction was positive in 3.6 per cent only, while in a series of hospital patients nearly 10 per cent gave a positive reaction. Of all the positive cases in these two series of pregnant women more than one third were detectable by serum examination only - a point which they consider shows the value of the Wassermann reaction in dealing with pregnant women. It was noted by these writers also that a surprisingly large number of non-syphilitic women gave a history of frequent abortion.

Day, A.B., and McNitt, W. (Am. J. of Syphilis, 1919, iii, 595) made a study of the incidence of syphilis as manifested by routine Wassermann reactions on 2,925 hospital and dispensary patients. Brief reference has already been made to this work above, and the following shows the results in tabular form:-

The cases were divided into four groups, as follows:-

1. Private Pavilion cases ("well-to-do" patients).
2. Pay Ward cases (middle class patients).
3. Free Ward cases (lower white class patients).
4. Coloured patients.

A. Hospital cases = 675 patients.

	Positive W.R.	Estimated incidence of Syphilis.
Group 1.	8.3%	6.3%
2.	12.6%	13.6%
3.	23.0%	19.8%
4.	33.0%	30.0%

Of strongly positive cases 61 per cent were clinically syphilitic, of weakly positive cases 7.3 per cent were clinically positive.

B. Out-patients = 2,250 patients.

Group 1.	17.6%	15.9%
2.	42.7%	40.5%

Of 853 white male adults W.R. was positive in 30 per cent.

Of 924 white female adults W.R. was positive in 16 per cent.

McLester, J.S. (J. Am. Med. Assn., 1916,lxvi, 2063) examined a series of 300 consecutive private patients and found a positive W.R. in 18.8 per cent.

Rosenberger, R.C. (N.Y. Med. J., 1917, cv., 1233, & ibid. 1918, cviii, 584) examined the records of 5,106 cases in the Philadelphia General Hospital during the year 1916, and found that there was a positive W.R. in 27 per cent. A further series of 5,106 cases in the same hospital during the year 1917 showed a positive reaction in 25.9 per cent of the patients. He does not state that the series was an unselected one.

Walker, I.C. and Haller, D.A. (J. Am. Med. Assn., 1916, lxvi, 1001) examined 1,200 routine medical cases in the wards and out-patient department of a general hospital and found that the W.R. was positive in 12 per cent.

Vedder, E.B. (Therap. Gaz., 1916, xl, 308) found that of a series of 1,019 U.S. Army recruits 16.77 per cent gave a positive W.R., and from examination of the men he was of opinion that 7.75 per cent of the series were clinically syphilitic.

From a study of the results of the present investigation shown in tables i and ii and table ia., it is evident that pregnant women of the class attending the Maternity Hospital in Glasgow give a positive Wassermann reaction in the blood in a little over nine per cent of cases. The conclusion has already been drawn that in the majority of cases a positive result gives a correct indication of the presence of syphilis, whether active or latent, while a small proportion of cases of syphilis fail to give a positive reaction. If this conclusion be correct, then in the series of women examined, the estimate that between nine and ten per cent were syphilitic is probably one which errs, if at all, in being a low one. Whether this interpretation of the significance of the Wassermann reaction in pregnant women be accepted or not, it is apparent at any rate that the proportion of cases in which a positive reaction was obtained agrees with that found by most workers who have made an investigation of similar material.

6. Incidence of Syphilis in Infants.

The question of the incidence of congenital syphilis is one to which a good deal of attention has been directed within recent years, and it is remarkable that there should be such wide variations as are found in the estimates made by various writers as to the frequency of the condition. Work on the subject falls naturally into two categories - that based on clinical findings only and that based on serological and pathological investigations either alone or combined with clinical studies. To whichever of these two groups they belong many publications have the defect that they are based on data which were not collected primarily with the object of determining the rate of incidence of congenital syphilis, and consequently various modifying factors cannot be excluded with certainty. When one compares the results of investigations based on clinical findings alone with the more recent serological and clinical studies it is seen that not only are there wide variations in the results obtained by these two methods, but that the findings of workers using the same method differ considerably from one another. The lack of agreement in the older estimates based on clinical data only is probably to be explained by the lack of uniformity in the clinical material examined, and by the personal factor in diagnosis. It is interesting to note, however, that if the clinical findings be compared with the later

serological findings the incidence rate of congenital syphilis is seen to be estimated at a much lower figure on the whole by the older writers than by the authors of more recent work who employed the Wassermann reaction.

At first sight one might be inclined to explain the relatively low incidence of congenital syphilis in the purely clinical studies as due to the number of latent cases showing no signs of the disease clinically at birth and for some time afterwards. Only a comparatively small number of cases examined by serological methods have been drawn from among the new-born, and many of the published series of clinical studies have also been based on the examination of older children. Since a considerable number of cases of congenital syphilis die in infancy or early childhood it is obvious that figures based on the examination of children surviving at any given age must show a lower incidence rate of the disease than do figures based on the examination of younger children (other things being equal). The older the children in any series investigated the greater will be the error from this cause, for as age increases the greater will be the number of individuals who have been removed from the series by death. For this reason it might be thought advisable to base such estimates of the prevalence of congenital syphilis on the examination of infants as soon after birth as possible, but in avoiding this source of error

there is a danger of falling into another, for the difficulties of making an accurate differentiation between the syphilitic and the non-syphilitic are much greater in the new-born than later in childhood.

The Value of the Wassermann reaction in the Infant.

Opinion at the present time is somewhat divided as to the value of the Wassermann reaction in the blood of infants and, more particularly, in the foetal blood as obtained from the placenta. Many workers, particularly in America, but also in this country (Wright and Ross for example) appear to accept the presence of a positive Wassermann reaction in the new-born as evidence of congenital syphilis. That the occurrence of a positive reaction at birth has such a significance was challenged by Fildes, in 1915, and the conclusions which he then drew from a study of this point are of considerable interest. He states as one of his conclusions that " the Wassermann reaction obtained with blood from the placental end of the cord is not diagnostic of syphilis in the infant but of syphilis in the mother" . His chief objection to accepting the results of the Wassermann reaction of the placental blood as an indication of the incidence of congenital syphilis is that while a positive Wassermann reaction in the placental blood is diagnostic of syphilis in the mother, " in the majority of cases" women with a positive reaction do not induce a positive reaction in their infants. He considers that a positive

placental reaction at birth does not necessarily imply the presence of syphilis in the infant, " but may simply be due to the passage of substances from the maternal blood to the circulation of the child, which are capable of providing a positive Wassermann reaction" . He also points out that the phenomenon does not depend upon the use of placental blood but is also met with when the blood is obtained direct from the infant - as one would, of course, expect.

In support of these contentions he reexamined a series of 660 infants during the early months of life with the following surprising results:-

In the 1,015 sera from the cords of infants at birth, which he originally examined, there was found to be a positive Wassermann reaction in 1.3 per cent of cases, while in the sera of infants of the same series, reexamined at periods varying from two and a half to four months after birth, the W.R. was positive in 0.45 per cent (i.e., in three cases). The mother's blood of all three cases gave a positive reaction, but the placental blood of all three infants had been clearly negative at birth and the infants themselves had been healthy. At the time of reexamination two (aged 2½ months) still appeared healthy but the third (aged 2 months) showed signs of congenital syphilis and was under treatment.

The statement of Fildes that in the majority of cases women with a positive Wassermann reaction do not induce a positive reaction in their infants is not in accordance with the findings of the present writer. In my series there was agreement between the reaction of the mother's blood and of the child's at birth in 94.6 per cent of cases, and of the 5.4 per cent of cases in which the reactions failed to agree, in only 3.18 per cent of the whole series was there a positive reaction in the mother and a negative one in the infant. The remainder of the cases in which there was disagreement were due to either

a doubtful reaction or inhibition in the control tube. (See Table 4).

The opinions expressed by Fildes in the Report quoted above were repeated by him in 1921 in connection with the work of S.M. Ross and A. F. Wright (Lancet, 1921, i, 321). These writers made an investigation of the Wassermann reaction in the placental blood of 340 unselected cases in an industrial and mining area, and found that there was a positive reaction in 3.5 per cent of the sera. They stated quite definitely their belief that figures based on the results of the examination of the placental blood give probably an under estimate of the prevalence of congenital or pre-natal syphilis in the general population. In support of this they quoted a statement of Fildes that only a minority of syphilitic women induce a positive reaction in their placental blood. Ross and Wright stated also that the view that such estimates were too low was held by Amand Routh and Morna Rawlins. Such an interpretation of his results was repudiated by Fildes. At the same time he repeated his opinion that a test of the umbilical cord serum cannot be taken as evidence of syphilis in the infant, and that " estimates based on such tests will be much too high" .

Jewesbury, R.C. (Lancet, 1921, i, 962) has found the Wassermann reaction to be a very reliable and valuable test. In his experience the reaction in syphilitic infants was often negative during the first few months of life and later became positive.

With regard to the effect on the child of inherited syphilis in the mother, Jewesbury found (loc. cit.) that in the series of 77 families which he investigated there were 332 pregnancies. Of these pregnancies 97 - or 30.2 per cent - resulted in miscarriage or still-birth, 73 (22.8 per cent) in death during infancy or early childhood, and 152 (47.0 per cent) were alive at the time of the investigation. The mortality of children born alive was 32.4 per cent.

The following figures, collected by Jeans (Amer. J. of Syph., 1919, iii, 1) are of interest in this connection.

1. A clinical study was made of 854 infants of one year or under in St. Louis, and the Wassermann reaction was tested in all those whose family or personal history or clinical examination gave any suspicion of syphilis. 4.9 per cent of this series were found to be syphilitic, but it is to be noted that the Wassermann reaction was not done in all cases, so that some latent cases may have been overlooked.

2. Holt, in New York, examined 161 cases, some of which gave a history suggestive of syphilis, though none of the patients were syphilitic clinically. The Wassermann reaction was positive in 6.2 per cent of these children.

3. Commisky, in Brooklyn, examined 1,074 new-born infants and found that 3.2 per cent gave a positive Wassermann reaction.

Jeans concludes from these figures that, taking into account the frequency of a negative Wassermann reaction in syphilitic infants at birth, the incidence of syphilis in the infant population may be taken as five per cent.

Kolmer [illegible] after a full consideration of the significance of the Wassermann reaction in congenital syphilis makes the following conclusions:- " The W.R. at birth in cases where syphilis of the mother is suspected is of prognostic value" . " A large number of the children reacting positively develop symptoms of syphilis, while the majority of those reacting negatively remain healthy" . " An examination of the mother alone does

not warrant an absolutely definite prognosis for the child, but, in general, it may be said that a positive reaction is not a favourable prognostic sign for the child". Kolmer also emphasises the point first demonstrated by Boas and Thomsen that the value of the Wassermann reaction as an indication of syphilis in the infant varies with the time at which the examination is made.

Thomsen and Boas, whose work Kolmer quotes, found that of 88 new-born infants of syphilitic mothers the W.R. was positive in only 35.22 per cent. Of these infants with positive W.R. 87.09 per cent either developed syphilis or died later with syphilitic manifestations in various organs, while the remaining 12.91 per cent showed no symptoms during periods of observation varying from three to nine months. Of the infants showing a negative reaction at birth 73.68 per cent showed no evidence of syphilis during the first three months of observation, 3.49 per cent died with evidence of syphilis in internal organs, and 2.88 per cent developed symptoms of syphilis and gave a positive Wassermann reaction.

Elliot, W.M., (Trans. Glasg. Med.-Chir. Socy., 1914, 58) took blood from 130 children selected for their unhealthiness or drawn from the poorer classes of the city and found a definitely positive Wassermann reaction in 14 of the specimens (approximately 10.8 per cent). As there were four children in the series who showed definite signs of congenital syphilis (which he considered an unusual number) he estimated the corrected incidence of

positive reactions at 8.5 per cent approximately. He also drew the following conclusions from this study:-

1. Poorly nourished children are not in that condition to any extent because of syphilitic infection.
2. Eight per cent of all classes of children of the poorer classes of Glasgow give a positive Wassermann reaction.
3. Congenital syphilis can exist without any clinical evidence of its effect on the general health of the child.

Williams, of Baltimore (Journ. Am. Med. Assocn., 1915, Jany. 5th) analysed the results of 10,000 pregnancies and found that there resulted 705 still-births (26 per cent of which were due to syphilis) and that of the children born alive 3.5 per cent were definitely syphilitic. From this he concludes that there was an incidence of five per cent of syphilitic cases in the series of ten thousand.

Browning, C.H. (B.M.J., 1914, Jany. 10th) estimated the incidence of congenital syphilis at ten per cent of the population after an investigation based on the results of the Wassermann reaction.

Churchill and Austin, (Amer. J. of Dis. of Child. 1916, October) examined a series of 695 unselected cases in Chicago during 1915-16 and found evidence of syphilis in 3.3 per cent of cases. They conclude that the incidence of congenital syphilis among hospital infants and children in New York, San Francisco and Chicago appears to range from 2.0 per cent to 6.0 per cent - with an average of 4.0 per cent.

Nabarro, (Lancet, 1921,cc. 484) speaking at a discussion on Congenital Syphilis before the Royal Society

of Medicine's Section for the Study of Children's Diseases, expressed his great faith in the Wassermann reaction when reliably done. He believed that a strong positive reaction always meant syphilis, while a negative W.R. did not preclude syphilis. He had noted that very young children might give a negative reaction, so that he had made it a rule to test the blood of the mothers of infants under one year of age. He found that the mother's blood was practically always positive when the child's blood was positive and that very rarely was the mother's blood negative when the child's blood was positive. The father's blood he had frequently found negative. He spoke also of the difficulty of obtaining a negative W.R. after treatment in congenital syphilis.

Browne, F.J., in his report to the Medical Research Council on Still-birth (for a summary of which see B.M.J. 1921, ii, 140) refers to syphilis as an important cause of still-birth and neo-natal death. In the series of two hundred cases examined post-mortem he found evidence of syphilis in 35 instances (17 per cent). This number included 14 macerated foetuses. He points out the numerous difficulties in making a diagnosis of syphilis in the new-born. In only six of the cases was there clinical evidence or a history of syphilis in the mother. While recognising the value of a positive Wassermann reaction in the mother, Browne places so little stress on the finding of a negative reaction that, in all cases with

a history of repeated still-births, abortions or neo-natal deaths which cannot be accounted for by obstetrical complications or albuminuria, he carries out anti-syphilitic treatment. He also emphasises the uncertainty of the diagnosis of syphilis from examination of the foetus or infant even when autopsy is augmented by histological examination of the tissues (including the placenta). The frequent failure to demonstrate spirochaetes even in undoubted cases of syphilis is commented upon. He has also noted the inconstancy of the classical signs of congenital syphilis - enlargement of the spleen, pneumonia alba, chondro-epiphysitis, and enlargement and pallor of the placenta.

Some of the grounds upon which Browne makes a diagnosis of syphilis in some of his cases will perhaps not meet with general acceptance, so that his finding of seventeen per cent of syphilitic foetuses in an unselected series of two hundred is possibly somewhat in excess of the actual number.

De Buys, L.R., and Loeber, M., (J. Amer. Med. Assoc. 1919, lxxiii, 1028) made a series of studies with the object of determining the incidence of congenital syphilis. The material employed was all obtained from a Foundling Hospital. They examined the blood of 106 infants and found that the Wassermann reaction was negative in all, though ten of the infants (9.43 per cent) were considered to be syphilitic on account of the presence of skin

eruptions and enlarged spleens and livers. The Luetin test was carried out on the same children and was found to be positive in 79 cases, negative in 18, and doubtful in 9 cases. The writers of this publication consider that the incidence of congenital syphilis in the institution in which they worked was 83.96 per cent. This estimate is based on the results of the Luetin reaction which they consider of more value than the Wassermann reaction in the infant. They explain the complete series of negative Wassermann reactions in the study as due to intensive treatment " or it may be that the bloods had not yet become positive" . 74.6 per cent of the children examined were under two years of age and 41.7 per cent were under one year. Enlarged livers, spleens and glands appeared to be the most constant signs of congenital syphilis. The results of this investigation are at such variance with those of most other workers that it does not seem possible to consider them as giving any indication of the incidence of congenital syphilis in the general infant population.

Results of the Wassermann reaction in the Infant in the present Study.

In the present study the placental blood of 1,350 infants was examined and the Wassermann reaction was found to be positive in 4.6 per cent, negative in 94.4 per cent and doubtful in 1 per cent.

The statement of Fildes that in the majority of cases women with a positive Wassermann reaction do not induce a positive reaction in their infants was not supported by the findings in the present study. In my series there was agreement between the reaction of the mother's blood and of the child's at birth in 94.6 per cent of (over 400) cases. In only 3.18 per cent of the whole series was there a positive reaction in the mother and a negative one in the infant at birth, and the remainder of the cases in which there was disagreement were due either to a doubtful reaction or to an invalid test. In one case the mother's blood gave a negative reaction while the child's blood gave a positive reaction and it was found that this woman had been receiving anti-syphilitic treatment during her pregnancy, the last of a series of intravenous injections having been given less than a month before delivery.

While these figures show clearly a close agreement between the Wassermann reaction in the mother and in the child at birth, and that the main differences which occur are due to a tendency for a comparatively small number of the children of positive mothers to give a negative reaction, there still remains for consideration the question of the interpretation of the results of Wassermann tests in the blood of the new-born. Is the occurrence of a positive reaction to be regarded as due simply to the transference of the mother's reacting

substances to the foetal circulation, or is one justified in concluding that the presence of a positive or a negative Wassermann reaction in the blood of an infant at birth is a safe guide in determining whether the child is or is not syphilitic? With the object of settling this point a number of children with their mothers were reexamined at periods ranging from three weeks to twenty months after birth.

The results of this reexamination of infants in the present series agree in the main with the conclusions drawn by Fildes, though certain points of difference are to be noted. An attempt was made to reexamine all the surviving infants in the series of a thousand cases but the practical difficulties in carrying out such an investigation made it impossible to do so in many cases. A fair number of negative cases were dealt with, and, in order to supplement the small number of positive cases available, certain others not originally included in the series were added. In this way it has been possible to reexamine 181 children and their mothers at periods varying from three weeks to twenty months after their birth. The following results have been obtained:-

1. In eighty-five cases reexamined between ten and twenty months after delivery the Wassermann reaction in the blood of both mother and child remained negative as it had been originally.

2. In forty-four cases in which the blood had given a strongly positive Wassermann reaction at

birth there was a negative reaction when the child was reexamined at periods varying from three weeks to twenty months after birth. In thirty-eight cases the mother's reaction remained positive, in three it was doubtful, and in three it had changed from positive to negative.

3. There were four cases in which there was a strongly positive reaction at birth and a strongly positive reaction in both mother and child when reexamined at periods varying from seven weeks to nineteen months afterwards.

4. There were eight cases in which the blood at the time of delivery gave a clearly negative reaction, while from fifteen to sixteen months afterwards the mother's blood was weakly or doubtfully positive though the child's blood was still negative. In two of the cases, however, there was a trace of inhibition with 3 m.h.d. in the test of the child's blood on the latter occasion.

5. There was one case in which the mother's blood had been examined more than six months before delivery and gave a clearly negative reaction. The child was born at home and was not examined until it was nine months old. At that time it gave a negative reaction, while in its mother's blood, examined on the same date, the reaction was doubtfully positive (3+5-). In a second case the mother's blood gave a

negative reaction nearly two months before delivery, the child was not seen at birth but sixteen months afterwards its blood as well as the mother's gave a strongly positive reaction.

6. There were seven cases in which the mother's reaction was positive and the child's was a clear negative at birth. In all of them, on reexamination at periods varying from twelve days to ten months afterwards, the reactions were found to be the same as on the first occasion. In addition, there was one case in which the mother's blood gave a strongly positive reaction and the child's a doubtfully negative reaction at birth, while on reexamination seven months later the mother's reaction was still strongly positive but the child's was a clear negative.

7. There were nine cases in which the mother's reaction was positive or strongly positive about the time of delivery but negative when reexamined at a later date, and in six of these cases the child's reaction was negative at birth. The remaining three infants were not examined at this time, but in all nine cases the child's reaction was negative when the blood was tested from one to fourteen months after birth.

8. There were nine cases in which the mother's reaction was weakly or doubtfully positive about the time of delivery, but was negative when the case

was reexamined at a later date. In three instances the child's reaction was negative at birth, in one it was positive, and in five the blood was not examined. In every one of these nine cases the child's blood gave a negative reaction when examined from one to thirteen months after birth.

9. There were two cases in which both mother and child gave a clearly negative reaction at the time of delivery, while fourteen and sixteen months later the mother's reaction was doubtful. In one of these cases the child's reaction was also doubtful, but in the other it was still clearly negative.

10. Of the fifty-one cases in which there was a strongly positive reaction in the mother or child, or in both at the time of delivery, a negative reaction was found in forty-seven of the children and a positive reaction in four of the children on reexamination. In this (admittedly small) series only 8 per cent of the children giving a positive reaction at birth showed any evidence of a positive reaction afterwards. The youngest child in which this positive reaction persisted was aged seven weeks, and the three others were aged ten, fourteen, and nineteen months respectively. The cases which were found to have become negative included one child aged twenty-three days, one aged six weeks, one seven weeks, and one eight weeks, while the remainder

were all over two months old. Of the 111 children who gave a negative reaction at birth not one gave a positive reaction when reexamined, but two gave a doubtful reaction.

Dealing first with the value of the Wassermann reaction in the new-born, one may sum up the evidence as follows. There is a widespread disinclination to accept the results of the Wassermann reaction in the infant as reliable. While most workers regard a positive result as valuable evidence in favour of the presence of syphilitic infection in the infant, it is agreed that where the reaction fails is that it does not detect a certain proportion of cases. To what extent negative reactions are obtained in infants which later prove to be syphilitic is not so clear. In general terms one may say that the value of a negative reaction in the new-born is considerably less than the value of a similar reaction in the adult or even in older children. Apart from the results of others, the present writer has found that in the cases which he has examined the variations between the reaction at birth and the reaction during the first year of life are so great as to make it advisable to carry out the test in the blood of the mother as well as in that of the child at birth.

The objection has been raised that the Wassermann in the infant does not agree with that of the mother (see Fildes and others). This has not been borne out by the results of the present investigation, however, for the

reaction of the mother's blood and of the placental blood agreed in 94.6 per cent of cases in the series. From Table iv. it will be seen that the result of the test was the same in both mother and child in 387 of the 408 cases in which both were examined. In 13 cases (3.2 per cent) the mother's blood gave a positive reaction and the child's (placental) blood a negative reaction, in 6 cases (1.5 per cent) the reaction was doubtful in the mother and negative in the child, and in 1 case the child's reaction was doubtful and the mother's negative. The mother's blood in one case gave a negative reaction, while the child's blood gave a positive reaction. On inquiry it was found that this woman had been receiving anti-syphilitic treatment during her pregnancy, and that the last of a series of intravenous injections had been given less than one month before delivery. These results show a very close agreement between the Wassermann reaction in the mother and in the child at birth.

While these figures show clearly that the agreement between the Wassermann reaction in the mother and that in the child is a close one, and that the main differences that occur are due to a tendency for a comparatively small number of the children of positive mothers to give a negative reaction at birth, there still remains for consideration the question of the interpretation of the results of Wassermann tests in the blood of the new-born. Is the occurrence of a positive reaction to be regarded as due simply to a transference of the mother's reacting

substances to the foetal circulation, or is one justified in concluding that a positive or a negative reaction in the blood of the infant at birth is a safe guide as to whether the child is or is not syphilitic?

From the above results one may conclude

(a). that in the series of cases examined all the children which at birth gave a negative Wassermann reaction continued to do so from ten to twenty months afterwards.

(b). that of the children in this series who at birth gave a positive reaction the great majority gave a clearly negative reaction when reexamined from three weeks to twenty months afterwards.

(c). that there is a small group of cases in which the mother's reaction was positive or doubtfully positive at the time of delivery but subsequently became negative or doubtfully negative; and that in these cases the child was born with a negative or a doubtful reaction, and when reexamined during the first year of life it was found to be negative.

The close agreement between the Wassermann reaction in the mother and in the child at birth, the persistence of a negative reaction in the cases where one was originally present, and the disappearance of a positive reaction in the majority of infants in whose blood such a reaction was obtained at birth all point to the conclusion that the Wassermann reaction in the new-born is of little value in

Fig. 3.

Incidence of Congenital Syphilis.

1. Epstein, Prague. (Clinical.)
2. Watson, Glasgow. (Wassermann)
3. Browning, Glasgow. (Wassermann)
4. Elliott, Glasgow. (Wassermann)
5. Jeans & Cooke. (Placental W.R.)
6. Williams, Baltimore. (? clinical & Pathological)
7. Churchill & Austin. (Wassermann)
8. Ross & Wright, (Wassermann)
9. Churchill & Austin. (Wassermann)
10. Adair, (Wassermann)
11. Lee. (Clinical.)
12. Fruhinsholz. (Clinical; 17,282 cases.)
13. Newman & Oberwarth, (Clinical; 69,221 cases.)
14. Cassell, (Clinical; 17,448 cases.)
15. Still, (Clinical; 4830 cases.)
16. Fildes, (Clinical & Pathological.)

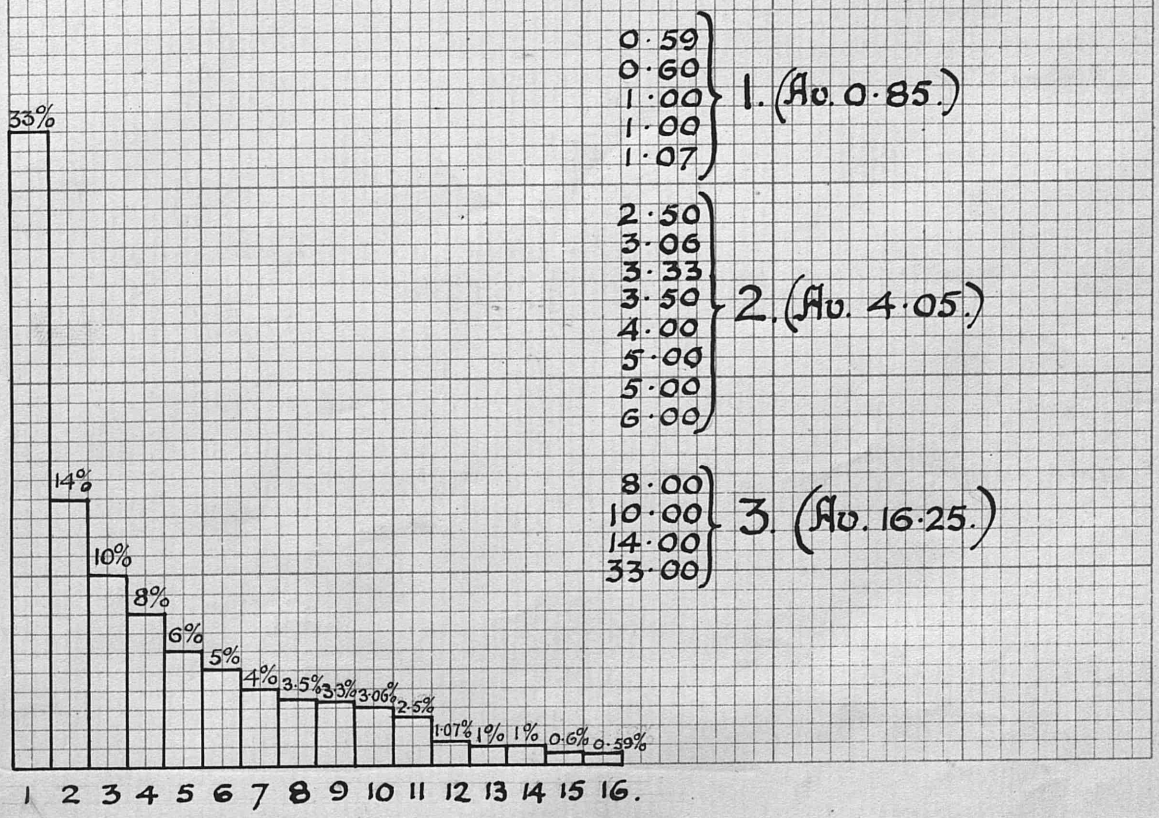

proving the presence of congenital syphilis. The appearances suggest that in most cases a positive reaction in the infant's blood at birth is due, as Fildes maintains, to the transference to the foetal blood of reacting substances. From the above facts, as well as from the clinical examination of the infants included in the present series of cases, it would appear that the incidence of congenital syphilis has been greatly exaggerated by most recent writers, and that the estimate of under one per cent, made by many authorities, such as Still, Fruhinsholz and Cassell, is nearer the truth. At the same time the question of latent syphilis has to be considered, and further observation is required to exclude the possibility of lues tarda developing.

7. The effects of Syphilis on the incidence of Abortion, Premature Birth and Still-birth.

The idea that a history of repeated still-birth and abortions is a certain diagnostic sign of syphilitic infection has been handed down by tradition for so long that it has almost been accepted as an axiom. Of recent years, however, there has been a tendency to doubt whether syphilis is really such an important factor in the causation of abortion and still-birth as formerly was supposed. For this reason an attempt has been made to estimate in the present study the part which syphilitic

infection in the mother plays in the production of abortion, premature birth and still-birth. In doing so it was found to be difficult to discover what was recognised as the average incidence of abortion in the population generally for the estimates of different authorities vary considerably. One of the reasons for such discrepancies is that some investigators differentiate between early abortion, late abortion, premature birth and still-birth, while others do not make these distinctions. Another difficulty in making such an estimate is the fact that many of the interruptions of pregnancy in the earlier stages pass unnoticed or at least fail to be recorded in subsequent inquiries.

There is a good deal of evidence to be obtained from the results of older writers to show that about thirty per cent of all pregnancies end in abortion or miscarriage, but later writers tend to give much lower figures. De Lee considers that approximately six and a half per cent of pregnancies are prematurely interrupted, and he includes in this estimate a little over four per cent of abortions (i.e. abortions and "miscarriages") and a little over two per cent of premature births. Routh estimates the total annual loss of foetal life by abortion (including miscarriage) at 8.8 per 100 live births.

With regard to the incidence of still-birth there are also marked differences of opinion, and here again

the question of the type of material selected for investigation must play an important part in influencing the result. In figures based on the admissions to a maternity hospital where the proportion of cases of delayed and complicated labour is enormously greater than the proportion of abnormal labours in the general population, the incidence of still-birth must be much too high. Routh estimates the total loss of foetal life by still-birth in the population generally as 2.2 per 100 live births, and five American workers, quoted by Jeans, consider that approximately five per cent of all births are still-births.

In the cases composing the present series the incidence of still-birth was found to be 11.4 per cent of a thousand pregnancies, while in 12.8 per cent of these pregnancies there was abortion or miscarriage. This gives a total incidence of still-birth and abortion[1] of 24.2 per cent of a thousand pregnancies actually observed. An examination of the obstetrical histories of the thousand mothers shows that in a total of 3,039 pregnancies there were 11.4 per cent of still-births and 8.4 per cent of abortions. As an illustration of the difficulty of drawing general conclusions from such

---

[1] Except where otherwise stated, the word abortion will be employed below to describe any interruption of pregnancy before the seventh lunar month.

findings it is interesting to note that during the whole year 1920 (a part of which is covered by the present investigation) of a total of 2,467 births in the hospital there were 15.6 per cent of still-births, while in the previous year (1919) out of 1,790 deliveries there were 18.5 per cent of still-births.

Apart from the actual incidence rate of abortion the proportion of abortions to still-births in the present series of cases is considerably lower than the commonly accepted one, but this discrepancy can, I think, be accounted for by the fact that in this hospital the admission of cases of abortion is strictly limited to Threatened Abortion and non-septic Incomplete Abortion. If allowance be made for such modifying factors as this, it will be admitted that statistics, if drawn from hospital admissions without selection of cases, while of little value as an indication of the actual incidence of abortion and still-birth, do give some indication of the relative incidence of abortion or still-birth in syphilitic and non-syphilitic women of the hospital class.

Attention has already been drawn to the recent tendency to doubt whether syphilis is really such a common factor in the causation of abortion and still-birth as formerly was supposed. Findlay in his book " Syphilis in Childhood" says:- " to accept that still-births and miscarriages per se are evidence of a mother being syphilitic will lead to serious error. In

all probability the presence of (a miscarriage or still-birth) in a syphilitic family (may) be taken as evidence of infection of the foetus" . In ninety-seven syphilitic families under Findlay's care, 19 per cent of 427 pregnancies ended in still-birth or abortion. In nineteen definitely non-syphilitic families also under his observation 19 per cent of 123 pregnancies ended in still-birth or abortion. This series is not a very large one, but the results are in agreement with those of Adair (quoted below) and to a certain extent with those of the present writer.

In contrast to the results of Findlay's investigation of this point one might quote a number of opposite ones. For example, Veeder found that of 331 pregnancies in syphilitic families 40 per cent of the foetuses died before term, while in another series of 453 pregnancies in syphilitic families the ante-natal death rate was 25.6 per cent. In two control series of 886 pregnancies in unselected families the ante-natal death rate was just under ten per cent.

Perhaps the most valuable investigation of this question hitherto published is the work of Adair (Am. J. of Obstr., 1918). He examined a series of 1,095 women and found that:-

1. 30.6 per cent of pregnancies in women with negative W.R. ended in abortion.

2. 31.08 per cent of pregnancies in women with positive W.R. ended in abortion.

From this he concluded that since in both groups the incidence of abortion is approximately one in every three pregnancies, syphilis is not an important factor in producing abortion in the first three months.

With regard to miscarriage Adair found that:-

1. 30.7 per cent of pregnancies in women with negative W.R. ended in miscarriage.

2. 30.4 per cent of pregnancies in women with evidence of syphilis ended in miscarriage.

From this he concluded that syphilis has little influence on the incidence of abortion during the second three months of pregnancy since the incidence in both syphilitic and non-syphilitic groups is approximately the same.

The most striking fact brought out by the study of these cases of Adair's is with regard to premature births and still-births. In this series he found that:-

1. The incidence of syphilis in 857 women was estimated at 6.2 per cent.

2. The incidence of syphilis in the mothers of premature infants in the series was estimated at 30 per cent.

3. The incidence of syphilis in the mothers of still-born infants was estimated at 10 per cent.

He concludes, therefore, that, while syphilis is not responsible for a large proportion of the interruptions of pregnancy in the first six months, it is the commonest

single cause of premature births and still-births. While the actual frequency of premature terminations of pregnancy in Adair's series is perhaps unusually high, the relation of the incidence of these abnormalities to the presence or absence of syphilis is in close agreement with the results of the present investigation.

Results of the present study with regard to Syphilis in the Mother as a factor in the etiology of Abortion, Premature Birth and Still-birth.

i. ABORTION (i.e. pregnancy ending before the seventh lunar month).

Of one thousand pregnancies observed in one thousand women 128 ended in abortion. There were 94 mothers in the series whose Wassermann reaction was positive, and the pregnancy of six of these ended in abortion. There were 889 mothers whose W.R. was negative and the pregnancy of 122 of these ended in abortion. The incidence of abortion, as shown by these figures, would appear to be 6.17 per cent for the negative group, but the number of positive cases in which abortion occurred forms too small a series for any importance to be attached to this difference. At most it may be said that there was no greater incidence of abortion in the positive group than in the negative group.

ii. STILL-BIRTH.

Before considering the question of premature birth, it will be more convenient to deal with still-birth. The following figures with regard to still-birth refer to those pregnancies observed in the series of one thousand women which were not interrupted before the commencement of the seventh lunar month. Of one thousand pregnancies observed, 114 ended in the birth of a dead viable foetus (11.4 per cent). In fifteen of these 114 cases the mother had a positive Wassermann reaction, while in the remaining ninety-nine cases the mother's W.R. was negative. In estimating the incidence of still-birth in the series, the cases which ended in abortion ought not to be included, so that the basis of the percentage should be 737 cases in which a viable child was born, and not the entire series of 1000 cases. Making this adjustment, it is seen that of the 737 pregnancies in which a viable foetus was delivered, there were 114 still-births (equivalent to 15.46 per cent). There were 83 women with a positive Wassermann reaction whose pregnancy ended in the birth of a viable infant, and the incidence of still-birth in this positive group was 15 (equivalent to 18.07 per cent). There were 654 women with a negative W.R. whose pregnancy ended in the birth of a viable infant, and the incidence of still-birth in this negative group was 99 (equivalent to 15.15 per cent). It is seen from the above figures that

still-birth occurred in the series with slightly greater frequency amongst syphilitic women than amongst non-syphilitic women; and this, it is to be noted, is in a collection of cases containing an unusually high proportion of abnormal labours.

iii. ABORTION AND STILL-BIRTH.

If the results with regard to abortion and still-birth be considered together, it will be seen that of the one thousand pregnancies in the series 623 (62.2 per cent) ended in the birth of a live child. In the group of mothers with a positive Wassermann reaction (94 cases) the percentage of live births was 72.4 while in the negative group (889) the percentage of live births was 62.42. (This curious result appears to be due to the higher incidence of abortion amongst women with a negative Wassermann reaction - a point commented upon above). The total incidence of abortion and still-birth in the whole series of one thousand cases was 242 (24.2 per cent). Of these 242 mothers 221 had a negative W.R., while in 21 the reaction was positive. In the whole series the mother's W.R. was positive in 94 cases and negative in 889 cases. In the positive group, therefore, the incidence of abortion and still-birth was 22.58 per cent, while in the negative group it was 24.94 per cent.

Comment:- The above analysis of results with regard to the incidence of abortion and still-birth in the positive

and negative groups of mothers shows that in the present series of cases the two conditions together occurred with almost equal frequency in syphilitic and non-syphilitic women. The greater incidence of abortion in the negative than in the positive group is rather difficult to account for unless it be due to the degree of selection in the type of abortion case admitted to the hospital. The small number of abortions actually occurring in the group has been commented upon above. At any rate the conclusion seems justified that abortion is not more frequent amongst syphilitic than amongst non-syphilitic women in the series.

The greater incidence of still-birth in the positive group as compared to the negative group is remarkable - particularly when it is remembered how many of the cases were sent into hospital on account of obstetrical complications. Even without making allowance for this, and still more so if such allowance be made, it is clear that in the present series of cases still-birth is distinctly more common in syphilitic than in non-syphilitic women. Both these results are in agreement with the conclusions of Jeans and of Adair to whose work reference has already been made.

Relation between Syphilis in the Mother and the incidence of Premature Birth.

From an analysis of Table Vll it is seen that of the 737 viable infants born in the series of one thousand pregnancies, 580 (78.69 per cent) were born approximately at term, while 157 (21.30 per cent) were born prematurely. In other words, 15.7 per cent of one thousand pregnancies ended in the birth of a premature but viable child. Of the 83 viable infants born to mothers with a positive W.R. 56 (67.46 per cent) were born at term and 27 (32.54 per cent) were born prematurely.

It is thus shown that, whereas the incidence of premature birth amongst the viable infants of mothers with a negative W.R. was only 19.88 per cent, the incidence of premature birth amongst the infants of mothers with a positive W.R. was as high as 32.54 per cent. This figure illustrates in a remarkable way the importance of syphilis as a cause of premature birth.

The point is further illustrated by the following result:- Of the 130 premature children born to mothers with a negative W.R. 45 (34.61 per cent) were still-born, but of the 27 premature infants born to mothers with a positive W.R. 11 (68.75 per cent) were still-born.

Relation between Abortion, Premature Birth and Still-birth, and the presence of Syphilis in the Mother.

Taking the three conditions together - Abortion, Premature Birth and Still-birth - one is able to realise what I take to be the true significance of their relation to syphilis in the mother. It has been pointed out above, with reference to the present series of cases, that if abortion and still-birth are grouped together the incidence of the combined group shows little difference in syphilitic as compared with non-syphilitic mothers (22.58 per cent and 24.94 per cent respectively). The incidence of still-birth taken by itself has been shown to be somewhat greater in the syphilitic than in the non-syphilitic groups in this series (18.07 per cent and 15.15 per cent respectively). It is the analysis of the figures with regard to PREMATURE births, however, which reveals the most important effect of syphilis in the production of ante-natal and neo-natal death. As has been noted above, 19.88 per cent of the viable infants born to non-syphilitic mothers were premature, while of the viable infants of syphilitic mothers 32.54 per cent were born prematurely. Of these premature infants 34.61 per cent were still-born in the non-syphilitic group, and 68.75 per cent were still-born in the syphilitic group. It is, then, as a cause of premature still-birth that syphilis is of greatest importance in the later months of pregnancy.

Summary:- The results of the present investigation confirm the view advanced by several recent writers on the subject that syphilis is one of the most important causes of still-birth and of interruptions of pregnancy in its later months, leading to premature birth, and, more particularly, to premature birth with death of the foetus. Syphilis in the mother, however, cannot be shown to be a factor of predominating importance in the etiology of the interruptions of pregnancy in the earlier months.

8. Relation between Syphilis in the Mother and the occurrence of Ante-partum and Post-partum Haemorrhage.

In the whole series of one thousand pregnancies upon which the present study is based there were 66 cases of ante-partum and post-partum haemorrhage. Of these 66 cases there was Accidental Haemorrhage in twenty-four, Unavoidable Haemorrhage in twenty-three and Post-partum Haemorrhage in twenty-one. A better idea of the relationship between syphilitic infection in the mother is obtained if the rate of incidence is based not on the whole series, but on the 737 cases in which the pregnancy did not end before the seventh lunar month. It is then seen that in 737 pregnancies ending in the birth of a viable infant, Accidental Haemorrhage occurred in twenty-four patients (3.25 per cent of 737), Unavoidable Haemorrhage in twenty-three (3.12 per cent) and Post-partum Haemorrhage (apart from Placent Praevia) in twenty-one (2.84 per cent). The total number of cases of Maternal Haemorrhage - excluding Abortion - was 66 or 8.94 per cent of 737 pregnancies.

Of these 66 cases of Haemorrhage three were associated with a positive Wassermann reaction in the mother, and in the remaining 63 cases the mother's blood was negative. Of the 737 pregnancies which ended in the birth of a viable infant the mother's W.R. was positive in 83 instances, and of these 83 pregnancies only three were complicated by haemorrhage (i.e., 3.61 per cent of 83). Of the 654 cases

in which the mother's W.R. was negative haemorrhage occurred in 63 (i.e., 9.63 per cent of 654).

Of the twenty-four cases of Accidental Haemorrhage two were associated with a positive W.R. in the mother while in the remaining twenty-two cases the mother's W.R. was negative. Of 737 pregnancies ending in the birth of a viable foetus the mother's W.R. was positive in 83 cases, and of these 83 pregnancies only two were complicated by Accidental Haemorrhage. In the 654 cases in which the mother's W.R. was negative, 22 were complicated by this form of bleeding (22 = 3.36 per cent of 654).

Of the twenty-three cases of Unavoidable Haemorrhage one was associated with a positive W.R. in the mother while in the remaining twenty-two cases the mother's W.R. was negative. Of 737 pregnancies ending in the birth of a viable foetus there was a positive W.R. in the mother in eighty-three cases. Of these eighty-three cases only one (= 1.20 per cent) was complicated by Unavoidable Haemorrhage. While of the 654 cases in which the mother's W.R. was negative Unavoidable Haemorrhage occurred in twenty-two (22 = 3.36 per cent).

In all of the twenty-one cases of Post-partum haemorrhage (apart from those cases occurring in association with Placenta Praevia) there was a negative W.R. in the mother. Of 737 pregnancies ending in the birth of a viable foetus there was a negative W.R. in the

mother in 654 cases. Post-partum Haemorrhage in twenty-one (= 3.21 per cent of 654) and in no case was the mother's W.R. positive.

SUMMARY:- (See Table ix).

1. The incidence of Ante-partum and Post-partum Haemorrhage was 6.6 per cent in the whole series of cases and 8.94 per cent of the cases in which the pregnancy ended in the birth of a viable foetus.

2. In pregnancies ending in the birth of a viable foetus Ante-partum and Post-partum Haemorrhage occurred in 3.61 per cent of the group in which the mother's W.R. was positive and in 9.63 per cent of the group in which the mother's W.R. was negative.

3. In pregnancies ending in the birth of a viable foetus Accidental Haemorrhage occurred in 2.40 per cent of the positive W.R. group and in 3.36 per cent of the negative W.R. group. The incidence of Accidental Haemorrhage in the whole series of one thousand cases was 2.4 per cent.

4. In pregnancies ending in the birth of a viable foetus Unavoidable Haemorrhage occurred in 1.3 per cent of the positive group and 3.36 per cent in the negative group. The incidence of Unavoidable Haemorrhage in the whole series of one thousand cases

was 3.3 per cent.

5. In pregnancies ending in the birth of a viable foetus Post-partum Haemorrhage occurred in 3.21 per cent of the negative group and there were no cases in the positive group. The incidence of Post-partum Haemorrhage in the whole series of one thousand cases was 2.1 per cent.

It is concluded, therefore, that in the cases examined, syphilis was not a common predisposing factor in the occurrence of Accidental Haemorrhage, Unavoidable Haemorrhage or Post-partum Haemorrhage.

9. Relation between Syphilis in the Mother and the occurrence of Eclampsia.

In the series of one thousand cases there were thirty-four women who were eclamptic. In addition, there were many cases of the lesser degrees of toxaemia, hyperemesis gravidarum, nephritis and so forth, but these are not considered here. The thirty-four cases dealt with all showed typical eclamptic convulsions either before or after delivery. If we consider only the 737 women whose pregnancy ended in the birth of a viable foetus, the incidence of eclampsia is found to be 4.61 per cent. Among the eighty-three mothers whose W.R. was positive there were three cases of eclampsia (equivalent to 3.61 per cent), while among the 654 negative mothers the incidence of eclampsia was 31 (equivalent to 4.74 per cent).

From these figures it is concluded that in the present series of one thousand cases syphilis was not an important factor in the etiology of Eclampsia.

10. The relation between Syphilis in the Mother and Post-Natal Mortality in the Infant.

Of 623 infants born alive 555 were children of mothers whose blood gave a negative Wassermann reaction, and 68 were the children of mothers whose blood gave a positive Wassermann reaction. In following up the after history of these infants a constant difficulty was the fact that many of the patients disappeared after dismissal so that no further information with regard to them could be obtained. Thus, for example, it was found that of the original 623 cases there were 112 of whom no trace could be found at the end of the first month. Since the average stay in the Hospital of all patients is 11 days - and many of the cases in the series spent a considerably longer periods in the wards - it may be taken that accurate figures as to the infant death rate are obtainable for the first fourteen days of life. In the series of 623 cases at present under consideration there was a total death rate during the first fourteen days of life of 61 (equivalent to 9.79 per cent). Of these 61 deaths 53 were children of mothers with a negative Wassermann reaction and 8 were children of mothers with a positive Wassermann reaction. Since there were 555 mothers in the former group and 68 mothers in the latter group, it follows that the infant death rate during the first fortnight of life was 9.54 per cent in the negative

group and 11.76 per cent in the positive group.

Deducting those cases which died during the first fortnight of life, there were 562 infants which were known to be alive at the end of the first fortnight of life. During the second fortnight of life all trace was lost of 112 of these children and 29 (equivalent to 6.55 per cent of 450) are known to have died, so that at the end of the first month there were 421 living children who could still be traced. During the second month of life 6 children in the negative group and 1 in the positive group were lost sight of, leaving a total of 414 children known to be alive. Of these 362 children were in the negative group and 52 were in the positive group. During the second month of life 13 deaths occurred, giving a rate equivalent to 3.14 per cent - 3.04 per cent of the negative group and 3.84 per cent of the positive group died during this second month period.

At the beginning of the third month 401 children were definitely known to be alive but 5 were lost trace of during the third month, and there were thus 396 children about whom information was available during the third month of life. Of these children 8 died - a death rate equivalent to 2.02 per cent - and it is interesting to note that while in the negative group the death rate was 1.73 per cent, it was as high as 4.08 per cent in the positive group.

Throughout the succeeding months - up till the end of the seventeenth - corrections in the totals have been made in a similar manner as to allow for those cases of which no further trace could be found. These corrections are shown in detail in Table so that it will be sufficient to refer simply to the death rate in each of the following months. During the fourth month there was a death rate of 1.84 per cent, composed of 1.18 per cent in the negative group and 6.97 per cent in the positive group. In the fifth month the death rate was .54 per cent, there being two deaths (equivalent to .60 per cent) in the negative group and no deaths amongst the 39 surviving children in the positive group. In the sixth month the death rate was 0.83 per cent (0.62 per cent in the negative group and 2.70 per cent in the positive group). In the seventh month the death rate was 0.56 per cent - there being .62 per cent of deaths in the negative group and none in the positive group of 36 cases. In the eighth month the death rate was 1.13 per cent (0.94 per cent in the negative group and 2.78 per cent in the positive group). In the ninth month the death rate was 0.28 per cent, there being one death in the negative group and none in the positive group. There were no deaths during the tenth month, but during the eleventh month two children in the negative group died, giving a death rate of 0.60 per cent of the total 334 surviving children. During the twelfth month four

children in the negative group died (equivalent to 1.24 per cent of the total). In the thirteenth month there were two deaths amongst the children in the negative group and again none in the positive group, giving a death rate of 0.68 per cent. In the fourteenth month the death rate was 1.79 per cent (1.61 per cent in the negative group and 3.22 per cent in the positive group). In the fifteenth month one child in the negative group died, giving a death rate of 0.37 per cent. In the sixteenth month there were three deaths amongst the negative children, giving a death rate of 1.13 per cent, and in the seventeenth month one death occurred amongst the negative and two amongst the positive children, leaving a total of 262 children still definitely known to be alive - 234 being in the negative group and 28 in the positive group. During the course of the investigation 35 per cent of the original negative group had been lost trace of and 25 per cent of the original positive group. These results are perhaps more clearly shown when the month periods are grouped together as in the following summary:-

Percentage Death Rate as in the following Table:-

	Negative Group.	Positive Group.
During first month	8.22%	9.60%
Beginning of second to end of third month	2.45%	3.95%
Beginning of fourth to end of sixth month	.80%	3.68%
Beginning of seventh to end of twelfth month	.84%	1.30%
Beginning of thirteenth to end of seventeenth month	.89%	1.92%

11. TABULATED RESULTS OF WASSERMANN REACTIONS.

" 1000 SERIES" TABLES.

TABLE 1.

Number of Mothers examined	1000	
Number of mothers with W.R. positive	94	9.40%
Number of mothers with W.R. negative	889	88.90%
Number of mothers with W.R. doubtful	17	1.70%

TABLE 11.

Number of married mothers examined	785	
Number of married mothers with W.R. positive	70	8.91%
Number of married mothers with W.R. negative	705	89.80%
Number of married mothers with W.R. doubtful	10	1.27%
Number of single mothers examined	215	
Number of single mothers with W.R. positive	24	11.16%
Number of single mothers with W.R. negative	184	85.58%
Number of single mothers with W.R. doubtful	7	3.25%

TABLE 111.

Number of Infants examined (placental blood)	408	
Number of infants examined with W.R. positive	26	6.35%
Number of infants examined with W.R. negative	381	93.15%
Number of infants examined with W.R. doubtful	1	.24%

TABLE IV.

Number of cases in which W.R. of mother only was done	592	
Percentage of 1000 cases in which W.R. of mother only was done		59.20
Number of cases in which W.R. of both mother and child was done	408	
Percentage of 1000 cases in which W.R. of both mother and child was done		40.80
Number of cases in which W.R. of both mother and child was positive	25	
Percentage of 408 cases in which W.R. of both mother and child was done, and in which both was positive		6.12
Number of cases in which W.R. of both mother and child was negative	362	
Percentage of 408 cases in which W.R. of both mother and child was done, and in which both was negative		88.70
Number of cases in which W.R. of mother was positive and W.R. of child was negative	13	
Percentage of 408 cases in which W.R. of both mother and child was done, and in which the mother's W.R. was positive and the child's was negative		3.18
Number of cases in which W.R. of mother was negative and W.R. of child was positive	1	
Percentage of 408 cases in which W.R. of both mother and child was done, and in which the mother's W.R. was negative and the child's was positive		.24
Number of cases in which W.R. of mother was doubtful and W.R. of child was positive	0	
Number of cases in which W.R. of mother was doubtful and W.R. of child was negative	6	

TABLE IV. (contd.)

Number of cases in which W.R. of both mother and child was doubtful	0	
Number of cases in which W.R. of mother was positive and W.R. of child was doubtful	0	
Number of cases in which W.R. of mother was negative and W.R. of child was doubtful	1	
Number of cases in which W.R. of both mother and child was the same	387	
Percentage of 408 cases in which W.R. of both mother and child was done, and in which both was the same		94.60
Number of cases in which W.R. of mother and W.R. of child differ	21	
Percentage of 408 cases in which W.R. of both mother and child was done, and in which they differ		5.14

TABLE V.

Number of mothers whose pregnancy ended in the birth of a live child	623	
Percentage of 1000 mothers whose pregnancy ended in the birth of a live child		62.3
Number of mothers whose W.R. was positive and whose pregnancy ended in the birth of a live child	68	
Percentage of total 94 mothers with positive W.R. whose pregnancy ended in the birth of a live child		72.04
Number of mothers with negative W.R. whose pregnancy ended in the birth of a live child	555	
Percentage of 889 mothers with negative W.R. whose pregnancy ended in the birth of a live child		62.42

TABLE VI.

Number of mothers whose pregnancy ended in stillbirth	114	
Percentage of total 1000 mothers whose pregnancy ended in stillbirth		11.4
Number of mothers whose pregnancy ended in abortion	128	
Percentage of total 1000 mothers whose pregnancy ended in abortion		12.8
Number of mothers whose pregnancy ended in stillbirth or abortion	242	
Percentage of total 1000 mothers whose pregnancy ended in stillbirth or abortion		24.2
Number of mothers whose W.R. was positive and whose pregnancy ended in stillbirth	15	
Percentage of total 94 mothers whose W.R. was positive and whose pregnancy ended in stillbirth		16.12
Number of mothers whose W.R. was positive and whose pregnancy ended in abortion	6	
Percentage of total 94 mothers whose W.R. was positive and whose pregnancy ended in abortion		6.17
Number of mothers whose W.R. was positive and whose pregnancy ended in stillbirth or abortion	21	
Percentage of total 94 mothers whose W.R. was positive and whose pregnancy ended in stillbirth or abortion		22.58
Number of mothers whose W.R. was negative and whose pregnancy ended in stillbirth	99	
Percentage of total 889 mothers whose W.R. was negative and whose pregnancy ended in stillbirth		11.12
Number of mothers with W.R. negative whose pregnancy ended in abortion	122	

TABLE V1. (contd.)

Percentage of total 889 mothers with W.R. negative whose pregnancy ended in abortion		13.71
Number of mothers with W.R. negative whose pregnancy ended in stillbirth or abortion	221	
Percentage of total 889 mothers with W.R. negative whose pregnancy ended in stillbirth or abortion		24.94

TABLE V11.

Total number of viable infants born	737	
Total number of children born at term	580	
Percentage of 737 infants which were born at term		78.69
Total number of infants born prematurely	157	
Percentage of 737 infants which were born prematurely		21.31
Total number of viable infants born whose mother had a positive W.R.	83	
Total number of viable infants born whose mother had a negative W.R.	654	
Total number of infants born alive at term	522	
Percentage of 623 infants born alive at term		83.79
Total number of children born alive at term whose mother had a positive W.R.	52	
Percentage of 522 infants born alive at term whose mother had a positive W.R.		9.96
Total number of infants born alive at term whose mother had a negative W.R.	470	

TABLE V11 (contd.)

Percentage of 522 infants born alive at term whose mother had a negative W.R.		90.04
Total number of infants stillborn at term	58	
Percentage of 114 infants stillborn at term		50.88
Total number of infants stillborn at term whose mother had a positive W.R.	4	
Percentage of 58 infants stillborn at term whose mother had a positive W.R,		6.90
Total number of infants stillborn at term whose mother had a negative W.R.	54	
Percentage of 58 infants stillborn at term whose mother had a negative W.R.		93.10
Total number of viable infants born alive prematurely	101	
Percentage of 623 infants born alive prematurely		16.21
Total number of viable infants born alive prematurely whose mother's W.R. was positive	16	
Percentage of 101 viable infants born alive prematurely whose mother's W.R. was positive		15.85
Total number of viable infants born alive prematurely whose mother's W.R. was negative	85	
Percentage of 101 viable infants born alive prematurely whose mother's W.R. was negative		84.5
Total number of viable infants stillborn prematurely	56	
Percentage of 114 viable infants stillborn prematurely		49.12

TABLE V11 (contd.)

Total number of viable infants stillborn prematurely whose mother's W.R. was positive	11	
Percentage of 56 viable infants stillborn prematurely whose mother's W.R. was positive		19.64
Total number of viable infants stillborn prematurely whose mother's W.R. was negative	45	
Percentage of 56 viable infants stillborn prematurely whose mother's W.R. was negative		80.36

RELATION OF LIVE-BIRTH AND STILL-BIRTH TO THE WASSERMANN REACTION IN THE MOTHER.

TABLE V111.

Number of pregnancies which ended in live birth	623	
Percentage of 1000 pregnancies which ended in live birth		62.3
Number of pregnancies which ended in still-birth	114	
Percentage of 1000 pregnancies which ended in still-birth		11.4
Number of pregnancies which ended in live or in still-birth	737	
Percentage of 1000 pregnancies which ended in live or in still-birth		73.7
Number of pregnancies which ended in live birth in which the W.R. of the mother was negative	555	
Number of pregnancies which ended in still-birth in which the W.R. of the mother was negative	99	

TABLE V111 (contd.)

Number of pregnancies which ended in live or in still-birth in which the W.R. of the mother was negative	654	
Percentage of 737 pregnancies which ended in live or in still-birth in which the W.R. of the mother was negative		88.73
Percentage of total 889 mothers with negative W.R. whose pregnancy ended in live or in still-birth		73.56
Number of mature live births in which the W.R. of the mother was negative	470	
Number of mature still-births in which the W.R. of the mother was negative	54	
Number of mature live and still-births in which the W.R. of the mother was negative	524	
Percentage of 580 mature live and still-births in which the W.R. of the mother was negative		90.34
Number of premature live births in which the W.R. of the mother was negative	85	
Number of premature still-births in which the W.R. of the mother was negative	45	
Number of premature live and still-births in which the W.R. of the mother was negative	130	
Percentage of 157 premature live and still-births in which the W.R. of the mother was negative		82.80
Number of mature live births in which the W.R. of the mother was positive	52	
Number of mature still-births in which the W.R. of the mother was positive	4	
Number of mature live and still-births in which the W.R. of the mother was positive	56	
Percentage of 580 mature live and still-births in which the W.R. of the mother was positive		9.66

TABLE V111 (contd.)

Number of pregnancies which ended in live birth in which the W.R. of the mother was positive	68	
Number of pregnancies which ended in still-birth in which the W.R. of the mother was positive	15	
Number of pregnancies which ended in live or in still-birth in which the W.R. of the mother was positive	83	
Percentage of 737 pregnancies which ended in live or in still-birth in which the W.R. of the mother was positive		11.26
Percentage of total 94 mothers with positive W.R. whose pregnancies ended in live or in still-birth		88.29
Number of mature live births	522	
Number of mature still-births	58	
Number of mature live and still-births	580	
Percentage of 1000 pregnancies which ended in mature birth		58.0
Number of premature live births	101	
Number of premature still-births	56	
Number of premature live and still-births	157	
Percentage of 1000 pregnancies which ended in premature birth		15.7
Number of premature live births in which the W.R. of the mother was positive	16	
Number of premature still-births in which the W.R. of the mother was positive	11	
Number of premature live and still-births in which the W.R. of the mother was positive	27	
Percentage of 157 premature live and still-births in which the W.R. of the mother was positive		17.20

TABLE IX.

Total number of live born children	623	
Number of children who died within 14 days of birth	66	
Percentage of children who died within 14 days of birth		10.59
Number of mature live births	522	
Percentage of 623 live births which were mature		83.79
Number of mature children who died within 14 days of birth	25	
Percentage of 522 mature children who died within 14 days of birth		4.78
Number of premature live births	101	
Percentage of 623 live born children who were premature		16.21
Number of premature children who died within 14 days of birth	41	
Percentage of 101 premature children who died within 14 days of birth		40.59
Number of pregnancies which ended in live birth in which the W.R. of the mother was negative	555	
Percentage of 623 pregnancies which ended in live birth in which the W.R. of the mother was negative		89.08
Number of mature live births in which the W.R. of the mother was negative	470	
Percentage of 555 live births which were mature in which the W.R. of the mother was negative		84.68
Number of mature infants who died within 14 days of birth in which the W.R. of the mother was negative	23	
Percentage of 470 mature infants who died within 14 days of birth in which the W.R. of the mother was negative		4.89

TABLE IX (contd.)

Number of premature live births in which the W.R. of the mother was negative	85	
Percentage of 555 live births which were premature in which the W.R. of the mother was negative		15.32
Number of premature infants who died within 14 days of birth whose mother's W.R. was negative	35	
Percentage of 85 premature infants who died within 14 days of birth whose mother's W.R. was negative		41.17
Number of pregnancies which ended in live birth in which the W.R. of the mother was positive	68	
Percentage of 623 pregnancies which ended in live birth in which the W.R. of the mother was positive		10.92
Number of mature live births in which the W.R. of the mother was positive	52	
Percentage of 68 live births which were mature in which the W.R. of the mother was positive		76.47
Number of mature infants who died within 14 days of birth in which the W.R. of the mother was positive	2	
Percentage of 52 mature children who died within 14 days of birth whose mother's W.R. was positive		3.84
Number of premature live births in which the W.R. of the mother was positive	16	
Percentage of 68 live births which were premature in which the W.R. of the mother was positive		23.53
Number of premature infants who died within 14 days of birth in which the W.R. of the mother was positive	6	
Percentage of 16 premature children who died within 14 days of birth whose mother's W.R. was positive		37.50

TABLE IX. (contd.)

Total number of children born alive	623	
Percentage of 1000 pregnancies which ended in live birth		62.3
Total number of children born alive who were known to be alive 14 days after birth	557	
Number of children born alive who were known to have died within 14 days of birth	66	
Percentage of 623 children born alive who were known to have died within 14 days of birth		10.59
Number of children born alive in which the W.R. of the mother was positive	68	
Percentage of children born alive in which the W.R. of the mother was positive		10.93
Number of children known to be alive 14 days after birth in which the W.R. of the mother was positive	60	
Percentage of children known to be alive 14 days after birth in which the W.R. of the mother was positive		88.23
Number of children born alive in which the W.R. of the mother was negative	555	
Percentage of children born alive in which the W.R. of the mother was negative		89.08
Number of children known to be alive 14 days after birth in which the W.R. of the mother was negative	497	
Percentage of children known to be alive 14 days after birth in which the W.R. of the mother was negative		89.54

TABLE X.

Total number of still-born children	114	
Percentage of 1000 pregnancies which ended in still-birth		11.4
Number of mature still-births	58	
Percentage of 114 still-births which were mature		50.88
Number of premature still-births	56	
Percentage of 114 still-births which were premature		49.12
Number of still-births in which the W.R. of the mother was negative	99	
Percentage of 114 still-births in which the mother's W.R. was negative		86.84
Number of still-births in which the mother's W.R. was positive	15	
Percentage of 114 still-births in which the mother's W.R. was positive		13.16
Number of mature still-births in which the W.R. of the mother was negative	54	
Percentage of 99 still-births which were mature in which the mother's W.R. was negative		54.54
Number of mature still-births in which the W.R. of the mother was positive	4	
Percentage of 15 still-births which were mature in which the W.R. of the mother was positive		26.67
Number of premature still-births in which the W.R. of the mother was negative	45	
Percentage of 99 still-births which were premature in which the W.R. of the mother was negative		45.46
Number of premature still-births in which the W.R. of the mother was positive	11	
Percentage of 15 still-births which were premature in which the mother's W.R. was positive		73.33

TABLE XI.

Number of mothers whose pregnancy, labour or puerperium was complicated by Eclampsia	34	
Percentage of total 1000 mothers whose pregnancy, labour or puerperium was complicated by Eclampsia		3.4
Percentage of 737 mothers whose pregnancy ended in live or in still-birth, and whose pregnancy, labour or puerperium was complicated by Eclampsia		4.61
Number of mothers with positive W.R. whose pregnancy ended in live or in still-birth	83	
Number of mothers with positive W.R. whose pregnancy ended in live or in still-birth, and who also had Eclampsia	3	
Percentage of 83 mothers with positive W.R. who did not miscarry, but who had Eclampsia		3.61
Number of mothers with W.R. negative whose pregnancy ended in live or in still-birth	654	
Number of mothers with, W.R. negative whose pregnancy ended in live or in still-birth, and who had Eclampsia	31	
Percentage of 654 mothers with negative W.R. whose pregnancy ended in live or in still-birth, and who had Eclampsia		4.74

TABLE X11.

Note.- This Table is based on cases of Haemorrhage occurring after the commencement of the seventh lunar month.

Number of cases of haemorrhage	66	
Percentage of total 1000 mothers who had haemorrhage (after seventh lunar month)		6.6
Percentage of 737 mothers whose pregnancy did not end before the seventh lunar month, and who had haemorrhage		8.94
Number of mothers with positive W.R. who had haemorrhage	3	
Percentage of 83 mothers with positive W.R. and pregnancy not ending before the seventh lunar month who had haemorrhage		3.61
Number of mothers with negative W.R. who had haemorrhage	63	
Percentage of 654 mothers with negative W.R. and pregnancy not ending before the seventh lunar month who had haemorrhage		9.63
Number of cases of Accidental Haemorrhage	24	
Percentage of 1000 mothers who had Accidental Haemorrhage		2.4
Percentage of 737 mothers whose pregnancy did not end before the seventh lunar month who had Accidental Haemorrhage		3.25
Number of mothers with positive W.R. who had Accidental Haemorrhage	2	
Percentage of 83 mothers with positive W.R. and pregnancy not ending before the seventh lunar month who had Accidental Haemorrhage		2.40

TABLE XII (contd.)

Number of mothers with negative W.R. who had Accidental Haemorrhage	22	
Percentage of 654 mothers with negative W.R. and pregnancy not ending before the seventh lunar month who had Accidental Haemorrhage		3.36
Percentage of total 94 mothers with positive W.R. who had Accidental Haemorrhage		2.12
Percentage of total 889 mothers with negative W.R. who had Accidental Haemorrhage		2.47
Number of mothers who had Unavoidable Haemorrhage	23	
Percentage of 737 mothers with pregnancy not ending before the seventh lunar month who had Unavoidable Haemorrhage		3.12
Number of mothers with positive W.R. who had Unavoidable Haemorrhage	1	
Percentage of 83 mothers with pregnancy not ending before the seventh lunar month and with positive W.R. who had Unavoidable Haemorrhage		1.20
Number of mothers with negative W.R. who had Unavoidable Haemorrhage	22	
Percentage of 654 mothers with pregnancy not ending before the seventh lunar month and with negative W.R. who had Unavoidable Haemorrhage		3.36
Number of mothers who had Post-partum Haemorrhage (apart from Placenta Praevia)	21	
Percentage of 737 mothers with pregnancy not ending before the seventh lunar month who had Post-partum Haemorrhage (apart from cases of Placenta Praevia)		2.84

TABLE X11 (contd.)

Number of mothers with pregnancy not ending before the seventh lunar month and with positive W.R. who had P.P.H. (apart from cases of Placenta Praevia)	0
Percentage of 52 mothers with pregnancy not ending before the seventh lunar month and with positive W.R. who had P.P.H. (apart from cases of Placenta Praevia)	0
Number of cases with pregnancy not ending before the seventh lunar month and with negative W.R. who had P.P.H. (apart from cases of Placenta Praevia)	21
Percentage of 654 mothers with pregnancy not ending before the seventh lunar month and with negative W.R. who had P.P.H. (apart from cases of Placenta Praevia)	3.21

TABLE XIII.

INFANT DEATHS.

Deaths during	NEGATIVE GROUP. Married.	Single.	Total.	POSITIVE GROUP. Married.	Single.	Total.	Totals Neg. & Positive.
1st month	19.37%	12.69%	17.49%	14.58%		18.46%	
2nd "	3.52%	1.88%	3.04%	5%		3.84%	3.14%
3rd "	.82%	3.88%	1.73%	2.70%	8.33%	4.08%	2.02%
4th "	.83%	2.06%	1.18%	9.09%		6.97%	1.84%
5th "	.42%	1.05%	.60%				.54%
6th "		2.24%	.62%	3.45%		2.70%	.83%
7th "	.42%	1.15%	.62%				.56%
8th "	.86%	1.19%	.94%		12.5%	2.78%	1.13%
9th "	.44%		.32%				.28%
10th "							
11th "	.90%		.66%				.60%
12th "	1.40%	1.33%	1.38%				1.24%
13th "	.52%	1.47%	.76%				.68%
14th "	1.08%	3.12%	1.61%	4.17%		3.22%	1.79%
15th "	.56%		.41%				.37%
16th "	1.70%		1.25%				1.13%
17th "	.58%		.43%		14.28%	3.45%	.76%

	Neg. Grp.	Pos. Grp.	Total.
Number of children born alive	555	68	623
Number lost trace of	196	18	214
	359	50	409
Number who died	125 (34.82%)	22 (44%)	147(35.94%)
	234	28	262

"3231" SERIES.

TABLE 1a.

		Percentage of 1881.
Number of Mothers examined	1881	
Number of Mothers with W.R. Positive	170	9.04
Number of Mothers with W.R. Negative	1678	89.21
Number of Mothers with W.R. Doubtful	33	1.75

TABLE 11a.

		Percentage of 1350.
Number of Infants examined (Placental blood)	1350	
Number of Infants with W.R. Positive	56	4.15
Number of Infants with W.R. Negative	1280	94.81
Number of Infants with W.R. Doubtful	14	1.04

PART 11.

POST-MORTEM EXAMINATIONS.

PART 11.

The Results of the Post-Mortem Examination of the Foetus and Infant.

The cases examined post-mortem have been divided into two main groups - the first including those in which there was a positive Wassermann reaction in the mother or child, and the second those in which the Wassermann reaction was negative. Further classification of the cases falling into these two categories has been made on the basis of the most common lesion, namely, Haemorrhage.

In addition to a description of the post-mortem appearances there has been made in every case an examination of the tissues for spirochaetes by Levaditi's method. In many instances additional histological examination of organs has been carried out. The weights of all the organs were noted, but for the sake of brevity they have not been included in the post-mortem summaries. In the case of the liver, spleen and placenta, however, the organ weight has been worked out as a ratio to body weight so that a more accurate estimate of the presence or degree of enlargement of these organs may be made. These results are shown in tabular form along with certain other data on page . Owing to lack of facilities for the collection of the placentae it was found impossible to include a systematic study of placental changes in the present investigation.

In all, 139 autopsies are recorded - 39 in the Wassermann positive group and 100 in the Wassermann negative group. Since the original series of 1000 cases did not contain more than a few positive cases which were available for post-mortem examination, the positive group has been supplemented by the addition of other cases not included in it at first.

In every instance the approximate stage of development of the child has been estimated from the number and dimensions of the centres of ossification, as follows:-

TABLE OF CENTRES OF OSSIFICATION WITH CORRESPONDING STAGE OF DEVELOPMENT IN LUNAR MONTHS.

6th month	Femur, Tibia, Astragalus all absent, Os Calcis absent or just present.
7th month	Femur and Tibia absent, Astragalus first appears, and may be 1-2 m.m. Os Calcis 2-4 m.m.
8th month	Femur and Tibia absent, Astragalus 1-5 Os Calcis 3-6.
9th month	Femur and Tibia absent, Astragalus 3-5 Os Calcis 3-8.
10th month.Full Time.	Femur present, Tibia present but may be absent. Astragalus present. Os Calcis present.

"Femur" = centre in lower epiphysis of femur.

"Tibia" = centre in upper epiphysis of tibia.

While it is admitted that this method gives only approximately correct results, it has been employed because it appeared to be more reliable in the main than an estimate of the degree of development based on such details of the menstrual history as were available.

The following sub-division of the "Wassermann Positive" and "Wassermann Negative" cases has been made.

A. NON-MACERATED CASES.

GROUP 1.

Cases in which haemorrhage was found.

Sub-group i.

Cases showing capillary oozings or petechiae only.

Sub-group ii.

Cases showing gross intracranial haemorrhage.

Section a. Cases showing gross intracranial haemorrhage not associated with haemorrhage elsewhere other than petechiae or capillary oozings.

Section b. Cases showing gross intracranial haemorrhage associated with visceral haemorrhage.

Sub-group iii.

Cases showing gross haemorrhage into the viscera and scalp, but no gross intracranial haemorrhage.

GROUP 11.

Cases showing no haemorrhage of any kind.

B. MACERATED CASES.

This classification may appear to be unduly complex, but it has been retained for the sake of continuity with a series of 200 mature infants studied by Professor A.M. Kennedy and a series of 200 premature infants studied by the present writer. In these two series this sub-division of cases, based upon the degree and variety of haemorrhages, was employed. The only modification of the scheme in the present series is the separation of the macerated from the non-macerated foetuses.

The numbers of cases falling into each group are here shown in tabular form:-

GROUP	WASSERMANN POSITIVE.		WASSERMANN NEGATIVE.	
A.1.		19		63
i.	10		24	
ii.	6		22	
iii.	3		17	
A.11.		11		23
Total A. 1. & 11.		30		86
B. Macerated		9		14
Total A. & B.		39		100

NOTE:- In the following description of post-mortem results the cases in the Wassermann positive group are referred to by their number in the post-mortem records of the Laboratory, while those in the Wassermann negative group are referred to by their number in the series of 1000 cases (see Appendix).

POSITIVE GROUP.

Group 1. Sub-group i.

Group showing Capillary oozings and Petechiae only

- ten cases (exclusive of macerated foetuses).

P.M. No. 119 was a sparely built female still-born child, weighing just over 4 lbs. It was about the eighth - ninth lunar month of development and the breech presented. The head showed nothing worthy of note except that there were marks of the cord round the neck. In the heart the right auricle and right ventricle were greatly distended and engorged with blood, the coronary veins and capillaries were congested, and several sub-epicardial petechial haemorrhages were present. While there were areas of fairly complete expansion in the right middle lobe and near the anterior margins of the upper and lower lobes of both lungs, the remainder of the lung was consolidated and had a greyish-brown appearance. From the cut surface there exuded purulent fluid. The spleen was greatly enlarged (weighing 18 grammes) but the other organs showed nothing of note to the naked eye. The epiphyseal line at the lower end of the femur was regular, and showed none of the changes usually associated with congenital syphilis. The diaphysis, however, was rather paler than normally. Histological examination of the lung showed a widespread infiltration with polymorphs and large epithelioid cells. There were several over distended alveoli to be seen here and there throughout

the consolidated areas, and these alveoli were filled with air only. No caseated areas or giant cells were seen. In the portions of the lung which were free from consolidation a fairly well marked degree of emphysema was observed. Some of the bronchi showed desquamation of the epithelium. In portions of the lung, stained by Levaditi's method, large numbers of spirochaetes were seen throughout the tissue. The kidney was also examined microscopically, and many of the convoluted tubules were seen to be degenerated with granular and frayed epithelium which showed considerable loss of nuclear staining. The appearances were those of a coagulation necrosis of the cells and there was no swelling of the epithelium. The glomeruli were not affected. Some congestion was noted in the vessels between the cortex and the medulla. Large numbers of spirochaeta pallida were found in sections stained by Levaditi's method. Numerous spirochaetes were also found in the portions of the liver and spleen examined. The mother was a single woman, aged 27 years, and this was her third pregnancy. The pelvis was roomy, and the labour lasted three hours and forty minutes. The breech presented and delivery was spontaneous, but the child was dead when born and showed marks of the cord round its neck. The placenta weighed 1½ lbs. and was expelled spontaneously.

In P.M. No. 66 the child was a fairly well nourished premature female, which had lived for three days. There was well marked congestion of the meningeal veins and capillaries, with generalised meningeal oozing. The tentorium was intact, however, and there was no gross haemorrhage. In the heart there was engorgement of the right auricle and congestion of the coronary veins and capillaries. The lungs were wholly expanded for the most part, but showed a number of small consolidated grey patches scattered throughout. The kidneys were pale and there was definite enlargement of the liver, spleen and placenta. There were no definite changes to be made out in the bones. On microscopical examination numerous spirochaetes were found by Levaditi's method in the lung, liver, spleen and kidney. Sections of the lung showed that the numerous consolidated areas described were made up for the most part of epithelioid cells. These patches showed little vascularity and the bronchioles in their vicinity were filled with desquamated epithelial cells, large epithelioid cells and a few polymorphs. In the kidney many of the tubules - particularly of the convoluted ones - showed granular degeneration of the epithelium, with fraying at the thinned margins and disappearance of many of the nuclei. The glomeruli were not affected. The thymus showed moderate congestion. Its lymphoid tissue appeared normal, as did also the numerous Hassal corpuscles and there was no increase in the amount of

interstitial fibrous tissue. In the thyroid most of the acini were broken down, though the nuclear staining remained good. Some of the acini were well filled with colloid, others contained only a small amount. The interstitial tissue seemed rather prominent but the increase did not amount to actual fibrosis. In the pancreas, however, moderate degree of fibrosis was present and the parenchyma showed marked post-mortem change. Sections of the suprarenal showed nothing worthy of note beyond congestion. The mother was a married multipara, aged 38 years, and this was her third pregnancy. She appeared to be healthy but suffered from hydramnios. The labour was premature but otherwise normal and the child was born alive five minutes after the rupture of the membranes. It died, however, three days later. In her previous pregnancies the mother had borne one premature and one mature child, both being alive at birth.

P.M. No. 157 was a fairly well developed still-born male child, weighing 5 lbs. 14 ozs. There was considerable bruising of the face, and a well marked caput was present over the frontal region, including both eyes. The brain and meninges were congested but showed no bleeding. The coronary veins and capillaries were congested and a number of small subepicardial petechial haemorrhages were present. The right auricle was greatly distended and engorged with blood, and the right ventricle was similarly distended

but in less degree. Microscopic examination of the heart wall showed no evidence of any actual lesion in the muscle. The lungs were wholly unexpanded and like all the other organs they showed considerable congestion. Microscopic examination confirmed the presence of congestion and the almost complete absence of expansion. No fibrosis or other changes suggestive of syphilis could be found. There was nothing else worthy of note to be seen in the organs with the naked eye except that there was very slight enlargement of the spleen (which weighed 10.6 grammes). The epiphyseal line at the lower end of the femur was perfectly healthy in appearance. Histological examination failed to reveal any sclerosis in the thyroid, thymus, suprarenal or liver. The last named organ showed the presence of a large number of primitive blood cells. Spirochaeta pallida was present in small numbers in the liver and lung, but none could be found in the portions of the spleen and kidney examined. The mother was a small anaemic woman, aged 27 years. She had previously borne three children, of which the first two lived only a few months, and the third was still-born. There was a marked degree of pelvic contraction, and forceps had been applied before admission but had failed to deliver. A brow and half-face presentation was found, and after attempts to extend to a face presentation, delivery was carried out with forceps. The child was still-born but had been alive a short time before birth. The labour lasted over three days and the membranes ruptured prematurely. The mother

had not menstruated since before the previous pregnancy, but the child appeared to be mature. The placenta, which weighed 1 lb., was expelled spontaneously.

P.M. No. 181 was a premature female infant, weighing 3 lbs. 5 ozs., and showing some greenish discolouration of the abdomen. There was slight meningeal oozing all over the surface of the brain, and from its appearance the blood had apparently been present since birth. The child had lived for seven days. There was nothing worthy of note to be made out in the heart but the lungs showed numerous dark and congested areas scattered throughout the more fully expanded tissue. These consolidated patches had the appearance and consistence of areas of bronchopneumonia, but they were rather more grey in colour. In size they varied from about a quarter to a half inch in diameter. Histologically there were seen to be patches of necrosis in which the tissue was granular and almost homogeneous - though nuclei were visible here and there. These areas were surrounded by a zone in which haemorrhage had occurred into the alveoli. In other places there were patches of tissue showing a more definite appearance of bronchopneumonia of the usual type - the alveoli being filled with polymorphs and large catarrhal cells. There were also seen areas of unexpanded tissue which was rather avascular and in which the alveolar epithelium showed some swelling of the cells.

Spirochaeta pallida was present in large numbers in sections stained by Levaditi's method, but in a section stained by the Gram-Weigert method no other organisms could be demonstrated. The liver appeared normal to the naked eye, but in sections there were seen numerous spirochaetes. The parenchyma showed swelling and granularity of the cytoplasm with deposit of brown pigment in fairly large intracellular masses, and also as a fine dust scattered throughout the section (the latter probably an artefact). The nuclei were not very well stained. There was some congestion generally and the interstitial tissue appeared slightly more prominent than usual. The spleen was greatly enlarged, and of firm consistence, and it weighed 17.4 grammes. There were numerous spirochaetes in its substance. Sections showed congestion and post-mortem change throughout. The Malpighian corpuscles were indistinct. Some collections of epithelioid cells were seen near the vessels and the stroma was rather prominent. The kidneys showed some uratic deposits at the tips of the pyramids, and several of the pyramids in the right kidney were deeply congested, as was also the base of one in the left kidney. The macroscopic appearances were otherwise normal. On histological examination, however, there was seen to be well marked necrosis in the epithelium of many of the convoluted tubules. The nuclei had lost their staining power, and the cells were swollen, rounded and granular. In many places the edges of the epithelium were frayed and

broken down. In the straight tubules of the medulla similar changes were seen. Many were necrosed and their lumina were dilated and filled with granular casts. Large numbers of spirochaeta pallida were present. The other organs showed nothing of note to the naked eye, but on histological examination the thyroid showed well marked fibrosis throughout. Most of the acini were of small size and were more or less disintegrated. Practically no colloid substance could be seen in most of them, and the lumina were below the normal in diameter. A few abnormally large acini were seen, however, and these were well filled with colloid. The epiphyseal line at the lower end of the femur was irregular and showed a broad whitish-yellow line, while in the cartilage there was a well marked zone of congestion. The mother was a well nourished single woman, aged 28 years. She had ulceration of the vulva and perineum, sore throat, and other evidences of active syphilis. This was her second pregnancy, but no information was available about the previous one. The labour was normal and the child, which was premature, was born alive and survived till the eighth day.

P.M. No. 297 was a fairly well developed female child, weighing 7 lbs. 5 ozs., which was delivered after craniotomy. There was a good deal of generalised oedema, but the external appearances showed nothing worthy of note beyond pallor. The head had been perforated and the brain was destroyed. There was no congestion of the

organs generally, but the coronary veins were filled with blood and some subepicardial petechial haemorrhages were noted. The lungs were wholly unexpanded. The liver was not enlarged but the spleen was slightly heavier than normal for the size of the child - weighing 17.0 grammes. The thymus showed slight congestion and there was some cloudy swelling in the kidneys but no other abnormality was noted, and the epiphyseal line at the lower end of the femur was perfectly regular and healthy looking. On histological examination of portions of the lung, liver, spleen and kidney, no evidence of spirochaetes could be found by Levaditi's method. Sections of the lung stained by the ordinary methods showed complete lack of expansion. No marked increase of interstitial fibrous tissue could be demonstrated, but the alveolar epithelium was desquamated. The alveoli were filled with polymorphs, mononuclears and catarrhal cells. The bronchioles also contained a considerable amount of epithelial debris, with desquamation of the epithelium in places. In sections of the liver there was fairly well marked increase in the amount of connective tissue stroma throughout the liver, the strands of fibrous tissue being distinctly thicker than normally. There were numerous collections of deeply staining nuclei scattered all through the liver, but most marked around vessels. The cells were chiefly of the embryonic blood-cell type. The parenchyma cells of the liver showed a good deal of cloudy swelling and post-mortem

change. In the kidneys no increase of fibrous tissue could be demonstrated but there was a widespread degeneration of the epithelium of the convoluted tubules. The cytoplasm was granular and opaque, and in many places completely disintegrated, while the nuclei stained irregularly, and for the most part faintly. In the epithelium of the medullary tubules there was a good deal of loss of substance - apparently from post-mortem change. The glomeruli also showed only slight cytoplasmic change. A slight degree of congestion was present in the capillaries at the junction of the cortex and medulla. Sections of the suprarenal showed nothing abnormal. In the pancreas there was a marked degree of autolytic change, and a distinct degree of interstitial fibrosis was visible. Similar appearances were noted in the thyroid. The thymus and the cardiac muscle both showed a moderate degree of post-mortem change only. The mother was a single woman, aged 26 years, and this was her second pregnancy. The first child had been still-born at term after a forceps delivery. She was admitted in labour on the second occasion, and a marked degree of pelvic contraction was noted. The labour was allowed to go on, but the head did not mould well and became fixed in the brim of the pelvis. Forceps were applied unsuccessfully and craniotomy was thereafter performed. The placenta was retained and had to be removed manually. The membranes were incomplete and ragged. The mother showed no active

signs of syphilis, but her blood and that of the child gave a strongly positive Wassermann reaction.

P.M. No. 350 was a still-born mature male, weighing 5½ lbs. It was fairly well developed and well nourished, and had been decapitated. Macroscopically there was nothing noteworthy to be seen in the organs beyond slight congestion of the coronary veins and the presence of a few subepicardial petechial haemorrhages. There was no enlargement of liver or spleen, and the bones appeared healthy. Portions of the lung, liver, spleen and kidney were examined for spirochaetes but with negative result. Sections of the lung, liver, spleen, kidney, thyroid, thymus, pancreas, suprarenal and heart were examined, but in none of these tissues was there any change suggestive of syphilis to be found. A good deal of post-mortem change had occurred, however, and the appearances of the softer tissues was thus considerably obscured. There was no evidence of interstitial fibrosis in the sections examined. The mother was an unhealthy looking woman, aged 41 years, who had a marked degree of pelvic contraction, and various other rickety deformities as well. During the last pregnancy (her tenth) she had suffered from bronchitis. Of her nine previous pregnancies all but one had gone on till term, and the one miscarriage which she had was the result of a fall. Most of the deliveries were instrumental and three of the children were still-born. The ninth child was born seven years before the tenth pregnancy. On admission the labour had been in

progress for some time, and the child was found to be presenting transversely, with the hand prolapsed. The mother was exhausted and collapsed, and the uterine contractions were strong. The foetal heart was not audible. Decapitation was performed and the child was delivered. The placenta, which was adherent, was removed manually. The whole labour lasted for about four days.

P.M. No. 626 was a well developed and well nourished male child, weighing 7 lbs. 15 ozs. The body surface was pale and there was a purulent secretion in the conjunctival sacs (this pus was found to contain streptococci and Coliform bacilli). The meningeal veins and capillaries were congested, but there was no haemorrhage and the tentorium was intact. The heart showed engorgement of the right auricle with blood, congestion of the coronary veins and capillaries, and two minute subepicardial petechial haemorrhages. Both the lungs were congested and wholly unexpanded, and there were numerous subpleural petechial haemorrhages all over. There was no actual pneumonia, but from the cut end of the bronchi and bronchioles there exuded meconium, and a swab from the lung contained streptococci and Coliform bacilli. The liver and spleen were not enlarged and none of the other organs showed any features worthy of note. Large quantities of meconium must have been swallowed as well as inspired, for the stomach was filled with it. Histological examina-

tion confirmed the naked-eye appearances in the lung. There was practically complete absence of expansion. Congestion was well marked. Sections of the spleen, kidney, pancreas and thymus showed nothing worthy of note. Sections of the liver showed well marked congestion, fairly numerous collections of primitive blood cells but no fibrosis. The thyroid showed a good deal of post-mortem change. Many of the acini were broken down, the cytoplasm being poorly stained though the nuclei were well preserved. Quite a fair amount of colloid was present. A distinct increase in the amount of interstitial fibrous tissue was noted. A section of the lower end of the femur did not show any evidence of osteo-chondritis. The mother was an unmarried primipara, aged 26 years. Her pregnancy was without incident and the labour was normal, the child being born dead spontaneously thirteen and a half hours after the onset of the pains. The mother's blood was not examined but the child's gave a strongly positive Wassermann reaction. The placenta weighed 24 ozs.

P.M. No. 694 was a small but fairly well nourished child, weighing 3 lbs. 2 ozs., which was born dead, prematurely. There was a considerable amount of cyanosis of the lower extremities. The meningeal veins and capillaries were congested and there was well marked haemorrhagic oedema of the meninges. In the heart there was congestion of the coronary veins and capillaries and the right auricle was distended and engorged with blood.

There were numerous and extensive subepicardial petechiae. The lungs were wholly unexpanded and showed congestion but no subpleural haemorrhages. The liver and spleen were not enlarged and both showed a considerable degree of congestion. The other organs showed nothing worthy of note, except that there was a well marked zone of congestion in the kidneys at the junction of cortex and medulla. The bones appeared perfectly healthy. It was noted that the general development of the child was more advanced than the centres of ossification would have indicated. No spirochaetes were found in the portions of lung, liver, spleen and kidney examined by Levaditi's method. Histological examination of the lung showed moderate congestion and non-expansion. There were no changes suggestive of syphilis. In the liver congestion was also marked and there was an extreme degree of infiltration with primitive blood cells. A moderate degree of periportal fibrosis was also noted. The spleen and pancreas also showed some increase in the amount of interstitial tissue but no evidence of fibrosis could be found in the kidney, suprarenal or thyroid. In the last named organ the acini were for the most part of large size and were well filled with colloid. The mother was a married woman, aged 23 years, who had previously been pregnant twice. The first pregnancy ended at term and the child was delivered instrumentally, while the second pregnancy ended in abortion at about four months. The woman had not felt well since her second pregnancy, and suffered from frequent attacks

of bronchitis. She stated that she had been taking Pennyroyal pills regularly for the last three months before delivery, and that the day before labour commenced she had been kicked on the abdomen. The labour lasted about five and a half hours, the breech presented, and delivery was spontaneous. The mother's blood was not examined but the child's gave a strongly positive Wassermann reaction.

P.M. No. 769 was a poorly developed female infant, weighing 2 lbs. 11¼ ozs. It showed considerable generalised oedema in the face and head. The abdomen was large and distended. The lower extremities showed several deformities, the knee being hyperflexed and the leg rotated inwards so that its posterior surface lay parallel to the anterior surface of the thigh. The tibia had an anteriorly convex curvature, the head of the fibula projected subcutaneously and the foot was dorsiflexed so that its dorsum lay in the curvature on the anterior surface of the tibia. In the head there was congestion of the meningeal veins and capillaries, with slight capillary oozing and some oedema of the meninges. The longitudinal sinus and its tributaries were filled with blood clot of firm consistence. There was slight subpericranial haemorrhage, but no bleeding was noted either into or under the scalp. In the heart there was engorgement of the right auricle and both ventricles, their cavities being filled with firm clot. The coronary veins and capillaries were congested, and there were a few

subepicardial petechial haemorrhages. The myocardium was rather pale. The lungs were partially expanded throughout and were congested. Their surface had a curiously mottled appearance and their consistence was firm. There were no subpleural petechiae. The liver was greatly enlarged and its consistence was markedly harder than normally. Externally it appeared normal, but on section the tissue showed an extreme degree of overgrowth of the interstitial framework. The fibrous tissue formed large, firm, cheesy-looking tuberculae. Otherwise the naked-eye appearances were normal, though the tissue was moderately congested. Like the vessels throughout the remainder of the body, the veins of the portal system were filled with firm clot. The spleen, like the liver, was greatly enlarged and weighed 17 grammes. It was of firm consistence. The pulp of the spleen was congested and there were patches of perisplenitis with recently formed peritoneal adhesions. The kidneys showed congestion at the junction of the cortex and medulla, and there was slight congestion generally. The renal vessels were almost the only vessels examined in which there was fluid blood and not firm clot. The suprarenals were moderately congested and the pancreas was large and pale. There was also pallor of the thyroid and thymus. There was a small amount of clear straw-coloured fluid in the peritoneal cavity. The epiphyseal line at the lower end of the femur showed very typical syphilitic osteo-chondritis, being irregularly ragged and broad and having

a white-yellow zone at the line of junction. Examination of the lung, liver, spleen and kidney by Levaditi's method showed the presence of spirochaetes in the lung only. The pulmonary tissue was greatly congested throughout and showed only a few areas of fairly complete expansion. For the most part the lung was completely airless, but in places partially expanded alveoli were seen, filled with structureless exudate, erythrocytes and epithelioid cells. On the whole the alveolar epithelium showed no marked changes. There was a good deal of infiltration with mononuclear cells and polymorphs. The bronchi appeared fairly normal though they shared in the degree of post-mortem change which was present throughout the lung. No evidence of fibrosis could be found. The liver showed well marked congestion throughout. The parenchyma cells were granular and many of the nuclei stained rather poorly. Very numerous collections of primitive blood cells were present all through the tissue, both scattered about and collected into definite clumps. A moderate increase in the amount of perivascular connective tissue and a definite fibrosis of the portal tracts was noted but there was no fine cirrhosis. A good deal of autolytic change was present in the kidney and suprarenal but neither organ showed any changes suggestive of syphilis. There seemed to be some increase in the fibrous stroma of the pancreas and of the thymus, but otherwise there was nothing noteworthy to be found in the organs. The mother was a healthy looking woman, aged

32 years, and this was her fifth pregnancy. There had been four mature children born alive, and during the fifth pregnancy the mother's health was good till about six weeks before delivery, at which time she had a fall. She was admitted in labour three days after the premature rupture of the membranes, and delivered herself of a still-born child two and a half hours later. The placenta, which was of large size (2 lbs. weight) was delivered spontaneously ten minutes later. The mother's blood was not examined but the child's gave a strongly positive Wassermann reaction.

P.M. No. 865 was a fairly well developed premature female, weighing just under 4 lbs. The skin surface had a dusky tint and there were numerous subcutaneous petechiae producing a mottled appearance. The abdomen was prominent. In the head there were numerous petechiae into the scalp and pericranium. The meninges showed well marked oedema and the meningeal veins and capillaries were congested. Some capillary oozing was also present and the brain was oedematous. The heart showed slight congestion of the coronary veins and capillaries but nothing else worthy of note. The lungs were both pale and firm and were wholly unexpanded. Numerous subpleural petechiae were present all over. On section the tissue had the typical appearances of a " pneumonia alba" . The liver was greatly enlarged, and extended well below the level of the umbilicus. It was pale in colour and firm in consistence and on its surface there were numerous whitish areas of pin-head size.

The spleen also was large and firm and weighed 13.4 grammes. Except that there were petechiae under the capsule of the thymus the other organs showed nothing worthy of note. The mesenteric glands were enlarged, and there was a small amount of clear fluid in the peritoneal cavity. The epiphyseal line at the lower end of the femur was fairly regular, but there was a large yellowish-white wedge extending up from the line of junction into the diaphysis. There was no zone of congestion in the cartilage. Spirochaetes were found in the lung, kidney and liver but not in the spleen. Sections of the lung showed well marked congestion and almost complete unexpansion. Here and there, however, fairly well expanded alveoli were seen and these contained amorphous debris, erythrocytes and mononuclear and epithelioid cells. Polymorphs were very few in number. There appeared to be slight proliferation of the epithelium of the unexpanded alveoli in places. The bronchioles and small bronchi contained a catarrhal exudate similar to that found in the alveoli. Distinct increase in the amount of interstitial and vascular connective tissue was noted. The liver showed some post-mortem change and congestion. There was a very marked degree of infiltration with mononuclear cells, of which some were erythroblasts, but the greater number were of larger size and less deeply stained (epithelioid in type). Fairly marked periportal fibrosis was present, and a slight

intralobular increase of connective tissue was noted. The spleen was deeply congested and showed only a slight increase in stroma tissue. In the thyroid the acini were, on the whole, smaller than normal but they contained a moderate amount of colloid. From some of the larger acini, however, this had apparently been washed out during preparation. There was well marked sclerosis of the vessels, and a less distinct increase in the amount of stroma tissue. In the thymus there was moderate congestion, the lymphoid tissue was well stained, and the Hassal's corpuscles were numerous and prominent, with thickened walls, and in many cases containing mononuclears and a few polymorphs. There was a slight increase in the amount of connective tissue. Nothing noteworthy was found in the other organs examined. The mother was a multipara, aged 29 years, and this was her seventh pregnancy. The first four pregnancies and the sixth one resulted in the birth of a dead child at term, while the fifth child was born alive. The seventh pregnancy was without incident, and the child was born dead after a normal labour lasting twenty-four hours. At the commencement of labour the foetus was alive. The placenta weighed 22 ozs. The mother's blood was not examined, but the child's gave a strongly positive Wassermann reaction.

POSITIVE GROUP.

Group 1. Sub-group ii.

Section A.

Cases showing gross intracranial haemorrhage not associated with any haemorrhage elsewhere other than petechial haemorrhages or capillary oozings.

P.M. No. 370 was a fairly well developed and well nourished male, weighing 5 lbs. 5½ ozs. There was well marked congestion of the meningeal veins and capillaries, and a considerable amount of haemorrhage was present all round the cerebrum, cerebellum, pons and medulla, but most marked at the base of the brain. The right auricle was engorged with blood, the coronary veins and capillaries were deeply congested, extensive perivascular extravasations of blood were present over the surface of the heart, and there were numerous subendocardial haematomas. The lungs showed a few areas of partial expansion scattered here and there throughout, but for the most part they were congested and wholly unexpanded, and there were a few subpleural petechial haemorrhages on their surface. The liver was congested, but neither it nor the spleen showed any enlargement. The thyroid was congested, and the thymus contained a quantity of grumous fluid in its centre. Otherwise the organs showed nothing worthy of note. The epiphyseal line at the lower end of the femur, however, was slightly irregular, and showed a whitish-yellow line

and a zone of congestion. There was a tendency for the epiphysis to separate from the diaphysis. Histological examination of portions of the lung, liver, spleen and kidney by Levaditi's method failed to reveal any spirochaetes. Sections of the lung showed a fair degree of expansion in most places. There was considerable congestion of the tissue generally, but no other abnormality was noted. In the liver there was seen well marked congestion throughout, and collections of embryonic blood cells were fairly numerous, but there was nothing else worthy of note. In sections of the kidney there was a good deal of loss of staining power in the epithelium of the tubules, which was so universal as to suggest that it was entirely due to post-mortem change. The nuclei were well stained. There appeared to be quite a definite increase in the amount of interstitial tissue in the kidneys. Considerable congestion was also present. The spleen showed congestion only. The mother was an unmarried multipara, aged 40 years, and this was her fourth pregnancy. All her previous pregnancies were normal, and ended in the birth of a live mature child - the last 9 years previously. Her pregnancy was without incident and the labour, though premature, was without incident. The child was born alive but died the following day.

The child in P.M. No. 390 was a premature female which lived for a few hours only. There was well marked headmoulding, and bruising of the head was noted. A moderate amount of haemorrhage was present at the base above the tentorium, and a smaller amount was present under it. The tentorium itself showed a complete tear on the left side close to the anterior margin of the falx. This tear was about half an inch in length. All the organs were congested, and the right heart was distended with blood. The lungs showed some small areas of partial expansion, but were otherwise airless and congested. No subepicardial or subpleural petechiae were present. The kidneys showed well marked congestion of the medulla with relative pallor of the cortex. (A large caput was present over the posterior part of the right parietal region). The liver and spleen were not enlarged and the bones appeared perfectly healthy. Histological examination of a number of the organs showed no changes suggestive of syphilis, and no spirochaetes could be demonstrated by Levaditi's method. There was nothing worthy of note to be made out in the lung. The liver showed numerous primitive blood cells but no fibrosis. The kidneys showed well marked degeneration of the tubular epithelium, affecting particularly the convoluted tubule. No casts were seen and there was no evidence of fibrosis. Of the other organs examined none showed any features worthy of note except the pancreas and the thyroid, in both of

which the interstitial tissue appeared rather prominent. In neither case, however, could the condition be described as a fibrosis. The mother was an unmarried primipara, with a moderate degree of pelvic contraction. She had attended at the Ante-natal Dispensary but had received no anti-syphilitic treatment. Before admission the head had been well down for fully four hours, but no progress was being made, and the child's pulse was becoming erratic. Forceps were applied and delivery was effected about sixteen and a half hours after the onset of labour. The placenta was not unduly large, and was expelled spontaneously. The blood of both mother and child gave a strongly positive W.R.

In P.M. No. 471 the child was a moderately well developed male, which was slightly premature. There was considerable cyanosis of the head, the meningeal veins and capillaries were congested, and there was a moderate amount of generalised meningeal haemorrhage which increased in amount towards the base. The tentorium was not injured, however. The heart showed congestion of the coronary veins and capillaries, the right auricle was distended with blood, but no subepicardial petechiae were seen. The foramen ovale was rather more widely patent than normally. The lungs were congested and wholly unexpanded, and there were numerous subpleural petechial haemorrhages over their surface. The liver and spleen were deeply congested but showed no enlargement. The

kidneys were congested, particularly at the bases of the pyramids, and there was a small amount of haemorrhage into the central portion of the suprarenals. The epiphyseal line at both ends of the femur was normal in appearance. Portions of the lung, liver, spleen and kidney were examined by Levaditi's method but no spirochaetes were found. The liver contained a moderate number of collections of primitive blood cells but nothing else worthy of note. No fibrosis or other change suggestive of syphilis could be found in the lung, kidney, suprarenal, spleen, thyroid, thymus or pancreas. The mother was a married woman, aged 34 years, who had previously been pregnant five times. There had been two full-time live-born children, and one abortion. Her blood, like that of the child, gave a strongly positive W.R. The sixth pregnancy was without incident till the onset of bleeding from a marginal placenta praevia. Version was performed and the child was delivered spontaneously as a footling, but did not breathe. The placenta was not enlarged.

In P.M. No. 793 the child was a female, weighing 6 lbs. 3½ ozs. There was generalised oedema with a considerable degree of ascites (the circumference at the umbilicus was 14¼"). The body surface was pale, and had a rather dusky tint, and there were numerous purpuric looking petechiae all over the skin. Marked oedema of the scalp was present. Examination of the head showed slight congestion of the meningeal veins and capillaries,

with moderate oedema of the meninges. An incomplete tear of the tentorium was present on the right side, with a localised area of haemorrhage extending from it over the floor of the middle fossa. On the left side of the tentorium a complete tear was present. The heart showed engorgement of the right auricle with blood, and congestion of the coronary veins and capillaries. The lungs were wholly unexpanded, and were small, pale and fleshy looking. The liver was exceptionally large, reaching to within one and a half inches of the symphysis pubis. It was dark-red in colour, firm in consistence, and congested. The spleen was also of exceptional size and reached as far down as the anterior superior iliac spine. It was firm and moderately congested. The kidneys showed well marked cloudy swelling, and there was generalised pallor - more marked in the cortex. The perinephric tissues were oedematous, and there were some petechial haemorrhages under the peritoneum near them. The suprarenals showed some petechial haemorrhages under and into their peritoneal covering. The pancreas was oedematous, and the peritoneal sac was filled with dark coloured clear fluid. The thyroid was exceptionally large, of firm consistence and pale in colour. The thymus was exceptionally small, and was dark in colour, with a fine reticulum of whitish-yellow lines over its surface. The epiphyseal line at the lower end of the femur was regular, but had a slightly congested zone in the cartilage, and showed a

distinct yellow band at the junction of bone and cartilage - at which point there was a tendency to separation. Portions of lung, liver, spleen and kidney were examined by Levaditi's method but no spirochaetes were found. The mother was a married woman, aged 29 years, who had previously borne three full-time living children. This was her fourth pregnancy, and the labour was a difficult one - as had been all the three previous ones. A moderate degree of pelvic contraction was present. The child presented by the breech, and foetal ascites was present. Eventually the child was delivered spontaneously as a footling, but it was dead. The mother's blood, like that of the child, gave a strongly positive W.R.

Section B.

This section contains two cases in which there was intra-cranial haemorrhage associated with gross haemorrhage into internal organs.

P.M. No. 251 was a case in which the child was a large well developed male, weighing 8 lbs. There was supratentorial haemorrhage associated with a tear of the tentorium cerebelli on the right side, which extended into its substance for about a quarter of an inch close to its junction with the falx. Slight bleeding had

occurred also into the substance of the tentorium. The right heart was engorged with blood, the auricle being distended to an unusual degree. The coronary veins and capillaries were congested, and numerous subepicardial petechial haemorrhages were present. The lungs were wholly unexpanded and deeply congested. The lower lobes were dark in colour and had an almost haemorrhagic appearance. Fairly numerous subpleural petechiae were present all over the lungs. The liver was deeply congested, and on the posterior surface of the right lobe there was an area of separation of the capsule by haemorrhage (about 3 cms. in diameter). The left kidney showed well marked congestion, while the right one was only slightly congested. There was deep congestion in the spleen and thyroid, and the thymus, in addition to congestion, showed petechial haemorrhages into its substance and under its capsule. (There were two superficial bruises in the right groin, and the right foot was markedly cyanosed). The spleen was slightly larger than normally, but there was no definite increase in the size of the liver. Portions of the lung, liver, spleen and kidney were examined by Levaditi's method, but no spirochaetes were found. The mother was 31 years of age, and this was her fourth pregnancy. She had been treated at the Lock Hospital, and had continued her pregnancy till term. The labour was a long and difficult one, and the child presented by the breech. Delivery was spontaneous. The placenta was adherent, but it

was no heavier than normally. The mother's blood gave a positive W.R. at the time of delivery.

P.M. No. 529 was a case in which the child was a fairly well developed and well nourished male. There was some cyanosis of the body surface generally, and the abdomen was prominent. The scalp was oedematous and numerous petechial haemorrhages were present into and under it. There was congestion of the meningeal veins and capillaries, and the meninges were very oedematous. A small amount of haemorrhage was present above the tentorium on both the left and the right side of the falx. There was a small oval tear of the tentorium on the left side (apparently the origin of the bleeding), while on the right side no lesion of the tentorium could be demonstrated beyond some extravasation of blood into its substance. The heart showed the right auricle and right ventricle distended with blood. The coronary veins and capillaries were congested, and there were a few sub-epicardial petechial haemorrhages. The lungs, which were wholly unexpanded, were deeply congested, and showed numerous subpleural petechiae all over. In each of the lower lobes anteriorly there was an area of haemorrhage into the lung substance about the size of a small pea. The liver was exceptionally large, and extended down to the level of the umbilicus. Its surface was studded with pin-point gummata all over. Some congestion was present in the liver tissue generally, and a small

accessory lobe was attached to the under surface of the right lobe. The spleen was also of great size, and of firm consistence. There was an accessory spleen the size of a pea attached near the tail of the pancreas. The kidneys were congested and the suprarenals were markedly so, while the pancreas was oedematous. Except for some congestion, the stomach and intestines appeared normal, but the abdomen contained a small quantity of slightly haemorrhagic fluid, and there were some small areas of haemorrhage under the peritoneum of the posterior abdominal wall. The subcutaneous tissues, in addition to well marked oedema, were the seat of numerous petechial haemorrhages. These were particularly well marked in the muscles of the thigh. The thyroid and thymus were congested and oedematous, but showed no particular abnormality of size. The epiphyseal line at the lower end of the femur was irregular, showed a well marked yellow band with spicules running up into the cartilage, and the cartilage itself contained a zone of congestion, which was not very well defined. Portions of the lung, liver, spleen and kidney were examined by Levaditi's method but no spirochaetes were found. The lung showed nothing worthy of note, but in sections of the liver there was seen to be an exceptional degree of infiltration, with cells both scattered and in clumps. A few polymorphs, mononuclears and epithelioid cells were included, but the greater number were of the primitive blood cell type. Similar

collections of cells were found scattered throughout the kidney, chiefly in the cortical tissue. Well marked degeneration of the epithelium of the convoluted tubules was found. Except that the spleen had a prominent fibrous stroma nothing suggestive of fibrosis was found in any of the organs. The mother was a married woman, aged 25 years, and this was her third pregnancy. The two previous ones had ended in the birth of mature living children, and the third pregnancy was without incident. The child presented by the breech, and was born dead after a spontaneous delivery. It was slightly premature. The placenta was not markedly enlarged, but the membranes were adherent and ragged, and had to be removed by digital curettage. The blood of both mother and child gave a strongly positive W.R.

POSITIVE GROUP.

Group 1. Sub-group iii.

This Sub-group contains three cases showing gross haemorrhage into or from internal organs without gross meningeal haemorrhage.

In Case No. 339 the child was a fairly well developed and almost mature female. The body surface was pale generally. There was nothing worthy of note in the brain or meninges. In the heart there were several areas of haemorrhage under the endocardium of the left ventricle, and one of these areas, situated on the ventro-ventricular septum just below the pars membranacia, was over a quarter of an inch in diameter. The lungs showed a few small areas of partial expansion, but were for the most part completely airless. There was an extensive subcapsular haemorrhage over the whole of the upper surface of the right lobe of the liver. From this, bleeding had taken place in large amount into the abdomen. The rupture of the liver capsule was situated at the extreme right margin of the organ. On the under surface of the liver three small areas of subcapsular haemorrhage without rupture had occurred. There was nothing worthy of note in any of the other organs. The liver and spleen were not enlarged and the bones appeared healthy. No spirochaetes could be found in the portions of lung, liver, spleen and kidney examined. In the liver a moderate number of collections of primitive blood cells were found, but neither here nor

in any of the other organs was there any evidence of fibrosis. The lung showed incomplete expansion with widespread areas of patchy consolidation in which the alveolar and bronchial epithelium were desquamated and infiltrated with epitheliod and mononuclear cells and some polymorphs. No evidence of syphilis could be found in any of the other organs. The mother was a multipara, aged 29 years, and this was her eighth pregnancy. She was well until two days before admission when pains began accompanied by irregular bleeding. The child presented by the vertex and was born alive spontaneously more than thirty-two hours after the onset of labour, and it survived its birth only a few hours. During the puerperium the mother developed sepsis and died on the twenty-fifth day. In her previous pregnancies she had borne six full-time, living children, and the seventh pregnancy had ended prematurely in the birth of twins. The blood of both the mother and child gave a strongly positive Wassermann reaction.

In Case No. 391 the child was a well developed, mature male, which had been decpaitated during delivery. The head was destroyed and was not examined. The heart showed pallor and the right auricle was thin. There was absence of congestion of the coronary vessels, and the only evidence of haemorrhage was a small haematoma on the tricuspid. The lungs were completely airless except for a few small areas of partial expansion at their edges.

There was moderate congestion of the liver and one or two petechial haemorrhages were present under the capsule of the thymus. The left kidney was of large size but of normal shape, and it showed moderate congestion, particularly of the medulla. No evidence could be found of a right kidney or right ureter. The left suprarenal was of normal appearance, while the right one was flattened and reniform and extended downwards on the posterior abdominal wall into the area normally occupied by the kidney. The bladder was normal in appearance and the testes were well developed, and had descended into the scrotum. The pylorus was distinctly thicker than normally, its walls measuring 1.5 mm. from peritoneal to mucosal surface. The stomach and oesophagus contained freshly swallowed blood and mucous. The liver and spleen were not enlarged and the bones appeared healthy. No spirochaetes were found in the portions of lung, liver, spleen or kidney examined. No changes suggestive of syphilis were found in any of the organs, though the stroma of the spleen appeared rather prominent. The mother was a married primipara, aged 21 years. Her pregnancy was uneventful and the patient came to the Dispensary on account of delay in the labour. The pains had then been in progress for fifty-six hours. On admission a hand and arm were presenting and the shoulder was found to be impacted. A Bandl's ring had fallen round the head and the cord was not pulsating. Attempts to extract the head with forceps

having proved unsuccessful, decapitation was performed. The body was delivered, and the aftercoming head was perforated and crushed. The mother was a healthy looking woman with no pelvic contraction or other deformity. Her puerperium was febrile. Her blood gave a strongly positive Wassermann reaction.

In Case No. 443 the child was a well developed mature male, showing cyanosis of the body surface, and marked headmoulding with elongation towards the vertex. There was a large caput over the vertex and extending downwards over the occipital region. The meningeal veins and capillaries were congested, but there was no intracranial haemorrhage and the tentorium was intact. The heart showed engorgement of the right auricle, and congestion of the coronary veins and capillaries. Subepicardial petechiae were present in large numbers, and there was one subendocardial haematoma on one of the cusps of the aortic valve. The lungs were congested and wholly unexpanded and showed a few haemorrhagic areas. The liver and spleen were greatly congested but showed no haemorrhage or enlargement. There was nothing worthy of note in any of the other organs except marked congestion, and the bones appeared healthy. No spirochaetes were found in the portions of lung, liver, spleen and kidney examined by Levaditi's method. No fibrosis or other evidence of syphilis could be found in the lung, liver, spleen, kidney, suprarenal, thyroid, thymus or bones. The mother

was a healthy looking primipara, aged 22 years. Her pregnancy was without incident but there was delay in the second stage of labour. The pains had been in progress for about eighteen hours before admission, and the child, which was alive, presented by the vertex. The labour was allowed to go on but eventually forceps were applied and the child was delivered dead twenty-nine hours after the onset of the pains. Except that her blood gave a strongly positive Wassermann reaction, the mother showed no evidence of disease.

POSITIVE GROUP.

Group 11.

There were eleven cases in which there was no haemorrhage of any kind, and these are here grouped together. Ten were born alive and one was still-born.

In P.M. No. 127 the child was a fairly well developed and well nourished mature female, showing post-mortem staining of the abdomen. The meninges showed well marked congestion of the veins and capillaries, but there was no haemorrhage. There was nothing worthy of note in the heart, but the lungs showed numerous dark, congested, and firm greyish areas scattered throughout. To the naked eye these patches looked like bronchopneumonia, but on histological examination they were seen to resemble gummata. The areas affected were of varying size, and in them the alveoli were necrotic and were filled with finely granular, almost homogeneous material. The alveolar walls themselves were necrotic, as was also the interstitial tissue in places. Some of the masses of necrosis showed a well marked cellular reaction around them, the tissue being infiltrated with epithelioid and mononuclear cells and a few polymorphs. No giant cells were noted. There was a similar cellular infiltration around the arterioles in many parts of the lung. In sections prepared by Levaditi's method the spirochaeta pallida were present in large numbers. The

liver, which was not enlarged, showed some post-mortem softening, and spirochaetes were found by Levaditi's method. The spleen was soft and almost diffluent, and was definitely larger than normally. No spirochaetes could be demonstrated in it, however. There was well marked autolytic change in the kidneys and no spirochaetes were found by Levaditi's method. There was nothing worthy of note in any of the other organs, except that the thymus was rather small. The bones appeared healthy. Sections of the thymus showed an increase in the fibroid stroma with perivascular fibrosis and thickening of the media. The intima of the vessels appeared normal. Hassal's corpuscles were numerous and much laminated, while the lymphoid tissue was less conspicuous than normally. The thyroid and pancreas showed no definite increase in the amount of fibrous tissue. The acini in the thyroid showed considerable variation, some being well filled with colloid, and others containing little colloid and showing disintegration of the endothelium. Some masses of dark staining debris were noted here and there. In the pancreas the islet tissue was ill defined.

The mother was a married secundipara, aged 23 years. Her health was good throughout the pregnancy, and the labour was without incident - the child presenting by the vertex, and being delivered alive spontaneously. In her previous pregnancy the mother had borne a full-time living child. She herself appeared perfectly healthy, but, unfortunately, neither her blood nor that of the child was obtained for

examination. The infant appeared normal at birth, but in the course of a few days it developed pemphigoid bullae on the hands and feet, and it died at the age of seven days. The placenta was heavier than normally.

In P.M. No. 209 the child was a very premature female, one of triplets, which lived for a few hours only. There was marked oedema of the subcutaneous tissues of the neck, scalp and upper parts of the body, and the meninges also were oedematous. There was nothing worthy of note in any of the organs beyond congestion. The liver and spleen were not enlarged, and the epiphyseal line, though showing a very slight yellowish zone, was quite regular. No spirochaetes were found in the portions of lung, liver, spleen and kidney examined by Levaditi's method. The lung tissue was airless but showed no catarrhal changes or fibrosis. The liver was deeply congested, and the parenchyma cells showed considerable post-mortem change. Collections of primitive blood cells were numerous, but no fibrosis was noted. The kidney showed congestion, oedema and degeneration of the tubular epithelium. None of the other organs examined showed any fibrosis or other changes suggestive of syphilis. The mother was a multipara, aged 32 years, and this was her seventh pregnancy. She had suffered from varicose veins, and there had been pain on the right side for three weeks before admission. A considerable degree of hydramnios

was present and labour was induced early in the seventh month. Triplets were born alive spontaneously but all died within a few hours. In her previous pregnancies the mother had borne five full-time children and one premature - all except the premature one were alive at birth, but several died in infancy. The mother's blood, examined after delivery, gave a weakly positive Wassermann reaction, but no other evidence of syphilis was noted.

In P.M. No. 361 the child was a fairly well developed, mature male, delivered by caesarean section, which died on the day of its birth. The external appearance showed nothing worthy of note, and the brain and meninges appeared normal. In the heart there was engorgement of the right auricle and the coronary veins and capillaries were congested. The lungs showed very slight partial expansion of the extreme lower and anterior margins, but otherwise they were pale and airless, had a fleshy opaque appearance, and felt firm and somewhat oedematous. There was nothing else worthy of note in the organs except that the liver was slightly heavier than normally, and the spleen appeared to be slightly enlarged, though its weight factor was within normal limits. The bones, however, showed quite definite changes, the epiphyseal line being slightly irregular, with yellowish wedge-shaped projections running up from the cartilage into the bone. No spirochaetes were found in the liver, spleen or kidney, though a few were present in the lung. Sections of the lung tissue

showed almost complete absence of expansion. Many of the alveoli were packed with large epithelioid catarrhal cells and there was desquamation of the bronchial and bronchiolar epithelium. There was apparently some increase of fibrous tissue in the lung stroma and in the vessel walls. The liver was congested but otherwise the tissue generally showed no marked abnormality except that there was extensive infiltration with cells, both in clumps and scattered throughout the sinuses. These cells were of two types (a) primitive blood cells and (b) paler epithelioid cells. No spirochaetes were found, and there was no necrosis or fibrosis. In the spleen considerable post-mortem change had occurred, the pulp stained poorly, and the fibrous tuberculae stood out prominently. There appeared to be a definite increase in the amount of fibrous tissue, both in the stroma and round the vessels. In the kidney a post-mortem degeneration of the parenchyma had occurred and the only feature worthy of note was a slight degree of perivascular fibrosis in some of the vessels. The thyroid, thymus and pancreas all showed a slight increase in the amount of fibrous tissue, but otherwise, nothing characteristic was noted. The mother was an unmarried secundipara, aged 26 years. In her first pregnancy she had borne a dead premature child. She had continuous headaches throughout the present pregnancy, but was otherwise fairly well. When admitted, she had been in labour for twelve hours and the membranes

had ruptured. There was a marked degree of pelvic contraction, and caesarean section was performed about fifteen hours after the onset of the pains. The child was feeble and survived only a few hours. The mother showed rachitic deformities and was anaemic. Her blood gave a strongly positive Wassermann reaction.

In P.M. No. 386 the child was a moderately well developed premature female, which lived for two days. To the naked eye the organs showed nothing worthy of note beyond some congestion and the absence of expansion in the greater part of both lungs. The liver and spleen were not enlarged and the bones appeared healthy. No spirochaetes were found in the portions of lung, liver, spleen and kidney examined. There was nothing worthy of note in the lung beyond a slight degree of desquamation in the alveolar and bronchiolar epithelium. In the lung numerous clumps of primitive blood cells were present, and in the kidney, which was extremely congested, there was degeneration of the tubular epithelium - the convoluted tubules, and to a less extent, the straight tubules, being affected. Some of the latter contained hyaline substance in the lumen. In none of the organs was there any fibrosis to be seen. The mother was a married secundipara, aged 28 years. She had " muscular rheumatism'' six weeks before admission, and she appeared to be very anaemic. The labour, which lasted just over fourteen hours, was without incident - the child presenting by the

vertex. Although born alive, the child was feeble and lived for two days only. Both its blood and that of the mother gave a strongly positive Wassermann reaction. In her first pregnancy - five years previously - the mother had borne a living mature child.

In P.M. No. 388 the child was a fairly well developed, mature male, which had lived for seven days. The meninges were oedematous, particularly at the base, and the meningeal veins and capillaries were congested. There was nothing worthy of note in the heart, but the lungs showed extensive patches of bronchopneumonic consolidation, dark and haemorrhagic in appearance. The surface of the lungs was somewhat mottled, and, like some of the abdominal viscera, it showed a degree of greenish yellow staining. The liver and spleen were dark and firm but were not heavier than normally, though the spleen appeared slightly enlarged to the eye. The kidneys were pale and showed cloudy swelling, but otherwise there was nothing worthy of note in the other organs. The epiphyseal line at the lower end of the femur, however, was irregular, with a well marked yellow zone and a well defined band of congestion. The lungs showed unexpanded and partially expanded areas, with congestion and more or less complete necrosis of all the elements. The liver showed cloudy swelling, with numerous collections of primitive blood cells throughout. The kidney showed gross degeneration of the parenchyma and of the supporting tissues. The

whole renal tissue was composed of more or less degenerate cells, and scarcely any evidence of tubular structure could be made out. All the glomeruli were degenerate, and some showed a laminated hyaline appearance. Sections of the lung, liver, spleen and kidney were examined by Levaditi's method, and numerous spirochaetes were found in all of them. No fibrosis was noted. The mother was a multipara, aged 26 years, and this was her fifth pregnancy. She suffered from bronchitis but otherwise appeared healthy. The labour was without incident and the child was born alive spontaneously about eleven hours after its onset. It died on the seventh day, having lost about 15 ozs. in weight. In her previous pregnancies the mother had borne two living mature children, and two dead premature children.

In P.M. No. 402 the child was an emaciated and poorly developed premature infant which had lived for about six days. There was nothing worthy of note in the brain or meninges or in the heart. The lungs showed considerable areas of full expansion, but in each of them there were areas of bronchopneumonic consolidation. The liver was not enlarged or congested, but its tissue had a firm feeling, and on section the cut surface showed streaks of fibrosis suggestive of cirrhosis. The spleen was definitely enlarged and rather soft. The placenta also was heavier than normally, but otherwise there was nothing worthy of note, and the bones appeared healthy.

No spirochaetes were found in the portions of lung, liver, spleen and kidney examined. None of the organs showed any features worthy of note except that primitive blood cell clumps were fairly numerous in the liver, marked tubular degeneration was present in the kidneys, and the interstitial fibrous tissue of the thyroid appeared slightly more prominent than normally. The mother was an unmarried secundipara, aged 24 years. She suffered from sore-throat, but showed no other clinical evidence of syphilis. The labour was premature but normal, and the membranes ruptured about twenty minutes before the spontaneous delivery of the child. In her previous pregnancy - two years before - the mother had borne a living premature child.

In P.M. No. 458 the child was a fairly well developed but emaciated mature male, showing jaundice and post-mortem lividity. There was a ganeralised purulent meningitis extending all over the brain and spinal cord. The vessels in the brain tissue were congested, and pus was present along the edges of the choroid plexus. Several minute purulent foci were noted also in the brain substance, about the region of the thalamus. There was nothing else worthy of note in the organs. The liver, spleen and placenta were not enlarged, and the bones appeared healthy. No spirochaetes were found in the portions of lung, liver, spleen and kidney examined. In the liver congestion was present, and the hepatic cells

were, in places, oedematous. Deposits of yellow-green pigment were noted both in and between the cells. There was no fibrosis, and collections of primitive blood cells were inconspicuous. None of the other organs showed any features worthy of note. Nowhere was there any increase in the amount of fibrous tissue. (Pneumococcus from brain). The mother was an unmarried secundipara, aged 22 years. She was well until fourteen days before delivery, at which time she began to have pains in the hips. The labour was normal and the child was born spontaneously and lived for about ten days. The mother's blood gave a strongly positive Wassermann reaction, but the child's reaction was negative.

In P.M. No. 505 the child was a premature male, which had lived for nineteen days. It was poorly developed and emaciated. The abdomen showed P.M. staining. There was a muco-purulent discharge from the nose and eyes, and a blotchy rash was present over the body surface. There was also some excoriation of the scrotum. There was nothing worthy of note in the heart, but the lungs, which were fairly well expanded throughout, showed numerous yellow, cazeous areas, both in the surface and one on the surface. The kidneys showed well marked cloudy swelling and the cortex was pale and broad. The liver was not enlarged, but the spleen had a weight ratio of 137 and extended fully half an inch below the costal margin anteriorly. The stomach and intestines were

distended with gas, and both mucous and peritoneal surfaces were congested. There was no evidence of ulceration or haemorrhage, however. There was nothing worthy of note in the other organs except that the thymus was of small size. The epiphyseal line at the lower end of the right femur showed an irregular wedge-shaped area, pale in colour, and extending up into the bone. There was some congestion of the bone on either side of this wedge but there was no congested zone in the cartilage. The upper line, though slightly irregular, showed no other characteristic changes, and the left femur appeared healthy. No spirochaetes were found in the portions of lung, liver, spleen and kidney examined. The lung was incompletely expanded and congested, and areas of consolidation were scattered throughout. In these the tissue was avascular and necrotic. The alveoli, bronchioles and bronchi showed definite catarrhal changes, and there was a well marked infiltration, with epithelioid and mononuclear cells and a few polymorphs. The liver showed marked cloudy swelling of the hepatic cells. There was a slight but definite increase in the amount of intra-cellular fibrous tissue and comparatively few primitive blood cells were present. There was slight fibrosis in the pancreas, and fairly well marked fibrosis in the thyroid, but none of the other organs showed any features worthy of note. The mother was a married multipara, aged 27 years, and this was her fifth pregnancy. She had

previously borne four full-time children - two alive and two still-born. During her fifth pregnancy her health was good, and she was admitted to the Ante-natal Department on account of contracted pelvis. The child was delivered by caesarean section as soon as labour came on and it lived for nineteen days. The placenta was not enlarged, and to the naked-eye it appeared healthy.

In P.M. No. 610 the child was a mature male, well developed but somewhat emaciated, which lived for seventeen days. There was green P.M. staining of the abdomen, the buttocks were excoriated, and a pustule was present on the right temple. The brain was rather soft, but otherwise there was nothing worthy of note within the cranium. The pericardial sac contained a moderate amount of pus, forming a thin layer from the apical portion, but present in larger amount towards the base of the heart and around the great vessels. The coronary veins and capillaries were slightly congested and nothing abnormal was noted in the endocardium. The lungs were well expanded throughout, and in places even over expanded, but there was some oedema in the lower portions. The liver was dark and firm but was not enlarged. The spleen was soft and definitely larger than normally, the weight ratio being 176. The kidneys were somewhat pale generally and showed well marked cloudy swelling. The stomach and intestines were distended with gas, and yellowish fluid escaped from the anus. There was no evidence of ulceration,

however. None of the other organs showed anything worthy of note except that the thymus was small and congested. The bones in both upper and lower extremities appeared healthy. Portions of the kidney were examined by Levaditi's method but no spirochaetes were found. The mother was a married primipara, aged 21 years, who was admitted late in labour on account of contracted pelvis. The membranes had been ruptured for about ten hours but the child was alive. Caesarean section was performed and the child delivered. It weighed 7 lbs. at birth, but after death - seventeen days later - its weight was only 4 lbs. 15 ozs. The mother's blood gave a positive Wassermann reaction.

In P.M. No. 645 the child was a large and well developed mature male, which was still-born. There was very slight congestion of the meningeal veins and capillaries. The tentorium was intact, and there was no intracranial haemorrhage. The heart showed congestion of the coronary veins and capillaries, and the right auricle was engorged with blood. No subepicardial haemorrhages were present, however. The foramen ovale was slightly more patent than normally and had an additional fenestrum - the size of a pin-head. The lungs were congested and wholly unexpanded. The liver showed very marked congestion but there was no separation of the capsule and neither it nor the spleen showed any enlargement.

All the organs were deeply congested but there was no haemorrhage of any kind. About 10 ccs. of clear straw-coloured fluid was present in the peritoneal cavity. The bones appeared healthy. A good deal of autolytic change was seen in the parenchyma of the various organs examined, but none showed any fibrosis or other features worthy of note. The mother was an unmarried primipara, aged 24 years. From about the third month she had suffered from a vaginal discharge but she was otherwise in fair health. When admitted at the onset of labour, there was a copious brownish discharge from the vagina, and soon afterwards her temperature rose to 100. The labour was fairly lengthy but otherwise normal, but the child was delivered dead though not macerated. A large quantity of brown fluid with a foetid odour escaped from the uterus after the birth of the child. The mother's blood was not examined, but the child's gave a strongly positive W.R.

In P.M. No. 795 the child was a poorly developed and poorly nourished premature female. There was a good deal of emaciation and the body surface was cyanosed. The brain showed slight meningeal congestion and well marked post-mortem softening, but there was no haemorrhage. The tentorium was intact. The heart showed moderate distension of the right auricle and slight congestion of the coronary veins and capillaries, and the lungs

were fairly well expanded but showed some congested areas of incomplete expansion which had not the appearance of bronchopneumonic consolidation. The kidneys were soft and showed very marked post-mortem change. Portions of lung, liver, spleen and kidney were examined by Levaditi's method but no spirochaetes were found. Well marked P.M.change was noted in all the organs, but in none was there any fibrosis or other noteworthy change. Primitive blood cells were not a marked feature in the liver. The mother was a married primipara, aged 21 years, who had suffered from influenza during her pregnancy. The labour was normal though premature, and the child, which was born alive, lived for six days. The mother's blood gave a strongly positive Wassermann reaction.

NEGATIVE GROUP.

Group 1. Sub-group 1.

This group contains twenty-four cases which showed capillary oozings and patechiae but no gross haemorrhage.

There were five cases of craniotomy. In one (No. 136) the child was a fairly well nourished female infant with a marked degree of hydrocephalus and a lumbar spinabifida. The lower extremities were relatively poorly developed. The head had been perforated, and the brain partially destroyed. The heart was soft and showed slight congestion of the coronary vessels with some subepicardial petechial haemorrhages. The lungs, which were small, were for the most part completely unexpanded, but there were a few areas of incomplete expansion scattered throughout them. The liver was soft and showed no congestion, but neither it nor the spleen was larger than normal. All the other organs were soft from post-mortem change. The epiphyseal line at the lower end of the femur was irregular, showed a whitish zone, and tended to separate spontaneously. In the kidneys there was generalised congestion and one or two petechiae were present at the tips of the pyramids. Portions of lung, liver, spleen and kidney were examined by Levaditi's method but no spirochaetes were found. The mother, a married primipara, aged 26 years, was well throughout her pregnancy. The breech presented and the body was delivered easily but the hydrocephalic aftercoming head had to/

to be perforated. The child appears to have been dead some time before the onset of labour.

Case No. 257 was one in which a well developed male child was born after craniotomy and cleidotomy. One or two subepicardial petechial haemorrhages were present and a few minute petechiae were noted under the pleura of both lungs. Otherwise there was nothing worthy of note in the internal organs. The liver and spleen were not enlarged and the bones appeared healthy. Portions of lung, liver, spleen and kidney were examined by Levaditi's method but no spirochaetes were found. The mother was a married primipara, aged 26 years, who had suffered for some time from dysmennorhoea and irregular menstruation. Her pregnancy was uneventful, however. The vertex presented, and on admission the cord and one arm had prolapsed and the child was dead. (Admission nine hours after the onset of labour). Craniotomy was performed to effect delivery. The placenta, which was of normal size, was expelled spontaneously.

In Case No. 664 the child was a large well developed mature male. The head had been crushed and the brain destroyed. In the heart there was absence of engorgement and there were no subepicardial haemorrhages. Minute subendocardial haematomas were present, however, on the mitral, aortic and tricuspid valves. The lungs were wholly unexpanded. There was nothing worthy of note beyond pallor and depletion in the other organs. The liver/

liver and spleen were not enlarged and the bones appeared healthy. Portions of lung, liver, spleen and kidney were examined by Levaditi's method but no spirochaetes were found. The mother, a well developed married primipara, aged 22 years, had a considerable degree of pelvic contraction. Her pregnancy had been without incident, but the labour was a lengthy one and forceps had been applied unsuccessfully on two occasions before admission. When she was first seen the foetal heart was inaudible and movements had ceased. Craniotomy was performed and the child delivered less than twenty-four hours after the commencement of labour.

In Case No.795 the child was an exceptionally large and well nourished mature male. The left occipital region had been perforated and the brain destroyed. There was pallor and depletion of all the organs and tissues. One small subepicardial petechial haemorrhage was present on the surface of the right auricle, and a few subpleural petechiae were present over the lungs. There was practically somplete lack of expansion of the pulmonary tissue. The liver and spleen were not enlarged and the bones appeared healthy. Portions of lung, liver, spleen and kidney were examined by Levaditi's method but no spirochaetes were found. The mother was a healthy looking unmarried primipara, aged 28 years. Her pregnancy was without incident but the labour was delayed. A moderate degree of pelvic contraction was present (flat/

flat pelvis) and the breech presented. On admission labour had been in progress for twenty-four hours and the membranes had ruptured. The child was still alive but its very large head was fixed above the brim. The aftercoming head was perforated and delivery was effected.

In Case No.369 the child was a large and well developed female. The head had been perforated and the brain destroyed. There were a few minute areas of partial expansion in the lungs, several subpleural haemorrhages were present but otherwise the internal organs showed nothing worthy of note. The liver and spleen were not enlarged and the bones appeared healthy. Portions of lung, liver, spleen and kidney were examined by Levaditi's method but no spirochaetes were found. The mother was a multipara, aged 40 years, and she had a moderate degree of pelvic contraction. She was admitted some hours after the onset of labour and appeared exhausted. There was an occipito-posterior presentation. Scopolamine and morphine were given, and the next morning, as the foetal heart-rate was increasing, two unsuccessful attempts at delivery with forceps were made. The maternal pulse rate was also rising, and the child by this time was dead, the cord having prolapsed. Craniotomy was performed about twenty-four hours after admission. In her previous pregnancies the mother had borne six living and five still-born children, all after instrumental delivery.

There were 12 cases of Antepartum Haemorrhage, of which 6 were due to Placenta praevia and 6 were due to Accidental Haemorrhage.

Placenta Praevia.

In case No.155 the child was a well developed, mature female. There was some cyanosis of the left leg and foot. The meningeal veins and capillaries were moderately congested. In the heart there was congestion of the coronary veins and two or three subepicardial petechial haemorrhages were present near the A-V ring. The lungs, which were wholly unexpanded, had subpleural petechiae scattered over their surface. All the other organs were more or less congested and there was considerable post-mortem change throughout. The liver and spleen were not enlarged but the epiphyseal line at the lower end of the femur was irregular and showed a suggestion of a yellowish zone and a tendency to separation. All the centres of ossification were slightly paler than normally. There was nothing abnormal noted in the placenta. Portions of lung, liver, spleen and kidney were examined by Levaditi's method, but no spirochaetes were found. Marked autolytic change was present in the lung and kidney but no fibrosis was noted. The mother was a multipara, aged 38 years, and this was her eleventh pregnancy. Her health was good until three weeks before delivery, when she had some bleeding. This ceased, but began again five hours before/

before admission. A central placenta praevia was diagnosed, and packing was inserted temporarily. Later, internal version was performed after douching. A leg was pulled down and the child was delivered spontaneously about sixteen hours after the onset of labour. Death of the foetus appears to have occurred some time before delivery. The placenta was expelled by expression and the membranes were ragged and incomplete. The day after delivery the mother developed puerperal septicaemia. All her previous pregnancies had been normal - ten mature living children having been born spontaneously.

Case No. 470 was a large well developed, mature female. There was congestion of the meningeal veins and capillaries, but the tentorium was intact and no intracranial haemorrhage was present. The heart showed engorgement of the right auricle and congestion of the coronary veins. The lungs were both wholly unexpanded and there were one or two subpleural petechiae. There was marked congestion of the liver, and the spleen was large, firm and congested. There was nothing else worthy of note in the organs beyond congestion, and no haemorrhages were present. The epiphyseal line at the upper end of the femur was regular, but that at the lower end, though regular, showed slight suggestion of a pale zone. Portions of lung, liver, spleen and kidney were examined by Levaditi's method but no spirochaetes were found. The kidney showed marked post-mortem change in the parenchyma, the interstitial fibrous tissue appearing very prominent.

There/

There was no definite fibrosis, however. The mother was a multipara, aged 33 years, and this was her sixth pregnancy. Her health was good until the onset of a severe bleeding from a central placenta praevia three hours before admission. The presentation was changed from vertex to footling, and the dead child was delivered spontaneously about seven hours after the onset of labour. All the previous pregnancies had been normal and five mature living children were born.

Case No. 512 was one in which the child was a poorly developed premature female, the face and neck were cyanosed, and considerable headmoulding was present. The meninges were oedematous and there was congestion of the meningeal veins and capillaries. The brain tissue was also oedematous, and blood stained watery fluid was present in the ventricles. The right heart was engorged with blood and the coronary veins and capillaries were congested. The lungs, which were wholly unexpanded, showed numerous minute subpleural petechial haemorrhages. The kidneys were pale generally but showed a zone of congestion between the cortex and medulla. The peritoneal and pericardial sacs contained a moderate amount of clear, straw coloured fluid. The organs generally showed moderate or marked congestion, the liver and spleen were not enlarged and the bones appeared healthy. Portions of lung, liver, spleen and kidney were examined by Levaditi's method but no spirochaetes were found. The kidney showed marked post/

post-mortem degeneration of the epithelium but nothing suggestive of fibrosis. The mother was a primipara, aged 28 years. Throughout her pregnancy her health was good, but two days before admission she felt exhausted and the same evening haemorrhage began. It continued until the time of observation. The child presented by the vertex and appeared to be lively. The vagina was packed and a tight binder applied. Spontaneous delivery occurred thirty-six hours after the onset of labour but the child was dead. There was a marginal placenta praevia, which was retained, and had to be removed manually. The blood of both mother and child gave a negative W.R.

In Case No.644 the child was a well developed mature male, showing cyanosis of the head and of the extremities. There was some congestion of the meninges but no haemorrhage. The right auricle and ventricle were distended with blood and the coronary veins were congested. The lungs were wholly unexpanded. All the other organs were deeply congested, particularly the left kidney, and there were two minute subcapsular haemorrhages on the thymus. The liver and spleen were not enlarged and the epiphyseal line was regular at the upper end of the femur. At the lower end of the femur, however, the line was slightly irregular and showed a suggestion of a whitish zone, but there was little congestion in the cartilage and no tendency to separation. Portions of lung, liver, spleen and kidney were examined by Levaditi's method but no spirochaetes

were/

were found. The kidney showed marked post-mortem degeneration of the epithelium but nothing suggestive of fibrosis. The mother was a multipara, aged 30 years, and this was her ninth pregnancy. She had felt tired and out of sorts throughout the pregnancy but there were no definite symptoms till the onset of slight bleeding at the commencement of labour. A marginal placenta praevia was diagnosed, version was performed, and a foot was brought down. At the time no foetal heart sounds could be heard and when spontaneous delivery occurred two hours later the child was found to be dead. There had previously been seven full-time children and one premature (whose birth was associated with ante-partum haemorrhage). All the children were born alive. In the first pregnancy there was a retained placenta and in the seventh and eighth, as well as the present one, there was antepartum haemorrhage. Otherwise there was nothing worthy of note in the obstetric history.

In Case No.82 the child was a well developed female, showing cyanosis of the head and the upper part of the body. There was oedema of the meninges, and the meningeal veins and capillaries were congested, but there was no intracranial haemorrhage. The coronary veins and capillaries were congested and a few subepicardial petechiae were present. Both lungs were deeply congested and petechiae were present. All the other organs showed more or less congestion but the only other haemorrhage present was in the gastro-intestinal tract./

tract. Some haemorrhagic fluid had escaped from the mouth and the stomach contained a small quantity of mucous and blood, while the whole of the rest of the intestinal tract was filled with partially clotted blood. There was no evidence of ulceration and it was thought that the blood had been swallowed. Portions of lung, liver, spleen and kidney were examined by Levaditi's method but no spirochaetes were found. The lung showed a few incompletely expanded alveoli filled with blood. The bronchi and bronchioles also contained haemorrhagic material and there appeared to be slight perivascular fibrosis. In the liver considerable post-mortem change was present. A moderate number of primitive blood cells were found, particularly near the portal tracts, and there was well marked periportal fibrosis. Post-mortem change was well marked in the kidney but no fibrosis was detected. The mother was a multipara, aged 38 years, and this was her tenth pregnancy. She was well until the onset of severe harmorrhage from a marginal placenta praevia on the day of admission. The child was alive and presented by the vertex. Bipolar version was performed and three hours later the still-born child was delivered spontaneously. All the previous pregnancies had ended in the birth of ~~a~~ mature living children and the labours had been without incident.

No. 83 was a well developed, slightly premature male, showing no evidence of headmoulding. The veins and capillaries of the meninges were congested, particularly towards the base. The tentorium was intact but there was

some/

some haemorrhage beneath it. In the heart there were a few subepicardial petechial haemorrhages, and the lungs (which were congested and wholly unexpanded) showed numerous petechial haemorrhages both under the pleura and in the lung substance itself. The liver was greatly congested but was not enlarged. The spleen, which was firm and congested, was slightly larger than normal. All the other organs were congested and a few small haemorrhages were noted in the substance of the thymus. The bones appeared healthy. Portions of lung, liver, spleen and kidney were examined by Levaditi's method but no spirochaetes were found. Post-mortem change was well marked in the renal epithelium. The mother was a multipara aged 38 years, and this was her ninth pregnancy. She was well until bleeding began five hours before admission. The vagina was packed and later bipolar version was performed. At that time the child was alive but when spontaneous delivery occurred about twelve hours later it was dead. The marginal placenta praevia was expelled spontaneously and the membranes were complete. The mother was an apparently healthy woman, and, except for the use of instruments at her first confinement, her previous obstetrical history was without incident.

Accidental Haemorrhage.

Of the six cases of Accidental Haemorrhage, Case No.153 was one in which the child was a very premature female, poorly/

poorly developed and poorly nourished, which had lived for part of a day. There was a caput in the right parietal region and the whole scalp was oedematous. The meningeal veins and capillaries were congested and there was oedema of the meninges. In the left lateral ventricle there was found a spherical clot the size of a pea. The heart showed distension of the right auricle and congestion of the coronary veins and capillaries, and some subepicardial petechial haemorrhages were present. The lungs were partially expanded throughout and were nowhere completely airless. The liver was soft and friable and greatly congested. Neither it nor the spleen was enlarged. The kidneys were pale generally, but showed congestion at the junction of cortex and medulla and at the tips of the pyramids. The intestines were deeply congested and the stomach and small intestines were filled with slightly altered blood, while in the large bowel there was blood which was apparently due to less recent haemorrhage. No evidence of bleeding could be found in the oesophagus. All the other organs showed more or less congestion but nothing else worthy of note. The centres of ossification were pale and the epiphyseal line at the lower end of the femur was somewhat irregular. Portions of lung, liver, spleen and kidney were examined by Levaditi's method but no spirochaetes were found. The renal epithelium showed some disintegration in places. No fibrosis was noted. The mother was a multipara, aged 25 years, and this was her third pregnancy. She/

She was well until the occurrence of haemorrhage seven days before the onset of labour. The bleeding continued at intervals until admission. The length of labour is uncertain, but it appears to have been of only moderate duration. The child presented by the vertex and was born alive spontaneously. The mother's first and second pregnancies had both ended in the birth of living mature children. The Wassermann reaction of both the mother and the child was negative.

In Case No. 265 the child was a very premature female twin, sparely built and sparely nourished. There was some oedema of the meninges with slight haemorrhage at the base above the tentorium. The heart showed nothing worthy of note beyond congestion of the coronary vessels. The lungs were congested and wholly unexpanded and there were a few minute petechial haemorrhages under the pleura. The liver showed well marked congestion, as did also the medulla of the suprarenals. Otherwise the organs showed nothing worthy of note. The liver and spleen were not enlarged and the bones appeared healthy. Portions of lung, liver, spleen and kidney were examined by Levaditi's method but no spirochaetes were found. There was nothing worthy of note in the lung or kidney beyond a degree of autolytic change in the epithelial elements. The liver contained numerous collections of primitive blood cells and the stroma tissue was prominent. In the spleen there was slight increase in the fibrous tuberculae and in/

in the fibrous tissue surrounding the vessels. No other features worthy of note were found. The mother was a multipara, aged 28 years, and this was her fifth pregnancy. She had been in good health until a fortnight before delivery. At that time she is said to have had ptomaine poisoning, and while laid up she fell out of bed. From the time of this accident she was kept at rest and nothing abnormal was noted until antepartum haemorrhage began shortly before admission. Premature twins were born spontaneously four and a half hours after the onset of labour, and both were dead. The child at present under consideration was the second one, and was only about half the weight of the other. The mother was pale and had a moderate degree of secondary anaemia (3 million red cells and a colour index of .59). In her previous pregnancies she had borne four mature living children.

No. 294 was a case in which a small and very premature female child had been born alive and had lived for almost two days. There was a good deal of post-mortem change throughout. The meningeal veins and capillaries were congested, and there was a moderate amount of haemorrhage in both lateral ventricles, the masses of clot being adherent to, and apparently arising from the choroid plexus. The organs showed nothing of note beyond slight congestion, and the lungs were fairly well expanded except at the bases. The liver and spleen were not enlarged and the bones appeared healthy. Portions of lung, liver, spleen and kidney were examined by Levaditi's method but no

spirochaetes/

spirochaetes were found. Post-mortem change was well marked throughout the organs but no fibrosis was noted. The mother was a multipara, aged 31 years, and this was her sixth pregnancy. She had been in fairly good health, but for a week before admission she had had heavy work to do each day. On the morning of admission painless bleeding came on, followed a few hours later by labour pains. About twelve hours later the child was born alive, but the placenta with its ragged membranes had to be removed manually on account of adhesions. Except for two instrumental deliveries all her confinements were normal, and four living mature children were born. After the last confinement two years previously she had puerperal fever, and about a year later there was an abortion at about the sixth week of pregnancy.

In Case No. 401 the child was a premature male which lived for about an hour. The head was elongated and asymmetrical. There was congestion of the meningeal veins and capillaries and well marked oedema of the meninges was present. There was also slight capillary oozing of the meninges. There was nothing worthy of note beyond slight congestion in the organs. The lungs showed some areas of incomplete expansion. The liver and spleen were not enlarged and the bones appeared healthy. Portions of lung, liver, spleen and kidney were examined by Levaditi's method but no spirochaetes were found. The mother was a secundipara, aged 30 years, with a slight degree of pelvic contraction. About a week before admission some bleeding had occurred, but the patient/

patient was kept in bed and had no further bleeding till just before the onset of labour. The child was born alive spontaneously about twenty-four hours after the onset of the pains but it survived its birth only about an hour. The mother's first pregnancy had gone on to term and the child was still-born after a forceps delivery.

In Case No. 442 there was a slightly premature still-born male child, which was fairly well developed and well nourished. Congestion of the meningeal veins and capillaries was present, and though there was some oedema and capillary oozing there was no gross haemorrhage within the cranium. The heart showed congestion of the coronary vessels and there were several subepicardial haemorrhages near the A-V junction and at the roots of the great vessels. The lungs, which were wholly unexpanded, showed one or two petechial haemorrhages under the pleura. All the organs were congested and showed a good deal of post-mortem change The liver and spleen were not enlarged, and though there was a slightly pale zone at the epiphyseal line at the lower end of the femur, the line itself was regular and showed no congestion or tendency to separation. Portions of lung, liver, spleen and kidney were examined by Levaditi's method but no spirochaetes were found. The mother was a multipara, aged 37 years, and this was her eleventh pregnancy. Nearly a fortnight before admission she had fallen and bruised herself. Painless bleeding began two days before she was admitted but ceased after a few hours to return again with the/

the onset of labour. The child presented by the vertex and was delivered spontaneously four hours after the pains began. Although still-born, it had been alive at the commencement of labour. In her previous pregnancies the mother had borne ten mature children, and except that on the last four occasions instruments were used, the labours were without incident.

In Case No.914 there was a small poorly developed and premature female child, which had lived for nearly two days. There was congestion of the meningeal veins and capillaries and a moderate degree of haemorrhage had occurred into the left lateral ventricle. Beyond congestion of moderate degree, the organs showed nothing noteworthy. The lungs were on the whole fairly well expanded and patches of emphysema were noted in places. The left lower lobe, however, was dark, firm and congested, and had the appearance of bronchopneumonic consolidation. The liver and spleen were not enlarged and the bones appeared healthy. Portions of lung, liver, spleen and kidney were examined by Levaditi's method but no spirochaetes were found. The mother was an unmarried secundipara, aged 19 years. She was well throughout her pregnancy, but for several days before admission there had been occasional pain, and the night before admission bleeding began. When she was first seen the os was dilating and the child presented by the vertex. The membranes were ruptured artificially, and shortly afterwards spontaneous delivery occurred. The child lived for about two days. The mother had suffered from albuminuria during/

during her first pregnancy but had gone on to term and had borne a healthy living child. During her second pregnancy her health appears to have been fairly good, though on admission there was oedema of the feet and legs, and the urine was loaded with albumen. During the puerperium the albuminuria rapidly cleared up.

There were two cases in which marked pelvic contraction was present. Of these, Case No. 338 was one in which the child was a well developed and well nourished female and was practically mature. It showed pallor of the body surface and slight cyanosis of the face, and no marked headmoulding was present. There was congestion of the meningeal veins and capillaries all over, and a moderate amount of capillary oozing was present above and below the tenterium, which was intact. The coronary veins and capillaries in the heart were congested, and a few sub-epicardial petechial haemorrhages were present. Both lungs were fairly completely expanded but showed scattered areas of less complete expansion throughout. The kidneys were pale generally and the other organs showed moderate congestion. The liver and spleen were not enlarged and the bones appeared healthy. Portions of lung, liver, spleen and kidney were examined by Levaditi's method but no spirochaetes were found. The organs had undergone considerable post-mortem change but showed no evidence of fibrosis. The mother was a married primipara, aged 26 years, with a fairly marked degree of pelvic contraction. Labour/

Labour was induced with bougies and packing, and spontaneous delivery occurred three hours after the onset of pains. The child was alive but was made to breathe only with difficulty, and had several "bad turns" during which its colour became very pale. About twenty-four hours later it died. The mother showed marked rickety deformity of the long bones but was apparently healthy.

Case No. 896 was a fairly well developed male infant, slightly premature. There was absence of meningeal congestion and the brain tissue was slightly oedematous. The right auricle of the heart was engorged with blood and the ventricular walls appeared slightly thicker than usual. The coronary veins and capillaries were congested, several subepicardial petechial haemorrhages were present, and there were also noted one or two subendocardial haematomas in the mitral and tricuspid valves and three small subendocardial haemorrhages in the wall of the left ventricle. The lungs were congested and completely airless except for a few small areas of incomplete expansion. The kidneys were united at their lower poles. There was congestion of the renal tissue and some cloudy swelling and a small amount of haemorrhage had occurred in the perinephric tissues. The liver was extremely congested but the spleen was rather pale and flabby. Neither of these organs showed any enlargement, and the bones appeared healthy. The thyroid was/

was extremely congested and the other organs showed moderate congestion. Portions of lung, liver, spleen and kidney were examined by Levaditi's method but no spirochaetes were found. The mother was a secundipara, aged 35 years. She had a generally contracted pelvis and on this account labour was induced about the eighth month. The vertex presented and delivery was spontaneous, the child being born alive after a labour of moderate length. At first it appeared to be doing well, but on the fourth day it began to have twitchings in the face, which extended later to the body and limbs, and death occurred in a few hours. The mother was a rickety but otherwise healthy looking woman, and both her blood and that of the child gave a negative Wassermann reaction. Her first pregnancy had been normal and a living child had been born at term.

Maternal Albuminuria.

There were two cases associated with marked maternal albuminuria. Of these, one was case No.167. Here the child was a small, poorly developed, premature female, showing slight superficial maceration. There was some oedema of the scalp in the occipital region, and the meningeal veins and capillaries were congested. There was commencing maceration of all the organs. In the heart the coronary veins and capillaries were congested and numerous fairly large subepicardial petechial haemorrhages were present. The lungs were wholly unexpanded, and petechial haemorrhages were present in both parietal

and/

and visceral pleurae. The kidneys showed marked congestion of the medulla with relative pallor of the cortex. The liver and spleen were congested but neither showed any enlargement and the bones showed maceration only. All the other organs were congested and soft. Portions of lung, liver, spleen and kidney were examined by Levaditi's method but no spirochaetes were found. The organs showed marked post-mortem change. Collections of primitive blood cells were numerous in the liver but there was no evidence of fibrosis. The mother was a secundipara, aged 31 years, and on admission to the Ante-natal Department she was suffering from headache, dizziness, and loss of vision of about ten days' duration, and she had marked albuminuria. She was then about seven months pregnant. There had been oedema of the legs and scanty urine for about a month, and slight haemorrhage had been noted about the fourth and fifth months of pregnancy. Two days after admission premature labour began and the child was born dead, spontaneously, about seven hours later. The breech had presented. The placenta was expelled by expression. In her former pregnancy - a year previously - the mother had been in good health, and a living mature child was born.

In Case No. 733 the child was a well developed and well nourished mature female. There was bruising of the head and face and right side of the neck. On opening the head the meninges were found to be congested, but the only haemorrhage present was an area about 10 m.m. in diameter situated between the layers of the right half of the tentorium. The tentorium itself was intact. The

heart showed great engorgement of the right auricle, congestion of the coronary vessels, and one or two subepicardial petechiae. Both the lungs showed congestion and were for the most part unexpanded. There were several small petechial haemorrhages under the capsule and in the substance of the thymus, and the thyroid was moderately congested. Otherwise the organs showed nothing worthy of note. The liver and spleen were not enlarged and the bones appeared healthy. Portions of lung, liver, spleen and kidney were examined by Levaditi's method but no spirochaetes were found. The organs were congested and showed some post-mortem change. In the parenchyma no fibrosis was noted. The mother was a primipara, aged 20 years, who was admitted to the Ante-natal wards about the beginning of the ninth lunar month of pregnancy. She had been quite well until nine days before admission when dimness of vision developed. There was no headache, epigastric pain or sickness, but the visual acuity became progressively diminished, and oedema of the face and legs, which had been present in slight degree for about three months, became very marked. Albuminuria and signs of bronchitis were noted also. Labour was induced, and the child, which presented by the vertex, was delivered alive by forceps eleven hours after the onset of labour. The child died about fifteen hours later.

Hydramnios.

There was one case of Hydramnios (Case No.898) in which a small premature female was born alive and lived about three days. The meningeal veins and capillaries were congested and the meninges were oedematous. There was no gross intracranial haemorrhage. The heart showed marked engorgement of the right auricle and ventricle and the coronary veins and capillaries were congested. The lungs were well expanded for the most part, but both lower lobes were dark, firm and congested, and a few subpleural petechial haemorrhages were present. The kidneys were pale generally, with a narrow zone of congestion round the bases of the pyramids. All the other organs were congested. There was no enlargement of the liver or spleen and the bones appeared normal. Portions of lung, liver, spleen and kidney were examined by Levaditi's method but no spirochaetes were found. The mother was a married primipara, aged 18 years, who was admitted in labour. The pregnancy had been uneventful and the abdomen was enlarged to full-time size. A considerable degree of hydramnios was present, however, and when the child was born it was found to be premature. The vertex presented and delivery was spontaneous, but about thirty-six hours elapsed between the onset of labour and delivery. The mother was a small woman but appeared to be in good health.

Cicatrised Cervix was present in one case (No.826). The child was a poorly developed premature female - the first of twins. Slight superficial maceration was present all over and there was brown discolouration of the cord. There was not much evidence of a caput succedaneum, but there was marked headmoulding with overlapping of the parietal and occipital bones, associated with which there was some haemorrhage under the pericranium. The meningeal veins and capillaries were moderately congested and the tentorium cerebelli was intact. The heart showed one subepicardial petechial haemorrhage posteriorly. The lungs were wholly unexpanded and all the organs showed more or less congestion. In addition to the generalised slight maceration, the kidneys showed complete disintegration of the tissues lying at the junction of cortex and medulla. The spleen and liver were slightly enlarged but the bones showed maceration only. Portions of lung, liver, spleen and kidney were examined by Levaditi's method but no spirochaetes were found. The mother was a multipara, aged 28 years, and this was her fourth pregnancy. She was admitted about forty-eight hours after the onset of labour. There was a twin pregnancy and the first child presented by the vertex, the second by the breech. The case at present under consideration was that with the cephalic presentation. The labour was delayed by cicatrisation of the cervix, but /

but when this had been incised delivery was accomplished with the aid of forceps. The first child was dead and the second alive. The mother had previously borne three living mature children, but after the birth of the third there had been a vaginal operation for prolapse which had given rise to the scar which impeded labour. Otherwise, she was a healthy woman.

Premature Birth following Threatened Abortion occurred in one case (No.263). This was a premature male infant, which was born alive and lived less than two days. There was oedema of the meninges, the heart showed one or two subepicardial petechial haemorrhages, and the lungs were incompletely expanded. There was nothing worthy of note in the other organs. The liver and spleen were not enlarged but the epiphyseal line at both upper and lower ends of the femur showed slight irregularity with a distinct yellow zone, a band of congestion in the cartilage, and a tendency to separation. Portions of lung, liver, spleen and kidney were examined by Levaditi's method but no spirochaetes were found. The kidney showed congestion and slight granularity in the cytoplasm of the epithelial cells but no fibrosis was noted. The mother was a multipara, aged 33 years, and this was her seventh pregnancy. About three weeks before admission she began to have irregular pains, and on the day of admission the pain was accompanied/

accompanied by some haemorrhage. She was sent into hospital as a case of Threatened Abortion but no uterine contractions were noted until the onset of premature labour several days later. The child presented by the breech and was born alive spontaneously a few hours after the onset of the pains. It died, however, about thirty-six hours later. In her previous pregnancies the mother had borne four full-time living children and one premature child (which lived for thirty-six hours) and there had been one abortion. Her blood was examined on two separate occasions and both specimens, as well as a sample of the child's blood, gave a negative Wassermann reaction.

NEGATIVE GROUP.

Group 1. Sub-group ii.

This sub-group consists of 22 cases in which there was gross meningeal haemorrhage and it is divided into two sections. In Section A. are included 14 cases which showed gross intracranial haemorrhage not associated with haemorrhage elsewhere other than capillary oozings or petechiae. In Section B. are included 8 cases in which gross intracranial haemorrhage was associated with gross haemorrhage into internal organs or under the scalp.

Section A.

There were 3 cases of contracted pelvis.

Of these, case No. 131 was one in which the child was a large, well developed and mature male. There was cyanosis of the head and neck and of the upper part of the body. Headmoulding was well marked and the head was flattened and elongated towards the vertex. A caput was present over the parietals, and the scalp was oedematous generally, while in the right parietal region haemorrhage had occurred into the scalp and under the pericranium. The meningeal veins and capillaries were moderately congested but showed no extravasation of blood. The tentorium cerebelli was intact, but a small amount of subtentorial haemorrhage was present around the cerebellum, pons/

pons and medulla. The heart showed engorgement of the right auricle, congestion of the coronary veins and capillaries and a few subepicardial petechial haemorrhages scattered over the ventricles and the roots of the great vessels. The lungs were congested but were fairly well expanded throughout. The other organs showed marked congestion but nothing else worthy of note. The liver and spleen were not enlarged and the bones appeared healthy. Portions of lung, liver, spleen and kidney were examined by Levaditi's method but no spirochaetes were found. The mother was a married primipara, aged 19 years, who had a considerable degree of pelvic contraction. An unsuccessful attempt at forceps delivery had been made outside, and on admission to hospital the foetal head was in the pelvic cavity. There was a good deal of contraction at the outlet and by the time delivery had been effected with the aid of forceps the child was found to be dead. The labour had lasted less than twenty-four hours. The mother was slightly built but appeared quite healthy.

In Case No. 204 the child was a premature male twin, showing some superficial maceration of the legs. There was slight haemorrhage under the pericranium of both parietal bones and a good deal of haemorrhage had taken place into and under the scalp in the parietal and occipital regions. There was nothing worthy of note in the/

the meninges or brain or in the heart. The lungs were wholly unexpanded, rather pale in colour and studded with numerous subpleural petechial haemorrhages. Congestion was only slight in the liver and was not noted in any of the other organs. The liver and spleen were not enlarged and the bones appeared healthy. All the organs showed commencing maceration. Portions of lung, liver, spleen and kidney were examined by Levaditi's method but no spirochaetes were found. No evidence of fibrosis could be found in the organs. The mother was a multipara, aged 28 years, and this was her seventh pregnancy. A year previously she had influenza and pneumonia, but the pregnancy itself was without incident until the onset of ante-partum haemorrhage the day before admission. There was a twin pregnancy with marginal placenta praevia. The first child presented by the vertex, the second by the breech. After admission the membranes were ruptured artificially and the vagina packed, after which the bleeding ceased. The children were delivered spontaneously about fifteen hours after the rupture of the membranes. The exact duration of labour is uncertain, but it was at least twenty-four hours, and both the children were dead. The mother had previously borne six living mature children and her pregnancies and labours had been without complication except that the attack of pneumonia referred to above had/

had occurred about three months before the sixth child was born.

In Case No. 806 the child was a well developed mature female. The body surface was somewhat pale, headmoulding was well marked and the left parietal bone overlapped the right one. There was oedema of the scalp with haemorrhage into its posterior part. The meningeal veins and capillaries showed moderate congestion but no meningeal haemorrhage was present. Underneath the tentorium, (which was intact), a moderate amount of bleeding had occurred however. The heart showed nothing worthy of note beyond a few subepicardial petechial haemorrhages. The lungs were congested and wholly expanded and all the other organs showed more or less congestion. The liver and spleen were slightly enlarged but the bones appeared healthy. Portions of lung, liver, spleen and kidney were examined by Levaditi's method but no spirochaetes were found. There was no evidence of fibrosis in the spleen or kidney. The mother was an unmarried primipara, aged 24 years. She had a generally contracted, flat pelvis, and on admission the head was fixed and well through the brim, apparently caught by the symphysis pubis. Labour was allowed to continue for several hours after admission but the pains went off and did not reappear until twenty-four hours later when forceps were applied and the child was delivered. It was dead and a

considerable/

considerable amount of bruising had occurred from pressure of the sacral promontory on the head. The duration of labour was about forty-eight hours. The mother was a healthy woman and presented no obvious deformity beyond slight curvature of the tibiae.

Malpresentation.

There were 3 cases of malpresentation. In one of these (Case No. 681) the child was a well developed, well nourished, mature male, which showed slight pallor of the body surface generally and cyanosis and slight oedema of the feet. There was marked headmoulding and the scalp was oedematous. The meningeal veins and capillaries were congested and a moderate amount of haemorrhage was present above the tentorium. Very slight and incomplete bilateral tears of the tentorium were noted. The meninges and brain tissue were oedematous but there was no haemorrhage into the brain substance or ventricles. The heart showed nothing worthy of note. The lungs, which were congested and almost wholly unexpanded, had a few subpleural haemorrhages on their surface. The liver was slightly congested, but neither it nor the spleen showed any enlargement. There was marked congestion at the tips of the pyramids in the kidneys and in the medulla of the suprarenal, but otherwise the abdominal viscera showed nothing worthy of note. A good deal of oedema was present in the soft tissues of the posterior abdominal wall and of the/

the pelvis. The thyroid and thymus were congested. The centres of ossification showed no abnormality. Portions of lung, liver, spleen and kidney were examined by Levaditi's method but no spirochaetes were found. The kidney showed post-mortem degeneration but no fibrosis. The mother was a multipara, aged 40 years, and this was her twelfth pregnancy. Two months, and again one month before delivery there was some bleeding. This soon passed off, however, and her health otherwise was good till the onset of labour. The pains began about a fortnight before admission and lasted more or less continuously until delivery. On admission the child was presenting transversely with an arm prolapsed, and severe pains had been in progress for nearly six hours. The child was turned to a footling, and spontaneous delivery occurred about two and a half hours later. The foetal pulse had been audible till just before delivery but the child was still-born. In her previous pregnancies the mother had borne eight full-time living children, and two others had been carried till term but were still-born on account of difficult labour and breech presentation. Between the birth of the last child and the present pregnancy there was one early abortion. The mother was a fairly healthy looking woman, rather pale but with no obvious deformity. A slight degree of pelvic contraction was present, however.

Case No. 962 was a large, well developed and well nourished/

nourished male, showing oedema of both lower extremities with exfoliation of the epidermis of the left leg. The meningeal veins and capillaries were congested and there was some capillary oozing over the vertex. A small amount of supratentorial haemorrhage was present at the base and there was a tear about half an inch in length in each half of the tentorium. There was no haemorrhage into the brain tissue or ventricles. The heart showed moderate congestion of the coronary veins and capillaries and the lungs were congested and almost wholly unexpanded. There was some congestion of the liver and spleen but neither showed any enlargement. The epiphyseal line at the lower end of the femur was regular but there was a narrow white zone close to it and beyond this - in the cartilage - there was a zone of congestion with radiating streaks passing from it. The lower end of the femur and the upper end of the femur, ulna and radius all appeared normal. Portions of lung, liver, spleen and kidney were examined by Levaditi's method but no spirochaetes were found. The mother was a primipara, aged 24 years, and her pregnancy was without incident. She was admitted in labour with the breech presenting, and the pains had been in progress for fifteen hours. The child was born spontaneously shortly afterwards and had apparently been dead for some time.

In Case No. 978 the child was a well developed and well nourished male, showing cyanosis of the head and upper/

upper half of the body. There was well marked generalised meningeal haemorrhage both above and below the tentorium and extending down the spinal cord. An incomplete tear was present on each half of the tentorium close to the falx and involving the superficial layers only. The heart showed engorgement of the right auricle and congestion of the coronary veins and capillaries. The lungs, which were congested, showed a few areas of partial expansion at the margins, and several subpleural petechial haemorrhages on the surface. The liver and spleen were greatly congested but were not enlarged. All the organs showed marked congestion but nothing else worthy of note. The bones appeared healthy. Portions of lung, liver, spleen and kidney were examined by Levaditi's method but no spirochaetes were found. The mother was a multipara, aged 40 years, and this was her ninth pregnancy. For a month before admission she had felt tired and had noticed swelling of the lower limbs. She was pale and anaemic-looking and had a mitral systolic murmur. When admitted she had been in labour for some hours. The breech, which presented, was impacted, and the child was dead, but delivery occurred spontaneously shortly afterwards. During the puerperium a blood count showed a marked degree of anaemia, there being under two millions red cells and a colour index of about one. Films showed many of the characters of pernicious anaemia. In her previous pregnancies she had borne seven full-time living children, and/

and there had been one miscarriage at the sixth month. The blood of both the mother and child gave a negative Wassermann reaction.

Maternal Chronic Nephritis.

In Case No. 73 the child was a well developed, well nourished, mature female, showing marked headmoulding and bruising of the scalp. A moderate amount of meningeal haemorrhage was present all over the cerebrum but there was no subtentorial haemorrhage. An incomplete tear was present in the tentorium on the left side, involving its upper layers only, and there were also one or two small areas of haemorrhage into its substance. The heart showed well marked engorgement of the right auricle and ventricle, congestion of the coronary veins and capillaries and a few subepicardial petechial haemorrhages near the A-V ring and over the roots of the great vessels. The lungs were congested and wholly unexpanded and showed numerous subpleural ecchymoses. There was nothing worthy of note in the other organs. The liver and spleen were not enlarged and the bones appeared healthy. Portions of lung, liver, spleen and kidney were examined but no spirochaetes were found. The lung was congested and oedematous and showed catarrhal changes in the alveolar epithelium. The kidney also showed marked congestion with widespread degeneration in the tubular epithelium, particularly in that of the convoluted tubules. There was no evidence of fibrosis. The mother was an unmarried primipara, aged 15 years, who was admitted to the Ante-natal Department on/

on account of chronic nephritis. At the commencement of labour the child was alive and presented by the vertex. Forceps were applied and delivery occurred about eight and a half hours after the onset of the pains but the child was dead. There was some post-partum haemorrhage. Two days after delivery the mother went into uraemic coma and died.

Placenta Praevia.

Case No. 610 was one in which the child was a premature female twin. There was slight superficial maceration of the legs but the cord had not turned brown. Slight haemorrhage was present under the epicranium of the occipital and both parietal bones. The meningeal veins and capillaries were congested and there was a moderate amount of haemorrhage at the base of the brain both above and below the tentorium. The tentorium itself showed a complete tear on the left side close to the middle line, extending backwards from its free edge for about three quarters of an inch, and there was also an incomplete tear on the right side involving the upper layers only. The heart showed engorgement of the right auricle, congestion of the coronary veins and capillaries and several large subepicardial ecchymoses. The lungs were wholly unexpanded and congested and a few subpleural petechial haemorrhages were present. The liver and spleen were congested but neither showed any distinct enlargement, and the bones were healthy in appearance.

There/

There was nothing of note in the other organs beyond some congestion and some post-mortem change. Portions of lung, liver, spleen and kidney were examined by Levaditi's method but no spirochaetes were found. The kidney showed post-mortem degeneration of the tubular epithelium but there was no fibrosis. The mother was a multipara, aged 28 years, and this was her seventh pregnancy. She was well until the onset of haemorrhage from a marginal placenta praevia the day before admission. The bleeding lasted for some hours but was arrested by packing. The time of onset of the pains is indefinite but the labour appears to have been of moderate duration. The children were born spontaneously and both were dead. In the case under consideration the child presented by the breech while the other (first twin) presented by the vertex. Each of her six previous pregnancies had ended at term in the birth of a living child, but during the sixth pregnancy she had suffered from influenza and pneumonia.

In Case No. 675 the child was a poorly developed premature male. A moderate degree of headmoulding was present with a large caput, and there was haemorrhage into and under the scalp in the left parietal region. The meningeal veins and capillaries were deeply congested and a moderate degree of generalised meningeal haemorrhage was present. The tentorium was intact and there was no bleeding under it. The heart showed congestion of the coronary/

coronary veins and capillaries and numerous subepicardial petechial haemorrhages. Several haematomas were noted also on the mitral and tricuspid valves. The lungs were congested and wholly unexpanded and showed very numerous subpleural petechiae. The liver and spleen showed no marked congestion and were not enlarged. The kidneys were rather oedematous and the cortex was pale relatively to the medulla. The suprarenals also showed congestion of the medulla but there was nothing worthy of note in the other organs. The epiphyseal line in the femur was slightly irregular but was otherwise perfectly normal in appearance. Portions of lung, liver, spleen and kidney were examined by Levaditi's method but no spirochaetes were found. A moderate degree of post-mortem change was present in the renal parenchyma but there was no fibrosis. The mother was a multipara, aged 44 years, and this was her tenth pregnancy. She had been well until the third month of pregnancy when slight bleeding occurred. After that there was no unusual incident until severe bleeding from a central placenta praevia began twelve hours before admission. When first seen, the patient was pale and collapsed and was bleeding freely. The foetus appeared to be dead. The vagina was packed and the child was born spontaneously about eleven hours after the onset of labour. In her previous pregnancies the patient had borne seven mature living children and there had been one premature still-birth and one early abortion.

In/

In Case No. 336 the child was a well developed, well nourished, mature male, showing cyanosis of the feet and lower part of the legs. There was no marked headmoulding, but a roughly circular saucer-like depression was present on the left parietal bone. There was no bruising of the overlying tissues. The meningeal veins and capillaries were congested and there was some capillary oozing over the vertex. At the base haemorrhage was of moderate amount above the tentorium and well marked under the tentorium. The latter structure had a tear on each side of the falx involving the upper and middle layers, but there was no haemorrhage into the brain substance or ventricles. The heart showed engorgement of the right auricle, slight congestion of the coronary veins and capillaries, one small subepicardial haemorrhage just at the root of the aorta and a minute haematoma on the tricuspid valve. The lungs, except for a few minute areas at the margin, were almost completely unexpanded. The liver was moderately congested and the spleen slightly congested, but neither showed any enlargement and the bones appeared healthy. There was nothing worthy of note in any of the other organs except that the left kidney showed marked general congestion while the right one was relatively pale. Portions of lung, liver, spleen and kidney were examined by Levaditi's method but no spirochaetes were found. The left kidney showed very marked congestion with degeneration of the parenchyma. The right kidney/

kidney showed moderate congestion only, with well marked degeneration of the tubular epithelium, particularly that of the convoluted tubules. There was no fibrosis. The mother was a multipara, aged 37 years, and this was her third pregnancy. There had been some painless bleeding about the third month, and again fourteen days before admission. On the evening before she came in fairly severe haemorrhage began and continued. When admitted, the child was alive and presented by the breech and placenta praevia was diagnosed. Bleeding was not severe at first, and the labour was allowed to go on without interference. A few hours later, however, the amount of haemorrhage increased and there were signs of maternal and foetal distress. The membranes were accordingly ruptured artificially, and the child was born spontaneously less than two hours afterwards. Apart from the effects of haemorrhage, the mother appeared healthy, and both her blood and that of the child gave a negative W.R. Her first pregnancy had ended prematurely in the birth of a still-born child, and her second pregnancy had ended in miscarriage.

Maternal Albuminuria.

In Case No. 879 the child was a well developed, still-born female, practically mature. There was cyanosis of the body surface generally. The meningeal veins/

veins and capillaries showed marked congestion and there was a moderate amount of haemorrhage all over the surface of the brain, both above and below the tentorium. The tentorium itself showed a complete tear on each side of the falx, extending on the left side into the lateral sinus. The right auricle of the heart was engorged with blood, and the coronary veins and capillaries were congested. The lungs showed several subpleural petechial haemorrhages and were congested and completely unexpanded. All the organs showed congestion, in some cases of a marked degree. The liver and spleen were not enlarged and the bones appeared healthy. Portions of lung, liver, spleen and kidney were examined by Levaditi's method but no spirochaetes were found. The mother was a primipara, aged 28 years, who had suffered from swelling of the feet and legs, with marked albuminuria during the last months of her pregnancy. She was under treatment at home, and showed considerable general improvement, but on admission the urine was almost solid with albumen. Labour was somewhat premature and was of moderate duration, and instruments were not used. The child's heart was beating at the time of delivery but it could not be resuscitated. During the puerperium the mother's condition improved rapidly and by the fourth day after delivery the amount of albumen was reduced to a mere haze.

Eclampsia.

In Case No. 393 the child was a well developed, mature/

mature male, showing marked pallor of the body surface generally. A large caput was present in the left occipito-parietal region. The meningeal veins and capillaries were not congested, but a moderate amount of supratentorial haemorrhage was present, and there was a complete tear of the tentorium on the left side. The heart showed no marked engorgement of the right auricle but there were several subepicardial petechial haemorrhages. The lungs were almost completely airless but showed some minute scattered areas of partial expansion. The liver and spleen were not enlarged and the bones appeared healthy. Portions of lung, liver, spleen and kidney were examined by Levaditi's method but no spirochaetes were found. The mother was a primipara, aged 27 years, who had suffered from pain in the back and abdomen for fourteen days before delivery. Labour appears to have begun about a week before admission, and the day before admission the pains increased in strength. When first seen the vertex was presenting and the foetus was dead. There was a slight degree of pelvic contraction and the child was delivered with forceps. Post-partum eclampsia developed but was soon controlled by treatment. The woman was very emaciated and pale, and there was slight albuminuria. She gave a history of pulmonary disease but no active lesion was detected while she was under observation.

Accidental/

Accidental Haemorrhage.

In Case No. 584 the child was a well developed and well nourished male, showing haemorrhage under the pericranium in the right parietal region. The meningeal veins and capillaries were congested, there was slight supratentorial haemorrhage, and a tear of the tentorium was present on the right side close to the falx. In the heart there was congestion of the coronary veins and capillaries and a few subepicardial petechial haemorrhages were present. The lungs, which were congested and showed some subpleural ecchymoses, were airless. All the other organs showed a considerable degree of congestion. The liver was of normal size but the spleen was markedly enlarged. The epiphyseal lines at both ends of the femur appeared perfectly normal. Portions of lung, liver, spleen and kidney were examined by Levaditi's method but no spirochaetes were found. The mother was a multipara, aged 27 years, and this was her third pregnancy. During the early months she had "threatened appendicitis and pleurisy" but she was otherwise well until the morning of admission. At that time she passed a quantity of thick, dark coloured blood, and thereafter no life was felt. On admission the membranes were artificially ruptured and a tight binder was applied. The child presented by the vertex, and a few hours after the onset of labour it was spontaneously delivered. The heart was not beating. The placenta was expelled spontaneously along/

along with a large quantity of clot. The mother had previously borne two mature living children and there was nothing worthy of note in her previous pregnancies.

Bronchopneumonia.

In Case No.659 the child was a poorly developed, premature male. A slight amount of haemorrhage was present over the meninges on the upper, lower and lateral surfaces of the cerebrum. This haemorrhage looked as if it had occurred some time previously. A small incomplete tear was present on the right half of the tentorium involving its upper layers only but there was no infratentorial haemorrhage. The heart showed some engorgement of the right auricle. In the lungs there were numerous dark, consolidated patches, chiefly in the lower lobe, and these had the naked-eye and microscopic appearances of bronchopneumonic consolidation. Except that there was well marked cloudy swelling in the kidneys, there was nothing else worthy of note in the organs. The liver and spleen were not enlarged and the bones appeared healthy. Portions of lung, liver, spleen and kidney were examined by Levaditi's method but no spirochaetes were found. The mother was an unmarried primipara, aged 20 years, and her pregnancy was without incident until the onset of premature labour. Twins were born - both alive - seven hours after the onset /

onset of the pains and delivery was spontaneous. Both children died on the third day. The blood of both the mother and the children gave a negative Wassermann reaction.

Section B.

Contracted Pelvis.

There was one case of contracted pelvis in this section.

In Case No.723 the child was a well developed, mature male, showing marked headmoulding, with haemorrhage and oedema into and under the scalp, and haemorrhage under the epicranium (with overlapping of the bones). There were two transverse fractures of the frontal bone extending from the left side across to the right. Sub-conjunctival haemorrhage was present. The meningeal veins and capillaries were congested and there was generalised meningeal haemorrhage, most marked at the base above and below the tentorium. There was a small complete tear on each half of the tentorium itself. The heart showed engorgement of the right auricle, congestion of the coronary veins and capillaries, and numerous subepicardial petechiae. The lungs were congested and wholly unexpanded. There was congestion of all the other organs, but nothing else/

else worthy of note. The liver and spleen were not enlarged and the bones appeared healthy. Portions of lung, liver, spleen and kidney were examined by Levaditi's method but no spirochaetes were found. The mother was a multipara, aged 32 years, and this was her ninth pregnancy. There was nothing worthy of note until the onset of labour when delay occurred owing to pelvic contraction. The membranes ruptured early, and high forceps were applied to effect delivery. The child was born dead about thirty-six hours after the onset of the pains. The mother had previously borne eight mature children - the first two were delivered instrumentally, and were still-born, while the others were all born alive, spontaneously.

There were three cases of "failed forceps".

In case No.559 the child was well developed, mature male, showing superficial bruising of the right side of the face and head. There was some haemorrhage into the scalp and also under the pericranium. The meningeal veins and capillaries were congested and a small amount of bleeding had occurred above and below the tentorium. On the left side there was a complete tear of the tentorium, while on the right side there was haemorrhage into its substance. The heart showed nothing worthy of note beyond some engorgement of the right auricle, but the lungs had numerous small, dark, haemorrhagic/

haemorrhagic areas scattered throughout their lower lobes. These dark areas had the consistence and appearance of bronchopneumonic consolidations. Elsewhere the lung tissue had been well expanded. The kidneys showed some post-mortem change but otherwise the internal organs showed nothing worthy of note. The liver and spleen were not enlarged and the bones appeared healthy. Portions of lung, liver, spleen and kidney were examined by Levaditi's method but no spirochaetes were found. The mother was a multipara, aged 28 years, who had suffered from epileptic fits for seven years. She had not felt well during pregnancy and had complained of pains in the back. Labour had been in progress for five hours before admission and the case was sent in as one of impacted shoulder or locked twins. Forceps had been applied unsuccessfully. When examined, the head was at the perineum and shortly afterwards the child was born spontaneously. It was alive but showed marks of bruising with forceps and it was blue in colour all over. The head was of large size and was well ossified. The following day the child died. There was no pelvic contraction in the mother and she had previously borne three mature, living children. The blood of both mother and child gave a negative W.R.

Case No.642 was one in which the child was a well developed, mature female, showing cyanosis of the body surface/

surface, well marked headmoulding and a large caput in the left parietal region. There was oedema of the scalp generally and some subepicranial haemorrhage was present over the left parietal bone. The meningeal veins and capillaries were deeply congested and a moderate amount of meningeal haemorrhage was present over the vertex. There was a complete tear on the left side of the tentorium and both supra and infra-tentorial haemorrhage was present. The brain was deeply congested but there was no haemorrhage into its substance or into the ventricles. The heart showed very marked engorgement of the right auricle and ventricle, deep congestion of the coronary veins and capillaries and several subepicardial petechial haemorrhages. There were several subendocardial haematomas on the mitral and tricuspid valves. The lungs showed one or two minute areas of partial expansion, but were otherwise deeply congested and completely airless. The liver was markedly congested and there was a small area of subcapsular haemorrhage on the under surface of its right lobe. Both liver and spleen were slightly heavier than normally, but the bones appeared healthy. All the other organs showed marked congestion. Portions of lung, liver, spleen and kidney were examined by Levaditi's method but no spirochaetes were found. The mother was a multipara, aged 27 years, and this was her third pregnancy. Her pelvis was contracted but otherwise there was no marked deformity. The pregnancy had/

had been without incident until the onset of labour. Forceps were applied unsuccessfully outside, and when she was admitted there was marked exhaustion and the child was dead. Forceps were again applied and the foetus was delivered about twenty-four hours after the onset of the pains. In her former pregnancies the mother had borne two mature children, the first being still-born and the second live-born. In both cases there was an instrumental delivery.

In Case No.836 the child was an exceptionally large, mature female. There was marked headmoulding with haemorrhage into and under the scalp. The meningeal veins and capillaries were deeply congested and there were a few small areas of meningeal haemorrhage over the vertex. At the base there was a small amount of supra and intra-tentorial haemorrhage, and the tentorium itself showed an incomplete tear of the superficial layers on the right side. The heart showed engorgement of the right auricle, the coronary veins and capillaries were congested but there were no subepicardial petechiae. A few small sub-endocardial haematomas were present, however. The lungs were congested generally and wholly unexpanded, and they showed numerous subpleural ecchymoses. The liver was deeply congested and showed two areas of subcapsular haemorrhage on the under surface of the right lobe and a third area over which there had been separation of the/

the capsule, with rupture and escape of blood into the abdominal cavity. The liver and spleen, though deeply congested, showed no definite enlargement and the epiphyseal lines were normal in appearance. All the organs showed marked congestion. Portions of lung, liver, spleen and kidney were examined by Levaditi's method but no spirochaetes were found. The mother was a multipara, aged 35 years, and this was her eleventh pregnancy. She was well until the onset of labour. The pains were apparently somewhat irregular at first and forceps were applied unsuccessfully outside. On admission the child was presenting by the vertex and was apparently dead. Spontaneous delivery occurred about thirty hours after the onset of labour. In her previous pregnancies all the children had been mature and all were born alive - three were delivered with forceps but the others were born spontaneously.

Malpresentation.

In Case No.472 the child was a well developed male. There was slight meningeal haemorrhage over the vertex and rather more marked supra-tentorial haemorrhage at the base. A small complete tear of the tentorium cerebelli was present on each side, close to the falx. The heart showed engorgement of the right auricle and ventricle, and congestion of the coronary veins and capillaries.

The /

The lungs were congested, and, except for a few minute areas of incomplete expansion, they were quite airless. A few minute subpleural petechiae were present. The liver was congested and showed an area of subcapsular haemorrhage about an inch in diameter on the under surface of the right lobe. All the other organs showed more or less congestion, but it was particularly marked in the suprarenals and kidneys. The left suprarenal showed a slight amount of haemorrhage at its lower pole superficially, while there was fully a dram of free blood in the centre of the right one. The left kidney was dark brownish-red in colour but showed no actual haemorrhage into its substance. There was no thrombosis of the renal or suprarenal veins, and the ureter and bladder appeared healthy. There was, however, haemorrhage round the pelvis and calyces of the kidney, and a large amount of blood was extravasated into the perinephric tissues and extended subperitoneally as far downwards as the brim of the pelvis, while its upper limit surrounded the lower pole of the left suprarenal. The right kidney showed nothing worthy of note beyond a moderate degree of congestion. The liver and spleen were not enlarged and the bones appeared healthy. Portions of lung, liver, spleen and kidney were examined by Levaditi's method but no spirochaetes were found. The mother was a primipara, aged 34 years. She had been very sick/

sick and much troubled with vomiting throughout her pregnancy but was otherwise healthy. Labour had been in progress for about twenty hours before she was seen. The breech presented and the child was alive and very active and the membranes had been ruptured for about five hours. About an hour and a half after admission spontaneous delivery occurred. It is to be noted that the child had presented in the R.S.A. position and showed a tendency to a transverse lie. It was dead on delivery.

In Case No.955 the child was a large, well developed, mature male, showing pallor of the body surface. A small amount of haemorrhage was present into and under the pericranium of the left parietal bone. The meningeal veins and capillaries showed only a moderate degree of congestion and there was no haemorrhage over the vertex. A large amount of infratentorial haemorrhage was present and there was a complete tear through the right side of the tentorium itself. The heart showed nothing worthy of note and the lungs were wholly unexpanded. All the organs were moderately congested. There was a small amount of haemorrhage in the centre of the left supra-renal, and the left kidney showed a slight degree of extravasation of blood round its pelvis. There was no haemorrhage into the kidney substance and no thrombosis was /

was detected. The liver and spleen were not enlarged and the bones appeared healthy. Portions of lung, liver, spleen and kidney were examined by Levaditi's method but no spirochaetes were found. The mother was a multipara, aged 33 years. She had complained of sickness and vomiting throughout her pregnancy but was otherwise healthy and free from deformity. When she was admitted the pains had been in progress for about seven hours. The face presented, and the child was alive. Version was performed and almost twelve hours after the onset of labour the child was born dead spontaneously. The membranes had ruptured about nine hours before delivery. In her previous pregnancies the mother had borne two mature living infants, one of which was born spontaneously while the other was delivered by forceps.

Placenta Praevia.

In Case No.174 the child was a mature but poorly developed female, showing some superficial bruising of the chest. There was congestion of the meningeal veins and capillaries and slight supratentorial haemorrhage was noted at the base. There was also a considerable amount of infra-tentorial haemorrhage and bilateral complete tears of the tentorium itself were present, extending outwards on each side from close to the falx. There/

There was nothing worthy of note in the heart beyond the presence of a few subspicardial petechiae. The lungs were almost completely airless and showed several subpleural ecchymoses. The left suprarenal showed a small amount of haemorrhage in the upper part of its medulla, while the right one, though deeply congested, showed no actual extravasation. The kidneys showed only slight congestion generally but there were small areas of haemorrhage into the kidney substance at the tips of several of the pyramids. The other organs showed nothing worthy of note. The liver and spleen were not enlarged and the bones appeared healthy. Portions of lung, liver, spleen and kidney were examined by Levaditi 's method but no spirochaetes were found. The mother was a multipara, aged 41 years, and this was her third pregnancy. She was well until the onset of bleeding from a placenta praevia (marginal) a few hours before admission. She was sent in with packing in situ. The breech presented and delivery was spontaneous about twelve hours after the onset of labour but the child was dead. The placenta was removed manually and was ragged in appearance. There was slight post-partum haemorrhage on the day of delivery.

Precipitate Labour.

In Case No.403 the child was a well developed, mature female, which lived for about three days. There was slight general pallor of the body surface and the scalp was oedematous over the vertex. In the occipital region there was haemorrhage into and under the scalp, extending downwards to the upper cervical region. The meningeal veins and capillaries were moderately congested and there was a considerable amount of generalised haemorrhage over the vertex, and particularly above the tentorium at the base. Under the tentorium a small amount of bleeding had occurred and there was a tear on the right side, involving the superficial layers of the tentorium itself. There was no engorgement of the right auricle of the heart or congestion of the coronary vessels, but several small haematomas were present on the tricuspid valve. The lungs were both well expanded but showed numerous haemorrhagic areas throughout. There was nothing of note in any of the other organs except that the stomach and part of the small bowel were filled with altered blood. There was no evidence of ulceration and the blood appeared to have been swallowed. The liver and spleen were not enlarged and the bones appeared healthy. Portions of lung, liver, spleen and kidney were examined by Levaditi's method but no spirochaetes were found. The mother was a primipara, aged 26 years, and her health/

health before and during the pregnancy had been excellent. The labour was without incident but was precipitate. The vertex presented and the child was born alive spontaneously, two hours later.

NEGATIVE GROUP.

Group I. Sub-group iii.

This sub-group contains all cases of gross haemorrhage into or from internal organs not associated with intracranial haemorrhage. It is composed of 16 cases. Of these 16 cases there were four which had been delivered after craniotomy and would probably have shown intracranial haemorrhage had the head been intact, so that the number of cases in this sub-group should, perhaps, be smaller.

Of the four cases of craniotomy one (Case No.154) was a large, well developed, mature female, showing pallor of the body surface. The brain had been destroyed. In the heart there was some congestion of the coronary veins and capillaries and a small quantity of haemorrhagic fluid was present in the pericardial sac. A few small subepicardial haemorrhages were present over the surface of the heart and of the great vessels, and there were also three haematomas of pin-point size on the tricuspid valve. The lungs were congested and almost completely airless but there were no subpleural petechiae. All the other organs were more or less congested and there was one small subcapsular haemorrhage in the liver, while numerous petechiae were present under the capsule of the thymus. The liver and spleen were not enlarged and the bones appeared healthy. Portions of lung, liver, spleen and kidney were examined by Levaditi's method but no spirochaetes/

spirochaetes were found. The mother was a multipara, aged 34 years, and this was her fifth pregnancy. There was no incident worthy of note until the onset of labour, and the mother herself was healthy and free from deformity. Labour had been in progress for only a short time before admission but the cord had prolapsed and was almost pulseless. After the cord had been replaced an attempt was made to deliver by forceps but without success. As the child was dead the head was perforated and the foetus delivered. In her previous pregnancies the mother had borne four full-time living children and all her labours were normal.

In Case No.160 the child was a well developed mature male. The head had been crushed and the brain destroyed, and there was a deep lacerated wound in the back in the mid-lumbar region. The heart showed absence of engorgement and congestion and there were no petechiae. The lungs were dark, soft and wholly unexpanded. All the other organs showed more or less congestion and post-mortem softening, and there was an area of haemorrhage about an inch in diameter under the capsule of the liver on the anterior surface of its right lobe. The liver and spleen were not enlarged and the bones appeared healthy. Portions of lung, liver, spleen and kidney were examined by Levaditi's method but no spirochaetes were found.

The/

The mother was a secundipara, aged 39 years. The pregnancy was without incident but the breech presented and the pelvis was contracted. On admission the child was born as far as the umbilicus and the cord had prolapsed and was pulseless. The after-coming head was perforated and the child delivered. In her former pregnancy the mother had borne a full-time child but delivery was effected only after forceps had failed and craniotomy had been performed.

In Case No.440 the child was a moderately well developed mature female, showing pallor of the body surface. The head had been crushed and the brain destroyed and there was evidence of marked headmoulding. The heart showed deep congestion of the coronary veins and capillaries, with numerous subepicardial petechial haemorrhages, some of considerable size, all over the heart and the roots of the great vessels. The deeply congested lungs were completely airless and there were numerous subpleural haemorrhages on the visceral and parietal surfaces and a few small areas of haemorrhage in the lung tissue itself. The liver was greatly congested but there was no subcapsular haemorrhage. The kidneys both showed deep congestion, and the left one had a dark haemorrhagic appearance, the tissues being somewhat necrotic. There was no thrombosis of the renal veins, however. All the other organs showed congestion and/

and there was one small petechial haemorrhage under the capsule of the thymus. The liver and spleen were not enlarged and the bones appeared healthy. Portions of lung, liver, spleen and kidney were examined by Levaditi's method but no spirochaetes were found. The mother was a primipara, aged 32 years, and her pelvis was badly contracted. She was well throughout her pregnancy but five days before admission the membranes ruptured painlessly. Three days later severe pains began and continued, and on admission the patient's condition was critical, a hand was presenting at the cervix but the head was not fixed and the child was still alive. The following day, as no progress had been made the cervix was dilated manually, the head perforated and the child delivered. Shortly before delivery the mother had two eclamptic fits. The total duration of labour was almost six days.

In Case No.241 the child was a well developed, mature female, with the head crushed and the brain destroyed. In addition to craniotomy there had been decapitation and there was bruising of the legs and left arm and a lacerated wound was present in the left axilla. The organs were depleted, and the only haemorrhage noted was in the substance of the left lung. The liver and spleen were not enlarged and the bones appeared healthy. Portions of lung, liver, spleen and kidney were examined by Levaditi's method but no/

no spirochaetes were found. The mother was a multipara, aged 40 years, and this was her eighth pregnancy. For some months she had been breathless and had suffered from insomnia, and when admitted she was pale and slightly jaundiced. The practitioner who saw her outside thought there had been some hydramnios. The vertex presented and he pulled down both arms. About eight hours after the onset of the pains the patient was sent in. Both arms were presenting and the head and shoulders were impacted at the cervix. The child, which was of medium size, was dead. Craniotomy and decapitation were performed to effect delivery. The mother had previously borne five mature children, two of which appear to have been still-born - one on account of a breech presentation - while the remaining two of her seven pregnancies ended in abortion.

Subcapsular Liver Haemorrhage.

There were 8 cases of subcapsular liver haemorrhage, two of which (Nos.154 and 160) have already been described amongst the cases of craniotomy.

In Case No.153 the child was a poorly developed premature female. There was no evidence of headmoulding but the body surface was deeply cyanosed. The meningeal veins and capillaries were greatly congested and there was generalised capillary oozing in the meninges. No rupture of the tentorium could be found but there was a moderate amount of bleeding under it, surrounding the cerebellum, pons and medulla. The right auricle was engorged/

engorged with clotted blood and there was extreme congestion of the coronary veins and capillaries and many extensive areas of subepicardial haemorrhage were present. The lungs showed a few areas of incomplete expansion at their extreme margin but were otherwise airless. They were deeply congested, in places appearing almost haemorrhagic, and some subpleural petechiae were present. The liver was extremely congested and had two or three small subcapsular haemorrhages on its surface. All the other organs were congested and there were several minute petechiae in the pelvis of the left kidney and under the capsule of the thymus. The peritoneal cavity contained a small quantity of clear straw-coloured fluid, and the peritoneal surface of the stomach showed passive congestion. This was also well marked in the small intestine. In the stomach the mucosa was congested, but the gastric contents were not blood stained. In the small intestine, however, the congestion of the mucosa was extreme and the lumen was filled with blood. No evidence of ulceration was found in the small intestine and there was no blood in the colon. The liver and spleen were not enlarged and the bones showed no abnormality except slight irregularity in the epiphyseal line unaccompanied by any other change. Portions of lung, liver, spleen and kidney were examined by/

by Levaditi's method but no spirochaetes were found. The mother was an unmarried secundipara, aged 27 years, and her pregnancy was without incident. There was a transverse presentation which was converted to a footling with some difficulty. The child, which was delivered spontaneously, was dead. The labour lasted twenty-four hours and the membranes had ruptured early. In her first pregnancy the mother had borne a live mature child. She herself appeared healthy and her blood, like that of the infant, gave a negative Wassermann reaction.

In Case No.214 the child was a well developed, mature male, showing cyanosis of the body surface generally. There was some congestion of the meningeal veins and capillaries but no intracranial haemorrhage was noted and the tentorium was intact. In the heart there was great distension of the right auricle and ventricle. The coronary veins and capillaries were deeply congested and a few small subepicardial petachiae were present. The lungs were fairly well expanded throughout, with a few small unexpanded areas here and there. The liver as a whole showed no marked congestion, but there was a subcapsular haemorrhage about an inch in diameter on the surface of the posterior part of the right lobs. There was nothing worthy of note in any of the other organs. The liver and spleen were not enlarged and the bones appeared/

appeared healthy. Portions of lung, liver, spleen and kidney were examined by Levaditi's method but no spirochaetes were found. The mother was a secundipara, aged 24 years. For about five weeks before admission she had suffered from swelling of the feet and ankles, while later there was diminution in the amount of urine. She was admitted in eclamptic convulsions which had come on quite suddenly an hour before. Labour began a few hours later and was precipitate. The child, which presented by the breech, was born alive, spontaneously, and from the time of its birth until its death on the following day it had a continuous series of convulsions. The mother herself when admitted was found to have a marked degree of albuminuria, with oedema of the face and legs, and severe eclamptic fits were in progress. Her previous health had been good and in her first pregnancy she had borne a living child, which was, however, slightly premature and subsequently died.

In Case No.265 the child was a small premature male, sparely built and sparely nourished, and showing cyanosis of the lower extremities. The meninges were congested and oedematous and there was some haemorrhagic oedema under the tentorium. The latter was free from rupture. Beyond some congestion there was nothing worthy of note in any of the organs except the liver. On the upper surface of the right lobe of the liver, however,/

however, there was an area of subcapsular haemorrhage about an inch in diameter. The liver and spleen were not enlarged and the bones appeared healthy. Portions of lung, liver, spleen and kidney were examined by Levaditi's method but no spirochaetes were found. The mother was a multipara, aged 28 years, and this was her fifth pregnancy. Owing to an injury, she had been in bed for a fortnight before delivery. The onset of the pains was accompanied by slight accidental haemorrhage, and when she was admitted she was rather pale and looked ill. Twins were born prematurely after a labour of short duration. The child under consideration presented by the breech while the second one presented by the vertex. In her previous pregnancies the mother had borne four living, mature children, and her obstetrical history was without incident worthy of note.

In Case No.330 the child was a well developed but emaciated, mature male, which had lived for nine days. There was congestion of the meningeal veins and capillaries but no gross haemorrhage. The brain was oedematous and there was also some haemorrhagic oedema of the meninges. The heart showed engorgement of the right auricle and moderate congestion of the coronary veins and capillaries. There was also one subendocardial haematoma on the tricuspid. The lungs were, on the whole, well expanded, and in places emphysematous. The greater part of the left lower lobe was/

was occupied by a massive bronchopneumonic consolidation and there were similar areas in the lower part of the left upper lobe and in the right lower lobe. The liver showed well marked post-mortem change throughout and two areas of subcapsular haemorrhage which were not of recent origin. One, about an inch and a quarter in diameter, was situated in the right lobe, while the other and slightly smaller one, was situated posteriorly on the left lobe. The kidneys showed uratic deposits at the tips of the pyramids and some cloudy swelling generally. The suprarenals were soft, the thyroid deeply congested, and the thymus was abnormally small. Apart from these features, there was nothing worthy of note to be seen. The liver and spleen were not enlarged and the bones appeared healthy. Portions of lung, liver, spleen and kidney were examined by Levaditi's method but no spirochaetes were found. The mother was a primipara, aged 22 years. She had suffered from anorexia and sickness throughout her pregnancy, and, when admitted, had been in labour for about twelve hours. A considerable degree of pelvic contraction was present and the membranes had ruptured early. Forceps were applied to the presenting head and the child was delivered alive nearly thirty-four hours after the onset of labour. During the puerperium the mother developed delirium and jaundice and was acutely ill. She was thought to be suffering/

suffering from acute yellow atrophy, but in the course of a week or so her condition improved and recovery was complete before she was dismissed. During the acute stage of the illness the urine was carefully examined for leucin and tyrosin (by Huppert's method) but with negative result. The child lived for about nine days.

In Case No.492 the child was a well developed, mature male. There was slight congestion of the meningeal veins and capillaries and the meninges were oedematous but there was no intracranial haemorrhage. The right auricle and ventricle were engorged with blood and there was moderate congestion of the coronary veins and capillaries. Several subepicardial petechial haemorrhages were present and there were two haematomas on the tricuspid. The lungs were well expanded throughout and showed oedema and congestion. In the left lung, about the middle of the upper lobes there was an area, which, on palpation, felt cystic. On cutting into the lung at this point there was found to be a wedge-shaped area of haemorrhage, hollow in the centre and filled with grumous semi-fluid material. The apex of this wedge was situated near the root of the lobe, while its base reached the surface and was about ten millimetres in diameter. In the right lung there was a small haemorrhagic area on the periphery of the lower part of the lower lobe and one or two smaller areas were present also in the interlobular surface of the lower/

lower lobe. The liver showed marked congestion and there was a small subcapsular haemorrhage at the extreme right edge of its inferior surface. The kidneys were both deeply congested and in the left one there was extensive haemorrhage under the capsule. There was no thrombosis of the renal vein. A small amount of haemorrhage was present in both kidneys in and around the pelvis. The right kidney was not quite so deeply congested as the left and showed no subcapsular haemorrhage. Both suprarenals also showed marked congestion, and though there was only slight oozing into the medulla of the right, the left one showed well marked haemorrhage into the medulla, the whole gland being distended with blood. There was nothing worthy of note beyond congestion in any of the other organs except the thymus, which showed two small petechiae under its capsule. The liver and spleen were not enlarged and the bones appeared healthy. Portions of lung, liver, spleen and kidney were examined by Levaditi's method but no spirochaetes were found. The mother was a primipara, aged 21 years, who had apparently been suffering from cystitis, and possibly pyelitis, during her pregnancy. She was admitted on account of an impacted breech with both arms displaced. The membranes ruptured early and the child was delivered spontaneously about fifteen hours after the onset of labour. It was pale, but the heart was beating and

continued/

continued to do so for about forty-five minutes. All attempts to start respiration failed. Except for the presence of slight oedema and fairly well marked albuminuria, the mother appeared healthy.

In Case No.500 the child was a poorly developed, premature male, which showed haemorrhagic oedema of the scalp and oedema and congestion of the brain and meninges. There was no gross intracranial haemorrhage. The heart showed congestion of the coronary veins and capillaries with several subepicardial petechial haemorrhages. Both lungs were wholly unexpanded and congested and there were a few subpleural petechiae. The liver was soft and greatly congested and there was an area of subcapsular haemorrhage in the anterior surface of its right lobe. Both kidneys also showed marked congestion with a small amount of haemorrhage round the pelvis of each. There was congestion and oedema of the organs generally but nothing else worthy of note. The liver and spleen were not enlarged and the bones appeared healthy. Portions of lung, liver, spleen, and kidney were examined by Levaditi's method but no spirochaetes were found. The mother was a multipara, aged 43 years, and this was her ninth pregnancy. She was well until the onset of bleeding from a marginal placenta praevia the day before admission. When first seen labour had been in progress for the best part of a day, the breech presented and the/

the child was dead. The membranes were ruptured artificially, a foot was brought down, and spontaneous delivery occurred shortly afterwards. In her previous pregnancies the mother had borne six mature living children and there had been two early abortions.

Haemorrhage into the Lungs.

There were 8 cases of haemorrhage into the lungs, two of which (Nos.241 and 492) have already been described.

In Case No.81 the child was a well developed mature male, showing lividity of the head, left arm and legs. There was moderate congestion of the meningeal veins and capillaries but no gross intracranial haemorrhage was present. In the heart there was congestion of the coronary veins and capillaries and a few small subepicardial petechiae were present. The lungs were for the most part completely airless though one or two partially expanded areas of small size were noted. Scattered throughout both lungs there were a number of small haemorrhagic areas. All the other organs showed congestion but there was nothing else worthy of note. The liver and spleen were not enlarged and the bones appeared healthy. Portions of lung, liver, spleen and kidney were examined by Levadi i's method but no spirochaetes were found. The mother was a multipara, aged 23 years, and this was her third pregnancy Nothing worthy of note occurred until after the onset of labour./

labour. When the patient was first seen the foetus was lying transversely and the pains had been in progress for some hours. There was a slight degree of pelvic contraction. After both feet had been brought down labour was allowed to go on until the os was fully dilated. The breech was then delivered under an anaesthetic. The arms were extended and one was fractured during extraction. On delivery the child was dead. The exact duration of the labour is uncertain. In her previous pregnancies the mother had borne two mature living children and both labours were normal.

In Case No.192 the child was a well developed mature male, showing cyanosis of the head and face. There was generalised congestion of the meningeal veins and capillaries but no haemorrhage was present. The cranial bones were exceptionally well ossified. In the heart there was well marked congestion of the coronary veins and capillaries and the right auricle and ventricles were distended and engorged with blood. A few subepicardial petechial haemorrhages were present. The lungs were wholly unexpanded and deeply congested throughout and there were numerous small areas of haemorrhage both under the pleura and into the substance of the lung tissue. The liver showed very marked congestion but there was no separation of the capsule. There were two or three minute petechiae under the capsule of the thymus but no other haemorrhages/

haemorrhages were noted, though all the organs showed congestion, in some cases of a marked degree. The liver was not enlarged but the spleen was slightly heavier than usual. The bones appeared healthy. Portions of lung, liver, spleen and kidney were examined by Levaditi's method but no spirochaetes were found. The mother was an unmarried primipara, aged 29 years, and her pregnancy was uneventful. There was a marked degree of pelvic contraction and when the patient was first seen irregular labour pains had been going on for over three days. The vertex presented and there was marked overlapping at the brim. The child was then alive, but, when it was delivered some hours later by caesarean section, it was dead. For about twelve hours before delivery the pains were strong and regular, and the foetal heart was beating strongly two hours before the child was born. Shortly after that, however, meconium was passed and it was doubtful whether the foetal heart was audible at the commencement of the operation. When the child was removed from the uterus the cord was pulseless and no attempts at breathing were made in spite of artificial respiration, hot and cold douching, and so forth. It was noted that the placenta had not separated when the uterus was opened.

In Case No.630 the child was a well developed mature female, showing well marked headmoulding and oedema of the scalp. The meningeal veins and capillaries were congested/

congested but there was no intracranial haemorrhage. The heart showed engorgement of the right auricle and ventricle and congestion of the coronary veins and capillaries but there were no subepicardial petechiae. Except for a few pin-point areas of partial expansion the lungs were completely airless. They showed generalised congestion, and a few small areas of haemorrhage in the substance of the right lower lobe. The liver was deeply congested but there was no separation of its capsule. The only other haemorrhage noted was a small one in the upper part of the medulla of the left suprarenal. All the organs showed marked congestion, however. The liver and spleen were not enlarged but the epiphyseal line at the lower end of the femur was slightly irregular and showed a suggestion of a yellow zone. Portions of lung, liver, spleen and kidney were examined by Levaditi's method but no spirochaetes were found. The mother was a secundipara, aged 21 years. Her pregnancy was uneventful and the labour was normal though of considerable duration (about two days). The membranes ruptured nearly nineteen hours before delivery. The child was delivered spontaneously and was still-born though the heart had been beating a short time beforehand. The mother was a healthy looking woman with no pelvic contraction or other deformity, but she suffered from premenstrual pain and her only previous pregnancy - six years before - had ended in abortion during the fourth month.

In Case No.610 the child was a premature male, showing slight superficial maceration of the legs and there was haemorrhage under the pericranium over both parietal bones and over the occipital and frontal bones. There was also some haemorrhage into and under the scalp forming an exaggerated caput to the right of the vertex. There was nothing worthy of note in the brain or meninges or in the heart. The lungs were wholly unexpanded, rather pale generally, and covered with numerous subpleural ecchymoses. The liver showed slight congestion only. There was nothing worthy of note beyond post-mortem change in the other organs. The liver and spleen were not enlarged and the bones appeared normal. Portions of lung, liver, spleen and kidney were examined by Levaditi's method but no spirochaetes were found. The kidney showed considerable post-mortem degeneration of the parenchyma and a moderate degree of congestion. There was no fibrosis. The mother was a multipara, aged 28 years, and this was her seventh pregnancy. Some time before she had suffered from pneumonia and influenza but throughout the pregnancy itself her health was good. On the day before admission there was bleeding from a marginal placenta praevia and this continued for some hours. After admission the membranes were ruptured artificially, the vagina was packed and premature still-born twins were delivered spontaneously about eighteen hours after the onset of labour. In her previous pregnancies the mother had borne six mature living children.

In Case No.708 the child was a well developed mature male, showing a small abrasion under the left eye. There was congestion of the meningeal veins and capillaries and the meninges were oedematous. There was no gross intracranial haemorrhage, however. The right auricle of the heart was engorged with blood but otherwise the organ showed nothing worthy of note. Both lungs were well expanded and there were no haemorrhages. The kidneys showed pallor of the cortex, some cloudy swelling, and uratic deposits at the tips of the pyramids. There was a congested area at the upper pole of the left one. The left suprarenal was large in size and dark-red in colour, and there were about two and a half drams of blood free in its interior. The other suprarenal showed slight congestion only. There was nothing worthy of note in any of the other organs except that the spleen was larger than normally. There was no enlargement of the liver and the epiphyseal line at the lower end of the femur was regular and showed only the slightest suggestion of a yellow zone. Portions of lung, liver, spleen and kidney were examined by Levaditi's method but no spirochaetes were found. The mother was a multipara, aged 39 years, and this was her tenth pregnancy. She was admitted to the Ante-natal Department on account of hydramnios, oedema of the legs and albuminuria. The labour was long and the child was born alive. At birth it weighed 10 lbs.

but /

but at the time of its death, seven days later, it weighed only 8 lbs. 6 ozs.. In her previous pregnancies the mother had borne six full-time children (three living and three dead) and there had been three early abortions.

In Case No.480 the child was a fairly well developed and well nourished premature male, which showed bruising of the right lower extremity. There was nothing worthy of note in the head beyond oedema of the meninges. The heart showed two or three subepicardial petechiae in the neighbourhood of the A-V ring but appeared otherwise normal, and the lungs were almost completely unexpanded and showed several minute subpleural ecchymoses. The liver and spleen showed no marked congestion and no enlargement and the bones appeared healthy. All the other organs except the suprarenals showed slight congestion. In the medulla of each suprarenal, however, there was a small amount of haemorrhage. Portions of lung, liver, spleen and kidney were examined by Levaditi's method but no spirochaetes were found. The mother was a multipara, aged 29 years, and this was her fourth pregnancy. There was threatened abortion at the sixth week but the pregnancy continued though there was slight bleeding at intervals till about the end of the fourth month. When the patient was admitted she was about seven months pregnant and there had been haemorrhage from a marginal placenta praevia for seven hours. The child/

child was alive and presented by the vertex. Version was performed and the child was born dead, spontaneously, about forty-eight hours after the onset of labour. The mother was apparently a healthy woman though she had suffered from menorrhagia for about ten years and she had been curetted repeatedly. A ventro-fixation operation had also been performed. Her first and second pregnancies and labours were normal but the third labour was a lengthy one and was a forceps delivery. All the children were born alive at term.

NEGATIVE GROUP.

Group 11.

This group consists of twenty-three cases in which no haemorrhage of any kind was found. Four of the infants were still-born, and the remaining nineteen infants were born alive and survived for varying periods.

Of the four cases of still-birth three were associated with Contracted Pelvis.

In Case No. 275 the child was a well developed and well nourished mature male which showed marked head-moulding with elongation towards the vertex. There was nothing worthy of note, however, within the cranium. Congestion was not marked. There was no haemorrhage and the tentorium was intact. In the heart there was slight engorgement of the right auricle but no marked coronary congestion. In the lungs there was fairly complete aeration of considerable areas of all the lobes, but expansion was nowhere complete. There was nothing worthy of note in any of the other organs beyond congestion of the thyroid and thymus. The liver and spleen were not enlarged and the bones appeared healthy. Portions of lung, liver, spleen and kidney were examined by Levaditi's method but no spirochaetes were found. The mother was a married primipara, aged 23 years, who had considerable degree of pelvic contraction. During the early months of pregnancy there was a great deal of sickness, but after that had

ceased her health was good. Labour pains began two days before admission but passed off. The following day, however, they commenced once more and continued until delivery. On admission the child was alive and presented by the vertex. The membranes were stated to have ruptured painlessly three days before. Forceps were applied and the child was delivered dead. It had been alive shortly before the application of forceps. The mother's previous health had been good and, apart from pelvic contraction, she showed no abnormality.

In Case No. 645 the child was a large and well developed mature male. The head had been crushed and the brain destroyed and there was generalised pallor of the organs and tissues. The heart showed absence of engorgement except in the auricular appendages, and there were no subepicardial petechiae. The lungs were quite airless except for a few pin-point areas of partial expansion at the margin. There was nothing worthy of note in the other organs beyond pallor. The liver and spleen were not enlarged and the bones, which were exceptionally well ossified, appeared healthy. Portions of lung, liver, spleen and kidney were examined by Levaditi's method but no spirochaetes were found. The mother was a small rickety woman, aged 26 years, and this was her third pregnancy. A few months before it began there had been a uterine haemorrhage, the nature of which is unknown, and throughout the pregnancy she suffered from pain

in the back and legs. She was admitted some hours after the onset of labour with the os partly dilated. The child was alive and presented by the vertex but there was considerable pelvic contraction and slight overlap and the head remained movable above the brim. Craniotomy was performed and the child was delivered. In her previous pregnancies the mother had borne two mature children, the first dead, the second alive.

In Case No. 954 the child was a well developed, well nourished mature female, which had been delivered after craniotomy. There was marked pallor and depletion of all the organs and tissues, but nothing else worthy of note was found. The liver and spleen were not enlarged and the bones appeared healthy. Portions of lung, liver, spleen and kidney were examined by Levaditi's method but no spirochaetes were found. The mother was a small rickety woman, aged 32 years, and this was her third pregnancy. There was nothing unusual to record until the onset of labour. There was a marked degree of pelvic contraction, and before admission forceps had been applied unsuccessfully. When examined, the os was found to be only half dilated but was easily dilatable. The head was not fixed at the brim and the overlap was very marked. The foetal heart was very irregular and no foetal movements were noted. The membranes had ruptured prematurely.

About ten hours after the onset of labour craniotomy was performed and the child delivered. In her previous pregnancies the mother had borne one mature living child spontaneously (a small child) and there had been one delivered at term after craniotomy.

Of the one remaining case of still-birth in this group, Case No. 946 was a poorly developed, premature female with a meningo-myolocoele and various deformities. There was congestion of the meningeal veins and capillaries but no intracranial haemorrhage. There was nothing worthy of note in any of the organs beyond slight congestion. The liver and spleen were not enlarged and the bones appeared healthy. Portions of lung, liver, spleen and kidney were examined by Levaditi's method but no spirochaetes were found. The mother was a healthy looking woman, aged 26 years, and this was her sixth pregnancy. Just before it commenced she had a three months' abortion, and throughout she suffered from constipation and right-sided abdominal pain. Eight hours before admission a painless labour began. The foetus presented transversely and when admitted an arm had prolapsed. After version to a footling the foetus was expelled spontaneously about ten hours after the onset of labour. In her previous pregnancies the mother had borne four full-time living children and there had been one abortion. Although she herself appeared healthy there was a history of tuberculosis in both her own and her husband's family.

Of the nineteen cases in which the child was born alive and in which no haemorrhage was found -

13 died of Bronchopneumonia (9 showing lesions in the kidneys).
3 showed lesions in the kidneys not associated with Bronchopneumonia.
1 died of purulent meningitis.

1 was a monster.

1 was a very premature child which showed congenital atelectasis.

The Thirteen Cases of Bronchopneumonia.

In nine of these Bronchopneumonia was associated with lesions in the kidneys.

In Case No. 473 there had been threatened abortion but the pregnancy went on till term and the child was born alive before admission. The labour was normal except for the occurrence of retained placenta and some post-partum haemorrhage. On the fifteenth day the child died and there was found at post-mortem examination an early bronchopneumonia associated with oedema of the meninges and cloudy swelling in the kidneys. Portions of lung, liver, spleen and kidney wereexamined by Levaditi's method but no spirochaetes were found. The lung showed considerable congestion throughout. There were considerable areas of fairly complete expansion, but here and there patches were present which showed evidence of catarrhal change and early consolidation. There was no fibrosis. In the kidney there was well marked degeneration of the epithelium, chiefly in the convoluted tubules,

hyaline material was present in some of the straight tubules and there was marked congestion of the tissue with deposition of brownish pigment between cells. The interstitial fibrous tissue was prominent. The mother's blood gave a negative W.R. but the child's blood was not examined. This was the thirteenth pregnancy and all the previous ones had been normal except that the fourth and fifth children had been delivered with the mother anaesthetised.

In Case No. 461 the mother had chronic nephritis. The labour was normal and the child was mature. About the eighth day the infant became ill and death occurred on the eighteenth day. There was found a massive bronchopneumonic consolidation in the left lower lobe and a less extensive area of consolidation in the left upper lobe. Portions of lung, liver, spleen and kidney were examined by Levaditi's method but no spirochaetes were found. The W.R. in both the maternal and the placental blood was negative. This was the eighth pregnancy, and in all except one a live mature child had been born. In the seventh pregnancy, over a year previously, a premature child was born dead at the seventh month.

In Case No. 502 a premature labour followed a fall with bruising of the abdomen and vulva. The child was born alive (about the seventh month) and survived till the fifteenth day. There were large haemorrhagic looking

areas of bronchopneumonic consolidation in both lungs. Portions of lung, liver, spleen and kidney were examined by Levaditi's method but no spirochaetes were found. This was the third pregnancy, the first child was born alive at term but the second pregnancy ended (like the third) in premature labour following a fall - the child being born alive. The maternal blood gave a negative W.R. while the placental blood was not examined.

In Case No. 578 the labour was normal and the child was born alive at term. It died on the thirteenth day. There were bronchopneumonic consolidations in both lungs, the meninges were oedematous and the kidneys showed cloudy swelling. An acute generalised peritonitis was also present. Portions of lung, liver, spleen and kidney were examined by Levaditi's method but no spirochaetes were found. This was the first pregnancy. The mother appeared healthy and the W.R. was negative in both mother and child.

No. 585 was a case of generally contracted pelvis and the child was delivered at term by Caesarean Section. The mother's puerperium was febrile. The child died on the tenth day and there was found a widespread broncho-pneumonia. The kidneys were large and pale but were otherwise normal in appearance. Portions of lung, liver, spleen and kidney were examined by Levaditi's method but no spirochaetes were found. This was the first pregnancy,

the mother appeared healthy and her blood gave a negative W.R. The child's blood was not examined.

No. 649 was another case in which the child was delivered at term by Caesarean Section (the pelvis being contracted). The child was fairly well developed - weighing 6 lbs. at birth - but it did not thrive. The feet and legs were very oedematous at first and though this improved later on the child's general condition grew steadily worse and it died on the nineteenth day. Widespread bronchopneumonic consolidation was present in both lungs. Portions of lung, liver, spleen and kidney were examined by Levaditi's method but no spirochaetes were found. This was the second pregnancy and in the first the child had been delivered dead with forceps. The mother's blood gave a negative W.R. but the child's was not examined.

No. 659 was a premature twin child (born about the eighth lunar month) which died on the third day. The labour had been normal and the delivery spontaneous. At post-mortem the child showed bronchopneumonic consolidation in both lungs, and cloudy swelling was present in the kidneys. Portions of lung, liver, spleen and kidney were examined by Levaditi's method but no spirochaetes were found. The mother was a primipara, and both her blood and that of the child gave a negative W.R.

No. 711 was a case of severe toxaemia with marked albuminuria, in which labour was induced shortly before term. Delivery was spontaneous and the child lived till the eighth day. There was extensive bronchopneumonic consolidation in both lungs, the meninges were oedematous and there was an acute non-purulent peritonitis. Portions of lung, liver, spleen and kidney were examined by Levaditi's method but no spirochaetes were found. This was the fourth pregnancy. There had been eclampsia during the first pregnancy but the second and third pregnancies were normal. The W.R. of both mother and child was negative.

No. 748 was a case in which slightly premature twins were born spontaneously. The first child died on the ninth day, with numerous and extensive areas of bronchopneumonic consolidation in both lungs, extreme cloudy swelling in the kidneys and an early meningitis at the base. The mother had cystitis and possibly nephritis four years previously. Portions of lung, liver, spleen and kidney were examined by Levaditi's method but no spirochaetes were found. This was the eighth pregnancy and in all the others the children had been born alive. The blood of both mother and child gave a negative W.R.

The second twin - which died on the sixth day - also showed extensive areas of bronchopneumonia. There was oedema of the meninges and the kidneys showed cloudy swelling.

Case No. 763 was a mature child born spontaneously after the induction of labour on account of maternal albuminuria and oedema. The child died on the tenth day and at post-mortem examination there were found numerous areas of bronchopneumonic consolidation in the lungs and marked cloudy swelling in the kidneys. Portions of lung, liver, spleen and kidney were examined by Levaditi's method but no spirochaetes were found. This was the first pregnancy and the mother's blood gave a negative W.R. The placental blood was not examined.

Case No. 801 was a mature child delivered by caesarean section on account of contracted pelvis. The child died on the twenty-sixth day and showed early bronchopneumonic consolidation of the lower lobes of both lungs, oedema of the meninges, cloudy swelling in the kidneys and a non-ulcerative enteritis. Portions of lung, liver, spleen and kidney were examined by Levaditi's method but no spirochaetes were found. This was the third pregnancy. The mother's blood gave a negative W.R. but the child's blood was not examined.

Case No. 888 was a slightly premature child which was blue at birth and did not thrive. It died on the third day and the poorly expanded lungs showed commencing bronchopneumonia at the bases. Portions of lung, liver, spleen and kidney were examined by Levaditi's method but no spirochaetes were found. The labour was normal but the mother, who was a primipara, had suffered from pains

in the back during her pregnancy and had been subject to epileptic fits for about four years. The blood of both mother and child gave a negative W.R.

Of the six remaining children in this group which were born alive, three showed lesions in the kidneys not associated with bronchopneumonia.

Case No. 144 was an eighth month child which was born before admission. There was a placenta praevia and the cervix was torn. The child died on the seventh day. At post-mortem there was found well marked generalised oedema and there was considerable congestion of organs and post-mortem softening. The kidneys were almost diffluent. Portions of lung, liver, spleen and kidney were examined by Levaditi's method but no spirochaetes were found. This was the mother's fifth pregnancy but no details of the previous ones were available. Her blood gave a negative W.R. while the child's blood was not examined.

Case No. 460 was a slightly premature twin, the child of an albuminuric mother. There was also pelvic contraction but delivery was spontaneous. The other twin is described among the group of macerated cases. This child died on the first day and showed well marked generalised oedema and pallor of the renal cortex. Portions of lung, liver, spleen and kidney were examined

by Levaditi's method but no spirochaetes were found. This was the mother's second pregnancy and she had suffered from oedema during the last four months before delivery. After the birth of the children there was retention of the chorion, and the placenta was of a greenish-yellow colour. It was not preserved for detailed examination, however. During the first pregnancy there had been threatened eclampsia but the child was born alive. The mother's blood gave a negative W.R. but the child's was not examined.

Case No. 583 was a mature child delivered by caesarean section on account of contracted pelvis. The child died on the eleventh day and at post-mortem there was found a well marked parenchymatous nephritis. Portions of lung, liver, spleen and kidney were examined by Levaditi's method but no spirochaetes were found. The mother, who was a primipara, had marked albuminuria and pyelitis during her pregnancy. The mother's blood gave a negative W.R. but the child's was not examined.

Case No. 826 was a mature twin which died on the eighth day and showed at post-mortem a widespread purulent meningitis. The labour had been a protracted one owing to a cicatrized cervix. After incision of the cervix the first twin was delivered dead spontaneously. It weighed only 4½ lbs. The second twin, weighing 8 lbs., was delivered with forceps and survived till the eighth

day. In addition to purulent meningitis there was oedema and congestion of the lungs with evidence of some bronchitis. No actual bronchopneumonic consolidation was noted, however. Portions of lung, liver, spleen and kidney were examined by Levaditi's method but no spirochaetes were found. The mother's three previous pregnancies had all been normal and had ended in the birth of living children. Her blood gave a negative W.R. but the placental blood was not examined.

Case No. 785 was a monster with absence of the parietals and the greater part of the frontal bones. This was associated with incomplete development of the brain and of the suprarenals. This child lived for a few hours only. Portions of lung, liver, spleen and kidney were examined by Levaditi's method but no spirochaetes were found. The mother was well throughout the pregnancy. Some time after the onset of labour forceps were applied but delivery was not effected, and after admission to the wards she delivered herself spontaneously. This was her second pregnancy and the first child had been born alive five years before the second one. Between the two pregnancies the mother suffered from endometritis. Both mother and child gave a negative W.R. in the blood.

The last case in the group (No. 272) was one in which a very premature child was born spontaneously. At an earlier stage in the pregnancy there had been threatened

abortion but the pregnancy went on till well into the seventh month. Delivery was spontaneous and the child lived till the fifth day. At post-mortem there was found congestion of all the organs and very incomplete expansion of the lungs. Portions of lung, liver, spleen and kidney were examined by Levaditi's method but no spirochaetes were found. This was the mother's twelfth pregnancy and the threatened abortion was secondary to an injury two days before. There had been eight normal full-time live births and three early abortions. The mother's blood gave a negative W.R. but the child's was not examined.

MACERATED FOETUSES.

A. POSITIVE GROUP.

There were nine macerated foetuses in this group of forty cases.

One (Case No. 152) was a seventh month foetus in which there was advanced maceration. The W.R. was strongly positive in both mother and child. The pregnancy was normal so far as is known, and the labour was uneventful except that the membranes were ragged. This was the first pregnancy. The viscera of the child were badly macerated, and the liver and spleen were enlarged definitely. At the epiphyses of the bones there was maceration, but the picture was not particularly distinctive of syphilis. Spirochaeta pallida were found in small numbers in the lung, but could not be demonstrated by Levaditi's method in liver, spleen or kidney (all of which were in a more advanced stage of maceration than the lung). Sections of the lung showed widespread desquamation of the alveolar epithelium and infiltration of the tissues with mononuclear and epithelioid cells, with increase in the peri-arterial connective tissue, and in places a definite endarteritis was noted.

The second macerated foetus in this group (Case No. 935) was born prematurely at the eighth month. The labour was protracted, and no life had been felt for over a week

before delivery. There was a history of " strain from carrying a weight" one week before admission, and irregular pains were present from the time of this accident till the child was born. This was the mother's first pregnancy and she had felt well till the accident referred to. She gave a history of having had rheumatic fever seven years before. The foetus showed advanced maceration in all the organs, but the liver and spleen were not enlarged. Histological examination showed marked maceration of the organs, but no spirochaetes could be found in the portions of lung, liver, spleen and kidney examined by Levaditi's method.

The next case (P.M. No. 644) was a premature male child showing advanced maceration of all the organs and tissues. The abdomen was prominent and contained a quantity of haemorrhagic fluid, the liver and spleen were enlarged, and the epiphyseal line at the lower end of the femur showed marked changes. There was irregularity of the line with a distinct whitish yellow zone at the junction of cartilage and bone, and in the cartilage a deep band of congestion was present. A moderate number of spirochaetes were found in portions of the lung, liver, spleen and kidney examined by Levaditi's method. The mother was a married woman, aged 23 years, who had previously borne three healthy children. She was apparently well during her fourth pregnancy, and the labour though premature was normal. Her blood gave a strongly positive

Wassermann reaction.

In another case (P.M. 539) the child was a premature male showing advanced maceration. A considerable degree of hydrocephalus was present. There was no enlargement of liver and spleen and the bones showed only the changes due to maceration. Portions of the lung, liver, spleen and kidney were examined by Levaditi's method but no spirochaetes were found. The mother was a married primipara, aged 22 years. She stated that she had noticed a bad taste in her mouth for several weeks before admission, but that otherwise she had felt well during her pregnancy. She also noticed foetal movements up till ten days before delivery. Her blood like that from the cord gave a strongly positive Wassermann reaction.

In P.M. No. 223 the foetus was a premature female and the degree of maceration was moderate. The liver and spleen were enlarged, and the former showed numerous white areas of pin-head size scattered over its surface. There was a good deal of congestion of the organs as well as maceration, and numerous subpleural petechial haemorrhages were present. The changes in the epiphyseal line at the lower end of the humerus were suggestive of syphilis though the appearances were somewhat obscured by maceration. Portions of the lung, liver, spleen and kidney were examined by Levaditi's method and were found to contain large numbers of the spirochaeta pallida. No gummata could be found in the liver. The mother was

28 years of age, and this was her second pregnancy. During it she had been in fair health only, and for two months before delivery she had suffered from bronchitis. The labour was normal and lasted about twenty-five hours. The previous pregnancy had also ended in the birth of a dead premature child. The mother's blood gave a strongly positive Wassermann reaction.

In P.M. No. 91 the child was a male showing a moderate degree of maceration. The liver showed large numbers of small white areas of pin-head size all over its surface, and both it and the spleen were enlarged. The placenta showed extreme generalised fibrosis and fatty degeneration. The lower epiphysis of the femur showed changes fairly characteristic of syphilis. Spirochaeta pallida was present in large numbers in the portions of lung, liver, spleen and kidney examined by Levaditi's method. The liver tissue was macerated but it showed numerous minute clearer areas scattered throughout. These consisted of structureless material filled with round cells and a few polymorphs. The mother was a married woman aged 30 and this was her third pregnancy. Both the previous pregnancies had ended in the birth of a live child, but, while the first was mature, the second was premature. During the third pregnancy she suffered from bronchitis and hydramnios. Very marked increase in the size of the abdomen occurred during the last fortnight before delivery.

In P.M. 807 the child was a premature male, fairly well developed, but showing slight to moderate maceration of the various organs. The liver and spleen were enlarged and the epiphyseal line at the lower end of the femur was irregular and showed a broad white zone and a band of congestion in the cartilage. Spirochaeta pallida was present in large numbers in the portions of lung, liver, spleen and kidney examined by Levaditi's method. The mother had previously borne one child and this was the second pregnancy. She was a married woman, aged 22 years, and her pregnancy appears to have been uneventful - the child having been born before the mother was admitted. Her blood gave a positive W.R.

In P.M. No. 835 there was a premature female foetus showing a fair standard of development and nutrition, but with a moderate degree of maceration of all the organs and tissues. The liver, and more particularly, the spleen showed distinct enlargement, but there was only slight irregularity at the lower epiphyseal line of the femur. Portions of the lung, liver, spleen and kidney were examined by Levaditi's method and numerous spirochaetes were found. The organs showed considerable congestion in addition to early maceration, and subpleural petechial haemorrhages were noted. The mother was a married woman, aged 27 years, and this was her second pregnancy. Nothing worthy of note occurred during it, and the child was born

before she was admitted. She was sent in on account of a retained placenta which was expelled spontaneously some time after admission. The blood of both mother and child gave a strongly positive Wassermann reaction.

In P.M. No. 94 the child was a premature male which showed a considerable degree of maceration. The liver and spleen were moderately enlarged and the lungs showed several large white necrotic areas scattered throughout and giving a firm feeling to the lung generally. Large numbers of spirochaetes were found in the lung, liver, spleen and kidney in sections prepared by Levaditi's method. The lung contained a number of necrotic areas in the midst of unexpanded lung tissue. In these areas the cells had lost their nuclei and had become partly homogeneous. Although the cell outlines and supporting fibrils were still visible and the vessels could be distinguished, the tissue generally was necrotic. The mother was a primipara, aged 21 years. The pregnancy and labour were normal and delivery was spontaneous after fourteen hours.

B. NEGATIVE GROUP.

There were fourteen macerated foetuses in this group of a hundred cases with negative W.R.

Of these two (Nos. 392 and 595) were associated with Accidental Haemorrhage occurring at term. All these foetuses showed only a slight degree of maceration.

No. 392 was still-born after a protracted labour completed by a forceps delivery. The mother had been bleeding for three days, and the child showed congestion of organs with subpleural and subepicardial petechial haemorrhages. The organs all showed early maceration. Histological examination showed no spirochaetes in lung, liver, spleen and kidney. The blood of both mother and child gave a negative W.R. This was the first pregnancy.

In No. 595 maceration was slight. The mother gave a history of having had a fright fourteen days before admission, and Ante-Partum Haemorrhage began on the morning of the day of delivery. After packing the labour was completed spontaneously, but the child was still-born. This was the first pregnancy. The mother's blood gave a negative W.R.; the child's blood was not examined. Apart from the superficial maceration and the slight region of maceration of the viscera, there were signs of marked congestion having been present. Subpericranial haemorrhage and haemorrhage into and under the scalp were found. The meninges were oedematous and congested

and the brain was partly macerated. The liver was normal in size but the spleen was slightly enlarged. The epiphyseal line at the lower end of the femur showed slight irregularity with whitish yellow spicules projecting into the cartilage, which showed slight congestion. Portions of lung, liver, spleen and kidney were examined by Levaditi's method but no spirochaetes were found.

In Case No. 460 there was a twin pregnancy which ended at the eighth month. One twin showed advanced maceration, while the other was born alive and survived its birth for a few hours. The mother's blood gave a negative W.R. The blood of the infant was not examined. She had albuminuria, and oedema had been present for the last four months of pregnancy. The pelvis was contracted but the children were born spontaneously. The membranes were deficient, however, and had to be cleared out by curettage. The puerperium was febrile, and a swab from the uterine cavity showed on examination streptococci and coliform bacilli. This was the second pregnancy, and in the first one - four years before - there had also been albuminuria, oedema, and dimness of vision - a live child being born at term. This macerated twin showed extreme maceration in all the organs. The liver and spleen were not enlarged and there were no changes suggestive of syphilis in the bones. Portions of lung, liver, spleen and kidney were examined by Levaditi's method but no spirochaetes were found.

The twin which survived birth for a few hours was nearly a pound heavier than the macerated one, and was moderately well developed and well nourished. There was well marked generalised oedema. The organs showed nothing of note beyond slight congestion and the liver and spleen were not enlarged. Portions of the lung, liver, spleen and kidney were examined by Levaditi's method but no spirochaetes were found.

In Case No. 656 premature labour commenced at 6½ months. The child, which had a talipes valgus in the left foot and a talipes varus in the right foot, and a band-like constriction round the right knee, showed advanced maceration. The mother had nausea (but no vomiting) throughout this, her second, pregnancy. She had not felt life for three months before delivery. Her uterus was enlarged to about 6½ months' size, and the pelvis was normal. The W.R. in the mother's blood was negative but the child's blood was not examined. The first pregnancy - concluded a year before - had been normal, and a live child was born at term. The foetus showed advanced maceration in all the organs. The liver and spleen were not enlarged, and there were no changes in the bones at all characteristic of syphilis. Portions of lung, liver, spleen and kidneys were examined by Levaditi's method but no spirochaetes were found.

In Case No. 550 a premature labour ended in the birth of a seven months' foetus, showing advanced maceration in all the organs and tissues. The liver and spleen were not enlarged and the bones showed no lesions apart from maceration. The mother's blood gave a negative W.R., but the infant's blood was not examined. The pregnancy, a first one, was fairly normal, though it is stated that the patient had several attacks of sore-throat and that her hair was falling out. No life had been felt for several weeks before delivery. The foetus presented by the shoulder, but the labour was otherwise normal and delivery was spontaneous. Portions of lung, liver, spleen and kidney were examined by Levaditi's method but no spirochaetes were found.

Case No. 236 was another spontaneously delivered macerated foetus which was born at term. The foetus was anencephalic and examination of the centres of ossification indicated that development had gone on to the tenth lunar month. The uterus, however, was described as being about the size of a seventh month pregnancy, and the mother had had amenorrhoea since her last pregnancy, one year before. The W.R. in the mother's blood was negative; the child's blood was not examined. This was the second pregnancy and nothing abnormal was noted except that no life was felt for three days preceding delivery. The labour was without incident. The first child was born alive at the

eighth month after a forceps delivery, and died on the seventh day. The foetus in the present pregnancy showed a marked degree of maceration in all the organs, and the epiphyseal line at the lower end of the femur was irregular, with a distinct yellowish line between the bone and the cartilage. All the centres of ossification were pale. Portions of lung, liver, spleen and kidney were examined by Levaditi's method but no spirochaetes were found.

In Case No. 915 the mature foetus showed maceration. This was the sixth pregnancy and the mother had been in bed for eight weeks before delivery owing to a cystocoele. She was fairly well otherwise but no life was felt for five days before admission. The labour was normal and delivery was spontaneous. The W.R. in the mother's blood was negative, but the child's blood was not examined. In all her pregnancies she had a good deal of sickness, but all the children except one (an abortion at seven weeks) were normal and living. The abortion mentioned occurred after the birth of the first child thirteen years before the present (6th) pregnancy. The foetus was large and well developed, but maceration was moderately advanced. There was congestion of the meninges and of most of the viscera. The liver and spleen were not enlarged, and the epiphyseal line at the lower end of the femur was regular - though it showed a distinct yellowish line between bone and cartilage, and the cartilage contained

a zone of congestion. The suprarenals were not regarded as characteristic of syphilis. Portions of lung, liver, spleen and kidneys were examined by Levaditi's method but no spirochaetes were found.

In Case No. 198 labour was induced on account of death of the foetus. No life had been felt for two months before admission to the Ante-natal Wards; and the uterus was not increasing in size. This was the thirteenth pregnancy, the mother being 41 years of age. All the previous pregnancies had been normal and there was only one still-birth. All the deliveries had been spontaneous except the twelfth which required forceps. In the present pregnancy delivery was spontaneous after induction, and a very premature macerated foetus was born, the stage of development being, apparently, about the end of the sixth month. The W.R. in the mother's blood was negative; the child's blood was not examined. All the organa and tissues showed advanced maceration, and the epiphyseal line at the lower end of the femur was irregular, and showed a distinct yellow line and a zone of congestion in the cartilage. The appearances in the bone were suggestive of syphilis, but the liver and spleen were not enlarged. Portions of lung, liver, spleen and kidney were examined by Levaditi's method but no spirochaetes were found.

In Case No. 688 unsuccessful attempts at forceps delivery had been made before admission, and when the patient reached the wards labour had been in progress for three days and the head was fixed in the pelvis. The child was dead, and was delivered by forceps in the Hospital. It was a first pregnancy, and the mother had been well throughout. On admission, however, there was acute bronchitis and laryngitis. The blood of the mother gave a negative W.R. but the child's blood was not examined. The mother died, and at post-mortem a widespread purulent metritis was found. The foetus was large and well developed, but there was advanced maceration with widespread " gasogenic" infection, the organs being filled with gas bullae and deeply congested. The liver and spleen were not enlarged, and there were no changes in the bones suggestive of syphilis. Portions of lung, liver, spleen and kidney were examined by Levaditi's method but no spirochaetes were found.

In Case No. 189 there was Ante Partum Haemorrhage from a marginal placenta praevia. Internal version was performed, and a seven months macerated foetus was delivered spontaneously. This was the third pregnancy. The first had ended in the birth of a seven months living child, and the second child - also alive - was born at term. The mother appeared healthy and her blood gave a negative W.R. The child's blood was not examined. The foetus was small and showed congestion of the organs

and a considerable degree of maceration. The liver and spleen were not enlarged, and there were no typically syphilitic changes in the bones. Portions of lung, liver, spleen and kidney were examined by Levaditi's method, but no spirochaetes were found.

In Case No. 759 the mother was an eclamptic. This was her first pregnancy, and she was sick and vomited throughout. She did not have headaches and no oedema was noticed. For years she had been subject to bilious attacks. When admitted she was in coma, and was vomiting and having convulsions - four eclamptic fits occurred shortly after she came into the wards. The patient was put on the usual eclamptic treatment employed in the Hospital and responded well. Labour began a week after admission and a premature macerated foetus (about seventh month) was born spontaneously. The mother made a good recovery. The W.R. in the mother's blood was negative. The blood of the foetus was not examined. The foetus was poorly developed and poorly nourished, and showed advanced maceration in all the organs and tissues. The liver and spleen were not enlarged and there were no changes in the bones suggestive of syphilis. Portions of lung, liver, spleen and kidney were examined by Levaditi's method, but no spirochaetes were found.

In Case No. 768 the mother was admitted to the Ante-Natal wards on account of severe vomiting and increasing weakness of less than one week's duration.

Two days after admission a slightly premature macerated foetus was born. The mother's condition improved for several days but ultimately became worse, and she began to vomit altered blood. She died eight days after delivery. At post-mortem examination no very definite cause of death was found. The lungs contained old calcareous tuberculous foci at the apices. The stomach showed no ulceration and the caceum and large bowel were loaded with impacted faeces. This was the patient's second pregnancy. Her first, two years before, had ended in the birth of a still-born mature child after a forceps delivery. The mother's blood gave a negative Wassermann reaction. The child's blood was not examined. The foetus showed congestion of all the organs and advanced maceration of all the organs and tissues except the thyroid and thymus, which for some reason were only slightly macerated. The kidneys on the other hand were almost diffluent. The liver and spleen were not enlarged but the bones showed changes rather suggestive of syphilis. Portions of lung, liver, spleen and kidney were examined by Levaditi's method but no spirochaetes were found.

The twin foetuses in Case No. 165 were both macerated but were both born alive, and lived till the second day. The mother was a primipara and had a slightly contracted pelvis and hydrammios. Both children were born spontaneously after a normal labour. They were alive, but were feeble and poorly developed. The W.R. in the mother's

blood was negative (though there was a trace of inhibition in the tube containing 3 m.h.d. of complement) and the placental blood of the children gave a clearly negative reaction.

The first foetus, a small premature female, had a talipes of both feet. All the organs and tissues were soft and macerated. The liver and spleen were not enlarged, but the liver showed numerous minute whitish areas somewhat like gummata under the capsule all over the surface. There were uratic deposits at the tips of the renal pyramids. The bones showed changes at the epiphyseal lines very suggestive of syphilis. There was a rather irregular line, with a whitish yellow zone between the bone and the cartilage, and congestion was present in the cartilage. Portions of lung, liver, spleen and kidney were examined by Levaditi's method but no spirochaetes were found.

The second foetus, also a small premature female, showed advanced maceration throughout. The liver and spleen were not enlarged but the liver showed the same pin-point whitish areas described in the other foetus. There was rather more congestion in the organs of the second foetus than in those of the first. The bone changes were the same as described above. Portions of lung, liver, spleen and kidney were examined by Levaditi's method, but no spirochaetes were found.

TABULATED DATA

REGARDING POST-MORTEM EXAMINATIONS.

In the following tables:-

Column 1 indicates the Case Number in the "1000" series.

" 2 indicates the number of the case in the post-mortem records.

" 3 indicates the presence or absence of spirochaeta pallida in the tissues examined by Levaditi's method.

" 4 indicates the Wassermann reaction in the blood of the mother.

" 5 indicates the Wassermann reaction in the placental blood.

" 6 indicates the weight ratio factor of the liver.

" 7 indicates the weight ratio factor of the spleen.

" 8 indicates the weight ratio factor of the placenta.

" 9 indicates the presence or absence of bone lesions.

" 10 indicates the group and sub-group in the classification of cases to which the case belonged.

N.B. In columns 6, 7 and 8 the following signs are used:-

Livers with factor over 24 are classed as light (" - ").

Livers with factor under 16 are classed as heavy (" + ").

Livers with factor between 16 and 24 are classed as normal (" N ").

Spleens with factor over 400 are classed as light.

Spleens with factor under 200 are classed as heavy.

Spleens with factor between 200 and 400 are classed as normal.

Placentas with factor over 4.5 are classed as light.

Placentas with factor under 3 are classed as heavy.

Placentas with factor between 3.0 and 4.5 are classed as normal.

In column 9:-

The sign + indicates the presence of definite osteo-chondritis.

The sign - indicates that the epiphyseal line was normal.

The sign ± indicates that there were indefinite changes in the bone.

Case No.	P.M. No.	S.P.	Mother's W.R.	Child's W.R.	Liver.	Spleen.	Placenta.	Bone.	Group.
	119	+	?	?	+ 10	+ 102	+ 2.7	-	Pos. 1.i.
	66	+	?	?	+ 13.85	+ 159	+ 2.6	±	"
	157	+	?	?	N 18.85	N 252	- 5.9	-	"
	181	+	?	?	N 16.3	+ 86.3	+ 2.2	-	"
	297	-	+	+	N 22.3	+ 195	- 7.3	-	"
	350	-	+	?	N 23.4	N 233	N 3.67	-	"
	626	-	?	+	N 17.5	N 289	- 5.3	-	"
	694	-	?	+	N 18.6	- 423	N 3.1	-	"
	769	+	+	?	+ 9.42	+ 72	+ 1.35	+	"
	865	+	+	?	+ 11.05	+ 134	+ 2.27	+	"
	370	-	+	?	- 24.4	- 466	N 3.56	±	Pos. 1.ii.
	390	-	+	+	N 21.9	N 303	N 3.88	-	"
	471	-	+	+	N 18.9	- 510	N 3.37	-	"

Case No.	P.M. No.	S.P.	Mother's W.R.	Child's W.R.	Liver.	Spleen.	Placenta.	Bone.	Group.
	793	-	+	+	+ 12.55	+ 68.5	+ 2.07	±	Pos. 1.ii.
	251	-	+	?	N 16.1	N 217	N 4.03	-	"
	529	-	+	+	+ 6.9	+ 69.4	N 3.43	+	"
	351	-	+	+	N 18.1	N 268	N 3.59	-	Pos. 1.iii.
	343	-	+	+	N 21.7	- 440	- 6.12	-	"
	339	-	+	+	N 17.7	- 545	N 3.53	-	"
	127	+	?	?	N 16.75	N 206.5	N 3.13	-	Pos. 11.
	209	-	+	?	+ 11.95	+ 84.5	- 8.7	±	"
	361	+	+	?	+ 14.4	N 254.5	?	+	"
	386	+	?	+	N 21	N 270	N 3.94	-	"
	388	+	+	+	+ 14.7	+ 78	+ 2.53	+	"
	402	-	?	+	N 18.3	+ 179	+ 2.34	-	"
	458	-	+	-	N 18.7	N 204	N 3.31	-	"

Case No.	P.M. No.	S.P.	Mother's W.R.	Child's W.R.	Liver.	Spleen.	Placenta.	Bone.	Group.
	505	-	+	?	- 29.5	+ 137	N 3.87	+	Pos. 11.
	610	-	+	-	- 27.8	+ 176	?	-	"
	645	-	?	+	+ 15.95	N 366	- 5.27	-	"
	795	-	+	?	- 24.3	- 407	N 3.92	-	"
263	332	-	-	-	N 16.7	- 493	+ 2.06	±	Neg. 1.i.
826	414	-	-	?	+ 12.8	+ 199	+ 1.6	-	"
898	441	-	-	?	N 21.75	N 329	N 3.64	-	"
733	400	-	-	?	N 21.3	N 387	N 4.5	-	"
167	310	-	-	?	+ 15.3	N 338	- 4.76	±	"
338	342	-	-	-	N 23.4	- 432	N 3.5	-	"
896	444	-	-	-	N 21	N 347	- 5.37	-	"
133	301	-	-	-	+ 15.9	- 530	N 3.97	±	"
265	329	-	-	?	+ 15.5	- 659	+ 1.93	-	"

Case No.	P. M. No.	S.P.	Mother's W.R.	Child's W.R.	Liver.	Spleen.	Placenta.	Bone.	Group.
294	340	-	?	-	N 17.4	- 410	+ 1.63	-	Neg. l.i.
401	344	-	-	?	N 16.1	- 426	?	-	"
442	348	-	-	?	N 20.7	- 455	N 3.02	-	"
914	443	-	-	?	N 22.7	- 456	?	-	"
83	295	-	-	?	N 22.1	N 210	- 6.2	-	"
155	308	-	-	?	N 17.0	N 334	- 5.1	-	"
512	362	-	-	-	N 16.5	N 390	N 3.1	-	"
644	379	-	-	?	N 18.4	N 292	- 4.6	-	"
136	300	-	-	?	N 22.2	N 390	?	±	"
257	327	-	-	?	N 20	N 358	- 6.25	-	"
369	338	-	-	?	N 18	N 395	N 4.22	-	"
470	357	-	-	?	N 19.9	N 253	- 6	-	"
795	416	-	-	-	N 24.0	N 382	N 4.3	-	"
664	394	-	-	-	N 23.7	N 364	- 6.25	-	"

Case No.	P.M. No.	S.P.	Mother's W.R.	Child's W.R.	Liver.	Spleen.	Placenta.	Bone.	Group.
82	296	-	-	?	N 21.2	- 485	N 3.78	-	Neg. 1.i.
131	302	-	-	?	N 21	- 517	N 4.42	-	Neg. 1.ii.
204	374	-	-	?	?	?	?	?	"
659	392	-	-	-	- 29.8	- 793	N 3.36	-	"
584	369	-	-	?	N 19.2	+ 156	- 4.95	-	"
393	353	-	-	-	N 18.4	- 410	N 4.29	-	"
879	437	-	-	-	N 18.1	- 603	N 4.05	-	"
610	375	-	-	?	N 21.7	N 267	+ 2.03	-	"
675	393	-	-	?	N 19.3	N 375	- 5.63	-	"
73	337	-	-	?	N 18.7	N 364	- 5.32	-	"
681	397	-	-	?	- 24.6	- 423	N 3.81	-	"
978	450	-	-	-	N 18.6	N 274	- 5.64	-	"
336	341	-	-	-	N 20.5	N 356	- 4.58	-	"

Case No.	P.M. No.	S.P.	Mother's W.R.	Child's W.R.	Liver.	Spleen.	Placenta.	Bone.	Group.
962	445	-	-	-	N 23.6	N 325	- 6.03	-	Neg. 1.ii.
723	399	-	-	?	- 24.3	N 265	- 6.38	-	"
559	368	-	-	-	N 23.5	N 297	N 3.87	-	"
836	420	-	-	?	N 17.2	N 275	- 6.07	-	"
472	358	-	-	-	N 19.0	N 289	- 5.75	-	"
955	448	-	-	-	N 18.4	- 486	N 4.2	-	"
174	318	-	?	-	N 17.7	- 450	N 3.9	-	"
403	333	-	-	?	N 23	- 444	- 5.5	-	"
642	380	-	-	?	+ 14.5	N 288	?	-	"
81	299	-	-	?	N 22.1	N 325	- 6.6	-	Neg. 1.iii.
241	325	-	-	?	- 32	- 754	- 6	-	"
153	304	-	-	-	N 16.8	N 287	N 4.2	±	"
160	305	-	-	-	N 18.7	N 267	- 7	-	"

Case No.	P.M. No.	S.P.	Mother's W.R.	Child's W.R.	Liver.	Spleen.	Placenta.	Bone.	Group.
154	307	-	-	?	N 21.9	N 252	?	-	Neg. 1.iii.
192	320	-	-	?	N 18.5	+ 198	N 3.08	-	"
214	323	-	-	-	- 26.4	N 344	- 7	-	"
265	328	-	-	?	N 17.8	- 665	- 7.72	-	"
330	355	-	-	-	N 19.9	- 480	N 3.96	-	"
440	352	-	-	?	+ 14.3	N 344	+ 2.3	-	"
492	360	-	-	-	N 22	- 406	- 6.2	-	"
610	376	-	-	?	N 22.8	N 290	+ 2.14	-	"
630	378	-	-	-	+ 14.85	N 318	- 5.1	± ±	"
708	398	-	-	?	N 20.3	N 208	N 4.4	-	"
500	401	-	-	?	N 20.7	- 413	N 3.55	-	"
480	359	-	-	?	N 23	- 526	- 5.27	-	"
645	381	-	-	?	N 21.9	- 439	?	-	Neg. 11.

Case No.	P.M. No.	S.P.	Mother's W.R.	Child's W.R.	Liver.	Spleen.	Placenta.	Bone.	Group.
954	449	-	-	-	- 27.3	- 413	?	-	Neg. 11.
946	447	-	-	-	N 16.9	N 3820	?	-	"
461	372	-	-	-	N 21.4	N 266	?	-	"
473	366	-	-	?	- 24.7	- 423	?	-	"
502	367	-	-	-	N 18	N 364	N 3.38	-	"
578	389	-	-	-	N 21.5	N 288	+ 2.92	-	"
585	412	-	-	?	N 21.5	N 234	N 4.75	-	"
649	409	-	-	?	N 19.6	N 236	N 3.05	-	"
659	391	-	-	-	- 27.5	N 400	+ 2.4	-	"
711	405	-	-	-	N 21.7	N 230	N 4.42	-	"
763	422	-	-	?	N 21.1	N 272	+ 2.31	-	"
801	429	-	-	?	N 20.2	N 394	?	-	"
888	442	-	-	-	- 25.6	N 299	N 4.3	-	"

Case No.	P.M. No.	S.P.	Mother's W.R.	Child's W.R.	Liver.	Spleen.	Placenta.	Bone.	Group.
144	313	-	-	?	N 18.9	- 490	?	-	Neg. 11.
460	363	-	-	?	- 38.8	- 875	+ 2.12	-	"
785	408	-	-	-	- 25.6	N 245	- 5.1	-	"
272	336	-	-	?	N 16.4	N 374	N 3.08	-	"
583	424	-	-	?	N 23.4	- 433		-	"
826	423	-	-	?	+ 15.6	N 282	+ 2.33	-	"
275	331	-	-	?	N 17.5	- 466	- 4.68	-	"
748 a.	407	-	-	-	N 19.9	N 320	+ 1.87	-	"
748 b.	410	-	-	-	N 22.25	N 207	+ 1.87	-	"
152	306	+	+	+	+ 9.37	+ 47	+ 2.34	+ -	Mac. Pos.
935	446	-	+	?	- 35.6	- 695	N 4.08	± -	"
	644	+	+	+	+ 14.8	+ 114.6	N 3.73	+	"
	539	-	+	+	- 45.7	+ 174	?	± -	"

Case No.	P.M. No.	S.P.	Mother's W.R.	Child's W.R.	Liver.	Spleen.	Placenta.	Bone.	Group.
	223	+	?	?	N 18	N 213	- 8.47	+	Mac. Pos.
	91	+	?	?	N 20.3	+ 133	N 4.23	+	"
	807	+	+	?	N 19.8	+ 115	?	±	"
	835	+ .	+	+	N 16.9	+ 101.5	?	±	"
	94	+	?	?	N 18.05	+ 1.59	N 3.38	+	"
165 a.	316	-	-	-	- 25.8	N 351	- 7.75	±	Mac. Neg.
165 b.	317	-	-	-	+ 13.75	N 324	+ 1.20	±	"
189	312	-	-,	?	- 37.6	N 296	+ 2.95	±	"
198	322	-	-	?	- 54	- 1240	N 3.5	±	"
236	324	-	-	?	- 35.2	N 253	N 4.4	±	"
392	349	-	-	-	- 27. 5	N 231	- 4.82	-	Mac. Neg.
460	364	-	-	?	- 61.2	- 916	+ 1.72	-	"
550	354	-	-	-	- 43.1	- 500	- 4.75	±	"

Case No.	P.M. No.	S.P.	Mother's W.R.	Child's W.R.	Liver.	Spleen.	Placenta.	Bone.	Group.
595	373	-	-	?	N 19.1	N 205	N 4	±	Mac. Neg.
656	384	-	-	?	- 34.2	- 680	N 3.6	-	"
688	395	-	-	?	N 19.8	N 212	- 5.16	-	"
759	413	-	-	?	- 35.8	- 598	+ 1.85	-	"
768	404	-	-	?	N 19.9	- 498	N 3.53	±	"
915	440	-	-	?	- 30.8	- 517	- 6.4	±	"

SUMMARY AND DISCUSSION OF RESULTS OF POST-MORTEM EXAMINATIONS.

1. MACERATED CASES.

In comparing positive and negative cases it will be seen that in the former 23 per cent, and in the latter 14 per cent were macerated.

Of the 23 macerated cases in the negative group not one showed the presence of spirochaetes in the tissues examined. The organ weight factor of the liver, spleen and placenta showed no increase in weight in any of these organs except in one case where the spleen was just over the normal, and in four cases where the placenta was heavier than the normal.

In the 9 macerated cases in the positive group, however, spirochaetes were demonstrated in 7 (equivalent to almost 78 per cent of cases). A heavy spleen was found in six of these spirochaete positive cases and a heavy liver in two. The placental weight had not been recorded in several of the cases so that a comparison with the Wassermann negative macerated cases is not possible. With regard to the spleen, it is to be noted that of the two spirochaete negative cases in the Wassermann positive group of macerated foetuses one showed a spleen slightly over the normal weight. An abnormally heavy liver was found in only three of the Wassermann positive cases and

all three were spirochaete positive. The bone changes were too indefinite in the macerated foetuses to be of any value in diagnosis. Four of the spirochaete positive cases, however, showed a perfectly recognisable osteo-chondritis.

2. NON-MACERATED CASES.

Of the non-macerated cases 30 were Wassermann positive and 86 were Wassermann negative. Spirochaetes were searched for in portions of the lung, liver, spleen and kidney of each foetus - Levaditi's method being employed. In the Wassermann positive group spirochaetes were found in 10 but could not be demonstrated in 20. No spirochaetes were found in any of the cases in the Wassermann negative group. The examination for spirochaetes was carried out without previous knowledge as to which Wassermann group the case belonged.

3. WEIGHT RATIO OF ORGANS.

A study of the weight ratio factor for the spleen, liver and placenta shows the following points:-

+ = Organ heavier than normal.
N = Organ within normal weight limits.
- = Organ lighter than normal.

SPLEEN.

SPIROCHAETE POSITIVE.

	Macerated.		Non-macerated.		Total.	
+ =	7	(87%)	6	(30%)	13	(47%)
N =	1	(13%)	4	(20%)	5	(18%)
- =	0		10	(50%)	10	(35%)
	8		20		28	

SPIROCHAETE NEGATIVE.

+ =	1	(5.88)	10	(9.61%)	11	(9.09%)
N =	8	(47%)	59	(56.73%)	67	(55.37%)
- =	8	(47%)	35	(33.65%)	43	(35.53%)
	17		104		121	

SPLEEN.

WASSERMANN POSITIVE.

	Macerated.		Non-macerated.		Total.	
+ =	7	(77.77%)	12	(40%)	19	(48.71%)
N =	1	(11.11%)	12	(40%)	13	(33.33%)
- =	1	(11.11%)	6	(20%)	7	(17.94%)
	9		30		39	

WASSERMANN NEGATIVE.

+ =	1	(7.14%)	3	(3.61%)	4	(4.12%)
N =	3	(21.42%)	49	(59.03%)	52	(53.60%)
- =	10	(71.42%)	31	(37.34%)	41	(42.26%)
	14		83		97	

LIVER.

SPIROCHAETE POSITIVE.

+ =	2	(28.57%)	7	(63.63%)	9	(50%)
N =	5	(71.42%)	4	(36.36%)	9	(50%)
- =	0		0		0	
	7		11		18	

LIVER.

SPIROCHAETE NEGATIVE.

	Macerated.		Non-macerated.		Total.	
+ =	1	(6.25%)	8	(9.63%)	9	(9.09%)
N =	3	(18.75%)	64	(77.10%)	67	(6.76%)
- =	12	(75%)	11	(13.25%)	23	(23.23%)
	16		83		99	

WASSERMANN POSITIVE.

+ =	2	(22.22%)	10	(33.33%)	12	(30.77%)
N =	5	(55.55%)	16	(53.33%)	21	(53.84%)
- =	2	(22.22%)	4	(13.03%)	6	(15.38%)
	9		30		39	

WASSERMANN NEGATIVE.

+ =	1	(7.14%)	9	(10.84%)	10	(10.30%)
N =	3	(21.43%)	64	(77.10%)	67	(69.07%)
- =	10	(71.43%)	10	(12.04%)	20	(20.60%)
	14		83		97	

PLACENTA.

SPIROCHAETE POSITIVE.

	Macerated.		Non-macerated.		Total.	
+ =	1	(20%)	6	(66.6%)	7	(50%)
N =	3	(60%)	2	(22.2%)	5	(35.92%)
- =	1	(20%)	1	(11.1%)	2	(14.28%)
	5		9		14	

SPIROCHAETE NEGATIVE.

+ =	4	(26.66%)	16	(17.58%)	20	(18.86%)
N =	6	(40%)	41	(45.05%)	47	(44.34%)
- =	5	(33.33%)	34	(37.36%)	39	(36.79%)
	15		91		106	

WASSERMANN POSITIVE.

+ =	1	(16.66%)	8	(28.5%)	9	(26.5%)
N =	4	(66.66%)	14	(50%)	18	(52.9%)
- =	1	(16.66%)	6	(21.5%)	7	(20.6%)
	6		28		34	

WASSERMANN NEGATIVE.

+ =	4	(28.57%)	14	(20%)	18	(21.42%)
N =	5	(35.71%)	30	(42.85%)	35	(41.66%)
- =	5	(35.71%)	26	(37.14%)	31	(36.90%)
	14		70		84	

4. BONE CHANGES.

Bone changes were looked for in every case, and the following results were found with regard to the lower end of the femur:-

Examination of Lower End of Femur.

+ = Definite osteo-chondritis.
- = Bone normal.
± = Indefinite changes in bone.

	Macerated.		Non-macerated.		Total.	
SPIROCHAETE POSITIVE.						
+ =	4	(57.14%)	4	(40%)	8	(47.05%)
- =	0		5	(50%)	5	(29.41%)
± =	3	(42.85%)	1	(10%)	4	(23.62%)
	7		10		17	
SPIROCHAETE NEGATIVE.						
+ =	0		2	(1.92%)	2	(1.66%)
- =	5	(31.25%)	93	(89.42%)	98	(90%)
± =	11	(68.75)	9	(8.65%)	20	(16.66%)
	16		104		120	

4. BONE CHANGES (contd.)

	Macerated.		Non-macerated.		Total.	
WASSERMANN POSITIVE.						
+ =	4	(44.44%)	6	(20%)	10	(25.64%)
- =	0		20	(66.66%)	20	(51.28%)
± =	5	(55.55%)	4	(13.33%)	9	(23.07%)
	9		30		39	
WASSERMANN NEGATIVE.						
+ =	0		0		0	
- =	5	(35.71%)	78	(92.90%)	83	(84.69%)
± =	9	(64.28%)	6	(7.14%)	15	(15.30%)
	14		84		98	

5. VISCERAL LESIONS.

All the spirochaete positive cases and an equal number of the spirochaete negative cases were examined histologically in order to find whether any characteristic tissue changes could be found in the syphilitic group.

Definite fibrosis was found in the organs in 20 per cent of the non-macerated Wassermann Positive cases, and in 5 per cent of the non-macerated Wassermann

Negative cases examined. The inconstancy of fibrosis in definitely syphilitic infants is shown by the fact that it was present in only 50 per cent of the Spirochaete Positive cases.

The other histological change supposed to be characteristic of congenital syphilis in the New-born - the presence of masses of haemopoietic cells in the liver and other solid viscera - was similarily found to be frequently absent from definitely syphilitic cases. The degree of prematurity of the foetus is, of course, a factor which must be taken into account with regard to this histological feature. On the whole, then, it was impossible to find any histological change which was constantly present in the syphilitic foetus and absent from the non-syphilitic foetus.

DISCUSSION OF RESULTS OF POST-MORTEM EXAMINATIONS.

From consideration of the above findings in the macerated and non-macerated groups of cases the following conclusions are suggested.

1. VALUE OF THE WASSERMANN REACTION. In no case in the present series was there any evidence of syphilis in a child in a Wassermann negative group. On the other hand only about a third of the cases in the Wassermann positive group showed definite evidence of syphilis. The conclusions as to the value of the Wassermann reaction already drawn in the first part of this study appear, therefore, to be supported by the evidence obtained at autopsy.

2. VALUE OF EXAMINATION FOR SPIROCHAETES. The unreliability of all silver staining process must be recognised, but even allowing for this factor the finding of spirochaetes in over 43 per cent of all the Wassermann positive cases and in none of the Wassermann negative cases indicates that the method has some value.

3. VALUE OF ORGAN WEIGHT RATIOS. The weight factors for the various organs demonstrate the truth of the statement that, generally speaking, the spleen, and to a less extent the liver and the placenta, tend to be larger in syphilitic than in non-syphilitic infants. The

results also show, however, that such ratios are quite valueless as an aid to the diagnosis of individual cases.

4. VALUE OF BONE CHANGES. A typical syphilitic osteo-chondritis occurring in a fresh foetus is quite characteristic, but such a finding is so inconstant that its absence is of no value in excluding the possibility of syphilitic infection. In the macerated foetus the bone changes are usually so obscured by autolysis that a diagnosis cannot be made with accuracy.

5. VALUE OF MACERATION. Maceration per se is, of course, no evidence of syphilitic infection. In the present series of cases, less than 40 per cent of macerated foetuses were the children of syphilitic mothers, and not all of these foetuses showed definite evidence of syphilitic infection.

6. VALUE OF VISCERAL FIBROSIS. The presence of visceral fibrosis has been thought to be of considerable value in the diagnosis of syphilis in the new-born, and its importance is emphasised particularly in the recent work of F. J. Browne. In the present investigation, however, visceral fibrosis has been found in only 20 per cent of the non-macerated Wassermann Positive cases, while, on the other hand, it was also found in 5 per cent of the non-macerated Wassermann Negative cases examined. Even in the Spirochaete Positive group the lesion was found in only 50 per cent of cases. Its value,

then, appears to the writer to be very much less than the results of certain other observers would indicate.

In conclusion, it may be said that the results of the above series of post-mortem examinations serves to emphasise the difficulty of differentiating between the syphilitic and the non-syphilitic foetus. It is to be regretted that the number of placentae available for examination was too small to allow of any conclusions being drawn with regard to the incidence of placental changes. But even without such evidence it seems clear that the division of cases into syphilitic and non-syphilitic groups can be made only after carefully weighing the clinical, serological and post-mortem findings. In the main, the conclusions as to the value of the Wassermann reaction of the mother and of the new-born infant are borne out by the results of this series of post-mortem examinations.

PART 111.

GENERAL SUMMARY AND CONCLUSIONS.

1. Method of Investigation.

(a). With the object of investigating the incidence of Congenital Syphilis and its effect upon the ante-natal and neo-natal death-rate a combined clinical and serological study has been carried out.

(b). The Wassermann reaction was performed on over 3,500 specimens of serum from mothers and infants of the " hospital class" in Glasgow, and the reaction was found to be positive in 9.4 per cent of the mothers and 4.6 per cent of the infants at birth.

2. Incidence of Syphilis in Mothers.

(a). The question of the value of the Wassermann reaction as an indication of the incidence of syphilis is discussed, and particular reference is made to the value of the test in pregnant women. It is concluded that in the great majority of cases a positive reaction indicates the presence of syphilis - active or latent - and that the presence of a negative reaction in most instances means the absence of syphilis. It is recognised, however, that a certain small proportion of cases of syphilis do not give a positive

reaction, so that, such an investigation as the present one tends rather to under estimate than to over estimate the actual incidence of the disease.

(b) From the results of the present study it is concluded that in women of the "hospital class" in Glasgow the incidence of syphilis as estimated by the Wassermann test is between 9 and 10 per cent of cases.

3. Incidence of Syphilis in Infants.

(a) While in 1,758 infants examined at birth there was a positive Wassermann reaction in 4.6 per cent, these results are not to be taken as an indication of the incidence of syphilis in the new-born.

(b) The close agreement between the Wassermann reaction in the mother and in the child at birth, the persistence of a negative reaction in the cases where one was originally present, and the disappearance of a positive reaction in the majority of infants in whose blood such a reaction was obtained at birth, all support the view that in most cases a positive reaction in the infant's blood at birth is due to the transference of reacting substances from the maternal to the foetal blood.

(c) From the above facts, and from the clinical examination of the infants included in the present series of cases, it would appear that the incidence of congenital syphilis has been greatly exaggerated by most recent writers, and that probably less than one per cent of infants of the "hospital class" in Glasgow are syphilitic.

4. Effect of Syphilis on Incidence of Abortion, Premature Birth and Still-birth.

Syphilis is considered as a factor in the causation of abortion, premature birth and still-birth, and it is concluded from the results of the present study that, while syphilis is not a factor of predominating importance in the etiology of interruptions of pregnancy in the earlier months, the disease is one of the most important causes of still-birth and of premature birth, and that its greatest effect is seen in the production of premature still-births.

5. Effects of Syphilis on Incidence of Eclampsia and Maternal Haemorrhage.

From a study of the incidence of maternal haemorrhage and of eclampsia in the present series of cases,

no evidence could be found that syphilis has any marked influence on the production of accidental, unavoidable, or post-partum haemorrhage, or that eclampsia was any more common in syphilitic than in non-syphilitic women.

6. Relation between Syphilis in the Mother and Post-Natal Mortality in the Infant.

From a clinical and serological study of the infants in the series which survived birth, the following conclusions are drawn:-

(a) During the first fortnight of life the death-rate among the infants of syphilitic mothers was 11.76 per cent, while in the infants of non-syphilitic mothers it was 9.54 per cent.

(b) During the first month of life the death-rates were 9.60 per cent and 8.22 per cent respectively in the Wassermann positive and Wassermann negative groups.

(c) During the second and third months of life the death-rates were 3.90% in the positive and 2.45% in the negative group.

(d) From this point onwards the difference in the death-rate in the two groups become very marked, the number of deaths in the children of syphilitic mothers being particularly high

during the fourth, fifth and sixth months.

The actual figures were -

i. <u>4th, 5th & 6th month</u>

Positive 3.68%
Negative 0.80%

ii. <u>7th to 12th month (inclusive)</u>

Positive 0.84%

Negative 1.30%

iii. <u>13th to 17th month (inclusive)</u>

Positive 0.89%

Negative 1.92%

7. Post-mortem Results.

From a study of the post-mortem findings in 39 children of Wassermann positive mothers and in 100 children of Wassermann negative mothers the following conclusions are drawn:-

(a) HAEMORRHAGE. In the Wassermann positive group of non-macerated foetuses haemorrhage of greater or less degree was present in 76.9 per cent, while in the Wassermann negative group it was present in 86 per cent. In the series of cases examined, therefore, no greater tendency to birth haemorrhage was seen in the infants of syphilitic than of non-syphilitic mothers.

(b) MACERATION. 23.1 per cent of the Wassermann positive foetuses were macerated, while only 14 per cent of the Wassermann negative ones showed maceration. There was thus a greater incidence of maceration in the foetuses born of syphilitic mothers than in those born of non-syphilitic mothers in the series.

(c) SPIROCHAETA PALLIDA. Spirochaeta pallida was found in 78 per cent of the macerated foetuses in the Wassermann positive group but could not be demonstrated in any of the macerated foetuses in the Wassermann negative group. In the non-macerated foetuses spirochaetes were found in about 30 per cent of the Wassermann positive

cases but could not be detected in any of the Wassermann negative cases.

(d) **THE RATIO OF ORGAN WEIGHT TO BODY WEIGHT.** Examination of the weight factor for the liver, spleen and placenta shows that in the macerated group the spleen was enlarged in 87 per cent, the liver in 28 per cent, and the placenta in 20 per cent of the Spirochaete positive cases, and in 6 per cent, 4 per cent and 26 per cent respectively of the Spirochaete negative cases. In the non-macerated group the spleen was enlarged in 30 per cent, the liver in 63 per cent, and the placenta in 22 per cent of the Spirochaete positive cases, and in 10 per cent, 10 per cent and 17 per cent respectively of the spirochaete negative cases.

(e) **BONE CHANGES.** In the macerated group the presence of osteo-chondritis was in many cases difficult to determine owing to the degree of maceration. In the non-macerated group, however, 20 per cent of the Wassermann positive cases showed definite osteo-chondritis, while in 14 per cent the epiphyseal line showed indefinite irregularity. 40 per cent of the spirochaete positive cases showed definite osteo-chondritis, and 10 per cent showed indefinite changes in the bone. Of the Wassermann negative cases (all of which were

spirochaete negative) none showed definite osteo-chondritis though 7 per cent showed indefinite changes in the bone.

(f) VISCERAL LESIONS. Visceral fibrosis was found definitely in 20 per cent of the non-macerated Wassermann positive cases, and in 5 per cent of the non-macerated Wassermann negative cases examined histologically. Only one half of the Wassermann positive cases showing fibrosis were also spirochaete positive.

The presence in the liver and other viscera of numerous collections of cells (apparently a persistence of the nodes of haemopoietic tissue normally found at an earlier stage of development) was more frequent on the whole in the syphilitic than in the non-syphilitic foetuses. The presence of this appearance was too indefinite and inconstant, however, to make it of much value in differential diagnosis.

The following are the main points to which one would draw attention:-

1. The incidence of a positive Wassermann reaction in both mothers and new-born infants agrees in the present investigation with that in a number of other published investigations which were carried out on similar material.

2. The Wassermann reaction in the child at birth is in close agreement with that of the mother, but during the first few weeks of life the great majority of children born with a positive reaction lose that reaction and not only remain negative to the Wassermann test, but fail to develop clinical signs of syphilis during the first two years of life. From this it is concluded that -

a. A positive W.R. in the blood of a new-born infant is due at least in the majority of cases to a transference of reacting substances from the mother.

b. A positive W.R. in the new-born infant is of no value in diagnosis.

c. The incidence of congenital syphilis is very much less than purely serological data would indicate.

d. The high incidence of syphilis in the adult population of the class under consideration must be due either to acquired syphilis, or, less probably, to late congenital syphilis.

3. The effects of syphilis in the mother are seen chiefly in the later months of pregnancy at which time the disease leads to premature birth and, more particularly, to premature stillbirth. As a cause of interruptions of pregnancy in the earlier months syphilis does not appear to be of predominating importance.

4. There is no single macroscopic or microscopic lesion in the foetus upon the presence of which a positive diagnosis of congenital syphilis can be made in all cases. Many of the signs supposed to be characteristic of congenital syphilis in the new-born are quite inconstant in their presence in definitely syphilitic cases, and others - e.g. splenomegaly - are not confined to syphilitic infants. The diagnosis of syphilis in the new-born can be made definitely only after a careful review of the clinical, serological and pathological findings.

While the writer is of opinion that congenital syphilis is not by any means so common in the new-born as many published references to the subject would indicate, he believes that its incidence is sufficiently great to justify every effort being made to deal with it. Such small experience in the prenatal treatment of syphilitic pregnant women as the writer has had has been encouraging. It is unnecessary at the present time to make any defence of the pre-natal as opposed to the post-natal treatment of the congenitally syphilitic infant, for in recent years the superiority of the former method has been clearly

demonstrated by many independent observers (see, for example, the work of Findlay and others in Glasgow, and of Adams in London). In view of the fact that such a simple and successful method of treatment exists, it is to be regretted that in Glasgow at the present time the means for dealing with such cases are by no means satisfactory. The writer has noted that comparatively few of the syphilitic women with whom he has kept in touch after their dismissal from hospital have availed themselves of the existing facilities for treatment (though they were advised to apply for treatment by the Almoner). This appears to be due largely to the still prevalent custom of classifying all such patients as "venereal". Many respectable married women have complained of the publicity involved in attendance at Venereal treatment centres, and of the type of women with whom they were there in contact. The basis of any scheme for dealing with this form of syphilis is an efficient system of pre-natal and post-natal supervision. This already exists in the Child Welfare Centres with which the city is well supplied, and it should not be difficult to provide for the treatment of pregnant or recently delivered women at some or all of these clinics. In this way a greater number of syphilitic women would submit to treatment, and a considerable saving of foetal and infant life would be effected.

REFERENCES.

Adams, J.,	Brit. Med. Jour., 1918, ii. Lancet, 1920, ii, 913. Brit. Med. Jour., 1922, i, 56.
Adair, F.E.,	Amer. Jour. Obstet., 1918, , 678. Jour. Amer. Med. Assn., 1916, lxvi, 1818.
* Baisch,	Monatsech. f. Geb. u. Gyn., 1911, xxiv, 273 (see Journ. Obstet. & Gyn. Brit. Emp., 1911, xx,207.)
* Barenberg, L.H., & Rosenberg, P.,	Arch. of Pediatr. (see Amer. Jour. Syph., 1923, vii, 197.)
Bartholomew, R. A.,	Journ. Amer. Med. Assn., 1918, lxx, 289.
* Boas, & Thomsen, O.,	Arch. f. Dermatol. u. Syph., 1912, iii, 91. (see Kolmer, loc. cit.)
Browne, F. J.,	Journ. Obstet. & Gyn. Brit. Emp., 1921, xxviii, 178.
Browning, C. H.,	Brit. Med. Journ., 1914, i, 77.
Browning, C. H., & Kennaway, E. L.,	Journ. of Hyg., 1920, xix, 87.
Browning, C. H., & Watson, D.,	Venereal Diseases, 1919, 107 et seq.
Carpenter, Tubby, & others,	Rep. Soc. Study Dis. Children, 1908, viii, 133.
* Cassell, A.,	Arch. f. Kinderh., 1909, 1, 154. (quoted by Griffith, loc. cit.)
Churchill, & Austin,	Amer. Jour. Dis. Children, 1916, xii, 355.

Connell, L.L., & Stillians, A.W.,	Jour. Amer. Med. Assn., 1919, lxxii, 551.
Connell, L.L., & Stillians, A. W.,	Amer. Jour. Syph., 1920, i, 342.
Coutts, J. A.,	Lancet, 1896, i, 971.
Couvelaire,	Rev. mens. Gynec. et Obst., 1922, vi, 70.
* Daunay,	Rev. mens. d'Obstet., et de Gyn., 1912, , (see Jour. Obst. & Gyn. Brit. Emp., 1912, xxi, 299).
Day, A. B., & McNitt, W.,	Amer. Journ. Syph., 1919, iii, 595.
DeBuys, L. R., & Loeber, M.,	Journ. Amer. Med. Assn., 1919, lxxiii, 1028.
Dembo, L. H., Litchfield, H. R., & Foote, J. A.,	Jour. Amer. Med. Assn., 1922, lxxviii, 319.
Edgar,	Textbook of Obstetrics, , 346.
Elliot, W. M.,	Trans. Glasg. Med. Chir. Soc., 1914, 58.
Epstein,	(quoted by Churchill & Austin - loc. cit.)
Fildes, P.,	Local Gov. Board Rep., 1915.
Fildes, P., & Parnell, R. J. G.,	Spec. Med. Res. Council/Rep. Ser. No. 23.
Fildes, P.,	Lancet, 1921, i, 406.
Findlay, L.,	Syphilis in Childhood, 1920, 19. Brit. Med. Journ., 1921, ii, 887.
Fournier, A.,	L'heredite syphilitique, 1891, 309 et seq.
Fraser, J. F.,	Journ. Amer. Med. Assn., 1921, lxvii, 1623.
* Fruhinsholz,	Rev. d'hyg. et de med. inf., 1903, ii, 1, (quoted by Griffith, loc. cit.)

Glomset, D. J.,	Journ. Amer. Med. Assn., 1915, lxv, 682.
Graves, S.,	Journ. Amer. Med. Assn., 1918, lxx, 1751.
Griffith, J. P. C.,	Diseases of Infants and Children, 1919, i, 562, et seq.
Harman, M. B.,	Brit. Med. Journ., 1916, i, 196 .
Hewlett, R. T.,	Manual of Bacteriology, 1921, 608.
Hinton, W. A.,	Amer. Journ. Syph., 1923, vii, 155.
Hirst, B. C.,	Textbook of Obstetrics, 1900, 151.
*Hochsinger,	Ergeb. d. inn. Med. u. Kinderh., 1910, v, 125, (quoted by Griffith, loc. cit.)
Holland, E.,	Ministry of Health Rep. on Causation of Foetal Death, 1922.
Jardine, R.,	Clinical Obstetrics, 1910, 346.
Jeans, P. C.,	Amer. Journ. Syph., 1919, iii, 114, 118 et seq.
Jeans, P. C., & Cooke, J. V.,	N. Y. Med. Jour., 1920, cxii, 1049.
Jeans, P. C., & Cooke, J. V.,	Amer. Journ. Dis. of Child., 1921, xxii, 402.
Jeans, P. C., & Butler,	Amer. Jour. Dis. Children, 1914, viii, 327.
Jewesbury, R. C.,	Lancet, 1921, i, 962.
Keidel, A.,	Journ. Amer. Med. Assocn., 1921, lxxvii, 1.
Kolmer, J. A.,	Infection, Immunity & Specific Therapy, 1920, 489.
Kolmer, J. A.,	Jour. Amer. Med. Assn., 1921, lxxvii, 776.

*Klander, ,	Arch. mens. d'Obstet. & Gyn., 1912, (see Journ. Obst. & Gyn. Brit. Emp., 1912, xxi, 308.)
*Labourette,	These de Paris, 1916, quoted by Lasseur & Vermelin, loc.cit.
Larkin, J. H., Levy, I. J., & Fordyce, J.D.,	Journ. Amer. Med. Assn., 1918, lxx, 1589.
Lasseur, P., & Vermelin, H.,	Rev. mens. Gynec. & Obstet., 1923, vii, 130.
Lawrence, J. S.,	Journ. Amer. Med. Assn., 1922, lxxviii, 566.
*Le Pileur, ,	These de Paris, 1851, quoted by Fournier, p. 312, loc. cit.
McIlroy, A. L., & Watson, D.,	See Browning, C. H., 1914, loc.cit.
McLester, J. S.,	Journ. Amer. Med. Assn. 1911, lxvi,)
Medical Research Council,	Spec. Rep. Ser. No. 14. (2063) " " " " 21.
Naborro, D., Routh, A., & others,	Lancet, 1921, i, 484.
*Neumann & Oberwarth,	Arch. f. Kinderh., 1905, xlii, 64.
Osler, W., & McCrae, T.,	System of Medicine, 1915, ii, 187 et seq.
Rebman,	Textbook of Obstetrics, 1907, 349.
Rosenberger, R. C.,	N. Y. Med. Jour. , 1917, cv, 1233.
Ross, S. M., & Wright, A. F.,	Lancet, 1921, i, 962.
Routh, A.,	Brit. Med. Journ., 1918, i, 47.
Routh, A.,	Brit. Med. Journ., 1914, i, 170 et seq. 510.
Routh, A.,	Lancet, 1918, i, 45.
Rundle, G. W.,	Lancet, 1920, ii, 1268.
Slemmons, J. M.,	Journ. Amer. Med. Assn., 1915, lxv, 1265.

Still, G. F.,	Pediatrics, 1904, xvi, 577.
Still, G. F.,	Common Diseases of Infants and Children, 19 , 793.
Stoll, H. F.,	Journ. Amer. Med. Assn., 1921, lxxvii, 917.
Strickler, A.,	Journ. Amer. Med. Assn., 1922, lxxviii, 962.
Symmers, D. et al.,	Journ. Amer. Med. Assn., 1918, lxx, 279.
*Tissier, ,	Bull. de la Soc. d'Obstet. de Paris, 1910.
Turnbull, H. M.,	Lancet, 1922, i, 239.
Turnbull, H. M.,	Med. Res. Counc. Spec. Rep. Ser., No. 47.
Vedder, E. B.,	Therap. Gaz., 1916, xli, 308.
Veeder, B. S.,	Amer. Journ. Med. Sci., 1916, clii, 522.
Walker, I. C., & Halter, D. A.,	Journ. Amer. Med. Assn., 1916, lxvi, 1001.
Wallenstein, S.,	N. Y. Med. Journ., 1922, cxv, 514.
Watson, H. F.,	Thesis for M.D. Glasgow, 1913.
Williams, J. W.,	Bull. Johns Hopkins Hosp., 1920, xxxi, 335.
Williams, J. W.,	Bull. Johns Hopkins Hosp., 1922, xxxiii, 383.
Williams, J. W.,	Bull. Johns Hopkins Hosp., 1920, xxxi, 141.
Wilkiams, J. W.,	Journ. Amer. Med. Assn., 1915, lxiv, 95.

Publications marked with an asterisk were not available in the original, and reference to abstracts only was made.

APPENDIX 1.

THE CLINICAL HISTORY

OF ONE THOUSAND PREGNANT AND PARTURIENT WOMEN

TOGETHER WITH THE RESULTS OF THE WASSERMANN REACTION.

John Norman Cruickshank

(M.D. Thesis).

Case No.

1. W.R. Mother = Negative (3-5-). 3-9-20.
Child = Negative (3-5-). 3-9-20.

2nd Preg. Single. Age 24.
Normal pregnancy and labour - Child born alive 30-8-20, female, mature, weight 7½ lbs. Dismissed 8-9-20, weight 6¾ lbs.
29-4-22 - Both mother and child well - child 20 months old and so far no illness.
Prev. Preg.- Normal, F.T.

2. W.R. Mother = Negative (3-5-). 3-9-20.
Child = Negative (3-5-). 3-9-20.

7th Preg. Married. Age 34.
Normal pregnancy and labour - Child born alive 29-8-20, female, mature, weight 6¾ lbs. Dismissed 8-9-20, weight 7 lbs.
31-3-22 - Both mother and child well - child 19 months old. Had Measles and Whooping-cough.
W.R. Mother = Negative (3-5-). 31-3-22.
Child = Negative (3-5-). 31-3-22.
Prev. Pregs.- Three full-time pregs. and three miscarriages (at 3, 5 and 6 months respectively).

3. W.R. Mother = Negative (3-5-). 3-9-20.

2nd Preg. Married. Age 33.
L.P. 15-12-19. Admitted to Ante-natal Dept. 25-8-20 - Mitral stenosis. Patient had suffered from breathlessness and palpitation for two years and had been worse since she became pregnant. For fourteen days before admission feet were swollen. On admission marked oedema of legs, marked presystolic murmur heard during almost whole of diastole - occasional extrasystole. Dismissed undelivered 11-9-20. Delivered at home end March, 1921 (normal labour) - male.
11-2-22 - Both mother and child well - child 11 months old.
W.R. Mother = Negative (3-5-). 11-2-22.
Child = Negative (3-5-). 11-2-22.
Prev. Preg.- Normal, F.T.

Case No.

4. W.R. Mother = Negative (3-5-). 3-9-20.

6th Preg. Married. Age 29.
Admitted 29-8-20. Before admission patient had severe haemorrhage for four hours - vagina packed. Complete Miscarriage (6½ months) evening of admission. Under chloroform head was perforated and foetus expelled by supra-pubic expression. Placenta (degenerate) and membranes removed manually.
Prev. Pregs. - All stillborn - 1st at 7, 2nd at 8, 3rd = F.T., 4th and 5th at 7 months.

5. W.R. Mother = Negative (3-5-). 8-9-20.

9th Preg. Married. Age 40.
L.P. middle Decr., 1919. Admitted to Antenatal Dept. 13-8-20. Headache for week before admission: face and hands swollen and severe disturbance of vision. The left field of vision was said to be yellow in colour at times. On admission oedema of face, hands and feet: Albuminuria: Foetus alive - abdomen about 7½ months size. Child born 9-45 p.m. 4-9-20 - male, premature, weight 6 lbs. Dismissed 20-9-20, weight 5½ lbs.
The child died of 'congestion' at the age of 16 months.
Prev. Pregs.- History not recorded.

6. W. R. Mother = Negative (3-5-).

4th Preg. Married. Age 26.
Admitted to Antenatal Dept. 4-8-20 - examined under anaesthetic: considerable overlapping, head could not be pushed down into cavity. Dismissed to return at fulltime for caesarean section. (Diag. Conj. = 4").
Readmitted 21-8-20: Caesarean section on 1-9-20 - child born alive, male, F.T., weight 9¼ lbs. Dismissed 24-9-20, weight 8¼ lbs. No trace after dismissal.
Prev. Pregs. - History not recorded.

Case No.

7. W.R. Mother = Negative (3-5-). 3-9-20.

1st Preg. Single. Age 22.
L.P. 17-11-19. Small rachitic woman with marked curvature of legs and thighs - Contracted Pelvis (C.V. = 2½" +, Diag. Conj. = 3¼" +). Child lying obliquely - breech in right iliac fossa. Caesarean section 2-9-20 - female, alive, mature, weight 5½ lbs. Dismissed 23-9-20, weight 4½ lbs.
The child died two days after dismissal in R.H.S.C. - P.M.

8. W.R. Mother = Negative (3-5-). 3-9-20.
Child = Negative (3-5-). 3-9-20.

4th Preg. Married. Age 36.
Admitted to Antenatal Dept. 20-8-20 - Albuminuria and varicose veins. Reddish inflamed area (Phlebitis) over calf of left leg. Child born (forceps) 11-9-20 - Female, alive, mature, weight 9½ lbs. Dismissed 24-9-20, weight 9 lbs.
20-2-22 - Both mother and child well - child now aged 17 months: no illnesses.
Prev. Pregs.- All normal.

9. W.R. Mother = Negative (3-5-). 3-9-20.

8th Preg. Married. Age 30.
L.P. 6 weeks before admission. Admitted 29-8-20. Haemorrhage for four days intermittently. Pain and haemorrhage began after admission - 2½ months foetus discharged. Incomplete Abortion: Chloroform - uterus explored: placenta removed and uterus packed (haemorrhage).
Prev. Pregs.- 4 = F.T., alive: 3 = miscarriages - one at 4 and two at three months.

Case No.

10. W.R. Mother = Negative (3-5-). 3-9-20.

1st Preg. Married. Age 24.
Admitted 23-8-20 - Contracted Pelvis (True Conj. = 2¾", Diag. Conj. = 3½").
Spontaneous delivery - child born dead 23-8-20, male, premature (8 months), weight 5½ lbs.

11. W.R. Mother = Negative (3-5-). 3-9-20.

1st Preg. Married. Age 31.
L.P. 11-11-19. Admitted 23-8-20. Constant vomiting during first three months of pregnancy, since then has been uneventful. Was in labour for 40 hours before admission - not in good condition. Breech presentation: Episiotomy: Complete tear of perineum. Child born dead 23-8-20, male, F.T., weight 7½ lbs.

12. W.R. Mother = Negative (3∓5-). 3-9-20.

1st Preg. Single. Age 18.
L.P. 28-11-19. Attended Antenatal Dispensary. Admitted to Hospital 3-9-20. Normal labour - child born alive 3-9-20 - Female, weight 7½ lbs. Dismissed 13-9-20, weight 7½ lbs.
The child was known to be alive and well when aged 14 months but died since in Belvidere Hospital of Pneumonia.

Case No.

13. W.R. Mother = Negative (3-5-). 3-9-20.

12th Preg. Married. Age 43.
L.P. Novr., 1919. Admitted 27-8-20. Normal pregnancy and labour - child born alive 28-8-20, male, mature, weight 7½ lbs. Dismissed 6-9-20, weight 7 lbs.
17-11-21 - Baby aged 15 months: Mother has been 'extra well' since she left hospital: the child was breast-fed until one year old: had 'gastro-enteritis' in July and Novr., 1921: looked a little pale was otherwise healthy now.
Prev. Pregs.- History not recorded.

14. W.R. Mother = Negative (3-5-). 3-9-20.

6th Preg. Married. Age 38.
L.P. - Amenorrhoea for twelve months. Admitted 23-8-20. Normal pregnancy and labour - child born alive 23-8-20, Female, weight 5½ lbs. Mother has splenomegaly. Dismissed 4-9-20, weight 5 lbs.
Mother died in May, 1921: child reported well at the age of 14 months.
Prev. Pregs.- All F.T., alive.

15. W.R. Mother = Negative (3-5-). 3-9-20.

1st Preg. Married. Age 26.
Admitted 20-8-20. Head remained for a long time on the perineum - forceps applied - child born alive 20-8-20, male, mature, weight 8½ lbs. Dismissed 30-8-20, weight 8½ lbs.
Attended G.R.M.H. Infant Cons. until child one year old - child very healthy.

Case No.

16. W.R. Mother = Negative (3-5-). 3-9-20.

4th Preg. Married. Age 25.
Admitted in labour 25-8-20 - foot and cord prolapsed. Delivered under chloroform 25-8-20 - Twins born alive; both presented by the breech; 1st = male, weight 7½ lbs., 2nd = female, weight 7 lbs. Dismissed 4-9-20.
20-2-22 - Children both very healthy - now aged 18 months: Mother also well.

17. W.R. Mother = Negative (3-5-). 3-9-20.

1st Preg. Married. Age 23.
Admitted in labour 15-8-20. Mother had marked rachitic deformity of thighs and legs. Contracted Pelvis (Diag. Conj. = 3½" -, True Conj. = 2¾" -). Caesarean Section (not sterilised) - child born alive, male, weight 7½ lbs. Dismissed 4-9-20, weight 8 lbs.
21-2-22 - Mother and child both well: child now 19 months old and is slightly rickety: no illness.
W.R. Mother = Negative (3 ≋ 5 ≋). 21-1-22.
Child = Negative (3 ≋ 5 -). 21-1-22.

18. W.R. Mother = Positive (3+5-). 3-9-20.

4th Preg. Married. Age 33.
L.P. 10-11-19. Admitted to Antenatal Dept. 9-8-20 - Generally contracted pelvis (Diag. Conj. = 4¼" +, True Conj. = 3½"-). Caesarean section (patient sterilised) 17-8-20 - male born alive, weight 9 lbs. 6 ozs. Dismissed 7-9-20, weight 10 lbs. No trace after dismissal.
Prev. Pregs.- 1st = F.T.,(difficult labour) child stillborn: 2nd = F.T., CH.clz. & instrs., S.B.: 3rd = F.T., CH.clz. & instrs., S.B.

Case No.

19. W.R. Mother = Negative (3-5-). 3-9-20.

2nd Preg. Married. Age 33.
L.P. 3-1-19. Admitted 23-8-20. Slightly contracted pelvis (Diag. Conj. = 4½"). Child born alive 24-8-20, male, premature, weight 4½ lbs. Dismissed 2-9-20, weight 3¾ lbs.
20-2-22 - Both well:child now 18 months old - Has had Bronchitis and Pneumonia.
Prev. Preg.- Chloroform & instrs., Child born alive.

20. W.R. Mother = Negative (3-5-). 3-9-20.

16th Preg. Married. Age 45.
L.P. middle Decr., 1919. Admitted to Antenatal Dept. 16-8-20 - has been jaundiced and losing weight for two months and has had Anorexia with sickness and vomiting for several days before admission. On admission was emaciated, jaundiced and cachectic: very prominent abdomen: fluid thrill present: ballottement of foetus: Albuminuria. Under chloroform bougies inserted - changed after 36 hours: labour induced - spontaneous delivery - child born alive 22-8-20, female, weight 6½ lbs. Dismissed 1-9-20, weight 6 lbs.
17-2-22 - Child aged 18 months: Mother and child both well.
W.R. Mother = Negative (3-5-). 17-2-22.
Child = Negative (3-5-). 17-2-22.
Prev. Pregs.- All 15 previous pregnancies normal.

21. W.R. Mother = Negative (3-5-). 3-9-20.

2nd Preg. Married. Age 33.
L.P. Novr., 1919. Admitted to Antenatal Dept. 25-8-20. Normal labour - child born alive 26-8-20, Female, weight 8 lbs. Dismissed 6-9-20, weight 8¼ lbs.
21-1-22 - Both well: child now aged 17 months - measles only illness.
W.R. = Negative (3-5-). 21-1-22.
= Negative (3-5-). 21-1-22.
Prev. Preg.- History not recorded.

Case No.

22. W.R. Mother = Negative (3-5-). 3-9-20.

5th Preg. Married. Age 23.
Admitted 13-8-20. Ruptured ectopic gestation - laparotomy - ectopic gestation in ampullary part of left tube.
Prev. Pregs. - All F.T., normal.

23. W.R. Mother = Negative (3-5-).

2nd Preg. Married. Age 32.
Admitted Antenatal Dept. 31-8-20 - Contracted Pelvis. No albuminuria: Haemorrhoids: otherwise well. Dismissed (undelivered) 11-9-20.
Prev. Preg.- Caesarean Section in Dublin eleven years ago.

24. W.R. Mother = Strongly Positive (3+5+). 3-9-20.

8th Preg. Married. Age 30.
Admitted to Antenatal Dept. 20-8-20 - abdominal pain. No vomiting. Slight lumbar pain. Foetal movements ceased five days before admission. Was well till three weeks before admission when pain began in back and sides, accompanied by vomiting - vomiting after all food. This continued till two days before admission. No albuminuria. Dismissed (undelivered) 7-9-20. Stillborn macerated foetus born at own home a few days after dismissal.
18-1-21 - Marked anaemia: Malaise:
W.R. = Strongly Positive (3+5+). 18-1-21.
No treatment but promised to attend G.R.I. Disp.
29-7-21 - Has pains in back and thinks she is four months pregnant.
5-8-21 - W.R. = Strongly Positive (3+5+).

9th Preg. Admitted to Hosp. 23-11-21. Foetal movements ceased 10 days before admission. Child born dead 23-11-21.
W.R. Child = Negative (3-5-). 30-11-21.
24-12-21 - Salvarsan given.
Prev. Pregs.- 6 normal labours (last in March, 1914): one miscarriage at 6th week (Feby.1916).

Case No.

25. W.R. Mother = Negative (3-5-). 3-9-20.

5th Preg. Married. Age 25.
L.P. 16-6-20. Admitted to Antenatal Dept. 26-8-20. Hyperemesis gravidarum. Greatly improved under treatment. About 14 days before admission began to vomit day and night - neither solids nor fluids retained. On admission looked well, good colour, but tongue furred. Persistent vomiting: constipation. No abdominal tenderness or rigidity, uterus just palpable. Greatly improved on dismissal on 3-9-20. Readmitted 9-9-20 - Vomiting began after return to home - was more severe than before. No albuminuria, but acetone and diacetic acid present 19-9-20. Uterus emptied 24-9-20. Dismissed 4-10-20.
Prev. Pregs.- 3 normal labours (last in Novr., 1918). About third month of fourth pregnancy (summer 1918) was admitted to G.R.M.H. with Pernicious vomiting. 3rd preg. = miscarriage at third month (Novr., 1917).

26. W.R. Mother = Strongly Positive (3+5+). 3-9-20.
Child = Strongly Positive (3+5+). 17-9-20.

1st Preg. Married. Age 21.
L.P. 25-12-10. Admitted to Antenatal Dept. 26-8-20 - Chorea. Six or seven weeks before admission choreic movements of face began and speech affected: later hands, and, to less extent, legs involved. Movements slight on admission - only legs affected. Treatment. History of rheumatic fever seven years ago followed by chorea. Child born alive 13-9-20 - Female, weight 8½ lbs. Dismissed 28-9-20, weight 7¾ lbs. Attended Infant Cons. regularly.
18-2-22 - Both well - W.R. Mother = Str. Pos. Child aged 17 months - Child = Negative.

Case No.

27. W.R. Mother = Negative (3-5-). 3-9-20.

3rd Preg. Married. Age 28.
L.P. 3-7-20. Admitted to Antenatal Dept. 26-8-20 - Threatened Abortion. Well till day before admission when bled for two hours. No further bleeding after admission. Trace of albuminuria. Dismissed 3-9-20.
Prev. Pregs.- 1st = normal (Sept., 1916): 2nd = miscarriage at 6½ months (Octr., 1919).

28. W.R. Mother = Negative (3-5-). 3-9-20.

1st Preg. Married. Age 19.
L.P. 20-6-20. Admitted 1-9-20. Bleeding for one week before admission. Incomplete Abortion. Curettage.

29. W.R. Mother = Positive (3+5±). 3-9-20.

6th Preg. Married. Age 30.
Admitted to Antenatal Dept. 1-9-20 - Hyperemesis. Vomiting from second month onwards - much worse during two weeks before admission. Unable to retain anything. Uterus about five months size. Dismissed 17-9-20 and readmitted 8-10-20. Albuminuria. Dismissed (undelivered) 1-11-20. Female child born at home 24-12-20. Child was well when seen at age of 7 months and appeared to be well developed and well nourished. 26-7-21 - Mother has had feeling of giddiness since birth of child and pain after meals - vomiting at night.
30-3-22 - Child now aged 15 months: just better from Bronchopneumonia and Measles: Mother well.
Prev. Pregs.- 1st and 2nd = normal: 3rd, 4th and 5th = vomiting from second month onward - morning sickness specially severe. Hyperemesis was never bad enough to necessitate induction, however, and all the children were born full-time.

Case No.

30. W.R. Mother = Negative (3-5-). 3-9-20.

1st Preg. Married. Age 25.
L.P. 20-2-20. Admitted 1-9-20. Jaundice: history of headaches: disturbance of vision for some time: On admission well marked icterus of skin and sclerosis, and stools grey and very offensive. Foetal movements felt. Dismissed undelivered 7-9-20.

31. W.R. Mother = Negative (3-5-). 3-9-20.

6th Preg. Married. Age 36.
L.P. 3-12-19. Admitted 1-9-20 - Albuminuria. History of headaches occasionally during present pregnancy: feet and legs swollen for two weeks. On admission slight oedema of feet and legs: haze of albumen in urine-abdomen prominent: foetus alive. Child born alive 5-9-20 - male, mature, weight 7 lbs. Dismissed 29-9-20, weight 7½ lbs. No trace after dismissal.
Prev. Pregs.- All fulltime, normal.

32. W.R. Mother = Negative (3-5-). 10-9-20.

1st Preg. Single. Age 24.
L.P. 21-11-19. Admitted 1-9-20. Normal pregnancy and labour: R.P. Child born alive 2-9-20, female, weight 8 lbs. Dismissed 11-9-20. Child died of pneumonia when one year old.

33. W.R. Mother = Negative (3-5-).

3rd Preg. Married. Age 26.
L.P. 3-12-19. Admitted 1-9-20 - Mammary abscess. On admission pus was oozing from superficial abscess of left breast which was incised and drained. Dismissed undelivered 9-9-20.

Case No.

34. W.R. Mother = Negative (3-5-). 10-9-20.
Child = Negative (3-5-). 10-9-20.

1st Preg. Single. Age 18.
Admitted 1-9-20. Normal pregnancy and labour. Child born alive 1-9-20, female, mature, weight 8½ lbs. Gonorrhoeal warts on perineum. Dismissed 11-9-20. No further trace.

35. W.R. Mother = Negative (3-5-). 10-9-20.
Child = Negative (3-5-). 3-9-20.

1st Preg. Married. Age 22.
L.P. Decr., 1919. Admitted 30-8-20. Normal pregnancy and labour - child born alive 30-8-20, female, mature, weight 6½ lbs. Adherent placenta removed manually. Dismissed 10-9-20, weight 7 lbs.
W.R. Mother = Negative (3-5-). 21-1-22.
Child = Negative (3-5-). 21-1-22.
24-2-22 - Both mother and child well - child now 18 months old.

36. W.R. Mother = Negative (3-5-). 10-9-20.

1st Preg. Married. Age 26.
Admitted 1-9-20. Before admission seven months foetus, S.B., delivered. Two eclamptic fits after delivery but no further fits after admission. Trace of albumen in urine : no blood. Dismissed 17-9-20.

Case No.

37. W.R. Mother = Negative (3-5-). 3-9-20.

7th Preg. Married. Age 41.
L.P. 5-12-19. Admitted to Antenatal Dept. 1-9-20. Patient curetted seven years ago: Operation for left femoral hernia five years ago: Ventro-fixation two years ago - appendix and right ovary removed at same time. Caesarean Section (patient sterilised) - child born alive 24-9-20, female. Dismissed 23-10-20, weight 10¾ lbs.
20-2-22 - Child now 17 months old - never any illness.
Prev. Pregs.- no record.

38. W.R. Mother = Negative (3-5-). 10-9-20.
Child = Negative (3-5-). 10-9-20.

5th Preg. Married. Age 30.
L.P. 11-12-19. Admitted 1-9-20. Marginal Placenta Praevia. Commenced bleeding one hour before admission. Bipolar version - vagina packed. Spontaneous delivery - child born alive 2-9-20, female, weight 6 lbs. Dismissed 13-9-20, weight 5 lbs.
W.R. Mother = Negative (3-5-). 21-1-22.
Child = Negative (3-5-). 21-1-22.
20-2-22 - Child aged 17 months: no illness.
Prev. Pregs.- Not recorded.

39. W.R. Mother = Negative (3-5-). 10-9-20.
Child = Negative (3-5-). 10-9-20.

4th Preg. Married. Age 25.
L.P. Decr., 1919. Admitted 1-9-20 - Breech with prolapsed arm - arm replaced. Child born alive 1-9-20, male, weight 9 lbs. Dismissed 11-9-20, weight 8¾ lbs.
The child died of Broncho pneumonia at the age of 17 months.
Prev. Pregs.- All normal.

Case No.

40. W.R. Mother = Negative (3-5-). 10-9-20.

10th Preg. Married. Age 40.
L.P. 11-6-20. Admitted 1-9-20. Incomplete Abortion - curettage - placental remains removed. Had haemorrhage four weeks before admission - piece of ovum size of a walnut expelled. Bleeding ever since. Dismissed 8-9-20.
Prev. Pregs.- All normal except last which was premature (7 months).

41. W.R. Mother = Negative (3-5-). 10-9-20.
Child = Negative (3-5-). 10-9-20.

1st Preg. Single. Age 25.
L.P. middle Novr., 1919. Admitted 30-8-20. Normal pregnancy and labour - child born alive 1-9-20, female, weight 8½ lbs. Adherent placenta removed manually (adherent near fundus). Dismissed 10-9-20, weight 8 lbs.
28-2-22 - Both well - child now aged 17 months.

42. W.R. Mother = Positive (3±5∓). 10-9-20.
Child = Negative (3-5-). 10-9-20.

1st Preg. Single. Age 21.
Admitted 1-9-20. Normal pregnancy and labour. Child born alive 1-9-20, male, weight 8½ lbs. Dismissed 11-9-20, weight 8 lbs.
28-2-22 - Both well - child aged 17 months: no illness.

Case No.

43. W.R. Mother = Negative (3-5-). 24-9-20.
Child = Strong. Pos. (3+5+). 10-9-20.

1st Preg. Married. Age 23.
L.P. end Novr., 1919. Admitted 2-9-20. Post-Partum Eclampsia. Fece puffy: oedema of legs. Child born alive 2-9-20 - male, weight 8½ lbs. Mother had two fits morning after delivery - responded well to eclamptic treatment. History of rheumatism and nephritis in 1916. Occasional headaches but otherwise well during pregnancy. Had Anti-syphilitic treatment in Edinburgh and her W.R. was positive three months before delivery. Dismissed 24-9-20, weight 7½ lbs. No further trace.

44. W.R. Mother = Negative (3-5-). 10-9-20.

3rd Pregnancy. Married. Age 28.
L.P. ? Jany., 1920. Had a fall in January and has not felt well since. Feels very weak: very constipated.
Prev. Pregs.- 1st = male, F.T., alive: 2nd = Female, F.T., alive, normal labour.

45. W.R. Mother = Strong. Pos. (3+5+). 3-9-20.

3rd Preg. Married. Age 28.
L.P. 3-1-20. Attended Antenatal Disp. 3-9-20 - abdominal pain: pains in legs: constipation. Thin woman - sores on buttocks and copious white discharge. Albuminuria (+). Child born alive - Female, 8-10-20.
22-6-21 - Child well: mother complains of dimness of vision.
21-1-22 - W.R. Mother = Str. Pos. (3+5+).
Child = Negative (3-5-).
23-2-22 - Child aged 16 months when last visited - Both seemed well.

Prev. Pregs.- 1st = F.T., normal, alive (died at the age of three months): 2nd = F.T., normal, alive.

Case No.

46. W.R. Mother = Negative (3-5-). 10-9-20.

1st Preg. Single. Age 21.
L.P. Decr., 1919. Contracted Pelvis (Diag. Conj.= 3¾" -, True Conj. = 3" -). Patient was in Antenatal Wards from 17th to 23rd June, 1920: attended Antenatal Dispensary 4-8-20 and thereafter was admitted to Hospital. Caesarean section after about twelve hours labour - child born alive, male, weight 7 lbs. 10 ozs. Dismissed 5-11-20, weight 8½ lbs.
20-2-22 - Child aged 16 months - no illnesses.

47. W.R. Mother = Negative (3-5-). 10-9-20.

1st Preg. Married. Age 27.
L.P. Novr. or Decr., 1919. Attended Antenatal Dispensary 3-9-20 - Feet and legs swollen. (? urine). Had Scarlet fever, measles, whooping cough in childhood - also chickenpox and jaundice: later had abscess in neck and now has cough. Child born alive 19-9-20 - female. No further trace.

48. W. R. Mother = Negative (3-5-). 10-9-20.

4th Preg. Married. Age 27.
L.P. 4-4-20. Attended Antenatal Dispensary 3-9-20 history of stillbirth. Had a fall four weeks previously. Contracted Pelvis (C.V. = 2¾"). Admitted to Antenatal Dept. 3-12-20. Dismissed 7-12-20. Readmitted 29-12-20 - Caesarean Section (sterilised) - child born alive 29-12-20, male, weight 7 lbs. Dismissed 24-1-21.
21-1-22 - W.R. Mother = Negative (3-5-). 21-1-22.
Child = Negative (3-5-). 21-1-22.
24-2-22 - Child aged 14 months - has always been very healthy.
Prev. Pregs.- 1st and 2nd = S.B., (7 mos.): 3rd = F.T., S.B. (1917).

Case No.

49. W.R. Mother = Negative (3-5-). 10-9-20.
Child = Negative (3-5-). 19-11-20.

6th Preg. Married. Age 32.
L.P. end Jany., 1920. Attended Antenatal Disp. 3-9-20. Had a fall two weeks before and has not felt well since. Diarrhoea: pain at heart - has no murmur but first sound at apex soft and long: has very bad varicose veins: pelvis has normal conjugate but slight lateral contraction. Admitted 17-11-20. Child born alive 17-11-20 - male, weight 9¾ lbs. Dismissed 26-11-20, weight 9½ lbs.
The child was very healthy until 12 months old - he died of measles and broncho-pneumonia on 21-1-22.
Prev. Pregs.- All normal, F.T., alive, except the 5th which was a two months miscarriage during influenza in April, 1915. Last child was born 19-10-17.

50. W.R. Mother = Negative (3-5-). 10-9-20.

5th Preg. Married. Age 31.
L.P. ? 3rd March, 1920. Attended Antenatal Dispensary - Leucorrhoea and too frequent micturition. Was confined at home - premature female child born alive 22-11-20. Child died in R.H.S.C. 17-10-21.
Prev. Pregs.- 1st - 4th = F.T., normal, alive (last 18 months ago).

51. W.R. Mother = Negative (3-5-). 10-9-20.

3rd Preg. Married. Age 23.
L.P. 7-4-20. Attended Antenatal Dispensary 3-9-20 - Painful and scanty micturition.
Prev. Pregs.- 1st = F.T., normal, alive (died at 4 months): 2nd = F.T., normal (1917).

Case No.

52. W.R. Mother = Negative (3-5-). 10-9-20.

6th Preg. Married. Age 34.
L.P. 23-2-20. Attended Antenatal Dispensary 3-9-20. Had bleeding for one night seven days before. No life felt.
Prev. Pregs.- 1st - 4th = F.T., normal, alive: 5th = miscarriage at five months (Jany., 1920).

53. W.R. Mother = Negative (3-5-). 10-9-20.

1st Preg. Single. Age 19.
L.P. Novr. or Decr., 1919. Attended Antenatal Dispensary 3-9-20 - Abdominal pain: Anorexia: swelling of right leg and foot: pain in back. Normal labour - child born alive 21-9-20, male, weight 7 lbs. Dismissed 2-10-20, weight 6½ lbs. No further trace.

54. W.R. Mother = Negative (3-5-). 10-9-20.

7th Preg. Married. Age 26.
L.P. March, 1920. Admitted 4-9-20. Complete miscarriage. Bleeding began six weeks before admission and has been bleeding ever since. Uterus up to level of umbilicus. Dismissed 13-9-20.
Prev. Pregs.- 1st and 3rd = premature: 5th and 6th = F.T. (one lived 10 days only): 2nd & 4th = miscarriages at 3½ months.

55. W.R. Mother = Negative (3-5-). 10-9-20.

1st Preg. Single. Age 20.
L.P. 1-3-20. Admitted Antenatal Dept. 31-8-20 - Contracted Pelvis. Well till three days before admission when pains set in in right iliac region. Pain intermittent - some days absent. Slight discharge but no bleeding. Patient is anaemic and rachitic. Contracted Pelvis - (Diag. Conj. = 3⅞", True Conj. = 3⅛"). Urine clear. Dismissed 14-9-20.

Case No.

56. W.R. Mother = Negative (3-5-). 10-9-20.

9th Preg. Married. Age 28.
L.P. 2-6-20. Admitted Antenatal Dept. 4-9-20 - Habitual death of foetus. General condition fairly good. After W.R. was done put on biniodide mixture in "view of history". Dismissed 18-9-20.
Prev. Pregs.- 1st = premature (child lived one day): 2nd = miscarriage at 2½ months: 3rd = F.T., alive (lived 10 weeks): 4th = premature (lived two days): 5th = miscarriage at two months: 6th, 7th and 8th = miscarriage at 6th month (8th preg. delivered in hospital = 6½ months child could not be resuscitated (Jany., 1920).

57. W.R. Mother = Negative (3-5-). 10-9-20.

2nd Preg. Married. Age 25.
L.P. 12-5-20. Admitted to Antenatal Dept. 4-9-20 - pelvic cellulitis. Since last pregnancy has had pain in lower abdomen (left side) - gripping and dragging in character. Never been severe but worse after heavy work and has been more constant since became pregnant again. No rigidity, but tenderness on deep pressure left iliac fossa and left loin. No albuminuria. Dismissed 11-9-20 - feeling much better.
Prev. Preg.- Normal except for P.P.H. due to retained placenta.

58. W.R. Mother = Negative (3-5-). 10-9-20.

1st Preg. Single. Age 25.
L.P. Decr., 1919. Normal pregnancy and labour. Child born alive 3-9-20 - male, weight 8 lbs. Dismissed 13-9-20, weight 7¼ lbs. No further trace.

Case No.

59. W.R. Mother = Negative (3-5-). 10-9-20.
Child = Negative (3-5-). 10-9-20.

2nd Preg. Married. Age 37.
L.P. Novr., 1919. Admitted 6-9-20 - Failed forceps before admission. Labour began 5-9-20 at 9 p.m. Doctor outside had applied forceps but failed to deliver. On admission head on the perineum, meconium escaping. Forceps - child born alive 6-9-20 - female, weight 7 lbs. R.P. Dismissed 16-9-20, weight 7½ .
20-2-22 - Child alive and well when at the age of 17 months - no illness.
Prev. Preg.- Normal.

60. W.R. Mother = Negative (3-5-). 10-9-20.
Child = Negative (3-5-). 10-9-20.

1st Preg. Married. Age 21.
Normal pregnancy and labour. Child born alive 6-9-20, male, weight 7 lbs. Dismissed 18-9-20, weight 7½ lbs.
30-3-22 - Both well - child now 18 months old -
W.R. Mother = Negative (3-5-).
Child = Negative (3-5-).

61. W.R. Mother = Strongly Positive (3+5+). 10-9-20.

Attended Antenatal Dispensary. Child born alive 28-12-20 - Female.
4-2-22 - Child aged 14 months and has been very healthy - Mother also well.
W.R. Mother = Neg. (3-5-). 4-2-22.
Child = Neg. (3-5-). 4-2-22.

62. W.R. Mother = Negative (3-5-). 10-9-20.
Child = Negative (3-5-). 10-9-20.

1st Preg. Single. Age 21.
L.P. ? Decr., 1919. Child born alive 3-9-20 - male, weight 8 lbs. Mother dismissed on 13-9-20 but child was kept in for treatment and was taken home against the doctor's advice on 5-10-20. Died in Belvidere Hospital on 10-4-21 - Whooping-cough.

Case No.

63. W.R. Mother = Strong. Pos. (3+5+). 10-9-20.

3rd Preg. Married. Age 26.
L.P. 20-2-20. Admitted to Antenatal Dept. 21-8-20 - Diarrhoea. Day before admission was overcome by feeling of weakness in back and side. Diarrhoea but no vomiting: Anaemia noted. Dismissed 25-8-20. Readmitted 3-9-20 and was dismissed undelivered 13-9-20. Delivered at home on 9-11-20 - female, alive. Normal labour. Child had Congestion of lungs when two months old. Mother still pale and anaemic has weak turns. No treatment.
14-1-22 - Both well - W.R. Mother = D. Neg.(3+5-abs).
Child = Neg. (3-5-).
Prev. Pregs.- 1st = normal: 2nd = Premature (7½ months).

64. W.R. Mother = Negative (3-5-). 10-9-20.

2nd Preg. Married. Age 21.
L.P. 16-1-20. Admitted to Antenatal Dept. 2-9-20 - Contracted Pelvis. About fulltime size: some overlapping of head. Dismissed 11-9-20. Readmitted 19-9-20 in labour - membranes unruptured. Caesarean Section 20-9-20 - Child born alive - Female, weight 8 lbs. 10 ozs. Mother not sterilised. Dismissed 9-10-20, weight 9 lbs.
Mother and child both well when visited on 12-10-20 but on second visit learned that child died on 26-11-20 in Ruchhill Hospital after an operation for Hernia.
Prev. Preg.- Instr. delivery in July, 1919.

65. W.R. Mother = Negative (3-5-). 10-9-20.

2nd Preg. Married. Age 30.
L.P. 31-1-20. Admitted to Antenatal Dept. 31-8-20 - Contracted Pelvis (Diag. Conj. = 3½" , True Conj. = 2¾"). Urine clear. Dismissed 7-9-20.
Prev. Preg.- Vertex, Forceps, S.B. (Aug., 1919).

Case No.

66. W.R. Mother = Negative (3-5-). 10-9-20.
Child = Negative (3-5-). 10-9-20.

3rd Preg. Married. Age 24.
L.P. 3-11-19. Admitted 6-9-20 - Contracted Pelvis. Cough and spit for 14 days before admission - rales and ronchii all over chest. Child born alive 7-9-20, male, weight 8¼ lbs. P.P.H. Lacerations stitched. Dismissed 17-9-20, weight 8 lbs.
Child died on 23-1-21 of 'Gastritis".
Prev. Pregs.- 1st = F.T., alive, CH.clz. & Instrs.: 2nd = F.T., alive, spontaneous delivery.

67. W.R. Mother = Negative (3-5-). 10-9-20.

1st Preg. Married. Age 27.
L.P. Decr., 1919. Normal pregnancy and labour - child born alive 8-9-20, male, weight 8½ lbs. Dismissed 17-9-20, weight 8½ lbs.
26-11-21 - Child aged 14 months - a very healthy child.

68. W.R. Mother = Str. Positive (3+5+). 10-9-20.
Child = Str. Positive (3+5+). 10-9-20.

2nd Preg. Single. Age 26.
L.P. Novr., 1919. Contracted Pelvis (Diag. Conj. = 4¼", True Conj. = 3½"). Patient was allowed to go on as long as possible in second stage. Head did not mould well but became fixed in brim. Forceps applied unsuccessfully. Craniotomy. P.M. exam.
Prev. Preg.- F.T., CH.clz. & Instrs., S.B.

Case No:

69. W.R. Mother = Negative (3-5-). 10-9-20.

3rd Preg. Married. Age 31.
L.P. end Decr., 1919. Admitted 6-9-20 - small rickety woman. Contracted Pelvis. Caesarean section - child born alive 6-9-20, male, weight 6 lbs. Patient was sterilised. Dismissed 24-9-20, weight 6 lbs.
W.R. Mother = Negative (3-5-). 14-1-22.
Child = Negative (3-5-). 14-1-22.
21-2-22 - Both well - child now 17 months old.
Prev. Pregs.- 1st = Induction at 8 months, forceps, live child: 2nd = Induction at 8 months, spontaneous delivery, child born alive but died soon after birth.

70. W.R. Mother = Negative (3-5-). 10-9-20.

5th Preg. Married. Age 30.
L.P. 5-7-20. Admitted 7-9-20 - Incomplete Abortion - Curettage. Began to bleed one week before admission. Bleeding continued - some clots passed. Small piece of decidua at fundus. Slight thickening of both tubes.
Prev. Pregs.- All normal.

71. W.R. Mother = Negative (3-5-). 10-9-20.
Child = Negative (3-5-). 10-9-20.

1st Preg. Married. Age 17.
L.P. Novr., 1919. Normal pregnancy and labour - child born alive 7-9-20 - male, weight 7½ lbs. Dismissed 16-9-20, weight 7 lbs.
No further trace.

Case No.

72. W.R. Mother = Negative (3-5-). 10-9-20.

1st Preg. Married. Age 31.
L.P. end Decr., 1919. Admitted to Antenatal Dept. 3-9-20. Contracted Pelvis: Haematemesis: Pain in epigastrium morning of admission. Haematemesis for two days previously. Morning sickness severe in earlier months - occasional attacks of vomiting throughout rest of pregnancy. Child born alive 20-9-20 - male, weight 6 lbs. 10 ozs. Dismissed 30-9-20, weight 6¼ lbs.
20-2-22 - Child was known to be alive and well when at the age of 17 months: no illness.

73. W.R. Mother = Negative (3-5-). 10-9-20.

1st Preg. Single. Age 15.
L.P. 27-12-19. Admitted to Antenatal Dept. 3-9-20 - Albuminuria. Swelling of legs for two weeks: no headache or dizziness: trace of albumen. Dismissed 11-9-20. Readmitted 15-10-20 - marked oedema: no headache or epigastric pain: vision good. Cloud of albumen in urine. Heart sounds good. History of occasional dyspnoea. Forceps delivery: R.P. Had an eclamptic fit about an hour before delivery. Some P.P.H. Child born dead 20-10-20, female, weight 9½ lbs.
21-10-20 - Mother became worse, was dazed and very restless but no fits - looked like uraemia. Perineal tear very septic. Died on 22-10-20 - P.M. exam.

74. W.R. Mother = Negative (3-5-). 17-9-20.
Child = Negative (3-5-). 17-9-20.

1st Preg. Married. Age 26.
L.P. Decr., 1919. Normal pregnancy and labour - Child born alive 8-9-20, weight 7¼ lbs. Dismissed 18-9-20, weight 6½ lbs.
No further trace.

Case No.

75. W.R. Mother = Negative (3-5-). 17-9-20.
Child = Negative (3-5-). 17-9-20.

1st Preg. Married. Age 24.
L.P. Decr., 1919. Admitted to Antenatal Dept. 8-9-20. Normal pregnancy and labour - child born alive 8-9-20, Female, weight 8½ lbs. Dismissed 17-9-20, weight 8½ lbs.
30-3-22 - Both mother and child well - child aged 18 months. W.R. Mother = Negative (3-5-).
Child = Negative (3-5-).

76. W.R. Mother = Negative (3-5-). 17-9-20.
Child = Negative (3-5-). 17-9-20.

2nd Preg. Single. Age 25.
L.P. Decr., 1919. Normal pregnancy and labour - child born alive 8-9-20, male, weight 7½ lbs. Dismissed 21-9-20, weight 7¾ lbs. Child has talipes varus and mother was advised to take him to R.H.S.C.
18-11-21 - Mother and child were in Merryflatts Hospital from Octr., 1920 - child still in at 18-11-21 (then 14 months old). Very ill with Whooping-cough and Measles.
7-3-22 - Baby now recovered - still attending R.H.S.C.
Prev. Preg. - Normal.

77. W.R. Mother = Strongly Positive (3+5+).10-9-20.

5th Preg. Married. Age 36.
L.P. 28-4-19. Admitted to Antenatal Dept. 3-9-20 - Threatened Abortion. Haemorrhage for several days before admission. Dismissed 16-9-20. Readmitted to Antenatal Dept. 11-4-21 - Not pregnant - Amenorrhoea from Septr., 1920 till bleeding began on 2nd and 3rd April. Mole suspected, but bleeding thought to be menstrual.
W.R. Mother = Strongly Positive (3+5+). 15-4-21.
15-4-21 - Attends Dispensary - "A" mixture.
Prev. Pregs.- all normal except for miscarriage between first and second child.

Case No.

78. W.R. Mother = Negative (3-5-). 17-9-20.
Child = Negative (3-5-). 1-10-20.

4th Preg. Married. Age 30.
Normal pregnancy and labour - child born alive 18-9-20, male, weight 8½ lbs. Dismissed 27-10-20, weight 8½ lbs.
28-3-22 - Child just had measles but now quite well - 18 months old.
W.R. Mother = Negative (3-5-). 28-3-22.
Child = Negative (3-5-). 28-3-22.
Prev. Pregs.- 1st = 6½ months: 2nd and 3rd = F.T., normal.

79. W.R. Mother = Negative (3-5-).

9th Preg. Married. Age 34.
L.P. 26-5-20. Admitted to Antenatal Dept. 8-9-20 - Threatened Abortion. Bleeding for two days before admission. Uterus about 3½ months size.
Prev. Pregs.- 1st - 4th = F.T., normal, alive, (Chloroform with first): 5th = Instrs., F.T., S.B.: 6th = seven months, S.B.: 7th and 8th = five months, S.B.

80. W.R. Mother = Negative (3-5-). 17-9-20.

3rd Preg. Married. Age 45.
L.P. 1-3-20. Admitted 6-9-20 - Fibroid uterus. Has had pain in abdomen for several days before admission - pain continuous but worse at times than at others. Bleeds easily on examination. Small fibroid in anterior wall of uterus - tender on pressure. Dismissed 16-9-20.
Prev. Pregs.- 1st = miscarriage at two months: 2nd = F.T., normal.

Case No.

81. W.R. Mother = Negative (3-5-). 17-9-20.

3rd Preg. Married. Age 23.
L.P. Decr., 1919. Transverse presentation - version. Difficulty with aftercoming head - child born dead, weight 7 lbs. R.P. P.M. exam.
Prev. Pregs.- 1st and 2nd = normal, F.T.

82. W.R. Mother = Negative (3-5-). 17-9-20.

10th Preg. Married. Age 38.
L.P. Jany., 1920. Marginal Placenta Praevia. Bipolar version - child born dead 8-9-20, female, weight 7 lbs. Mother had severe haemorrhage on day of admission (8-9-20) - was packed and sent to Hospital.
Prev. Pregs.- All normal.

83. W.R. Mother = Negative (3-5-). 17-9-20.

9th Preg. Married. Age 38.
L.P. 5-1-20. Marginal Placenta Praevia. Version. Began to bleed five hours before admission - packed and sent in to Hospital. Bipolar version- leg brought down - spontaneous delivery two hours later, male, stillborn, weight 6½ lbs. 7-9-20. Child was alive on admission. P.M. exam.
Prev. Pregs.- Chloroform & Instrs. 1st and 3rd: others normal.

Case No.

84. W.R. Mother = Negative (3-5-). 17-9-20.

2nd Preg. Married. Age 25.
L.P. Decr., 1920. Normal pregnancy and labour: R.P. Child born alive 8-9-20, female, weight 6½ lbs. Dismissed 17-9-20, weight 7 lbs. No further trace.
Prev. Preg.- Normal.

85. W.R. Mother = Negative (3-5-). 17-9-20.

5th Preg. Married. Age 30.
L.P. ?. Admitted Antenatal Dept. 9-9-20. Incomplete Abortion curettage.
Prev. Pregs.- No record.

86. W.R. Mother = Negative (3-5-). 17-9-20.

8th Preg. Married. Age 30.
L.P. 10-7-20. Admitted to Antenatal Dept. 11-9-20 - Hyperemesis gravidarum. No sickness except when on face. Two weeks before admission morning sickness began and later became more frequent. No food retained. Uterus retruverted - pessary inserted. Dismissed much improved 24-9-20. Readmitted 11-10-20. Since dismissal only occasional vomiting till four days before readmission when she began to vomit everything. Pessary removed: Put on rectal feeding: very nervous: no albumen or sugar in urine but acetone and diacetic acid present. Dismissed 27-10-20.
Prev. Pregs.- 1st = Abortion at two months+ 2nd = Premature, S.B. (6 months): 3rd = F.T., alive: 4th to 7th = F.T., alive. Vomiting in 5th pregnancy.

Case No.

87. W.R. Mother = Negative (3-5-). 17-9-20.

3rd Preg. Married. Age 23.
L.P. 9-7-20. Attended Antenatal Dispensary 10-9-20 - nervousness and constipation. Pelvis contracted at outlet: Uterus retroflexed. Child born in Hospital 2-3-21, dead, male, Footling, weight 3 lbs.
Prev. Pregs.- 1st = 2½ months miscarriage: 2nd = S.B. (7 months).

88. W.R. Mother = Negative (3-5-). 17-9-20.

7th Preg. Married. Age 31.
L.P. 4-2-20. Attended Antenatal Dispensary 10-9-20 - pain in back and abdomen: headache: constipation.
Prev. Pregs.- 1st to 6th = alive, F.T. (last in 1918). Operation for prolapse (successful) after 4th child born.

89. W.R. Mother = Negative (3-5-). 17-9-20.

6th Preg. Married. Age 36.
L.P. 25-6-20. Attended Antenatal Dispensary 10-9-20 - sickness and vomiting and abdominal pain. Confined at home - G.R.M.H. nurses - male child born alive 3-4-21.
14-1-22 - W.R. Mother = Negative (3-5-).
Child = Negative (3-5-).
18-2-22 - Child alive and well - never any illness.
Prev. Pregs.- 4 children born fulltime, alive (last three years ago). Had some bleeding at three months at last pregnancy: Twins at 8 months - one stillborn and one alive. Had operation for prolapse 10 years ago (not successful).

Case No.

90. W.R. Mother = Negative (3-5-). 17-9-20.

4th Preg. Married. Age 26.
L.P. middle April, 1920. Attended Antenatal Dispensary 10-9-20 - severe headaches and slight pain in left side. Vomiting.
Prev. Pregs.- 1st - 3rd = F.T., normal, alive. The first died at the age of 10½ months: the third was twins.

91. W.R. Mother = Negative (3-5-). 17-9-20.

1st Preg. Single. Age 22.
L.P. 12-5-20. Attended Antenatal Dispensary 10-9-20 - sickness, vomiting and abdominal pain. Normal pregnancy.

92. W.R. Mother = Negative (3-5-). 17-9-20.

2nd Preg. Married. Age 29.
L.P. 25-6-20. Attended Antenatal Dispensary 10-9-20 - varicose veins.
Prev. Preg.- Normal, F.T., alive (1915).

93. W.R. Mother = Negative (3-5-). 17-9-20.

1st Preg. Married. Age 20.
L.P. 5-4-20. Attended Antenatal Dispensary 10-9-20 - Contracted Pelvis. Confined at home 5-1-21, male, alive, F.T.

Case No.

94. W.R. Mother = Negative (3-5-). 24-9-20.
Child = Negative (3-5-). 17-9-20.

1st Preg. Single. Age 18.
History of vaginal discharge. Child born alive 10-9-20 - male, F.T., weight 7½ lbs.
Dismissed 20-9-20, weight 6¾ lbs.
20-2-22 - Child was alive and well when aged 17 months - no illness.

95. W.R. Mother = Negative (3-5-). 17-9-20.
Child = Negative (3-5-). 17-9-20.

10th Preg. Married. Age ?.
L.P. Decr., 1919. Admitted 10-9-20. Contracted pelvis: High forceps. Allowed to continue in labour to give time for head moulding. Head was engaged and firmly fixed in brim - easily brought down with forceps - Child born alive 11-9-20, female, weight 10 lbs.
Dismissed 23-9-20, weight 10 lbs.
31-3-22 - Both well. W.R. Mother = Neg. (3-5-).
Child = Neg. (3-5-).
Prev. Pregs.- 1st to 6th = Chloroform and Instrs., F.T., alive: 7th = F.T., spontaneous: 8th = forceps, S.B.: 9th ?.

96. W.R. Mother = Negative (3-5-). 17-9-20.

3rd Preg. Married. Age 31.
Complete miscarriage (B.B.A.) at 6 months.

Case No.

97. W.R. Mother = Negative (3-5-). 17-9-20.

2nd Preg. Married. Age 21.
L.P. Jany., 1920. Concealed accidental haemorrhage. Shivering followed by sharp abdominal pain at 12 p.m. on day of admission. Began to bleed externally and soon became collapsed - continuous abdominal pain not like labour pain. On admission uterus tense and tender: mo foetal parts palpable: os admitting two fingers - dilated to admit four fingers and membranes ruptured. One hour later os size of teacup. Two pints saline subcutaneously. Os dilated manually and child delivered with forceps. Uterus full of dark blood clot. Placenta removed manually and uterine cavity packed. Child born dead 3-9-20 - male, weight 5½ lbs. Mother dismissed 15-9-20.
Prev. Preg.- Twins (male and female) F.T., alive.

98. W.R. Mother = Negative (3-5-).

Not pregnant. Married. Age 30.
L.P. 23-8-20. Has pain in both iliac fossae - more on right - dragging in nature and worse after exercise. Yellowish discharge since last child born 29-2-20. Pains date from that time. Dismissed 13-9-20.
Prev. Pregs.- Has had four children - 1st = 7 months: 2nd = 7½ months: 3rd = 7¾ months: 4th = 5 months.

99. W.R. Mother = Negative (3-5-). 17-9-20.
Child = Negative (3-5-). 1-10-29.

1st Preg. Single. Age 23.
L.P. 15-12-19. Admitted to Antenatal Dept. 7-9-20 - Hyperemesis: Pendulous abdomen. Has had vomiting of varying severity every day since first month. Very little after admission. Dismissed 18-9-20. Readmitted 21-9-20 in labour. Forceps applied - child born alive, male, weight 8 lbs. Dismissed 4-10-20, weight 8½ lbs.
31-3-22 - Child aged 18 months - a very healthy child - had measles recently but now quite recovered. W.R. Mother = Neg. (3-5-).
Child = Neg. (3-5-).

Case No.

100. W.R. Mother = Negative (3-5-). 24-9-20.
Child = Negative (3-5-). 17-9-20.

4th Preg. Married. Age 35.
L.P. Decr., 1919. Normal pregnancy and labour. Child born alive 16-9-20 - female, weight 7½ lbs. Dismissed 25-9-20, weight 7 lbs.
18-11-21 - Neither mother nor child very well.
11-2-22 - Baby's digestion not good. When she was six months old had a cough and vaccination postponed till nine months. Also had sore throat about one week after vaccination. Since birth has pain when passes urine and always very constipated.
Prev. Pregs.- All normal.

101. W.R. Mother = Negative (3-5-). 1-10-20.
Child = Negative (3-5-). 17-9-20.

4th Preg. Married. Age 36.
L.P. Decr., 1919. Marginal Placenta Praevia. Bleeding for two days before admission - packed. Spontaneous delivery - child born alive 13-9-20, male, weight 5¼ lbs. Dismissed 24-9-20, weight 5 lbs.
The child died of pneumonia on 29-10-20.
Prev. Pregs.- All normal.

102. W.R. Mother = Negative (3-5-). 17-9-20.

1st Preg. Married. Age 22.
L.P. 24-12-19. Normal pregnancy and labour. R.P. Child born alive 9-9-20, male, weight 6¾ lbs. Dismissed 18-9-20, weight 5½ lbs.
4-2-22 - Child had congestion of lungs when about six months old but now very healthy - aged 17 months.

Case No.

103. W.R. Mother = Negative (3-5-). 17-9-20.
Child = Negative (3-5-). 17-9-20.

2nd Preg. Married. Age 23.
L.P. Decr., 1919. Normal pregnancy and labour - Child born alive 15-9-20 - female, weight 7½ lbs. Dismissed 24-9-20, weight 6½ lbs. No further trace.
Prev. Preg.- Normal, F.T.

104. W.R. Mother = Negative (3-5-). 17-9-20.

3rd Preg. Married. Age 35.
L.P. end Decr., 1919. Admitted 13-9-20 - Impacted Breech - os not fully dilated on admission. Allowed to go on till breech further down, then under chloroform a leg was brought down and child was delivered - some difficulty in pulling arms down but child was born alive, female, weight 8½ lbs. Dismissed 24-9-20, weight 8½ lbs.
22-2-22 - Child alive and well - just recovered from measles.
Prev. Pregs.- Normal except for slight difficulty in second stage from contracted outlet.

105. W.R. Mother = Negative (3-5-). 17-9-20.

1st Preg. Single. Age 30.
Normal pregnancy and labour. Child born alive 10-9-20, male, weight 7½ lbs. Dismissed 23-9-20. Baby was known to be well when at the age of two months - no further trace.

Case No.

106. W.R. Mother = Negative (3-5-). 17-9-20.

4th Preg. Married. Age 24.
Admitted 13-9-20. Os fully dilated on admission, meconium being expelled. Contracted outlet - Forceps - child born alive 13-9-20, male, weight 8¼ lbs. Dismissed 24-9-20, weight 9 lbs.
No further trace.
Prev. Pregs.- 1st and 2nd = spontaneous delivery: 3rd = Forceps.

107. W.R. Mother = Negative (3-5-). 17-9-20.

4th Preg. Married. Age 38.
L.P. Decr., 1919. Normal pregnancy and labour - child born alive 10-9-20 - male, weight 7½ lbs. Dismissed 20-9-20, weight 7¾ lbs.
18-11-21 - Child was known to be alive and well when at the age of 14 months - no illness.
Prev. Pregs.- Normal.

108. W.R. Mother = Negative (3-5-). 17-9-20.

1st Preg. Married. Age 31.
Normal pregnancy and labour - child born alive 12-9-20, female, weight 8½ lbs. Uterine inertia: Forceps: R.P. Dismissed 24-9-20, weight 7¼ lbs.
Mother and child attended Dispensary when child was 16 months old - child had gastro-enteritis (4 days duration) three weeks before. Started to walk at 14 months. Mother was in Blawarthill Sanatorium, Clydebank during January, Feby. and March, 1921 - affection of right lung. Now has no cough and feels much better. At present is two months pregnant.

Case No.

109. W.R. Mother = Negative (3-5-). 17-9-20.

1st Preg. Married. Age 34.
L.P. Decr., 1919. Admitted 13-9-20. Doctor outside had applied forceps but failed to deliver. On admission the head was ballotting above the brim and a bag of unruptured membranes was still present. Contracted Pelvis - Caesarean section - child born alive 13-9-20, female, weight 7 lbs. 6 ozs. Dismissed 25-10-20, weight 6¾ lbs.
17-2-22 - Child now aged 17 months - never any illness.

110. W.R. Mother = Negative (3-5-). 17-9-20.

8th Preg. Married. Age 35.
L.P. 8-12-19. Admitted in labour 13-9-20. Pendulous abdomen: Contracted Pelvis. Little progress by morning after admission - forceps applied - child born alive 14-9-20, male, weight 7¼ lbs. Dismissed 24-9-20, weight 8 lbs.
20-2-22 - Child died 26-12-21 of pneumonia.
Prev. Pregs.- All normal.

111. W.R. Mother = Doubt. Negative (3+-5-C-). 17-9-20.

13th Preg. Married. Age 40.
L.P. Decr., 1918. Admitted 15-9-20. Retained twin. Transverse presentation - version. First child = vertex - delivered five hours before birth of second and several hours before admission: Second child, lying transversely - right shoulder presenting - version under chloroform - child delivered as a breech. Good deal of P.P.H. Dismissed alive 6-10-20 - weight of first twin = 8¼ lbs. weight of second = 7½ lbs.
20-2-22 - Both alive and well - now 16 months old: Both had pneumonia and were very ill but made a good recovery.
Prev. Pregs.- All normal except last which was stillborn and two miscarriages at 2 and 4 months respectively.

Case No.

112. W.R. Mother = Negative (3-5-). 17-9-20.

2nd Preg. Married. Age 30.
L.P. June, 1920. Incomplete Abortion - curettage. Admitted 16-9-20. Blleding followed dance - bled for one week then pain began and small foetus was passed. Still bleeding on admission - curetted.
Prev. Preg.- F.T., normal (1915).

113. W.R. Mother = Negative (3-5-). 24-9-20.
Mother = Negative (3-5-). 1-12-20.

1st Preg. Married. Age 29.
L.P. 3-3-20. Attended Antenatal Dispensary 17-9-20 - nervousness. Had rickets in childhood - did not walk till she was 3½ years old. Had rheumatism in childhood: nervousness and melancholia in adult life (following blow on head 15 years ago). Child born in hospital 29-11-20, alive, female, weight 7½ lbs. (induced labour). Dismissed 8-12-20, weight 7 lbs. No further trace.

114. W.R. Mother = Negative (3-5-). 24-9-20.

7th Preg. Married.
L.P. end March, 1920. Attended Antenatal Dispensary 17-9-20. Contracted Pelvis (Diag. Conj. = 4¼", True Conj. = 3½").
Prev. Pregs.- 1st to 4th = alive, F.T.: 5th and 6th = S.B., F.T. (last in June, 1919).

115. W.R. Mother = Negative (3-5-). 24-9-20.

2nd Preg. Married. Age 27.
L.P. 28-6-20. Admitted 16-9-20 - . Had slight haemorrhage on 6-9-20 and has been bleeding off and on since. Severe bleeding morning of admission. Uterus cleared out - curetted.
Prev. Preg.- normal (1919).

Case No.

116. W.R. Mother = Negative (3-5-). 24-9-20.

3rd Preg. Married. Age 34.
L.P. July, 1920. Admitted 11-9-20 - Incomplete Abortion. Bleeding at intervals for three weeks before admission.
Prev. Pregs.- 1st = normal: 2nd = chloroform and forceps (1913).

117. W.R. Mother = Strongly Positive (3+5+). 24-9-20.

11th Preg. Married. Age 39.
L.P. 28-5-20. Admitted to Antenatal Dept. 9-9-20. Was well till three days before admission when bleeding began and continued - said to have been brought on by lifting heavy weights. Inevitable miscarriage (induced). Uterus emptied and packed. Brisk P.P.H.
Prev. Pregs.- 1st to 6th = F.T., alive: 7th = premature, alive (7 months): 8th = premature (7 months) lived three days: 9th = F.T., S.B.: 10th = premature (7½ months) alive.

118. W.R. Mother = Negative (3-5-). 24-9-20.

1st Preg. Married. Age 27.
L.P. 8-6-20. Admitted 16-9-20. Was well till ten days before admission when abdominal pain began with retention of urine -. Examined under chloroform outside - distended bladder and retroverted uterus found. Catheterised and uterus replaced. Has had intermittent abdominal pain since then. Rigor and haemorrhage on admission. Widal negative. Septic abortion diagnosed. Uterus emptied and curetted.

Case No.

119. W.R. Mother = Negative (3-5-). 24-9-20.

1st Preg. Married. Age 34.
L.P. 11-11-19. Admitted Antenatal Dept. 31-8-20. Contracted Pelvis. Caesarean section - child born alive 2-9-20, male, weight 9 lbs. Dismissed 22-9-20, weight 8½ lbs. Child was known to be alive when aged 15 months. Had very acute bronchitis in Decr., 1920. Had 'eczema' of scalp for six months after leaving hospital. Mother has been quite well.

120. W.R. Mother = Negative (3-5-). 24-9-20.

1st Preg. Single. Age 18.
L.P. Decr., 1919. Child born alive 9-9-20, male, weight 8¼ lbs. Dismissed 22-9-20, weight 8 lbs.
No further trace.

121. W.R. Mother = Negative (3-5-). 24-9-20.

3rd Preg. Married. Age 38.
Normal pregnancy. Sapraemia. I.U.D. Generalised rales in chest. Foul lochia. Gonococcus found. Child born alive 5-9-20, male, weight 7 lbs. Dismissed 27-9-20, weight 6 lbs.
18-11-21 - Child was well when aged 14 months.
7-2-22 - Child died of double pneumonia on 20-1-22.
Prev. Pregs.- 1st and 2nd = normal: 3rd = some haemorrhage at 3rd month.

122. W.R. Mother = Negative (3-5-). 24-9-20.

8th Preg. Married. Age 40.
L.P. end June, 1920. Began to bleed night before admission on 16-9-20 - bleeding worse day of admission. Sent in as Incomplete Abortion - diagnosed as Metrorrhagia. Curetted - nothing found in uterus.
Prev. Pregs.- All normal.

Case No.

123. W.R. Mother = Negative (3-5-). 24-9-20.

6th Preg. Married. Age 32.
L.P. 15-12-19. Admitted 9-9-20. Concealed Accidental Haemorrhage. Pains began morning of admission but were not like true labour pains - bleeding began at 1 p.m. Uterus tense and tender: patient collapsed and exsanguinated - transfused, etc. Packed. Forceps applied - child born dead 9-9-20, female, weight 5 lbs. Mother dismissed 20-9-20.
Prev. Pregs.- 1st to 3rd = normal: 4th and 5th = Forceps.

124. W.R. Mother = Negative (3-5-). 24-9-20.

1st Preg. Married. Age 21.
L.P. 21-12-19. Admitted to Antenatal Dept. 14-9-20. Normal till July when in Hospital with Pyelitis and in again in August with false labour pains. For two months before admission has been vomiting daily and during last fourteen days gradual loss of power in legs. Bladder washed out, etc. Urine (catheter spec.) contains Coliform bacillus, Staphylococcus and Streptococcus. Temperature. Left Hospital against advice on 4-10-20.

125. W.R. Mother = Negative (3-5-). 24-9-20.

7th Preg. Married. Age 38.
L.P. middle July, 1920. Admitted 14-9-20 - Hyperemesis gravidarum. About three weeks before admission sickness began - vomiting all day. No response to treatment outside. Some ptosis of stomach. Improved greatly on treatment after admission. Urine contained acetone and diacetic acid but no albumen or sugar. History of chronic rheumatism of hands and arms. Dismissed 27-9-20.
Prev. Pregs.- 1st to 3rd = F.T., normal: 4th = miscarriage at two months: 5th = miscarriage at five months (1916): 6th = F.T., normal (1917). Much sickness in all pregnancies.

Case No.

126. W.R. Mother = Strong. Positive (3+5+). 1-10-20.
Child = Negative (3-5-). 24-9-20.

3rd Preg. Single. Age 32.
Normal pregnancy and labour - child born alive 17-9-20, female, weight 7½ lbs. Dismissed 27-9-20, weight 7½ lbs.
18-11-21 - Child alive and well - aged 14 months: mother also well - no treatment.
16-2-22 - Child died 5-2-22 - double pneumonia: mother does not look well.
Prev. Pregs.- Normal.

127. W.R. Mother = Negative (3-5-). 24-9-20.

2nd Preg. Married. Age 36.
L.P. March, 1920. Admitted 17-9-20 - Placenta Praevia. Some haemorrhage on evening of admission. Under chloroform os dilated and membranes ruptured - version attempted unsuccessfully. Vagina packed - twenty-four hours later cervix incised (had not dilated well) and child delivered - stillborn, premature (6½ months).
Prev. Preg.- Normal.

128. W.R. Mother = Negative (3-5-). 24-9-20.

8th Preg. Married. Age 34.
L.P. end April, 1920. Admitted 12-9-20 - Threatened Abortion. Some haemorrhage day of admission - uterus about five months size - os closed. Dismissed 23-9-20.
Prev. Pregs.- All normal except one which was stillborn, premature (7 months).

129. W.R. Mother = Negative (3-5-). 24-9-20.

6th Preg. Married. Age 31.
L.P. Amenorrhoea since birth of last child (Aug., 1919) till 25th Jnay., 1920 - no menstruation since. Admitted to Antenatal Dept. 17-9-20. Threatened Abortion. Had bleeding evening of admission. Uterus about five months size - os closed. Dismissed 21-9-20.
Prev. Pregs.- All F.T., spon. except last (Chloroform & Instrs.).

Case No.

130. W.R. Mother = Negative (3-5-). 24-9-20.

1st Preg. Married. Age 28.
L.P. end Feby., 1920. Admitted 13-9-20 - Eclampsia. History of eight fits before admission. Admitted in coma: face puffy: oedema of legs. In spite of treatment continued to take fits at frequent intervals - Bougies inserted. Uterine contents removed 14-9-20. Rapid recovery. Child born dead 14-9-20, female, macerated, weight 5 lbs. Mother dismissed 1-10-20.

131. W.R. Mother = Negative (3-5-). 24-9-20.

1st Preg. Married. Age 19.
Contracted Pelvis. Failed forceps before admission. Os fully dilated, head in cavity of pelvis, large caput. Probably masculine type of pelvis (no other deformity) with greatest contraction at outlet. Forceps - child born dead 15-9-20 - male, weight 6¾ lbs. In spite of prolonged efforts to resuscitate it child would only give a few spasmodic gasps. P.M. exam.

132. W.R. Mother = Negative (3-5-). 17-9-20.
Child = Negative (3-5-). 17-9-20.

4th Preg. Married. Age 23.
L.P. Decr., 1919. Child born alive 16-9-20 - female, weight 7½ lbs. Dismissed 25-9-20, weight 6¾ lbs.
Child died in Belvidere Hospital on 21-5-21 - broncho-pneumonia.
Prev. Pregs.- No record.

Case No.

133. W.R. Mother = Negative (3-5-). 24-9-20.
Child = Negative (3-5-). 17-9-20.

3rd Preg. Married. Age 25.
L.P. 12-4-20. Antepartum Haemorrhage. Uterus about six months size. Admitted 13-9-20 - had some bleeding seven days before which continued at irregular intervals. Child born dead 14-9-20, premature, female, weight 2¼ lbs. P.M. exam.
Prev. Pregs.- 1st and 2nd = normal.

134. W.R. Mother = Negative (3-5-). 17-9-20.
Child = Negative (3-5-). 17-9-20.

7th Preg. Married. Age 42.
L.P. end Decr., 1919. Admitted 15-9-20 - Lateral Placenta Praevia - had lost about a pint of blood. Os admitted two fingers - sausage shaped bag of membranes. When os dilated to four fingers membranes were ruptured - binder and pituitrin. Spontaneous delivery 1½ hours later - child born alive, male, weight 6½ lbs. Dismissed 24-9-20, weight 6¼ lbs. Child died when about two months old.
Prev. Pregs.- normal, F.T. - all alive.

135. W.R. Mother = Negative (3-5-). 24-9-20.

2nd Preg. Married. Age 43.
L.P. Feby., 1920. Admitted to Antenatal Dept. 10-9-20 - Eclampsia. Headache, dizziness and weakness of one arm for some time before admission. Two fits on day of admission: Albumen abundant. On second day after admission had two fits and went into labour - child born dead 13-9-20, male, weight 4½ lbs. Foetal heart was not heard twenty-four hours after admission though present on admission. Mother's face puffy: oedema of ankles. Child slightly macerated.
Prev. Preg.- F.T., normal.

Case No.

136. W.R. Mother = Negative (3-5-). 24-9-20.

1st Preg. Married. Age 26.
L.P. 25-12-19. Breech with Hydrocephalic after-coming head perforated. When os was fully dilated patient was put under chloroform and breech delivered as far as umbilicus - great difficulty in bringing down arms. Head perforated and was delivered easily. Chil born dead 12-9-20 - female, weight 5¼ lbs. P.M. exam.

137. W.R. Mother = Negative (3-5-). 24-9-20.

3rd Preg. Married. Age 25.
L.P. 17-6-20. Admitted to Antenatal Dept. 17-9-20. Hyperemesis gravidarum. Began to have sickness about fourteen days after last period. It became worse and patient was confined to bed for eight weeks - on fluids only. On admission tongue furred, breath foul, pulse 134. 1-10-20 - sickness getting worse, uterus emptied - twin foetuses removed and uterus explored and douched. Definite hydramnios. Uterus about 2½ months size: external os open. Uterus anteflexed.
Prev. Pregs.- 1st = miscarriage at two months - a little sickness during this pregnancy: 2nd = miscarriage at 6½ months - severe sickness during this pregnancy.

138. W.R. Mother = Negative (3-5-). 24-9-20.

5th Preg. Married. Age 30.
L.P. 26-5-20. Admitted 10-9-20 - Incomplete Miscarriage - curettage. Threatened to abort for three weeks before admission - bleeding all the time. Twin foetuses about three months size expelled three days before admission. Placenta did not come away. On admission patient pale and blanched: os admitting one finger: placenta palpable. Uterus explored and curetted. Placental site extended nearly all over uterine surface and placenta was extremely adherent.
Prev. Pregs.- All alive, F.T., Ch.clz. & forceps - cervix and perineum torn badly.

Case No.

139. W.R. Mother = Negative (3-5-). 24-9-20.

6th Preg. Married. Age 30.
L.P. 27-3-20. Admitted to Antenatal Dept. 15-9-20. Mitral Stenosis. Cough, dyspnoea since she became pregnant - much worse for three weeks before admission. One bad attack of cardiac asthma three weeks before admission. On admission some oedema of both legs: pre-systolic murmur: bronchitis. Uterus 6½ to 7 months size. History of scarlet fever when seven years of age. Dismissed 29-9-20.
Prev. Pregs.- 1st to 5th = normal, F.T., but dyspnoea bad during last two pregnancies.

140. W.R. Mother = Negative (3-5-). 24-9-20.

2nd Preg. Married. Age 34.
L.P. seven months before admission to Hospital. Admitted to Antenatal Dept. 15-9-20 - Eclampsia. Was on strict eclamptic treatment outside and was responding well. Two fits before admission. Treatment continued after admission. Haze of albumen in urine. Mastitis right breast: some oedema of ankles. 17-9-20 - Urine clear: breast cleared up: Foetus alive. Dismissed 23-9-20.
Prev. Preg.- difficult labour - Chloroform and Instruments - child alive.

141. W.R. Mother = Negative (3-5-). 24-9-20.

9th Preg. Married. Age 39.
L.P. 26-6-20. Incomplete abortion. Bleeding started 14-9-20 and passed several large clots. Some pain during the night. On admission os admitted two fingers : placenta palpable. Uterus explored and curetted.
Prev. Pregs.- Normal, F.T.

Case No.

142. W.R. Mother = Negative (3-5-). 11-2-21.

1st Preg. Married. Age 24.
L.P. April, 1920. Admitted 9-2-21 in labour. Face presentation: prolapsed cord. Forceps - child born dead 9-2-21, male, mature, weight 7½ lbs. Dismissed 26-2-21.

143. W.R. Mother = Str. Positive (3+5+). 24-9-20.
Mother = Str. Positive (3+5+). 1-10-20.

7th Preg. Married. Age 38.
Uterus six and a half months to seven months size on admission. Sent in as eclampsia but diagnosed hysteria. One fit evening of admission. No albuminuria. Dismissed undelivered 5-10-20. Child born in Merryflatts Hospital on 30-10-20 - was admitted there 6-10-20. Dismissed 18-1-21. No trace at old address after dismissal from Merryflatts.
Prev. Pregs.- 1st and 2nd = alive, F.T.: 3rd, 4th and 5th = F.T., S.B.: 6th = F.T., normal.

144. W.R. Mother = Negative (3-5-). 24-9-20.

5th Preg. Single. Age 30.
B.B.A. Delivered on district. Placenta Praevia: Torn cervix repaired.

145. W.R. Mother = Negative (3-5-). 1-10-20.

1st Preg. Single. Age 29.
L.P. beginning of Jany., 1919. Admitted 17-9-20 - Albuminuria. No headache or dizziness: swelling of legs and abdominal wall for three weeks. On admission legs very oedematous, face puffy and abdominal wall markedly swollen. Urine solid on boiling. When os fully dilated forceps applied. Episiotomy. Child born alive 17-9-20 - male, weight 7½ lbs. Dismissed 4-10-20, weight 5 lbs.
Child died 21-10-21 (aged 13 months) - cause of death unknown to mother.

Case No.

146. W.R. Mother = Negative (3-5-). 1-10-20.

1st Preg. Single. Age 20.
Breech: Contracted Pelvis (Diag. Conj. = 4¼", True Conj. = 3½"). On admission breech engaged in brim - allowed to go on. Membranes ruptured thirty-six hours before admission and legs extended. Breech allowed to descend till buttocks at vulva. Delivered under chloroform - arms extended. Vaginal lacerations and ruptured perineum. Child born alive 21-9-20, male, weight 8 lbs. 10 ozs. Dismissed 4-10-20, weight 8 lbs.
20-2-22 - Child aged 17 months - had serious illness but now well.

147. W.R. Mother = Negative (3-5-). 1-10-20.

1st Preg. Single.
Normal pregnancy and labour. Child born alive 17-9-20 - female, weight 7½ lbs. Dismissed 25-9-20, weight 7¼ lbs.
Child was known to be alive and well when at the age of 7 months - no further trace.

148. W.R. Mother = Negative (3-5-). 1-10-20.

L.P. ? Membranes ruptured two days before admission. Foul vaginal discharge - child born dead 14-9-20, female, macerated, weight 5½ lbs. Mother died 2-10-20 - Sepsis.

Case No.

149. W.R. Mother = Negative (3-5-). 1-10-20.
Child = Negative (3-5-). 24-9-20.

3rd Preg. Married. Age 24.
Normal pregnancy and labour. Child born alive 18-9-20, male, weight 10 lbs. Dismissed 27-9-20, weight 8 lbs. Mother had warts on perineum and round vaginal orifice.
21-2-22 - Child was known to be alive and well when at the age of 17 months.
Prev. Pregs.- No record.

150. W.R. Mother = Negative (3-5-). 1-10-20.

4th Preg. Married. Age 26.
L.P. 28-6-20. Incomplete Abortion - curettage. Began to bleed four days before admission - worse on night of admission (20-9-20). Vagina packed and patient sent in to Hospital. Uterus explored and piece of adherent placenta removed.
Prev. Pregs.- No record.

151. W.R. Mother = Negative (3-5-). 1-10-20.

1st Preg. Married. Age 22.
L.P. 19-12-19. Contracted Pelvis (Diag. Conj. = 4 1/8", True Conj. = 3 3/8"). Child born alive 25-9-20, female, weight 7 3/4 lbs. Dismissed 2-10-20, weight 8 1/2 lbs.
Child died on 1-1-21 - pneumonia and thrush throat.

Case No.

152. W.R. Mother = Str. Positive (3+5+). 1-10-20.
Child = Str. Positive (3+5+). 1-10-20.

1st Preg. Single. Age 22.
L.P. end Feby., 1920.
Normal pregnancy and labour. Child born dead 22-9-20, macerated, male, premature, weight 2 lbs. 14 ozs. Membranes ragged. P.M. exam.

153. W.R. Mother = Negative (3-5-). 1-10-20.
Child = Negative (3-5-). 1-10-20.

2nd Preg. Single. Age 27.
L.P. Feby., 1920. Cord prolapsed on admission, membranes had ruptured twelve hours before admission - arm presenting, foot brought down with difficulty. Child born dead 23-9-20 - female, premature, weight 4 lbs. 13 ozs.
Prev. Preg.- F.T., alive, normal.

154. W.R. Mother = Negative (3-5-). 1-10-20.

5th Preg. Married. Age 34.
Failed forceps outside: cord prolapsed and patient exhausted on admission. Forceps delivery again attempted but failed. Craniotomy - persistent occipito-posterior with large caput (23-9-20). P.M. exam.
Prev. Pregs.- All normal (last in 1915).

155. W.R. Mother = Negative (3-5-). 1-10-20.

11th Preg. Married. Age 38.
L.P. 31-12-19. Central Placenta Praevia. Admitted 21-9-20 - had some bleeding three weeks before - began to bleed again day of admission. Central Placenta Praevia - packed - version on admission. Spontaneous delivery 23-9-20, child dead, female, weight 7 lbs. Membranes and placenta ragged. Septic puerperium.
Prev. Pregs.- No record.

Case No.

156. W.R. Mother = Negative (3-5-). 1-10-20.

1st Preg. Married. Age 31.
L.P. 6-6-20. Abortion. Admitted to Antenatal Dept. 21-9-20. Abdominal pain with haemorrhage began two weeks before admission and continued until admission though pain grew less. Bleeding continued steadily but in small amount a daily diminishing. On admission patient pale and anaemic but almost no bleeding. Cervix soft and large: uterus hard and retroverted: discharge from cervix. Cervix was dilated and decidual tissue removed from canal. Ulcerating growth on right side of cervix - curetted. Dismissed 29-9-20.
L.P. 14-10-20. Readmitted to Antenatal Dept. 31-1-21 - sent as Threatened Abortion. History of difficult micturition for one month and slight bleeding before admission. Found to have non gravid retroflexed uterus. Dismissed 6-2-21. Albumen present - had to be catheterised.

157. W.R. Mother = Negative (3-5-). 1-10-20.

5th Preg. Married. Age 32.
L.P. 5-6-20. Incomplete Abortion. Admitted 19-9-20 - bleeding at intervals for fourteen days - passed much clot and some other substance. Very stout woman - os dilated to admit one finger - small piece of decidua removed. Uterus swabbed out with iodine. History of cerebral haemorrhage five years ago- loss of speech - paralysis of right arm.
Prev. Pregs.- normal.

158. W.R. Mother = Negative (3-5-).

5th Preg. Married. Age 31.
L.P. 21-7-20. Incomplete Abortion. Admitted 18-9-20. Began to bleed day of admission - bleeding continued. Uterus explored and some debris removed. History of three operations for carbuncle.
Prev. Pregs.- 1st - 3rd = normal (last in 1917): 4th = four months miscarriage (Feby., 1920).

Case No.

159. W.R. Mother = Negative (3-5-). 9-2-21.

2nd Preg. Married. Age 26.
L.P. April, 1920. Normal pregnancy. Failed forceps outside. Membranes ruptured 9½ hours before admission (labour began about 17 hours before admission). Head well fixed in pelvis but caught at outlet (narrow outlet). Child alive - large caput - forceps applied with difficulty - child dead on delivery - female, weight 9½ lbs. P.M. exam.
Prev. Preg.- Chloroform and Instrs. - living, (April, 1919).

160. W.R. Mother = Negative (3-5-). 1-10-20.

2nd Preg. Married. Age 39.
L.P. Decr., 1919. Contracted Pelvis (Diag. Conj. = 3¼", True Conj. = 2½"). Breech with prolapsed cord (born as far as umbilicus on admission). Child dead - perforation of aftercoming head. male, weight 7¼ lbs., born 22-9-20. P.M. exam.
Prev. Preg.- Failed forceps - ended in craniotomy.

161. W.R. Mother = Negative (3-5-). 1-10-20.

2nd Preg. Single. Age 20.
L.P. middle Novr., 1919. Breech - child born alive 23-9-20, male, mature, weight 8 lbs. Dismissed 2-10-20.
11-2-22 - Baby well - now aged 17 months - W.R. Child = Negative (3-5-).
Prev. Preg.- S.B., F.T., spontaneous.

Case No.

162. W.R. Mother = Negative (3-5-). 1-10-20.

1st Preg. Married. Age 29.
Forceps delivery before admission - male child. Adherent placenta. Patient almost pulseless on admission 22-9-20 - bleeding. Placenta removed manually and uterus contracted well. No further haemorrhage. Dismissed 5-10-20.
11-2-22 - Mother and child well - child aged 17 months - W.R. Mother = Neg. (3+5-).
Child = Neg. (3-5-).

163. W.R. Mother = Negative (3-5-). 1-10-20.

1st Preg. Single. Age 33.
L.P. Decr., 1919. Head remained on perineum for a long time. Forceps applied - child born alive 23-9-20, male, weight 7¾ lbs. R.P. Dismissed 4-10-20, weight 7 lbs. No further trace.

164. W.R. Mother = Negative (3-5-). 8-10-20.
Child = Negative (3-5-). 1-10-20.

1st Preg. Single. Age 26.
L.P. Decr., 1919. Normal pregnancy and labour. Child born alive 27-9-20, female, weight 8½ lbs. Dismissed 8-10-20, weight 8½ lbs. No further trace.

165. W.R. Mother = Negative (3+5-). 8-10-20.
Child = Negative (3-5-). 1-10-20.

1st Preg. Married. Age 22.
L.P. Decr., 1919. Hydramnios: Twins. Children born 26-9-20, both alive but feeble and premature - 1st a female, weight 3¾ lbs. - ascites and talipes rt. foot: 2nd a female, weight 2½ lbs. Both died. P.M. exam.

Case No.

166. W.R. Mother = Negative (3-5-). 8-10-20.
Child = Negative (3-5-). 1-10-20.

1st Preg. Single. Age 20.
L.P. Decr., 1919. Normal pregnancy and labour.
Child born alive 28-9-20, male, weight 7½ lbs.
Dismissed 7-10-20, weight 8 lbs.
No further trace.

167. W.R. Mother = Negative (3-5-). 1-10-20.

2nd Preg. Married. Age 31.
L.P. 18-2-20. Admitted to Antenatal Dept.
23-9-20 - Albuminuria. Began to have headache with dizziness and impaired vision ten days before admission. In June and July had slight haemorrhage. Legs were swollen for four weeks. Scanty urine - highly coloured. On admission oedema of legs present: no abdominal tenderness: uterine enlargement not large enough to correspond with last period. Mass (not like uterus) in right iliac fossa. Uterus found to be displaced to right and to be enlarged to just above umbilicus. Quickening felt in July. Marked albuminuria. Child born dead 26-9-20, premature, weight 3½ lbs.
Prev. Pregs.- normal, F.T. (10-11-19). No previous ilness.

168. W.R. Mother = Negative (3-5-). 1-10-20.

3rd Preg. Married. Age 25.
L.P. 20-5-20. Incomplete Abortion. Began to bleed night before admission - passed foetus day of admission (25-9-20). Bleeding continued. Uterus explored and placental tissue removed. Uterus swabbed with iodine.
Prev. Pregs.- normal, - last in 1918.

Case No.

169. W.R. Mother = Negative (3-5-). 1-10-20.

5th Preg. Married. Age 36.
L.P. ?. Marginal Placenta Praevia. Admitted 28-9-20 - not bleeding. Had some bleeding three weeks before admission - began again day of admission. Pale, but good pulse. Oedema. Began to bleed again some hours after admission. Os fully dilated - version. - shoulders could not be expelled. Perforated aftercoming head. Child born dead 25-9-20 - male, mature, weight 7 lbs.
Prev. Pregs.- normal, F.T.

170. W.R. Mother = Negative (3-5-). 1-10-20.

10th Preg. Married. Age 31.
L.P. June, 1920. Incomplete Abortion. Bleeding since 23-9-20. No pain. Admitted 25-9-20. Ovum delivered on admission. Uterus curetted and swabbed with iodine.
Prev. Pregs.- 1st - 5th = normal, F.T.: 6th = miscarriage at 3rd month: 7th = miscarriage at 7th month with A.P.H.: 8th = premature: 9th = 7 months miscarriage.

171. W.R. Mother = Negative (3-5-). 8-10-20.
Child = Negative (3-5-). 8-10-20.

2nd Preg. Married. Age 32.
L.P. 23-12-19. Normal pregnancy and labour. Pain in abdomen three weeks before delivery - child born alive 1-10-20, male, weight 9½ lbs. Dismissed 9-10-20, weight 9 lbs.
20-2-22 - Mother and child well - child now 16 months old.
Prev. Preg.- Normal - 12 years ago.

Case No.

172. W.R. Mother = Negative (3-5-). 8-10-20.
Child = Negative (3-5-). 8-10-20.

1st Preg. Married. Age 18.
L.P. 13-2-20. Admitted 29-9-20. Accidental Haemorrhage. Bleeding night of admission and was sick and vomited. Spontaneous delivery - child born dead, premature, male, weight 4½ lbs.

173. W.R. Mother = Negative (3-5-). 8-10-20.
Child = Negative (3-5-). 8-10-20.

1st Preg. Married. Age 24.
L.P. end Decr., 1919. Normal pregnancy and labour. Child born alive 1-10-20, weight 6½ lbs.
20-2-22 - Mother and child well - child 16 months old.

174. W.R. Mother = Negative (3-5-). 22-10-20.
Child = Negative (3-5-). 8-10-20.

3rd Preg. Married. Age 41.
L.P. ?. Placenta Praevia (marginal). Child born dead 30-9-20, female, weight 5½ lbs.
A.P.H. Douched and packed. Ragged placenta.
R.P. P.M. exam.
Prev. Pregs.- normal.

175. W.R. Mother = Negative (3-5-). 8-10-20.
Child = Negative (3-5-). 8-10-20.

1st Preg. Single. ? age.
L.P. end Decr., 1919. Normal pregnancy and labour. Child born alive 1-10-20, male, weight 7½ lbs. Dismissed 9-10-20, weight 7 lbs.
23-2-22 - Reported to be a very healthy child - never any illness - now 16 months old.

Case No.

176. W.R. Mother = Negative (3-5-). 15-10-20.
Child = Negative (3-5-). 8-10-20.

1st Preg. Married. Age 24.
L.P. 26-12-19. Normal pregnancy and labour. Child born alive 11-10-20, male, weight 6½ lbs. Dismissed 11-10-20, weight 6½ lbs. Mother had appendix removed two years ago.
9-3-22 - Child alive and well when 17 months old: mother also well.

177. W.R. Mother = Negative (3-5-). 8-10-20.
Child = Negative (3-5-).23-10-20.

1st Preg. Married. Age 25.
L.P. 10-1-20. Attended Antenatal Dispensary 1-10-20 - indigestion and constipation. Admitted to Hospital 18-10-20. Normal labour - child born alive 19-10-20, female, weight 6¼ lbs. Dismissed 28-10-20, weight 6½ lbs. Patient had operation for goitre when aged 16 years - has been well since.
26-2-22 - Child was known to be alive and well when about six months old - no further trace.

178. W.R. Mother = Strong. Positive (3+5+). 8-10-20.

2nd Preg. Single. Age 29.
L.P. Jany., 1920.
Attended Antenatal Dispensary 1-10-20 - spasmodic pain in back, vomiting, headache and giddiness. Admitted to Antenatal Dept. 1-10-20 - ? ectopic pregnancy - diagnosed as normal three months pregnancy but with distinct swelling in right fornix - probably inflammatory. Dismissed 9-10-20 - undelivered. Female child born in Duke St. Hospital on 5-4-21. Mother and child attended G.R.M.H. Dispensary on 4-2-22 (child then 10 months old): Both well. W.R. Mother = Str. Pos.
Child = Str. Pos.
Prev. Pregs.- F.T., alive (1916), CH.clz. & Instrs. History of general weakness and neuritis following influenza. Curetted in 1915 for dysmenorrhoea.

Case No.

179. W.R. Mother = Negative (3-5-). 8-10-20.

20th Preg. Married. Age 38.
L.P.1-7-20. Attended Antenatal Dispensary 1-10-20 - bleeding on day of visit and had pain in abdomen. Admitted to Hospital 17-11-20 - complete miscarriage (twins).
Prev. Pregs.- 9 F.T. (4 still alive): 5 premature births (2 at 8 months, 2 at 7 months and 1 at 6 months): 5 early miscarriages (last pregnancy was a 5 months miscarriage - March, 1920).

180. W.R. Mother = Negative (3-5-). 8-10-20.

12th Preg. Married. Age 36.
L.P. end Decr., 1919.
Attended Antenatal Dispensary 1-10-20 - uterus not more than three months size. To report again in one month but did not return.
Prev. Pregs.- 8 = F.T., living: ? other pregs.

181. W.R. Mother = Negative (3-5-). 8-10-20.

5th Preg. Married. Age 26.
L.P. April, 1920. Attended Antenatal Dispensary 1-10-20 - pain in back. Uterus seven months size. Cervix eroded and glandular.
Prev. Pregs.- 1st and 2nd = F.T., normal, alive: 3rd = miscarriage at four months: 4th = premature at seven months.

Case No.

182. W.R. Mother = Negative (3-5-). 8-10-20.

3rd Preg. Married. Age 24.
L.P. end April, 1920. Attended Antenatal Disp. 1-10-20 - pain in back. Child born alive 21-1-21, female, weight 7½ lbs. Mother and baby well when baby aged two months but no further trace.
Prev. Pregs.- Normal, F.T., alive.

183. W.R. Mother = Negative (3-5-). 8-10-20.

4th Preg. Married. Age 25.
L.P. ?. Attended Antenatal Dispensary 1-10-20 - uterus eight months size. Incontinence of urine: pain in right side.
Prev. Pregs.- 1st and 2nd = normal, F.T., alive: 3rd = early miscarriage.

184. W.R. Mother = Negative (3-5-). 1-10-20.

13th Preg. Married. Age 28.
L.P. 10-9-20. Admitted to Antenatal Dept. 28-9-20. Persistent miscarriage. Pain in left side from pericardium to left iliac fossa. Nothing characteristic in its mode of onset or its duration. Small cystocoele and rectocoele - badly lacerated cervix eroded bilaterally. Uterus small: retroflexed and anteflexed - utero sacral ligaments tense and tender - ovaries normal.
Prev. Pregs.- 1st = F.T., alive: 2nd = 2½ months miscarriage: 3rd = F.T., alive: 4th = F.T., alive: 5th - 9th = miscarriages at 2½ to 3 mos.: 10th = twins (8 months) alive: 11th = miscarriage at 4½ months: 12th = miscarriage at 6 weeks: 13th= miscarriage at 4½ months.

Case No.

185. W.R. Mother = Negative (3-5-). 8-10-20.
Child = Negative (3-5-). 8-10-20.

8th Preg. Single. Age 36.
L.P. 5-12-19. Admitted 1-10-20 in labour. Accidental Haemorrhage. Pregnancy was normal till bleeding began with onset of labour. Child born alive 2-10-20, male, weight 7½ lbs. Dismissed 11-10-20, weight 7 lbs. No further trace after dismissal.
Prev. Pregs.- All normal.

186. W.R. Mother = Negative (3-5-). 8-10-20.
Child = Negative (3-5-). 8-10-20.

1st Preg. Single. Age 20.
L.P. Jany., 1920. Normal pregnancy and labour: R.P. Child born alive 1-10-20, male, mature, weight 8¼ lbs. Dismissed 11-10-20.
11-2-22 - Both mother and child well - W.R. Mother = Negative (3-5-).

187. W.R. Mother = Negative (3-5-). 8-10-20.
Child = Negative (3-5-). 8-10-20.

1st Preg. Married. Age 28.
L.P. end Decr., 1919. Normal pregnancy and labour. Child born alive 2-10-20, female, weight 6 lbs. R.P. Dismissed 11-10-20. No further trace.

188. W.R. Mother = Negative (3-5-). 8-10-20.

10th Preg. Married. Age 38.
L.P. 17-7-20. Admitted 29-9-20. Incomplete Abortion. Bleeding began morning of admission. On admission patient still bleeding - os admitted one finger and remains of ovum palpable. Uterus explored and curetted.
Prev. Pregs.- 1st to 3rd = normal, F.T.: 4th and 5th = miscarriages at 5th and 6th months: 6th = F.T.: 7th = 7 months: 8th and 9th = F.T.

Case No.

189. W.R. Mother = Negative (3-5-). 8-10-20.

3rd Preg. Married. Age 42.
L.P. 17-2-20. Admitted 26-9-20 - Placenta Praevia. Began to bleed morning of admission - was packed and sent in. Os dilated - version - foot brought down. Child born dead 27-9-20 - female, premature, weight 3½ lbs.
Prev. Pregs.- 1st = 7 months, alive: 2nd = F.T., alive, normal.

190. W.R. Mother = Negative (3-5-). 9-10-20.
Child = Negative (3-5-). 9-10-20.

3rd Preg. Married. Age 37.
L.P. 22-12-20. Admitted 1-10-20 - Albuminuria: Slight oedema of legs. Not feeling well but nothing definite - complained of " heaviness" since July. Some headache. On admission distinct oedema of legs, trace of albumen in urine: headache: dimness of vision. Spontaneous delivery - child born alive 5-10-20, male, weight 8¾ lbs. Dismissed 15-10-20, weight 9 lbs.
25-11-21 - Child was known to be very well at 13 months old - never any illness. Mother has had headaches ever since confinement.
18-2-22 - Both well - W.R. Mother = Negative.
Child = Negative.
Prev. Pregs.- 1st = normal, F.T., Breech, Chloroform and Forceps: 2nd = 8 weeks abortion (8 years ago) - curetted.

191. W.R. Mother = Negative (3-5-). 8-10-20.

1st Preg. Married. Age 22.
L.P. March, 1920. Admitted to Antenatal Dept. 1-10-20 - Albuminuria. The pregnancy was normal till night before admission when had pain in right side with slight rise of temperature. On admission tenderness on pressure over right kidney. No pus in urine. Uterus seven months size. Urine clear on 4-10-20. Irregular dismissal 6-10-20.

Case No.

192. W.R. Mother = Negative (3-5-). 8-10-20.

1st Preg. Single. Age 29.
L.P. 5-12-19. Contracted Pelvis (Diag. Conj. = 3½" : True Conj. = 2¾" . Diag. Conj. taken from false promontory below true but nearer symphysis than true promontory = 3½"). Head freely movable. Marked overlapping. Meconium coming away before operation. Caesarean section 2-10-20 (child thought to be alive) - child born dead, male, weight 7½ lbs. P.M. exam.

193. W.R. Mother = Negative (3-5-). 8-10-20.

2nd Preg. Married. Age 31.
L.P. March, 1920. Admitted to Antenatal Dept. 27-9-20. Throughout pregnancy troubled with varicose veins. Swelling of legs for few days before admission. Dismissed 11-10-20 - uterus seven months size.
Prev. Preg.- Normal.

194. W.R. Mother = Negative (3-5-). 8-10-20.

1st Preg. Married. Age 28.
L.P. 15-12-19. Admitted 1-10-20 after thirty hours labour with retraction ring round neck clasping head. Forceps delivery - extensive tearing of fornices - child born dead 1-10-20 - male, weight 7½ lbs. Febrile puerperium: Retention of urine.

195. W.R. Mother = Str. Positive (3+5+). 15-10-20.

1st Preg. Married. Age 24.
L.P. end Jany., 1920. Labour was normal till slight bleeding commenced three weeks before delivery - felt quite well afterwards. Child born dead 5-10-20 (breech) macerated (about 8 months). Ragged placenta: Deficient membranes.

Case No.

196. W.R. Mother = Negative (3-5-). 8-10-20.
Child = Negative (3-5-). 8-10-20.

1st Preg. Single. Age 20.
L.P. 22-12-19. Pains began 1-10-20 - child born alive 4-10-20, male, weight 7 lbs. Dismissed 13-10-20, weight 6½ lbs.
20-4-21 - The child was known to be alive and well when 6 months old - no further trace.

197. W.R. Mother = Negative (3-5-). 8-10-20.
Child = Negative (3-5-). 8-10-20.

1st Preg. Married. Age 28.
L.P. 16-12-19. Normal pregnancy and labour. Child born alive 3-10-20, female, weight 7½ lbs. Dismissed 12-10-20, weight 8 lbs. Child died of broncho-pneumonia on 14-11-20.

198. W.R. Mother = Negative (3-5-). 8-10-20.

13th Preg. Married. Age 41.
L.P. Feby., 1920. Admitted to Antenatal Dept. 2-10-20. Felt life in July but none for last two months - abdomen not increasing in size (about 5th month size). Dead foetus - induction - child born dead 4-10-20, female, weight 2½ lbs.
Prev. Pregs.- 11 born alive, F.T. (Instrs. with last - two years ago): 1 (10th) = S.B., F.T.

199. W.R. Mother = Negative (3-5-). 8-10-20.

1st Preg. Married. Age 25.
L.P. 14-5-20. Complete Miscarriage - spontaneous evolution - premature macerated foetus born 3-10-20.

Case No.

200. W.R. Mother = Negative (3-5-). 8-10-20.

5th Preg. Married. Age 26.
L.P. February or March, 1920. Admitted 30-9-20 - Was well till two months before admission when she was kicked in abdomen since then she has passed blood almost daily. No foetal movements felt for three days. Dismissed 7-10-20.
Prev. Pregs.- 3 normal and 1 miscarriage at 6 months (1919).

201. W.R. Mother = Negative (3-5-). 8-10-20.
Child = Negative (3-5-). 19-11-20.

7th Preg. Married. Age 34.
L.P. 25-1-20. Admitted to Antenatal Dept. 28-9-20 - pains in left side: anaemia. Child born 18-11-20, male, mature, weight 10 lbs. Dismissed 27-11-20, weight 9¾ lbs.
21-2-22 - Mother well - child just recovered from influenza and not very well - aged 15 months.
Prev. Pregs.- All normal, F.T.

202. W.R. Mother = Negative (3-5-). 8-10-20.

5th Preg. Married. Age 26.
L.P. May, 1920. Admitted to Antenatal Dept. 28-9-20 - Hyperemesis gravidarum. Frequent vomiting since June - unable to retain food. Losing weight. Dismissed 4-10-20.
Prev. Pregs.- 3 normal, F.T., alive and 1 premature, alive (7½ months - May, 1919).

203. W. R. Mother = Negative (3-5-). 8-10-20.

8th Preg. Married. Age 37.
L.P. Jany., 1920. Admitted 30-9-20 to Antenatal Dept. - Hyperemesis gravidarum (mild). Incessant vomiting for four months before admission. For fourteen days before admission vomited all food more or less. Spontaneous delivery 13-10-20 - male child born alive weight 7½ lbs. Dismissed 22-10-20, weight 7¾ lbs. Child died in Stobhill Hosp. 22-6-21.
Prev. Pregs.- 1st - 6th = normal, alive: 7th = F.T., stillborn (June, 1919).

Case No.

204. W.R. Mother = Negative (3-5-). 8-10-20.

6th Preg. Married. Age 31.
L.P. Jany., 1921. Admitted to Antenatal Dept. 30-9-20 - Bronchitis. Patient was well throughout pregnancy till five days before admission when cough commenced. Uterus enlarged to midway between umbilicus and ensiform and cartilage. Dismissed 4-10-20. Readmitted 16-11-20 - Slight exophthalmos. Flat pelvis (Diag. Conj. = 4", True Conj. = 3¼"). Anterior parietal presentation. High forceps delivery. Child born dead 16-11-21, male, weight 9 lbs. Labour had begun over 48 hours before admission. History of peritonitis after last two confinements - cause unknown.
Prev. Pregs.- 4 children born alive - all very small (last in July, 1917): One miscarriage at 3½ months (July, 1918).

205. W.R. Mother = Negative (3-5-). 8-10-20.
Child = Negative (3-5-). 19-10-20.

1st Preg. Married. Age 19.
L.P. 28-1-20. Admitted Antenatal Dept. 28-9-20 - Hyperemesis gravidarum. Constant daily vomiting since July - little food retained. Anaemia. Swelling of feet. Child born alive 17-10-20, male, weight 7½ lbs. Dismissed 30-10-20, weight 8½ lbs.
14-11-21 - Child was known to be alive and well when 13 months old - never any illness.

206. W.R. Mother = Negative (3-5-). 8-10-20.

2nd Preg. Married. Age 28.
L.P. 16-7-20. Incomplete Abortion. Bleeding began slightly on 1-10-20 after lifting heavy weight, and again on 2-10-20 (slight). Large clot passed when admitted on 3-10-20 - os dilated to two fingers - clot coming away. No albuminuria. Uterus cleared out - curetted and douched - iodine swab.
Prev. Preg.- Normal (March, 1920).

Case No.

207. W.R. Mother = Negative (3-5-). 8-10-20.
Child = Negative (3-5-). 8-10-20.

4th Preg. Married. Age 34.
Normal pregnancy and labour. R.P. Child born alive 5-10-20, female, weight 7 lbs. Dismissed 15-10-20, weight 8 lbs.
18-2-22 - Child was well when aged 16 months -
W.R. Mother = Doubt. Pos. (3+5+). 18-2-22.
Child = Negative (3-5-).

Prev. Pregs.- 1st = Chloroform & Instrs., R.P. (Decr., 1904): 2nd = miscarriage at 3 months (1909): 3rd = miscarriage at 3 months (1910).

208. W.R. Mother = Negative (3-5-). 8-10-20.

3rd Preg. Married. Age 27.
L.P. 27-1-20. Admitted to Antenatal Dept. 4-10-20 - Generally contracted pelvis (Diag. Conj. = 5". True Conj. = 4 1/4".).
Prev. Pregs.- 1st = Chloroform and Instrs. (child dead): 2nd = Transverse - Chloroform & Instrs. (child lived a few hours (22-4-19).

209. W.R. Mother = Negative (3-5-). 8-10-20.

3rd Preg. Married. Age 28.
Admitted to Antenatal Dept. 1-10-20 - complaining of pains. Found to have non-gravid uterus. False pregnancy. Dismissed 2-10-20.
Prev. Pregs.- 1st and 2nd = normal.

Case No.

210. W.R. Mother = Negative (3-5-). 8-10-20.

9th Preg. Married. Age 26.
L.P. ?. Admitted 4-10-20 - Incomplete Abortion. On week before admission ovum came away followed by bleeding - since then bleeding intermittently. Pain low down on right side. Looked ill and anaemic on admission - bleeding - temperature and pulse both high. Uterus explored - decomposed placental tissue removed - curetted. Dismissed well 11-10-20.
Prev. Pregs.- Has had three miscarriages all about 4th month - present one at 3rd month: Other pregnancies normal (last in Feby., 1918).

211. W.R. Mother = Negative (3-5-). 15-10-20.
Child = Negative (3-5-). 8-10-20.

1st Preg. Married. Age 22.
L.P. ?. Normal pregnancy and labour. Child born alive 5-10-20, female, weight 8 lbs. Mother has a watery vaginal discharge. Dismissed 15-10-20, weight 7¾ lbs.
Child was known to be alive and well when aged 13 months - no illness so far.
18-2-22 - Child died on 6-2-22 - Measles.

212. W.R. Mother = Negative (3-5-). 8-10-20.
Child = Negative (3-5-). 8-10-20.

1st Preg. Single. Age 22.
L.P. 2-1-20. Hyperemesis gravidarum and acute gastritis in Feby., 1920. Patient was well throughout this pregnancy till two days before admission when vomiting began again and continued till labour set in. Spontaneous delivery child born alive 5-10-20, male, weight 9 lbs. Dismissed 15-10-20, weight 9 lbs. No further trace.

Case No.

213. W.R. Mother = Negative (3-5-). 8-10-20.

1st Preg. Married. Age 21.
L.P. 20-12-19. Normal pregnancy and labour. Child born alive 6-10-20, male, weight 7 lbs. Dismissed 15-10-20, weight 6½ lbs.
18-3-22 - Child was well when 17 months old - never any illness.
W.R. Mother = Negative (3-5-). 21-3-22.
Child = Negative (3-5-). 21-3-22.

214. W.R. Mother = Negative (3-5-). 8-10-20.
Child = Negative (3-5-). 8-10-20.

2nd Preg. Married. Age 24.
L.P. 19-1-20. Admitted 5-10-20 - Eclampsia. Had swollen feet and ankles for five weeks before admission - first convulsion about an hour before admission. On admission face puffy, marked oedema of legs. Albuminuria ++++ - was taking fits. Rather precipitate labour - child born alive 5-10-20 - male, weight 7¾ lbs. The baby was having fits when born and continued having convulsions till it died the following day. Mother dismissed.
Prev. Preg.- Child born alive (8 months) but died shortly after birth.

215. W.R. Mother = Negative (3-5-). 8-10-20.
Child = Negative (3-5-). 8-10-20.

1st Preg. Married. Age 21.
L.P. 6-1-20. Face presentation: Forceps: R.P. Child born 6-10-20, male, weight 8 lbs. Mother had vomiting throughout pregnancy and was pale and anaemic.
24-2-22 - Both well - child 16 months old.
W.R. Mother = Negative (3-5-). 24-2-22.
Child = Negative (3-5-). 24-2-22.

Case No.

216. W.R. Mother = Negative (3-5-). 8-10-20.

2nd Preg. Married. Age 23.
L.P. end Novr., 1919. Labour began 1-10-20 and continued with moderate severity till 5-10-20 when admitted to Hospital. Os then nearly fully dilated. Labour continued till afternoon - foetal pulse rate rising - meconium coming away. Flat pelvis - high forceps delivery - child born alive 5-10-20, male, weight 9¾ lbs. Laceration - portion of membranes left behind. Dismissed 13-10-20.
22-3-22 - Child was known to be alive and well when aged 17 months.
Prev. Preg.- Three months abortion (Aug., 1919).

217. W.R. Mother = Negative (3-5-). 8-10-20.

1st Preg. Married. Age 19.
L.P. 24-12-19. Normal pregnancy and labour. Child born alive 5-10-20, female, weight 7½ lbs. R.P. Dismissed 15-10-20, weight 7 lbs.
20-2-22 - Both well - child aged 16 months.

218. W.R. Mother = Negative (3-5-). 8-10-20.

2nd Preg. Married. Age 24.
L.P. 14-4-20. Antepartum haemorrhage. Bleeding at three months and then again on 5-10-20 (week before admission). Had cramp-like pains from 6-10-20 and passed brown discharge. Child alive in utero. No bleeding noted after admission. Dismissed 14-10-20.
Prev. Preg.- Chloroform and forceps (July, 1919).

Case No.

219. W.R. Mother = Str. Positive (3+5+). 8-10-20.
Child = Negative (3-5-). 17-11-20.

1st Preg. Married. Age 31.
L.P. 14-2-20. Admitted to Antenatal Dept. 4-10-20. Vomiting for first three months and morning sickness and vomiting returned. Slightly contracted pelvis. Dismissed 6-10-20 - spontaneous delivery anticipated. Readmitted 15-11-20 - Forceps applied - child born alive, weight 7 lbs. No further trace after dismissal.

220. W.R. Mother = Negative (3-5-). 15-10-20.
Child = Negative (3-5-). 8-10-20.

2nd Preg. Single. Age 26.
L.P. Jany., 1918. Normal pregnancy and labour - child born alive 4-10-20 - male, weight 8 lbs. Dismissed 14-10-20, weight 8½ lbs. Child died in Ruchhill Hospital when about 4½ months old - Whooping-cough.
Prev. Preg.- Difficult labour : forceps (Jany., 1918).

221. W.R. Mother = Negative (3-5-). 8-10-20.

1st Preg. Married. Age 19.
Normal pregnancy and labour - child born alive 3-10-20, female, weight 6½ lbs. Indefinite malaise during pregnancy - anaemic looking and generally puffy. Dismissed 16-10-20, weight 5½ lbs. Child died when two months old.

Case No.

222. W.R. Mother = Negative (3-5-). 15-10-20.
Child = Negative (3-5-). 8-10-20.

1st Preg. Married. Age 27.
L.P. end Decr., 1919. Admitted to Antenatal Dept. 4-10-20 - contracted pelvis. History of epileptic fits from childhood - one fit before admission. Labour began 5-10-20 - Forceps delivery after head at perineum for two hours. Child born alive 6-10-20, female, weight 6¼ lbs. Dismissed 16-10-20, weight 6 lbs.
25-2-22 - Both mother and child well - child aged 16 months. - W.R. Mother = Negative.
Child = Negative.

223. W.R. Mother = Negative (3-5-). 8-10-20.

1st Preg. Married. Age 20.
L.P. 15-1-20. Breech Presentation: R.P. Child born alive 6-10-20, female, weight 7¼ lbs. Dismissed 16-10-20, weight 8 lbs. No further trace.

224. W.R. Mother = Negative (3-5-). 8-10-20.
Child = Negative (3-5-). 8-10-20.

2nd Preg. Single. Age 26.
L.P. 7-1-20. Child born alive 6-10-20, female, weight 7½ lbs. Dismissed 16-10-20, weight 7 lbs.
8-3-22 - Baby reported well when aged 5 months (adopted) - no further trace.
Prev. Pregs.- 1st = normal (6 years ago).

Case No.

225. W.R. Mother = Str. Positive (3+5+). 8-10-20.

3rd Preg. Married. Age 37.
L.P. Jany., 1920. Normal pregnancy and labour - child born alive 4-10-20, female, weight 6¼ lbs. Dismissed 14-10-20, weight 7 lbs.
16-2-22 - Both mother and child well - child aged 16 months.
Prev. Pregs.- F.T., living, normal.

226. W.R. Mother = Negative (3-5-). 22-10-20.
Child = Negative (3-5-). 8-10-20.

2nd Preg. Married. Age 27.
L.P. beginning Jany., 1920.
Normal pregnancy and labour. Child born alive 8-10-20, female, weight 8¾ lbs. Dismissed 16-10-20, weight 8 lbs. No further trace.

227. W.R. Mother = Negative (3-5-). 15-10-20.
Child = Negative (3-5-). 8-10-20.

6th Preg. Married. Age 37.
L.P. 12-1-20. Forceps: Occipito-posterior. Labour began 10 p.m. 4-10-20. Membranes ruptured 5-10-20. Admitted 7-10-20 - six hours after full dilatation of os. Persistent occipito-posterior: uterine contractions tetanic: child alive- Absence of moulding - head would not engage. Slight degree of flat pelvis - partial version - forceps delivery. Child born alive 7-10-20, female, weight 7½ lbs. R.P. Slightly febrile puerperium. Dismissed 19-10-20, weight 7 lbs. No further trace after dismissal.
Prev. Pregs.- 1st = Chloroform & Forceps: 2nd = spontaneous: 3rd = premature (8 months) - spontaneous - died three weeks after birth): 4th = miscarriage at 2½ months: 5th = miscarriage at 2½ months.

Case No.

228. W.R. Mother = Negative (3-5-). 15-10-20.
Child = Negative (3-5-). 8-10-20.

1st Preg. Married. Age 19.
L.P. 16-1-20. Normal pregnancy and labour. Child born alive 8-10-20, female, weight 6 lbs. Dismissed 16-10-20, weight 6 lbs. No further trace.

229. W.R. Mother = Negative (3-5-). 16-10-20.
Child = Negative (3-5-). 8-10-20.

1st Preg. Single. Age 18.
L.P. end Decr., 1919. Admitted 23-9-20 - False labour. Dismissed 24-9-20. Readmitted 6-10-20 - child born alive 7-10-20, male, weight 8½ lbs. Slight P.P.H. Dismissed 16-10-20, weight 8 lbs. Mother was at Lock Hospital and was treated for vulvar sores. Leucorrhoea - No G.C. found - Swab from cervix.
Child died in Belvidere - double pneumonia - when aged 5 months.

230. W.R. Mother = Str. Positive (3+5+). 8-10-20.
Mother = Negative (3-5-). 15-4-21.
Child = Negative (3-5-). 15-4-21.

? Pregnancy. Married. Age 33.
Attended Antenatal Dispensary 7-10-20 (8th month). Child born at home 31-10-20, male. No treatment for either mother or child. 11-4-21 - Mother not feeling well. 13-4-21 - Blood taken off from both mother and child (both negative). Baby seems well - has slight eczema of left ear and a few blotchy spots on face.
14-11-21 - Child getting on well - over one year old.
20-2-22 - Child well - no illness - 16 months old.

Case No.

231. W.R. Mother = Negative (3-5-). 16-10-20.

7th Preg. Married. Age 30.
L.P. 28-7-20. Attended Antenatal Dispensary 8-10-20 - Incomplete Abortion - Bleeding five days before visit and bleeding ever since. Admitted for curettage.
Prev. Pregs.- 4 = F.T., living, normal: 2 = premature, stillborn (6 and 8 months) - the last pregnancy was an eight months miscarriage in Jany., 1920.

232. W.R. Mother = Negative (3-5-). 8-10-20.

3rd Preg. Married. Age 29.
L.P. 28-8-20. Attended Antenatal Dispensary 8-10-20 - abdominal pain and frequent and painful micturition: profuse leucorrhoea: constipation. Child born at home 5-1-21 - female, alive.
14-1-22 - Both mother and child well - child one year old. W.R. Mother = Negative.
Child = Negative.
Prev. Pregs.- 1st = F.T., normal, alive (died of Pneumonia when about 4 years old): 2nd = abortion (2 months) in Hospital (June, 1920).

233. W.R. Mother = Str. Positive (3+5+). 8-10-20.
Child = Str. Positive (3+5+). 1-12-20.
Mother = Str. Positive (3+5+). 3-12-20.

1st Preg. Single. Age 26.
Attended Antenatal Dispensary when seven months pregnant (Octr., 1920). Had scabies, rickets, etc. Contracted Pelvis (Diag. Conj. = 4½", True Conj. = 3¾"). Forceps delivery - child born alive 27-11-20 (8th month), weight 6¼ lbs. but died same day.

Case No.

234. W.R. Mother = Negative (3-5-). 8-10-20.
Child = Negative (3-5-).29-10-20.

7th Preg. Married. Age 40.
L.P. middle Jany., 1920. Attended Antenatal Dispensary 8-10-20 - slight swelling of left foot. Admitted to Hospital 25-10-20 - normal labour - child born alive 26-10-20, Female, weight 7½ lbs. Dismissed 20-11-20, weight 8½ lbs.
25-2-22 - Child was known to be alive and well when aged 16 months - no illness.
Prev. Pregs.- 5 born alive, F.T.: 1 miscarriage at 3 months. - The last pregnancy was fulltime - 6 years ago.

235. W.R. Mother = Negative (3-5-). 8-10-20.

3rd Preg. Married. Age 25.
L.P. Septr., 1920. Attended Antenatal Dispensary 8-10-20 - menstruating every month but period in August lasted only one day. Patient thinks she is pregnant but no signs of pregnancy found up to 26-11-20.
Prev. Pregs.- 1st and 2nd = normal, F.T. (last in 1916).

236. W.R. Mother = Negative (3-5-).

2nd Preg. Married. Age 20.
L.P. - Amenorrhoea since last pregnancy. Complete miscarriage - macerated foetus. Life felt toll 3-10-20. Anencephalic macerated foetus born 6-10-20, male, weight 6½ lbs. Mother healthy.
Prev. Pregs.- Premature (8 months) child born alive. Forceps on account of " bobe obstruction'' - child lived seven days only (Octr., 1919).

Case No.

237. W.R. Mother = Negative (3-5-). 22-10-20.
Child = Negative (3-5-). 15-10-20.

1st Preg. Single. Age 21.
L.P. Jany., 1920. Normal pregnancy and labour: R.P. Child born alive 8-10-20, female, weight 8 lbs. Slightly febrile puerperium. Dismissed 18-10-20, weight 6¾ lbs.
10-3-22 - Child was known to be alive and well when aged 17 months.

238. W.R. Mother = Negative (3-5-). 15-10-20.

2nd Preg. Married. Age 21.
L.P. first week Jany., 1920. Patient had bronchitis for last two months of pregnancy: history of tonsilitis twice (last time three years ago). Forceps delivery after 18 hours labour - head at perineum for two hours - (delayed second stage). Child born alive 9-10-20, female, weight 7½ lbs. Dismissed 18-10-20, weight 7½ lbs.
The child was known to be alive and well when aged 11 months - no further trace.
Prev. Preg.- Breech (1-10-19) - child died during delivery.

239. W.R. Mother = Negative (3-5-). 23-10-20.
Child = Negative (3-5-). 15-10-20.

1st Preg. Married. Age 25.
L.P. 28-12-19. Mother had displacement of uterus corrected in 1917. Child born alive 9-10-20, female, weight 8 lbs. Normal labour. Dismissed 18-10-20, weight 8 lbs.
18-11-21 - Baby alive and well - has had bronchitis and tonsilitis (mild).
18-2-22 - Mother and child both well - child now 16 months old - W.R. Mother = Negative (3-5-).
Child = Negative (3-5-).

Case No.

240. W.R. Mother = Negative (3-5-). 15-10-20.
Child = Negative (3-5-). 15-10-20.

3rd Preg. Married. Age 31.,
L.P. last week Decr., 1919. Very severe vomiting throughout pregnancy. Normal labour: R.P. (extensive). Child born alive 9-10-20, female, weight 8 lbs. Dismissed 24-10-20, weight 7¼ lbs.
26-2-22 - Child was alive and well when 16 months old.
Prev. Pregs.- 1st = delayed delivery - Chloroform & forceps (March, 1917): 2nd = abortion at five weeks (May, 1916).

241. W.R. Mother = Negative (3-5-). 15-10-20.

8th Preg. Married. Age 40.
L.P. Feby., 1920. Patient had been very breathless and very sleepless for some months: had some bleeding and some ? hydrammios. Labour began 6-10-20 - Double arm presentation (artificial). Doctor sent for who pulled down two arms and sent patient to Hospital. Admitted 7-10-20 - pale and slightly jaundiced - severe labour pains and both arms presenting. Decapitation (head impacted at cervix) - child small and slightly premature, weight 4½ lbs., female. Slightly febrile puerperium.
Prev. Pregs.- No record.

242. W.R. Mother = Negative (3-5-). 22-10-20.
Child = Negative (3-5-). 15-10-20.

3rd Preg. Married. Age 28.
L.P. first week Jany., 1920. Normal pregnancy and labour - child born alive 9-10-20, female, weight 7 lbs. Dismissed 19-10-20, weight 7 lbs.
18-2-22 - Mother fairly well: child has bronchitis - W.R. Mother = Negative (3-5-).
Child = Negative (3-5-).
Prev. Pregs.- 1st = F.T., chloroform & forceps (1915): 2nd = abortion at three months (1918).

243. W.R. Mother = Negative (3-5-). 22-10-20.
Child = Negative (3-5-). 15-10-20.

1st Preg. Married. Age 20.
L.P. 5-1-20. Normal pregnancy and labour. Child born alive 10-10-20, female, weight 7½ lbs. Mother had bronchitis and pain in chest during puerperium. Dismissed 20-10-20, weight 7¾ lbs.
Child died on 27-3-21.

Case No.

244. W.R. Mother = Negative (3-5-). 9-2-21.

2nd Preg. Married. ? age.
L.P. 17-7-21. Patient was well throughout till morning of admission when she felt sick. Liquor amnii began to come away and she had pains frequently. Pains ceased shortly before admission (31-1-21) but came on again severely - foetus and placenta expelled. Complete miscarriage at 6½ months - macerated foetus.
Prev. Preg.- miscarriage at 2½ months (24-2-20). History of pneumonia in 1916 and 1917. Now anaemic but otherwise healthy.

245. W.R. Mother = Negative (3-5-). 9-2-21.

3rd Preg. Married. Age 43.
L.P. May, 1920. Post-partum eclampsia. Child born before admission at 12 midnight 1-2-21 - normal labour. Mother was well till 4-30 a.m. 2-2-21 when she had a fit followed by two others. Admitted at 11 a.m. 2-2-21 - stomach washed out, etc. One fit after admission. Albuminuria ++++ (0.7%). Patient unconscious but colour good. Slight oedema - arteriosclerosis - improved on treatment. Albumen down to 0.35% by 5-2-21 but persisted in varying amount (0.2% to 0.05%). General condition improved. Dismissed 18-2-21.
Child died of Whooping-cough 15-4-21.
Prev. Pregs.- 1st = F.T., alive, Chloroform & forceps: 2nd = F.T., living, normal.
Patient had faecal fistula about 16 years ago: had scarlet fever and nephritis when aged 17 years - and has been troubled with her kidneys off and on ever since. Feet and legs were swollen almost throughout whole of pregnancy.

246. W.R. Mother = Negative (3-5-). 15-10-20.
Child = Negative (3-5-). 15-10-20.

5th Preg. Married. Age 34.
L.P. last week Decr., 1919. Forceps - persistent occipito-posterior - delayed second stage - head at perineum for two hours. Child born alive 9-10-20, male, weight 8 lbs. Dismissed 19-10-20, weight 7½ lbs.
20-2-22 - Child alive and well - no illness.
Prev. Pregs.- 1st = Chloroform & Forceps: 2nd = normal, spontaneous: 3rd = Instruments (1916).

Case No.

247. W.R. Mother = Str. Positive (3+5+). 22-10-20.
Child = Negative (3-5-). 15-10-20.

4th Preg. Married. Age 28.
Mother had sickness and general malaise for ten weeks before delivery. Had one child in Ruchhill where it died - dates her own symptoms from that time. Face presentation - spontaneous delivery - child born alive 11-10-20, female, weight 7½ lbs. Dismissed 21-10-20, weight 7 lbs.
29-11-20 - Child alive and in fair health but not gaining well.
9-4-21 - Child died on 31-1-21 - convulsions: Mother complains of 'not feeling well'.
28-3-22 - Mother 7 months pregnant - has cough and does not feel well - no rash. W.R. = Str. Positive - No treatment.

Prev. Pregs.- 1st = F.T., alive: 2nd and 3rd = Forceps, alive (3-6-1918).

248. W.R. Mother = Negative (3-5-). 22-10-20.

1st Preg. Single. Age 16.
L.P. ?. Normal pregnancy and labour - child born alive 9-10-20, female, weight 7¾ lbs. Slightly febrile puerperium. Dismissed 18-10-20, weight 7¾ lbs.
Child died in Merryflatts Hospital on 25-12-20.

249. W.R. Mother = Negative (3-5-). 15-10-20.

3rd Preg. Married. Age 22.
L.P. 15-7-20. Inevitable Abortion. Curetted and swabbed with iodine. Normal pregnancy till 14 days before admission (7-10-20) when she had a fall and within three days bleeding began and continued till admission. Placental debris, etc. protruding from os on admission.
Prev. Pregs.- 1st and 2nd = normal (last on 20-9-19).

Case No.

250. W.R. Mother = Negative (3∓5-).

8th Preg. Married. Age 37.
Admitted 4-10-20 (B.B.A. 4-10-20 - male).
Post-partum Haemorrhage: Partially retained Placenta. On admission patient was blanched - rapid small pulse. Transfused - uterus explored and portion of placenta removed. Slightly febrile puerperium - foul lochia - swelling in Pouch of Douglas. Patient has chronic bronchitis.
Dismissed 18-11-20, weight 8 lbs.
9-3-22 - Child has been difficult to bring up but seems stronger now - aged 15 months.
Prev. Pregs.- 1st = living, F.T., forceps (died on 7th day): 2nd to 7th = normal.

251. W.R. Mother = Negative (3-5-). 15-10-20.

4th Preg. Married. Age 37.
Admitted to Ante-natal Dept. 7-10-20. Fibroid Uterus - some small lacerations of cervix - uterus slightly enlarged -some endometritis. Looks pale but otherwise healthy. Dismissed 9-10-20 to apply to Samaritan Hospital for admission.
Prev. Pregs.- 1st - 3rd = miscarriages at 5½ months - in each has had sickness till 4th month.

252. W.R. Mother = Negative (3-5-). 22-10-20.

4th Preg. Married. Age 33.
L.P. 12-1-20. Admitted to Antenatal Dept. 6-10-20 - Contracted Pelvis. Spontaneous delivery - child born alive 12-10-20, female, weight 6 lbs. Dismissed 21-10-20, weight 7½ lbs.
18-2-22 - Both mother and child well - child 16 months old - W.R. Child = Negative (3-5-).
Prev. Pregs.- 3 F.T., living, forceps (last in 1917).

Case No.

253. W.R. Mother = Negative (3-5-). 15-10-20.

2nd Preg. Married. Age 24.
L.P. 22-12-19. Normal pregnancy and labour. Child born alive 11-10-20, weight 6¼ lbs. Dismissed 20-10-20, weight 7¼ lbs.
Child was alive and well when aged 16 months - had just recovered from measles.
Prev. Preg.- Abortion (incomplete) at about two months - July, 1919. Has had yellow vaginal discharge since.

254. W.R. Mother = Negative (3-5-). 15-10-20.

3rd Preg. Married. Age 26.
L.P. March, 1920. Complete Abortion: Macerated Foetus. During the three months before admission patient had several floodings - had been in bed off and on. Pain on 3-10-20 - later bleeding on 4-10-20 and some placental tissue came away. Admitted 6-10-20 - foetus in vagina - head still in uterus - about 6½ to 7 months size - macerated. Patient anaemic and sickly looking: Rash. Uterus cleared out and douched.
Prev. Pregs.- 1st = F.T., normal, alive (1916): 2nd = Abortion at three months (March, 1919).

255. W.R. Mother = Negative (3-5-). 15-10-20.

3rd Preg. Married. Age 28.
L.P. last week Decr., 1919. Varicose veins but otherwise well throughout pregnancy. Normal labour - child born alive 9-10-20, male, weight 8½ lbs. Dismissed 19-10-20, weight 9 lbs.
18-2-22 - Child was known to be alive and well when aged 16 months - had catarrh in stomach in Novr., 1921 but this was only illness. Mother well. - W.R. Mother = Negative.
Child = Negative.
Prev. Pregs.- 1st = Chloroform & forceps: 2nd = normal.

Case No.

256. W.R. Mother = Negative (3-5-). 15-10-20.

1st Preg. Single. Age 22.
L.P. first week January, 1920. Normal pregnancy and labour. Child born 10-10-20, female, weight 8 lbs. Dismissed 20-10-20, weight 7½ lbs.
Child adopted - no trace after one month old.

257. W.R. Mother = Negative (3-5-). 15-10-20.

1st Preg. Married. Age 26.
L.P. 8-1-20. Hands and cord prolapsed on admission - child dead - Craniotomy. R.P. Child born dead 11-10-20, male, weight 6½ lbs.

258. W.R. Mother = Negative (3-5-). 15-10-20.

4th Preg. Married. Age 36.
L.P. middle July, 1920. Bleeding at intervals for a few days before admission and more on day of admission (13-10-20). Uterus curetted and swabbed with iodine.
Prev. Pregs.- All F.T., normal, alive.

259. W.R. Mother = Negative (3-5-). 22-10-20.
Child = Negative (3-5-). 15-10-20.

1st Preg. Married. Age 28.
L.P. Jany., 1920. Labour began 24 hours before admission. Forceps delivery: R.P. Child born alive 13-10-20, male, weight 8 lbs. Dismissed 23-10-20, weight 7½ lbs.
22-2-22 - Child alive and well at the age of 16 months: Mother pregnant again.

Case No.

260. W.R. Mother = Negative (3-5-). 12-10-20.

1st Preg. Married. Age 20.
L.P. ?. Post-partum Eclampsia. Twins born (B.B.A.) at 5 a.m. 4-10-20. Some post-partum haemorrhage. Mother took a fit at 8-35 a.m. followed by several others - the last at 5-30 p.m. Transfused, etc. - good recovery. Albumen ++ on 4-10-20 - albumen gone from urine for some days before 14-10-20 when mother and children were dismissed.
The children died on 17-10-20.

261. W.R. Mother = Negative (3-5-). 15-10-20.

6th Preg. Married. Age 21.
L.P. 2nd or 3rd week Aug., 1920. Incomplete Abortion - Curettage. Patient felt well till pain and bleeding began on 8-10-20 - still bleeding fairly freely when admitted on 9-10-20. Looked anaemic. Uterus cleared out-curetted and swabbed.
Prev. Pregs.- 1st = 6½ months, living: 2nd = F.T., living, Chloroform and Instrs.: 3rd = F.T., living: 4th = F.T., living (23-3-17). Patient was in Duke St. Hospital with inflammation of womb in June, 1920.

262. W.R. Mother = Negative (3-5-). 12-10-20.

2nd Preg. Married. Age 25.
L.P. Jany., 1920. Admitted to Antenatal Dept. 11-10-20 - Contracted Pelvis (Diag. Conj. = 4¼", True Conj. = 3½"). No marked deformity. Spontaneous delivery - child born alive 12-10-20, male, weight 6½ lbs. Dismissed 21-10-20, weight 6 lbs.
20-2-22 - Child alive and well when aged 16 months - had bronchitis when one year old.
Prev. Preg.- F.T., 2 days in labour - spontaneous delivery, S.B.

Case No.

263. W.R. Mother = Negative (3-5-). 13-10-20.
Child = Negative (3-5-). 5-11-20.

7th Preg. Married. Age 35.
L.P. 31-5-20. Admitted to Antenatal Dept. 8-10-20 - Threatened Abortion - Premature labour. Patient was well till three days before admission when she had pain in back which continued at intervals till 8-10-20 - then bleeding began. No placenta palpable. Child born alive 11-10-20, male, weight 2½ lbs. Died 13-10-20.
Prev. Pregs.- 1st = F.T., normal: 2nd = F.T., precipitate, painless labour: 3rd = miscarriage at 6½ months - child lived 36 hours: 4th = miscarriage at 4½ months: 5th = F.T., normal: 6th = F.T., normal (June, 1916).

264. W.R. Mother = Negative (3-5-). 15-10-20.
Child = Negative (3-5-). 15-10-20.

8th Preg. Single. Age 31.
L.P. ?. Admitted 6-10-20 - Albuminuria (7 esbach). Abdomen about 7 months size. Patient was well till one week before admission when pain in epigastrium began - vomiting, headache, and oedema of legs - increasing in severity - did not respond to treatment - oedema increasing. Induction (bougies) 12-10-20. Child born alive 14-10-20, female, weight 5½ lbs. Mother improved after delivery. Dismissed 19-10-20. No further trace.
Prev. Pregs.- 1st = F.T., normal: 2nd = F.T., (1915): 3rd to 7th = all abortions at three months (last in 1916).

Case No.

265. W.R. Mother = Negative (3-5-). 13-10-20.

5th Preg. Married. Age 28.
L.P. March, 1920. Patient fell out of bed fourteen days before admission and had been in bed since. At the same time had ? ptomaine poisoning. Pains began evening of 10-10-20. Some A.P.H. Patient anaemic looking and had yellow tint of skin. Twins born 10-10-20 - both dead, premature, 1st = male, weight 2½ lbs., 2nd = female, weight 1½ lbs.
Prev. Pregs.- All F.T., living, normal.

266. W. R. Mother = Negative (3-5-). 15-10-20.

4th Preg. Married. Age 29.
L.P. 22-1-20. Patient was well till three weeks before admission when had pains (probably false labour pains), dizziness but no headache: no dimness of vision and no oedema. Some bleeding on 8-10-20. When admitted on 8-10-20 bleeding had ceased but was pale and collapsed. Albuminuria. Forceps - child born dead 8-10-20, male, weight 7¾ lbs. Some P.P.H. Albuminuria cleared up before dismissal on 23-10-20.
Prev. Pregs.- All normal, F.T. (last on 12-3-18).

267. W.R. Mother = Negative (3-5-). 15-10-20.

1st Preg. Married. Age 20.
L.P. 7-1-20. Normal pregnancy. Child born alive 14-10-20 - Impacted Breech - female, weight 6½ lbs. R.P. Dismissed 23-10-20, weight 6½ lbs.
20-2-22 - Child alive and well when 16 months old - never any illness.

Case No.

268. W.R. Mother = Negative (3∓5-). 15-10-20.

12th Preg. Married. Age 40.
L.P. end July, 1920. Incomplete Abortion.
Patient was well till 5-10-20 when bleeding began and continued till admission on 11-10-20 - bleeding not profuse. Uterus cleared out - curetted and swabbed with iodine.
Prev. Pregs.- All F.T., normal, living (last 21-3-19).

269. W.R. Mother = Negative (3-5-). 15-10-20.
Child = Negative (3-5-). 5-11-20.

4th Preg. Married. Age 28.
L.P. 23-1-20. Admitted to Antenatal Dept. 11-10-20 - Contracted Pelvis (Diag. Conj. = 4½", True Conj. = 3¾"). Spontaneous delivery 30-10-20 - child born alive, female, weight 8¼ lbs. Dismissed 9-11-20, weight 7½ lbs.
24-2-22 - Both mother and child well - child 16 months old - no illness.
Prev. Pregs.- 1st = F.T., living, normal: 2nd = F.T., living, normal: 3rd = S.B., Chloroform & forceps, F.T. (said to have been transverse).

270. W.R. Mother = Negative (3-5-). 15-10-20.
Child = Negative (3-5-). 23-10-20.

2nd Preg. Married. Age 24.
L.P. 5-1-20. Admitted to Antenatal Dept. 4-10-20 - male, weight 8½ lbs. born alive 15-10-20. Normal delivery. Dismissed 23-10-20, weight 7¾ lbs.
20-2-22 - Child alive and well - no illness.
Prev. Preg.- Normal.

Case No.

271. W.R. Mother = Negative (3-5-). 15-10-20.

6th Preg. Married. Age 31.
L.P. 16-5-20. Inevitable Abortion: Acute lobar pneumonia. Some bleeding im June, 1920 and once or twice later - losing much more six to seven weeks before admission. Bougies inserted - os did not dilate well. Explored digitally 12-10-20 and cleared out. Died on 21-10-20 - Acute lobar pneumonia.
Prev. Pregs.- All F.T., living - Chlofoform & instrs. with all - last in 1915.

272. W.R. Mother = Negative (3-5-). 15-10-20.

12th Preg. Married. Age 38.
L.P. early in May, 1920. Threatened Abortion: Premature labour - six months living foetus. Admitted 6-10-20 - not feeling well but no definite complaint. History of stain two days before admission - began to bleed day of admission - no bleeding on admission. Bleeding 15-10-20. Child born alive 16-10-20 (premature six months child) weight 2½ lbs. Died 20-10-20. P.M. exam.
Prev. Pregs.- 8 normal, F.T., alive: 3 miscarriages - one at 4 months, 2nd at 4 months and 3rd at 10 weeks. Last child - March, 1919 - last miscarriage Novr., 1917.

Case No.

273. W.R. Mother = Negative (3-5-). 15-10-20.

3rd Preg. Married. Age 36.
L.P. 21-7-20. Threatened Abortion. Admitted 8-10-20 - Patient was well till one month before admission when had swelling of legs and pain on passing urine. Had some bleeding fourteen days before admission and again three days later and also on 8-10-20. Severe pain: bleeding on admission - tenderness. Symptoms suggest ectopic but normal 2½ months size uterus found - P.V. under chloroform. Albumen ++ on 9-10-20. No bleeding for nine days before dismissal. Dismissed 1-11-20.
Prev. Pregs.- 1st = Twins, F.T., chloroform and instruments: 2nd = F.T., normal (April, 1915).

274. W.R. Mother = Negative (3-5-). 15-10-20.
Child = Negative (3-5-). 5-11-20.

4th Preg. Married. Age 30.
L.P. 2-1-20. Admitted to Antenatal Dept. 6-10-20 - Albuminuria. Pain in left side since March, 1920 - prolapse - wore pessary for three months. Day before admission had headache and pains: dimness of vision - particularly at night: legs swollen for seven weeks and later hands and face: Urine scanty. On admission oedema of face, hands (slight) and legs (marked). Albumen +. Rather dazed and slow of speech. 7-10-20 - albumen gone and patient brighter. 15-10-20 - albumen and oedema gone and general condition good. Child born alive 30-10-20, female, weight 8 lbs. Dismissed 9-11-20, weight 7½lbs.
22-2-22 - Both mother and child well, child's only illness was measles.
26-5-22 - Mother not very well - oedema, pallor, oligurea, sleeps badly: Child now 17 months old - has urticaria but well otherwise. W.R. Mother = Negative.
Child = Negative.
Prev. Pregs.- 1st to 3rd = F.T., living - 3rd = breech (July, 1915).

Case No.

275. W.R. Mother = Negative (3∓5-). 15-10-20.

1st Preg. Married. Age 23.
L.P. 12-1-20. Patient was very sick during early months of pregnancy but well since. Labour began 10-10-20 (p.m.) but passed off and began again 11-10-20. Contracted Pelvis - (Diag. Conj. = 4", True Conj. = 3¼"). Child alive (heart feeble) just before delivery - Forceps - Child born dead 12-10-20 male. Vaginal lacerations.

276. W.R. Mother = Negative (3-5-). 15-10-20.

3rd Preg. Married. Age 25.
L.P. Aug., 1920. Inevitable Abortion. No palpable enlargement of uterus. Patient was well till 8-10-20 when bleeding began and large clots were passed. Bleeding on admission 9-10-20. Curetted, swabbed and packed.
Prev. Pregs.- 1st = 10 weeks abortion: 2nd = F.T., normal (15-10-19).

277. W.R. Mother = Negative (3-5-). 15-10-20.

5th Preg. Married. Age 39.
L.P. April, 1920. Patient was well till 8-10-20 when life no longer felt. Slight persistent haemorrhage began 9-10-20 but no pain. Admitted - abdomen about six months size - slight but persistent bleeding - packed - premature foetus expelled 10-10-20, male, weight 2¼ lbs. Placenta ragged.
Prev. Pregs.- 1st = 6½ months, S.B.: 2nd = S.B. - 7 months: 4th = 8 months, S.B.: Ante-partum haemorrhage with all (last in 1916).

Case No.

278. W.R. Mother = Negative (3-5-). 15-10-20.

2nd Preg. Married. Age 24.
L.P. 14-1-20. Mother had pneumonia just shortly before admission to Hospital - had been well for about fourteen days before. Admitted to Antenatal Dept. 9-10-20 - pains and swelling of left wrist for five days (acute rheumatism). Mitral systolic murmur. Uterus up to costal margin. Child born alive 9-11-20 - male, weight 7¾ lbs. Dismissed 18-11-20, weight 7½ lbs. The child died in R.H.S.C. when aged five weeks - Gastric catarrh.
Prev. Preg.- F.T., normal.

279. W.R. Mother = Negative (3-5-). 15-10-20.
Child = Negative (3-5-). 15-10-20.

10th Preg. Married. Age 40.
L.P. 2nd week Jany., 1920. Patient was very well until about two months before delivery when did not feel well but nothing definite. Slight bleeding began morning of admission (12-10-20). Child born alive 12-10-20, female, weight 7½ lbs. Dismissed 22-10-20, weight 7¼ lbs.
18-11-21 - Baby very well: Mother not feeling well - has headaches.
25-2-22 - Baby 16 months old - Both well.
W.R. Mother = Doubt. Pos. (3±5-).
Child = Negative (3-5-).
Prev. Pregs.- All normal except 3rd which was an instr. delivery.

280. W.R. Mother = Negative (3-5-). 15-10-20.

1st Preg. Married. Age 19.
L.P. 15-5-20. Inevitable Abortion. Patient has been very sick and liable to " dizzy turns" throughout. Bleeding began fourteen days before admission - at first large clots and then fluid blood: no pain till just before admission on 12-10-20. Uterus up to umbilicus - cleared out - curetted.

Case No.

281. W.R. Mother = Negative (3-5-). 5-11-20.
Child = Negative (3-5-). 29-10-20.
Mother = Negative (3-5-). 22-10-20.

1st Preg. Married. Age 22.
L.P. (always very scanty and irregular) - last saw flow in July, 1919. Normal pregnancy and labour - Child born (B.B.A. in ambulance) alive 26-10-20, male, weight 7¼ lbs. R.P. Mother was treated for anaemia but none evident. Dismissed 4-11-20, weight 6½ lbs.
20-2-22 - Child very well when 16 months old - never had any illness.

282. W.R. Mother = Negative (3-5-). 15-10-20.

13th Preg. Married. Age 35.
L.P. May, 1920. Admitted to Ante-natal Dept. 12-10-20. Some three months before admission had Dyspnoea and oedema of ankles and feet at night. On admission no oedema noted: heart enlarged: mitral systolic and presystolic: low tension pulse rate 132. Ran temperature after admission - herpes - bronchitis - dim resonance at right base. Has had pain at heart for years: Fainting turns: Albuminuria. Dismissed 1-11-20.
Prev. Pregs.- 11 children alive: Twins, S.B., premature (Feby., 1920).

283. W.R. Mother = Negative (3-5-). 15-10-20.

16th Preg. Married. Age 41.
L.P. 27-7-20. Incomplete Abortion. Very slight bleeding for four days before ovum came away- afterwards haemorrhage was more profuse. Bleeding when admitted on 12-10-20 - Curetted.
Prev. Pregs.- 1st = S.B.: 11 normal (one twin born dead July, 1914): 5 miscarriages (4 at 2½ months and 1 (twins - March, 1917) at 5½ months).

Case No.

284. W.R. Mother = Negative (3-5-). 15-10-20.

6th Preg. Married. Age 38.
L.P. April, 1920. Inevitable Abortion.
Patient was well till end of June when discharge appeared - dryish and red. Normal again till patient had a fall in August and broke some ribs. Admitted 12-10-20 - pale and bleeding. Uterus explored, curetted and swabbed.
Prev. Pregs.- All normal (last in Jany., 1919). Patient had Pneumonia and Influenza in April, 1920.

285. W.R. Mother = Negative (3-5-). 15-10-20.
Child = Negative (3-5-). 15-10-20.

1st Preg. Single. Age 20.
L.P. 8-1-20. Leucorrhoea during last four months of pregnancy. Child born alive 12-10-20, male, weight 8½ lbs. (Mother had warts on labia). Dismissed 22-10-20, weight 7 lbs. 6 ozs.
20-2-22 - child was alive and well when 16 months old - mother still has leucorrhoea but otherwise well.

286. W.R. Mother = Negative (3∓5-). 15-10-20.
Child = Negative (3-5-). 15-10-20.

1st Preg. Single. Age 23.
L.P. 12-1-20. Child born alive 12-10-20, male, weight 5¾ lbs.
No further trace after dismissal.

Case No.

287. W.R. Mother = Negative (3-5-). 15-10-20.

2nd Preg. Married. Age 26.
L.P. 13-1-20. Contracted Pelvis: Forceps.
Admitted 12-10-20 after 30 hours labour.
Contracted Pelvis (Diag. Conj. = 4" -,
True Conj. = 3¼" - head fixed at brim.
Forceps delivery - child born alive 12-10-20
male, weight 8 lbs. R.P. Dismissed 27-10-20,
weight 7 lbs. No further trace after
dismissal.
Prev. Pregs.- Failed forceps before admission
to G.R.M.H. (May 1919) - Craniotomy.

288. W.R. Mother = Negative (3-5-). 15-10-20.

1st Preg. Single. Age 17.
L.P. 25-12-19. Normal pregnancy: Breech
presentation - prolapsed cord - Forceps
on aftercoming head. Child born alive
12-10-20 - male, weight 7½ lbs. R.P.
Dismissed 21-10-20, weight 7¼ lbs.
20-2-22 - Child alive and well when aged
16 months - a very healthy child - never
any illness.

289. W.R. Mother = Negative (3-5-). 22-10-20.
Child = Negative (3-5-). 22-10-20.

1st Preg. Single. Age 22.
L.P. second week Decr., 1919. Uterine
inertia: Forceps: P.P.H.: R.P. Child born
alive 12-10-20, male, weight 8 lbs.
Dismissed 1-11-20, weight 6¾ lbs.
11-3-22 - Child alive and well when 17 months
old - no illness.

Case No.

290. W.R. Mother = Negative (3-5-). 16-10-20.
Mother = Negative (3-5-). 5-11-20.
Child = Negative (3-5-). 5-11-20.

1st Preg. Single. Age 20.
L.P. 7-2-20. Attended Ante-natal Dispensary 15-10-20 - pain in right side: constipation: Contracted Pelvis (Diag. Conj. = 4¼", True Conj. = 3½". Admitted to Hospital 1-11-20 - Footling - Forceps applied - child born 1-11-20, male, weight 7¾ lbs. Dismissed 15-11-20, weight 7½ lbs.
Mother and child were both alive and well when child was five months old but no further trace.

291. W.R. Mother = Negative (3-5-). 15-10-20.

6th Preg. Married. Age 26.
L.P. 15-9-20. Attended Ante-natal Dispensary 15-10-20 - vomiting a good deal: constipation and poor digestion. Admitted to Hospital 8-5-21 until 11-5-21. Was readmitted 18-5-21 and child born alive 18-5-21, female, mature, weight 9 lbs. Dismissed 27-5-21, weight 8½ lbs.
24-2-22 - Child known to be alive and well when 9 months old - never any illness.
26-5-22 - Child now one year old -
W.R. Mother = Negative (3-5-).
Child = Negative (3-5-).
Prev. Pregs.- 2, normal, F.T., alive: 3 miscarriages (one at 4 months and two at 3 mos.

292. W.R. Mother = Negative (3-5-). 15-10-20.

4th Preg. Married. Age 28.
L.P. 15-6-20. Attended Ante-natal Dispensary 15-10-20 when four months pregnant - Abdominal pain.
Prev. Pregs.- 3 alive, F.T.

Case No.

293. W.R. Mother = Doubt. Negative (3+5-).22-10-20.

1st Preg. Married. Age 20.
L.P. 7-2-21. Attended Ante-natal Dispensary 15-10-20 - abdominal pain. Legs were swollen for three months: some oedema present (? urine). Has a profuse leucorrhoea. Has had congestion of lungs.

294. W.R. Mother = Negative (3-5-). 22-10-20.

6th Preg. Married. Age 31.
L.P. 1-5-20. Attended Ante-natal Dispensary 15-10-20 - profuse leucorrhoea and incontinence of urine. Admitted 17-10-20 - history of bleeding after very heavy washing. A quantity of blood came away morning of admission but no pain. Child born 20-11-20, female, alive, weight 2 lbs. Lived for two days only. Adherent placenta removed manually.
Prev. Pregs.- 1st and 3rd = F.T., Chloroform & Forceps: 2nd and 4th = F.T., normal: One abortion at six weeks (Septr., 1919). Last child born Jany., 1918 - puerperal sepsis.

295. W.R. Mother = Negative (3-5-). 22-10-20.

3rd Preg. Married. Age 24.
L.P. 6-3-20. Attended Ante-natal Dispensary 15-10-20 - headaches and weakness - uterus 7 months size. Has had " weak turns" since childhood. Child born alive in Stobhill Hospital on 19-12-20, male.
3-3-22 - The child was known to be alive when 15 months old - had Broncho-pneumonia but made a good recovery.
W.R. Mother = Negative (3-5-). 2-3-22.
Child = Negative (3-5-). 2-3-22.
Prev. Pregs.- Normal, F.T., alive - (last two years ago).

Case No.

296. W.R. Mother = Negative (3-5-). 22-10-20.

1st Preg. Married. Age 26.
L.P. 1-3-20. Attended Ante-natal Dispensary 15-10-20. Abdominal pain: headaches: constipation.

297. W.R. Mother = Strong. Positive (3+5+). 22-10-20.

Attended Ante-natal Dispensary 22-10-20 till 1-12-20 - Delivered 24-3-21 - a healthy looking male child. Dismissed 1-4-21. Attended Infant Cons. - Baby sore breasts - mother taking fainting turns.
30-9-21 - Baby better - mother also feeling better.
4-2-22 - Child 11 months old - attended R.H.S.C. where had blood tested and it was found to be negative.

298. W.R. Mother = Negative (3-5-). 22-10-20.

9th Preg. Married. Age 29.
L.P. 5-4-20. Attended Antenatal Dispensary 15-10-20 - history of miscarriages - now has severe pain in back and cough : constipation. Child born at home 2-1-21. Blood of mother and child tested 14-1-22 (child then one year old) and both found to be negative.
20-2-22 - Child not long recovered from Measles and Bronchial catarrh and at date is attending R.H.S.C. - abscess under arm.
Prev. Pregs.- 4 children born full-time: 4 miscarriages at 4 and 6 months.

Case No.

299. W.R. Mother = Negative (3-5-). 22-10-20.

3rd Preg. Married. Age 23.
L.P. 28-6-20. Attended Ante-natal Dispensary 15-10-20 - constipation till four weeks before visit - since then diarrhoea at intervals of ten days or so: Headaches. Child born at home 31-3-21 - male.
20-2-22 - Child was known to be alive and well when 11 months old.
Prev. Pregs.- F.T., normal.

300. W.R. Mother = Negative (3-5-). 22-10-20.

8th Preg. Married. Age 37.
L.P. Decr., 1919. Normal pregnancy and labour - child born alive 11-10-20, male, weight 7½ lbs. Dismissed 21-10-20, weight 7 lbs. No further trace after dismissal.
Prev. Pregs.- Normal, F.T., alive (last in Novr., 1917).

301. W.R. Mother = Negative (3-5-). 22-10-20.
Child = Negative (3-5-). 22-10-20.

1st Preg. Married. Age 22.
L.P. 5-1-20. Normal pregnancy and labour. P.P.H. Child born alive 15-10-20, female, weight 8¼ lbs. Dismissed 25-10-20, weight 6½ lbs. No further trace after dismissal.

Case No.

302. W.R. Mother = Negative (3-5-). 22-10-20.

1st Preg. Married. Age 25.
L.P. Jany., 1920. Normal pregnancy. Contracted Pelvis (Diag. Conj. = 4" +, True Conj. = 3¼" +). Forceps delivery - child born alive 15-10-20, male, weight 7½ lbs. R.P. Mother had slightly febrile puerperium.
9-3-22 - Mother well - she is a deaf mute - Child well (17 months old) and can both speak and hear.

303. W.R. Mother = Negative (3-5-). 22-10-20.

5th Preg. Married. Age 34.
L.P. 2-12-19. Child born alive 10-10-20, Dismissed 19-10-20, weight 8 lbs. No further trace after dismissal.
Prev. Pregs.- All normal, F.T., alive.

304. W.R. Mother = Negative (3-5-). 29-10-20.
Child = Negative (3-5-). 23-10-20.

9th Preg. Married. Age 47.
L.P. 27-2-20. Placenta Praevia: Version. Patient was well till 12-10-20 when there was some haemorrhage which ceased but began again with severity on 15-10-20. Admitted 15-10-20 - blanched and bleeding. Child born alive 15-10-20, male, weight 3¼ lbs. Died 30-10-20. Mother was dismissed 29-10-20.
Prev. Pregs.- 1st = F.T., alive, Chloroform & forceps: 2nd = F.T., alive, normal: 3rd and 4th = F.T., alive, normal: 5th = twins at five months - dead: 6th = F.T., alive, normal: 7th and 8th = F.T., alive, normal (1919).

Case No.

305. W.R. Mother = Negative (3+5-). 29-10-20.
Child = Negative (3-5-). 22-10-20.

1st Preg. Single. Age 18.
L.P. Jany., 1920. Normal pregnancy and labour Child born alive 16-10-20 - male, weight 9 lbs. R.P. Puerperal disturbance of temperature - threatened sepsis - uterus tender. Perineal repair gave way - septic. Uterus involuting fairly well on dismissal 19-11-20.
20-2-22 - Child known to be alive and well when aged 16 months - never any illness: Mother well.

306. W.R. Mother = Negative (3-5-). 29-10-20.
Child = Negative (3-5-). 29-10-20.

2nd Preg. Married. Age 32.
L.P. Jany., 1920. Admitted 20-10-20 - Albuminuria and very slight oedema of legs. Severe headaches and epigastric pain for some time before admission. Child born alive 21-10-20 - female, weight 6¼ lbs. Mother's urine clearing up before dismissal on 30-10-20, child's weight = 5½ lbs.
25-2-22 - Child alive and well when aged 16 months - no illness. Mother also well.
Prev. Preg.- Normal, F.T.

307. W.R. Mother = Negative (3-5-). 22-10-20.

6th Preg. Married. Age 30.
L.P. 19-12-19. Normal pregnancy and labour. Child born alive 25-9-20, male, mature, weight 10¼ lbs. Slight P.P.H. Dismissed 23-10-20, weight 9 lbs.
The child died in R.H.S.C. on 22-9-21 when 11 months old -'Vomiting and Diarrhoea'.
Prev. Pregs.- No record.

Case No.

308. W.R. Mother = Negative (3-5-). 22-10-20.
Child = Negative (3-5-). 22-10-20.

1st Preg. Single. Age 23.
L.P. 15-12-19. Persistent occipito-posterior - rotated manually and delivered with forceps. Pelvis - Diag. Conj. = 4½", True Conj. = 3¾". Child born alive 20-10-20 - male, weight 8 lbs. Dismissed 29-10-20, weight 7½ lbs.
20-2-22 - The child was known to be alive and well when aged 16 months - no illness: Mother also well.

309. W.R. Mother = Str. Positive (3+5+). 22-10-20.
Child = Str. Positive (3+5+). 29-10-20.

1st Preg. Single. Age 22.
L.P. 20-1-20. Admitted 20-10-20 - mother had condylomata round arms and on perineum. Child born alive 20-10-20, male, weight 6 lbs. Mother had febrile puerperium. Retained placenta removed manually. Mother and child dismissed 1-11-20. Mother and child admitted to Lock Hospital 19-12-20. At 18-1-21 - both were reported to be getting on well - living at Salvation Army Home and continuing treatment. 15-2-22 - Child well.
18-6-22 - Both well - child now one year & eight months - has strabismus - Blood of Mother = Str. Positive (3+5+). 8-6-22
Child = Str. Positive (3+5+). 8-6-22.

310. W.R. Mother = Negative (3-5-). 22-10-20.
Child = Negative (3-5-). 5-11-20.

9th Preg. Married. Age 30.
L.P. Jany., 1920. Admitted to Ante-natal Dept. 14-10-20. Patient was well throughout pregnancy till injured in a tramcar accident three weeks before admission - shock, etc. Child born alive 1-11-20, female, weight 8¼ lbs. Dismissed 9-11-20, weight 8 lbs. No further trace after dismissal.
Prev. Pregs.- 1st = F.T., normal: 2nd = premature (8 months) lived 4 weeks: 3rd & 4th = 3½ months miscarriages: 5th = F.T.: 6th = F.T. - protracted labour: 7th = threatened appendicitis: 8th = normal.

Case No.

311. W.R. Mother= Negative (3-5-). 29-10-20.
Child = Negative (3-5-). 22-10-20.

2nd Preg. Married. Age 24.
L.P. early Jany., 1920. Child born alive 21-10-20, male, weight 8½ lbs. - labour began three days before delivery. Dismissed 30-10-20, weight 8 lbs. No trace after dismissal.
Prev. Preg.- Twins (locked) S.B., instrs. in G.R.M.H. in Jany., 1919.

312. W.R. Mother = Negative (3-5-). 22-10-20.

3rd Preg. Married. Age 31.
L.P. Jany., 1920. Admitted 14-10-20 - Pelvis - Diag. Conj. = 4½", True Conj. = 3¾". Dismissed 23-10-20 - false labour.
Prev. Pregs.- normal (last in Aug., 1919).

313. W.R. Mother = Doubt. Negative (3∓5-). 22-10-20.

5th Preg. Married. Age 35.
L.P. 21-7-20. Patient was well till a few days before admission when she began to have pain on micturition, bearing down pains and headache - sent in as albuminuria but no albumen found. Admitted 17-10-20 - uterus enlarged (2½ months) and anteflexed. Dismissed undelivered 22-10-20.
Prev. Pregs.- All protracted labours - forceps with first. History of acute nephritis four years before date of admission.

Case No.

314. W.R. Mother = Negative (3-5-). 22-10-20.

2nd Preg. Married. Age 26.
L.P. 16-7-20. Admitted to Ante-natal Dept. from Dispensary 19-10-20 - Threatened Abortion. Had flooding three weeks before admission - treated with douches. Haemorrhage eleven days before with pains across back and tip of coccyx.
Prev. Preg.- Chloroform & instrs - white swelling (9 months before admission).

315. W.R. Mother = Negative (3-5-). 22-10-20.

2nd Preg. Married. Age 22.
L.P. 23-2-20. Admitted to Ante-natal Dept. 19-10-20. Patient was well till five days before admission when began to have pains on micturition and frequency. Pain in back and headaches daily - urine noticed to be red in colour: vomiting and flatulence after food. Pains shooting down legs - never over shoulder. Very slight oedema of ankles: no albuminuria and no blood. Uric acid. Tenderness over right kidney. Temperature and pulse elevated. Dismissed 28-10-20.
Prev. Preg.- normal (3 years before admission). Bronchitis one year ago.

316. W.R. Mother = Negative (3-5-). 29-10-20.

4th Preg. Married. Age 30.
L.P. ? Threatened abortion. Began to bleed six days before admission - some clot passed each day. Admitted 16-10-20 - uterus not palpable. Slight bleeding for about six days after admission. No albuminuria. Dismissed 29-10-20.
Prev. Pregs.- 1st and 2nd ?: 3rd = miscarriage (?stage) in March, 1920.

Case No.

317. W.R. Mother = Positive (3+5$\overset{=}{+}$). 29-10-20.

1st Preg. Married. Age 24.
L.P. end of Jany., 1920.
Admitted to Ante-natal Dept. 19-10-20 - Contracted Pelvis (Diag. Conj. = 4¼"+: True Conj. = 3½" -). Caesarean section 6-11-20 - child born alive, female, weight 7½ lbs. Child died Decr., 1920 when about nine weeks old. No treatment for mother.

318. W.R. Mother = Weak. Positive (3$\overset{+}{-}$5-). 29-10-20.

1st Preg. Single. Age ?.
Attended Ante-natal Dispensary. Was delivered in Duke St. Hospital on 17-11-20.
After dismissal from Hospital attended an Inf. Welfare centre but no "special treatment."
20-2-22 - Child 15 months old and in Stobhill (for relief only).

319. W.R. Mother = Negative (3-5-). 29-10-20.

3rd Preg. Married. Age 25.
L.P. ? April, 1920.
Attended Antenatal Dispensary 22-10-20.
Prev. Pregs.- 2 alive, F.T., normal (last in May, 1919).

Case No.

320. W.R. Mother = Weak. Positive (3±5-). 29-10-20.
Child = Negative (3-5-). 28-12-20.

7th Preg. Married. Age 40.
L.P. Feby./March, 1920. Attended Ante-natal Dispensary from 22-10-20 to 2-12-20 - Diarrhoea and fainting turns: varicose veins both legs. Admitted to Hospital 23-12-20 - Normal labour - child born alive 23-12-20, Female, weight 8¼ lbs. Dismissed 31-12-20, weight 8¼ lbs. Mother and child attended Dispensary 14-1-22 - Grave's disease, Pulse 136. Goitre. No ocular symptoms - W.R. Mother = Negative (3-5-).
Child = Negative (3-5-).
20-2-22 - Child 14 months old and very well.
Prev. Pregs.- All full-time, alive, normal - last 8½ years ago.

321. W.R. Mother = Str. Positive (3+5+). 29-10-20.
Mother = Str. Positive (3+5+). 17-12-20.
Child = Str. Positive (3+5+). 17-12-20.

2nd Preg. Single. Age 30.
Normal pregnancy and labour - child born alive 3-12-20, male, mature, weight 8 lbs.
1-2-22 - Both well - child 14 months old. No treatment.
Prev. Preg.- normal, F.T., alive (April, 1916).

322. W.R. Mother = Negative (3-5-). 29-10-20.
Child = Negative (3-5-). 5-11-20.

2nd Preg. Married. Age 22.
L.P. ? Jany., 1920. Attended Ante-natal Dispensary. Admitted to Hospital 26-10-20 - Normal labour - child born alive 26-10-20, premature, male, weight 5½ lbs. Dismissed 5-11-20, weight 6 lbs. Child died 13-12-20.
Prev. Preg. - normal, F.T. (March, 1919).

Case No.

323. W.R. Mother = Weak. Positive ($3^{+}5^{\mp}$). 29-12-20.

4th Preg. Married. ? Age.
L.P. 15-3-20. Attended Ante-natal Dispensary 15-10-20. Child born alive 19-12-20 - male. After dismissal from Hospital attended Infant Consultations - 14-1-21 - child well. 15-2-21 - Child now clinicall syphilitic - rash, copper-coloured patches, coffee skin, etc. 4-3-21 - Baby said to have pain in left side. 14-4-21 - Patient pale and ill - complaining of sore breasts. 14-1-22 - Child now 13 months old -
W.R. Mother = Negative ($3^{\mp}5-$)17-1-22.
Child = Negative (3-5-)17-1-22.
Prev. Pregs.- All full-time, alive, normal (last was born 26-1-19 and died when six weeks old).

324. W.R. Mother = Negative (3-5-). 29-10-20.

2nd Preg. Married. Age 30.
L.P. ?. Attended Ante-natal Dispensary 22-10-20 - not sure how far on. Child born alive 26-10-20 - male, premature (8 months) No further trace.
Prev. Preg.- F.T., alive (is delicate - has T.B. abscess), 11 years ago.

Case No.

325. W.R. Mother = Doubt. Positive (3+5-). 29-10-20.

2nd Preg. Married. Age 25.
L.P. 24-6-20. Attended Ante-natal Dispensary 22-10-20 - irregular menstruation and menorrhagia before onset of pregnancy. Frequent micturition with incontinence - (Albumen +). Slight leucorrhoea. Admitted to Ante-natal Dept. 14-3-21 to 18-3-21 - Contracted Pelvis (C.V. = 3½"). Readmitted to Hospital 11-4-21 - spontaneous delivery - child born alive 11-4-21, female, weight 6½lbs. Dismissed 21-4-21, weight 7½ lbs.
26-5-22 - Both well - child 14 months old.
Prev. Pregs.- 1st = F.T., normal (Feby., 1919) died when two weeks old.

326. W.R. Mother = Negative (3+5-). 29-10-20.
Child = Negative (3-5-). 29-10-20.

2nd Preg. Married. Age 21.
L.P. - Amenorrhoea since last pregnancy. Contracted Pelvis - (Diag. Conj. = 4¼" +, True Conj. = 3½" +). Knock-knees, tibial curves. Occipito-posterior presentation - Forceps delivery - child born alive 22-10-20, male, weight 8 lbs. Dismissed 1-11-20, weight 7¼ lbs. No further trace after dismissal.
Prev. Preg.- F.T., forceps, alive (Octr., 1919).

327. W.R. Mother = Negative (3-5-). 29-10-20.
Child = Negative (3-5-). 29-10-20.

1st Preg. Single. Age 17.
L.P. 18-1-20. Pregnancy was normal till onset of labour on 23-10-20 - child born alive 24-10-20, male, weight 9 lbs. Immediately after delivery mother had two severe eclamptic fits and a quantity of dark reddish brown fluid washed out of stomach. Albumen ++ - no diacetic acid or acetone. Dismissed 3-11-20, weight 7½ lbs.
22-2-22 - The child was known to be alive and well when aged 16 months - had one serious illness - Bronchitis.

Case No.

328. W.R. Mother = Str. Positive (3+5+). 29-10-20.
Child = Str. Positive (3+5+). 29-10-20.

2nd Preg. Married. Age 25.
L.P. 17-1-20. Pelvis - Diag. Conj. = 4¼"+, True Conj. = 3½" +. Normal labour - child born alive 23-10-20, female, weight 6½ lbs. Dismissed 31-10-20, weight 6 lbs.
22-2-22 - Child, now 16 months old, just recovering from measles and is very thin and does not look well: mother well. No treatment for either mother or child.
Prev. Preg.- prolonged labour, craniotomy (Novr., 1917).

329. W.R. Mother = Negative (3-5-). 29-10-20.
Child = Negative (3-5-). 29-10-20.

1st Preg. Married. Age 21.
L.P. Jany., 1920. Normal pregnancy and labour - child born alive 23-10-20, female, weight 6 lbs. Dismissed 2-11-20. Attended Infant consultations regularly until 30-7-21 - child thriving. 9-3-22 - Child 17 months old and both mother and child well.

330. W.R. Mother = Negative (3-5-). 29-10-20.
Child = Negative (3-5-). 29-10-20.

1st Preg. Married. Age 22.
L.P. 10-1-20. Throughout the pregnancy patient had loss of appetite and sickness. Contracted Pelvis (Diag. Conj. = 3¾", True Conj. = 3"+). Admitted on 23-10-20 - after 12 hours labour - after 24 hours more forceps were applied and the child was delivered with great difficulty on 24-10-20, male, alive, weight 8½ lbs. Patient had marked jaundice during the puerperium but recovered before dismissal on 17-11-20. The baby died on 4-11-20 - P.M. exam.

Case No.

331. W.R. Mother = Negative (3-5-). 29-10-20.

8th Preg. Married. Age 43.
L.P. June, 1920. Incomplete Abortion. Bleeding began ten weeks before admission - slight and persistent ever since and was severe three days before admission. Admitted 23-10-20 - uterus explored and curetted. Dismissed 30-10-20.
Prev. Pregs.- 1st = normal, still-born: all other full-time, alive (last in May, 1919).

332. W.R. Mother = Negative (3-5-). 29-10-20.
Child = Negative (3-5-). 29-10-20.

4th Preg. Married. Age 32.
L.P. 23-1-20. Persistent vomiting throughout present pregnancy - Attended Ante-natal Dispensary - " neuritis in legs" . Normal labour - child born alive 24-10-20, male, weight 8 lbs. Dismissed 2-11-20.
26-5-22 - Both well - child aged 19 months -
W.R. Mother = Negative (3-5-). 26-5-22.
Child = Negative (3-5-). 26-5-22.
Prev. Pregs.- 1st to 3rd = normal, F.T. (last in 1915): The third child died of peritonitis at the age of three years. Patient had chorea as a child.

333. W.R. Mother = Negative (3-5-). 29-10-20.
Child = Negative (3-5-). 29-10-20.

1st Preg. Married. Age 19.
L.P. 3-1-20. Slightly contracted pelvis (Diag. Conj. = 4¼" , True Conj. = 3½"). Normal labour - child born alive 22-10-20, female, weight 8½ lbs. Dismissed 31-10-20, weight 8½ lbs.
17-3-22 - Child was well when aged 17 months- never any illness.

Case No.

334. W.R. Mother = Str. Positive (3+5+). 29-10-20.

1st Preg. Married. Age 20.
L.P. 27-1-20. Cough and hoarseness and eyes inflamed throughout pregnancy. Normal labour - child born alive 21-10-20 (slightly premature) male, weight 5½ lbs. Dismissed 30-10-20, weight 5¼ lbs. The child died of convulsions on 8-11-20.

335. W.R. Mother = Negative (3-5-). 29-10-20.

1st Preg. Married. Age 27.
L.P. end of Jany., 1920. Occipito-posterior presentation - Forceps delivery-child born alive 21-10-20, weight 8¼ lbs. R.P. 9-3-22 - Child 17 months old and very healthy.

336. W.R. Mother = Negative (3-5-). 29-10-20.
Child = Negative (3-5-). 29-10-20.

3rd Preg. Married. Age 37.
L.P. Jany., 1920. Placenta Praevia (lateral). Patient had slight painless bleeding at third month and again fourteen days before admission and fairly severe bleeding on 24-10-20 just before admission. Patient said she menstruated for three days in Feby., 1920. Pelvis - promontory marked but no contraction. Admitted 24-10-20 - slight bleeding at 4 a.m. At 7 p.m. severe bleeding - membranes were ruptured artificially (breech presenting) - foot brought down - child was then alive. Child born dead at 8-50 a.m. 24-10-20, male, weight 6¼ lbs. Fracture of left parietal bone. P.M. exam.
Prev. Pregs.- 1st = premature, S.B. - painless labour: 2nd = miscarriage.

Case No.

337. W. R. Mother = Str. Positive (3+5±). 29-10-20.

3rd Preg. Married. Age 23.
L.P. Decr., 1919. Contracted Pelvis (Diag. Conj. = 3¾" +, True Conj. = 3" +). Cord presenting. Caesarean Section (not sterilised). Child born alive 21-10-20, male, weight 7 lbs. Dismissed 11-10-20, weight 6½ lbs. Child was in attendance at R.H.S.C. Disp. after dismissal from G.R.M.H. - attended five times until seven months old. Looks very healthy. Mother not feeling well but nothing definite.
W.R. Mother = Negative (3-5-). 27-1-22.
Child = Negative (3-5-). 27-1-22.
22-2-22 - child was known to be alive and well when 16 months old.
Prev. Pregs.- 1st = Chlor. & Instrs. (Aug., 1918)- child died when 14 months: 2nd = miscarriage at five months (Septr., 1919).

338. W.R. Mother = Negative (3=+5-). 29-10-20.
Child = Negative (3-5-). 29-10-20.

1st Preg. Married. Age 26.
L.P. ? Jany., 1920. Admitted to Ante-natal Dept. - Marked rickets : Contracted Pelvis (Diag. Conj. = 4" +, True Conj. = 3¼" - outlet small. Induction - bougies - Child born alive 24-10-20, female, weight 4¾ lbs. , premature (27 hours labour). The child could be made to breathe only with difficulty. It had one or two bad turns when its colour became blue. It died at 2-45 a.m. 25-10-20 - P.M. exam.

339. W.R. Mother = Str. Pos. (3+5+). 29-10-20.
Child = Str. Pos. (3+5+). 29-10-20.

8th Preg. Married. Age 29.
L.P. end Feby., 1920. Patient was well till 19-10-20 when pain began - had some bleeding on 20-10-20 which persisted intermittently. Child was born alive 23-10-20, female, weight 5¾ lbs. but died same day. P.M. exam. Patient died from puerperal sepsis 4-11-20.
Prev. Pregs.- 1st - 6th = normal, F.T., alive: 7th (Jany., 1918) = Twins - 6½ months - alive.

Case No.

340. W.R. Mother = Negative (3-5-). 29-10-20.
Child = Negative (3-5-). 29-10-20.

1st Pregnancy. Married. Age 24.
L.P. February, 1920.
Child born 24-10-20, male, weight 7¼ lbs. Normal labour. Ruptured Perineum.
Mother had mastitis during puerperium.
Dismissed 13-11-20, weight 7 lbs.
Child died - convulsions - on 26-11-20.

341. W.R. Mother = Doubt. Positive (3±5-) 29-10-20.
Mother = Negative (3-5-). 20-11-20.
Child = Negative (3-5-). 29-10-20.

1st Pregnancy. Single. Age 21.
L.P. end of Jany., 1919.
Child born 24-10-20, Female, weight 9 lbs.
Normale labour: Ruptured Perineum: P.P.H.
Dismissed 4-11-20, weight 8½ lbs.
1-3-22. Child alive and well - now 16 months.

342. W.R. Mother = Negative (3-5-). 29-10-20.

1st Pregnancy. Single. Age 21.
L.P. 16-1-20.
Child born 23-10-20, male, weight 8 lbs.
Normal labour.
Dismissed 2-11-20.
23-3-21 - Child known to be alive and well - then 5 months.

343. W.R. Mother = Positive (3+5-) 29-10-20.

1st Pregnancy. Married. Age 21.
L.P. 20-1-20.
Mother had varicose veins in latter months of pregnancy but was otherwise well. Marked tibial curves.
Child born 24-10-20, Female, weight 5¾ lbs. - Face converted to vertex.
Dismissed 2-11-20.
Attended Infant Consultations regularly till 1 year. Both mother and child well when last seen.

Case No.

344. W.R. Mother = Negative (3-5-). 29-10-20.
Child = Negative (3-5-). 29-10-20.

1st Preg. Married. Age 26.
L.P. 16-1-20. Admitted to Ante-natal Dept. 23-10-20 - slightly contracted outlet. Child born alive (spontaneously) 23-10-20, Female, weight 5½ lbs. Dismissed 3-11-20, weight 6 lbs.
18-11-20 - Child 13 months old and very well - never had any illness.

345. W.R. Mother = Negative (3-5-). 29-10-20.

1st Preg. Single. Age 23.
L.P. 20-1-20. Child born alive (normal labour) 24-10-20, Female, weight 6¾ lbs. Dismissed 4-11-20, weight 6 lbs.
18-11-21 - Child very well - now aged 13 months and so far no illness.

346. W.R. Mother = Str. Positive (3+5+). 29-10-20.
Mother = Str. Positive (3+5+). 5-11-20.

11th Preg. Married. Age 36.
L.P. 19-6-20. Ante-partum Haemorrhage: Threatened Abortion. Admitted 21-10-20 - one month before admission had slight haemorrhage but nothing further noted till week before admission when quantities of clot came away - since then slight haemorrhagic discharge. On admission patient was pale - uterus two fingers below umbilicus. Dismissed 11-11-20. Patient was re-admitted and child was born alive on 22-2-21, mature, weight 6½ lbs. Dismissed 4-3-21, weight 6½ lbs.
28-7-21 - a home visit was paid and patient was fairly well but had headaches recently and looked anaemic. Baby tendency to diarrhoea - green stools - for fourteen days but was otherwise well.
23-2-22 - Child very ill - Measles & Pneumonia. The older child (2¼ years) died three weeks ago - Measles and Pneumonia.
30-3-22 - Child (now 13 months old) has discharge from nose - W.R. Mother = Doubt. Neg.(3+5-).
Child = Negative (3-5-).
Prev. Pregs.- 7 = normal, F.T., alive (last in Octr., 1919): 3 miscarriages at - 2 at three months and 1 at 3½ months (last in 1918).

Case No.

347. W.R. Mother = Negative (3-5-). 29-10-20.
Child = Negative (3-5-). 29-10-20.

10th Preg. Married. Age 42.
L.P. early in February, 1920.
Arm presentation - converted to footling - Breech delivery - Child born alive 23-10-20, female, weight 7¾ lbs. Dismissed 1-11-20, weight 6¾ lbs. Patient has eye trouble and is now blind in both eyes. Has old and marked iritis with posterior synechia in left eye. Right eye appears normal externally - prominent.
20-2-22 - Child 16 months old and very well - never any illness.

348. W.R. Mother = Negative (3-5-). 29-10-20.

4th Preg. Married. Age 40.
L.P. 31-7-20. Incomplete Abortion. Admitted 19-10-20 - slight haemorrhage 24 hours before admission which became very severe later and just before admission some large clots were passed. Curetted and swabbed. I. U. D. Dismissed 25-10-20.
Prev. Pregs. - 1st = Chlor. & Instr. - slight haem. at 10th week: 2nd = premature (7 mos.) after A.P.H. - S.B.: 3rd = normal in July, 1919.

349. W.R. Mother = Negative (3∓5-). 29-10-20.

1st Preg. Married. Age 25.
L.P. early April, 1920. Patient in Ante-natal wards - Has never felt well throughout whole of pregnancy - was treated for stone in kidney twelve weeks before admssion and improved temporarily, but has had severe spasmodic pain on left side at first but latterly always on right side. It shoots round back and is relieved by warmth. Pyuria on admission (22-10-20). Coliform bacillus found in urine. Labour induced - bougies - children born alive 1-11-20 - twins (both male) premature, weight of each = 3½ lbs. Both died shortly after birth.

Case No.

350. W.R. Mother = Negative (3-5-). 29-10-20.

3rd Preg. Married. Age 27.
L.P. early Feby., 1920. Admitted to Ante-natal Dept. 21-10-20 - Contracted Pelvis (Diag. Conj. = 4¼"+, True Conj. = 3½" +). Dismissed 30-10-20 - to return in labour.
Prev. Pregs.- Both labours instrumental - both children alive (the first died when three months old).

351. W.R. Mother = Negative (3=5-). 29-10-20.

9th Preg. Married. Age 40.
L.P. Jany., 1920. For four weeks before labour commenced patient had headaches, swollen feet and frequent micturition (? albuminuria). Transverse presentation - hand prolapsed, version to footling. Child's left shoulder damaged. Child born 22-10-20, male, alive, weight 11 lbs. Child was not well on 26-10-20- had slight convulsions - temperature elevated- respirations rapid - Broncho-pneumonia. Child died 2-11-20.
Prev. Pregs.- 1st to 4th = F.T., alive: 5th = F.T., normal, S.B.: 6th and 7th = F.T., normal, alive: 8th = F.T., S.B. (1917).

352. W.R. Mother = Negative (3=5-). 29-10-20.

1st Preg. Married. Age 26.
L.P. Jany., 1920. Patient has had pain in stomach for some months - especially on lying down at nights. Noticed swelling of feet and legs for about fourteen days - no headaches, no dimness of vision. Admitted 18-10-20 - very marked oedema of legs, abdomen and vulva. Urine loaded with albumen but no acetone or diacetic acid. Mental condition clear. Children born - both male - both breech -(first impacted) 19-10-20. Adherent placenta. Weights of children at birth = 7 lbs. and 6¼ lbs. Mother improved greatly after delivery - urine cleared up. Dismissed 6-11-20, weights 7¼ lbs. and 6¾ lbs.
18-11-21 - One child died when six months old, the other is very healthy. 26-5-22 - Mother and child both well - child now 19 months and so far no illness.

Case No.

353. W.R. Mother = Negative (3-5-). 29-10-20.
Child = Negative (3-5-). 29-10-20.

2nd Preg. Single. Age 26.
L.P. 15-1-20. Contracted Pelvis (Diag. Conj. = 4¼", True Conj. = 3½") - Outlet small - projecting sacral promontory. The tibiae are curved. Spontaneous delivery - child born alive 21-10-20, Female, weight 7 lbs. Dismissed 30-10-20, weight 7 lbs. Child attended Infant Consultations regularly until five months old - then gaining well but no further trace.

354. W.R. Mother = Negative (3-5-). 29-10-20.

3rd Preg. Married. Age 25.
L.P. Jany., 1920. Normal labour - child born alive 18-10-20, male, weight 8¼ lbs. Dismissed 28-10-20, weight 8½ lbs.
11-11-21 - Child 13 months old and very healthy - only illness was Whooping-cough.
Prev. Pregs.- 1st = F.T., S.B., spon.:
2nd = F.T., living, spon.

355. W.R. Mother = Negative (3-5-). 29-10-20.
Child = Negative (3-5-). 29-10-20.

1st Preg. Single. Age 22.
L.P. Jany., 1920. Normal labour - child born alive 25-10-20, weight 7½ lbs. R.P. Dismissed 3-11-20, weight 7½ lbs.
22-2-22 - Both mother and child well - child 16 months old and never any illness.
W.R. Mother = Negative (3-5-). 3-3-22.
Child = Negative (3-5-). 3-3-22.

356. W.R. Mother = Negative (3-5-). 29-10-20.
Child = Negative (3-5-). 29-10-20.

1st Preg. Married. Age 24.
L.P. Jany., 1920. Contracted Pelvis (Diag. Conj. = 4¼", True Conj. = 3½" +). Normal delivery - child born alive 21-10-20, male, weight 7½ lbs. Dismissed 30-10-20, weight 7¼ lbs.
28-2-22 - Both well. Child 16 months old and so far no illness.

Case No.

357. W.R. Mother = Negative (3-5-). 29-10-20.
Child = Negative (3-5-). 29-10-20.

1st Preg. Single. Age 19.
L.P. 25-2-20. Normal delivery - child born alive 25-10-20, male, weight 9¼ lbs. Dismissed 3-11-20.
22-2-22 - Child alive and well - only illness was Whooping-cough. Now 16 months old.
26-5-22 - Both well. Baby has had measles but now better. W.R. Mother = Negative
Child = Negative.

358. W.R. Mother = Negative (3-5-). 29-10-20.
Child = Negative (3-5-). 23-10-20.

1st Preg. Married. Age 20.
L.P. early Decr., 1919. Admitted to Ante-natal Dept. 11-8-20 - Contracted Pelvis. Patient was well till one week before admission when sickness and vomiting began. Dismissed from Hospital and was re-admitted 13-10-20 - child born 17-10-20, male, weight 6¾ lbs. Dismissed 27-10-20, weight 6 lbs. No trace after child one month old.

359. W.R. Mother = Doubt. Neg. (3∓5-). 29-10-20.
Mother = Negative (3-5-). 5-11-20.

2nd Preg. Married. Age 30.
L.P. Jany., 1920. Occipito-posterior: Contracted Pelvis (True Conj. = 3½"). In July patient complained of pain on micturition, shivering and scanty urine - was in bed for fourteen days. Admitted to Hospital 25-10-20 - after 24 hours labour - head had rotated when examined (sent in as persistent occipito-posterior). Marked head moulding and overlapping of bones. Child born 25-10-20, alive, male, mature, weight 7½ lbs. Retained placenta - uterus explored and curetted. Ruptured perineum repaired. Dismissed 29-11-20.
21-2-22 - Child alive and well - had whooping-cough a year ago and measles four months ago.
26-5-22 - Both well (child 19 months old).
W.R. Mother = Doubt. Neg.
Child = Negative.

Case No.

360. W.R. Mother = Negative (3-5-). 29-10-20.

2nd Preg. Single. Age 25.
L.P. Feby., 1920. Vaginal discharge. Skin rash about vulva and anus suggesting syphilis. Child born 22-10-20, female, alive, weight 6 lbs. Dismissed 4-11-20, weight 6 lbs. Child died of septic poisoning on 12-11-20.

361. W.R. Mother = Negative (3∓5-). 29-10-20.

2nd Preg. Married. Age 20.
L.P. Decr., 1919. Pelvis - external conj. = 4½", True Conj. = 3¾" - outlet small. Normal labour - child born alive 20-10-20, male, weight 6 lbs. Dismissed 30-10-20. Child died of Pneumonia on 30-10-20 when 11½ months old.
Prev. Preg.- F.T., normal, alive (Octr., 1919).

362. W.R. Mother = Doubt. Pos. (3∓5∓). 5-11-20.
Child = Negative (3-5-). 29-10-20.

1st Preg. Single. Age 19.
L.P. Jany., 1920. Normal pregnancy and labour. Severe post-partum haemorrhage - uterus packed, etc. Normal labour - child born alive 25-10-20, female, weight 7½ lbs. Dismissed 4-11-20, weight 7 lbs.
21-2-22 - Child alive but very ill at present (16 months old).

363. W.R. Mother = Str. Positive (3+5+). 29-10-20.

1st Preg. Single. Age 22.
L.P. ? July, 1920. Complete Abortion. Had some bleeding fourteen days before admission which continued till 11-10-20 when pains began. Admitted 22-10-20. Never felt life. Patient was pale but otherwise healthy. Foetus and placenta expelled shortly after admission. Placenta was complete but looked unhealthy and membranes were ragged and deficient. Sores on vulva. Syphilitic clinically.

Case No.

364. W.R. Mother = Str. Positive (3+5+). 5-11-20.
Child = Str. Positive (3+5+).29-10-20.

6th Preg. Married. Age 25.
L.P. Jany., 1920. Normal delivery - child born alive 25-10-20, male, Full-time, weight 7½ lbs. Dismissed 3-11-20, weight 8 lbs.
Mother and one other child were being treated at R.H.S.C. - mother's last injection was five days before admission to G.R.M.H. Mother was advised to take baby (6th) for treatment. Child's blood was sent from R.H.S.C. (taken off 21-12-20) - W.R. = Weakly positive (3-5+C-). Same specimen on 30-12-20 = 3 - 4 - 5 - 6 - C -.
23-2-22 - Both mother and child seemed well - child suffers from Diarrhoea but this the only complaint. No further treatment for either.
23-3-22 - Mother now five months pregnant - no treatment - only fairly well. Child (now 17 months old) has mucous patches at angles of mouth and discharge from nose. No rash. Spleen not palpable. W.R. Child = Negative.
Prev. Pregs.- 1st = F.T., S.B., normal, puerperal sepsis: 2nd and 3rd = F.T., S.B., (3-8-16): 4th = Abortion at two months: 5th = Abortion at two months (March, 1918).

365. W.R. Mother = Str. Positive (3+5+). 29-10-20.
Child = Negative (3-5-). 29-10-20.

5th Preg. Married. Age 33.
L.P. Jany., 1920. Normal pregnancy and labour - child born alivr 26-10-20, male, weight 8¾ lbs. Dismissed 5-11-20, weight 8 lbs. No further trace after dismissal.
Prev. Pregs.- 1st, 2nd and 3rd = normal, Full-time, alive (last 17-1-19): 4th = miscarriage (may, 1919).

366. W.R. Mother = Negative (3-5-). 29-10-20.

6th Preg. Married. Age 30.
L.P. 22-7-20. Admitted to Ante-natal Dept. 20-10-20. Patient was well till a few days before admission when pain and bleeding began - was wearing a pessary for 'prolapse' which dates from last miscarriage. Inevitable Abortion - curetted 25-10-20, douched & swabbed.
Prev. Pregs.- 1st - 4th = F.T., living, normal: 5th = 2½ - 3 months abortion (Jany., 1920).

Case No.

367. W.R. Mother = Negative (3 ∓ 5-). 29-10-20.

8th Pregnancy. Married. Age 39.
L.P. 10th Feby., 1920.
Pain in left side: headaches about one month: Epigastric pain and swelling of legs.
Admitted 20-10:20, oedema of legs: slight oedema under eyes. Albuminuria(++) - Uterus about 8 months size - child alive. Slightly Contracted Pelvis (Diag. Conj. = 4¼ inches, True Conj. = 3½ inches).
Dismissed undelivered 1-11-20.

Previous Pregnancies.- 1st = 7 months, alive, spontaneous: 2nd = 5ransverse, alive, CH.clz. & Forceps: 3rd = full-time, alive, CH.clz. & Instrs. (1912): 4th = 3 months miscarriage: 5th, 6th and 7th = 3 months miscarriage (last in 1915 (curetted). Had osteomystitic left Tibia 5 years ago: had one ovary removed one year ago. Has had excessive sickness with all pregnancies and some albuminuria in last (7th).

368. W.R. Mother = Negative (3-5-). 5-11-20.
Child = Negative (3-5-). 29-10-20.

2nd Pregnancy. Single. Age 21.
L.P. 5-1-20. Normal pregnancy.
Child born 24-10-20, male, weight 8½ lbs.
Mother has nasty vaginal discharge - No G.C. found but bacilli coliform and streptococci found.
Dismissed 4-11-20, weight 8½ lbs.
Child was known to be alive and well at 16 months.

Previous Pregnancy was normal, full-time, living.

369. W.R. Mother = Negative (3-5-) 29-10-20.

12th Pregnancy. Married. Age 40.
L.P. Jany., 1920.
Contracted Pelvis (Diag. Conj. = 4¼ inches, True Conj. = 3½ inches). Occipito-posterior - later changed spontaneously to brow - forceps applied after flexion - failed - cord now prolapsed and pulseless. Craniotomy - child born 21-10-20 (long labour) Female, weight 9 lbs.(S.B.)
Previous Pregs.- 11 labours - Chloroform and Instrs. with all - 6 born alive, 5 born dead. Mother was a fat, flabby woman who made no use of her pains.

Case No.

370. W.R. Mother = Negative (3-5-) 29-10-20.
Child = Negative (3-5-) 29-10-20.

1st Pregnancy. Single. Age 21.
L.P. 12-1-20.
Patient had Bright's Disease in 1914 and 1916. States that swelling of face occurs periodically. On admission (21-10-20) marked oedema of ankles and legs: slight oedema of face: Albuminuria.
Child born 21-10-20 - delayed 2nd stage - Forceps - slight rupture of perineum. Child alive, Female, weight 7¾ lbs.
Dismissed 6-11-20, weight 7 ¼ lbs.
No further trace after dismissal.

371. W.R. Mother = Negative (3-5-). 5-11-20.
Child = Negative (3-5-). 29-10-20.

1st Pregnancy. Single. Age 27.
L.P. 1-1-20.
Child born 26-10-20, Female, weight 7 lbs., died 19-11-20. Labour normal: Ruptured Perineum.
Patient was dismissed on 15-11-20.

372. W.R. Mother = Negative (3-5-). 5-11-20.
Child = Negative (3-5-). 5-11-20.

6th Pregnancy. Married. Age 34.
L.P. Jany., 1920.
Pregnancy uneventful throughout: no headaches but says feet were slightly swollen for last 2-3 months.
Child born 27-10-20 - normal labour - Female, alive, weight 8½ lbs.
Dismissed 5-11-20, weight 8 lbs.
Child was known to be alive and well at 16 months - no illnesses.

Previous Pregnancies.- 3 normal, F.T. living children (last in 1915): 2 miscarriages - one at 2 months between 1st and 2nd children: one at 2 months between 2nd and 3rd children (last in 1914).
Mother has been almost blind since she had measles at the age of 2 years. Operation for 'misplaced womb' in 1913 (G.R.I.)

Case No.

373. W.R. Mother = Negative (3-5-). 5-11-20.
Child = Negative (3-5-). 5-11-20.

3rd Preg. Married. Age 33.
L.P. 4-2-20. Patient was fairly well throughout pregnancy - had occasional 'bilious attacks' with bad headache, and was easily tired. Normal delivery - child born alive 27-10-20, male, weight 6½ lbs. R.P. Dismissed 5-11-20, weight 6 lbs.
1-3-22- Both mother and child well when child aged 16 months-W.R. Mother = D. Pos. (3±5-).
Child = Negative (3-5-).
Prev. Pregs.- 1st = 8 months, alive (March, 1916): 2nd =(3 months)miscarriage (March, 1919).

374. W.R. Mother = Negative (3-5-). 29-10-20.
Child = Negative (3-5-). 29-10-20.

1st Preg. Married.
L.P. 30-1-20. Patient was well throughout pregnancy but noticed swelling of legs for six weeks before admission. Eclamptic fits began 21-10-20 - patient had three or four fits before admission (10-30 a.m. 21-10-20). Patient's colour was good: slight oedema of ankles: uric acid: Albumen +++. No acetone or diacetic acid. Venesection: salines, etc. - fits decreased. Child born twelve hours after admission - female, ? premature, weight 6¾ lbs. Dismissed 13-11-20, weight 6½ lbs. No further trace after dismissal.

375. W.R. Mother = Positive (3+5∓). 29-10-20.
Child = Negative (3-5-). 29-10-20.

1st Preg. Married. Age 19.
L.P. early Feby., 1920. Pregnancy normal throughout. Child born alive 23-10-20, male, weight 9¼ lbs. (36 hours labour). Dismissed 4-11-20. No further trace after dismissal.

Case No.

376. W.R. Mother = Negative (3-5-). 29-10-20.

5th Pregnancy. Married. Age 26.
L.P. 27-4-20.
Inevitable Abortion: Macerated Foetus.
Patient has had 'heart burn' during present pregnancy: been wearing a pessary which came out 3 days before admission - on day following bleeding began and was very severe. On admission (23-10-20) pale: internal strabismus. Had Diphtheria 7 years ago - often has headache.

Previous Pregnancies.- 1st = normal: 2nd = Transverse, S.B. 3rd = normal: 4th = normal, F.T. Twins (since dead) born Novr., 1919.

377. W.R. Mother = Strongly Positive (3+5+) 29-10-20.

3rd Pregnancy. Married. Age 29.
Inevitable Abortion.
L.P. early Aug., 1920.
Has not felt well during present pregnancy: loss of appetite and lassitude. Very slight bleeding began 21-10-20 - increased in severity - profuse on admission (23-10-20). Curetted, douched.

Previous Pregnancies.- 1st = normal: 2nd = normal (7 months) lived 20 minutes only (5-1-20).

378. W.R. Mother = Negative (3-5-) 29-10-20.

1st Pregnancy. Married. Age 22.
Incomplete Abortion.
Admitted 21-10-20. (L.P. last week July, 1920).
Well till bleeding began 20-10-20 - severe with passage of clots - very slight bleeding for 4-5 days previously. Curetted, douched, swabbed.

Case No.

379. W.R. Mother = Negative (3-5-). 5-11-20.
Child = Negative (3-5-). 29-10-20.

1st Pregnancy. Married. Age 27.
L.P. 5-1-20.
Gastric pain and vomiting during 3 weeks before admission: (history of gastric ulcer). Some anaemia noted. Menstruation very irregular - 2-3 times per annum.
Child born 28-10-20, Female, weight 8¾ lbs.
Dismissed 6-11-20, weight 7½ lbs.
No further trace after dismissal.

380. W.R. Mother = Negative (3-5-) 5-11-20.
Child = Negative (3-5-) 29-10-20.

2nd Pregnancy. Married. Age 31.
L.P. 28-1-20.
Present pregnancy normal throughout.
Child born 27-10-20, Male, weight 10 lbs,
Dismissed 8-11-20, weight 8¾ lbs.
No further trace after dismissal.

Previous pregnancy was normal (March, 1916).

381. W.R. Mother = Negative (3-5-). 5-11-20.
Child = Negative (3-5-). 29-11-20.

2nd Pregnancy. Single. Age 22.
L.P. 24-1-20.
Pregnancy normal throughout.
Had fall day before admission - labour over 48 hours - Practically whole of Chorion retained - slight P.P.H. - Uterus curetted and douched.
Child born 27-10-20, Female, weight 8½ lbs.
Child's eyes purulent 1-11-20. Mother has abundant leucorrhoeal discharge - B. Diphtheroid but no G.C. found.
Dismissed 5-11-20, weight 7½ lbs.
No trace after dismissal.

1st pregnancy was normal in Octr., 1918.

Case No.

382. W.R. Mother = Doubt. Pos. ($3\bar{+}5\bar{+}$). 5-11-20.

16th Preg. Married. Age 40.
L.P. ? 5-4-20. Patient was well till 14-10-20 when there was slight bleeding which passed off. Began to bleed fairly severely 28-10-20 - packed. Admitted 28-10-20 - in labour. Child born alive 28-10-20, premature, male, weight 3 lbs. - died same day. P.M. exam.
Prev. Pregs.- 1st = normal: 2nd = premature: 3rd = normal: 4th = normal: 5th = normal: 6th = premature: 7th = premature: 8th - 11th = normal. A number of the children born alive died after a few days. Four miscarriages all associated with A.P.H. - last in Decr., 1919.

383. W.R. Mother = Negative (3-5-). 5-11-20.
Child = Negative (3-5-). 5-11-20.

1st Preg. Single. Age 20.
L.P. 6-2-20.
Pregnancy normal throughout. Child born 29-10-20, male, weight 6 lbs. Dismissed 8-11-20, weight 5¾ lbs. Child died 14-12-20 - 'was very delicate'.

384. W.R. Mother = Negative ($3\bar{\bar{+}}5-$). 5-11-20.

2nd Preg. Married. Age 38.
L.P. 27-2-20. Admitted to Ante-natal Dept. 26-10-20 - headaches during first four months: feet and ankles bagan to swell fourteen days before admission. Had Bright's disease at last confinement. Dismissed - undelivered - 1-11-20.
Prev. Preg.- = Chloroform and Forceps - five days in labour (Edinburgh Maternity Hospital) March, 1917. Had enteric fever 30 years ago.

Case No.

385. W.R. Mother = Negative (3-5-) 5-11-20.

5th Pregnancy. Married. Age 33.
L.P. ? May, 1920 - very indefinite history - states that she was 3 months pregnant when abortion occurred (in August), thereafter she saw nothing for one month - then haemorrhage began again for 2 months before admission and has continued - very little just before admission.
Admitted 26-10-20 - very anaemic - Incomplete Abortion, curetted, douched, swabbed, packed.
Dismissed 2-11-20.

Previous pregnancies all normal - last in Feby., 1918.

386. W.R. Mother = Weakly Positive (3^{+} $5^{\mp}$) 5-11-20.
Child = Negative (3-5-) 5-11-20.

6th Pregnancy. Married. Age 22.
L.P. 24-2-20.
Spontaneous rotation from 3rd to 2nd vertex - normal delivery, child born 28-10-20, male, weight 7 lbs.
Dismissed 5-11-20, weight 6¼ lbs.
20-11-20 - Home visit paid - Child gaining well Mother has swelling in neck.
26-7-21 - Home Visit paid - Mother stated that baby had died of 'whooping-cough' on 14-1-21. Mother herself not looking well.

Previous Pregnancies.- All normal.
Patient deaf (Right ear) since accident in childhood.

387. W.R. Mother = Negative (3-5-) 5-11-20.
Child = Negative (3-5-) 5-11-20.

1st Pregnancy. Single. Age 20.
L.P. ? Feby., 1920.
Child born 29-10-20, normal labour, Ruptured perineum - Child male, weight 7 lbs.
Dismissed 8-11-20, weight 7 lbs.
No trace since dismissal.

Case No.

388. W.R. Mother = Negative (3-5-). 5-11-20.
Child = Negative (3-5-), 5-11-20.

1st Pregnancy. Married.
L.P. ?
Admitted Ante-natal Dept. 29-10-20.
Child born 29-10-20, male, weight 7 lbs., alive.
Dismissed 8-11-20, weight 7½ lbs.
Child was known to be alive when aged 4 months but no trace since.

389. W.R. Mother = Weakly Positive ($3^{\pm}5^{\mp}$) 5-11-20.

1st Pregnancy. Married. Age 28.
L.P. = ? April, 1920.
Patient was well till two hours before admission when she took an eclamptic fit: a second fit in ambulance wagon: a third on admission 28-10-20. On admission - cyanosed: oedema of face and ankles; fits. Venesection: saline: Chloroform - died 2½ hours later - undelivered. Uterus was larger than stage of pregnancy (5 months) - Hydramnios probably present.

390. W.R. Mother = Negative (3-5-). 5-11-20.
Child = Negative (3-5-). 5-11-20.

1st Pregnancy. Single. Age 32.
L.P. 1st week Feby., 1920.
Child born 30-10-20, Female, alive, weight 7 lbs. Labour normal - Ruptured Perineum. Febrile puerperium.
Child was known to be alive and well at 16 months.

Case No.

391. W.R. Mother = Strongly Positive (3+5+). 5-11-20.

1st Pregnancy. Married. Age 21.
L.P. Decr., 1919.
Impacted Shoulder, arm presentation: Decapitation and extraction of aftercoming head with cranioclast and cephalotribe - in labour about 60 hours. Pelvis - Diag. Conj. = 4¾", True Conj. = 4".
Child born 26-10-20, dead, male, weight 6¼ lbs.
I.U.D. given. Febrile Puerperium.
Mother seemed well at 9 months after confinement - no treatment.

392. W.R. Mother = Negative (3-5-). 5-11-20.
Child = Negative (3-5-). 5-11-20.

1st Pregnancy. Single. Age 25.
L.P. 26-1-20.
Patient was well throughout pregnancy till labour began 3 days before admission - accidental haemorrhage occurred during this period, and became very severe just before admission on 30-10-20 - delayed 2nd stage - forceps -
Child born 30-10-20, male, dead, weight 6½ lbs.

393. W.R. Mother = Negative (3-5-). 5-11-20.
Child = Negative (3-5-). 5-11-20.

1st Pregnancy. Married. Age 27.
L.P. Feby., 1920.
Patient was well throughout till 15-10-20 when pains began in back and abdomen. Labour began about 23-10-20, very strong pains before admission on 30-10-20. Patient very emaciated and anaemic. Pelvis - Diag. Conj. = 4¼"+, True Conj. = 3½"+. Uric acid: Albumen + 4 grains per oz.
Forceps delivery - child born 31-10-20, dead, male, weight 7 lbs.
After delivery Mother had two eclamptic fits.

Case No.

394. W.R. Mother = Negative (3-5-). 5-11-20.

4th Pregnancy. Married. Age 27.
L.P.?
Child born before admission on 27-10-20.
Retained Placental debris - causing secondary P.P.H. - Uterus curetted, douched, swabbed.
Dismissed 9-11-20.
No trace after dismissal.

Previous Pregnancies.- 1st to 3rd = Normal, full-time, last in Octr., 1919.

395. W.R. Mother = Negative (3-5-). 5-11-20.

4th Pregnancy. Married. Age 40.
L.P. May, 1920.
Admitted Ante-natal Dept. 27-10-20, Threatened Abortion - began to bleed 2 months before admission - continued to bleed - at first no pains, but for last 3 weeks abdominal pain present at intervals. Has not felt life. Uterus up to umbilicus: no foetal heart sounds or movements - no foetal parts made out.
Dismissed 9-11-20.

Previous 3 pregnancies - normal, full-time, last in Octr., 1919.

396. W.R. Mother = Negative (3-5-). 5-11-20.

14th Pregnancy. Married. Age 42.
L.P. July, 1920.
Incomplete Abortion.
Admitted 25-10-20 - had some bleeding one month before when ovum was expelled - has been losing heavily for 10 days before admission. Curetted - only a few shreds of placental tissue - I.U.D. - Swabbed.

Previous Pregnancies.- 9 normal deliveries - Full-time, alive - last in Novr., 1918.
3 miscarriages at 3½, 2 and 3 months - last in 1912.

Case No.

397. W.R. Mother = Negative (3-5-). 5-11-20.
Child = Negative (3-5-).10-11-20.

11th Pregnancy. Married. Age 37.
L.P. ? March, 1920.
Toxaemia: premature labour.- Patient was well till 26-10-20 when she had pain in loin radiating to back.
Admitted 27-10-20 - vomited all day - marked tenderness over gall-bladder. Enema given - good result, no blood. Patient did not look seriouly ill: sickness continued till 31-10-20 but was less severe: tenderness less marked and is localised - no general abdominal tenderness: Stools normal. Mother's urine (28-10-20) no albumen, but acetone and diacetic acid present.
Child born 1-11-20, male, alive, weight 4 lbs.
Dismissed 11-11-20, weight 4½ lbs.
Child died when from 3-4 weeks old.

Previous Pregnancies.- All full-time, normal, alive - last in Decr., 1919.

398. W.R. Mother = Negative (3∓5-). 3-11-20.

1st Pregnancy. Married. Age 35.
L.P. end Feby., 1920.
Patient was well throughout pregnancy except for discharge and pain in left side.
Delayed 2nd stage - Forceps - child born, dead, (alive on admission) on 28-10-20 - Female, weight 6½ lbs.
Mother was attending Lock Hospital for 5 months before admission - treated for Gonorrhoea.

399. W.R. Mother = Negative (3-5-). 5-11-20.

1st Pregnancy. Married. Age 27.
L.P. 28-1-20.
Admitted 29-10-20 - False Labour -
Dismissed - undelivered - 1-11-20.

Case No.

400. W. R. Mother = Negative (3-5-). 5-11-20.

1st Pregnancy. Married. Age 20.
L.P. 31-1-20.
Admitted 29-10-20 - False Labour.
Dismissed - undelivered - 1-11-20.

401. W.R. Mother = Negative (3-5-). 5-11-20.

2nd Pregnancy. Married. Age 30.
L.P. 30-3-20.
Ante-partum Haemorrhage: Premature Labour.
Admitted 25-10-20- Had some bleeding about one week before admission - was kept in bed and no further bleeding till she got up then bleeding again with pains. Pelvis - Diag. Conj. = 3¾", True Conj. = 3".
Child (7 months) born alive, male, 26-10-20 - lived 1 hour.

Previous Pregnancy was Full-time, stillborn on 15-12-19.

402. W.R. Mother = Negative (3-5-). 22-10-20.

6th Pregnancy. Married.
L.P. 12-1-20.
Pregnancy normal throughout.
Child born - male - 10-10-20, weight 6 lbs.
Dismissed 20-10-20.
Child was known to be alive and well at 16 months - never any illness.

W.R. Mother = Negative (3-5-) 4-3-22.
Child = Negative (3-5-) 4-3-22.

Case No.

403. W.R. Mother = Negative (3-5-). 22-10-20.

1st Preg. Married. Age 26.
L.P. Jany., 1920. Pregnancy normal throughout. Child born alive 13-10-20, female, weight 7 lbs. but died 16-10-20. Mother was dismissed 23-10-20.

404. W.R. Mother = Negative (3-5-). 22-10-20.

1st Preg. Married. Age 21.
L.P. end Decr., 1919. Contracted Pelvis - (Diag. Conj. = 4¼" -, True Conj. = 3½" -). Persistent occipito-posterior - Manual rotation-Forceps - child born alive 8-10-20, male, weight 8 lbs. R.P. Dismissed 18-10-20, weight 7½ lbs. Child was alive and well when aged 16 months - only illness was measles.

405. W.R. Mother = Negative (3-5-). 22-10-20.

7th Preg. Married. Age 31.
L.P. 1-3-20. Premature still-born children - born before admission to Hospital -. Adherent placenta. Patient was well throughout pregnancy until 9-10-20 when pain began and twins were born - dead. Placenta removed manually - curetted. Ruptured perineum repaired.
Prev. Pregs.- 1st = 7 months, living: 2nd = F.T., S.B., instrs.: 3rd = F.T., living, instrs.: 4th and 5th = F.T., living, instrs.: 6th = F.T., S.B., instrs. (? pelvis).

Case No.

406. W.R. Mother = Negative (3-5-). 22-10-20.

2nd Pregnancy. Married. Age 38.
L.P. 10-2-20.
Mother attended Ante-natal Dispensary throughout Pregnancy - no albuminuria.
Child born 8-10-20, male, weight 8½ lbs. Labour normal.
Dismissed 16-10-20, weight 5 lbs.
Child was known to be alive and well at 16 months - no serious illness.

W. R. Mother = Negative (3-5-) 7-3-22.
Child = Doubt. Neg. (3+5-).9-3-22.

Previous Pregnancies.- 1st = F.T. stillborn (April, 1918) Eclampsia.

407. W.R. Mother = Negative (3-5-). 22-10-20.

2nd Pregnancy. Married. Age 21.
L.P. end Decr., 1919.
Pregnancy normal throughout.
Child born 11-10-20, Female, weight 6 lbs.
Dismissed 25-10-20, weight 6 lbs. Child had Mastitis but was better before dismissal.
Child died 15-9-21 - (at 11 months).

Previous Pregnancy was Full-time, living, normal - 9-7-19.

408. W.R. Mother = Negative (3-5-). 22-10-20.

3rd Pregnancy. Married. Age 24.
L.P. 17-1-20.
Pregnancy normal throughout.
Child born 15-10-20, Female, weight 10 lbs.
Dismissed 25-10-20, weight 9¼ lbs.

Previous Pregnancies were both normal - last in 1918.

Child was known to be alive and well at 16 months - only illness had been whooping-cough.

Case No.

409. W.R. Mother = Strongly Positive (3+5+) 22-10-20.

2nd Pregnancy. Single. Age 21.
L.P. 18-2-20.
Admitted 14-10-20 - Bronchitis and False Labour.
Dismissed - undelivered - 18-10-20.

Previous Pregnancy was normal.

410. W.R. Mother = Negative (3-5-). 22-10-20.
Child = Negative (3-5-). 22-10-20.

1st Pregnancy. Single. Age 19.
L.P. Jany., 1920.
Admitted Ante-natal Dept. 11-10-20 - slightly contracted Pelvis - (Diag. Conj. = 4¼" + and True Conj. = 3½"+).
Spontaneous delivery - Child born 17-10-20, Female, weight 8 lbs. Ruptured Perineum. Dism. 17-10-20
Child was known to be alive and well when 3 months old - no trace since.

411. W.R. Mother = Negative (3-5-). 22-10-20.

2nd Pregnancy. Married. Age 32.
L.P. ?
Admitted Ante-natal Dept. 4-10-20 - Contracted Pelvis - Diag. Conj. = 3¾", True Conj. = 3 inches.
Caesarean Section Child born 5-10-20, Female, alive, weight 7½ lbs. Dismissed 28-10-20.

Child was known to be alive and well at 16 months- only illness was 'slight congestion'.

Previous Pregnancy was prolonged and difficult labour - Chloroform and Forceps - 1917.

Case No.

412. W.R. Mother = Str. Positive (3+5+). 22-10-20.

1st Preg. Single. Age 24.
Normal pregnancy. Mother has exophthalmos which is said to be always present but worse during pregnancy. Normal labour - child born alive 11-10-20, female, mature, weight 7 lbs. Dismissed 26-10-20, weight 7¾ lbs.
17-12-20 - Attending Infnat Consultations.
21-3-21 - child attending Inf. Cons. and mother having treatment from panel doctor.
18-11-21 - mother very poorly, has bleeding at nose and is very pale and thin. Baby very well - no rash. Some diarrhoea in summer. Spleen not palpable. Mother attending G.R.I. Disp. 19-11-21 - Has exophthalmos: some tremor: some Tachycardia: very slight enlargement of thyroid: no skin rash: Complained of hoarseness but nothing beyond slight Laryngitis. W.R. Mother = Str. Pos.
24-12-21 - Has had six weeks mercury: two weeks Potassium Iodide: four injections Neokharsivan (2.18 grms. in all).
22-2-22 - Child very ill with Influenza & Conjestion of lungs.
12-6-22 - W.R. Child = Neg. (3-5abs.Cabs.)
4-7-22 - Mother having treatment at Ophthalmic institution.

413. W.R. Mother = Negative (3-5-). 22-10-20.

1st Preg. Married. Age 29.
L.P. Decr., 1920. Impacted intramural fibroid. Breech: Caesarean Section and enucleation of tumour. Patient was well till labour began on 6-10-20 - pains continued till 8-10-20 when patient was admitted - foot presenting - mass on right side - patient becoming exhausted. Caesarean section - child born 8-10-20, female, mature, alive, weight 7¾ lbs. Mother made a good recovery and was dismissed 21-10-20. Child dismissed 29-10-20.
22-2-22 - child alive and well - no illness (now 16 months old).

Case No.

414. W.R. Mother = Negative (3-5-). 22-10-20.

11th Preg. Married. Age 42.
L.P. June, 1920. Incomplete Abortion. Patient began to bleed middle of August and bleeding continued for four weeks then foetus was expelled. Bleeding continued for other three weeks. Admitted 8-10-20 - emaciated, pale, pulse poor. Curetted.
Prev. Pregs.- All normal, F.T. (last in 1915).

415. W.R. Mother = Str. Positive (3+5+). 22-10-20.

2nd Preg. Single. Age 30.
L.P. Jany., 1920. Normal pregnancy. Child was born before admission to Hospital on 13-10-20 - Placenta was expelled after admission. Patient had condylomata on vulva and was admitted to Lock Hospital on 27-10-20.
23-3-21 - Mother and child alive but latter not looking well. Not now attending Lock Hospital. No further trace.
Prev. Preg.- Normal.

416. W.R. Mother = Str. Positive (3+5+). 22-10-20.
Child = Negative (3∓5-). 22-10-20.

7th Preg. Married. Age 30.
L.P. Jany., 1920. Normal pregnancy till onset of labour on 14-10-20. While in labour had three fits (slight twitchings only) and became unconscious. Admitted to Hospital 15-10-20 and child was born just after admission - female, alive, weight 7 lbs. No further fits after admission - put on eclamptic treatment. Albumen ++ (15-10-20). No oedema. Dismissed 23-10-20, weight 6½ lbs. The child died of Convulsions on 20-1-21. No further trace of mother.
Prev. Pregs.- 1st = F.T., spontaneous, S.B.: 2nd = F.T., alive: 3rd = F.T., forceps, alive: 4th = spontaneous, F.T., S.B.: 5th and 6th = F.T., alive (July, 1919).

Case No.

417. W.R. Mother = Negative (3-5-). 22-10-20.
Child = Negative (3-5-). 22-10-20.

1st Preg. Single. Age 19.
L.P. Jany., 1920. Normal pregnancy and labour. Child born alive, mature, 15-10-20, weight 7½ lbs. Dismissed 25-10-20, weight 7½ lbs.
The child was alive and well when 16 months old - only illness had been Chickenpox.

418. W.R. Mother = Negative (3-5-). 22-10-20.
Child = Negative (3-5-). 22-10-20.

2nd Preg. Married. Age 23.
L.P. last week Decr., 1919. Normal pregnancy and labour. Child born alive 16-10-20, female, weight 6 lbs. Dismissed 25-10-20, weight 6¼ lbs.
25-5-22 - Both well. Baby had Broncho-pneumonia and measles but now better (aged 19 months) - W.R.(Mother)= Negative, (Child)= Negative.
Prev. Preg.- normal, F.T., alive (Feby., 1917).

419. W.R. Mother = Negative (3-5-). 22-10-20.

10th Preg. Married. Age 35.
L.P. 3-7-20. Incomplete Abortion. On 7-10-20 patient began to bleed a good deal. But no further bleeding till 15-10-20 when bleeding came on severely. Admitted 15-10-20 - blanched, uterus explored and placental tissue cleared out. Bleeding stopped.
Prev. Pregs.- 1st = F.T., living, normal: 2nd and 3rd = F.T., living, normal: 4th = miscarriage at four months: 5th = F.T., living, normal: 6th and 7th = F.T., living, normal: ? 8th : 9th = premature (6½ months) in G.R.M.H. in Decr., 1919 - patient had pleurisy during puerperium and has been attending T.B. Disp. at Granville St. ever since.

Case No.

420. W.R. Mother = Negative (3-5-). 22-10-20.

2nd Pregnancy. Married. Age 27.
L.P. Jany., 1920.
Pregnancy normal throughout.
Admitted Ante-natal Dept. 11-10-20.
Child born 11-10-20, Female, weight 7½ lbs.
Dismissed 21-10-20, weight 8 lbs.
Child alive at 16 months - has Chronic Bronchitis.

Previous Pregnancy was Full-time, normal, living.
A third child born on 8-1-22 - W.R. done = Neg.
Repeated (4-3-22) = Neg.
Mother's repeated (4-3-22) = Neg.

421. W.R. Mother = Negative (3-5-).

2nd Pregnancy. Single. Age 19.
L.P. Jany., 1920.
Pregnancy normal throughout.
Child born - Breech - 10-10-20, Female, weight 7½ lbs.
Dismissed 20-10-20, weight 7 lbs.
Child known to be alive and well when 5 months - no trace since.

Previous Pregnancy was full-time, normal, Sept., 1918.

422. W.R. Mother = Negative (3-5-). 22-10-20.

3rd Pregnancy. Married. Age 24.
L.P. 28-1-20.
Pregnancy normal throughout.
Patient very anaemic looking: child born 15-10-20, male, weight 7 lbs.
Dismissed 24-10-20, weight 7½ lbs.
No trace after dismissal from Hospital.
Previous Pregnancies.- 1st = normal: 2nd = normal labour: albuminuria during pregnancy (Octr., 1919)

Case No.

423. W.R. Mother = Weakly Positive (3+5-) 22-10-20.
Child = Negative (3-5-). 22-10-20.

1st Pregnancy. Single. Age 30.
L.P. 27-2-20.
Slight Lateral Placenta Praevia: P.P.H.: Acute yellow Atrophy of liver.
Patient was quite well till October when vomiting (everything she ate) began. Slight pain and bleeding at onset of labour.
Admitted 16-10-20 - jaundiced (not noticed before admission).
Child born 16-10-20, male, premature, weight 6 lbs. dead. Slight A.P.H. - brisk P.P.H. Jaundice more marked - drowsiness: diminished liver dullness - coma - death 19-10-20.

424. W.R. Mother = Negative (3-5-). 22-10-20.

1st Pregnancy. Single. Age 23.
L.P. Jany., 1920.
Child born before arrival at hospital on 12-10-20 - alive.
Dismissed 25-10-20, weight 6½ lbs.

Child was known to be alive and well at 13 months - never any illness.

425. W.R. Mother = Negative (3-5-). 22-10-20.
Child = Negative (3-5-). 22-10-20.

1st Pregnancy. Single. Age 20.
L.P. 4-1-20.
Pregnancy normal throughout.
Child born 16-10-20, Female, weight 9½ lbs. Labour normal. Ruptured Perineum.
Dismissed 26-10-20, weight 9 lbs.

Child was known to be alive and well at 13 months - never any illness.

Case No.

426. W.R. Mother = Negative (3-5-). 22-10-20.
Child = Negative (3-5-). 22-10-20.

2nd Preg. Single. Age 30.
L.P. 3-1-20. Normal pregnancy and labour. Child born alive 15-10-20, female, weight 8 lbs. Dismissed 26-10-20, weight 8 lbs. No further trace after dismissal.
Prev. Preg.- normal, F.T. (in 1912).

427. W.R. Mother = Negative (3-5-). 22-10-20.
Child = Negative (3-5-). 22-10-20.

1st Preg. Married. Age 20.
L.P. 27-12-19. Normal pregnancy and labour. Child born alive 15-10-20, male, weight 6½ lbs. Dismissed 23-10-20, weight 6 lbs.
The child was known to be alive and well when 16 months old - only illness had been Whooping-cough.

428. W.R. Mother = Negative (3-5-). 22-10-20.
Child = Negative (3-5-). 22-10-20.

3rd Preg. Married. Age 23.
L.P. Jany., 1920. Normal pregnancy and labour. Child born alive 14-10-20, female, weight 5¾ lbs. (? mature). Dismissed 23-10-20, weight 5¾ lbs. No further trace.
Prev. Pregs.- 1st and 2nd = normal, F.T. (last in 1918).

429. W.R. Mother = Negative (3-5-). 22-10-20.
Child = Negative (3-5-). 22-10-20.

1st Preg. Married. Age 39.
L.P. end Decr., 1919. Normal pregnancy and labour. Child born alive 15-10-20, female, weight 7½ lbs. Dismissed 25-10-20, weight 7½ lbs. Mother developed Erysipelas and was transferred to Ruchhill Hospital on 20-10-20.

Case No.

430. W.R. Mother = Negative (3-5-). 22-10-20.
Child = Negative (3-5-). 29-10-20.

2nd Preg. Married. Age 21.
L.P. = Amenorrhoea since last child born. Admitted 16-10-20 - pain in left side (? muscular). Dismissed 25-10-20 and was readmitted 26-10-20. Normal labour - child born alive 26-10-20, male, weight 6¼ lbs. Dismissed 3-11-20, weight 6½ lbs. The child was known to be alive and well when 16 months old - no illness.
Prev. Preg. - normal (April, 1919).

431. W.R. Mother = Negative (3-5-). 22-10-20.

6th Preg. Married. Age 32.
L.P. ?. Incomplete Abortion. Admitted 17-10-20. Abdominal pain throughout present pregnancy (about four months). Bleeding (clots passed) and severe pain a few hours before admission. Curetted, douched and swabbed.
Prev. Pregs.- 1st = S.B. at 7½ months: 2nd = normal: 3rd = normal: 4th = normal (May, 1919): 5th = abortion (6 weeks) in Octr., 1919.

432. W.R. Mother = Negative (3-5-). 22-10-20.
Child = Negative (3-5-). 22-10-20.

2nd Preg. Single. Age 24.
L.P. 15-2-20. Patient has not felt well throughout this pregnancy - has had muscular cramps and sickness throughout. Membranes ruptured three days before onset of labour pains. Child born (normal labour)17-10-20, male, alive, weight 6 lbs. Dismissed 26-10-20, weight 5½ lbs. The child died on 17-12-21 of Measles and Congestion of Lungs.
Prev. Pregs.- 1st = normal (1916). Patient had Diphtheria in 1915.

Case No.

433. W.R. Mother = Negative (3-5-). 22-10-20.

4th Preg. Married. Age 33.
L.P. 10-7-20. Incomplete Abortion. Had slight abdominal pain for one week: haemorrhage began 16-10-20: foetus and part of placenta expelled. Curetted, douched and swabbed. Patient had pleurisy in childhood and is very subject to Bronchitis. Rhonchi on admission.
Prev. Pregs.- 1st = S.B. at 6½ months: 2nd = 7 months (lived 3 days): 4th = Abortion (3½ months).

434. W.R. Mother = Negative (3-5-). 22-10-20.
Child = Negative (3-5-). 22-10-20.

1st Preg. Single. Age 19.
L.P. end Feby., 1920. Normal pregnancy and labour - child born alive 19-10-20, female, weight 7 lbs. Dismissed 30-10-20, weight 6 lbs.
18-2-22 - Mother and child both well - child now 16 months old. W.R. Mother = D. Pos.
Child = D. Neg.

435. W.R. Mother = Negative (3-5-). 29-10-20.
Child = Negative (3-5-). 29-10-20.

2nd Preg. Married. Age 28.
L.P. Jany., 1920. Impacted Breech: Ruptured Perineum. Cough and pain in back from fifth month - swelling of feet and legs and occasional headaches. Admitted 18-10-20. Urine.- albumen and blood present. Admitted after 14½ hours labour - Impacted breech - Bandl's ring forming. Anaesthetic given and breech pushed up - leg brought down. Child born alive 18-10-20, male, weight 9¼ lbs. Dismissed 28-10-20, weight 8¼ lbs.
22-2-22 - Child alive (now 16 months old). Had Congestion of lungs and Pleurisy.
Prev. Preg.- F.T., alive, normal labour (23-7-19).

Case No.

436. W.R. Mother = Negative (3-5-). 9-2-21.

1st Pregnancy. Married. Age 17.
L.P. June, 1920.
Patient was well till 23-1-21 when she had sudden severe pain in left side - continued till admission to Ante-natal Dept. on 28-1-21. Abdomen about 8 months size: tenderness down left side and in both fornices, but no thickening to be made out. Condition thought to be a necrosis. Foetal heart sounds heard and movements noted. Dismissed undelivered 4-2-21.

437. W.R. Mother = Negative (3+5-). 29-10-20.

8th Pregnancy. Married. Age 36.
L.P. ?
Attended Ante-natal Disp. 22-10-20.
Had bleeding in July, 1920 which she thought was miscarriage - says she feels life now. Contracted Pelvis - C.V. = 3½ inches +.
Stillborn child born 27-12-20.

438. W.R. Mother = Strongly Positive (3+5+). 5-11-20.

10th Pregnancy. Married. Age 41.
L.P. ? March, 1920.
Transverse Presentation. (Contracted Pelvis - Diag. Conj. = 3¾" True Conj. = 3"). Chronic Bronchitis.
Patient was very ill on admission - pulse rapid and irregular. Had been in labour since 25-10-20. Left hand and arm presenting - child dead. Decapitation: Placenta retained and removed manually. Child - male - born dead 29-10-20.

Previous Pregnancies.- 1st = Footling, Still-born, Full-time: 2nd = full-time, alive, Chloroform and Instruments: 3rd = full-time, living, spontaneous: 4th = full-time, living - Chloroform & Instruments: 5th = 4 months (result of fall): 6th = full-time, still-born - Chloroform and Instruments: 8th = full-time, still-born, Chloroform and instruments: 9th = full-time, living, spontaneous (1913).

Case No.

439. W.R. Mother = Negative (3-5-).

10th Pregnancy. Married. Age 21.
L.P. June, 1920.
Patient was married in June - missed period in July, but had slight bleeding at end of August - stopped for a day or two and then began again - continued till 10-10-20 when she 'miscarried' - very slight pain and no vomiting.
Admitted 23-10-20 - uterus enlarged - curetted - no vesicles and no definite placental tissue. At a subsequent chloroform examination there was a swelling of left ovarian region which burst on pressure, and mucoid material escaped through uterus. Uterus returned to normal before dismissal on 1-11-20.

440. W.R. Mother = Negative (3-5-). 5-11-20.

1st Pregnancy. Married. Age 32.
Contracted Pelvis: Eclampsia: Perforation: Craniotomy - delivery with cranioclast and cephalotribe.
L.P. 1st week Feby. - uneventful till 5 days before admission when waters came away: slight pains only till 2 days before admission when pains became very severe. Pelvis - Diag. Conj. = 4", True Conj. = 3¼". Admitted 30-10-20, condition of mother bad, but child alive - head not fixed. After 24 hours no progress so craniotomy done. Two eclamptic fits 10 hours after delivery. Child born 31-10-20, male, weight 7 lbs - still-born.

441. W.R. Mother = Negative (3-5-). 5-11-20.

3rd Pregnancy. Single. Age 29.
L.P. ?. Amenorrhoea since last pregnancy.
Child born 30-10-20, Female, alive, weight 7¾ lbs.
Dismissed 9-11-20, weight 7½ lbs.

Child was known to be alive and well at 16 months,- no illness.

Previous Pregnancies.- 1st = Vertex - Chloroform and Forceps: 2nd = normal - Novr., 1919.

Case No.

442. W.R. Mother = Negative (3-5-). 5-11-20.

11th Pregnancy. Married. Age 37.
L.P. end Feby., 1920.
Patient was well till 2 days before admission (had a fall 14 days before admission). Bleeding began without pain 28-10-20 - stopped after a few hours but began again 30-10-20 - 5 hours before admissi on. Child born 31-10-20, Male, weight 4½ lbs, dead.

Previous Pregnancies.- mostly normal: last 4 labours were instrumental: all children Full-time and alive (last in March, 1918).

443. W.R. Mother = Strongly Positive (3+5+). 5-11-20.

1st Pregnancy. Married. Age 22.
L.P. 18-2-20.
Child was alive before delivery - delayed 2nd stage: head 2 hours on perineum - forceps - child, male, born dead.

444. W.R. Mother = Negative (3-5-). 5-11-20.

4th Pregnancy. Married. Age 36.
L.P. March, 1920.
Patient was well till 30-10-20 when moderately severe Ante-partum Haemorrhage took place.
Admitted 31-10-20 in labour - restless.
Child born 2-11-20, alive, Female, weight 4¾ lbs.
Mother developed Lobar Pneumonia on 6-11-20 and died (12-11-20.
Child died 17-11-20.

Previous Pregnancies.- 1st - 3rd = normal - last in July, 1919.

Case No.

445. W.R. Mother = Negative (3-5-). 5-11-20.

1st Preg. Married. Age 17.
L.P. 23-1-20. Normal pregnancy and labour. Delivery took place before admission to Hospital (? date). On 4th day of puerperium patient suddenly began to have eclamptic fits and was admitted unconscious on 31-10-20 - slight oedema of feet (? albuminuria) Dismissed 2-12-20. No further trace.

446. W.R. Mother = Str. Positive (3+5+). 5-11-20.

1st Preg. Married. Age 21.
L.P. March, 1920. Patient was well till 25-10-20 when she took a chill - shivering. Spontaneous delivery - child born dead -. male, weight 4 lbs. 1-11-20. Retained placenta expressed under anaesthesia. Placenta was greenish in colour and generally unhealthy looking. Curetted after delivery and ragged membranes removed. Apical Pneumonia was diagnosed 2-11-20 and patient died 4-11-20. P.M. showed recent ulcerative endocarditis.

447. W.R. Mother = Str. Positive (3+5+). 5-11-20.

2nd Preg. Married. Age 28.
L.P. end Feby., 1920. Admitted to Ante-natal Dept. 30-10-20 - complained of 'rheumatic pains' in bones of legs for a few weeks. Dismissed undelivered 3-11-20 as unsuitable for treatment in G.R.M.H. Readmitted 25-11-20. Normal labour - child born alive 25-11-20 but died 27-11-20. P.M. exam.
Prev. Preg.- normal, F.T. (1917).

Case No.

448. W.R. Mother = Negative (3-5-). 5-11-20.

2nd Pregnancy. Married. Age 33.
L.P. Feby., 1920.
Child born 29-10-20, Female, weight 7½ lbs. Normal delivery - B.B.A. Placenta expressed after admiss-ion. Ruptured Perineum.
Dismissed 6-11-20.
Child was known to be alive and well at 13 months - no illness.

Previous Pregnancy was full-time, normal, 11-6-19.

449. W.R. Mother = Strongly Positive (3+5+) 5-11-20.

1st Pregnancy. Married. Age 25.
L.P. early April, 1920.
Patient had sore throat, 'neuritis in head' and sickness during whole of pregnancy. Had 3 intravenous injections from her own doctor - the last one week before admission. Father also treated.
Child born 1-11-20 - premature - alive, weight 4 lbs.
Dismissed 13-11-20, weight 3 ¾ lbs.
Child died 27-11-20 - Pneumonia.

450. W.R. Mother = Negative (3-5-). 5-11-20.

1st Pregnancy. Married. Age 21.
L.P. 5-2-20.
Patient had been attending her own doctor for a month on account of swelling of legs - has been in bed during that time. A large, healthy looking woman: marked oedema of feet and some puffiness of face. Urine contains albumen (6 grams per litre).
Mother admitted 1-11-20 - had 3 fits before admission - Puerperal Eclampsia - dazed but conscious - just after admission had a severe eclamptic fit - transfusions, bleeding, &c.
Child was born before admission (31-10-20).
Marked improvement before dismissal on 27-11-20 - Albumen down to 0.5 Esbach.
No trace after dismissal.

Case No.

451. W.R. Mother = Negative (3-5-). 4-11-20.
Child = Negative (3-5-). 4-11-20.

4th Preg. Married. Age 25.
L.P. Jany., 1920. Normal pregnancy and labour- Child born alive 1-11-20, Female, weight 5¼ lbs. Dismissed 10-11-20, weight 5 lbs.
7-6-22 - Child 19 months old and very well.
Prev. Pregs.- 1st = F.T., normal, living: 2nd = miscarriage (4 months): 3rd = F.T., normal, living (Octr., 1919).

452. W.R. Mother = Negative (3-5-). 5-11-20.
Child = Negative (3-5-). 5-11-20.

10th Preg. Married. Age 39.
L.P. last week Jany., 1920. Patient has felt weak and 'done' during present pregnancy - Dyspnoea during later months. Admitted after a few hours labour on 31-10-20 - very emaciated and sallow, pulse rapid, slight systolic murmur and dilatation (? where), Chronic Bronchitis. Slightly contracted pelvis (Diag. Conj. = 4¼", True Conj. = 3½"). Spontaneous delivery - child born alive 1-11-20, male, weight 7¼ lbs. Dismissed 13-11-20, weight 7½ lbs.
4-3-22 - Both well - Child never had any illness till 15 months old then had measles.
W.R. Mother = Negative (3-5-). 14-3-22.
Child = Negative (3-5-). 14-3-22.
Prev. Pregs.- All F.T., normal (last in Novr., 1917): One miscarriage (2½ mos.). Some rheumatism and is troubled with Bronchitis.

453. W.R. Mother = Negative (3-5-). 5-11-20.
Child = Negative (3-5-). 5-11-20.

1st Preg. Single. Age 34.
L.P. 27-1-20. Normal pregnancy and labour. Child born alive 31-10-20, female, weight 6 lbs. Dismissed 10-11-20, weight 6½ lbs.
3-3-22 - Child alive and well when 16 months old - never any illness.

Case No.

454. W.R. Mother = Negative (3-5-). 5-11-20.

1st Pregnancy. Married. Age 28.
L.P. Jany., 1920.
Delayed 2nd stage: rigid perineum: forceps delivery-child born 26-10-20, Female, weight 7 lbs.
Dismissed 5-11-20, weight 5½ lbs.
Child was known to be alive and well at 16 months, - only illness Bronchitis.

455. W.R. Mother = Negative (3-5-). 5-11-20.
Child = Negative (3-5-). 5-11-20.

11th Pregnancy. Married. Age 40.
L.P. 8-1-20.
Patient was well till 2 months before admission when feet and ankles became swollen: scanty urine: no treatment: Admitted 31-10-20 - Child born 31-10-20 - after 18 hours labour - Female, weight 7 lbs. Dismissed 19-11-20, weight 6 1/4 lb.
Patient very dark-skinned: feet and ankles very oedematous: 2nd aortic sound accentuated: no murmur. (? urine).
Child was known to be alive and in excellent health at 16 months: is very subject to chills and twice has been very seriously ill.

Previous Pregnancies.- All normal except 4th (cord presenting): Forceps - last in Octr., 1918. One miscarriage at 3 months in 1908.

456. W.R. Mother = Negative (3-5-). 5-11-20.

1st Pregnancy. Married. Age 20.
L.P. 8-1-20.
Child born 26-10-20 - delayed 2nd stage - Forceps Ruptured Perineum - child asphyxiated but resuscitated with difficulty - Child, male, weight 7 3/4 lbs. Febrile puerperium. Respiratory symptoms (? diagnosis). No T.B. found. Leucoyte = 11.500 (polym. = 78%.).
Child died at 6 weeks old.

Case No.

457. W.R. Mother = Negative (3-5-). 5-11-20.

2nd Preg. Single. Age 28.
L.P. early Jany., 1920. Admitted to Ante-natal Dept. 25-10-20 - Contracted Pelvis (Diag. Conj. = 4" , True Conj. = 3¼"). Labour began morning of 29-10-20 - Forceps delivery - child born alive mrrning of 30-10-20, male, weight 10¼ lbs. R.P. Dismissed 9-11-20, weight 9½ lbs. Attended Inf. Cons. until 7 months old - then very well but no further trace.
Prev. Preg.- miscarriage (3 months).

458. W.R. Mother = Negative (3=5=). 5-11-20.
Child = Negative (3-5-). 10-11-20.

1st Preg. Married. Age 23.
L.P. end Decr., 1919. Admitted to Ante-natal Dept. 1-11-20 - had continuous vomiting from fourth to sixth month and also headache. Has had oedema of feet for some weeks. Albuminuria = 2 grms. per litre. Normal labour - child born alive 3-11-20, male, weight 10¼ lbs. R.P. and some P.P.H. No albuminuria on 10-11-20. Dismissed 19-11-20, weight 9½ lbs.
18-11-21 - child alive and well - one year old. No further trace.

459. W.R. Mother = Negative (3-5-). 5-11-20.
Child = Negative (3-5-).10-11-20.

3rd Preg. Married. Age 21.
L.P. first week Feby., 1920. For three months patient has had pain in both legs and has had difficulty in walking. Normal labour - child born alive 2-11-20 - male, weight 6½ lbs. Dismissed 11-11-20, weight 6 lbs.
17-3-22 - Both mother and child well: Child has had Whooping-cough, Pneumonia and Measles.
Prev. Pregs.- 1st = F.T., living, normal: 2nd = premature, living (6 mos.).

Case No.

460. W.R. Mother = Negative (3-5-). 5-11-20.

2nd Preg. Married. Age 38.
L.P. ? Feby., 1920. Contracted Pelvis: Spontaneous Delivery: Twins: Membranes incomplete - curetted. Oedema of legs for four months before delivery - no treatment. Admitted 3-11-20. Contracted Pelvis - (Diag. Conj. = 4" , True Conj. = 3¼" .) Oedema - Urine - Albumen = 0.75 Esbach. Spontaneous delivery - Twins born 4-11-20 - 1st = male, born alive, weight 5¼ lbs., lived a few hours only: 2nd = male, weight 5 lbs., macerated. Chorion retained. Curetted, douched, swabbed. Placenta was greenish yellow in appearance.
Prev. Preg.- ? F.T., living, Chloroform - oedema, headaches, dimness of vision G.R.M.H. in 1916.

461. W.R. Mother = Negative (3-5-). 5-11-20.
Child = Negative (3-5-). 5-11-20.

8th Preg. Married. Age 37.
L.P. 13-2-20. Admitted to Ante-natal Dept. 3-11-20 - Albuminuria (+). Patient was well till three weeks before admission when she had some headache and dimness of vision. No oedema: urine has character of chronic nephritis. Normal labour - child born alive 4-11-20, female, weight 5½ lbs. - died 15-11-20 of Bronchopneumonia (took ill on 12-11-20).
Prev. Pregs.- 1st - 6th = F.T., normal, living: 7th = S.B. (7 mos.).

462. W.R. Mother = Negative (3-5-). 5-11-20.

2nd Preg. Married. Age 27.
? L.P. Normal pregnancy and labour. Child born alive 3-11-20, male, weight 7¾ lbs. Dismissed 13-11-20, weight 7 lbs. Attended Infant Consultations until child seven months but no further trace.
Prev. Preg.- normal, F.T.

Case No.

463. W.R. Mother = Negative (3-5-). 5-11-20.
Child = Negative (3-5-). 5-11-20.

8th Preg. Single. Age 32.
L.P. 31-1-20. Patient was a small rickety woman. Contracted Pelvis (Diag. Conj. = 4" +, True Conj. = 3¼" +). Spontaneous delivery - child born alive 4-11-20, male, weight 6¾ lbs. Dismissed 17-11-20. No further trace after dismissal.
Prev. Pregs.- Details not recorded.

464. W.R. Mother = Negative (3-5-). 5-11-20.
Child = Negative (3-5-).10-11-20.

1st Preg. Married. Age 23.
L.P. 17-11-20. Normal pregnancy and labour. Child born alive 4-11-20, male, weight 8 lbs. Dismissed 13-11-20, weight 8½ lbs. No further trace after dismissal.

465. W.R. Mother = Str. Positive (3+5+). 5-11-20.
Child = Negative (3-5-). 19-11-20.

1st Preg. Married. Age 35.
L.P. 10-2-20. Patient was well till about three weeks before delivery when she caught cold and had severe cough ever since. Admitted from Ante-natal Dispensary 2-11-20 - Contracted outlet: Pott's curvature: pigeon chest: Bronchitis (has had pleurisy four or five times - last in 1919). Consumptive family history. Forceps delivery - child born alive 16-11-20, female, weight 7¼ lbs. Dismissed 25-11-20, weight 6¾ lbs.
Attended Infant Consultations regularly till child over a year old.
4-2-22 - Child 15 months old and very well except for severe colic and constipation. Child's W.R. was negative at R.H.S.C. when three months old.

466. W.R. Mother = Negative (3-5-). 5-11-20.
Child = Negative (3-5-). 10-11-20.

2nd Pregnancy. Married. Age 29.
L.P. Feby., 1920.
Leucorrhoea in June, 1920.
Child born 2-11-20, Female, weight 8 lbs. (normal labour).
Dismissed 12-11-20, weight 6½ lbs.
Child was known to be alive and well at 15 months old - never had any illness.
1st Pregnancy was normal in Octr., 1919.

467. W.R. Mother = Negative (3-5-). 5-11-20.

1st Pregnancy. Married. Age 22.
L. P. 16-3-20.
Patient was well till 2 days before admission when pain began in right side. Patient vomited brown material. Was sent in as possible appendicitis - temperature swinging. Admitted 31-10-20 - pain in right side: tenderness over McBurney's point & posteriorly on pressure over kidneys. Temperature, Pulse and Urine normal. Os dilating.(pain thought to be due to stretching of round ligaments ?).
Child born - Female - 1-11-20, premature, (7 months) weight 5½ lbs.
Dismissed 10-11-20, weight 4½ lbs.
Child was known to be alive and well at 15 months - never any illness. Mother had not had return of abdominal pain.

468. W.R. Mother = Negative (3-5-). 5-11-20.
Child = Negative (3-5-). 12-1-21.

4th Pregnancy. Married. Age 25.
L.P. ? May, 1920.
Admitted Ante-natal Dept. 2-11-20 - had been feeling 'done up' since last confinement: uterine prolapse: had pessary from July to Septr. and then felt more comfortable: lost pessary during a fit of coughing. Trouble with Bronchitis - râles & ronchi present. Ring pessary inserted (uterus prolapsed beyond vulva): oedema locally: large cystocele: Life felt. Dismissed 6-11-20.
Re-admitted 4-1-21 - child born 7-1-21 - male, weight 7 lbs. (normal labour). Dismissed 18-1-21, weight 6¼ lbs.
Child was known to be alive when 10 months old but was then not very well - had Diarrhoea, Cough, etc. Soon after dismissal from G.R.M.H. child had Whooping-cough and was in Ruchhill Hospital for nearly six months.
Previous Pregnancies.- 1st = Chlor. & Forceps: 2nd & 3rd = normal, F.T. (Decr., 1919). During last puerperium patient says she caught a chill and was in G.W.I. with Endometritis. Was in Rotunda Hosp., Dublin, for Prolapse Sept. 1920 - no operation.

Case No.

469. W.R. Mother = Negative (3-5-). 12-11-20.
Child = Negative (3-5-). 12-11-20.

1st Preg. Married. Age 22.
L.P. end Jany., 1920. Normal pregnancy and labour. Child born alive 3-11-20, female, weight 7½ lbs. Dismissed 13-11-20, weight 7½ lbs. No further trace of child after one month.

470. W.R. Mother = Negative (3-5-). 10-11-20.

6th Preg. Married. Age 33.
L.P. 27-12-19. Patient was well till severe bleeding began three hours before admission to hospital. Central Placenta Praevia - version - foot brought down - child born dead 2-11-20, female, weight 8¾ lbs. Mother dismissed 20-11-20.
Prev. Pregs. - All normal.

471. W.R. Mother = Negative (3-5-). 10-11-20.

2nd Preg. Married. Age 26.
L.P. 30-1-20. Admitted to Ante-natal Dept. 1-11-20. Normal labour - child born alive 6-11-20, female, weight 8½ lbs. Dismissed 15-11-20, weight 8¼ lbs.
Child was known to be alive and well when 16 months old - never any illness.
W.R. Mother = Negative (3-5-). 14-3-22.

Prev. Preg.- F.T., normal, living.

Case No.

472. W.R. Mother = Negative (3-5-). 10-11-20.
Child = Negative (3-5-). 10-11-20.

1st Preg. Married. Age 34.
L.P. 17-1-20. Patient was very sick and vomited throughout pregnancy. Was in labour twenty hours before admission on 2-11-20. Severe pains. Breech - child born 3-11-20 - child alive on admission but born dead - male, weight 8½ lbs. R.P.

473. W.R. Mother = Negative (3∓5-). 10-11-20.

13th Preg. Married. Age 42.
L.P. 17-2-20. Admitted to Ante-natal Dept. beginning Octr., with threatened abortion. Child born (B.B.A.) 30-10-20, Female, weight 6½ lbs. Profuse P.P.H. - none after admission. Child died 14-11-20. Mother dismissed 26-11-20.
Prev. Pregs.- All normal except 4th and 5th (Chlor. but no instrs.). Had Pneumonia when 15 years old and T.B. Enteritis as a child.

474. W.R. Mother = Negative (3-5-). 10-11-20.

1st Preg. Married. Age 32.
L.P. 1st Aug., 1920. Incomplete Abortion. Aborted 22-10-20. Had a fall while at work in her house the day before. Bleeding continued - admitted 30-10-20. Curetted.

475. W.R. Mother = Negative (3-5-). 10-11-20.

9th Preg. Married. Age 39.
L.P. 3-8-20 (or ? June, 1920). Incomplete Abortion. Was about ten weeks pregnant when haemorrhage began - clots passed. Admitted 28-10-20 - placental debris protruding from os. Curetted, douched, swabbed.
Prev. Pregs.- All normal except 7th (instrs.) - last in 1918.

Case No.

476. W.R. Mother = Negative (3-5-). 10-11-20.

9th Preg. Married. ? age.
L.P. 9-8-20. Incomplete Abortion. Admitted 2-11-20. Patient was well till two weeks before admission when she felt 'giddy' and a quantity of brownish fluid was passed per vagina. For w week before admission haemorrhage was continuous (red in colour). Curetted and douched. Dismissed 8-11-20.
Prev. Pregs.- All normal.

477. W.R. Mother = Str. Positive(3+5+).

4th Preg. Single. Age 40.
L.P. ? July, 1920. Admitted 2-11-20. Normal labour - child born alive 13-11-20, male, premature. Died 14-11-20. P.M. exam.
Prev. Pregs.- All normal, F.T., (last in 1911)

478. W.R. Mother = Negative (3-5-). 10-11-20.
Child = Negative (3-5-). 10-11-20.

3rd Preg. Married. Age 33.
L.P. 7-2-20. Patient was well till week before admission when oedema of ankles and feet appeared. On admission face puffy but no oedema of feet and legs. Child born alive 4-11-20, male, weight 7½ lbs. Dismissed 13-11-20, weight 8 lbs.
28-5-22 - Both mother and child well although child looks slightly rickety. Has had Catarrh in stomach, Chickenpox and Whooping-cough but now well.
W.R. Mother = Negative (3-5-). 28-5-22.
Child = Negative (3-5-). 28-5-22.
Prev. Pregs.- 1st = Abortion (3 months):
2nd = Chlor. & forceps in 1914.

Case No.

479. W.R. Mother = Negative (3-5-). 10-11-20.

2nd Preg. Married. Age 37.
L.P. 22-6-20. Incomplete Abortion: Prolapse of cord. Patient has had occasional shooting pains in breasts: morning sickness during early weeks of August - nothing abnormal till four weeks before admission when slight haemorrhage began and continued: some pain in back: On morning of 2-11-20 'felt something give way'. Admitted - bleeding - uterus three fingers below umbilicus - pulseless cord prolapsed into vagina. Placenta manually removed: uterus explored, curetted and douched.
Prev. Preg.-Normal (1903).

480. W.R. Mother = Negative (3-5-).

4th Preg. Married. Age 29.
L.P. 8-4-20. Marginal Placenta Praevia. Patient had haemorrhage when six weeks pregnant and severe pains a few days later. Her doctor attempted to clear out uterus digitally - pregnancy continued with slight bleeding at intervals - none for past few days then severe bleeding began with pain on 2-11-20. Admitted to Hospital - Vertex - version to footling - child born dead 4-11-20, male, weight 5½ lbs. Adherent placenta praevia removed manually.
Prev. Pregs.- 1st and 2nd = normal: 3rd = Chlor. & forceps after long labour. Patient had been twice in Samaritan Hospital for curettage, and on second occasion had ventro-fixation. Also curetted twice at home (last in May, 1919). Has had Menorrhagia since birth of 2nd child in 1910. Cycle 7/21.

481. W.R. Mother = Negative (3-5-). 10-11-20.

4th Preg. Married. Age 25.
L.P. 5-1-20. Normal pregnancy and labour. Had Cystitis in Aug., 1920. Was three days in labour before admission on 2-11-20. Dismissed 9-11-20 - False labour. Child born at home 24-11-20 - Died 15-6-21.
Prev. Pregs.- No record.

Case No.

482. W.R. Mother = Negative (3-5-). 10-11-20.

1st Preg. Married. Age 25.
L.P. 21-7-20. Admitted to Ante-natal Dept. 4-11-20 - prolapse of gravid uterus. Dismissed undelivered 9-11-20.
History of T.B., Pleurisy, etc. in patient's parents.

483. W.R. Mother = Negative (3-5-). 10-11-20.

4th Preg. Single. Age 24.
L.P. 6-1-20. Admitted to Ante-natal Dept. 4-11-20. Normal labour - child born alive 4-11-20, female, weight 7 lbs. Dismissed 13-11-20, weight 8 lbs.
Child alive and well when one year old - no illness.
Prev. Pregs.- All normal.

484. W.R. Mother = Negative (3-5-). 10-11-20.

12th Preg. Married. Age 44.
L.P. early June, 1920. Patient was very sick about seventh week and onwards. Bleeding continued from early August with only short intervals. Continuous flow began 2-11-20. Admitted 4-11-20 - bleeding slightly. Incomplete Abortion: Retained Placenta: P.P.H. Uterus explored and curetted digitally.
Prev. Pregs.- One miscarriage at three months (1919):all others normal. Patient had anaemia at 18 years of age.

Case No.

485. W.R. Mother = Negative (3-5-). 12-10-20.

1st Preg. Married. Age 25.
L.P. 5-2-20. Patient had slight oedema of ankles for two months before delivery. Suddenly began to have fits two hours before admission on 4-11-20 - unconscious on admission. No life felt after 2-11-20. Forceps delivery. Several eclamptic fits in rapid succession. Stomach lavage, veratrone, etc. Condition improved - no fits after 5-11-20. Child born dead 4-11-20, male, weight 6¼ lbs. Adherent placenta removed manually. Ruptured Perineum Mother's urine.- acid - albumen 4.5 grs. per oz.

486. W.R. Mother = Negative (3-5-). 12-11-20.
Child = Negative (3-5-). 12-11-20.

1st Preg. Married. Age 24.
L.P. Feby., 1920. Normal pregnancy and labour. Occasional vomiting. Child born alive 4-11-20, male, weight 7 lbs. Dismissed 13-11-20, weight 7 lbs.
28-5-22 - Child alive and well when 19 months old. Had Measles March/April, 1922.
W.R. Mother = Negative (3-5-). 28-5-22.
Child = Negative (3-5-). 28-5-22.

487. W.R. Mother = Negative (3-5-). 12-10-20.

9th Preg. Married. Age 29.
L.P. end Aug., 1920. Threatened Abortion. Patient was well till ten days before admission when very slight bleeding began and continued intermittently - sometimes severe. Admitted 4-11-20 - pale, os practically closed, slight bleeding. Dismissed undelivered 13-11-20.
Prev. Pregs.- Three abortions (all at 3½ mos.) Five labours - sponatneous deliveries - one at 7 months (last in Aug., 1918).

Case No.

488. W.R. Mother = Strongly Positive (3+5+). 12-11-20.

2nd Pregnancy. Single. Age 26.
Child born 5-11-20, male, mature, weight 5½ lbs. - lived 5¾ hours. P.M.
Contracted Pelvis - Caesarean Section.

Previous Pregnancy = spontaneous delivery - (7 months) still-born child. (G.R.M.H. July, 1919).

489. W.R. Mother = Negative (3-5-). 12-10-20.

1st Pregnancy. Single. Age 25.
L.P. Feby., 1920.
Patient has had Psoroasis on legs and arms for past three months: Anaemia. Labour in progress 20 hours before admission - normal delivery -
Child born 4-11-20, Female, weight 7½ lbs.
Dismissed 13-11-20, weight 7¾ lbs.
Child was known to be alive and well when 1 year old - never any illness.

490. W.R. Mother = Negative (3+5-). 12-10-20.
Child = Negative (3-5-). 12-10-20.

1st Pregnancy. Single. Age 23.
L.P. 25-1-20.
Sickness and vomiting continued throughout whole of pregnancy. Headache and difficult micturition (? urine).
Child born 5-11-20, Female, weight 8 lbs. 2 ozs.
Dismissed 15-11-20, weight 8¾ lbs.
Mother had urticaria on admission.
Child alive at 1½ months - no trace after.

Case No.

491. W.R. Mother = Negative (3-5-). 12-11-20.
Child = Negative (3-5-). 12-11-20.

1st Pregnancy. Single. Age 19.
L.P. 2nd week Jany., 1920.
Child born 5-11-20, male, weight 8¼ lbs. (normal labour).
Dismissed 15-11-20, weight 8 lbs.
No trace of mother and child after dismissal.

492. W.R. Mother = Negative (3-5-). 12-11-20.
Child = Negative (3-5-). 12-11-20.

1st Pregnancy. Married. Age 21.
L.P. 2nd Feby., 1920.
Patient was in Hospital at 3rd month with pain on micturition, headache and vomiting. Has had weak-ness of legs and difficulty in micturition throug-out. Admitted 5-11-20 - slight oedema of legs: Albumen ++. Impacted Breech - both arms impacted and displaced - child alive - and heart continued to beat for ¾ hour after birth but child could not be got to breathe properly. Child born 5-11-20 - male, weight 6½ lbs. died same day. P.M.

493. W.R. Mother = Negative (3-5-). 12-11-20.
Child = Negative (3-5-). 12-11-20.

1st Pregnancy. Married. Age 21.
L.P. 1st week Feby., 1920.
Patient had slight bleeding for 2 days in first week of June - no pain. Labour began 1 a.m. 5-11-20 - delayed 2nd stage - head showing for 4½ hours. meconium coming away and foetal heart slowing. Forceps - delivered 7-45 p.m. 5-11-20, child male, weight 8 lbs. Dismissed 15-1120 weight 7¼ lbs.
I.U.D.: Vaginal Laceration: Albumen + on admission but cleared up by 11-11-20.

Child was known to be alive and well at 15 months - no illness.

Case No.

494. W.R. Mother = Negative (3-5-). 12-11-20.
Child = Negative (3-5-). 12-11-20.

1st Pregnancy. Single. Age 19.
L.P. Feby., 1920.
Child born 10-11-20 (26 hours labour) - Male, weight 9½ lbs. Ruptured Perineum.
Dismissed 19-11-20, weight 8½ lbs.
No trace after dismissal.

495. W.R. Mother = Negative (3-5-). 12-11-20.
Child = Negative (3-5-). 12-11-20.

3rd Pregnancy. Married. Age 25.
L.P. 28-1-20.
Patient was troubled with sleeplessness during latter months.
Child born 6-11-20, Male, weight 9½ lbs. (normal labour).
Dismissed 15-11-20, weight 9½ lbs.
Child was known to be alive and well when 1 year old - never any illness.

Previous Pregnancies.- 1st = 3½ months miscarriage (after a fright): 2nd = normal, slight P.P.H. 1918.

496. W.R. Mother = Negative (3-5-). 12-11-20.
Child = Negative (3-5-). 12-11-20.

1st Pregnancy. Married. Age 17.
L.P. March, 1920.
Eclampsia: Marked Oedema. Albumen = Esbach 7+. (2-11-20).
Admitted 5-11-20 - unconscious and very restless - said to have been quite well till morning of 5-11-20 when she complained of severe headache, became unconscious and had a fit. Vigorous eclamptic treatment.
Children born - Forceps delivery - 10-11-20 - Twin males, alive, weights (1) = 5¾ lbs. (2) = 5¼ lbs
Both children died (1) 24-11-20 and (2) 25-11-20.
Mother had P.P.H. Patient was improving rapidly when she was taken home on 26-11-20(against advice).

Case No.

497. W.R. Mother = Negative (3-5-). 12-11-20.
Mother = Negative (3-5-). 17-11-20.

3rd Pregnancy. Married. Age 25.
L.P. end of August, 1920.
Patient was well till 14 days before admission when haemorrhage began accompanied by pain - said ovum was expelled: haemorrhage continued until admission on 7-11-20 - Incomplete Abortion - placental debris curetted away. Dismissed 13-11-20.

Previous Pregnancies.- 1st = miscarriage at 2 months
2nd = miscarriage at 4½ months - May, 1920.
Patient a healthy woman: has conical ulceration left eye with loss of vision - result of measles.
Dysmenorrhoea.

498. W.R. Mother = Negative (3-5-). 12-11-20.

4th Pregnancy. Single. Age 29.
L.P. end Feby., 1920.
Patient was well till morning of 4-11-20 when she felt labour-like pains: she became unconscious: no fits, no oedema - eyes normal.
Admitted, unconscious, 5-11-20 - Diagnosed as Hysteria. Pelvis - Diag. Conj. = 4¼ +, True Conj. = 3½ +.
Dismissed 12-11-20.

Previous Pregnancies.- 1st, 2nd, & 3rd = F.T., living, Chloroform and Forceps - last on 23-11-17.
Operation for(?)Prolapse in 1914.

499. W.R. Mother = Negative (3-5-). 12-11-20.

3rd Pregnancy. Married. Age 22.
L.P. 12-8-20.
Complete Abortion.
Patient was well till 10 days before admission when there was some bleeding - did not lose much - stopped but began again next day: none till 3-11-20. No haemorrhage after admission on 5-11-20.
Abortion considered to have been complete.
Dismissed 9-11-20. Patient looked healthy.

Previous Pregnancies.- 1st = F.T., living, normal - Sept., 1919: 2nd = 7 months - lived 1 month.

Case No.

500. W.R. Mother = Negative (3-5-). 12-11-20.

8th Pregnancy. Married. Age 35.
L.P. 2-3-20.
Patient was well till waters broke morning of 5-11-20 - no pain - no further escape of liquor amnii after admission on 5-11-20. ? Premature rupture of membranes. Prolapse since birth of 3rd child - was wearing a pessary on admission (inserted in April at Ante-natal Disp.). Pelvis - Diag. Conj. = 4¼ , True Conj. = 3½ .
Dismissed 8-11-20, undelivered.

Previous Pregnancies.- 1st = Full-time, living, - Forceps: 2nd - 6th = F.T., normal, living, spontaneous delivery: 7th = 8 months, living (April, 1917).

501. W.R. Mother = Negative (3-5-). 12-11-20.
Child = Negative (3-5-). 12-11-20.

1st Pregnancy. Single. Age 22.
L.P. end Feby., 1920.
Normal Pregnancy and labour.
Child born 7-11-20, Female, weight 6½ lbs.
Dismissed 18-11-20, weight 6½ lbs.
No further trace of patient and baby.

502. W.R. Mother = Negative (3-5-). 12-11-20.

3rd Pregnancy. Married. Age 21.
L.P. 13-3-20.
Admitted Ante-natal Dept. 7-11-20.
Patient was well till 2 days before admission when she fell and bruised her abdomen and vulva. Membranes ruptured some hours before admission - Premature labour - child born 9-11-20, Female, weight 3½ lbs., alive - died 13-11-20. P.M.

Previous Pregnancies.- 1st = F.T., living, spontaneous: 2nd = 7 months, living - 28-11-19(following a fall).

Case No.

503. W.R. Mother = Negative (3∓5-). 5-11-20.

8th Preg. Married. Age 35.
L.P. 23-2-20. Admitted to Ante-natal Dept. 29-10-20 - Severe varicose veins: a good deal of vomiting during first months but very little since third month but has had heart-burn. Varicose veins have got worse with each pregnancy - veins are markedly swollen, tortuous and tender. Patient is otherwise healthy. Delivered 1-12-20 - (labour normal) - Female, alive, weight 8½ lbs. Dismissed 13-12-20, weight 7½ lbs. Child was known to be alive and well when one year old but no trace thereafter.
Prev. Pregs.- 1st = F.T., living, Chlor. & Instrs.: 2nd = F.T., living: 3rd = F.T., living, spontaneous: 4th = F.T., living, Chloroform and Forceps: 5th and 6th = F.T., living, Chlor. & Forceps: 7th = F.T., living, normal, spontaneous (3-10-19).

504. W.R. Mother = Negative (3-5-). 5-11-20.

5th Preg. Married. Age 35.
L.P. 14-7-20. Incomplete Abortion. Patient has had pain in legs and difficulty in walking since beginning of pregnancy. Bleeding began 28-10-20 - slight discharge for about twelve hours before. Blanched on admission (2-50 a.m. 29-10-20). Varicose veins for some years. Curetted, douched and swabbed.
Prev. Pregs.- 1st, 2nd and 3rd = F.T., living, normal: 4th = F.T., living, Chlor. & Instrs.

505. W.R. Mother = Negative (3-5-). 12-10-20.

1st Preg. Single. Age 21.
L.P. early Feby., 1920. Admitted to Ante-natal Dept. 5-11-20 till 19-11-20. Re-admitted 5-12-20 - normal labour - child born alive 5-12-20, female, weight 7¼ lbs. Dismissed 14-12-20, weight 6½ lbs.
17-2-22 - Child alive and well - never any illness.

Case No.

506. W.R. Mother = Negative (3-5-). 12-11-20.

11th Pregnancy. Married. Age 32.
L.P. early August, 1920.
Patient began to bleed 26-10-20 - lost a good deal, but stopped after a few hours. Had abdominal pain but no further bleeding.
Admitted 6-11-20 - Inevitable Abortion - Curettage.
Dismissed 15-11-20.

Previous Pregnancies.- 1st - 5th = Full-time, normal, spontaneous: 6th = 5½ months miscarriage: 7th = full-time, alive: 8th = full-time, breech, alive: 10th = 7½ months - alive - Decr., 1919. Ventro-fixation done in Victoria Infy. 6 years ago.

507. W.R. Mother = Negative (3-5-). 12-11-20.

11th Pregnancy. Married. Age 36.
L.P. 12th Sept., 1920.
Incomplete Abortion.
Patient had a flooding on 27-10-20 accompanied by pain. No sickness or vomiting: pain mostly over uterus. Bled slightly till 2-11-20 when she lost a quantity of blood - still bleeding on admission 5-11-20. Slight swelling in left fornix (old scar tissue). Tenderness on deep pressure over uterus. Curetted, douched, swabbed. No extra-uterine abnormality.
Dismissed 11-11-20.

Previous Pregnancies.- Nine normal deliveries - all full-time, alive: One miscarriage at 3-4 months, (19-8-20).

508. W.R. Mother = Negative (3-5-). 12-11-20.

1st Pregnancy. Married. Age 25.
L.P. 25-1-20.
Contracted Pelvis: Craniotomy: R.P.: P.P.H.
Labour began 2-11-20. Membranes ruptured 3-11-20. Failed forceps outside: Admitted 5-11-20 - child alive. Pelvis - Diag. Conj. = 3½ inches, True Conj. = 2¾ inches. Albumen ++. Os was not fully dilated till evening of 5-11-20. Head perforated - child delivered 6-11-20 - dead, male, weight 7½ lbs. Ruptured Perineum - Vaginal lacerations - went badly septic. Rickets.
Dismissed 12-12-20.

Case No.

509. W.R. Mother = Strong. Positive (3+5+). 12-11-20.

7th Preg. Married. Age 29.
L.P. 11-3-20. Ante-partum Haemorrhage.
Patient was well till about fifth month when there was intermittent haemorrhage for a week - bleeding then ceased. Bleeding began again on rising on 4-11-20 and continued till admission on evening of 5-11-20 - after admission only slight haemorrhage. Os closed: no placenta praevia: no pain: uterus about eight months size: patient pale and anaemic looking. Dismissed undelivered 17-11-20.
Child born at home 2-12-20 - female, alive.
19-5-22 - Mother pale and anaemic - does not feel well. Child not thriving but nothing definite - not walking at 17 months. Liver and spleen not enlarged. No skin rash.
Mother = Strong. Pos.(3+5+).
Child = Negative (3-5-).
Prev. Pregs.- 1st = F.T., normal, living: 2nd = premature (7/12) - lived two hours, A.P.H.: 3rd = F.T., normal, living: 4th = premature (6½ mos.), normal labour, A.P.H., ? alive: 5th = premature (7 mos.) living, A.P.H. (at 4½ mos.): 6th = premature(6½ mos.) - lived a few hours, A.P.H.

510. W.R. Mother = Negative (3-5-). 12-11-20.
Child = Negative (3-5-). 12-11-20.

3rd Preg. Married. Age 26.
? L.P. Normal pregnancy and labour. Child born alive 7-11-20, weight 9¼ lbs. Dismissed 16-11-20, weight 8¾ lbs. No trace after dismissal.
Prev. Pregs.- 1st and 2nd = F.T., normal, alive (30-6-18).

511. W.R. Mother = Negative (3-5-). 12-11-20.
Child = Negative (3-5-). 12-11-20.

1st Preg. Married. Age 29.
L.P. first week Feby., 1920. Normal pregnancy and labour. Child born alive 7-11-20 - male, weight 6½ lbs. Ruptured Perineum.
Dismissed 16-11-20, weight 5¾ lbs.
28-5-22 - Both well - W.R. Mother = Negative.
Child = Negative.

Case No.

512. W.R. Mother = Negative (3-5-). 12-11-20.
Child = Negative (3-5-). 12-11-20.

1st Preg. Married. Age 28.
L.P. 10th April, 1920. Marginal Placenta Praevia. Bleeding began 4-11-20 and continued till admission on 6-11-20. No clotted blood passed. Vagina packed and tight binder applied. Vertex presentation. Child born dead 7-11-20 - female, weight 3½ lbs. Adherent placenta removed manually. Mother dismissed 13-11-20.

513. W.R. Mother = Negative (3-5-). 12-11-20.

7th Preg. Married. Age 35.
L.P. 8-2-20. Patient was excessively sick during first three months but she was well after that. Normal labour - child born alive 7-11-20, female, weight 8 lbs. Dismissed 16-11-20, weight 7¾ lbs.
The child was known to be alive and well when 16 months old - her only illness had been measles.- W.R. Mother = Doubt. Negative.
Child = Negative.
Prev. Pregs.- All normal (last in Octr., 1919). Had operation for retroversion of uterus in April, 1919.

514. W.R. Mother = Negative (3-5-). 12-11-20.
Child = Negative (3-5-). 12-11-20.

15th Preg. Married. Age 40.
L.P. end Jany., 1920. Patient had indigestion and occasional headaches throughout: sometimes swelling of feet (? urine). Has history of ? Neurasthenia. Child born alive 8-11-20, male, weight 9 lbs. Dismissed 18-11-20, weight 9 lbs.
19-4-22 - The child was known to be alive and well when 17 months old - only illness was measles. - W.R. Mother = Negative (3-5-).
Child = Negative (3-5-).
Prev. Pregs.- 1st to 5th = F.T., living, normal: 6th = premature (6 mos.) lived half an hour: 7th to 11th = normal, living, F.T.: 12th = F.T., S.B., ? monster, Instrs.: 13th & 14th = F.T., living, normal (1914).

Case No.

515. W.R. Mother = Negative (3-5-). 19-11-20.
Child = Negative (3-5-). 26-11-20.

1st Pregnancy. Married. Age 23.
L.P. 20-2-20.
Admitted to Ante-natal Dept. 17-11-20.
Complained of headache throughout pregnancy: morning sickness was excessive and continued till about the 6th month: had an attack of vomiting a few days before admission. Patient a healthy look-ing woman: slight oedema of legs: no albuminuria.
Dismissed 20-11-20.
Re-admitted - in labour - 21-11-20.
Child born, Female, weight 6 lbs. 4 ozs. 21-11-20.
Dismissed 30-11-20, weight 6 lbs. 6 ozs.
Child was alive and well at one year old - weight 19 lbs. 2 ozs. - had then a rash for which attend-ed R.H.S.C. Disp. for a time.

516. W.R. Mother = Negative (3-5-). 12-11-20.
Child = Negative (3-5-). 12-11-20.

1st Pregnancy. Single. Age 24.
L.P. end Feby., 1920.
Pregnancy normal.
Child born 8-11-20, male, weight 7½ lbs.
Dismissed 18-11-20, weight 7 lbs.
Child died 1-12-20 - convulsions.

517. W.R. Mother = Negative (3-5-). 12-11-20.
Child = Negative (3-5-). 12-11-20.
Mother = Negative (3-5-). 17-11-20.

1st Pregnancy. Single. Age 26.
L.P. 2-2-20.
Patient had excessive sickness for first four weeks - after that she improved but still had occasional vomiting. Admitted in labour 8-11-20, looking pale and tired. Albumen +. Membranes ruptured artificially: Forceps - child born 8-11-20, Female, weight 7¾ lbs. Uterus explored after expression of placenta and ragged membranes.
Dismissed 19-11-20, weight 8 lbs.
No further trace.

Case No.

518. W.R. Mother = Negative (3-5-). 12-11-20.
Child = Negative (3-5-). 12-11-20.

1st Preg. Single. Age 18.
L.P. Feby., 1920. Normal pregnancy. Patient had condylomata on vulva and perineum. Normal labour - child born alive 8-11-20 - male. Dismissed 12-12-20, weight 7 lbs.
18-11-21 - The child was alive and well when one year old - No further trace.

519. W.R. Mother = Negative (3-5-). 12-11-20.
Child = Negative (3-5-). 12-11-20.

1st Preg. Married. Age 26.
L.P. 17-1-20. Patient has been very sick periodically throughout the pregnancy. 'Obstruction' in July. In albour 22 hours before admission. Breech presentation - child born alive (26 hours labour), male, weight 7½ lbs. Ruptured perineum: Adherent placenta manually removed. Dismissed 19-11-20, weight 7½ lbs.
19-5-22 - Both well - child now 18 months old.
W.R. Mother = Negative (3-5-). 19-5-22.
Prev. Preg.- ? Abortion at 4 weeks (Aug., 1919). Menstrual cycle 3/28 - usually has crampy pains.

520. W.R. Mother = Negative (3-5-). 12-11-20.

5th Preg. Married. Age 37.
L.P. 24-8-20. Incomplete Abortion. Patient was well till 30-10-20 when she had slight bleeding which continued and became severe on 5-11-20 - clots passed. Has had intermittent pain in right iliac fossa since pregnancy began - looks very anaemic. Uterus cleared out manually. Dismissed 12-11-20.
Prev. Pregs.- All F.T., living, instrs. (last in Feby., 1919).

Case No.

521. W.R. Mother = Negative (3-5-). 12-11-20.
Child = Negative (3-5-). 17-11-20.

2nd Pregnancy. Married. Age 21.
L.P. 18-1-20.
Child born 10-11-20, Female, weight 8½ lbs.
Normal labour: Ruptured Perineum.
Dismissed 20-11-20, weight 8½ lbs.
Child was known to be alive at 15 months. When one year old had an abscess on buttock and when last seen (at 15 months) had two abscesses behind left ear.

Previous Pregnancy was full-time, normal, living (31-3-19).

522. W.R. Mother = Negative (3-5-). 26-11-20.
Child = Negative (3-5-). 17-11-20.

2nd Pregnancy. Married. Age 26.
L.P. 18-2-20.
Normal Pregnancy.
Swelling of feet was noticed one week before admission and frequent micturition for 3 weeks before admission (scanty before that).
Admitted 19-11-20 - slight oedema of feet and ankles: good colour: slight accentuation of 2nd aortic sound: Uric Acid - Albumen + (absent on dismissal). Labour lasted 25 hours - child born 9-11-20, male, weight 8½ lbs.
Dismissed 23-11-20, weight 8½ lbs.
Child died of Pneumonia on 8-10-21.

Previous Pregnancy was in February, 1918 - Chloroform and Foeceps.

523. W.R. Mother = Negative (3-5-). 12-11-20.

5th Pregnancy. Married. Age 30.
L.P. 25-8-20.
Incomplete Abortion.
Patient was well till first week October when bleeding began and continued for 4 weeks - severe for first time on 8-11-20.
Admitted 9-11-20 - Uterus found to be not enlarged, cervix hard and nodular, barely admitting one finger, some blood on examining finger. Uterus explored and curetted - swabbed. Patient pale and anaemic: slightly built. Dismissed 18-11-20.
Previous Pregs.- 1st - 4th = normal, Full-time (last in July, 1919).

Case No.

524. W.R. Mother = Negative (3-5-). 12-11-20.

9th Pregnancy. Married. Age 32.
L.P. 9th Feby., 1920.
Patient has been troubled increasingly with varicose veins - particularly in legs and right foot. Nursing her husband for 14 days before admission - veins worse and threatening to give way.
Admitted to Ante-natal Dept. 6-11-20 - healthy, except for great oedema of legs - specially right leg and right foot has much distended veins: also some tortuous veins on abdomen. Breech presenting
Dismissed - undelivered - 18-11-20.

Previous Pregnancies.- 1st, 4th and 5th = normal: 2nd and 3rd = Chloroform and Forceps, full-time - last in May, 1918: 3 miscarriages all at 3 months (1910-1911). Had influenza twice in 1918. Septic synovitis in 1918. Varicose veins have always troubled patient during pregnancy.

525. W.R. Mother = Strongly Positive (3+5+). 12-11-20.
Child = Strongly Positive (3+5+). 1-12-20.

3rd Pregnancy. Married. Age 21.
L.P. 19-3-20.
Admitted to Ante-natal Dept. 9-11-20.
Patient has felt well since vomiting ceased at 4th month, but states that movements of foetus are felt only at night and cause pain in left side. Uterus 3 fingers above umbilicus. Labour induced 24-11-20 (bougies). Child born 25-11-20, Female, weight 6 lbs. Placenta not adherent: membranes complete. Dismissed 6-12-20.
27-1-21 - Child alive and well. Child's W.R. said to be Negative. Mother has had prolonged treatment (Ante-natal) with "A" Mixture.
4-2-22. Both mother and baby well - having treatment at Central Dispensary.

Previous Pregnancies.- 1st = Vomited throughout - normal, full-time, labour, child still-born - had felt life till onset of labour: 2nd = vomited throughout - normal labour, still-born - no life felt for a week before delivery (Feby., 1920).

Case No.

526. W.R. Mother = Negative (3-5-). 17-11-20.
Child = Negative (3-5-). 12-11-20.

1st Pregnancy. Married. Age 20.
L.P. early Feby., 1920.
Normal pregnancy.
Child born 10-11-20, Female, weight 6 lbs., F.T.
Dismissed 24-11-20, weight 5½ lbs.
No further trace after dismissal.

527. W.R. Mother = Negative (3-5-). 26-11-20.
Child = Negative (3-5-). 12-11-20.
1st Pregnancy. Single. Age 16.
L.P. end of Jany., 1920.
Patient has had headaches since onset of morning sickness in March: improved later:
Child born 10-11-20, Female, weight 8 lbs. (36 hours labour). Vaginal lacerations: numerous gonorrhoeal vulvar warts excised.
Dismissed 25-11-20, weight 8 lbs.
No further trace after dismissal.

528. W.R. Mother = Negative (3-5-). 17-11-20.
Child = Negative (3-5-). 12-11-20.

1st Pregnancy. Single. Age 20.
L.P. ?.
Normal pregnancy.
Child born 10-11-20, Female, full-time, weight 8½ lbs.
Dismissed 20-11-20, weight 7 lbs.

Child was known to be alive and well when 15 months old - had never any illness.

529. W.R. Mother = Negative (3-5-). 17-11-20.
Child = Negative (3-5-). 12-11-20.

2nd Pregnancy. Married. Age 31.
L.P. 14-2-20.
Child born 11-11-20, Female, weight 7 lbs.
Dismissed 20-11-20, weight 6½ lbs.
Child was known to be alive and well at 15 months.
Prev. Pregnancy was normal, F.T., living - 1915.
Occasional Dysmenorrhoea.

530. W.R. Mother = Negative (3-5-). 12-11-20.

7th Pregnancy. Married. Age 38.
L.P. 19-1-20.
Patient had some swelling of feet during last three weeks, but was otherwise well. Labour began 70 hours and membranes ruptured 48 hours before delivery - Delayed 2nd stage: head fixed at brim with much moulding and large caput (Diag. Conj. = 4", True Conj. = 3¾" - Outlet roomy). Ruptured Perineum. Child born 9-11-20, male, weight 7½ lbs., alive. Patient had slightly febrile puerperium. Dismissed 19-11-20, weight 7½ lbs.
Child was known to be alive and well when 15 months old: had Bronchitis at 6 months and Catarrh of Stomach when 9 months old.
W.R. Mother = Negative (3-5-). 4-3-22.
Child = Negative (3-5-). 4-3-22.

Previous Pregnancies.- All spontaneous deliveries but after protracted labour - minimum 48 hours: membranes have always ruptured early. Last pregnancy was in Decr., 1918.

531. W.R. Mother = Negative (3-5-). 17-11-20.

4th Pregnancy. Married. Age 29.
L.P. end August, 1920.
Attended Ante-natal Dispensary 12-11-20 - Leucorrhoea, feeling weak and constipation.

Previous Pregnancies were all full-time, normal alive (last in Jany., 1919.).

532. W.R. Mother = Negative (3-5-). 12-11-20.
Child = Negative (3-5-). 12-11-20.
Mother = Negative (3-5-). 26-11-20.

2nd Pregnancy. Married. Age 33.
L.P. Jany., 1920.
Generally Contracted Pelvis (Diag. Conj. = 3¾" +, True Conj. = 3" +). Occasional swelling of feet. Pains began 8 hours before admission and membranes ruptured 5 hours before admission.
Admitted 11-11-20 at 9 a.m. - os size of coffee-cup: head fixed at brim: marked moulding. Forceps applied when head almost through brim - Ruptured Perineum.
Child born 4.5 p.m. 11-11-20, Female, weight 7½ lbs. Retained placenta removed manually- Membranes complete. Dismissed 22-11-20, 7 lbs
Previous Preg. = Chlor. & Forceps after 72 hrs. labour (Feby., 1918). Enteric Fever - 1913.

Case No.

533. W.R. Mother = Negative (3-5-). 12-11-20.
Child = Negative (3-5-). 12-11-20.

1st Pregnancy. Single. Age 21.
L.P. March, 1920.
Child born 11-11-20, male, weight 8¼ lbs.
Normal labour - Ruptured Perineum.
Dismissed 23-11-20, weight 8 lbs.
Child was known to be alive and well at 1 year old - said to be an exceptionally healthy child.

534. W.R. Mother = Negative (3-5-). 12-11-20.
Child = Negative (3-5-). 12-11-20.

1st Pregnancy. Single. Age 23.
L.P. 21-1-20.
Normal pregnancy and labour (24 hours labour): Full-time: Ruptured Perineum.
Child born 11-11-20, Female, weight 8½ lbs.
Dismissed 22-11-20, weight 7½ lbs.
Child known to be alive and well when 1 year old - never had any illness.

535. W.R. Mother = Strongly Positive (3+5+). 17-11-20

3rd Pregnancy. Married. Age 29.
Child born at home 23-12-20, Male.
Mother and child appeared to be well when visited on 23-3-21 but no further trace as patient removed soon after.

Previous Pregnancies were normal, full-time (last in Septr., 1916).

Case No.

536. W.R. Mother = Negative (3-5-). 17-11-20.

3rd Pregnancy. Married. Age 24.
L.P. 4-9-20.
Attended Ante-natal Dispensary 12-11-20 - had pains in left side and was curetted in G.R.I. in April, 1920. September period was not quite normal - scanty flow. At visit legs swollen and face puffy (? urine).
Admitted to Ante-natal Dept. 15-11-20 - 18-12-20. Albuminuria (+) no casts - Pale and puffy - looked ill. V.S. murrur at apex. Slight oedema of abdomen.
Readmitted 11-4-21 - history of bleeding of 2 days duration on week before admission - no further bleeding. Cystic erosion of cervix portion removed for examination - Cystic Erosion with ulcerated surface.
Readmitted 6-6-21 - supposed to be in labour but pains ceased. Sent out to return in in labour.
Child born at home 11-6-21.
Child was known to be alive and well when 9 months old - no illness.

W.R. Mother = Doubt. Neg. (3+-5-). 4-3-22.
Child = Negative (3-5-). 4-3-22.

History of previous pregnancies not obtained.

537. W.R. Mother = Negative (3-5-). 17-11-20.

2nd Pregnancy. Married. Age 24.
L.P. 16-4-20.
Attended Ante-natal Disp. on 12-11-20 - then 7 months. Generally contracted Pelvis - C.V. = 3½" .

1st Pregnancy (at home) = full-time, face, still-born (Octr., 1919).

538. W.R. Mother = Negative (3-5-). 17-11-20.
Child = Negative (3-5-). 8-12-20.
Mother = Negative (3-5-). 8-12-20.

1st Pregnancy. Single. Age 23.
L.P. 15-2-20.
Attended Ante-natal Disp. 12-10-20.
Child born in Hospital 3-12-20, male, weight 6 lbs. Dismissed 13-12-20.
Patient had a history of anaemia.

Case No.

539. W.R. Mother = Negative (3-5-). 17-11-20.

2nd Pregnancy. Married. Age 23.
L.P. 3-3-20.
Attended Ante-natal Dispensary 12-10-20 - then 8 months.
Child born in Hospital 25-11-20, male, weight 8¾ lbs. P.P.H.
Dismissed 4-12-20, weight 8¼ lbs.

1st Pregnancy was normal, full-time, alive (Feby., 1919).

540. W.R. Mother = Negative (3-5-). 17-11-20.
Child = Negative (3-5-). 17-11-20.

1st Pregnancy. Married. Age 19.
L.P. 3-3-20.
Patient felt well, had no headaches, no sickness, no dimness of vision. Noticed oedema of vulva on 8-11-20 and oedema of feet about 1 month before admission - never prevented her "getting on her shoes".
Admitted to Ante-natal Dept. 10-11-20 - marked oedema of vulva: slight oedema of legs: Albumen +.
Child born 14-11-20 (normal labour) Male, weight 6½ lbs.
Dismissed 23-11-20, weight 6 lbs.
Child was known to be alive and well at 16 months.

W.R. Mother = Negative (3-5-). 4-3-22.
Child = Negative (3-5-). 4-3-22.

541. W.R. Mother = Negative (3-5-). 17-11-20.

5th Pregnancy. Married. Age 35.
L.P. 16-8-20.
Incomplete Abortion.
Admitted 8-11-20. Patient was well till she was kicked on the stomach a few days before admission. Pain began 7-11-20 - aborted - severe haemorrhage which lessened but was stil present on admission - pale, anaemic - rapid pulse - os admitting finger tip - placental tissue palpable. Uterus curetted, douched and swabbed. Dismissed 17-11-20.

Previous Pregnancies.- 1st = F.T., normal, living, spontaneous: 2nd and 3rd = Full-time, living, normal: 4th = miscarriage at 4½ months (Jany., 1920).

542. W.R. Mother = Negative (3-5-). 17-11-20.

5th Pregnancy. Married. Age 23.
L.P. middle Septr., 1920.
Incomplete Abortion.
Admitted 10-11-20. Pain and bleeding began 8-10-20. Ovum expelled before admission: Blanched: Uterus softened and a little enlarged - Curetted, douched, swabbed.
Dismissed 15-11-20.

Previous Pregnancies.- 1st and 2nd = Full-time, spontaneous, alive: 3rd = miscarriage at 6 weeks (May, 1919): 4th = Full-time, living, (24-4-20).

543. W.R. Mother = Negative (3-5-). 17-11-20.

1st Pregnancy. Married. Age 26.
L.P. March, 1920.
Child born 29-10-20, male,
Admitted 10-11-20 Secondary P.P.H. (11th day). Uterus explored and placental tissue removed: douched, swabbed.
Dismissed 19-11-20. Child well.
Child was known to be alive and well at 16 months -
W.R. Mother = Positive (3+5-). 4-3-22.
Child = Negative (3-5-). 4-3-22.

544. W.R. Mother = Negative (3-5-). 17-11-20.

9th Pregnancy. Married. Age 43.
L.P. 1st week August, 1920.
Incomplete Abortion.
Patient was well till 14 days before admission when there was some haemorrhage - intermittent till 4-11-20 when there was severe haemorrhage with pain - bleeding slightly but continuously till admitted on 8-11-20. Pale but otherwise healthy: placental debris palpated - uterus explored, curetted and swabbed.

Previous Pregnancies.- 1st to 3rd = Full-time, living, forceps: 4th = 3½ months pregnancy: 5th = 3½ months: 6th = normal: 7th = alive, full-time, Chloroform and Forceps: 8th = 3 months abortion (May, 1920). Last live child in April, 1915).

Case No.

545. W.R. Mother = Negative (3-5-). 17-11-20.

1st Pregnancy. Single. Age 21.
L.P. Aug., 1920.
Incomplete Abortion.
Admitted 10-11-20 - had slight haemorrhage 14 days before admission which did not last long and further bleeding on 7-11-20 when " something came away". Bleeding continued till admission but was unaccompanied by pain. Uterus explored and placental tissue removed - douched, swabbed. Uterus soft and slightly enlarged.

546. W.R. Mother = Negative (3-5-). 17-11-20.

1st Pregnancy. Married. Age 19.
L.P. 12-3-20.
Admitted to Ante-natal Dept. - Leucorrhoeal discharge since before pregnancy. Itching in left nipple about 9 weeks before admission - had been attending Dispensary. Nipple tend -ing to suppurate. Dismissed 20-11-20.
Re-admitted 16-12-20 - Pelvis - Diag. Conj. = 4" +, True Conj. = 3¼" +.
Child born, Female, 16-12-20, weight 7¼ lbs.
Dismissed 29-12-20.
No further trace of mother and child after dismissal.

547. W.R. Mother = Negative (3-5-). 17-11-20.

4th Pregnancy. Married. Age 23.
L.P. 23-6-20.
Threatened Abortion.
Patient was well till 12 days before admission when there was some bleeding but no pain. Haemorrhage continued intermittently till admission on 10-11-20. Uterus acutely anti-flexed: patient looks anaemic and tired.
Dismissed from Ante-natal Dept. 27-11-20 - undelivered.

Previous Pregnancies.- 1st = Full-time, normal, living: 2nd = 8 months - spontaneous delivery - alive: 3rd = Full-time, normal, alive (March, 1919).

Case No.

548. W.R. Mother = Negative (3-5-). 17-11-20.

3rd Pregnancy. Married. Age 22.
L.P. 30-6-20.
Patient was well till she had " a turn or two" with vomiting on 6-11-20 - vomited also on 7th and 8th Novr.
Admitted 10-11-20 - has not felt life for 1-2 weeks. No oedema, colour good, pulse normal, urine normal. Diagnosed Hysteria.
Dismissed 17-11-20 - uterus about 5 months size.

Previous Pregnancies.- 1st = Full-time, living, forceps - Eclampsia: 2nd = full-time, living - spontaneous delivery (19-6-19). Has severe premenstrual headaches. Osteomyelitis (left ankle) as a child.

549. W.R. Mother = Negative (3-5-). 17-11-20.

1st Pregnancy. Single. Age 21.
L.P. 1st week Feby., 1920.
Admitted 8-11-20.
Dismissed 18-11-20 - False Labour.

550. W.R. Mother = Negative (3-5-). 17-11-20.

1st Pregnancy. Married. Age 29.
L.P. 23-2-20.
Admitted 1-11-20 - no life felt for several weeks - uterus about 7 months size, presenting part not made out.
Macerated Foetus born 1-11-20, male, weight 4 3/4 lbs. Placenta not adherent: membranes complete: foul smelling liquor amnii. Patient says she has occasional sore throats and that her hair has been coming out.

551. W.R. Mother = Negative (3∓5-). 17-11-20.

1st Pregnancy. Married. Age 19.
L.P. 2nd Feby., 1920.
Labour began 8-11-20 - admitted 10-11-20. Membranes ruptured just before onset of pains
Child born 10-11-20 - Impacted Breech - Ruptured Perineum - Female, weight 7 lbs., born dead.
Mother attended G.R.I. skin Disp. for Psoriasis. Labial warts present. Perineal repair went septic.

Case No.

552. W.R. Mother = Negative (3-5-). 17-11-20.

10th Pregnancy. Married. Age 32.
L.P. 1st week Septr., 1920.
Incomplete Abortion. Patient was fairly well till 5-11-20 when bleeding but no pain commenced. Bleeding continued till admission on 10-11-20. Uterus explored, curetted and swabbed.
Dismissed 17-11-20.

Previous Pregnancies.- 1st = full-time, alive - Chloroform and Instruments: 2nd - 5th = normal, full-time, spontaneous, alive (Decr., 1915). Three miscarriages since Decr., 1919 - all at 2 months - last in June, 1920.

553. W.R. Mother = Strongly Positive (3+5+). 19-11-2
Child = Strongly Positive (3+5+). 19-11-2

1st Pregnancy. Married. Age 25.
L.P. Feby., 1920.
Slightly Contracted Pelvis (Diag. Conj. = 4", True Conj. = 3¼"). Patient did not feel well for 3 months before labour and for last three weeks had cough. Pains began 9-11-20 -
Admitted morning of 12-11-20 - head jammed well down in pelvis: os coffee-cup size: flushed and exhausted: slight oedema of legs: os not dilating very well - dilated manually under chloroform some hours after admission -
Forceps - child born 12-11-20, Female, weight 6¾ lbs. Ruptured Perineum.
Mother has Bronchitis: had mastitis after injury to breast 4 years ago - operation in G.R.I. No history of Rheumatism or Scarlet Fever: Has Mitral Stenosis.
Dismissed 6-12-20, weight 7½ lbs.
Visited 26-12-20 - Child alive but has lost weight- having Hydrarg c̄ cret. at Dispensary. Mother died at home 8-12-20.
Visited later - child doing well.
When next visit paid people had removed.

Case No.

554. W.R. Mother = Negative (3-5-). 17-11-20.

1st Preg. Married. Age 25.
L.P. Feby., 1920. Normal Labour: R.P.
The child was born before admssion to Hospital on 11-11-20, female, alive, weight 7½ lbs. Dismissed 20-11-20, weight 7½ lbs. No trace after dismissal.

555. W.R. Mother = Negative (3-5-). 26-11-20.
Child = Negative (3-5-). 17-11-20.

7th Preg. Married. Age 27.
L.P. Feby., 1920. Patient was well till two months before delivery when swelling of feet appeared. Admitted 14-11-20 - very slight oedema of feet: Uric acid: Albumen ++. On 21-11-20 albumen had gone completely. Child born alive 14-11-20, female, weight 6½ lbs. Dismissed 23-11-20, weight 6½ lbs.
18-11-21 - The child was known to be alive and well when one year old - only illness was Whooping-cough.
Prev. Pregs.- 5 = F.T., normal, alive (last in Aug., 1918): one was a four months miscarriage - the result of a fall in Aug., 1917.

556. W.R. Mother = Negative (3-5-). 26-11-20.
Child = Negative (3-5-). 17-11-20.

1st Preg. Married. Age 18.
L.P. Feby., 1920. Normal pregnancy. Child born alive 13-11-20 (28 hours labour), male, weight 7 lbs. R.P. Dismissed 23-11-20.
19-5-22 - Both well - W.R. Mother = Negative.
Child = Negative.

Case No.

557. W.R. Mother = Negative (3-5-). 19-11-20.
Child = Negative (3-5-). 17-11-20.

4th Pregnancy. Married. Age 24.
L.P. 7th Feby., 1920.
Patient was well throughout pregnancy but for occasional weak turns.
Membranes ruptured 12-11-20.
Child born 14-11-20, male, weight 6 lbs.
Dismissed 24-11-20, weight 6¼ lbs.
Child was known to be alive and well when 15 months old: Mother fairly well - attending G.R.I. Dispensary.

W.R. Mother = Doubt. Positive (3±5∓). 4-3-22.
Child = Negative (3-5-). 4-3-22.

Previous Pregnancies.- 1st = Full-time, normal, alive: 2nd = full-time, normal, still-born - secondary P.P.H.: 3rd = normal, full-time, alive (13-5-17). Patient had Rheumatism and swelling of hands about 4 years ago.

558. W.R. Mother = Negative (3-5-). 26-11-20.
Child = Negative (3-5-). 17-11-20.

1st Pregnancy. Married. Age 21.
L.P. Feby., 1920.
Normal pregnancy: Mother healthy: 23 hours labour.
Child born 13-11-20, Female, weight 6½ lbs.
Dismissed 23-11-20, weight 6 lbs.
No further trace after dismissal.

559. W.R. Mother = Negative (3-5-). 26-11-20.
Child = Negative (3-5-). 17-11-20.

4th Pregnancy. Married. Age 28.
L.P. 27-2-20.
Patient has always felt " done out" during present pregnancy and complained of pains in the back: Failed Forceps before admission - Spontaneous delivery. - Child born 13-11-20, male, weight 7½ lbs. Bruising of head. Labour lasted 4½ hours (?). Child died 14-11-20.

Previous Pregnancies.- 1st = Transverse - 12 years ago (illegitimate): 2nd and 3rd = normal, full-time (last in Feby., 1919).
Mother healthy: Epilepsy appeared at 7 years of age - still has occasional fits.

Case No.

560. W.R. Mother = Negative (3-5-). 17-11-20.

1st Pregnancy. Married. Age 19.
L.P. Feby., 1920.
Patient on admission had bad scabies.
Normal labour - Child born 14-11-20, Female, weight 7 lbs. 4 ozs,
Dismissed 23-11-20 - both well.
7-2-21 - Visited - Baby gaining well but has rash over head and body.
Child was known to be alive and well at 15 months old.

561. W.R. Mother = Negative (3-5-). 26-11-20.
Child = Negative (3-5-). 17-11-20.

2nd Pregnancy. Married. Age 23.
L.P. 31-1-20.
Child born 13-11-20, male, weight 8½ lbs. - 16 hours labour. Ruptured Perineum.
Dismissed 23-11-20, weight 7¼ lbs.
Child was known to be alive and well when 15 months old: Bronchitis only illness.

1st Pregnancy = Chloroform and Forceps - Full-time, alive. Mother had hare-lip operation in infancy: had diphtheria in 1913 and scarlet fever in 1916.

562. W.R. Mother = Strongly Positive (3+5+).19-11-20.
Child = Strongly Positive (3+5+).17-11-20.

3rd Pregnancy. Married. Age 25.
L.P. early Feby., 1920.
Normal labour - Child born 15-11-20, male, weight 8½ lbs.
Dismissed 25-11-20, weight 7¾ lbs.
Visited - Child alive 2-12-20 - sore buttocks. No treatment for mother but child having Hydrarg c̄ cret. at Dispensary. Child not gaining. A previous child died about one year ago in Baird Street.
Attended Dispensary 18-2-22 (child 15 months) Both well -
W.R. Mother = Strong. Positive (3+5+) 18-2-22.
Child = Negative (3-5-). 18-2-22.

Previous Pregnancies.- 1st = 8 months, normal, alive: 2nd = full-time, normal, alive (Dec., 1919). Mother small but healthy.

Case No.

563. W.R. Mother = Strongly Positive (3+5+). 19-11-20
Child = Strongly Positive (3+5+). 19-11-20.

2nd Pregnancy. Married. Age 23.
L.P. Feby., 1920.
Normal pregnancy and labour.
Child born 16-11-20, male, weight 7½ lbs.
Dismissed 25-11-20, weight 7½ lbs.
Visited 1-12-20 - child gaining slightly: treated with Hydrarg c cret. at Dispensary. Mother has sore right breast.
Visited 1-2-22 - Patient returned to Ireland about 3 months ago and child died of Pneumonia shortly after arrival in Ireland.

1st Pregnancy was Full-time, living, normal 26-9-19. Mother healthy.

564. W.R. Mother = Negative(3-5-). 17-11-20.

1st Pregnancy. Single. Age 20.
L.P. middle August, 1920.
Admitted to Ante-natal Dept. 8-11-20 - Hyperemesis Gravidarum. One month before admission sickness began in the morning at first - grew gradually worse - no food retained - losing weight but no headache. Uterus just palpable on admission. Acetone and Diacetic acid present but no albuminuria. Improved after admission. Dismissed 20-11-20.

565. W.R. Mother = Negative (3-5-). 17-11-20.
Child = Negative (3-5-). 8-12-20.

1st Pregnancy. Married. Age 23.
L.P. 7-2-20.
Admitted 15-11-20 - False Labour. Dismissed 15-11-20.
Re-admitted 5-12-20 - child born 6-12-20 - Female, weight 8 lbs. Forceps - lacerations.
Dismissed 16-12-20, weight 6 lbs.
Child known to be alive and well when 11 months old - no illness.

Case No.

566. W.R. Mother = Negative (3-5-). 17-11-20.
Child = Negative (3-5-). 25-11-20.

2nd Pregnancy. Married. Age 25.
L.P. 16-4-20.
Admitted to Ante-natal Dept. 12-11-20 - Dismissed 20-11-20 and re-admitted 28-1-21 - Patient complained of left sided pain since birth of 1st child - worse since second pregnancy began. Pain severe when child moves - no haemorrhage. Uterus up to umbilicus on first admission - multiple fibromyomata palpable.
Child born 18-2-21 - spontaneous delivery - male, weight 8 lbs.
Dismissed 28-2-20, weight 8 lbs.
Child was alive and well at 9 months old - then no illness.

1st Pregnancy was Full-time, alive, spontaneous in April, 1919.

567. W.R. Mother = Negative (3-5-). 17-11-20.

1st Pregnancy. Married. Age 25.
L.P. 2nd week in June, 1920.
Complete miscarriage 12-11-20.
Patient felt well till 5 p.m. on 14-11-20 when she had severe pain in back with haemorrhage. Was kicked on abdomen 2 months previously and had abdominal pain for 2 days. Uterus about 4 months' size on admission (12-11-20).

568. W.R. Mother = Negative (3-5-). 17-11-20.

9th Pregnancy. Married. Age 34.
L.P. Feby., 1920.
Patient was complaining of abdominal pain for two months before admission - resembled labour pains.
Child born before admission on 12-11-20 - spontaneous delivery, child still-born.
Post-Partum Haemorrhage - bleeding on admission
Uterus flabby but responded to massage and pituitrin.

Previous Pregnancies.- 1st - 6th = normal, full-time, living: 7th = still-born (2-4-19).
A.P.H.: 8th = 4 months' miscarriage - Octr., 1919.

Case No.

569. W.R. Mother = Negative (3-5-). 17-11-20.

9th Pregnancy. Married. Age 46.
L.P. 8-9-20.
Patient was well till 1st Novr., 1920 when she began to bleed, but had no pain. Bleeding continued till admission on 12-11-20.
Inevitable Abortion. - Uterus just palpable - ovum lying loose in uterus with placental tissue. Curetted and swabbed.
Dismissed 19-11-20.

Previous Pregnancies were all normal, full-time - last im March, 1915.

570. W.R. Mother = Negative (3-5-). 17-11-20.

5th Pregnancy. Married. Age 30.
L.P. 25-8-20.
Incomplete Abortion - ovum expelled 14-11-20, placenta retained - some bleeding since. Only slight pains just before expulsion of ovum. Curetted 15-11-20 - uterus swabbed.
Dismissed 22-11-20.

Previous Pregnancies.- 1st = full-time, normal, living: 2nd = full-time, Chloroform, living (16-3-12): 3rd and 4th (Octr., 1919) = four months' miscarriages.

571. W.R. Mother = Negative (3-5-). 17-11-20.
Child = Negative (3-5-). 3-12-20.

2nd Pregnancy. Single. Age 26.
L.P. 15-2-20.
Admitted Ante-natal Dept. 15-11-20.
There had been slight bleeding at 7 months and a little pain but settled down with rest-Breech presenting on admission - spontaneous version before labour - Child born 30-11-20, normal labour, male child, weight 6 lbs. On 9th day of puerperium bright red blood p.v. - Secondary P.P.H. Curetted - a few shreds of placental tissue removed.
Dismissed 15-12-20, weight 5 lbs.
No trace after dismissal.

Previous Pregnancy was full-time, delayed 2nd stage - Forceps - lived a short time.

Case No.

572. W.R. Mother = Negative (3-5-). 17-11-20.

11th Pregnancy. Married. Age 42.
L.P. early Septr., 1920.
Incomplete Abortion. Patient had some bleeding on 25-10-20 - continued for one week when clots started to come away - ovum expelled but placental tissue remaining.
Admitted 15-11-20 - curetted and swabbed.

Previous Pregnancies.- First 9 = full-time, living, normal: 10th (April, 1920) = Placenta Praevia (7 months) Still-born in G.R.M.H. Patient pale and blanched (? haem.) V.S. mitral murmur.

573. W.R. Mother = Negative (3-5-). 17-11-20.

1st Pregnancy. Married. Age 32.
L.P. 14-2-20.
Normal Pregnancy.
Pains began 14-11-20 at 11-30 p.m. over 12 hours after rupture of membranes. Breech presenting Failed Forceps 2-3 times before admission. On admission exhausted and partly anaesthetis-ed - child born as far as neck. Forceps bruising on breech and depressed fracture of fronto parietal region. Torn Perineum and bruising of vagina and vulva. Head easily delivered - child dead - male, weight 7¾ lbs Pelvis was not contracted.

574. W.R. Mother = Negative (3-5-). 26-11-20.
Child = Negative (3-5-). 19-11-20.

1st Pregnancy. Married. Age 27.
L.P. 27-1-20.
Patient vomited throughout pregnancy. Has Bronchitis: internal strabismus: looks healthy.
Child born 16-11-20, Female, weight 7 lbs. normal labour - lasted 9 hours. Ruptured Perineum.
Dismissed 26-11-20, weight 6½ lbs.

No trace after dismissal - Patient said to have gone to Ireland.

Case No.

575. W.R. Mother = Negative (3-5-). 20-11-20.
Child = Negative (3-5-). 19-11-20.

2nd Preg. Single. Age 26.
L.P. 1-2-20. Patient has had discharge ever since she became pregnant but is otherwise well. Child born alive 16-11-20 after 19 hours labour - female, weight 6½ lbs. Dismissed 24-11-20, weight 7½ lbs.
The child was known to be alive and well when 15 months old - never any illness. Mother also well. - W.R. Mother = Negative (3-5-).
Child = Negative (3-5-).
Prev. Pregs.- F.T., alive - Chlor. & Forceps (Aug., 1917) - lived only 26 hours.

576. W.R. Mother = Negative (3-5-). 26-11-20.
Child = Negative (3-5-). 19-11-20.

1st Preg. Married. Age 26.
L.P. early Feby., 1920. Severe vomiting at first but no other complications. Attended Antenatal Dispensary on account of Contracted Pelvis (contracted A.P. at outlet). Forceps delivery - child born alive 16-11-20, female, weight 6½ lbs. Dismissed 26-11-20, weight 6 lbs. The child was reported to be well when one year old and until then never any illness, but died of Pneumonia when 14 months old.

577. W.R. Mother = Negative (3-5-). 26-11-20.
Child = Negative (3-5-). 19-11-20.

9th Preg. Married. Age 33.
L.P. end Feby., 1920. Transverse (anterior parietal). Flat pelvis (Diag. Conj. = 4" +, True Conj. = 3¼" +). Slight tibial curvature - otherwise healthy. Had Bright's disease 19 years ago. High forceps applied (after 24 hours labour) - child born alive 15-11-20, male, weight 8½ lbs. Retained placenta removed manually. Dismissed 24-11-20, weight 7¾ lbs.
17-5-21 - Child shortly since had operation for rupture in R.H.S.C.
18-5-22 - Child 18 months old and very healthy.
W.R. Mother = Negative (3-5-). 18-5-22.
Child = Negative (3-5-). 18-5-22.
Prev. Pregs.- 1st, 2nd, 6th, 7th and 8th = all male, forceps (2nd = transverse, S.B., 1st and 8th = alive but died within a few days of birth): 3rd, 4th and 5th = spontaneous, alive (last child born May, 1919).

Case No.

578. W.R. Mother = Negative (3-5-). 26-11-20.
Child = Negative (3-5-). 19-11-20.

1st Preg. Single. Age 24.
L.P. Feby., 1920. Normal pregnancy and labour. Child born alive 16-11-20, female, weight 7 lbs. (3½ hours labour). Child died 29-11-20.

579. W.R. Mother = Negative (3-5-). 26-11-20.
Child = Negative (3-5-). 19-11-20.

1st Preg. Single. Age 33.
L.P. 16-2-20. Patient was well throughout pregnancy except for heart-burn. Pelvis - Diag. Conj. = 4½" +, True Conj. = 3¾"+. Third vertex presentation- persistent occipito-posterior. Forceps (30 hours labour). Ruptured Perineum. Child born alive 15-11-20, female, weight 9 lbs. Dismissed 26-11-20, weight 7¾ lbs. Child very delicate and died when one month old.

580. W.R. Mother = Negative (3-5-). 26-11-20.
Child = Negative (3-5-). 29-11-20.

14th Preg. Married. Age 44.
L.P. 17-2-20. Normal pregnancy and labour: marked chloasma. Child born 16-11-20, male, weight 9¼ lbs. Dismissed 23-11-20, weight 8¾ lbs.
25-5-22 - Child had measles but better now. Very well. Mother fairly well.
W.R. Mother = Negative (3-5-). 26-5-22.
Child = Negative (3-5-). 26-5-22.
Prev. Pregs.- 12 = F.T., normal, alive: 13th = Transverse, Chlor. & Forceps (1915).

Case No.

581. W.R. Mother = Negative (3-5-). 26-11-20.
Child = Negative (3-5-). 19-11-20.

1st Pregnancy. Single. Age 22.
L.P. 6-2-20.
Normal Pregnancy and labour. Ruptured Perineum.
Child born 16-11-20, male, weight 8¾ lbs.
Dismissed 25-11-20, weight 7½ lbs.
Child was known to be alive and well at 15 months - had been very seriously ill with Catarrh in Stomach and Bowels but now quite well.

582. W.R. Mother = Negative (3-5-). 26-11-20.
Child = Negative (3-5-). 19-11-20.

2nd Pregnancy. Single. Age 28.
L.P. 11-2-20.
Normal pregnancy and labour.
Child born 17-11-20, male, weight 8 lbs.
Dismissed 25-11-20, weight 8 lbs.
22-2-22 - Child boarded out and mother out working. Child stated to be alive and well - now 15 months old.

1st Pregnancy was normal, full-time, alive (May, 1917).

583. W.R. Mother = Negative (3-5-). 19-11-20.

1st Pregnancy. Married. Age 24.
L.P. 10th March, 1920.
Admitted to Ante-natal Dept. 13-11-20 - from Ante-natal Dispensary - Albuminuria. Patient complained of pain in left side for some time, but has not been troubled with it recently. Albuminuria noted at Dispensary. Had Nephropexy (left) in G.R.I. Sept., 1919. On admission very slight oedema of ankles. Uric acid: Albumen ++. Pus Cells, Staphylococcus and Coliform Bacillus present. "Head down - not fixed" (? size of pelvis). Caesarean Section - child born 16-12-20, male, weight 6 lbs., alive. Patient sterilised. Child died 27-12-20.

Case No.

584. W.R. Mother = Negative (3-5-). 19-11-20.

3rd Pregnancy. Married. Age 27.
L.P. end of Jany., 1920.
Patient had " threatened Appendicitis and Pleurisy" early in pregnancy, otherwise well till morning of admission (14-11-20) when thick dark red blood was passed - no life felt thereafter. Accidental Haemorrhage (concealed and apparent). Bleeding on admission - no placenta praevia - binder applied. Spontaneous delivery a few hours later - Child born 14-11-20 male, weight 8 lbs. dead. Placenta slightly ragged at margin (? complete).

Previous Pregnancies were full-time, normal, alive (last in Jany., 1918).

585. W.R. Mother = Negative (3-5-). 19-11-20.

1st Pregnancy. Single. Age 24.
L.P. 3rd week March, 1920.
Admitted Ante-natal Dept. 13-11-20 - Generally Contracted Pelvis (Diag. Conj. = 3¼" ; True Conj. = 2½"). Patient very small and slightly built: no deformity of limbs. Caesarean Section 12-12-20 - Child, male, weight 6 lbs. died 22-12-20. During puerperium mother had symptoms suggesting Enteric Fever - Widal Reaction = Negative 20-12-20.
Dismissed 30-12-20.

586. W.R. Mother = Negative (3-5-). 19-11-20.

1st Pregnancy. Married. Age 23.
L.P. 15-6-20.
Patient admitted to Ante-natal Dept. 13-11-20 - Hyperemesis Gravidarum. Since middle of August patient has vomited all food, and during 3-4 weeks before admission even sips of water have been followed by vomiting. Anorexia - losing weight. Slightly built woman: rather pale and with sunken eyes (? urine). Uterus midway between Symphysis and umbilicus. Responded to Stomach lavage, Sod. bicarb.
Dismissed undelivered 27-11-20.

Case No.

587. W.R. Mother = Negative (3$\overline{=}$5-). 19-11-20.
Child = Negative (3-5-).

1st Preg. Married. Age 27.
L.P. 20-3-20. Admitted to Ante-natal Dept. 13-11-20 - Albuminuria -. Has complained of headaches and dizziness for three weeks: noticed swelling of feet and legs two weeks before admission: noticed that urine was scanty recently. On admission oedema of feet and ankles, slight puffiness of face, good colour. Uric acid: Albumen +++ - no blood. Induced labour - child born alive 12-12-20, male, premature. Mother was dismissed 31-12-20 but child died in Hospital on 1-1-21.

588. W.R. Mother = Negative (3-5-). 19-11-20.

6th Preg. Married. Age 29.
L.P. early July, 1920. Placenta Praevia: Inevitable Abortion. Patient was well till early in Septr. when bleeding began very slightly and continued - more severe for fourteen days before admission. No clots passed. Admitted 13-11-20, very pale and anaemic. Vagina douched and packed tightly. Spontaneous abortion 14-11-20 - complete. Placenta overlapping os.
Prev. Pregs.- All normal, F.T., alive (last in Octr., 1919).

589. W.R. Mother = Negative (3-5-). 19-11-20.
Child = Negative (3-5-). 19-11-20.

2nd Preg. Married. Age 23.
L.P. Feby., 1920. Normal pregnancy and labour - child born alive 18-11-20, female, weight 9¾ lbs. Severe P.P.H. Uterus packed 18-11-20. Dismissed 26-11-20, weight 9¾ lbs.
18-5-22 - Child 18 months old and very well - never any illness. -
W.R. Mother = Negative.(3tr. 5-). 18-5-22.
Child = Negative.(3-5-). 18-5-22.
Prev. Preg.- Normal, F.T., alive (1915).

Case No.

590. W.R. Mother = Negative (3-5-). 26-11-20.
Child = Negative (3-5-). 19-11-20.

2nd Pregnancy. Single. Age 25.
L.P. 2-4-20.
Normal Pregnancy and Labour. Ruptured Perineum.
Child born 18-11-20, Female, weight 9 lbs.
Dismissed 25-11-20.
Child was alive and well when 15 months old - never had any illness.

Previous Pregnancy was normal, Full-time, alive (June, 1919). Mother a healthy woman - scar of Mastitis right breast.

591. W.R. Mother = Negative (3-5-). 19-11-20.
Child = Negative (3-5-). 19-11-20.

13th Pregnancy. Married. Age 43.
L.P. 16-3-20.
Normal pregnancy and labour.
Patient had Erysipelas 19 months before admission - was in Ruchhill.
Child born 17-11-20, male, weight 7½ lbs.
Dismissed 27-11-20, weight 7¼ lbs.
No further trace.

Previous Pregnancies.- All 10 children full-time, living, spontaneous (last in May, 1918): 2 miscarriages at 3 months - 1st = 13 years ago - 2nd in 1917.

592. W.R. Mother = Negative (3-5-). 19-11-20.
Child = Negative (3-5-). 19-11-20.

2nd Pregnancy. Married. Age 28.
L.P. 15-2-20.
Patient was well throughout pregnancy, till short pains a few days before labour began. Some ricketty deformity and pelvis slightly contracted.
Child born 17-11-20, spontaneous, Male, weight 7½ lbs.
Dismissed 26-11-20, weight 8¼ lbs.
Child was alive and well when 15 months old - only illness was Measles.

Previous Pregnancy was full-time, living - Chloroform and Instruments 22-5-16.

Case No.

593. W.R. Mother = Negative (3-5-). 19-11-20.

7th Preg. Married. Age 40.
L.P. 9-3-20. Patient was admitted to Antenatal Dept. 13-11-20. Accidental Haemorrhage - slight-apparent. Some fluid blood came away day of admission. Patient had been well till then. Slight bleeding on admission - no placenta palpable - child alive -. Dismissed undelivered 20-11-20.
Prev. Pregs.- All normal (last in March, 1914) but slight A.P.H. with first. Patient had influenza and pneumonia in 1919.

594. W.R. Mother = Negative (3-5-). 19-11-20.

1st Preg. Married. Age 26.
L.P. 2-3-20. Eclampsia: Forceps: Ruptured perineum. Patient had loss of appetite in September with vomiting and headaches then noticed oedema of feet and legs. Went to bed but did not consult a doctor. Labour began 10-11-20 and shortly after patient became unconscious and remained so till after delivery on 11-11-20. Admitted on 10-11-20 in coma - head down: os well dilated: marked oedema of body generally: continuous fits. Urine - Esbach 5.5. Child born dead 11-11-20, weight 9 lbs., female. Patient responded to eclamptic treatment. Dismissed 4-12-20.

595. W.R. Mother = Negative (3-5-). 19-11-20.

1st Preg. Married. Age 21.
L.P. ? end March, 1920. Patient was well till 1-11-20 when she got a fright - restless night 14/15 Novr., 1920. Bleeding began 15-11-20 - uterus packed before admission. Admitted 15-11-20 - pale, pulse rapid but good quality. Pains came on soon after admission - packing expelled 16-11-20. Spontaneous delivery 16-11-20 - child born dead - female, weight 6½ lbs. Placenta complete.

Case No.

596. W.R. Mother = Negative (3-5-). 19-11-20.

7th Preg. Married. Age 40.
L.P. Feby., 1920. Normal pregnancy. Slight pains commenced night of 14-11-20: membranes ruptured 16-11-20. Delivered 17-11-20 (normal labour) - male, weight 6¾ lbs., living. Dismissed 25-11-20, weight 6¾ lbs.
The child was well when sixteen months old - never any illness. Mother had pain in side but otherwise well. 25-5-22 - Mother well : child died of Pneumonia and Bronchitis 2-3-22.
Prev. Pregs.- 1st = F.T., living, spontaneous: 2nd = F.T., S.B.: 3rd to 6th = F.T., living, spontaneous (last in March, 1916).

597. W.R. Mother = Negative (3-5-). 19-11-20.

16th Preg. Married. Age 42.
L.P. ?: Amenorrhoea for years - " always pregnant before there was time for menstruation" . Admitted to Ante-natal Dept. 17-11-20 - abdominal pain (present since 7th month). Abdomen now full-time size, pelvis normal. Patient unhealthy looking. Dismissed undelivered 20-11-20.
Prev. Pregs.- 1st = S.B., F.T., normal: 2nd = F.T., living: 3rd = S.B., F.T.: 4th = S.B., F.T.: 5th = S.B., F.T.: 6th to 13th = living, F.T., normal: 14th = miscarriage (5 mos.): 15th = S.B., Chlor. (July, 1919).

598. W.R. Mother = Negative (3-5-). 19-11-20.

2nd Preg. Married. Age 29.
L.P. Feby., 1920. Admitted to Ante-natal Dept. 17-11-20 - Cardiac. Patient was well till fourteen days before admission when she had vomiting and fainting turns. Had pain in back throughout pregnancy and frequent " heart-burn" . On admission - no oedema: dark under eyes: roughening of first mitral sound: second aortic accentuated. Slight albuminuria. Normal labour - child born alive 7-12-20, female, weight 8¼ lbs. Dismissed 16-12-20. The baby was admitted to Ruchhill Hosp. at 4 months with Bronchopneumonia - was there for about eight months. 25-5-22 - Child(17 months old) rickety but otherwise well.
Prev. Preg.- normal, F.T., living (16-9-19).

Case No.

599. W.R. Mother = Negative (3-3-). 10-11-20.

6th Pregnancy. Married. Age 32.
L.P. 16-2-20.
Admitted to Ante-natal Dept. 17-11-20 - Slightly contracted pelvis (? conjugates).
Pregnancy was normal throughout. Head showed no signs of fixing after labour had progressed some hours. Caesarean Section performed
Child born 1-12-20, male, weight 9 lbs.
Dismissed 22-12-20, weight 9½ lbs.
Child was reported to be well when at the age of 6 weeks but no further trace.
Patient was sterilised.
Previous Pregnancies.- 1st = full-time, Chloroform and Forceps - alive, Male: 2nd = Full-time, living, Male, Chloroform and Forceps: 3rd = spontaneous, Full-time, Female, alive: 4th and 5th = Full-time, living, male, Chloroform and Forceps (last in June, 1919).

600. W.R. Mother = Strongly Positive (3+5+).1911-20.

6th Pregnancy. Married. Age 41.
L.P. 3-3-20.
Patient was very well till one week before admission when continuous vomiting began. Headache for first time on day of admission.
Admitted to Ante-natal Dept. 17-11-20 - Toxaemia of Pregnancy. Patient looked ill on admission - no lesion in circulatory or respiratory systems: uterus 8½ months size: Urine - trace of albumen: no acetone or diacetic acid: tongue furred and dry.
Dismissed 29-11-20 - undelivered.
Child born at home 9-12-20, Female, normal labour.
Visited 28-7-21. - Mother fairly well - no treatment: Baby just recovering from Whooping Cough but otherwise well.
12-1-22 - Mother has Influenza: child well.
W.R. Mother = Strongly Positive (3+5+) 4-2-22.
Child = Strongly Positive (3+5+) 4-2-22.

Previous Pregnancies.- 1st = F.T., living: 2nd= F.T., living: 3rd = F.T., living - died after a few days: 4th = F.T., living: 5th = 8 months' macerated Foetus (Feby., 1919).

Case No.

601. W.R. Mother = Negative (3-5-). 26-11-20.
Child = Negative (3-5-). 19-11-20.

1st Pregnancy. Married. Age 37.
L.P. 15-2-20.
Patient was sick for first 6 months but was otherwise well till onset of labour which lasted 7 hours. Mother a healthy woman.
Child born 18-11-20, male, weight 8 lbs.
Dismissed 27-11-20, weight 8¼ lbs.
No trace after dismissal.

602. W.R. Mother = Negative (3-5-). 26-11-20.

2nd Pregnancy. Married. Age 24.
L.P. May or June, 1920.
Admitted to Ante-natal Disp. 19-11-20 - headaches, blurred vision (? urine), bearing down pain.
Admitted 22-2-21, in labour - Twins born 22-2-21 (1) male, weight 5 lbs., breech: (2). Male, weight 5¾ lbs., Transverse, leg brought down - delivered as breech. R.P.
Dismissed 2-3-21 (1) weight = 5 lbs.
(2) weight = 5½ lbs.
Died - one on 9th and the other on 10th March, 1921 - " Debility" .

Previous pregnancy was normal - May, 1918.

603. W.R. Mother = Negative (3-5-). 26-11-20.
Child = Negative (3-5-). 26-11-20.

3rd Pregnancy. Single. Age 24.
L.P. Feby., 1920.
Patient was well thorughout pregnancy -. Normal labour (lasted 4 hours).
Child born 20-11-20, male, weight 7½ lbs.
Dismissed 29-11-20, weight 7¼ lbs.

Child was alive and well at the age of 15 months - never any illness.

Previous Pregnancies were ? normal.

604. W.R. Mother = Strongly Positive (3+5+).26-11-20.
Child = Strongly Positive (3+5+).26-11-20.

5th Pregnancy. Married. Age 26.
L.P. 16-2-20.
Patient had Bronchitis twice during pregnancy -
Child born 20-11-20, male, weight 6 lbs. (11 hours labour). Child died 27-11-20.
Previous Pregnancies.- 1st = normal, F.T., alive: 2nd = normal, F.T., alive: 3rd and 4th = Premature, stillborn (3rd at 6½ months and 4th at 8¼ months on 10-11-19.)

26-7-21 - Visited. Patient complaining of headache and weakness - now 8½ months pregnant
Child - Male - born at home 6-10-21, F.T., weight 5 lbs. 14 ozs. - G.R.M.N. nurses in attendance.
26-10-21 - Visited. Child has rash on hands and feet: visited again 2-11-21 rash cleared up but face and lips broken out.
Child died 8-11-21.

605. W.R. Mother = Negative (3-5-). 26-11-20.

4th Pregnancy. Married. Age 32.
L.P. early June, 1920.
Admitted 19-11-20 - complaining of constant pain in back for some time. Bleeding began 18-11-20 and continued all night: foetus expelled early on 19-11-20 - still some slight bleeding on admission - uterus almost up to umbilicus - explored and cleared out. Placenta very dirty and foul smelling. Patient a healthy woman.
Previous Pregnancies.- 1st = 7 months, still-born (1912): 2nd = 6 months, still-born: 3rd = 3 months' miscarriage (curetted) Feby., 1917.

606. W.R. Mother = Negative (3-5-). 26-11-20.
Child = Negative (3-5-). 26-11-20.

3rd Pregnancy. Married. Age 22.
L.P. 15-2-20.
Patient was well throughout pregnancy till pains began 4 days before admission - not severe.
Admitted 18-11-20 - slightly contracted pelvis (Diag. Conj. = 5" ?, True Conj. = 4¼" +).
Child born 19-11-20 (normal labour - Ruptured Perineum) Male, weight 8¼ lbs.
Dismissed 27-11-20, weight 7½ lbs.
Child was known to be alive and well at the age of 15 months - never any illness.
Previous Pregnancies.- 1st and 2nd = Chloroform and Forceps: 1st = alive: 2nd = stillborn (Novr., 1919). Mother had Chorea in 1911 and 1915. Healthy woman.

Case No.

607. W.R. Mother = Negative (3-5-). 26-11-20.
Child = Negative (3-5-). 26-11-20.

2nd Pregnancy. Single. Age 23.
L.P. Feby., 1920.
Normal pregnancy.
Child born 18-11-20, male, weight 7½ lbs.
Dismissed 27-11-20, weight 7¾ lbs.
Child was knwon to be alive and well when at the age of 15 months.
1st Pregnancy = normal, full-time, alive - February, 1918.

608. W.R. Mother = Negative (3-5-). 26-11-20.
Child = Negative (3-5-). 26-11-20.

1st Pregnancy. Single. Age 17.
L.P. Feby., 1920.
Normal labour - lasted 36 hours.
Child born 18-11-20, Female, weight 6 lbs.
Dismissed 27-11-20, weight 6½ lbs.
Child was known to be alive and well when at the age of 15 months - has had Whooping-cough, measles and Chicken-pox but has never been very ill. Baby very small but healthy. Mother not very robust.

609. W.R. Mother = Strongly Positive (3+5+). 26-11-20
Child = Negative (3-5-). 26-11-20

1st Pregnancy. Married. Age 28.
L.P. Feby., 1920.
Normal pregnancy.
Slightly contracted pelvic outlet: delayed 2nd stage: Forceps - Child born 21-11-20, Male, weight 6¼ lbs.
Mother has no albuminuria. Had Pneumonia 12 years ago.
Dismissed 30-11-20, weight 6½ lbs.
Child had operation for Hernia in R.H.S.C. about March, 1920.
Both mother and child attended Disp. when child 15 months old - both seemed well.

W.R. Mother = Negative (3-5-). 4-2-22.
Child = Negative (3-5-). 4-2-22.

Case No.

610. W.R. Mother = Negative (3-5-). 26-11-20.

7th Pregnancy. Married. Age 28.
L.P. 6-4-20.
Admitted 20-11-20 - Marginal Placenta Praevia. Patient was well till bleeding began on 19th Novr., 1920 - continued - bleeding on admission - os admitting 3 fingers: membranes not ruptured - placenta felt on left. Membranes ruptured: vagina packed - spontaneous delivery Twins born 21-11-20 - still-born (1) Male, vertex, weight 4½ lbs. (2) Female, Breech, weight 4¼ lbs. Both still-born.

Previous Pregnancies.- 1st - 6th = Full-time, normal, alive (last in July, 1919).

611. W.R. Mother = Negative (3-5-). 26-11-20.

2nd Pregnancy. Married. Age 28.
L.P. March, 1920.
Patient was well throughout pregnancy.
Delivered instrumentally on 19-11-20.
Admitted 20-11-20 - slight oedema of feet and ankles and of face. Patient was very pale - complained of headache (noticed oedema for past two months). Slight puerperal eclampsia - stated to have had two fits within 12 hours of delivery.
Dismissed 9-12-20.
No trace after dismissal.
Previous Pregnancy was a two months' abortion (Octr., 1919). Had "Neurasthenia" 7 years ago.

612. W.R. Mother = Negative (3-5-). 1-12-20.
Child = Negative (3-5-). 26-11-20.

1st Pregnancy. Married. Age 34.
L.P. 27-2-20.
Patient was very well during pregnancy, but noticed swelling of feet for last three weeks: no headaches: Albuminuria and oedema of legs on admission: Normal labour: Child born 21-11-20 Female, weight 7¾ lbs. Died 30-11-20.

Case No.

613. W.R. Mother = Negative (3-5-). 1-12-20.
Child = Negative (3-5-). 26-11-20.

1st Pregnancy. Married. Age 30.
L.P. Feby., 1920.
Normal pregnancy and labour.
Child born 21-11-20, male, weight 8½ lbs., alive
Mother has slight premenstrual pain (Reg. 7/21.)
Child was known to be alive and well when 15 months old: never any illness.

614. W.R. Mother = Negative (3-5-). 26-11-20.
Child = Negative (3-5-). 26-11-20.

2nd Pregnancy. Married. Age 25.
L.P. 27-2-20.
Eclampsia. Patient was quite well during pregnancy - no headaches: no epigastric pain: noticed some swelling of legs 14 days before delivery.
Admitted 21-11-20 - cyanosed: unconscious: oedema of legs: (Ricketty deformity of legs) high tension pulse: slight bronchitis: Urine - albumen = 7 Esbach.
Forceps delivery - child had to be resuscitated - born alive, male, weight 7½ lbs.
Mother was dismissed 24-12-20. Child died 3-12-20.

Previous Pregnancy = full-time, living - Mother had Albuminuria but no fits(1917).

615. W.R. Mother = Negative (3-5-). 26-11-20.

4th Pregnancy. Single. Age 26.
L.P. early in May, 1920.
Patient was admitted to Ante-natal Dept. 19-11-20 complaining of acute epigastric pain and difficulty in passing urine. For a week before admission had headache, sickness and pain in left side. On admission - oedema of legs and labia: tongue dirty and furred: no abdominal tenderness: Slight albuminuria.
Dismissed 4-12-20 and re-admitted 30-1-21 -
Child born 30-1-21, male, weight 7½ lbs.
Dismissed 10-2-21, weight 7¼ lbs.
Mother gives history of occasional fits (" always after having bad news" - considered to be hysterical).
Child died 20-5-21 of Chronic Bronchitis.

Previous Pregnancies.- 1st = F.T., normal, living: 2nd = Normal, F.T., living - died after 24 hours: 3rd = Normal, F.T., living.

616. W.R. Mother = Negative (3-5-). 26-11-20.

2nd Preg. Married. Age 20.
L.P. 30-3-20.
Cardiac. For month before admission to hospital patient had been very breathless: cough: swelling of limbs and face: had brought up blood three times. Admitted 19-11-20 - pale, puffy face: lips cyanosed: orthopnoea: bad attacks of coughing: presystolic and systolic mitral murmur: marked thrill: heart dilated: slight murmur at triscuspid: albumen ++. Oedema of bases of both lungs: bronchitis: haemoptosis on 20-11-20: marked oedema of labia (punctured). Slight improvement for a few days after admission. Labour began 12-12-20 - Forceps - R.P. - Child born 12-12-20 - female, weight 6 lbs. Mother died 16-12-20 - had a history of epilepsy for which she was treated in Glasgow Royal Infirmary in May, 1920. Had diphtheria as a child. Child died on 2-1-21.

1st Preg. = abortion at three months (March, 1920).

617. W.R. Mother = Negative (3-5-). 26-11-20.

2nd Preg. Married. Age 26.
L.P. end of Jany., 1920.
Normal pregnancy and labour. Child born 14-11-20 - female, weight 7¼ lbs.
Mother and child dismissed 23-11-20 -child's weight = 7 lbs.
No trace after dismissal.

1st Preg. = normal - 12 days premature on account of fright. Patient a healthy woman.

618. W. R. Mother = Negative (3-5-). 26-11-20.

2nd Preg. Married. Age 22.
L.P. Feby., 1920.
Normal pregnancy. Flat pelvis - post. parietal presentation converted to ant. parietal. Forceps - child born 17-11-20 (40 hours labour) Female, weight 6 lbs.
Dismissed 26-11-20, weight 6 lbs.
18-11-21 - Both mother and child well - child now one year old.

1st Preg. = Ch.clz. & Forceps, F.T., alive - protracted labour (27-11-19).

Case No.

619. W. R. Mother = Negative (3-5-). 26-11-20.
Child = Negative (3-5-). 26-11-20.

1st Pregnancy. Married. Age 23.
L.P. 16-4-20.
Patient was well till four weeks before admission when she had bronchitis and noticed swelling of feet and ankles. Swelling of face for two weeks. Admitted 20-11-20 - healthy colour, marked oedema of feet, ankles and vulva: slight oedema of face - bronchitis present. Irregular labour pains. Albuminuria. Premature labour - R.P. Child born 20-11-20, female, weight 4¾ lbs. - died 27-11-20.
Mother had anaemia a few years ago and acute rheumatics three years ago.

620. W.R. Mother = Negative (3-5-). 26-11-20.

2nd Pregnancy. Married. Age 28.
L.P. 10-2-20.
Admitted to Antenatal Dept. 19-11-20 - Contracted Pelvis (Diag. Conj. 4¼"-: True = 3½"-). Induction (bougies) - Child born dead 25-11-20 - female, weight 6½ lbs. Forceps: cervical tear. Tibial curves: otherwise healthy: small woman.
1st Pregnancy = F.T., S.B. Chloroform and Forceps (June, 1919).

621. W.R. Mother = Negative (3-5-). 1-12-20.
Child = Negative (3-5-).26-11-20.

1st Preg. Married. Age 34.
L.P. 18-2-20.
Frequent micturition: swelling of legs for some time: otherwise well. Admitted 21-11-20 - labour in progress. Eclamptic fit when head reached perineum. Forceps delivery - R.P. Child born 22-11-20, male, weight 8½ lbs. Dismissed 10-12-20, weight 8 lbs. Healthy looking woman - oedema of legs (?urine).
10-11-20. Both mother and child well - Child now one year old.

Case No.

622. W.R. Mother = Negative (3-5-). 1-12-20.
Child = Negative (3-5-).26-11-20.

1st Preg. Single. Age 27.
L.P. Feby., 1920.
Normal pregnancy and labour. Child born 22-11-20 - male, weight 6½ lbs. Dismissed 1-12-20, weight 7½ lbs.
21-2-22 - Mother and baby known to be alive and well - child now 14 months old.

623. W.R. Mother = Negative (3-5-). 26-11-20.
Child = Negative (3-5-). 30-12-20.

1st Preg. Single. Age 25.
L.P. 15-3-20.
Admitted 16-11-20 - mastitis - incised. Dismissed 10-12-20. Readmitted 29-12-20 - child born 29-12-20, alive. Dismissed 10-1-21. Mother and child both healthy. 9-3-22 - Child alive - never any illness.

624. W.R. Mother = Negative (3-5-). 26-11-20.

3rd Preg. Married. Age 26.
L. P. 28-8-20.
Admitted 18-11-20 - Patient a thin pale woman. Incomplete Abortion - bleeding began three weeks before admission and continued for three days severely then slightly for one week. Began again three days before admission with sudden gush of dark blood and clots and continued till admission on 18-11-20. Placental debris protruding from os - curetted and swabbed. Dismissed 26-11-20.

Prev. Pregs.- 1st and 2nd = F.T., normal, alive (last in Aug., 1919). Has premenstrual pain (3/26).

625. W.R. Mother = Negative (3++5+). 26-11-20.

2nd Preg. Married. Age 27.
L.P. 23-8-20.
Hyperemesis gravidarum. Morning sickness began at six weeks and has continued lately growing worse. Vomited everything during last five weeks: losing weight. Admitted to Antenatal Dept. from Disp 16-11-20 - hollow-eyed- tending to emaciation: uterus about size of ten weeks pregnancy - no displacement. Dismissed 2-12-20.
1st pregnancy was normal, F.T., alive(Nov.1917).

Case No.

626. W.R. Mother = Negative (3-5-). 26-11-20.

2nd Pregnancy. Married. Age 30.
L.P. 27-2-20.
Phlebitis of L. Saphenous vein with Albuminuria. Admitted to Antenatal Dept. 18-11-20 - has had headaches and a 'tight feeling about the eyes' and occasional swelling of feet for over three months. Has noticed swelling at lower end left thigh for two months. Dismissed undelivered 18-12-20.
1st Pregnancy = protracted labour - Chloroform and forceps (April, 1919).

627. W.R. Mother = Strongly Positive (3+5+).26-11-20.

2nd Pregnancy. Married. Age 37.
L.P. Feby., 1920.
Patient felt very well throughout pregnancy. Admitted to Antenatal Dept. 20-11-20 - Contracted Pelvis. Small and rather anaemic. Caesarean Section (sterilised) 2-12-20 - male, weight 7¾ lbs. Dismissed 28-12-20, weight 7½ lbs. Attending Dispensary after dismissal - getting "A" mixture. Baby breast fed and getting on well - never any illness. Baby 13 months old.

W.R. Mother = Str. Pos. (3+5+). 14-1-22.
Child = Negative (3-5-). 14-1-22.

628. W.R. Mother= Negative (3-5-). 26-11-20.

1st Pregnancy. Single. Age 20.
L.P. Feby., 1920.
Patient was well throughout pregnancy. Child born 25-11-20 - male, stillborn, weight 7¼ lbs. Duration of labour indefinite. Mother became acutely maniacal for several hours before delivery and made efforts at escape and self destruction. (Morphia grs. ½ given). Became quiet after delivery.

629. W.R. Mother = Negative (3-5-). 1-12-20.
Child = Negative (3-5-). 26-11-20.

1st Preg. Married. Age 18.
L.P. 1-3-20. Vomiting throughout pregnancy: Attended Antenatal Disp.- vomiting improved but persistent at times. Normal labour - child born 22-11-20 - Female, weight 6¼ lbs. (? mature) alive. Mother healthy. Dismissed 1-12-20. No trace after dismissal.

Case No.

630. W.R. Mother = Negative (3-5-).1-12-20.
Child = Negative (3-5-).26-11-20.

2nd Preg. Married. Age 21.
L.P. Feby., 1920.
Normal pregnancy and labour. Child alive before delivery but dead when born: head well but not excessively moulded. P.M.378.
1st Preg. = miscarriage at three months.

631. W.R. Mother = Negative (3-5-). 1-12-20.
Child = Negative (3-5-). 1-12-20.

6th Pregnancy. Married. Age 34.
L.P. Feby., 1920. Pains in back but well otherwise. Normal labour - child born 23-11-20 - male, weight 7¾ lbs. Dismissed 2-12-20. 18-11-21 - Both mother and child well - child now one year old.

Previous pregnancies all normal, full-time, living (last in 1917). Dysmenorrhoea.

632. W.R. Mother = Negative (3-5-). 1-12-20.
Child = Negative (3-5-).26-11-20.

5th Pregnancy. Married. Age 26.
L.P. Feby., 1920. Normal pregnancy and labour-child born 22-11-20 - male, weight 7¾ lbs., alive. Dismissed 2-12-20.
18-11-21 - Both mother and child well - child now one year old.

Previous Pregs.- 1st = 7/12 living - normal labour: 2nd = F.T., Ch.clz. & Forceps: 3rd = F.T., living, normal: 4th = F.T., normal, living (Novr., 1919).

633. W.R. Mother = Negative (3-5-). 1-12-20.
Child = Negative (3-5-).26-11-20.

1st Preg. Married. Age 21.
L.P. Feby., 1920. Vomiting every day - very severe during first 2-3 months - continued (less severe) till delivery. Looks a healthy woman (? urine). Normal labour - child born 22-11-20, Female, weight 7¾ lbs. Dismissed 2-12-20, weight 7¼ lbs. Mother had vaginal lacerations. 22-5-22. - Mother and child both well. W.R. Mother = Negative
W.R. Child = Negative.
Child has a cough since whooping-cough in March, 1921.

Case No.

634. W.R. Mother = Negative (3-5-). 3-12-20.
Child = Negative (3-5-).26-11-20.

1st Preg. Married. Age 25.
L.P. early Feby., 1920. Patient was very sick throughout pregnancy. Child born alive 24-11-20 (33 hours labour) - male, weight 7 lbs. Slightly adherent placenta: ragged membranes: R.P. : Febrile puerperium. Dismissed 12-12-20. Baby died - Bronchitis- when two months old.

635. W.R. Mother = Negative (3-5-). 1-12-20.

8th Pregnancy. Married. Age 36.
? L.P. History of premature birth and still-birth. Attended Antenatal Disp. 26-11-20 - for past four months had menstruated for one day only each period. Bleeding since 19-11-20. Admitted 29-11-20. Child born alive 1-12-20 - Female, weight 2 lbs. Died shortly after birth.
Prev. Pregs.- 1st = S.B., F.T., Normal: 2nd = F.T., alive (instrs.): 3rd = F.T., S.B., (instrs.):
4th & 5th = F.T., N., alive: 6th = 7/12 - lived 18 hours: 7th = F.T., normal, alive (March, 1919).

636. W.R. Mother = Negative (3-5-). 1-12-20.

2nd Preg. Married. Age 24.
L.P. 8-4-20. Attended Antenatal Disp. 26-11-20 - Contracted Pelvis (Diag. Conj. = 3½" +, True Conj. = 2¾" +). Rickets. Admitted to Hosp. 28-1-21 - Caesarean Section 29-121 - Female born, weight 6½ lbs. Mother not sterilised. Dismissed 24-2-21, weight 6½ lbs. On 25-5-22 both mother and child attended disp. - Mother has irregular menstruation and dysmenorrhoea - child well. -
W.R. Mother = Strongly Positive (3+5+)25-5-22.
Child = Strongly Positive (3+5+)25-5-22.

Case No.

637. W.R. Mother = Negative (3-5-). 1-12-20.

6th Preg. Married. Age 30.
L.P. ? Aug., 1920. Attended Antenatal Disp. 26-11-20 - bleeding four weeks before, lasting five days - thinks she is three months pregnant. Seen again 18-3-21 - probably missed abortion.
Prev. Pregs.- 1st - 5th = normal, alive (last in June, 1918).

638. W.R. Mother = Negative (3-5-). 1-12-20.

2nd Preg. Married. Age 25.
L.P. 16-8-20. Attended Antenatal Disp. 26-11-20 - Threatened Miscarriage. Bleeding at intervals since Septr., 1920, continuous for past seven days - abdominal pain.
1st Pregnancy = F.T., normal, alive, (Sept., 1919).

639. W.R. Mother = Negative (3-5-). 1-12-20.

7th Preg. Married. Age 35.
L.P. 15-8-20. Attended Antenatal Disp. 26-11-20 - Threatened Abortion. Admitted to hosp. 4-5-21, normal labour, child born 4-5-21, Female, weight 6½ lbs. Dismissed 12-5-21, weight 6½ lbs. 25-2-22 - Child alive (now nine months old) - just recovering from Pneumonia: has chronic catarrh.
Prev. Pregs.- 1st - 4th = F.T., normal, alive: 5th = S.B.(during influenza): 6th = miscarriage at 4½ months (May, 1920).

640. W.R. Mother = Negative (3-5-). 1-12-20.

3rd Preg. Married. Age 43.
L.P. 15-7-20. Was well throughout until 20-11-20 when bleeding began at 6-30 a.m. and continued (without pain) till admission on 24-11-20. Incomplete Abortion - pale but not blanched: placental tissue palpable at cervix - digital curettage and douche.
Prev. Pregs.- 1st = F.T., Breech, S.B.(CH.Clz.): 2nd = 8/12, normal alive (21-10-17).

Case No.

641. W.R. Mother = Negative (3-5-). 1-12-20.
Child = Negative (3-5-). 1-12-20.

1st Preg. Married. Age 18.
L.P. Feby., 1920. Well throughout. Normal labour - child born alive 25-11-20 - Female, weight 7 lbs. Dismissed 4-12-20, weight 7 lbs. 23-2-22 - Child now 15 months old and in good health.

642. W.R. Mother = Negative (3-5-). 1-12-20.

3rd Preg. Married. Age 27.
L.P. Feby., 1920. Pregnancy normal throughout. Failed Forceps outside with R.P.: Admitted 24-11-20 - exhausted: Pelvis - Diag. Conj. = 4½" : True Conj. = 3¾" - head well into pelvis: fracture of left fronto-parietal region: os not fully dilated. Os dilated manually (child dead). Forceps delivery of stillborn child - Female, weight 8 lbs. Labour lasted about 24 hours. P.M. 380.
Prev. Pregs.- 1st = F.T., S.B., CH.clz. & Forceps: 2nd = F.T., living, CH.clz. & forceps (1916). Mother has slight bronchitis: occasional dysmenorrhoea.

643. W.R. Mother = Negative (3-5-). 1-12-20.

9th Preg. Married. Age 41.
L.P. 1st Sept., 1920. Admitted 24-11-20. Pain on defoecation for one week. Bleeding began early on 24-11-20 - severe and continuous. Bleeding freely on admission at 3-20 p.m. - os admitting two fingers - placental tissue felt. Incomplete abortion: Digital curettage.
Prev. Pregs.- 1st = F.T., normal, living: 2nd = 6/12, lived six weeks: 3rd = F.T., normal, alive: 4th, 5th, 6th & 8th = F.T., normal, alive: 7th = miscarriage at 3/12 (1915). Last child born 27-11-18. Menstruation irregular since last pregnancy. Dysmenorrhoea.

Case No.

644. W. R. Mother = Negative (3-5-). 1-12-20.

9th Preg. Married. Age 30.
L.P. March, 1920. Placenta Praevia (Marginal) - Has felt tired throughout pregnancy but nothing definite till onset of bleeding at 4 a.m. 24-11-20 - not severe. Packed and sent in to hospital 24-11-20 - uterus about 8 months size: marginal placenta praevia: - version: foot brought down - spontaneous delivery - child stillborn - male, weight 7 lbs. (? mature). P.M. 379.

1st Preg. = F.T., normal, living, R.P.: 2nd = 6th = F.T., normal, living: 7th = 8 months, living, A.P.H. - lived 12 hours: 8th = F.T., living, slight A.P.H., normal labour (7-4-18).

645. W.R. Mother = Negative (3-5-). 1-12-20.

3rd Preg. Married. Age 26.
L.P. Jany., 1920. Pain in back and legs throughout pregnancy. Contracted Pelvis (Diag. Conj. = 4" , True Conj. = 3¼"): Os failed to dilate fully: head did not come down: slight overlapping: os dilated manually: Craniotomy 23-11-20. P.M. 381.
Prev. Pregs.- 1st = F.T., S.B.: 2nd = F.T., living (Jany., 1917): Mother had a uterine haemorrhage (cause unknown - Sept., 1919). Small stumpy woman - rickets.

646. W.R. Mother = Negative (3-5-). 1-12-20.
Child = Negative (3-5-). 1-12-20.

1st Pregnancy. Married. Age 21.
L.P. 15-3-20. Swelling of feet noticed 14 days before admission, headache for first time day before admission: no vomiting: well otherwise. Admitted Antenatal Dept. 22-11-20- Albuminuria +++, marked oedema of face, legs and abdomen: slight bronchitis. Child born 24-11-20 (normal labour) R.P. Child born alive but died 9-12-20, mother dismissed 9-12-20.
Patient first menstruated July, 1919 - regular from them till 15-3-20.

Case No.

647. W.R. Mother = Negative (3-5-). 1-12-20.
Child = Negative (3-5-). 1-12-20.

3rd Preg. Married. Age 24.
L.P. early March, 1920, normal pregnancy and labour. Child born 24-11-20 - male, weight 7½ lbs. Dismissed 4-12-20, weight 6½ lbs. No further trace of mother and child.
Prev. Pregs.- 1st & 2nd = F.T., living, normal.

648. W.R. Mother = Negative (3-5-). 1-12-20.

1st Preg. Married. Age 27.
L.P. April, 1920. Patient was well till 24-11-20 when she suddenly collapsed - had no headaches previously but had noticed swelling of hands for a few days. B.B.A., S.B. (24-11-20) admitted in coma - Eclampsia: R.P. Stomach lavage, etc.: had several fits after admission: Bronchitis (? urine). Mother dismissed 23-12-20.

649. W.R. Mother = Negative (3-5-). 1-12-20.

2nd Preg. Married. Age 34.
L.P. early in March, 1920. Admitted to Antenatal Dept. 24-11-20 - Contracted Pelvis (Diag. Conj. =4¼" -: True Conj. = 3½" -). Small woman but no special deformity. Caesarean Section (sterilised) - child born 26-11-20 - Female, weight 6 lbs. (? premature) Child did not thrive: feet and legs very oedematous: oedema later improved but general condition grew worse and child died 15-12-20. P.M. 409.
1st Preg. = F.T., S.B., CH.clz. & forceps (16-10-13). Scanty menstrual flow (10/28) no dysmenorrhoea.

650. W.R. Mother = Negative (3-5-). 8-12-20.
Child = Negative (3-5-). 1-12-20.

1st Preg. Married. Age 21.
L.P. Feby., 1920. Well throughout pregnancy-slight pains before onset of severe labour pains. Child born 26-11-20 - Female, weight 8 lbs. Dismissed 8-12-20, weight 8 lbs.
Mother had Pneumonia in 1919 - otherwise healthy.
Mother and child known to be alive and well at 22-2-22 - child then 15 months old.

Case No.

651. W.R. Mother = Negative (3-5-). 1-12-20.
Child = Negative (3-5-). 1-12-20.

2nd Preg. Married. Age 20.
L.P. Jany., 1920. Normal pregnancy and labour - child born alive 26-11-20, female, weight 8 lbs. Dismissed 6-12-20.
22-2-22 - Child alive and well - 15 months old - no illness.
Prev. Preg.- F.T., living, normal (Novr., 1919).

652. W.R. Mother = Negative (3-5-). 1-12-20.

2nd Preg. Married. Age 30.
L.P. ? - Uterus about six months size. Normal until admission (21-11-20) when severe bleeding commenced - no further bleeding after admission. Albuminuria: Ante-partum Haemorrhage. Delivered of a macerated foetus 21-11-20. Retained placenta removed manually. Curetted.
Prev. Preg.- Miscarriage at five months (1919).

653. W.R. Mother = Negative (3-5-). 1-12-20.

6th Preg. Married. ? age.
L.P. 28-4-20. Patient was well till bleeding began on 23-10-20 and continued intermittently till admitted on 22-11-20. Incomplete Abortion: Uterus cleared out - very foul smelling placental tissue removed. Douched and swabbed. (About 4½ months abortion).
Prev. Pregs.- 1st = F.T., living, normal: 2nd = F.T., living, normal: 3rd = F.T., living, Chlor. & forceps: 4th = normal, F.T., living: 5th = normal, F.T., living (1918).

654. W.R. Mother = Negative (3-5-). 1-12-20.
Child = Negative (3-5-). 1-12-20.

8th Preg. Married. Age 32.
L.P. 15-2-19. Patient was anaemic throughout pregnancy. Very severe vomiting during first month but well otherwise. Contracted pelvis: normal labour - child born alive 27-11-20, female, weight 10 lbs. Dismissed 6-12-20, weight 9½ lbs.
18-11-21 - Both mother and child well - child now one year old.
Prev. Pregs.- 1st = premature, living, Chlor. & forceps: 2nd = F.T., living, Chlor. & forceps: 3rd, 4th and 5th = normal, F.T., living (15-2-19): 6th and 7th = miscarriages (6 weeks). Rheumatic fever 12 years ago. Eclampsia with first preg.: Alexander-Adam's operation in Jany., 1920.

Case No.

655. W.R. Mother = Negative (3-5-). 3-12-20.
Child = Negative (3-5-). 1-12-20.

6th Preg. Married. Age 34.
L.P. Feby., 1920. Patient was well throughout pregnancy till day before admission when she had nine eclamptic fits in 12 hours. Eclampsia. One fit just after admission on 25-11-20 - child born 25-11-20, male, weight 6 lbs. Child died 7-12-20. Mother was pale: no oedema.
Prev. Pregs. were all normal, F.T., alive.

656. W.R. Mother = Negative (3-5-). 1-12-20.

2nd Preg. Married. Age 25.
L.P. end of March, 1920. Patient felt very sick and ill at times but no vomiting: well otherwise: No life felt since August. Macerated foetus born 24-11-20, Female, weight 2 lbs. Placenta complete and not retained. P.M. 384.
1st Preg. = F.T., living, normal (1-7-10).

657. W.R. Mother = Strong. Pos. (3+5+).3-12-20.
Child = Strongly Pos. (3+5+). 1-12-20.

5th Preg. Single. Age 29.
L.P.15-2-20. Well throughout pregnancy. Normal labour - child born 27-11-20, male, weight 8½ lbs. Dismissed 6-12-20. Child died in Lock Hospital 15-12-20.
Prev. Pregs.- 1st to 3rd = normal, F.T., alive - retained placenta with 2nd: 4th = miscarriage at 5 months (April, 1919) - said to be result of a fright. Mother healthy - thin and pale, but well-built.

658. W.R. Mother = Negative (3-5-). 3-12-20.
Child = Negative (3-5-). 1-12-20.

1st Preg. Married. Age 24.
L.P. 23-2-20. Normal pregnancy: 18 hours labour - delayed 2nd stage: Forceps - R.P. Pelvis not contracted - Child born 25-11-20, Female, weight 6 lbs. Dismissed 7-12-20. Mother has had muscular rheumatism for last year. 11-11-21 - Baby alive: no illness of any kind: now almost one year old.

Case No.

659. W.R. Mother = Negative (3-5-). 3-12-20.
Children = Negative (3-5-). 1-12-20.

1stPreg. Single. Age 20.
L.P. end March, 1920. Normal - premature (7/12) labour - twins born 25-11-20 (1) male, weight 3½ lbs. (2) male, weight 3 lbs. - both alive but died 28-11-20. P.M. 391 & P.M. 392.

660. W.R. Mother = Negative (3-5-). 1-12-20.

1st Preg. Single. Age 22.
L.P. 28-2-20. Patient was well throughout pregnancy. Normal delivery - child born alive, weight 6½ lbs., male, 25-11-20. Dismissed 3-12-20, weight 7 lbs. Child was known to be alive and well when 9 months old.

661. W.R. Mother = Negative (3-5-). 1-12-20.
Child = Negative (3-5-). 1-12-20.

19th Preg. Married. Age 36.
L.P. Feby., 1920. Well throughout pregnancy. Contracted Pelvis (Diag. conj.= 4¼"+, True Conj. = 3½" +): Outlet small. Occipito-posterior - after about twelve hours labour meconium coming away, but os only half dilated - 9 hours later os fully dilated, child rotated manually - forceps applied: Child born alive 27-11-20, male, weight 7¼ lbs. Placenta removed by hand introduced: R.P. Dismissed 11-12-20, weight 8 lbs. 22-2-22 - Child alive and well (now 15 months): Had Influenza and Bronchial Catarrh.
Prev. Pregs.- 1st = F.T., S.B., CH.clz. & Forceps: 2nd = F.T., living, CH.clz. & forceps: 5th = S.B., CH.clz. & forceps. Two miscarriages before any F.T. children: one miscarriage after 2nd child: one miscarriage after 5th child. Small woman - rickets.

662. W.R. Mother = Negative (3-5-). 1-12-20.

1st Preg. Married. Age 25.
L.P. Feby., 1920. Normal pregnancy: delayed 2nd stage: Forceps, R.P. Child born alive 22-11-20, male, weight 7¾ lbs. Dismissed 3-12-20. Mother healthy: child had ophthalmia.
No further trace after dismissal.

Case No.

663. W.R. Mother = Negative (3-5-). 1-12-20.

9th Preg. Married. Age 37.
L.P. Feby., 1920. Normal pregnancy. Child born 22-11-20 (Footling), male, weight 9½ lbs., alive. Dismissed 2-12-20. 6-4-22 - Mother and child both well (child now 16 months old)-
W.R. Mother = Negative (3-5-). 6-4-22.
Child = Negative (3-5-). 6-4-22.
Prev. Pregs.- 1st, 2nd & 3rd = F.T., normal, living: 4th = S.B., CH.clz. ? Transverse: 5th = F.T., living, normal: 6th = F.T., S.B., normal: 7th and 8th = F.T., living, normal.

664. W.R. Mother = Negative (3-5-). 3-12-20.
Child = Negative (3-5-). 1-12-20.

1st Preg. Married. Age 22.
L.P. 14-3-20. Well throughout pregnancy: Contracted pelvis - Diag. Conj. = 4¼", True Conj. = 3½". Failed Forceps(outside): Craniotomy - child born 29-11-20, male, weight 8 lbs. P.M. 394.

665. W.R. Mother = Negative (3-5-). 1-12-20.
Child = Negative (3-5-). 3-12-20.

1st Pregnancy. Single. Age 23.
L.P. 26-2-20. Pain in legs but otherwise well throughout pregnancy. Child born alive 21-11-20, weight 7½ lbs. Mother had slight oedema of legs but no albuminuria: looks a healthy woman. Dismissed 1-12-20, weight 6¾ lbs. Child died 30-1-21 -'abscess on breast and debility'.

666. W.R. Mother = Negative (3-5-). 8-12-20.
Child = Negative (3-5-). 1-12-20.

1st Preg. Married. Age 25.
L.P. 15-2-20. Patient was well throughout but had slight discharge of blood in June, 1920 which did not continue. Normal (9 hours) labour - child born 28-11-20, male, weight 6¾ lbs. Dismissed 7-12-20, weight 7¼ lbs. 18-1-21 - both very well (Baby now one year).

Case No.

667. W.R. Mother = Negative (3-5-). 8-12-20.
Child = Negative (3-5-). 1-12-20.

1st Preg. Single. Age 20.
L.P. April, 1920. Vomited till two months before delivery but otherwise well. Child born 27-11-20, Female, weight 5¾ lbs. Dismissed 8-12-20, weight 4½ lbs. Child died 20-12-20 at R.H.S.C.

668. W.R. Mother = Negative (3-5-). 3-12-20.
Child = Negative (3-5-). 1-12-20.

1st Preg. Single. Age 18.
L.P. 30-1-20. Well throughout pregnancy: false labour pains four weeks before delivery - passed off. Spontaneous delivery after eight hours labour. Child born 28-11-20, Female, weight 6¼ lbs. Dismissed 7-12-20, weight 8 lbs. 10 ozs. 18-11-21- Mother well but baby has Diarrhoea - attdg. R.H.S.C.

669. W.R. Mother = Negative (3-5-). 3-12-20.
Child = Negative (3-5-). 1-12-20.

2nd Preg. Single. Age 31.
L.P. middle Feby., 1920. Sickness and 'heart-burn' throughout most of pregnancy - better before delivery. Child born 28-11-20 - female, weight 6½ lbs. (22 hours labour). Dismissed 6-12-20, weight 7 lbs. 25-2-22 - Attended G.R.M.H. Disp. - Mother operated on in Edinburgh Royal Infirmary for gastric ulcer and child has digestive troubles - vomits a lot and each attack is lengthy - the last one lasted two weeks. W.R. Child = Neg. 25-2-22.
1st preg. was normal, F.T., alive (Septr., 1914).

670. W.R. Mother = Negative (3-5-). 3-12-20.

4th Preg. Married. Age 25.
L.P. early Feby., 1920. Pregnancy was normal throughout unless for leucorrhoea: Prolapsed cord: Contracted Pelvis (Diag. Conj. = 4", True Conj. = 3¼"). Cord replaced: Forceps delivery - child born dead 26-11-20, male, weight 9½ lbs. Mother pale and exhausted - (over 24 hours labour).

Prev. Pregs.- 1st-3rd = normal, F.T., living.

Case No.

671. W.R. Mother = Negative (3-5-). 3-12-20.

2nd Preg. Married. Age 30.
L.P. 14-2-20. Admitted Antenatal Dept. 15-11-20 - Contracted Pelvis (Diag. Conj. =3½", True Conj. = 2¾"). Small rickety woman - Caesarean Section (sterilised) - Child born 16-11-20, Female, weight 8 lbs. 2 oz. - died aged 14 days with clinical signs of congenital syphilis (W.R. not done).
1st Preg. = Caesarean Section, live child, (Novr., 1919).

672. W.R. Mother = Negative (3-5-). 3-12-20.

4th Preg. Married. Age 26.
L.P. 23-5-20. Was well throughout pregnancy till tramcar accident 14 days before admission to hospital - did not feel well from that time. Attended Ante-natal Disp. and was admitted to Antenatal Dept. 25-11-20 - Albuminuria: Slight oedema of ankles and face (albumin =0.07%) dismissed after four weeks - persistent trace of albumin (0.03-0.04%). Diet to be continued at home. Readmitted 30-12-20 - albumin too abundant to be estimated. Anti-eclamptic treatment began at 1 a.m. 3-1-21 but coma developed and patient died from sudden cardiac failure at 2-15 a.m. 3-1-21.
Prev. Pregs.- 1st = S.B., F.T., eclampsia: 2nd = six months abortion - eclampsia (1916): 3rd = F.T., alive (eclampsia). Child died later (March, 1918).

673. W.R. Mother = Negative (3-5-). 3-12-20.

10th Preg. Married. Age 39.
Admitted to Antenatal Dept. 30-11-20: Dismissed 2-12-20.

674. W.R. Mother = Negative (3-5-). 3-12-20.

7th Preg. Married. Age 28.
L.P. July, 1920. Bleeding for some time before admission to Antenatal Dept. - Threatened Miscarriage. Left against advice on 2-12-20.

Prev. Pregs.- 1st = S.B., 2nd = S.B. (8 months): 3rd, 4th, 5th and 6th = normal, F.T.

Case No.

675. W.R. Mother = Negative (3∓5∓). 3-12-20.

11th Preg. Married. Age 44.
L.P. 19-4-20. Patient was well till two months pregnant when she had a slight haemorrhage: nothing further abnormal till some haemorrhage 12 hours before admission. Admitted 30-11-20 - Placenta Praevia (? central). Spontaneous delivery - packed - Child born dead 1-12-20, male, weight 4½ lbs. premature. Child was alive till onset of labour.
Prev. Pregs.- All normal except 9th (Ch.clz. & Forceps) and 7th (S.B. at 7 months. Last child born 1915. One miscarriage at two months in 1916. P.M. 393.

676. W.R. Mother = Negative (3-5-). 3-12-20.

9th Pregnancy. Married. Age 37.
L.P. July, 1920. Bleeding began 28-11-20 but stopped same day: came on again severely morning of admission (29-11-20) accompanied by pain. Incomplete Abortion - curetted before admission (District) - collapsed - Sent in. Dismissed 4-12-20.
Prev. Pregs.- 1st - 8th = F.T., living, normal (last 8-1-19). Occasional Dysmenorrhoea.

677. W.R. Mother = Negative (3-5-). 3-12-20.

2nd Preg. Married. Age 24.
L.P. early July, 1920. Patient was well till 29-11-20 when felt faint and had pain but no haemorrhage - Threatened Abortion - uterus 4 - 4½ months size. Dismissed 1-12-20.
1st Preg. = F.T., living, normal.

678. W.R. Mother = Negative (3-5-). 3-12-20.
Child = Negative (3-5-). 3-12-20.

1st Preg. Married. Age 34.
L.P. ? March, 1920. Normal pregnancy. Admitted to Antenatal Dept. 30-11-20. Readmitted 2-12-20- Child born 3-12-20, Female, weight 6½ lbs. mature. Mother healthy. Dismissed 11-12-20, weight 5¾ lbs. 6-4-22 - Mother and child both well (Baby now 16 months).

Case No.

679. W.R. Mother = Strongly Positive (3+5+)3-12-20.

2nd Preg. Married. Age 27.
L.P. 14-7-20. Patient was well till first week October when bleeding began and continued intermittently till admission on 30-11-20. Pain, and passage of clots (large) three nights before admission. Has noticed marked enlargement of uterus - Hydatiform mole: exploration and curettage.
Prev. Preg.- 1st = Normal, living, Septr., 1919. Menstrual cycle 7-10/28 - Some sickness and pain in the back. Influenza 1917, otherwise healthy: Slightly built: some anaemia.

680. W.R. Mother = Negative (3-5-). 3-12-20.

2nd Preg. Married. Age 27.
L.P. 15-7-20. Patient was well for first month of pregnancy then bleeding began and lasted four weeks then ceased and appeared again on two occasions - began again a few hours before admission. Admitted to Antenatal Dept. 28-11-20 - Inevitable Abortion (complete). Spare woman, healthy colour: no albuminuria. Dismissed 8-12-20.
1st Pregnancy = normal: long labour but no forceps (May, 1916).

681. W.R. Mother = Negative (3-5-). 3-12-20.

12th Preg. Married. Age 40.
L.P. ? 30-3-21 (possibly earlier). Patient was well till Auguat, 1920 when miscarriage threatened and bleeding began. In September similar threatening with bleeding: Well till onset of labour nearly 14 days before delivery - pain latterly very severe. Admitted 28-11-20 - Transverse presentation - version to footling - Child born dead 28-11-20, male, mature, weight 7¼ lbs. Pelvis (Diag. Conj. = 4½", True Conj. = 3¾").
Prev. Pregs.- 3rd and 9th = S.B., F.T., Breech - all others born alive F.T., three since dead. Last born Octr., 1918. One miscarriage at two months in 1919. P.M. 397.

Case No.

682. W.R. Mother = Negative (3-5-). 3-12-20.

5th Preg. Married. Age 33.
L.P. end May, 1920. Loss of appetite and frequent vomiting. Haemorrhage began suddenly 8 hours before admission on 28-4-20. Marginal Placenta Praevia - packed - version to footling after admission. Premature (6 months) child born 28-11-20 alive but breathed for two hours only (weight 2¼ lbs.) Placenta removed by hand introduced.
Prev. Pregs.- 1st - 3rd = F.T., normal, alive: 4th = premature, S.B., June, 1918.

683. W.R. Mother = Negative (3-5-). 3-12-20.

2nd Preg. Married. Age 33.
L.P. 17-5-20. Patient was well till day before admission then noticed swelling of feet. Admitted 28-11-20 after a "fainting turn" - Antepartum Eclampsia. Severe fit just after admission and two fits just before admission. Marked oedema of feet and ankles - sick and vomiting: Uric acid alb. 1 grain per oz. Eclamptic treatment - albumin negative by 10-12-20. Dismissed 15-12-20 (undelivered).
1st Preg. = normal, F.T. alive (March 1914). Had Scarlet Fever in childhood: Appears healthy.

684. W.R. Mother = Negative (3-5-). 3-12-20.

3rd Preg. Married. Age 23.
L.P. 15-9-20. Patient was well till 25-11-20 when bleeding began without pain - a few large clots were passed after which bleeding was slight but constant. Admitted 28-10-20 - Incomplete Abortion: curettage, swabbed.
1st and 2nd pregnancies were full-time, normal.

685. W.R. Mother = Negative (3-5-). 3-12-20.

3rd Preg. Married. Age 36.
L.P. 7-7-20. Patient was well till 23-10-20 when slight bleeding began - ceased for two days then began again. Admitted 27-11-20. Severe labour pains began a few hours after admission. Complete expulsion of ovum and placenta 28-11-20.
Prev. Pregs.- 1st and 2nd = normal, F.T., alive (1910). Oophorectomy 1916.

Case No.

686. W.R. Mother = Negative (3-5-). 3-12-20.

2nd Preg. Married. Age 26.
L.P. 2-3-20. Attending Antenatal Dispensary during last three months of pregnancy. Flat Pelvis (Diag. Conj. = 3¼", True Conj. = 2½"). Caesarean Section (sterilised) - Child born alive 12-12-20, Female, weight 8½ lbs. Dismissed 7-1-21, weight 9½ lbs. 21-3-22 - Mother and child both well - child now 14 months old.
Previous pregnancy = Protracted labour: transverse: decapitation (1915).

687. W.R. Mother = Negative (3-5-). 3-12-20.

3rd Preg. Married. Age 37.
? L.P. Admitted to Antenatal Dept. 29-11-20 - dazed - dry tongue, etc. Toxaemia. Uterus a little above umbilicus. Said to be seven months pregnant. Marked hydramnios present. Improved slightly on admission. Membranes were ruptured artificially - prolonged fit - remained in coma and died 1-12-20. Albumin ++. Pus +++. No casts: Streptocci and coliform b. in urine.
History of previous pregnancies not obtainable.

688. W.R. Mother = Negative (3-5-). 3-12-20.

1st Preg. Single. Age 28.
L.P. Feby., 1920. Failed forceps outside: R.P. Forceps delivery after admission 29-11-20 - Child, male, S.B. weight 9 lbs. Mother died 21-12-20. P.M.- Septic uterus- Metritis.

689. W.R. Mother = Negative (3-5-). 8-12-20.
Child = Negative (3-5-). 3-12-20.

1st Preg. Single. Age 19.
L.P. 15-3-20. Patient was well throughout pregnancy. Child born 2-12-20, male, alive, weight 8¼ lbs. Dismissed 11-12-20, weight 7 lbs. Mother a healthy woman - had scarlet fever and bronchitis as a child.
W.R. Mother = Doubt. Pos. (3±5∓). 3-3-22.

Case No.

690. W.R. Mother = Negative (3-5-). 3-12-20.
Mother = Negative (3-5-). 8-12-20.

8th Preg. Married. Age 34.
L.P. 15-4-20. Headache and nervousness during last three months of pregnancy - has not felt life since she became pregnant. Admitted to Antenatal Dept. 27-11-20, uterus just palpable above symphysis. Missed Abortion. Curetted - four months foetus removed. Dismissed 13-12-20.
Previous Pregnancies.- 1st, 2nd, 3rd, 4th and 6th = Normal, F.T., alive: 5th = Premature (7 months): 7th = Complete Miscarriage at about three and a half months (Aug., 1919).

691. W.R. Mother = Negative (3-5-). 8-12-20.
Child = Negative (3-5-). 3-12-20.

1st Preg. Single. Age 19.
L.P. 1-3-20. Normal pregnancy and twelve hours labour - Child born 1-12-20, Female, weight 8¼ lbs. R.P. Dismissed 19-12-20, weight 8 lbs. Mother a healthy woman.
Child was known to be alive and well when aged 2½ months, no trace since.

692. W.R. Mother = Negative (3-5-). 3-12-20.

4th Preg. Married. Age 38.
L.P. Feby., 1920. Normal pregnancy and labour. Child born 25-11-20, male, weight 9¼ lbs. Dismissed 4-12-20, weight 9½ lbs. 22-2-22 - Mother and child alive and well - child now aged 15 months and never any illness.
Previous Pregs.- 1st - 3rd = All F.T., normal, alive (last in Decr., 1918).

693. W.R. Mother = Negative (3-5-). 3-12-20.

1st Pregnancy. Married. Age 29.
? L.P. Contracted Pelvis - Caesarean Section (sterilised) - Child born 28-11-20, male, weight 7¼ lbs. Dismissed 22-12-20, weight 6 lbs. 6-4-22 - Both well. Child now aged 16 months -
W.R. Mother = Negative (3-5-). 6-4-22.
Child = Negative (3-5-). 6-4-22.

Case No.

694. W.R. Mother = Negative (3-5-). 8-12-20.
Child = Negative (3-5-). 3-12-20.

1st Preg. Single. Age 23.
L.P. 19-2-20. Normal pregnancy. Fifteen hours labour - child born 2-12-20, male, weight 8 lbs. Child had Ophthalmia. Dismissed 21-12-20, weight 6½ lbs. Mother healthy: pelvis normal: urine normal.
26-2-22 - Child alive and in good health - now aged 14 months.

695. W.R. Mother = Negative (3-5-). 8-12-20.
Child = Negative (3-5-). 3-12-20.

1st Preg. Single. Age 27.
Mother healthy, pelvis normal but coccyx prominent: No albuminuria. Normal pregnancy. Child born 2-12-20, Female, weight 7½ lbs. (20 hours labour). Dismissed 13-12-20, weight 8 lbs. No further trace after dismissal.

696. W.R. Mother = Negative (3-5-). 8-12-20.
Child = Negative (3-5-). 3-12-20.

1st Preg. Married. Age 19.
L.P. March, 1920. Normal pregnancy and labour: Slight P.P.H. Child born 2-12-20, Female, weight 7¾ lbs. Placenta expelled by expression, membranes ragged and incomplete. Mother healthy-some anaemia. Dismissed 11-12-20, weight 8 lbs. Child died 9-1-22, aged one year.

697. W.R. Mother = Negative (3-5-). 3-12-20.

2nd Preg. Married. Age 36.
L.P. 11-9-120. Admitted 30-11-20 - Incomplete Abortion. Bleeding began five days before admission and continued for three days then came on with greater severity on 5th day - large clots passed. Placental tissue protruding from cervix on admission - curetted. Mother healthy: no anaemia.
1st Pregnancy was F.T., normal (lived only 17 days): retained placenta (May, 1919).

Case No.

698. W.R. Mother = Negative (3-5-).3-12-20.

7th Preg. Married. Age 34.
L.P.- Amenorrhoea since last pregnancy. Well throughout pregnancy. Flat pelvis (Diag. Conj. = 3¾"-, True Conj. = 3"-.) Five hours labour - Child born alive 28-11-20, male, weight 9 lbs. Dismissed 6-12-20. 6-4-22 - Both well - Child now aged 16 months -
W.R. Mother = Negative (3-5-). 6-4-22.
Child = Negative (3-5-). 6-4-22.
Prev. Pregs.- 1st, 2nd, 3rd = all F.T., S.B., Chloroform and Forceps: 4th, 5th, 6th = all F.T., alive, Chloroform & Forceps (last in Novr., 1919).

699. W.R. Mother = Negative (3-5-). 8-12-20.
Child = Negative (3-5-). 3-12-20.

1st Preg. Single. Age 18.
L.P. 5-3-20. Normal pregnancy and labour. Child born 2-12-2o, male, alive, weight 7½ lbs. R.P. Mother anaemic but healthy otherwise. Dismissed 11-12-20, weight 7 lbs. 17-3-22 - Child alive and in good health - never any illness - now aged 15 months.

700. W.R. Mother = Negative (3-5-). 8-12-20.
Child = Negative (3-5-). 3-12-20.

1st Preg. Single. Age 23.
L.P. 12-e-20. Patient was well throughout pregnancy. Child born 2-12-20, Female, weight 7¼ lbs. (30 hours labour). Phlebitis Rt. saphenous vein during puerperium. Dismissed 24-12-20, 21-2-22 - Mother and child alive and both well - child now aged 14 months.

701. W.R. Mother = Negative (3-5-). 8-12-20.
Child = Negative (3-5-). 3-12-20.

1st Preg. Married. Age 20.
L.P. ? March, 1920. Normal pregnancy. Child born 3-12-20 (4 hours labour)- Female, weight 7 lbs. Dismissed 12-12-20, weight 6¾ lbs. Child died 20-12-20.

Case No.

702. W.R. Mother = Negative (3-5-).

6th Preg. Married. Age 30.
L.P. middle July, 1920. Attended Antenatal Dispensary 3-12-20 - bleeding for about one week with slight pain. Admitted 4-12-20 - Threatened Abortion. Dismissed 3-1-21. Readmitted 7-1-21 - Incomplete Abortion - curetted. Dismissed 14-1-21.
Previous pregnancies.- 1st = 7 months, normal labour (lived 6 hours): 2nd = F.T., normal, alive: 3rd = 8 months (? placenta praevia): 4th and 5th = F.T., normal (June, 1918).

703. W. R. Mother = Negative (3-5-). 8-12-20.

7th Preg. Married. Age 28.
L.P. 14-7-20 - Leucorrhoea.
All previous pregnancies normal, F.T.

704. W.R. Mother = Strongly Positive (3+5+). 5-12-20.

6th Preg. Married.
L.P. 3-9-20. Attended Antenatal Disp. 3-12-20 - bleeding 14 days before and again on 2-12-20 - periods irregular before pregnancy began. Pain left side abdomen and very marked oedema and thickening of left leg (Phlegmasia followed last pregnancy). Thin brown-red discharge: Piles. Laceration of vaginal orifice. Headache. Put on mercury 24-12-20 - great improvement. Swelling of leg almost cleared up. Child born at home 10-6-21, male, alive.
W.R. Mother = Strongly Positive (3+5+) 27-1-22.
Child = Negative (3-5-). 27-1-22.
23-2-22 - Child alive and well - never any illness - now aged 8 months.

Prev. Pregs.- 1st - 4th = F.T., normal, alive: 5th = F.T., S.B.

705. W.R. Mother = Negative (3-5-). 8-12-20.

2nd Preg. Married. Age 25.
L.P. 14-7-20. Attended Antenatal Disp. 3-12-20 - very bad vomiting: headaches: scanty urine. No albuminuria (24-12-20). Hands and feet slightly swollen. Premature labour.
1st Pregnancy = 8 months - Eclampsia (Feby.,1920). History of anaemia.

Case No.

706. W.R. Mother = Negative (3-5-). 8-12-20.

3rd Pregnancy. Married. Age 27.
L.P. Sept., 1920. Attended Antenatal Dispensary 3-12-20 - Contracted Pelvis (Pelvis C.V.=3¼"). Admitted to Antenatal Dept. 4-4-21 dismissed on 9-4-21 to return for section. Readmitted 4-5-21 - had gone into labour (36 hours in labour) and os was well dilated. Caesarean Section (sterilised) - Child born 4-5-21 - male, weight 7½ lbs. - head moulded. After several hours the infant developed blueness of extremities, pulse good and otherwise healthy looking. Died 13-5-21.
Previous pregnancies.- 1st Preg. = S.B. (8 months) 2nd = S.B., F.T. (Instrs.). Mother had Typhus at eight years of age: otherwise well.

707. W.R. Mother = Negative (3-5-). 8-12-20.
Child = Negative (3-5-). 8-12-20.

1st Preg. Single. Age 25.
L.P. 19-2-20. Patient was well till lip began to swell at two months but disappeared under treatment, but appeared again three months before delivery. Albuminuria - normal labour (12 hours) R.P. Child born 4-12-20, Female, weight 7 lbs. Dismissed 21-12-20, weight 6½ lbs. Mother on admission had marked oedema of face and ankles: slight presystolic murmur and thrill at apex: some bronchitis. History of oedema of legs four years ago. ? nephritis: ? rheumatism.
28-2-22 - Mother and child both alive and well - Child now aged 14 months.

708. W.R. Mother = Negative (3-5-). 17-12-20.
Child = Negative (3-5-). 8-12-20.

10th Preg. Married. Age 39.
L.P. 1st March, 1920. Admitted to Antenatal Dept. 1-12-20 - has felt well throughout pregnancy. Hydramnios: Albuminuria (3 esbach): oedema of legs and abdomen. Child born 3-12-20, Male, weight 10 lbs., alive but died 7-12-20. Mother dismissed 17-12-20. P.M.
Previous Pregnancies.- 1st & 2nd = F.T., normal, alive: 3rd = F.T., normal, S.B.: 4th = F.T., normal, living: 5th = F.T., normal, S.B.: 6th, 7th, 8th and 9th = miscarriages at six weeks- last child born 1918.

Case No.

709. W.R. Mother = Negative (3-5-). 17-12-20.
Child = Negative (3-5-). 8-12-20.

1st Pregnancy. Single. Age 19.
L.P. March, 1920. Child born (normal pregnancy and labour) 4-12-20, Female, weight 7 lbs. Vaginal lacerations. Dismissed 13-12-20, weight 5½ lbs. No further trace after dismissal.

710. W.R. Mother = Negative (3-5-). 8-12-20.
Child = Negative (3-5-). 8-12-20.

3rd Pregnancy. Married. Age 25.
Amenorrhoea since last pregnancy. Normal pregnancy and labour (10 hours). Child born 4-12-20, Female, weight 7½ lbs. Dismissed 14-12-20, weight 7¾ lbs. 22-2-22 - Child alive and well - now aged 14 months.

Prev. Pregs.- 1st and 2nd = (July, 1919), normal, F.T., alive.

711. W.R. Mother = Negative (3-5-). 17-12-20.
Child = Negative (3-5-). 8-12-20.

4th Pregnancy. Married. Age 29.
L.P. 7-4-20. Complained of sickness throughout pregnancy - gradually increasing in severity. Severe epigastric pain but no headache. Toxaemia: Induction of labour. Admitted 1-12-20, slight oedema - uterus 8 months size. Urine - Albumin ++ Blood +. Stomach lavage, etc., persistent vomiting: induction - child born 4-12-20, female, premature, weight 5 lbs. Child died 12-12-20. Mother dismissed 18-12-20. P.M.
Prev. Pregs.- 1st = F.T., living, Chloroform (eclampsia): 2nd & 3rd (Jany., 1917) = F.T., normal, alive.

712. W.R. Mother = Negative (3-5-). 8-12-20.

1st Preg. Single. Age 18.
L.P. end Feby., 1920. Patient was well throughout pregnancy until twelve hours after labour began when she had severe eclamptic fits (had 8 - 9 during morning of 4-12-20). Some cyanosis of face: only slight oedema of legs and ankles (? urine). Child born alive, female, 3-12-20. Dismissed 18-12-20. Child was alive and well when aged one year -.

Case No.

713. W.R. Mother = Negative (3-5-). 17-12-20.
Child = Negative (3-5-). 8-12-20.

11th Pregnancy. Married. Age 39.
L.P. 29-3-20. Patient was well throughout pregnancy until two days before delivery when she had pains in back, and on morning of 5-12-20 had bleeding. Child born 6-12-20, Female, weight 7 lbs. Accidental Haemorrhage: R.P. Dismissed 15-12-20, weight 6 lbs. 6 ozs.
6-4-22 - Both well. Blood - Mother = Neg.(3-5-).
(Child now aged 16 months)-Child = Neg.(3-5-).

Previous pregnancies all F.T., normal, alive (last in Feby., 1919).

714. W.R. Mother = Negative (3-5-). 17-12-20.
Child = Negative (3-5-). 8-12-20.

3rd Preg. Married. Age 32.
L.P. 10-3-20. Complained of sickness and vomiting throughout pregnancy - normal labour - child born 5-12-20 - Female, weight 7½ lbs. R.P. Dismissed 15-12-20, weight 7 lbs.
21-2-22 - Child alive (now aged 14 months): is ill with Pneumonia.
Prev. Pregs.- 1st and 2nd = F.T., normal (last in April, 1912).

715. W.R. Mother = Negative (3-5-). 8-12-20.
Child = Negative (3-5-). 8-12-20.

1st Preg. Single. Age 22.
L.P. 25-2-20. Pregnancy normal throughout. Child born 5-12-20 (36 hours labour) - female, weight 6½ lbs. Dismissed 15-12-20, weight 6¼ lbs. 28-2-22 - Child alive: never any illness (now aged 14 months).

716. W.R. Mother = Negative (3-5-). 17-12-20.
Child = Negative (3-5-). 8-12-20.

1st Preg. Married. Age 25.
L.P. end April, 1920. Constant sickness and vomiting throughout pregnancy. Premature labour - child born 5-12-20, Female, weight 6 lbs. Dismissed 15-12-20, weight 5 lbs. 6 ozs. 6-4-22 - Both well - child now 16 months: Blood Mother = Neg. (3-5-). 7-4-22.
Child = Neg. (3-5-). 7-4-22.

Case No.

717. W.R. Mother = Negative (3-5-). 17-12-20.
Child = Negative (3-5-). 8-12-20.

5th Preg. Married. Age 30.
L.P. 15-3-20. Normal pregnancy and labour. Child born 5-12-20 - Female, weight 7½ lbs. Dismissed 15-12-20, weight 7 lbs.
6-4-22 - Both well - child never any illness - now aged 16 months: Blood - Mother = Neg.
Child = Neg.
Prev. Pregs.- 1st to 4th = F.T., normal, living (last on 15-12-19).

718. W.R. Mother = Negative (3-5-). 8-12-20.

2nd Preg. Married. Age 27.
L.P. 27-9-20. Patient was well till two days before admission when she passed small clot and continued to bleed till admission on 30-11-20 - Patient said she got a fright three days previously. Inevitable Abortion: Packed: Curetted. Dismissed 8-12-20.
Previous pregnancy was normal, F.T., alive (Aug., 1918).

719. W.R. Mother = Negative (3-5-). 8-12-20.

5th Pregnancy. Married. Age 30.
L.P. ? July, 1920. Patient was unaware of pregnancy till a few days before admission: has had slight irregular bleedings for past three months and more or less constant bleeding since early in October - own doctor removed a four months embryo on 29-11-20 - placenta retained - Admitted 30-11-20, curetted: developed Acute Rheumatism with V.S. mitral murmur. Died 17-12-20.
Prev. Pregs.- 1st - 4th = normal, F.T., alive (last in March, 1919).

720. W.R. Mother = Negative (3-5-). 17-12-20.
Child = Negative (3-5-). 8-12-20.

2nd Preg. Single. Age 21.
L.P. March, 1920. Normal pregnancy and labour - child born 6-12-20, Female, weight 8 lbs. Dismissed 16-12-20, weight 6¾ lbs.
Child died in R.H.S.C. on 2-4-21.
1st Pregnancy was F.T., normal, living (1918).

Case No.

721. W.R. Mother = Negative (3-5-). 17-12-20.
Child = Negative (3-5-). 8-12-20.

1st Preg. Married. Age 22.
L.P. ?. Normal pregnancy and labour - Child born 6-12-20, Female, weight 9 lbs. Dismissed 16-12-20, weight 8½ lbs. Mother a healthy woman but deaf since measles as a child. No trace since dismissal from hospital.

722. W.R. Mother = Negative (3-5-). 17-12-20.
Child = Negative (3-5-). 8-12-20.

1st Preg. Married. Age 23.
L.P. 2-3-20. Appendicectomy in May, 1920 - has been well since. Normal labour: R.P. - Child born alive, 7-12-20, male, weight 6½ lbs. Dismissed 17-12-20. No trace of mother and child since dismissal.

723. W.R. Mother = Negative (3-5-). 17-12-20.
Child = Negative (3-5-). 8-12-20.

9th Preg. Married. Age 33.
L.P. 13-2-20. Contracted Pelvis: High Forceps - membranes ruptured before admission. (Pelvis - Diag. Conj. = 4½" +, True Conj. = 3¼"). Child born dead 7-12-20 (36 hours labour) male, weight 8 lbs. P.M.
Previous Pregnancies.- 1st and 2nd = S.B., F.T., instrs.: 3rd = F.T., living, normal labour: 4th, 5th, 6th, 7th and 8th = F.T., living, normal - last on 13-12-18. Convulsions (3 hysterical) with 7th preg.)

724. W.R. Mother = Negative (3-5-). 8-12-20.

1st Preg. Married. Age 20.
L.P. end March, 1920. Patient was well throughout pregnancy. Pains began day before admission, membranes remained unruptured and were ruptured artificially when full dilatation had taken place. Head unfixed above brim. Contracted Pelvis (Diag. Conj. = 4½"-: True Conj. = 3¾"). Mother healthy - no deformity of limbs. Child born 2-12-20, male, weight 7 lbs. Dismissed 11-12-20, weight 5½ lbs. No trace since dismissal.

Case No.

725. W.R. Mother = Negative (3-5-). 17-12-20.
Child = Negative (3-5-). 17-12-20.

1st Preg. Single. Age 20.
L.P. end March, 1920. Severe constipation throughout pregnancy and some sickness: complain-ed of general weakness. Premature (8 months) labour. Child born 8-12-20, Female, weight 6 lbs. Dismissed 17-12-20, weight 4½ lbs. Child died 7-1-21.

726. W.R. Mother = Strongly Positive (3+5+).17-12-20.
Child = Strongly Positive (3+5+).22-12-20.

2nd Preg. Married. Age 23.
L.P. middle April, 1920. Admitted to Antenatal Dept. 29-11-20. Severe and constant headache for ten days before admission but no epigastric pain: no sickness: no difficulty with urine. On admission had slight oedema of legs: uterus about seven months size. Albuminuria (++). Child born 20-12-20 - female, weight 7 lbs. Mother had sore throat about 25-12-20 - pneumococci and streptococci in swab - no K.L.B. Dismissed 1-1-21. Child was known to be alive and well when aged 11 months but no trace since.

727. W.R. Mother = Negative (3-5-). 17-12-20.

2nd Preg. Married. Age 24.
L.P. early March, 1920. Normal pregnancy and labour. Child born 6-12-20 - Male, weight 7 lbs. Membranes ragged but complete. Dismissed 16-12-20, weight 6¾ lbs. 22-2-22 - Child alive and very well - never any illness - now aged 14 months.
1st pregnancy = F.T., normal, alive (7-9-19).

728. W.R. Mother = Negative (3-5-).

3rd Preg. Married. Age 28.
L.P. end April, 1920. Admitted to Antenatal Dept. 5-12-20 - had some haemorrhage without pain 10 days before admission. Haemorrhage ceased but began again morning of admission. Antepartum Haemorrhage -premature labour - child born 9-12-20, male (about 7½ months) weight 5 lbs. Died 17-12-20.
Prev. Pregs.- 1st and 2nd = F.T., normal, living.

Case No.

729. W.R. Mother = Negative (3-5-). 17-12-20.
Child = Negative (3-5-). 17-12-20.

2nd Preg. Married. Age 20.
L.P. March, 1920. Pregnancy normal throughout except for some pain in legs. Normal labour: P.P.H. (douched). Child born 8-12-20, male, weight 9 lbs. Dismissed 18-12-20, weight 8½ lbs. 21-2-22 - Child alive and well - never any illness: Now aged 14 months.
Previous pregnancy was full-time, normal, living (16-10-19).

730. W.R. Mother = Negative (3-5-). 17-12-20.

1st Preg. Married. Age 25.
L.P. 29-2-20. Well throughout pregnancy except for pains in back. Persistent Occipito-posterior presentation. Forceps: R.P. Child born 7-12-20, Female, weight 6¾ lbs. Mother a healthy woman but deaf since measles as a child. 24-5-22 - Child now aged 17 months and very healthy - only illness measles.
W.R. Mother = Negative (3-5-). 24-5-22.
Child = Negative (3-5-). 24-5-22.

731. W.R. Mother = Strongly Positive (3+5+).17-12-20.

1st Pregnancy. Married. Age 24.
L.P. March, 1920. Normal pregnancy and labour. Child born 8-12-20, male, weight 7 lbs. Dismiss-ed 18-12-20, weight 7 lbs. Child was known to be alive and well when at the age of three months but no trace since.

732. W.R. Mother = Negative (3-5-). 17-12-20.

4th Preg. Married. Age 34.
L.P. end Sept., 1920. Patient was well till 26-11-20 when she had bleeding which she thought was menstrual - bleeding continued and was accompanied by severe pelvic pain. Ectopic gestation (right tube) operation. 4-12-20 - haemorrhage into abdominal cavity: Rt. salpingectomy and left oophorectomy. Dismissed 21-12-20. Mother pale and thin: was in G.R.I. with anaemia, etc. in March, 1920. Prev. Pregs.- 1st = F.T., living, normal: 2nd = F.T., living, twins: 3rd = F.T., living, normal (July, 1919).

Case No.

733. W.R. Mother = Negative (3-5-). 17-12-20.

1st Preg. Married. Age 20.
L.P. April, 1920. Patient was well throughout pregnancy till 1-12-20 when she began to have difficulty with vision : no headaches - no epigastric pain - no sickness: Had noticed swelling of legs for 3-4 months. Dimness of vision gradually increased. Toxaemia: Induction: Forceps. Admitted 6-12-20 - some oedema of legs and abdomen. High tension pulse. Urine - albumen ++++. Bougies inserted 7-12-20 - child born 9-12-20 (forceps) Female, alive, weight 6 lbs. Died 9-12-20. Mother dismissed 10-1-21.P.M.

734. W.R. Mother = Negative (3-5-). 17-12-20.
Child = Negative (3-5-). 17-12-20.

6th Preg. Married. Age 29.
L.P. 14-3-21. Normal pregnancy and labour. Child born 10-12-20 - Female, weight 8 lbs. Dismissed 20-12-20. 4-4-22 - Child now aged 16 months - Both well.
W.R. Mother = Negative (3-5-). 4-4-22.
Child = Negative (3-5-). 4-4-22.
Previous Pregnancies.- all normal except 3rd which was extra-uterine - operation. Last child in Jany., 1919.

735. W.R. Mother = Negative (3-5-). 17-12-20.

1st Preg. Married. Age 27.
L.P. 20-10-20. Bleeding began about 20-11-20 - since then intermittent bleeding - sometimes large clots passed. Some pain but never severe. Admitted 8-12-20 - Incomplete Abortion: decidual tissue removed by curettage - douched. Dismissed 15-12-20.

736. W.R. Mother = Negative (3-5-).

6th Preg. Single. Age 37.
L.P. end Aug., 1920. Some haemorrhage three weeks before admission - intermittent since then. Admitted to Ante-natal Dept. 1-12-20 - no bleeding. Incomplete Abortion: curettage. Patient looked pale and anaemic.
Prev. Pregs.- 1st = F.T., living, Chloroform & Instrs. 2nd - 5th = normal, F.T., living.

Case No.

737. W.R. Mother = Negative (3-5-). 17-12-20.

2nd Preg. Single. Age 23.
L.P. last week Feby., 1920. False labour - admitted to Antenatal Dept. 1-12-20. Uterus up to costal margin. Dismissed 11-12-20.
Previous pregnancy = F.T., normal, living.

738. W.R. Mother = Negative (3-5-). 17-12-20.

1st Preg. Married. Age ?
L.P. Sept., 1920. Bleeding began evening of 6-12-20 - intermittent till admission on 8-12-20 with slight pain at first. Incomplete Abortion - curettage. Patient slightly anaemic but otherwise healthy. Dismissed 15-12-20.

739. W.R. Mother = Negative (3-5-). 17-12-20.
Child = Negative (3-5-). 17-12-20.

1st Preg. Married. Age 27.
L.P. March, 1920. Contracted Pelvis (Diag. Conj. = 3¾", True Conj. = 3"). Uterus about 8½ months size. Admitted 9-12-20 - spontaneous delivery 11-12-20 - Female, weight 6 lbs. Patient was a small rickety woman (Caesarean section was proposed but patient delivered herself spontaneously). Dismissed 20-12-20.
4-4-22 - Child now aged 16 months and very well-
W.R. Mother = Negative (3-5-).
Child = Negative (3-5-).

740. W.R. Mother = Negative (3-5-). 17-12-20.

9th Preg. Married. Age 39.
L.P. Septr., 1920. Patient was well throughout pregnancy till evening of 6-12-20 when she had bleeding without pain. Admitted Antenatal Dept. - ovum in sac with placenta which came away completely 8-12-20. Dismissed 14-12-20. Readmitted 6-1-21 - bleeding since 31-12-20.
Previous Pregnancies.- 1st = F.T., alive, CH.clz. & Instrs: 2nd - 8th = F.T., normal, living (1-12-19).

Case No.

741. W.R. Mother = Negative (3-5-). 17-12-20.

3rd Preg. Married. Age 23.
L.P. early Septr., 1920. Patient was well till 30-11-20 when there was haemorrhage which soon stopped. Began again morning of 3-12-20 with pain - clots came away. Incomplete Abortion - curettage. Dismissed 10-12-20.
Previous Pregnancies.- 1st and 2nd (July, 1919)= F.T., living, normal.

742. W.R. Mother = Negative (3-5-). 17-12-20.

9th Preg. Married. Age 43.
L.P. 2nd week May, 1920. Began to bleed evening of 7-12-20- bleeding continued and pain came on morning of 8-12-20. Marginal Placenta Praevia, Breech - membranes ruptured and foot brought down - uterus about seven months size. Child born dead 8-12-20. P.M.
Prev. Pregs.- 1st, 3rd, 5th, 6th, 7th and 8th = normal, F.T., alive (last on 19-12-16): 2nd and 4th = miscarriages at three and two months respectively. Mother shows marked pallor but is otherwise healthy.

743. W.R. Mother = Negative (3-5-). 17-12-20.

8th Preg. Married. Age 40.
L.P. Octr., 1920. Slight bleeding on 5-12-20 which continued till 7-12-20 when it became severe. Severe pains throughout. Foetus passed before admission. Incomplete Abortion. Placental debris cleared out by curettage on 8-12-20. Mother had Pneumonia (influenzal) five weeks before admission (8-12-20).
Prev. Pregs.- 1st - 7th = All full-time, normal labours - children alive: had jaundice during last three pregnancies. Mother healthy woman - chest clear.

744. W.R. Mother = Negative (3-5-). 17-12-20.
Child = Negative (3-5-). 17-12-20.

6th Preg. Married. Age 37.
L.P. - Amenorrhoea since last pregnancy: has felt rather sick during present pregnancy: normal labour - child born alive, 9-12-20, male, weight 8 lbs. Dismissed 20-12-20, weight 7½ lbs.
Prev. Pregs.- 1st = CH.clz. & Forceps, F.T.,alive: all others = F.T., alive, normal.

Case No.

745. W.R. Mother = Negative (3-5-). 17-12-20.
Child = Negative (3-5-). 17-12-20.

5th Preg. Married. Age 30.
L.P. 28-2-20. Patient was well throughout pregnancy. Normal labour - child born alive, male, weight 8¼ lbs. 8-12-20. Dismissed 18-12-20, weight 7½ lbs. No trace after dismissal.
Prev. Pregs.- 1st - 4th = normal, F.T., alive.

746. W.R. Mother = Negative (3-5-). 17-12-20.
Child = Negative (3-5-). 17-12-20.

1st Preg. Single. Age 22.
L.P. 14-2-20. Well throughout pregnancy. Normal labour: R.P. - Child born 8-12-20 - Female, weight 9½ lbs. Dismissed 18-12-20, weight 8 lbs. 10 ozs. No trace of mother and child after dismissal.

747. W.R. Mother = Strongly Positive (3+5+). 17-12-20.
Child = Strongly Positive (3+5+). 17-12-20.

1st Preg. Single. Age 18.
L.P. end Feby., 1920. Normal pregnancy and labour. Child born 8-12-20, Male, weight 7¼ lbs. Dismissed 17-12-20, weight 7 lbs.
18-2-22. - Child well (adopted) - now 14 months old. Mother had tonsils removed but is otherwise well: Menorrhagia - looks anaemic.-
Blood W.R. Mother = Strongly Positive (3+5+).

748. W.R. Mother = Negative (3-5-). 17-12-20.
Child = Negative (3-5-). 17-12-20.

8th Preg. Married. Age 33.
L.P. ?: Twin pregnancy: has had vague pains in bones, vomiting and loss of appetite throughout pregnancy also slight irritating cough which is always present during pregnancy. Children born alive 7-12-20 - both female - 1st weighed 5½ lbs., 2nd weighed 5¾ lbs. Both died - 1st on 13-12-20 and 2nd on 16-12-20. Mother dismissed 18-12-20.
Previous Pregs.- 1st - 7th = Normal, F.T., alive: (last in Decr., 1918). Mother had Cystitis & Nephritis during confinement in 1916.

Case No.

749. W.R. Mother = Negative (3-5-). 17-10-20.
Child = Negative (3-5-). 17-10-20.

2nd Preg. Married. Age 23.
L.P. early March, 1920. Normal pregnancy. Brow presentation - version to vertex - forceps. Pains began four days before delivery but became severe only about twentyfour hours before delivery. Child born 9-12-20, Female, weight 7 lbs. Dismissed 20-12-20. 25-11-21 - Child now eleven months old: At eight months took Diarrhoea and vomiting. Was in R.H.S.C. two months. Now improving.
Prev. Pregnancy was normal, F.T., alive (June, 1919).

750. W.R. Mother = Negative (3-5-). 17-12-20.
Child = Negative (3-5-). 17-12-20.

1st Preg. Single. Age 27.
L.P. 12-3-20. Patient had sickness during last two months of pregnancy and was able to take light diet only. Child born 11-12-20 - male, weight 8 lbs. Dismissed 7-1-21, weight 8½ lbs. Mother developed rectal abscess but was otherwise healthy. Pus from abscess contains Staphylococci, streptocci diphtheroid and coliform bacilli.
25-2-22 - Child now aged 14 months and very well - W.R. Mother = Negative (3-5-).
Child = Negative (3-5-).

751. W.R. Mother = Negative (3-5-). 17-12-20.

6th Preg. Married. Age 33.
L.P. 22-2-20. Patient was well till three weeks before delivery when cough and dyspnoea became troublesome. Admitted 10-12-20 - coarse, dry and moist rales all over chest (Both sides) - percussion clear. Slight dilatation right side of heart: no murmurs. Forceps delivery on account of chest condition: child born 10-12-20, male, weight 9½ lbs. Dismissed 18-12-20, weight 9 lbs. Mother's chest cleared up considerably.
22-2-22 - Child now aged 14 months and very well: never any illness.
Prev. Pregs. - 1st - 4th = normal: 5th = CH.clz. & Instrs. (24-4-19). Has had bronchitis for past nine years - otherwise healthy.

Case No.

752. W.R. Mother = Negative (3-5-). 17-12-20.
Child = Negative (3-5-). 17-12-20.

1st Preg. Single. Age 17.
L.P. 13-2-20. Normal pregnancy. Child born 10-12-20 (30 hours labour) - Female, weight 8 lbs. Dismissed 18-12-20, weight 7¼ lbs. 21-2-22 - Child now aged 14 months and in very good health - never any illness.

753. W.R. Mother = Negative (3-5-). 17-12-20.
Child = Negative (3-5-). 17-12-20.

1st Preg. Single. Age 22.
L.P. 1-3-20. Normal pregnancy. Child born 9-12-20 (25 hours labour) - Female, weight 8 lbs. Dismissed 18-12-20, weight 7½ lbs., but died on 9-3-21 -'Chicken-pox.'

754. W.R. Mother = Negative (3∓5-). 17-12-20.

1st Preg. Married. Age 25.
L.P. 30-8-20. Attended Antenatal Dispensary 10-12-20 - severe abdominal pain, sickness and vomiting (excessive): Digestion poor: frequent micturition: 28-1-21 - complained of unconscious turn and dimness of vision. No albuminuria.

755. W.R. Mother = Doubt. Neg. (3∓5-). 28-12-20.
(Same specimen) (3-5-). 30-12-20.
Child = Negative (3-5-). 22-12-20.

2nd Preg. Married. Age 25.
L.P. early March, 1920. Normal pregnancy and labour - Child born 19-12-20, Female, weight 9½ lbs. Dismissed 28-12-20, weight 7¼ lbs. No further trace after dismissal.
Previous pregnancy was F.T., living, normal (Decr., 1919). Mother had Pneumonia four years ago but is otherwise healthy.

756. W.R. Mother = Neg. (3∓5-). 17-12-20.

1st Preg. Single. Age 32.
L.P. March or April, 1920. Attended Antenatal Dispensary 10-12-20 - constipation: swelling of leg. No albuminuria (20-12-20 & 24-12-20).

Case No.

757. W.R. Mother = Negative (3-5-). 17-12-20.

10th Preg. Married. Age 39.
L.P. end July, 1920. Attended Antenatal Disp. 10-12-20 - yellow vaginal discharge: severe pain in left side.
All previous pregnancies and labours normal (last 2½ years ago).

758. W.R. Mother = Doubt. Positive (3±5-). 17-12-20.
Child = Negative (3-5-). 27-12-20.

1st Preg. Single. Age 16.
L.P. last week March, 1920. Normal pregnancy and labour - Child born 11-12-20, male, weight 7¼ lbs., alive, but died 16-12-20. Mother's W.R. was repeated on first sample of serum - again gave doubtful, though less strongly, positive on 22-12-20. Mother dismissed 21-12-20. Patient was visited at her own home on 9-8-21 - she was in bed ill - had excessive vomiting on 8-8-21 which necessitated her leaving her work. Patient's glands were badly swollen.

759. W.R. Mother = Negative (3-5-). 17-12-20.

1st Preg. Married. Age 27.
L.P. April, 1920. Very sick throughout pregnancy-not only in the morning but at any time. Has had no headache and did not notice any oedema. Admitted 10-12-20 - had sickness followed by four convulsions that evening. Eclampsia. A large woman and feet, legs, arms, hands and face very oedematous. Comatose on admission and had two convulsions. Stomach lavage, etc. - further fits - Premature, macerated foetus - Female, weight 3 lbs. born 17-12-20. Improved rapidly after delivery. Patient has always been troubled with bilious attacks. ? urine.

760. W.R. Mother = Negative (3-5-).

2nd Preg. Married. Age 39.
L.P. 20-10-20. Admitted Antenatal Dept. 10-12-20-Well till day of admission when she had heavy sensation in pelvis and noticed slight bleeding. Incomplete Abortion. (Retroflexed Uterus) - Curettage: I.U.D. - uterus packed. Dismissed 27-12-20.
Previous pregnancy was a three months abortion.

Case No.

761. W.R. Mother = Negative (3-5-). 17-12-20.

8th Pregnancy. Married. Age 32.
L.P. 6-3-20. Admitted to Antenatal Dept. 10-12-20 - was in Antenatal Dept. in April, 1920 with bleeding: since then pregnancy has been normal except for pain in lumbar region. Albuminuria. Normal labour - child born 13-12-20 - Female, weight 7 lbs. Dismissed 27-12-20. 18-11-20 - Baby now eleven months old and very well.
Previous Pregs.- 1st to 6th = all normal normal- two children died of convulsions at eight months and fourteen weeks respectively. Mother looked healthy. 7th Preg. = miscarriage (June, 1919).

762. W.R. Mother = Strongly Positive (3+5+). 17-12-20.

11th Preg. Married. Age 40.
L.P. Sept., 1920. Admitted to Antenatal Dept. 10-12-20. Six weeks before admission had bleeding which lasted four weeks - large clots came away. Bleeding stopped for one week, then returned and persisted till admission. ? Abortion. Dismissed 13-12-20.
Previous pregnancies.- All normal - no miscarriages (last child in July, 1914). Four children alive: twins died aged one week: one girl died of consumption when aged 21 yrs., one of Small-pox and one of Whooping-cough.

763. W.R. Mother = Negative (3-5-). 17-12-20.

1st Pregnancy. Married. Age 25.
L.P. 4-3-20. Admitted Ante-natal Dept. 10-12-20 - Albuminuria - Patient was well till seventh month when swelling of legs was noticed - face swollen in mornings. Patient looked a healthy woman but had slight puffiness of face and marked oedema of feet and ankles: Right cardiac border 1" to right of M.S.- a presystolic murmur at apex - sounds pure in other areas: Lungs clear: Albuminuria +++. As albuminuria was increasing in amount labour was induced (bougies) 14-12-20. Child born 16-12-20 -alive, Female, weight 6½ lbs. - died 26-12-20. Slightly febrile puerperium: foul lochia. Albuminuria and general condition cleared up before dismissal(1-1-21). P.M.

Case No.

764. W.R. Mother = Negative (3-5-). 17-12-20.

1st Pregnancy. Married. Age 33.
L.P. 30-4-20. Patient was well throughout pregnancy till onset of Bronchitis at fifth month - worse than in former years: was in G.R.I. for a month - dismissed two weeks before admission to G.R.M.H. Patient looked healthy: has marked dyspnoea - rales and rhonchi generally: bronchitis and asthma. Has had bronchitis every winter since 1915 - worse since 1915 - worse since she had influenza in 1918. Admitted to Antenatal Dept. 6-12-20, dismissed 14-12-20.

765. W.R. Mother = Strongly Positive (3+5+). 17-12-20.

2nd Preg. Married. Age 28.
L.P. ? May, 1920. Admitted to Antenatal Dept. 7-12-20. Patient was well till onset of dyspnoea 14 days before admission: slight swelling of feet and ankles (particularly of left) for three to four days. Contracted Pelvis (Diag. Conj. = 3¼", True Conj. = 2½" +). Patient is a small woman with rickety legs: heart dilated to left: marked systolic whiff at mitral: Albuminuria: Some hydramnios. Dismissed 21-12-20 - became maniacal and was transferred to Duke Street Hospital when she went into labour, and was delivered by craniotomy on 25-11-20. She died on 26-12-20.
Previous pregnancy was F.T., Caesarean Section (Aug., 1914) - child lived 2½ hours.

766. W.R. Mother = Negative (3-5-). 17-12-20.

8th Preg. Married. Age 39.
L.P. 8-8-20. Hyperemesis gravidarum - Admitted Antenatal Dept. 7-12-20 - vomiting began 14 days before admission - no previous morning sickness. Since onset of vomiting it has grown worse - no food retained for past week. Uterus three fingers above symphysis. Looks a fairly healthy woman: some emaciation. Dismissed 17-12-20.
All previous pregnancies normal except one (1912) which ended in miscarriage at three months, and the last (Octr., 1918) which ended in premature labour - transverse - CH.clz. & forceps and secondary P.P.H. - all other labours normal. Patient had left-sided Bell's paralysis (2 years ago).

Case No.

767. W.R. Mother = Negative (3-5-). 17-12-20.

6th Preg. Married. Age 33.
L.P. 6-7-20. Admitted to Antenatal Dept.
9-12-20 - Inevitable Miscarriage. Began to bleed three weeks before admission - kept in bed for one week - no bleeding, but on getting up bleeding began again. No clots passed and no pain. Vagina packed - uterus explored and emptied 15-12-20. I.U.D.
Previous Pregnancies.- 1st - 5th = all normal, F.T., alive (last in April, 1919) - Vomiting fairly severe as a rule. Patient is well built and shows marked anaemia - said to be always present.

768. W.R. Mother = Negative (3+5-). 17-12-20.

2nd Preg. Married. Age 37.
L.P. 15-4-20. Admitted to Antenatal Dept.
9-12-20 - Severe vomiting: premature labour: macerated foetus. Patient was well till six days before admission when vomiting began (after a heavy meal) - unable to retain any food thereafter. Had some coffee-ground vomiting. Patient pale and looks ill, pulse rapid - frequent vomiting of black material. Macerated foetus - male, weight 5½ lbs. born 10-12-20. Patient developed toxic symptoms - verging on coma. Cellulitis of right buttock incised - died 19-12-20.
1st Pregnancy = CH. clz. & Forceps, S.B. (Aug., 1918). No serious illness.

769. W.R. Mother = Negative (3-5-). 17-12-20.

6th Pregnancy. Married. Age 35.
L.P. 24-7-20. Admitted to Antenatal Dept.
9-12-20 - Threatened Abortion - Bleeding began when patient was six weeks pregnant and continue spasmodically for one week: occurred again - very severely - six weeks later (lasted 10 minutes only). Further severe haemorrhage during whole of week preceding admission.
2-1-21 - Complete Miscarriage. Dismissed 10-1-21.
Previous pregnancies.- 1st, 3rd, 4th and 5th = F.T., normal, alive (last in August, 1918): 2nd = Placenta Praevia.

Case No.

770. W.R. Mother = Negative (3+5-). 17-12-20.

3rd Preg. Married. Age 29.
L.P. 21-8-20 - Incomplete Abortion: Digital Curettage. Slight bleeding began 8-12-20 (after a day's washing) and became very profuse (clots and foetus passed) on morning of admission (9-12-20). Great pallor on admission - pulse rapid and thready. Digital curettage. Dismissed 18-12-20.
Prev. Pregs.- 1st = F.T., Chlor. & Forceps, alive: 2nd = normal, F.T., alive (Decr., 1919).

771. W.R. Mother = Negative (3-5-). 17-12-20.

7th Preg. Married. Age 40.
L.P. 7-8-20. Complete Abortion. Haemorrhage began 9-12-20 but was very slight till four hours before admission on 11-12-20 when severe pain came on and bleeding became profuse. Uterus about four months size. Small macerated foetus and placenta expelled a few hours later. Dismissed 17-12-20.
Prev. Pregs.- 1st - 5th = All normal, F.T., alive (last in Aug., 1918): One miscarriage (4½ months) in Spring, 1914.
Operation for hernia 16 years ago - otherwise healthy.

772. W.R. Mother = Negative (3-5-). 17-12-20.

1st Preg. Married. Age 36.
L.P. 26-3-20. Contracted Pelvis (Diag. Conj. = 2¾" ++, True Conj. = 2¼" +) - marked flattening on left side: head not fixed: marked overlapping. Caesarean Section - child born alive 28-12-20, male, weight 9 lbs. Dismissed 22-1-21, weight 9½ lbs. Mother sterilised.
24-5-22 - Both mother and child well - child 17 months old - no illness so far.
W.R. Mother = Negative (3-5-). 24-5-22.
Child = Negative (3-5-). 24-5-22.

Case No.

773. W.R. Mother = Negative (3-5-). 22-12-20.
Child = Negative (3-5-). 22-12-20.

1st Preg. Married. Age 21.
L.P. 20-3-20. Admitted Antenatal Dept. 11-12-20 - fairly well throughout pregnancy till onset of sudden acute attack of asthma on 10-12-20 - pains came on at the same time. Chronic Bronchitis: slight woman - looks delicate. Breech presentation - child born 11-12-20, Female, weight 5½ lbs., alive. Placenta removed by hand introduced. Child died 17-12-20. Mother dismissed 20-12-20. Mother has had Chronic Bronchitis since childhood.

774. W.R. Mother = Negative (3-5-). 26-12-20.
Child = Negative (3-5-). 17-12-20.

1st Preg. Single. Age 23.
L.P. 19-3-20. Normal pregnancy and labour. Child born 13-12-20, Female, weight 7 lbs. Dismissed 22-12-20, weight 6½ lbs. No trace after dismissal from hospital.

775. W.R. Mother = Negative (3-5-).22-12-20.
Child = Negative (3-5-).17-12-20.

1st Preg. Married. Age 22.
L.P. March, 1920. Normal pregnancy. Child born (24 hours labour) 13-12-20, male, weight 7 lbs. Dismissed 21-12-20, weight 6½ lbs.
4-4-22 - Mother and child both well - child now aged 16 months - W.R. Mother = Negative.
Child = Negative.

776. W.R. Mother = Negative (3-5-). 28-12-20.
Child = Negative (3-5-). 17-12-20.

1st Preg. Single. Age 26.
L.P. end Feby., 1920. Normal pregnancy and labour - Child born 13-12-20, male, weight 8 lbs. Dismissed 23-12-20, weight 8 lbs. The Child was known to be alive and well when at the age of one year - no trace since.

Case No.

777. W.R. Mother = Negative (3-5-). 22-12-20.

3rd Preg. Married. Age 28.
L.P. 15-5-20. Attended Antenatal Disp. 24-9-20.- Contracted Pelvis (Diag. Conj. = 3¾", True Conj. = 3". Admitted to hospital 11-2-21 - Caesarean Section - (Patient sterilised) child born alive 2-3-21, Female, weight 8 lbs. Dismissed 23-3-21. 22-2-22- Child now aged 11 months and very well but ~~but~~ has has Whooping-cough at present.
Previous pregnancies.- 1st = F.T., S.B. (in hosp.): 2nd =(8 months) induction, S.B. (in hosp. June, 1919).

778. W.R. Mother = Strongly Positive (3+5+).22-12-20.

2nd Preg. Married.
Attended Antenatal Disp. once 19-12-20 - then was lost sight of till 23-3-21. States that she was delivered of twins on 4-2-21 - 1st lived 2 hours: 2nd lived 2 days. Mother is attending T.B. Dispensary (Elmbank St.)and G.R.M.H. Disp. (where she is getting "A" mixture. No trace since 23-3-21.

779. W.R. Mother = Negative (3-5-).

1st Preg. Single. Age 19.
L.P. 8-3-20. Attended Antenatal Dispensary 17-12-20. Generally Contracted Pelvis - C.V. = 4". Swelling of legs: profuse leucorrhoea - Child born 18-1-21, male, weight 6¼ lbs. - spina bifida - Died 19-1-21.

780. W.R. Mother = Negative (3-5-). 22-12-20.

3rd Preg. Married. Age 31.
L.P. 10-4-20. Attended Antenatal Dispensary 17-12-20 - excessive vomiting. Child born at home 1-3-21, male, alive. No further trace.
Prev. Pregs.- 1st = Abortion at three months: 2nd = Abortion at three months.

Case No.

781. W.R. Mother = Negative (3-5-). 22-12-20.

8th Preg. Married. Age 34.
L.P. end March, 1920. Attended Antenatal Disp. 17-12-20 - bleeding in November, 1920 for one day and again on 16-12-20. Had a fall early in November. ? Placental edge palpable. Male child born at home 20-12-20.
Prev. Pregs.- 1st - 7th = F.T., normal, alive (last in 1919).

782. W.R. Mother = Negative (3-5-). 22-12-20.

1st Preg. Married. Age 20.
L.P. end June, 1920. Attended Antenatal Disp. 17-12-20 - varicose veins both legs. Child born 19-1-21, male, weight 7½ lbs.
24-2-22 - Both mother and child well - child now aged 13 months -
W.R. Mother = Negative (3-5-). 24-2-22.
Child = Negative (3-5-). 24-2-22.

783. W.R. Mother = Strongly Positive (3+5+).22-12-20.
Child = Strongly Positive (3+5+).22-12-20.

12th Preg. Single. Age 42.
L. P. March, 1920. Patient was well throughout pregnancy. Normal labour - child born 16-12-20, Female, weight 7¼ lbs. Placenta - wt. 1 lb. expelled sponatneously: membranes complete. Dismissed 25-12-20, weight 7 lbs.
23-2-21 - Home visited - Both mother and child said to be attending the Central Disp. Baby seems fairly well. 18-11-21 - Visited - baby very well - never any illness but chicken-pox. 22-2-22 - Visited - Child very ill with Pneumonia and is at present in R.H.S.C.
Previous Pregs.- All previous pregnancies normal except one - a breech - all alive, F.T. (last in 1918). ? one abortion in 1910: P.P.H. after birth of third child.

784. W.R. Mother = Negative (3-5-). 22-12-20.
Child = Negative (3-5-). 22-12-20.

2nd Preg. Single. Age 26.
L.P. 1st week March, 1920. Normal pregnancy and labour - Child born 16-12-20 - male, weight 9 lbs. Dismissed 27-12-20. Mother had influenza and bronchitis in 1918. The baby died at the age of three weeks of ? gastro-enteritis.
Previous pregnancy was CH.clz. & Forceps (Sept.1912).

Case No.

785. W.R. Mother = Negative (3-5-). 22-12-20.
Child = Negative (3-5-). 22-12-20.

2nd Preg. Married. Age 32.
L.P. 2-3-20. Well through pregnancy. Forceps applied unsuccessfully by doctor outside first eight hours of labour - spontaneous delivery one hour after admission (9 hours labour in all). Child born 14-12-20 - absence of both parietal bones, slight talipes calcaneous varus of right foot - child alive when born - male, weight 6¾ lbs., but lived for a short time only. R.P. P.M.
Previous pregnancy = Normal, F.T., alive (1915). Mother had endometritis previous to second pregnancy - otherwise healthy.

786. W.R. Mother = Strongly Positive (3+5+). 28-12-20.
Child = Strongly Positive (3+5+). 22-12-20.

4th Preg. Married. Age 29.
L.P. ? Normal pregnancy and labour - Child born 17-12-20, male, weight 10 lbs. Dismissed 27-12-20, weight 8¾ lbs. Child died in R.H.S.C. about 9-2-21: No trace of mother.
Previous pregs.- 1st = F.T., S.B., normal: 2nd = F.T., living, normal: 3rd = F.T., living, normal (1918).

787. W.R. Mother = Negative (3-5-). 22-12-20.
Child = Negative (3-5-). 22-12-20.

3rd Preg. Married. Age 22.
L.P. 16-3-20. Patient was well throughout pregnancy: Normal labour (18 hours) - Child born 16-12-20, Female, weight 7¾ lbs. Dismissed 29-12-20, weight 7¼ lbs. No trace after dismissal from hospital.
Prev. Pregs.- 1st and 2nd (Sept., 1919) = normal, F.T., alive. Had Pleurisy in 1915.

788. W.R. Mother = Negative (3-5-). 22-12-20.

8th Preg. Married. Age 34.
L.P. 9-9-20. Incomplete Abortion. Admitted 16-12-20 - severe haemorrhage (possibly subsequent to shock) six weeks before admission - clots passed - continuous but not severe bleeding since then but profuse on 15-12-20 - masses of clot passed: Uterus about two months size: Curettage. Dismissed 22-12-20.
Prev. Pregs. - All F.T., normal, alive.

Case No.

789. W.R. Mother = Negative (3-5-). 28-12-20.
Child = Negative (3-5-). 22-12-20.

1st Preg. Single. Age 20.
L.P. early March, 1920. Normal pregnancy and labour. Child born 17-12-20, Female, weight 7½ lbs. Dismissed 27-12-20, weight 7½ lbs. Child died 22-11-21 when aged 11 months of Cerebral Meningitis.

790. W.R. Mother = Negative (3-5-). 28-12-20.
Child = Negative (3-5-). 22-12-20.

4th Preg. Married. Age 27.
L.P. middle March, 1920. Normal pregnancy and labour. Child born 18-12-20 - male, weight 8½ lbs. Dismissed 27-12-20, weight 7¾ lbs. No trace of mother and child since dismissal.
Prev. Pregs.- 1st - 3rd (Aug., 1918)= F.T., normal, living.

791. W.R. Mother = Negative (3-5-). 28-12-20.
Child = Negative (3-5-). 17-12-20.

2nd Preg. Married. Age 23.
L.P. Amenorrhoea since last pregnancy. B.B.A. - child born 17-12-20, male, weight 6½ lbs. Dismissed 27-12-20, weight 6 lbs. 2 ozs. 17-2-22 - Child alive and well - now aged 14 months and no illness so far.
Previous pregnancy = Normal, F.T., living (July, 1919).

792. W.R. Mother = Negative (3-5-). 28-12-20.
Child = Negative (3-5-). 22-12-20.

2nd Preg. Married. Age 23.
L.P. March, 1920. Normal pregnancy and labour - child born 13-12-20, Female, weight 8½ lbs. Dismissed 25-12-20, weight 8 lbs. No trace since dismissal.
Previous pregnancy = normal (23-4-18).

Case No.

793. W.R. Mother = Negative (3-5-). 28-12-20.
Child = Negative (3-5-). 17-12-20.

5th Preg. Married. Age 31.
L.P. 12-3-20. (Jacksonian) Epilepsy - 3 fits during pregnancy. Normal labour - severe fits - child born 13-12-20, male, weight 8½ lbs. Dismissed 22-12-20, weight 8½ lbs. No trace since dismissal.
Prev. Pregs.- 1st = F.T., forceps: 2nd and 3rd = miscarriages (1918): 4th = F.T., Forceps, (March, 1919): Subject to fits since her marriage (said to be of Jacksonian type). Uterine operation 1918.

794. W.R. Mother = Negative (3-5-). 22-12-20.
Child = Negative (3-5-). 22-12-20.

1st Pregnancy. Single. Age 20.
L.P. 3-3-20. Normal pregnancy and labour - child born 17-12-20, male, weight 7 lbs. Dismissed 27-12-20, weight 6¾ lbs. R.P. Mother healthy but had nasal catarrh during pregnancy: Patient's mother died of Bright's disease. No trace of mother and child since dismissal.

795. W.R. Mother = Negative (3-5-). 22-12-20.
Child = Negative (3-5-). 22-12-20.

1st Pregnancy. Single. Age 28.
L.P. 21-2-20. Normal pregnancy. Child born 18-12-20, Female, weight 8½ lbs. Flat pelvis (Diag. Conj. = 4¼" - True Conj. = 3½" -.). Breech presentation - perforation of after-coming head after over 24 hours labour. Ragged membranes. P.M. Mother had Scarlet Fever four years before admission to G.R.M.H.- otherwise healthy.

796. W.R. Mother = Strongly Positive (3+5+). 28-12-20.
Child = Strongly Positive (3+5+). 22-12-20.

9th Preg. Married. Age 35.
L.P. March, 1920. Well throughout except for Bronchitis. Normal labour - child born 19-12-20, Female, weight 7¼ lbs. Dismissed 29-12-20, weight 7½ lbs. When child was about one month old blood was tested at R.H.S.C. & found to be negative. 4-2-22 - Both mother and child well - baby now aged 14 months - W.R. Mother = Str. Positive. 4-2-22.
Prev. Pregs.- 3 S.B., normal: 5 living - all normal deliveries but one = CH.clz.(Hare-lip,&c.)

Case No.

797. W.R. Mother = Negative (3-5-). 28-12-20.
Child = Negative (3-5-). 22-12-20.

1st Preg. Single. Age 23.
L.P. end March, 1920. Excessive sickness - vomiting continuous more or less throughout pregnancy. Child born 19-12-20, male, weight 8 lbs. Dismissed 3-1-21, weight 8½ lbs. 21:2:22 - Both mother and child known to be well - child now 14 months old and never any illness.

798. W.R. Mother = Negative (3-5-). 22-12-20.
Child = Negative (3-5-). 22-12-20.

1st Preg. Married. Age 22.
L.P. 21-3-20. Patient was well throughout the pregnancy except for varicose veins. Admitted to Antenatal Dept. 14-12-20 - Normal labour - child born 19-12-20 - Female, weight 8 lbs., alive: R.P. Febrile puerperium: Dismissed 30-12-20. Child was known to be alive and well when aged three months but no trace afterwards.

799. W.R. Mother = Negative (3-5-). 28-12-20.
Child = Negative (3-5-). 22-12-20.

6th Preg. Married. Age 37.
L.P. March, 1920. General weakness, Vomiting and faintness persisted throughout pregnancy. Patient appeared healthy, however. Child born 19-12-20, Female, weight 8¼ lbs. Dismissed 29-12-20, weight 8½ lbs. 23-2-22 - Child now aged 14 months - at present has Bronchitis and three months ago had congestion of lungs.
Previous Pregs.- 1st - 5th = F.T. normal labours, living (last in 1917): Was well with first three pregnancies, but with last three had excessive sickness and vomiting, and pains in legs. Was in G.R.I. with Bright's Disease eight months after third child was born.

Case No.

800. W.R. Mother = Negative (3-5-). 22-12-20.
Child = Negative (3-5-). 22-12-20.

1st Preg. Single. Age 24.
L.P. April, 1920. Normal pregnancy and labour - child born 19-12-20 - Female, weight 6 lbs. (premature). Dismissed 28-12-20, weight 7 lbs. Patient has occasional bronchitis - her father is consumptive. 25-2-22 - Both well - Child now aged 14 months; she is said to have a weak chest. -
W.R. Mother = Negative (3-5-). 22-12-20.
Child = Negative (3-5-). 22-12-20.

801. W.R. Mother = Negative (3-5-). 22-12-20.

3rd Preg. Married. Age 36.
L.P. ? Admitted 14-12-20 - Contracted Pelvis (? conjugates). Caesarean Section - child born 14-12-20, Female, alive, weight 7 lbs. Child died 9-1-21: P.M. Mother dismissed 22-1-21.

802. W.R. Mother = Negative (3-5-). 28-12-20.
Child = Negative (3-5-). 22-12-20.

1st Pregnancy. Married. Age 26.
L.P. 11-3-20. Normal pregnancy and labour: R.P. - Child born 20-12-20, Female, weight 7 lbs. Dismissed 30-12-20, weight 7 lbs. 1-3-22 - Child now aged 14 months and she is said to be very well.

803. W.R. Mother = Negative (3-5-). 22-12-20.

1st Preg. Married. Age 26.
L.P. 29-2-20. Patient was well throughout her pregnancy. Labour had been in progress 24 hours when case first seen outside - face presenting: Admitted 11-12-20 after 26 hours labour - head on perineum - face presenting - forceps delivery. Child born 11-12-20, Female, weight 7 lbs., alive: Dismissed 20-12-20. No trace since dismissal.

Case No.

804. W.R. Mother = Negative (3-5-).

1st Pregnancy. Married. Age 29.
L.P. 26-3-20. Contracted Pelvis - Admitted to Antenatal Dept. 16-12-20. Pelvis (Diag. Conj. = 2¾", True Conj. = 2")- flattened left sacral bay. Head floating above brim, marked overlapping. Caesarean Section - Child born 23-1-21 - male, weight 8¾ lbs., alive. Mother has deformities of limbs: no albuminuria. Dismissed 18-2-21.
21-2-22 - Child now aged 13 months and is said to be very well: never any illness.

805. W.R. Mother = Negative (3-5-). 22-12-20.
Child = Negative (3-5-). 22-12-20.

1st Preg. Married. Age 28.
L.P. 18-3-20. Admitted to Antenatal Dept. 16-12-20 - Cardiac. Patient has felt better and stronger during pregnancy than before: slight enlargement of heart to left: pre-systolic and systolic murmur at mitral: roomy pelvis - Child born 21-12-20, Female, weight 7½ lbs. R.P. Dismissed 30-12-20, weight 7½ lbs. Mother had acute rheumatism at 11 and 22 years of age - with occasional pain at odd times since.
23-2-22 - Child now aged 14 months and is said to be a very healthy child.

806. W.R. Mother = Negative (3-5-). 22-12-20.

1st Preg. Single. Age 24.
L.P. March, 1920. Patient was well throughout pregnancy. Generally Contracted Pelvis (Diag. Conj. = 4" , True Conj. = 3¼") - Flat. Slight tibial curvature present. Mid Forceps - R.P. Child born 13-12-20 - Female, weight 8 lbs., dead - Slightly febrile puerperium. Mother dismissed 30-12-20.

Case No.

807. W.R. Mother = Negative (3-5-). 22-12-20.

7th Preg. Married. Age 33.
L.P. 25-7-20. Sickness and vomiting throughout present pregnancy. Strain just before onset of labour - Foetus expelled 18-12-20 - incomplete (6 months) miscarriage - placenta adherent - some P.P.H. Placenta removed digitally.
Previous Pregs.- 1st - 6th = all F.T., normal, alive except one miscarriage at three months (1907). The 6th child was born in 1917. Patient has occasional slight lumbago and cough.

808. W.R. Mother = Negative (3-5-). 22-12-20.

3rd Preg. Married. Age 20.
L.P. Amenorrhoea since last pregnancy. Admitted to Antenatal Dept. 18-12-20 - Hyperemesis gravidarum - vomited from earliest possible date in pregnancy and was unable to retain any food for last week before admission. Pale: sunken eyes: some emaciation. Uterus about 2½ months size. Dismissed 28-12-20.
Prev. Pregs.- 1st = 5 months abortion (Feby., 1919): 2nd = normal, F.T., alive (Feby.,1920).

809. W.R. Mother = Positive ($3^{+}5^{\mp}$). 22-12-20.

5th Preg. Married. Age 32.
L.P. 12-7-20. Admitted Antenatal Dept. 13-12-20 - Cardiac - haemoptysis before admission - had threatened abortion at 2½ months and was 5 weeks in bed - very sick all the time - no food retained. Teacupful of blood brought up (? coughed ? vomited) four times. Induction - delivered 24-12-20. Heart enlarged to right - presystolic and systolic murmurs at apex - marked irregularity - apical thrill. Dilatation less on dismissal (5-1-21) but murmurs still present. Patient was in Western Infy. on 23-3-21 - said to have brain and heart affected and was not expected to recover.
History of previous pregnancies not recorded.

Case No.

810. W.R. Mother = Negative (3-5-). 28-12-20.
Child = Negative (3-5-). 22-12-20.

1st Preg. Single. Age 17.
L.P. ? April, 1920. Normal pregnancy and labour - child born 21-12-20, male, weight 6¼ lbs. Dismissed 30-12-20, weight 6¾ lbs.
25-2-22 - Child now aged 14 months - has a rash suggesting 'milia' on face. Mother states that it comes on face and back from time to time.
W.R. Mother = D. Neg. (3+5-). 25-2-22.
Child = Negative (3-5-). 25-2-22.

811. W.R. Mother = Negative (3-5-). 28-12-20.
Child = Negative (3-5-). 22-12-20.

1st Preg. Married. Age 20.
L.P. 1-4-20. Normal pregnancy and labour - child born 21-12-20, male, weight 7 lbs. Dismissed 29-12-20, weight 8½ lbs. The baby was known to be alive and well when aged six months but there is no further trace.

812. W.R. Mother = Negative (3-5-). 22-12-20.

1st Preg. Single. Age 23.
L.P.? (about 6 months). Lobar Pneumonia. Induction - died undelivered 23-12-20 (3 days after admission). P.M.- Lobar pneumonia right base and commencing lobar pneumonia of left. Leucocytes (22-12-20) = 23,000, 78% polymorphs. No history of definite illness previously, but delicate as a child and had scarlet fever.

813. W.R. Mother = Negative (3-5-). 22-12-20.

5th Preg. Married. Age 30.
L.P. 8-10-20. Admitted to Antenatal Dept. 15-12-20 - Hyperemesis gravidarum. Was well till one week before admission when she began to have severe sickness and persistent vomiting accompanied by pain in the stomach - says she could retain nothing. Pale and ill looking: thin: tongue dirty and rather dry: some tenderness left side of abdomen - no rigidity over stomach or duodenum. Heart and lungs normal: (? urine): no visible enlargement of abdomen. ? hernia left side. Dismissed 23-12-20.
Previous Pregs.- 1st, 2nd & 3rd Pregs. = normal, F.T., living - CH.clz. & Forceps: 4th = miscarriage at 7 mos. - Antepartum Haemorrhage - macerated foetus (G.R.M.H. - 3-2-20).

Case No.

814. W.R. Mother = Negative (3-5-). 22-12-20.

4th Preg. Married. Age 26.
L.P. 4-4-20. Admitted to Antenatal Dept. 20-12-20 - Albuminuria: premature labour - macerated foetus. Patient was well till 2-3 weeks before admission when she noticed swelling of legs. Occasional headaches. Pale: oedema of legs and abdomen - uterus about 8½ months size - some hydrammios. Foetus expelled 21-12-20, male, weight 7 lbs. Placenta weighed 3¼ lbs.
Prev. Pregs.- 1st = F.T., normal, living, CH.clz. & Instrs.: 2nd = F.T., CH.clz. & instrs.: 3rd = F.T., S.B., CH.clz. & Instrs. (13-12-19).

815. W.R. Mother = Negative (3-5-). 22-12-20.

3rd Preg. Married. Age 27.
Amenorrhoea since before last pregnancy. Bleeding and pain began morning of admission (13-12-20) - pale but otherwise healthy looking: hysterical. While on slab foetus and large quantity of clot expelled (foetus about four months). Placenta retained. Incomplete Abortion - curettage, douched and swabbed.
History of previous pregnancies not recorded.

816. W.R. Mother = Negative (3=5-). 28-12-20.
Child = Negative (3-5-). 22-12-20.

1st Preg. Single. Age 17.
L.P. 29-3-20. Normal pregnancy and labour. Patient is small but healthy looking. Child born 20-12-20, female, weight 7 lbs. Dismissed 30-12-20, weight 6 lbs.
Child died 16-8-21 - convulsions.

817. W.R. Mother = Negative (3=5-).

7th Preg. Married. Age 39.
L.P. end August, 1920. Incomplete Abortion. Patient was well till 12-12-20 when waters came away - no pain but bleeding followed: Foetus and large quantity of clot passed - bleeding continued till admission on 15-12-20. Some anaemia but otherwise healthy. Digital curettage: swabbed.
Prev. Pregs.- 1st = Misc. at 2½-3 mos.: 2nd = F.T., normal, living: 3rd = F.T., normal, living: 4th = abor. at 3 mos. 5th & 6th = F.T.

Case No.

818. W.R. Mother = Negative (3-5-). 22-12-20.

9th Preg. Married. Age 25.
L.P. 1-8-20. Incomplete Abortion - Patient has not felt well since 10-12-20 - yellowish discharge and pain. On 17-12-20 pain became severe and foetus was expelled: placenta retained. Admitted 20-12-20 - curetted and douched. Dismissed 30-12-20. Menstruation irregular - sometimes every 14 days, sometimes every 21 days - profuse flow: marked left sided pain during menstruation.
Prev. Pregs.- 1st = F.T., living, Chloroform & Instrs.: 2nd, 3rd, 4th, 5th, 6th and 7th (19-11-16)= normal, F.T., living: 8th = miscarriage at 5 months (Novr., 1919):- was in Samaritan three years ago with chronic metritis and torn perineum.

819. W.R. Mother = Negative (3-5-). 22-12-20.

Not pregnant. Married. Age 41.
Menstruation irregular since last child was born (July, 1920) - menorrhagia and metrorrhagia -. Admitted 15-12-20 as an ? incomplete abortion or ectopic gestation - curetted - Chronic Metritis -. Small pale woman: thickening on left side due to enlarged ovary: tubes normal. Dismissed 22-12-20.
Prev. Pregs.- 1st = F.T., S.B., CH.clz. & instrs.: 2nd = F.T., living,normal: 3rd = F.T., living, normal: 4th = (6 mos.) twins, S.B.: 5th = F.T., living, CH.clz. & instrs.: 6th = F.T., living, normal: 7th = F.T., living, normal: 8th = F.T., living, normal: 9th = miscarriage at 3½ months (July, 1919): 10th = F.T., S.B., normal (28-7-20). General health good.

820. W.R. Mother = Negative (3-5-). 22-12-20.

1stPreg. Single. Age 19.
L.P. 25-4-20. Admitted Antenatal Dept. 19-12-20 and dismissed 23-12-20. Readmitted 19-1-21 - Contracted Pelvis (Diag. Conj. = 4¼" -: True Conj. = 3½" -). Caesarean Section - not sterilised. Small woman - marked rickets of legs. Child born alive - Female, 19-1-21. Dismissed 14-3-21.
25-2-22 - Both mother and child well - child now aged 13 months.
W.R. Mother = Neg. Child = Neg. (25-2-22).

Case No.

821. W.R. Mother = Strongly Positive (3+5+).22-12-20.

1st Preg. Single. Age 20.
L.P. end July, 1920.
Complete miscarriage at about 4½ months.
Mother healthy. No trace after 16-2-21.

822. W.R. Mother = Negative (3-5-). 22-12-20.

1st Preg. Single. Age 24.
L.P. 2nd week June, 1920. Patient felt well till 17-12-20 when she fell and bruised her abdomen - since then she has had pain. Admitted Antenatal Dept. 20-12-20 and was dismissed 23-12-20. Readmitted 5-3-21 - child born 6-3-21 - male, weight 6¾ lbs. Dismissed 18-3-21, weight 6 lbs.
25-11-21 - Baby now aged 11 months - said to be in very good health.

823. W.R. Mother = Str. Pos. (3+5+). 28-12-20.
Child = Str. Pos. (3+5+). 22-12-20.

3rd Preg. Single. Age 29.
L.P. 8-3-20 - Well throughout pregnancy except for "heart burn". Child born 20-12-20 - male, weight 8½ lbs. Dismissed 30-12-20, weight 9 lbs. 13-1-21 - Home visiting - Child not thriving - has rash and discharge from one eye. 18-11-21 - Baby died 3-8-21 - 'Enteritis'.

824. W.R. Mother = Doubt. Positive. 28-12-20.

1st Preg. Married. Age 18.
L.P. March, 1920. Normal pregnancy and labour - child born 19-12-20, Female, weight 6½ lbs. Dismissed 29-12-20, weight 7½ lbs.
Child died in Ruchhill Hosp. 19-5-21 - convulsions and whooping-cough.

Case No.

825. W.R. Mother = Negative (3-5-). 28-12-20.

2nd Preg. Married. Age 22.
L.P. March, 1920. Patient was well throughout pregnancy except for pain in left side. Normal labour - child born 19-12-20, female, weight 6¼ lbs. Dismissed 29-12-20, weight 6½ lbs. 25-5-22 - Child now aged 17 months - is in Stobhill hosp. with Measles and Pneumonia.
1st pregnancy = F.T., normal (1-2-19).

826. W.R. Mother = Negative (3-5-). 28-12-20.

4th Preg. Married. Age 28.
L.P. end March or early April, 1920. Protracted labour (about 48 hours). Cicatrised cervix. Forceps delivery - Twins born 17-12-20 - 1st = Vertex, S.B., Female, weight 4½ lbs.: 2nd = Breech, alive, Female, weight 8 lbs., died 25-12-20 of Meningitis.
Prev. Pregs.- 1st = F.T., living, CH.clz. & Instrs.: 2nd = F.T., living, CH.clz. & Instrs.: 3rd = F.T., living, normal delivery (April, 1918): Vaginal operation for uterine prolapse in Decr., 1918.

827. W.R. Mother = Negative (3-5-). 28-12-20.

? Preg. Married. Age 47.
L.P. 13-11-20. Fibrosis Uteri. Hysterectomy 15-12-20. History of irregular menstruation, menorrhagia and ? metrorrhagia.
Prev. Pregs.- Has had several living children - the last seven years ago: also 5 abortions.

828. W.R. Mother = Negative (3-5-). 28-12-20.

1st Preg. Married. Age 18.
L.P. middle April, 1920. Attended Antenatal Disp. 24-12-20 - abdominal pain. Looked healthy.

Case No.

829. W.R. Mother = Negative (3-5-). 28-12-20.

6th Preg. Married. Age 26.
L.P. end April, 1920. Attended Antenatal Disp. 24-12-20 - pain in back and legs: severe pain right side: loaded rectum.
Prev. Pregs.- 1st - 5th = F.T., normal, alive - last child was born Octr., 1919 and died Decr., 1920. All others still alive.

830. W.R. Mother = Negative (3-5-). 28-12-20.

2nd Preg. Married. Age 25.
L.P. 23-4-20. Attended Antenatal Disp. 24-12-20 - abdominal pain and constipation. Child born in hospital 8-2-21 - female, weight 8 lbs. Dismissed 17-2-21.
22-2-22 - Child now over one year old and is said to be very well - her only illness having been influenza (slight).
1st Preg.- Normal, F.T. (Octr., 1919).

831. W.R. Mother = Negative (3-5-). 28-12-20.
Child = Negative (3-5-). 28-12-20.

1st Preg. Single. Age 26.
L.P. Aug., 1920. Normal pregnancy - Twins born 25-12-20 - 1st macerated, vertex: 2nd = breech (premature) not macerated (Inevitable 5 months miscarriage).

832. W.R. Mother = Negative (3-5-). 28-12-20.

3rd Preg. Married. Age 36.
L.P. 28-10-20. Admitted 25-12-20 - Bleeding began one week before admission (slight). Ceased but on day of admission large clots were passed (Haemorrhage on first occasion began after heavy washing). Incomplete Abortion - curetted and swabbed. Dismissed 30-12-20.
Prev. Pregs.- 1st = CH.clz. & Forceps, F.T., alive: 2nd = normal, F.T., Twins (Jany.1914) - one survived three days only.

Case No.

833. W.R. Mother = Negative (3-5-). 28-12-20.

4th Preg. Married. Age 39.
L.P. March, 1920. Normal pregnancy. Forceps for delayed second stage. Narrow pelvic outlet. Child born 26-12-20, male, weight 11¾ lbs. Febrile puerperium. Dismissed 2-1-21, weight 11¾ lbs.
25-5-22 - Both mother and child well - child now aged 17 months.
W.R. Mother = Negative (3-5-). 25-5-22.
Child = Negative (3-5-). 25-5-22.
Prev. Pregs.- 1st - 3rd = All Chloroform and Forceps, alive (large children).

834. W.R. Mother = Doubtfully Neg. 28-12-20.
Child = Negative (3-5-). 28-12-20.

1st Preg. Single. Age 26.
L.P. 1st April, 1921. Sickness and headache for (? last) 4 months: marked swelling of feet, face and hands for one week: Scanty urine. Normal labour: R.P. Child born 24-12-20 - female, weight 6½ lbs., alive. Dismissed 3-1-21, ? weight. Mother healthy but had influenza two years ago. Albuminuria.

835. W.R. Mother = Negative (3-5-). 30-12-20.
Child = Negative (3-5-). 28-12-20.

11th Preg. Married. Age 44.
L.P. March, 1920. Patient has had " weak turns" since beginning of pregnancy - sent to hospital as eclamptic but history more like that of epilepsy. No oedema: looks healthy: no albumen. Child born 11-1-21 - female, weight 11½ lbs., alive. Dismissed 24-1-21, weight 10½ lbs.
18-5-22 - Child now aged 16 months and very well. Mother still taking fits.
W.R. Mother = Negative (3-5-). 18-5-22.
Child = Negative (3-5-). 18-5-22.
Prev. Pregs.- All labours normal, F.T., alive, except 4th which was a forceps delivery and two pregnanices about 1910 which ended in abortion at 2-3 months. Puerperal Septicaemia in 1911 after 8th confinement. General health good.

Case No.

836. W.R. Mother = Negative (3-5-). 28-12-20.

11th Preg. Married. Age 35.
L.P. end March, 1920. Normal pregnancy and eight hours labour. Failed forceps before admission. Spontaneous delivery after admission. R.P. Child born 23-12-20, Female, weight 10 lbs. S.B. P.M.
Prev. Pregs.- 3rd, 4th, 8th = F.T., alive, forceps: all others normal, alive (last in June, 1918). Mother healthy.

837. W.R. Mother = Negative (3-5-). 30-12-20.
Child = Negative (3-5-). 30-12-20.

2nd Preg. Married. Age 22.
L.P. 2-3-20. Has been attending Dispensary for " swelling of womb" (oedema of vulva) - well otherwise. Normal labour - child born 28-12-20, Female, weight 8½ lbs., alive. Dismissed 7-1-21.
4-2-22 - Both mother and baby look very well - baby now aged 14 months.
W.R. Mother = Neg. (3 tr. 5-). 4-2-22.
Child = Neg. (3-5-). 4-2-22.
1st Preg. = Abortion at three months (curetted thereafter) Feby., 1920.

838. W.R. Mother = Negative (3-5-). 30-12-20.

1st Preg. Married. Age 33.
L.P. May, 1920. Patient was well till four weeks before admission when she noticed swelling of feet: this increased and during last four days there was also swelling of face, arms and legs (marked oedema). Had several fits (eclamptic) before admission on 25-12-20. Uterus about seven months size: marked generalised oedema. Two days after admission patient became difficult to control - Child born 1-1-21, Female, weight 3½ lbs. macerated. Mother developed puerperal insanity and was transferred to Duke St. Hospital 4-1-21. Previous health good: no mental strain.

Case No.

839. W.R. Mother = Strongly Positive (3+5+).30-12-20.
Child = Strongly Positive (3+5+).30-12-20.

1st Preg. Single. Age 20.
L.P. uncertain. Patient was well throughout pregnancy. She has external strabismus and a suggestion of rhagades round mouth. Normal (10 hours) labour. Child born 28-12-20, Female, weight 6 lbs. Dismissed 7-1-21, weight 6 lbs. Baby died about 15-3-21.

840. W.R. Mother = Negative (3=5-). 30-12-20.

1st Preg. Single. Age 20.
L.P. 31-3-20. Normal pregnancy and labour. Child born 28-12-20, Female, weight 6¾ lbs. Dismissed 8-1-21, weight 7 lbs. 2 ozs.
25-2-22 - Both well - child now aged 14 months:
W.R. Mother = Negative (3-5-). 25-2-22.
Child = Negative (3-5-). 25-2-22.

841. W.R. Mother = Negative (3-5-). 12-1-21.

1st Preg. Married. Age 21.
L.P. ? July, 1920. Attended Antenatal Disp. 7-1-21 - profuse yellow (?gonorrhoeal) discharge and frequent micturition. Slightly contracted pelvis - (Diag. Conj. = 4"4 True Conj. = 3¼"4). Dismissed from hospital and readmitted 29-3-21 - Caesarean Section 2-4-21 - Child born, weight 7½ lbs., female, mature. Patient sterilised. Dismissed 22-4-21, weight 5½ lbs. 24-2-22 - Child and mother both well - child now aged 11 months - W.R. Child = Negative (3-5-).

842. W.R. Mother = Negative (3-5-). 12-1-21.

4th Preg. Married. Age 32.
L.P. 1-9-20. Attended Antenatal Dispensary 7-1-21 - slight leucorrhoea - otherwise healthy.
Prev. Pregs.- 1st - 3rd = Normal, F.T., alive (last three years ago).

Case No.

843. W.R. Mother = Strongly Positive (3+5+).12-1-21.

7th Preg. Married. Age 31.
L.P. 2-5-20. Patient was well throughout except for constipation. Attended Antenatal Dispensary 7-1-21. Contracted Pelvis (Diag. Conj. = 4½", True Conj. = 3¾")- laterally contracted on right side. Admitted to hospital and child born 13-1-21, male, premature, weight 4½ lbs. Baby died 29-1-21.
W.R. Mother = Strongly Positive (3+5+).24-2-22.
Previous Pregs. - 3 children (all difficult labours - instrs.) born alive: 3 miscarriages at 3½, 3 and 2 months. The last pregnancy (2 years ago) was a miscarriage at 3 months. Patient had rheumatic fever at 23 years of age and influenza two years ago.

844. W.R. Mother = Negative (3-5-). 12-1-21.

4th Preg. Married. Age 30.
L.P. early May, 1920. Attended Antenatal Disp. 7-1-21 - pain in chest. Contracted Pelvis (Diag. Conj. = 4¼" +, True Conj. = 3½" +). Male child born at home 28-3-21.
24-5-22 - Child now aged 14 months an very well-
W.R. Mother = Negative (3-5-). 24-5-22.
Child = Negative (3-5-). 24-5-22.

845. W.R. Mother = Negative (3-5-). 12-1-21.

1st Preg. Married. Age 19.
L.P. 17-9-20. Attended Antenatal Disp. 7-1-21 - slight abdominal pain. Swab from cervix - Coliform and diphtheroid bacilli and streptococci. Admitted 21-6-21 at 2-30 a.m. in labour - child born 22-6-21, female, alive, weight 7¾ lbs. Normal labour: R.P. Dismissed 1-7-21, weight 7½ lbs.

846. W.R. Mother = Negative (3-5-). 12-1-21.

6th Preg. Married. Age 30.
L.P. 12-11-20. Attended Antenatal Disp. 7-1-21 - pain left side umbilicus - profuse yellow discharge: constipated: stomach disturbed: Rt. ovary diseased. Pale and anaemic.
Prev. Pregs.- Four children born F.T., normal, alive - last 2 years ago. Had premature twins (8 months) which lived two days.

Case No.

847. W.R. Mother = Negative (3-5-). 12-1-21.

1st Preg. Single. Age 19.
L.P. early May, 1920. Attended Antenatal Dispensary 7-1-21 - Pale but healthy.

848. W.R. Mother = Negative (3-5-). 12-1-21.

3rd Preg. Married. Age 30.
L.P. April, 1920. Attended Antenatal Disp. 7-1-21 - excessive vomiting: feels weak: is very pale and thin.
Prev. Pregs.- 1st and 2nd = normal (precipitate) F.T., alive (last in Novr., 1919).

849. W.R. Mother = Negative (3-5-). 12-1-21.
Child = Negative (3-5-). 12-1-21.

1st Preg. Single. Age 27.
L.P. uncertain. Normal pregnancy and labour. R.P. Child born 6-1-21, Female, weight 7 lbs., alive. Dismissed 18-1-21.
9-3-22 - Mother and child both alive and well - child now aged 14 months.

850. W.R. Mother = Negative (3-5-). 12-1-21.

6th Preg. Married. Age 27.
L.P. July, 1920. Constant very slight discharge since early Novr., 1920. Large clots passed 8-1-21 then had severe cramping pain for 14 days. Incomplete Abortion - curettage 9-1-21.
Prev. Pregs. 4 normal, F.T., alive (last in May, 1919): one abortion at 3½ months (was the result of a fall in July, 1920). Healthy woman, but husband epileptic - committed suicide three months ago. Woman has had some anaemia for two years.

Case No.

851. W.R. Mother = Negative (3-5-). 12-1-21.

2nd Preg. Married. Age 26.
L.P. 1st week May, 1920. ? Eclampsia. ? Hysteria. Admitted to Antenatal Dept. 30-12-20 - has always had headaches during this pregnancy and at three months had severe sickness and vomiting: was in Kilmarnoc Infirmary for six weeks (Septr. - Octr.) on account of " swollen feet and kidney trouble" . While there she had a fit (?) and complained of severe headaches. There was a fit (?) just before admission on 30-12-20. Patient looked healthy when admitted to G.R.M.H.: no oedema: occasional paralysis of external rectus: occasional vomiting. Dismissed undelivered 15-1-21.
Previous pregs.- 1st = ?F.T., S.B., Chloroform (1910): Had acute rheumatism 12 years ago.

852. W.R. Mother = Negative (3-5-). 12-1-21.
Child = Negative (3-5-). 12-1-21.

1st Preg. Married. Age 25.
L.P. 28-4-20. Albuminuria - Patient was well till one week before admission when feet and legs became swollen. Sudden oedema of left labium on day of admission (1-1-21). Intense oedema of legs and labia and marked puffiness of face - slight oedema of lungs. Child born 10-1-21, Female, weight 6¼ lbs., ? premature, alive, but died 13-1-21. Mother died 17-1-21. P.M.- Generalised peritonitis: sloughing of the labia: pus in abdomen and pelvis: general septicaemia: subacute nephritis. (Patient was in G.R.I. in 1915 with nephritis.

853. W.R. Mother = Negative (3-5-). 21-1-21.
Child = Negative (3-5-). 12-1-21.

2nd Preg. Married. Age 22.
L.P. ? March, 1920. Admitted 8-1-21 - Patient was well till three weeks before admission when swelling of feet was noted. No headache till after admission. Child born 8-1-21 (8 hours labour)- Female, weight 7½ lbs. Puerperal eclampsia. Dismissed 19-1-21, weight 6½ lbs. 22-5-22 - Both mother and child well - child now aged 16 months - W.R. Mother = Neg. Child = Neg. (22-5-22).
Prev. Preg. = normal, F.T., alive (May, 1919).

Case No.

854. W.R. Mother = Negative (3-5-). 12-1-21.
Child = Negative (3-5-). 12-1-21.

1st Preg. Single. Age 22.
L.P. March, 1920. Some vomiting in early and in later months but well otherwise. Normal (12 hours) labour: Vaginal lacerations: Child born 6-1-21, Female, weight 7½ lbs. Dismissed 15-1-21, weight 7½ lbs.
24-2-22 - Both mother and child well - child now aged 13 months.

855. W.R. Mother = Negative (3-5-). 14-1-21.
Child = Negative (3-5-). 14-1-21.

1st Preg. Single. Age 22.
L.P. March, 1920. Normal pregnancy and labour - Child born 11-1-21, male, weight 8½ lbs. R.P. Dismissed 21-1-21, weight 7½ lbs.
22-2-22 - Child alive and well - now aged 13 months: never any illness.

856. W.R. Mother = Strongly Positive (3+5+).14-1-21.

1st Preg. Married. Age 19.
L.P. April, 1920. No life felt for six weeks before admission on 11-1-21. Never any bleeding but "had a difference with her husband" about six weeks before delivery. Macerated foetus (7½ months size) born 11-1-21, male, weight 3¾ lbs.
29-7-21 - Home visit paid - Patient very well - no treatment.

857. W.R. Mother = Negative (3-5-). 12-1-21.
Child = Negative (3-5-). 4-2-21.

8th Preg. Married. Age 37.
L.P. end April, 1920. Admitted to Antenatal Dept. 6-1-21 - oedema of feet for one month: Albuminuria +++. Dismissed 11-1-21 and was readmitted 28-1-21 - male child born 28-1-21, weight 8 lbs. Dismissed 10-2-21, weight 8¼ lbs. Mother's albumen = 0.3% on second admission: oedema of legs and face. The child was known to be well when three months old - no further trace.
Prev. Pregs.- 1st = Prem. (6 mos.) dead: 2nd and 3rd = F.T., living, forceps and chloroform: 4th = F.T., S.B., normal delivery: 5th = (8 mos.) spontaneous, breech, S.B.: 6th = (8 mos.) S.B., spon. (eclampsia): 7th = (8 mos.) normal, living, (Aug., 1919).

Case No.

858. W.R. Mother = Negative (3-5-). 14-1-21.
Child = Negative (3-5-). 14-1-21.

1st Preg. Single. Age 18.
L.P. April, 1920. Normal pregnancy and labour (8 hours). Child born 11-1-21, male, weight 7½ lbs. Dismissed 21-1-21, weight 7½ lbs. 25-2-22 - Both mother and child well - child now aged 13 months and never had any illness.

859. W.R. Mother = Negative (3-5-). 14-1-21.
Child = Negative (3-5-). 28-1-21.

1st Preg. Married. Age 23.
L.P. April, 1920. Admitted 11-1-21 - false labour: dismissed 13-1-21. Readmitted 24-1-21 - slightly peaked promontory - persistent occipito-posterior. Forceps - child born 25-1-21, Female, weight 6 lbs. Dismissed 4-2-wl, weight 6 lbs.
Baby died 3-3-21 - Pneumonia.

860. W.R. Mother = Neg. (3∓5-). 21-1-21.
Child = Neg. (3-5-). 18-3-21.

3rd Preg. Married. Age 24.
L.P. ? (About six months pregnant). Attended Antenatal Disp. 14-1-21. Life felt about three weeks before she attended Disp. Irregular menstruation before pregnancy. Patient took scarlet fever on 4th day of last puerperium. Admitted to Hosp. 12-3-21 - Female, weight 8¼ lbs. born 12-3-21. Normal labour: R.P. removed manually.
4-4-22 - Both moth r and baby well - baby now aged 13 months - only illness was Influenza
W.R. Mother = Negative (3-5-). 7-4-22.
Child = Negative (3-5-). 7-4-22.
Prev. Pregs.- 1st Preg. =(June, 1914) F.T., normal, alive: 2nd = normal, F.T., alive (Feby., 1920) Child died aged 3 weeks in G.R.M.H. (Mother removed to Ruchhill on 4th day of puerperium).

861. W.R. Mother = Negative (3-5-). 21-1-21.

4th Preg. Married. Age 31.
L.P. 25-9-20. Patient attended Antenatal Disp. 14-1-21 - had a fall six weeks before - now complains of pain in abdomen and back. Pale and anaemic, drowsy, but sleepless.
Prev. Pregs.- 1st - 3rd = F.T., normal, alive (last in Decr., 1919). Has had Diphtheria.

Case No.

862. W.R. Mother = Negative (3-5-). 21-1-21.

3rd Preg. Married. Age 35.
L.P. ? June, 1920. Attended Antenatal Disp. - Varicose veins: healthy. 8 months pregnant.
Previous pregs.- 1st and 2nd = F.T., normal, alive.

863. W.R. Mother = Negative (3-5-). 28-1-21.
Child = Negative (3-5-). 21-1-21.

4th Preg. Single. Age 33.
L.P. early April, 1920. Normal pregnancy and labour. Child born 20-1-21 - male, weight 10 lbs. Dismissed 28-1-21, weight 8¾ lbs. Child died 3-2-22 (aged 13 months) - 'Tubercular Peritonitis': was said to be subject to convulsion fits.
Prev. Pregs.- 1st and 2nd (Feby., 1915) = F.T., living, Chloform and Instrs. (slightly contracted pelvic outlet): 3rd = miscarriage at 6 months (1919).

864. W.R. Mother = Negative (3-5-). 28-1-21.
Child = Negative (3-5-). 21-1-21.

1st Preg. Married. Age 24.
L.P. April, 1920. Normal pregnancy and labour: R.P. Child born 19-1-21, male, weight 9¼ lbs. Dismissed 29-1-21. No further trace.

865. W.R. Mother = Neg. (3-5-). 16-10-20.
Mother = Neg. (3-5-). 28-1-21.
Child = Neg. (3-5-). 28-1-21.

5th Preg. Married. Age 35.
L.P. ? April, 1920. Varicose veins right leg - well otherwise. Child born 19-1-21, Female, weight 7 lbs. Dismissed 29-1-21.
22-2-22 - Both well - child now aged 13 mos.
Prev. Pregs.- 1st - 4th (June, 1919) = normal, F.T., alive.

Case No.

866. W.R. Mother = Negative (3-5-). 21-1-21.

3rd Preg. Married. Age 24.
L.P. ? 1st week May, 1920. Normal pregnancy. Contracted Pelvis (Diag. Conj. = 3¼", True Conj. = 2½"): narrow outlet. (Repeat) caesarean section - child born 6-1-21, male, weight 4 lbs. 9 ozs. Dismissed 7-2-21, weight 4½ lbs. Mother was sterilised: uterine wall and placenta appeared unhealthy. Child was small and was resuscitated with difficulty. No albuminuria. 25-5-22. - Both well - child now aged 16 months.
W.R. Mother = Negative (3-5-). 25-5-22.
Child = Negative (3-5-). 25-5-22.
Prev. Pregs.- 1st = ? Breech - ? craniotomy - F.T., S.B., 1916: 2nd = Caesarean Section - macerated foetus, Octr., 1919.

867. W.R. Mother = Negative (3-5-). 21-1-21.

6th Preg. Married. Age 28.
L.P. 16-10-20. Incomplete Abortion. Bleeding began ten days before admission - slight at first but continued till it became very severe five days before admission on 18-1-21 - clots passed and had pains. Curetted, swabbed.
Prev. Pregs.- 1st, 2nd and 5th = F.T., normal, alive - forceps (large children) - last in June, 1919: 3rd = Anencephalic, S.B.: one miscarriage at three months in 1916. Patient very pale - looks like a T.B. subject. Has had pleurisy several times. Diphtheria 8 years ago. Gall-stones (operation) winter of 1919-20.

868. W.R. Mother = Negative (3-5-). 21-1-21.
Child = Negative (3-5-). 21-1-21.

2nd Preg. Married. Age 29.
L.P. 18-3-20. Normal pregnancy, F.T. Child born 18-1-21, Female, weight 6¾ lbs. Dismissed 27-1-21, weight 7½ lbs. No further trace after dismissal.
Previous Pregnancy = Normal, F.T., alive (May,1918).

Case No.

869. W.R. Mother = Negative (3-5-). 21-1-21.

1st Preg. Single. Age 21.
L.P. April or May, 1920. Vomited at first - then noticed swelling of feet, legs, and face about two weeks before admission. Was sent in from Dispensary 18-1-21 - oedema of feet and ankles: albuminuria (0.05%). Pelvis contracted laterally (Diag. Conj. = 4¼" -, True Conj. = 3½" -). Caesarean Section - child born 21-2-21, female, weight 9 lbs. Dismissed 18-3-21, weight 8¼ lbs. No trace of mother and child after child one month old.

870. W.R. Mother = Negative (3-5-). 21-1-21.

1st Preg. Married. Age 22.
L.P. 8-5-21. Patient was well throughout pregnancy Admitted to Antenatal Dept. 18-1-21 - pelvis contracted anteriorly and laterally: promontory not easily palpable: Head above brim: Some overlapping laterally. Albuminuria: oedema of feet and ankles. Caesarean Section sterilised - Child born 17-2-21, male, weight 8¾ lbs. Dismissed 16-3-21, weight 8½ lbs. History of injury to pelvis through being run over two years ago. Patient had rheumatic fever ten years ago and was four months in G.R.I. Looks healthy. 24-5-22 - Mother ill - acute rheumatism - child now aged 15 months and very well - W.R. Child = Negative (3-5-).

871. W.R. Mother = Negative (3-5-). 21-1-21.
Child = Negative (3-5-). 21-1-21.

8th Preg. Married. Age 33.
L.P. March, 1920. Normal pregnancy and labour - Child born 18-1-21, female, weight 7½ lbs. Dismissed 26-1-21, weight 6½ lbs. 1-3-22. - Child alive and well - now aged 14 months and no illness so far.
Previous pregnancies.- All F.T., normal, alive - except 5th = delayed 2nd stage, CH.clz. & forceps, - last child born June, 1918.

Case No.

872. W.R. Mother = Negative (3-5-). 21-1-21.

2nd Preg. Single. Age 24.
L.P. 24-4-20. Normal pregnancy and labour. Child born 19-1-21, female, weight 7¼ lbs. Dismissed 28-1-21. 9-3-22 - Child alive and well - now aged 14 months and just recovered from Pneumonia.
1st Preg. = F.T., CH.clz. & Forceps - lived four days only(1915).

873. W.R. Mother = Negative (3-5-). 21-1-21.

3rd Preg. Married. Age 23.
L.P. Octr., 1920. Incomplete Abortion - Admitted 18-1-21 - had slight bleeding two days before admission which ceased but began again next day - twin ova passed - placenta retained. Curetted. (About three months).
Prev. Pregs.- 1st and 2nd = F.T., normal, alive (Feby., 1920). A healthy looking woman - some anaemia.

874. W.R. Mother = Negative (3-5-). 21-1-21.

1st Preg. Married. Age 23.
L.P. early May, 1920. Patient was well till three days before admission when swelling of feet noted. Admitted to Antenatal Dept. 8-1-21 - oedema of face, fingers and ankles. Albuminuria. Eclampsia - premature labour - child born 11-1-21, female, weight 5½ lbs. Dismissed 30-1-21, weight 3¾ lbs. 24-5-22 - Child now aged 16 months and both mother and child well.
W.R. Mother = Negative (3-5-). 24-5-22.
Child = Negative (3-5-). 24-5-22.

875. W.R. Mother = Negative (3-5-). 21-1-21.

2nd Preg. Single. Age 29.
L.P. ? Octr., 1920. Pains all over day before admission - severe haemorrhage - clots passed. Bleeding continued till admission on 18-1-21 - collapsed - Incomplete Abortion - curettage - placental debris removed. Uterus about three months size.
Prev. Preg.- F.T., normal, alive (Septr., 1918).

Case No.

876. W.R. Mother = Negative (3-5-). 21-1-21.
Child = Negative (3-5-). 21-1-21.

9th Preg. Married. Age 30.
L.P. 1st week April, 1920. Normal pregnancy and labour. Child born 18-1-21, female, weight 7¼ lbs. Dismissed 27-1-21, weight 6¾ lbs. No further trace.
Prev. Pregs.- All normal, F.T., alive - mother has internal squint.

877. W.R. Mother = Negative (3-5-). 21-1-21.
Child = Negative (3-5-). 21-1-21.

2nd Preg. Single. Age 23.
L.P. last week April, 1920. Normal pregnancy and twelve hours labour. Child born 18-1-21, male, weight 6¾ lbs. Dismissed 29-1-21.
23-2-22 - Baby well: never any illness - now aged 13 months.
Prev. Preg.- ? premature - live-born, spontaneous (March, 1918).

878. W.R. Mother = Negative (3-5-). 21-1-21.
Child = Negative (3-5-). 21-1-21.

1st Preg. Single. Age 19.
L.P. March, 1920. Normal pregnancy and labour - child born 18-1-21, male, weight 7½ lbs. Dismissed 28-1-21. 10-3-22 - Both mother and child alive and well - child now aged 14 months.

879. W.R. Mother = Negative (3-5-). 28-1-21.
Child = Negative (3-5-). 28-1-21.

1st Preg. Married. Age 28.
L.P. 27-4-20. (lbuminuria (++++). Face and legs swollen for about two months - under treatment an improving, but albumen persisted. On admission (16-1-21) oedema of legs and abdomen, and slightly of face - uterus about 8 months size. Half an hour's labour on 17-1-21 - female child born, weight 5½ lbs., premature - could not be resuscitated. P.M. Mother improved after delivery and was dismissed well on 9-2-21.

Case No.

880. W.R. Mother = Negative (3-5-). 28-1-21.
Child = Negative (3-5-). 21-1-21.

2nd Preg. Single. Age 24.
L.P. April, 1920. Normal pregnancy and labour. Child born 17-1-21, female, weight 7 lbs. Dismissed 26-1-21, weight 7 lbs. No further trace.
Prev. Preg. = F.T., living, normal (Septr., 1916).

881. W.R. Mother = Negative (3-5-). 28-1-21.
Child = Negative (3-5-). 28-1-21.

1st Preg. Single. Age 19.
L.P. May, 1920. Normal pregnancy and labour. Child born 16-1-21, female, weight 8 lbs. R.P. Dismissed 26-1-21, weight 8½ lbs. No trace of mother and child after child one month old.

882. W.R. Mother = Negative (3-5-). 28-1-21.
Child = Negative (3-5-). 21-1-21.

2nd Preg. Single. Age 34.
L.P. 14-4-20. Normal pregnancy - occipito-post. with spontaneous rotation and delivery - Child born 16-1-21, female, weight 7½ lbs. Dismissed 26-1-21, weight 7 lbs.
Prev. Preg.- 1st = F.T., living, chloroform and Instrs (31-10-12) in G.R.M.H.

883. W.R. Mother = Negative (3-5-). 28-1-21.
Child = Negative (3-5-). 21-1-21.

3rd Preg. Married. Age 26.
L.P. end March, 1920. Normal pregnancy and labour - Child born 14-1-21, Female, weight 9½ lbs. Dismissed 26-1-21, weight 9¾ lbs. Febrile puerperium.
Prev. Pregs.- 1st = miscarriage at 6 months (May, 1919): 2nd = miscarriage at three months Octr., 1919).

Case No.

884. W.R. Mother = Negative (3-5-). 31-1-21.
Child = Negative (3-5-). 31-1-21.

1st Preg. Married. Age 27.
L.P. 22-4-20. Normal pregnancy - delayed second stage. Forceps - child born 14-1-21, male, weight 7½ lbs. R.P. Patient a healthy woman - eyes slightly puffy (? urine). Patient's father and brother died of T.B. Her mother is still alive.
30-3-22 - Both mother and child well - child now aged 14 months.- W.R. Mother= Neg. (3-5-).
Child = Neg. (3-5-).

885. W.R. Mother = Negative (3-5-). 28-1-21.
Child = Negative (3-5-). 21-1-21.

4th Preg. Married. Age 28.
Amenorrhoea since last pregnancy. Patient looks thin and anaemic. Normal pregnancy and labour (but has had fits, probably epileptic, since childhood). Child born 17-1-21, female, weight 8½ lbs. Dismissed 26-1-21, weight 8 lbs.
30-3-22 - Both mother and child well - child now aged 14 months - W.R. Mother = Negative.
Child = Negative.
Prev. Pregs.- 1st = F.T., living, Chloroform & Instrs.: 2nd and 3rd (Jany., 1920) F.T., normal, alive. Patient healthy, but looks pale and anaemic: fits since a child.

886. W.R. Mother = Negative (3-5-). 28-1-21.
Child = Negative (3-5-). 21-1-21.

1st Preg. Married. Age 19.
L.P.early April, 1920. Normal pregnancy. Contracted Pelvis (Diag. Conj. = 4¼", True Conj. = 3½"). Spontaneous delivery - Child born 20-1-21, Female, weight 6½ lbs., alive. Dismissed 29-1-21. 18-11-21 - Child now aged 10 months and both very well.

887. W.R. Mother = Negative (3-5-). 28-1-21.

1st Preg. Single. Age 21.
L.P. early May, 1920. Normal pregnancy and labour - child born 19-1-21, male, weight 7½ lbs., Dismissed 1-2-21, weight 7½ lbs.
Baby died in R.H.S.C. 17-7-21 - Pneumonia.

Case No.

888. W.R. Mother = Negative (3-5-).28-1-21.
Child = Negative (3-5-).21-1-21.

1st Preg. Married. Age 21.
L.P. 1-4-20. Admitted to Antenatal Dept. 16-1-21 - Headache and backache throughout pregnancy: occasional fits, the last on 11-1-21. Uterus about eight months size. Child born 18-1-21 - premature and blue, Female, weight 5¼ lbs (? length of labour). Child not doing well - died 21-1-21. Mother dismissed 27-1-21. Mother had diphtheria at 17 years of age. Occasional (?) epileptic fits during past four years.

889. W.R. Mother = Negative (3-5-). 28-1-21.
Child = Negative (3-5-). 28-1-21.

1st Preg. Single. Age 21.
L.P. middle April, 1920. Normal pregnancy and labour. R.P. Child born 19-1-21, male, weight 7 lbs., alive. Dismissed 31-1-21.
30-3-22 - Both well. W.R. Mother = Negative.
Child = Negative.

890. W.R. Mother = Negative (3-5-). 21-1-21.

8th Preg. Married. Age 32.
L.P. ? Aug., 1920. Attended Antenatal Disp. - Flatulence: weakness: choking sensation: no life felt.
Prev. Pregs.- 7 children all F.T., alive - 5 now living - normal labours (last born April, 1920).

891. W.R. Mother = Negative (3-5-). 28-1-21.

4th Preg. Married. Age 27.
L.P. 24-6-21. Attended Antenatal Dispensary 21-1-21 - feels sick: constipation: digestion poor.
Prev. Pregs.- 1st-3rd = normal, F.T., alive - two now living: last = twins (Aug., 1919) - one dead, the other still alive.

Case No.

892. W.R. Mother = Negative (3-5-). 28-1-21.

10th Preg. Married. Age 35.
L.P. 18-11-20. Attended Antenatal Dispensary 21-1-21 - pain both sides and in back: constipation: poor digestion. Uterus retroflexed and enlarged and tender ovary. Patient about two months pregnant. In Antenatal Dept. 16-2-21 to 26-2-21 - retroflexed gravid uterus replaced and pessary inserted. Readmitted to hospital 31-8-21 - male child born 1-9-21, weight 7½ lbs. Dismissed 9-9-21, weight 7¾ lbs. 20-2-22 - Child now aged five months and very well - mother also in good health.
Previous Pregs.- All F.T., normal, living, except last pregnancy which = Twins (7 months), living, CH.clz. (Novr., 1919). Operation (abdominal) in G.R.I. ten years ago.

893. W.R. Mother = Strongly Positive (3+5+). 28-1-21.
Child = Strongly Positive (3+5+). 2-3-21.

1st Preg. Married. Age 21.
L.P. middle July, 1920. Admitted to Antenatal Dispensary 21-1-21 pain in back and pain on micturition: feeling of weakness - vomiting most of pregnancy. Admitted 2-3-21, in coma - history of continuous vomiting but no headache and no dimness of vision. Child born before admission - male. Mother had four fits (Eclamptic) before admission -(post-partum) - further fits after admission. Albumen (+++): high tension pulse: bronchitis. Dismissed 12-3-21. Patient attdg. Postnatal Disp. and "A" mixture prescribed. Baby died 19-6-21 : aged 3½ months.

894. W.R. Mother = Negative (3-5-). 28-1-21.

2nd Preg. Married. Age 21.
L.P. 1st July, 1920. Attended Antenatal Dispensary 21-1-21 - pain in left side: very constipated.
1st Pregnancy was normal, F.T., alive (Septr., 1919).

Case No.

895. W.R. Mother = Negative (3-5-). 28-1-21.

4th Preg. Married. Age 28.
L.P. 17-10-20. Incomplete Abortion. Bleeding and pain began 11-1-21 - large clots passed. The bleeding continued and on day of admission (16-1-21) a round mass was passed. Curetted. Dismissed 26-1-21. Uterus about three months size on admission.
Prev. Pregs.- 1st, 2nd and 3rd = F.T., normal, living (last in Jany.,1919).

896. W.R. Mother = Negative (3-5-). 28-1-21.
Child = Negative (3-5-). 28-1-21.

2nd Preg. Married. Age 35.
L.P. 7-5-20. Patient was admitted to Antenatal Dept. 4-1-21 - Contracted Pelvis. Uterus was about eight months size. Dismissed 7-1-21 and returned 20-1-21 - induction - child born 22-1-21, male, premature, weight 6 lbs., alive but died 25-1-21 before dismissal of mother on 1-2-21. P.M.
Prev. Preg.- 1st = F.T., May, 1916.

897. W.R. Mother = Strongly Positive (3+5+). 28-1-21.

2nd Preg. Married. Age 31.
L.P. April, 1920. Patient has not felt life throughout present pregnancy. Vomiting excessive throughout - always passed plenty of urine. Admitted 14-1-21 - Postpartum Eclampsia - child born 13-1-21 (patient in coma on admission). Albumen +++ (on 24-1-21 = 0.2% and still present on 26-1-21). Chronic Nephritis. Child alive and doing well. Both dismissed well.
27-7-21 - Has been attending own doctor - treatment (mixture). Urine not clear when last tested (4 months ago). Baby doing well on Glaxo. W.R. Mother = Str. Pos. (3+5+).
28-3-22. - Mother only fairly well - child very well - now aged 14 months - W.R. Child = Neg.
Prev. Preg.- 1st = F.T., living, normal (Feby., 1919). Mother had illness a year before first pregnancy - liver and kidneys said to have been affected.

Case No.

898. W.R. Mother = Negative (3-5-). 28-1-21.

1st Preg. Married. Age 18.
L.P. March or April, 1920. No morning sickness - Premature labour - Hydramnios:. Child born 17-1-21, female, weight 4½ lbs., born alive but died 20-1-21. P.M. Mother healthy.

899. W.R. Mother = Negative (3-5-). 28-1-21.
Child = Negative (3-5-). 28-1-21.

5th Preg. Married. Age 32.
L.P. April, 1920. Slightly flat pelvis (Diag. Conj. = 4½"+, True Conj. = 3¾" +). Normal pregnancy and labour - child born 25-1-21, male, weight 8½ lbs. Dismissed 3-2-21, weight 8 lbs. 31-3-22- Baby not thriving - nothing definite- now aged 14 months. W.R. Mother = Neg.(3-5-).
Child = Neg.(3-5abs.)
Prev. Pregs.- 1st - 4th = normal, F.T., alive (last in April, 1919).

900. W.R. Mother = Negative (3-5-). 28-1-21.
Child = Negative (3-5-). 28-1-21.

2nd Preg. Single. Age 25.
L.P. early April, 1920. Normal pregnancy and labour. Child born 25-1-21, female, weight 8¼ lbs. Dismissed 3-2-21, weight 8 lbs. 22-2-22 - Baby now aged 13 months (adopted) and said to be very well.
Prev. Preg.- Normal, F.T., alive (Jany., 1913).

901. W.R. Mother = Negative (3-5-). 28-1-21.

3rd Preg. Married. Age 27.
L.P. 24-6-20. Threatened Eclampsia - well till three days before admission when she noticed slight swelling of feet - said to have had an eclamptic fit on morning of admission (25-1-21). On admission no oedema found but uric acid: Albumen = 0.05%. One hysterical fit on afternoon of admission - no further fits. Dismissed undelivered 14-2-21. (Very faint trace of albumen in urine on 31-1-21). Uterus about seven months size.

Case No.

902. W.R. Mother = Negative (3-5-). 28-1-21.

1st Preg. Married. Age 24.
L.P. middle October, 1920.
Admitted to Antenatal Dept. 13-1-21 from Antenatal Disp. as ? Complete Abortion - well till 27-12-20 when slight bleeding began - four days later large clots came away with severe haemorrhage - since then slight but continuous bleeding. Dismissed 20-1-21 and readmitted 25-1-21 after some haemorrhage - clots passed - dilated and curetted - very little if any placental debris. Dismissed 1-2-21.

903. W.R. Mother = Negative (3-5-). 28-1-21.
Child = Negative (3-5-). 28-1-21.

2nd Preg. Single. Age 25.
L.P. April or May, 1920. Normal pregnancy - Contracted Pelvis (Diag. Conj. = 4¼", True Conj. = 3½" : outlet not much contracted). Child born 25-1-21 (mid forceps), male, weight 8¾ lbs. Dismissed 3-2-21, weight 8½ lbs. 17-11-21 - Child now aged 10 months - had whooping-cough for three months; now practically recovered. Bright healthy-looking baby.
Prev. Preg.- = Normal, spontaneous (small child) - May, 1918.

904. W.R. Mother = Negative (3-5-). 28-1-21.

3rd Preg. Married. Age 24.
L.P. 3-11-20. Incomplete Abortion. Slight blood stained discharge began four days before admission - clots passed almost painlessly three days before admission - since then slight continuous bleeding. Admitted 25-1-21 - packed - curetted 2Y-1-21. Dismissed 2-1-21.
Prev. Pregs.- 1st = Chloroform & Forceps - F.T., alive: 2nd = normal, F.T., alive (Aug., 1919).

905. W.R. Mother = Negative (3-5-). 28-1-21.

4th Preg. Married. Age 32.
L.P. ? Ruptured ectopic gestation - operation 10-1-21. Dismissed 28-1-21.
Patient a healthy woman, but a sister has T.B.
Prev. Pregs.- 1st - 3rd = Normal, F.T.

Case No.

906. W.R. Mother = Negative (3-5-). 28-1-21.

1st Preg. Single. Age 17.
? L.P. Irregular - First menstruation was one year before admission. Patient was well during pregnancy. Admitted 12-1-21 - Eclampsia, Low Forceps: R.P. Eclampsia developed after head had been on perineum for two hours. Patient had oedema (? of legs) on admission. Child born 12-1-21 - male, weight 8 lbs. - had dactylitis and an abscess of right ankle, died 28-1-21. Mother dismissed 29-1-21.

907. W.R. Mother = Negative (3-5-). 28-1-21.

4th Preg. Married. Age 35.
L.P. July, 1920. Patient was well till Novr., 1920 when cough, spit and night-sweats developed - very slight haemoptosis. Admitted 17-1-21 - very thin, and looked anaemic and ill. Mitral stenosis: dulness and rales right apex: hydramnios: abdomen about 7½ months size: Membranes ruptured artificially on 22-1-21 - Female, alive, weight 3½ lbs. born 22-1-21 but died after a few hours. Mother had haze of albumen in urine on admission.
Prev. Pregs.- 1st and 2nd = F.T., living, normal: 3rd = F.T., living, Chloroform and Forceps (19-1-13). Mother has menorrhagia and headaches during menstruation. Had acute rheumatism twice - 21 and 8 years ago - symptoms of endocarditis since second attack.

908. W.R. Mother = Negative (3-5-). 28-1-21.
Child = Negative (3-5-). 28-1-21.

6th Preg. Married. Age 33.
L.P. ? May, 1920. Had bleeding in Decr., 1920 for a short time: 14 days later recurred again: severe bleeding evening of admission (24-1-21) - there had been slight bleeding for a week previously. Lateral placenta praevia - Version, foot brought down - Child born alive 25-1-21, male, weight 8½ lbs. Dismissed 5-2-21, weight 7½ lbs. 30-3-22 - Child now aged 14 months and is very well - never any illness.
W.R. Mother = Negative (3-5-). 30-3-22.
Child = Negative (3-5-). 30-3-22.
Prev. Pregs.- 1st = F.T., living, Chloroform & Forceps: 2nd - 5th = F.T., normal, living (Last in Aug., 1918).

Case No.

909. W.R. Mother = Negative (3-5-). 28-1-21.
Child = Negative (3-5-). 28-1-21.

6th Preg. Married. Age 35.
L.P. 20-5-20. Patient was well till five weeks before admission when diarrhoea started - later vomiting appeared to have persisted till admission on 19-1-21 to Antenatal Dept. Sickness and diarrhoea persisted - condition considered to be due to persistent enteritis rather than to true toxaemia. Premature child born 21-1-21, Female, weight 6 lbs., alive. Child did well and mother improved after delivery- no further vomiting or diarrhoea. Dismissed 1-2-21, weight 6 lbs. Mother died 15th and child died on 17th Feby., 1921 - cause of death not stated.
Prev. Pregs.- 1st = F.T., living, CH.clz. & Instrs. 2nd, 3rd, 4th & 5th = normal, F.T., living.

910. W.R. Mother = Negative (3-5-). 28-1-21.

1st Preg. Married. Age 22.
L.P. end April, 1920. Had some sickness last 5-6 weeks but otherwise well. Persistent occipito-posterior - Forceps, R.P. Child born 22-1-21, male, weight 7½ lbs. Dismissed 12-2-21, to go to R.H.S.C. with baby who had an abscess. No trace since.

911. W.R. Mother = Negative (3-5-). 28-1-21.

1st Preg. Married. Age 25.
L.P. May, 1920. Well throughout pregnancy. Normal delivery - retained placenta with P.P.H. Placenta removed manually. Child born 21-1-21, male, weight 6¼ lbs. Dismissed 31-1-21, weight 5¾ lbs. No trace since dismissal.

912. W.R. Mother = Negative (3-5-). 28-1-21.
Child = Negative (3-5-). 28-1-21.

1st Preg. Single. Age 21.
L.P. 23-6-20. Normal pregnancy. Slight morning sickness - premature labour, child born 22-1-21, Female, weight 3½ lbs. Died 24-1-21. Mother dismissed 1-2-21.

Case No.

913. W.R. Mother = Negative (3-5-). 28-1-21.
Child = Negative (3-5-). 28-1-21.

2nd Preg. Married. Age 21.
L.P. end March, 1920. Normal pregnancy and labour. Child born 21-1-21, male, weight 9¼ lbs. On 23-1-21 child found to be ill - no meconium passed - anus patent - vomiting. Sent to R.H.S.C. 24-1-21 - at operation small intestime found to end blindly: no large intestime at all, but 2" of rectum present. Child died 25-1-21. Mother pale but healthy.
Prev. Preg. = F.T., alive, CH.clz. & Instrs. (Jany., 1920).

914. W.R. Mother = Negative (3-5-). 28-1-21.

2nd Preg. Single. Age 19.
L.P. middle June, 1920. Patient was well till night of 20-1-21 when had bleeding followed by pains - had occasional pain for several days before. Admitted 21-1-21 - Accidental Haemorrhage - premature labour - Child born alive 21-1-21, Female, weight 2 lbs. Died 24-1-21. Mother had albuminuria (+++) and oedema of feet and legs. Oedema and albumen diminished after delivery and urine was clear for several days before dismissal on 10-2-21. P.M.
Prev. Preg. = F.T., living, CH.clz. & Forceps (G.R.M.H.) Feby., 1920 - had albuminuria for some months during 1st pregnancy, otherwise healthy.

915. W.R. Mother = Negative (3-5-). 28-1-21.

6th Preg. Married. Age 44.
L.P. 5-4-20. Patient was in bed for eight weeks owing to cystocoele and frequency of micturition. Life felt last on 16-1-21 - labour overdue (?) - Child born (macerated) 20-1-21, male, weight 8¾ lbs. P.M.
Prev. Pregs.- 1st = F.T., living, CH.clz. & Instrs.: 2nd = miscarriage at 7 weeks (1907): 3rd, 4th, 5th = F.T., living, normal. Excessive sickness and general weakness with all pregnancies. Healthy looking woman.

Case No.

916. W.R. Mother = Negative (3-5-). 28-1-21.

5th Preg. Married. Age 24.
L.P. ? Bleeding on one occasion three weeks before admission, otherwise well till she had three eclamptic fits on 17-1-21 - Admitted to hospital - albumen = 0.6%. Spontaneous delivery - child born 18-1-21 - female, premature, weight 4 lbs. Dismissed 31-1-21, - Both mother and child well on dismissal - albuminuria cleared up after delivery. Child died at home on 9-2-21.
Prev. Pregs.- 1st - 3rd = F.T., living, normal: 4th = premature (April, 1920) lived only six hours.

917. W.R. Mother = Negative (3 Tr 5Tr.)28-1-21.

5th Preg. Married. Age 33.
L.P. Novr., 1920. Admitted to Antenatal Dept. 21-1-21 - Threatened Abortion on day of admission. No abdominal enlargement visible. Uterus about three months size. Slight bleeding with pain on 28-1-21 - Left hospital (irregul.) 29-1-21 - undelivered.
Prev. Pregs.- 1st - 3rd = normal, F.T., alive (last in 1913): 4th = miscarriage at 5 months in 1917. Patient a pale but healthy woman - Influenza two years before admission.

918. W.R. Mother = Negative (3-5-). 28-1-21.

1st Preg. Married. Age 19.
L.P. ? Normal pregnancy. Contracted Pelvis (Diag. Conj. = 4¼" , True Conj. = 3½"). Breech cord round child's neck. - R.P. Difficulty with head. Child born dead 15-1-21, Female, weight 8 lbs. 6 ozs, Long labour - membranes ruptured three days before delivery.

919. W.R. Mother = Negative (3-5-). 28-1-21.

3rd Preg. Married. Age 26.
L.P. July, 1920. Admitted to Antenatal Dept. 24-1-21 - Threatened Abortion. Bleeding in end of December, 1920 - bleeding again 23-1-21 and 24-1-21, with pain. No further bleeding. Dismissed 31-1-21 - uterus 4½-5 months size.
Prev. Pregs.- 1st = F.T., living, CH.clz. & Instr. (Novr., 1917): 2nd = Miscarriage at 3½ months (March, 1920). Healthy woman: Irreg. menstruat.

Case No.

920. W.R. Mother = Negative (3-5-). 28-1-21.

3rd Preg. Married. Age 32.
Admitted to Antenatal Dept. 24-1-21. L.P. last week May, 1920. Swelling of legs for one week. Vomited once but no headache. Albumen ++ (0.1%) Pale and anaemic: oedema of legs and abdomen. Went home 11-2-21 - urine clear and general condition much improved. Readmitted 21-2-21 - marked oedema of legs and abdomen: Albumen = 0.2%. Child born 2-3-21, female, alive, weight 5 lbs. Adherent placenta removed manually: P.P.H. Uterus and vagina packed - Aft r admission albumen lessened in amount (0.05%) and general condition improved at first, but patient had severe P.P.H. on 2-3-21 and died two hours after delivery.
Prev. Pregs.- 1st & 2nd = F.T., normal, alive (last on 21-1-19). Father of patient died of Phthisis in 1902.

921. W.R. Mother = Negative (3-5-). 28-1-21.
Child = Negative (3-5-). 16-2-21.

2nd Preg. Married. Age 28.
L.P. April, 1920. Admitted to Antenatal Dept. 5-1-21 - feet and legs began to swell 14 days before admission. General oedema on admission - Albumen = 0.175%. Child born 13-2-21, Female, weight 10½ lbs. Dismissed 22-2-21, weight 10 lbs. No trace since dismissal.
Prev. Preg.- Premature (7 months), living, spontaneous delivery (12-2-20).

922. W.R. Mother = Negative (3-5-). 28-1-21.

6th Preg. Married. Age 33.
L.P. 10-10-20. Admitted to Antenatal Dept. 17-1-21 and was dismissed 31-1-21. Had some bleeding on 27-11-20 - repeated several times since - pain in back and on micturition. Threatened Abortion. Readmitted 15-4-21 - Accidental Haemorrhage - slight for three weeks. Bleeding on 19-4-21, with clots. Premature child born 22-4-21 (6½ mos.) - Breech - male, weight 2 lbs. Died a few hours later. Mother has no albuminuria. ? cervical erosion.
Prev. Pregs.- 1st - 4th = F.T., living - forceps with 2nd (last on 20-1-19): 5th = miscarriage at 5 weeks (Septr., 1920). There was Threatened Miscarriage at 4½ months with 4th pregnancy.

Case No.

923. W.R. Mother = Negative (3-5-). 28-1-21.

2nd Preg. Married. Age 27.
L.P. 14-5-20. Admitted to Antenatal Dept. 5-1-21 - has attacks of faintness after exertion but has lost consciousness only twice. Mitral stenosis - compensation good. Some attacks of dyspnoea but no distress otherwise. Child born 3-3-21 - irregular labour pains for two days - child delivered with forceps, male, weight 6½ lbs. Baby died day after dismissal from hospital (15-3-21).
Prev. Preg.- F.T., normal, living, Instrs. (March, 1917). Mother had acute rheumatism in April, 1915: Puerperal fever in March, 1917 (6 weeks in Belvidere, 6 weeks at home and 8 weeks in G.R.I.).

924. W.R. Mother = Negative (3-5-). 28-1-21.

1st Preg. Single. Age 19.
L.P. 11-8-20. Admitted to Antenatal Dept. 19-1-21 - Hysteria - giddy turns. Fell several times but has never become unconscious. Abdomen about 6½ months size. Dismissed 29-1-21 - no albuminuria.

925. W.R. Mother = Negative (3-5-). 28-1-21.

2nd Preg. Married. Age 25.
L.P. March, 1920. Admitted to Antenatal Dept. 3-12-20 - Contracted Pelvis (Diag. Conj. = 4¼" : True Conj. = 3½" -). About seven months pregnant. Dismissed undelivered and was readmitted 23-12-20 - Caesarean Section 4-2-21 - Female, weight 8 lbs. Mother sterilised. Small rickety woman, but healthy. Dismissed 28-2-21, weight 7¼ lbs.
28-5-22 - Child now aged 15 months and both mother and child well: child never had any illness.
W.R. Mother = Negative (3-5-). 28-5-22.
Child = Negative (3-5-). 28-5-22.
1st Preg. = Abortion.

Case No.

926. W.R. Mother = Negative (3-5-). 28-1-21.

2nd Preg. Married. Age 20.
L.P. 24-10-20. Admitted to Antenatal Dept. 21-1-21 - " something pressing down" - slight bleeding 4 weeks before admission - attended Antenatal Dispensary. Uterus retroflexed, replaced and pessary inserted. Patient is anaemic but is otherwise well. Dismissed (comfortable) 26-1-21.
1st Preg. = F.T., living, normal (17-4-19).

927. W.R. Mother = Negative (3-5-). 28-1-21.

3rd Preg. Married. Age 27.
L.P. 20-7-20. In August and Septr., 1920 had excessive sickness, pain in left side and breathlessness - treated by doctor and improved but grew worse later. Admitted Antenatal Dept. 24-1-21. Rheumatic Endocarditis: compensation satisfactory while in hospital - left border slightly beyond nipple line: marked V.S. murmur at apex. Dismissed 5-2-21. Readmitted 14-2-21 - increased dyspnoea and oedema of legs. Bougies inserted twice - Stillborn premature foetus born 18-2-21, Female, weight 3¾ lbs. (macerated). Mother's condition fairly good, but became seriously ill on 24-2-21 - rise of temperature and pulse: coma: Died 24-2-21.
Prev. Pregs.- 1st = F.T., S.B., Chloroform & Forceps: 2nd = F.T., living, normal, 1917 - Had chorea as a girl: acute rheumatism in 1915 and a second attack in 1916: Had Bronchitis while carrying 1st baby (May,1915). Short of breath and giddy during 2nd pregnancy (June, 1917).

928. W.R. Mother = Strongly Positive (3+5+). 28-1-21.

8th Preg. Married. Age 34.
L.P. 19-11-20. Attended Antenatal Disp. 21-1-21. Admitted Antenatal Dept. 21-1-21 - retroflexed uterus - replaced under anaesthetic 24-1-21 - Dismissed well 26-1-21. Home visited 1-5-21 - Patient feeling fairly well - getting "A" mixture. Patient died suddenly 24-6-21 - **undelivered.**
Prev. Pregs.- 1st = 6 mos., lived 2 days, normal labour: 2nd = F.T., living, normal: 3rd = 8 mos. living, normal: 4th = 4 mos. S.B.: 5th = F.T., living, normal: 6th & 7th = F.T., living, Normal.

Case No.

929. W.R. Mother = Negative (3-5-). 28-1-21.

1st Preg. Married. Age 25.
L.P. 17-4-20. Normal pregnancy and labour. Child born 20-1-21 - male, weight 7½ lbs. R.P. Dismissed 30-1-21, weight 7 lbs. No further trace.

930. W.R. Mother = Negative (3-5-). 28-1-21.
Child = Negative (3-5-). 2-3-21.

1st Preg. Married. Age 26.
L.P. 31-7-20. Admitted to Antenatal Dept. 23-1-21 - Pyuria. Slight morning sickness during early months of sickness but was otherwise well till a few days before admission when she felt pain in the back and on right side. Five days before admission severe pain and ? suppression. Some pyrexia on admission. Uterus about five months size. Urine 24-1-21 - Acid, S.G. = 1018. Alb. +. Sugar - . No blood or pus present. Coliform bacilli direct and on culture 28-1-21. Much pus present on 30-1-21. Induction 24-2-21 - child born 26-2-21, female, mature, weight 4¾ lbs. Died 28-2-21. Mother dismissed 9-3-21.

931. W.R. Mother = Negative (3-5-). 28-1-21.
Child = Negative (3-5-). 21-1-21.

17th Preg. Married. Age 45.
L.P. ? . Admitted 17-1-21 - pale and anaemic. Uterus about seven months size. Footling - with hand prolapsed - anencephalic monster - dead - born 17-1-21. Mother had not felt well throughout pregnancy. Accidental haemorrhage: premature labour.
Prev. Pregs.- 14 normal, living children: 2 miscarriages.

932. W.R. Mother = Negative (3-5-). 28-1-21.

1st Preg. Single. Age 20.
L.P. 29-3-20. Patient was well throughout pregnancy. Normal labour. R.P. Child born 21-1-21, female, weight 8¾ lbs. Dismissed 2-2-21, weight 9½ lbs. Child was reported to be alive and well when aged 10 months.

Case No.

933. W.R. Mother = Negative (3-5-). 28-1-21.
Child = Negative (3-5-). 28-1-21.

3rd Preg. Married. Age 21.
L.P. April, 1920. Normal pregnancy and labour - false labour one week before delivery. Child born 20-1-21 - male, weight 7½ lbs. Dismissed 29-1-21, ? weight. Child was getting on well until March, 1922 when he died of measles - was then 14 months old. Mother a healthy woman.
Prev. Pregs.- 1st and 2nd = normal, F.T., alive (Last in Septr., 1919).

934. W.R. Mother = Negative (3-5-). 28-1-21.

2nd Preg. Married. Age 19.
L.P. ? . Has been very sick since Septr., 1920 - no bleeding till two weeks before admission since when there has been continuous bleeding. No further sickness. Incomplete Abortion - Admitted 20-1-21, curetted 20-1-21. Dismissed 27-1-21. No particulars of previous pregnancy available.

935. W.R. Mother = Strongly Positive (3+5+). 28-1-21.

1st Preg. Single. Age 23.
L.P. 1st week June, 1920. Normal pregnancy. Admitted to Antenatal Dept. 25-1-21 - labour pains began one week before admission after patient had been carrying a weight. No life felt since then. Child born 25-1-21 - premature - macerated, female, weight 3½ lbs. Mother dismissed 3-2-21. Patient getting "A" mixture.

936. W.R. Mother = Negative (3-5-). 28-1-21.
Child = Negative (3-5-). 28-1-21.

1st Preg. Married. Age 22.
L.P. 19-4-20. Normal pregnancy and labour. Child born 25-1-21 - male, weight 6¾ lbs. Dismissed 3-2-21, weight 6¾ lbs. Baby died 15-2-21 - Jaundice.

Case No.

937. W.R. Mother = Negative (3-5-). 28-1-21.

1st Preg. Single. Age 21.
L.P. end April, 1920. Normal pregnancy. Membranes ruptured before admission on 10-1-21. Transverse - version to footling - child dead - perforation of aftercoming head. Child born dead 11-1-21 - male, weight 6¾ lbs.

938. W.R. Mother = Negative (3-5-). 28-1-21.

6th Preg. Married. Age 41.
L.P. end Octr., 1920. Admitted 23-1-21. Well till bleeding began on day of admission. Pain in back - uterus about three months size. Inevitable abortion - curettage. Dismissed 29-1-21.
Prev. Pregs.- 1st - 5th = All normal, F.T. - last in August, 1916. Two since dead. Patient has some premenstrual pain.

939. W.R. Mother = Negative (3-5-). 1-2-21.

1st Preg. Married. Age 23.
L.P. 26-11-20. Admitted to Antenatal Dept. 22-1-21. Bleeding began 2-1-21 and continued for two weeks, since then only slight bleeding and occasional crampy pains. On admission only very slight haemorrhage and pain - uterus about two months size. Thickness and swelling in both iliac fossae - especially right. 27-1-21 - still occasional brown discharge. 31-1-21 - swelling both sides - marked tenderness. 17-2-21 - swelling on right side almost gone: swelling on left side still palpable. Bleeding again. ? Incomplete Abortion (no record of curettage). (W.R. Sheet " Complete miscarriage at six months"). Dismissed 26-2-21.

940. W.R. Mother = Negative (3-5-). 1-2-21.

2nd Preg. Married. Age 20.
L.P. 14-6-20. Normal pregnancy - threatened miscarriage. Pains began twelve hours before admission on 27-1-21 - uterus about seven months size. Dismissed undelivered 31-1-21.
Prev. Preg.- = Abortion at three months (Decr., 1919).

Case No.

941. W.R. Mother = Negative (3-5-). 1-2-21.

6th Preg. Married. Age 30.
L.P. 16-6-20. Patient attending outside doctor for cardiac condition throughout pregnancy - sent in as possible induction. Admitted to Antenatal Dept. 26-12-20 - thin woman, healthy colour: no oedema. Mitral Stenosis - presystolic and systolic murmur - some dilatation: marked thrill. Uterus about level of umbilicus. Dismissed 8-1-21 and readmitted 17-1-21 - dismissed undelivered 4-2-21.
Prev. Pregs.- 1st - 5th = normal, F.T., alive - last in Octr., 1917. Patient had Influenza, acute rheumatism, pleurisy and pneumonia all in 1918. Her mother died of "ulcerated throat".

942. W.R. Mother = Negative (3-5-). 1-2-21.

4th Preg. Married. Age 31.
L.P. 1st week Novr., 1920. Admitted 27-1-21 - Was well till day before admission when bleeding began and it became severe on afternoon of 27-1-21 - large clots passed - portion of placenta retained. Incomplete Abortion - Curettage 28-1-21. Dismissed 3-2-21.
Prev. Pregs.- 1st - 3rd = normal, F.T., alive - last in March, 1919. Patient had pleurisy as a girl. T.B. - foot amputated 16 years ago.

943. W.R. Mother = Strongly Positive (3+5+). 1-2-21.

2nd Preg. Married. Age 25.
L.P. 24-8-20. Admitted Antenatal Dept. - Threatened miscarriage - 22-1-21. Painless bleeding began ten days before admission - some clots passed at first, since then constant bleeding - no pain. Complete miscarriage (about 5 mos.) on 25-1-21. Dismissed 2-2-21.
Prev. Preg.- 1st = CH.clz. & forceps - delayed labour - F.T., S.B. (April, 1919).

944. W.R. Mother = Negative (3-5-). 1-2-21.

2nd Preg. Married. Age 23.
L.P. ? Octr., 1920. Well till 21-1-21 - headache: bleeding - ovum passed one hour before admission on 23-1-21. Incomplete abortion - spontaneously completed one hour after admission (about three months. Dismissed 29-1-21.
Prev. Preg.- 1st = normal, F.T., alive (Octr.1918).

Case No.

945. W.R. Mother = Negative (3-5-). 1-2-21.

1st Preg. Married. Age 18.
L.P. April, 1920. Well till early Jany., 1921 when ankles and face became swollen: did not consult doctor till confinement: had two Eclamptic fits before delivery and two after delivery. Child born - male - on 23-1-21, before admission. Mother admitted 23-1-21 - face puffy, oedema of ankles. Albumen: 0.15%. Acid: S.G. 1020. Heart hypertrophied: no sickness after admission. Mother and child dismissed 12-2-21. 23-5-22 - Child has had a good deal of trouble with chest but better now - now aged 16 months.- W.R. Mother = Negative.
Child = Negative.

946. W.R. Mother = Negative (3-5-). 1-2-21.
Child = Negative (3-5-). 28-1-21.

6th Preg. Married. Age 26.
L.P. - Amenorrhoea since last pregnancy - has complained of some right sided pain throughout pregnancy - also constipation (which is no longer present). Painless labour began eight hours before admission on evening of 20-1-21. Transverse presentation - arm prolpased - version to footling - child born 21-1-21 - anencephalic with spina bifida - macerated. P.M.
Prev. Pregs.- 1st - 4th = normal, F.T., alive (Last in Octr., 1918). One miscarriage at three months (May, 1920). Mother had a T.B. Knee - her husband's family are tuberculor.

947. W.R. Mother = Strongly Positive (3+5+).

2nd Preg. Married. Age ?.
L.P. last week June, 1920. Patient was well throughout pregnancy: life not felt for one week before onset of labour. Child born 23-1-21 - dead - macerated, weight 2 lbs., male. Transverse presentation - version to footling. Retained placenta removed manually. Mother anaemic: slight tibial curvature.
1st Preg. = prolonged labour, F.T., S.B. (Decr., 1919).

Case No.

948. W.R. Mother = Negative (3-5-). 1-2-21.

4th Preg. Married. Age 34.
L.P. 5-5-20. Admitted to Antenatal Dept.
24-1-21 - Contracted pelvis - Diag. Conj. = 4¼" +. True Conj. = 3½" +. Slight hydramnios: head unfixed: Very slight trace of albumen: Uric acid. Patient was well till seven months pregnant when vomiting became severe and persisted till admission: has also had slight oedema of ankles throughout. Caesarean section 10-2-21 - child born alive, male, weight 8¾ lbs. Patient sterilised. Dismissed 12-3-21.
25-5-22 - Child now aged 14 months and both very well. W.R. Mother = D. Neg. (3∓5∓).
Child = Neg. (3∓5-).
Prev. Pregs.- 1st = CH.clz. & Forceps, alive, F.T., severe vomiting throughout this pregnancy: 2nd = CH.clz. & Forceps, alive, F.T., oedema of ankles and legs: 3rd = CH.clz. & Forceps, S.B., F.T. (Septr., 1914.) Had measles at age of three years with abscesses of ankles and thigh.

949. W.R. Mother = Negative (3-5-). 1-2-21.

5th Preg. Married. Age 25.
L.P. ?. Admitted Antenatal Dept. 14-12-20 - Contracted Pelvis. Dismissed 17-12-20 and was readmitted 27-1-21. Caesarean Section 5-3-21 - child born alive, male, weight 9 lbs. Dismissed 31-3-21, weight 7½ lbs. No trace after dismissal.
History of previous pregs. not available.

950. W.R. Mother = Negative (3-5-).

1st Preg. Married. Age 24.
L.P. ? 4-10-20. Admitted to Antenatal Dept.
25-1-21 - threatened miscarriage. Well except for morning sickness till day before admission when there was moderately severe bleeding which continued till admission: no pain. Patient is a short woman with contracted pelvis - C.V. 2¾", Diag. Conj. = 4½". Uterus about 4½ months size. Rachitic head and markedly rachitic legs. History of T.B. in family. Dismissed 1-2-21 and was readmitted 16-2-21 - Bleeding started again on 15-2-21. Os softened but not patent. Uterus about 1" below umbilicus. Curetted 2-3-21. Dismissed 18-3-21.

Case No.

951. W.R. Mother = Negative (3-5-). 1-2-21.
Child = Negative (3-5-). 22-2-21.

1st Preg. Married. Age 21.
L.P. early May or late April, 1920. Admitted to Antenatal Dept. 26-1-21 - had not felt life for one week. Dismissed 29-1-21 and was readmitted 2-2-21 - child born alive 17-2-21, male, weight 8 lbs. Dismissed 28-2-21, weight 8 lbs. 22-2-22 - Both mother and child well - child now one year old.

952. W.R. Mother = Negative (3-5-). 1-2-21.

1st Preg. Married. Age 27.
L.P. 26-4-20. Normal pregnancy. Forceps delivery 26-1-21 (Before admission) - child born alive - male. Patient was blanched on admission: adherent placenta with P.P.H. Placenta was very adherent and had to be scraped off uterine wall. Child was known to be alive and well when aged 10 months - no further trace.

953. W.R. Mother = Negative (3-5-). 1-2-21.

1st Preg. Married. Age 22.
L.P. 15-9-20. Admitted to Antenatal Dept. 26-1-21 - Inevitable Abortion - had bleeding on 21-1-21 and pain - both intermittent till admission. Twin foetuses born 28-1-21 - much blood in uterus. Patient had acute rheumatism six years ago and scarlet fever five years ago.

954. W.R. Mother = Negative (3-5-). 1-2-21.
Child = Negative (3-5-). 1-2-21.

3rd Preg. Married. Age 32.
L.P. 19-4-20. Contracted Pelvis (Diag. Conj. = 3¾" -: True Conj. = 3" -). Failed forceps before admission. 26-1-21 - Craniotomy - male, weight 6 lbs.
Prev. Pregs.- 1st = normal (small child): 2nd = F.T., craniotomy (July, 1919 in G.R.M.H). Was told to come in good time for next labour but failed to do so.

Case No.

955. W.R. Mother = Negative (3-5-). 1-2-21.
Child = Negative (3-5-). 1-2-21.

3rd Preg. Married. Age 33.
L.P. end March, 1920. Sickness and vomiting throughout pregnancy. Face presentation - child born after version to footling - 27-1-21 - dead - male, weight 8½ lbs. P.M.
Prev. Pregs.- 1st = F.T., alive, CH.clz. & Instrs.
2nd = F.T., alive, normal delivery 23-11-15.

956. W.R. Mother = Negative (3-5-). 1-2-21.

2nd preg. Married. Age 24.
L.P. 1st week Aug., 1920. Pain and bleeding for 10-14 days before admission. Complete abortion in ambulance just before admission on 10-1-21. Thin anaemic woman.
Prev. preg. = F.T., living, normal (1918).

957. W.R. Mother = Negative (3-5-). 1-2-21.
Child = Negative (3-5-). 23-2-21.

1stPreg. Single. Age 22.
L.P. 15-5-20. Admitted to Antenatal Dept. 26-1-21 - Swelling of feet, headache and vomiting for one week. Albumen ++. Slight oedema of legs: tongue furred: uterus 8 months size. Dismissed much improved 14-2-21. Readmitted 18-2-21 - normal labour, child born 19-2-21 - male, weight 8¼ lbs. Dismissed 28-2-21, weight 7¼ lbs.
23-5-22 - Child now aged 15 months and reported well: just recovering from pneumonia.

958. W.R. Mother = Negative (3-5-). 1-2-21.
Child = Negative (3-5-).28-1-21.

1st Preg. Single. Age 21.
L.P. March, 1920. Normal pregnancy and labour - child born alive 23-1-21 - male, weight 9¾ lbs. Dismissed 4-2-21, weight 9¾ lbs.
14-11-21 - Child aged 10 months and very well - never any illness.

Case No.

959. W.R. Mother = Negative (3-5-). 1-2-21.
Child = Negative (3-5-). 28-1-21.

1st Preg. Single. Age 24.
L.P. end April, 1920. Normal pregnancy: contracted outlet: long labour: Child born alive 24-1-21, Female, weight 8 lbs. Dismissed 3-2-21, weight 7¼ lbs., but died in R.H.S.C. 13-2-21.

960. W.R. Mother = Negative (3-5-). 1-2-21.
Child = Negative (3-5-). 28-1-21.

5th Preg. Married. Age 26.
L.P. 1st week May, 1920. Normal pregnancy and labour - child born alive 23-1-21, female, weight 6 lbs. (? 8 months child). Dismissed 2-2-21, weight 7½ lbs. Mother healthy but had Enteric 14 years ago. No further trace after dismissal.
Prev. Pregs.- 1st = CH.clz. & Forceps, S.B., F.T.: 2nd = normal, F.T., alive (died aged 6 weeks): 3rd = normal, alive, F.T.: 4th = normal, alive, F.T. (Decr., 1918).

961. W.R. Mother = Negative (3-5-). 1-2-21.
Child = Negative (3-5-). 28-1-21.

2nd Preg. Married. Age 24.
L.P. April, 1920. Normal pregnancy and labour. Child born 23-1-21, female, weight 7½ lbs. Dismissed 4-2-21, weight 6 lbs. 10 ozs. No trace after dismissal.
Prev. Preg. was normal, F.T., alive, in Novr., 1919.

962. W.R. Mother = Negative (3-5-). 1-2-21.
Child = Negative (3-5-). 28-1-21.

1st Preg. Married. Age 24.
L.P. ? May, 1920. Normal pregnancy - breech - long labour. Macerated foetus born 25-1-21 - male, weight 7 lbs. P.M. Patient a healthy woman - her mother died of carcinoma (liver).

Case No.

963. W.R. Mother = Negative (3-5-). 1-2-21.
Child = Negative (3-5-). 28-1-21.

2nd Preg. Married. Age 30.
L.P. 13-4-20. Normal pregnancy and labour. Child born 22-1-21, male, weight 7¼ lbs. Dismissed 31-1-21 weight 7½ lbs. 28-2-22 - Child very strong and healthy - now aged 13 months.
Previous pregnancy = normal, F.T., alive (Novr., 1919).

964. W.R. Mother = Negative (3-5-). 1-2-21.

1st Preg. Married. Age 24.
L.P. 4-6-20. Pregnancy was normal throughout except for occasional swelling of feet. Attended Antenatal Dispensary 28-1-21. Delivered in hospital 1-3-21 - male, mature, alive, weight 7 lbs. Dismissed 11-3-21. 22-2-22 - Child alive and well - has occasional 'convulsions'.

965. W.R. Mother = Negative (3-5-). 1-2-21.

1st Preg. Married. Age 34.
L.P. end Aug., 1920. Attended Antenatal Dispensary 28-1-21 - pain in lower part of abdomen and left side, constipation, varicose veins left leg. Female child born at home 2-6-21. 8-6-22 - Baby had Pneumonia but is now better: has ? Pyelitis. Now one year old.

Case No.

966. W.R. Mother = Strongly Positive (3+5+). 1-2-21.

1st Preg. Married. Age 24.
L.P. ? - irregular menstruation. Attended Antenatal Dispensary 28-1-21 -. Said to have had Appendicitis in June, 1920 (no operation). Amenorrhoea since then. Mastitis right breast. Did not return to dispensary. Home visit to patient at beginning of May, 1921 - not delivered. No treatment but promised to attend dispensary. Female child born at home 4-5-21 (G.R.M.H. outdoor dept. in attendance). 14-1-22 - Patient called to see doctor at hospital - Child appeared well at birth. One month after birth she took recurrent epistaries (explained by R.H.S.C. doctor to be snuffles). There was also green 'matter' from nose. She seemed almost unable to breathe. Rash noted at G.R.M.H. dispensary and powders given. Buttocks noted to become red after first month. Was unwell ever after first month. At fifth month took a swelling at the heel and was taken into Sick Children's hospital and operated on. Was in hospital one month but died. Mother pregnant three months now. Admitted to G.R.M.H. for second pregnancy 20-7-22. Amenorrhoea since first pregnancy. Leucorrhoea since first pregnancy and during this one. Normal labour - child born alive 20-7-22 - male, mature, weight 8½ lbs. length 19". Dismissed alive 31-7-22. -
W.R. Mother = Strongly Positive(3+5+)25-7-22.
Child = Strongly Positive (3+5+)25-7-22.

967. W.R. Mother = Negative (3-5-). 1-2-21.

6th Preg. Married. Age 32.
L.P. Septr., 1920. Attended Antenatal Disp. 28-1-21 - cough and pain in chest: sickness and vomiting - looks like T.B. Thin and pale.
Prev. Pregs.- 1st - 5th = F.T., alive, normal labours - three children dead now. Last child born 2½ years ago.

Case No.

968. W.R. Mother = Negative (3-5-). 1-2-21.
Child = Negative (3-5-). 1-2-21.

1st Preg. Single. Age 31.
L.P. 16-4-20. Normal pregnancy and labour - Child born 28-1-21 - Female, weight 8½ lbs. Spontaneous rotation from 4th to 1st vertex). R.P. Dismissed 10-2-21, weight 8¼ lbs.
18-11-21 - Child now aged 10 months and very healthy - never any illness.

969. W.R. Mother = Negative (3-5-). 1-2-21.
Child = Negative (3-5-).16-2-21.

4th Preg. Married. Age 27.
L.P. May or early June, 1920. Well till six weeks pregnant then had appendicitis (operation 30-6-20 in G.R.Infy.) - has not been well since - lump in right iliac region which is sometimes very painful. Admitted to Antenatal Dept. 27-1-21 - history of former uterine displacement - said to be in labour on admission but no pains. Dismissed 3-2-21- readmitted in labour 13-2-21 - head in pelvis and membranes not ruptured. 4th Vertex rotated and delivered as occipito Anterior - Child born 13-2-21 - male, weight 6 lbs. Dismissed 22-2-21, weight 6 lbs. No trace after dismissal.
Prev. Pregs.- 1st and 3rd = normal, F.T., alive (Last in Novr., 1915). 2nd = 2½ months abortion (Octr., 1914). Patient has had anaemia and debility - .

970. W.R. Mother = Negative (3-5-). 4-2-21.
Child = Negative (3-5-). 1-2-21.

9th Preg. Married. Age 34.
L.P. 14-4-20. Contracted Pelvis (Diag. Conj. = 4¼", True Conj. = 3½"). Transverse - History of sickness at intervals for last three months - well otherwise. On admission elbow presenting - foot brought down (version)- Child born 30-1-21 Female, weight 8 lbs. Child had a cold and developed a small patch of broncho-pneumonia but recovered and was well on dismissal on 14-2-21 and weighed 7 lbs. 21-2-22 - Child now aged one year and very well.
Prev. Pregs.- 4 F.T., 3 S.B. and 1 alive: 4 miscarriages.

Case No.

971. W.R. Mother = Negative (3-5-). 4-2-21.
Child = Negative (3-5-). 1-2-21.

5th Preg. Married. Age 29.
L.P. 5-5-20. Normal pregnancy and labour. Child born 30-1-21 - Female, weight 6½ lbs. Dismissed 9-2-21, weight 6 lbs. Child died of Pneumonia when aged nine months.
Prev. Pregs.- 1st - 4th = F.T., normal, living.

972. W.R. Mother = Negative (3-5-). 4-2-21.
Child = Negative (3-5-). 1-2-21.

1st Preg. Married. Age 19.
L.P. 12-4-20. Normal pregnancy - said to have been anaemic, but felt well throughout. Delayed second stage. Contracted Pelvis (Diag. Conj. = 4¼" -: True Conj. = 3½" -). Forceps. R.P. - Child born alive 31-1-21 - Female, weight 8½ lbs. During puerperium mother had Pyrexia, sore throat, scarlatiniform rash - sent to Ruchhill on 5-2-21 as suspected scarlet. Child dismissed 13-2-21. 23-2-22 - child aged 13 months and very well - never any illness.

973. W.R. Mother = Negative (3-5-). 4-2-21.
Child = Negative (3-5-). 1-2-21.

5th Preg. Married. Age 31.
L.P. 28-4-20. Normal pregnancy and labour - child born alive 30-1-21 - male, weight 8 lbs. Dismissed 9-2-21, weight 8 lbs. 22-5-22 - Child now 16 months old - had measles and whooping-cough but now well: Mother also well.

W.R. Mother = Negative (3-5-). 22-5-22.
Child = Negative (3-5-). 22-5-22.

Prev. Pregs.- 1st and 2nd = F.T., normal, living: 3rd = 7½ months, lived 4 days: 4th = F.T., S.B., Transverse (15-12-19).

Case No.

974. W.R. Mother = Negative (3-5-). 4-2-21.
Child = Negative (3-5-). 4-2-21.

1st Preg. Married. Age 27.
L.P. ?. Normal pregnancy. Persistent Occipito-posterior - spontaneous delivery: R.P. Child born 1-2-21, male, weight 7½ lbs. Dismissed 13-2-21, weight 8½ lbs. Perineum was slightly septic but cleared up before dismissal. 22-2-22 - Child alive and well - never any illness.

975. W.R. Mother = Strong. Pos. (3+5+). 4-2-21.
Child = (Strong) Pos. 3+5+). 1-2-21.

2nd Preg. Married. Age 25.
L.P. April, 1920. Normal pregnancy and labour but had "weak turns" and loss of power in legs throughout pregnancy. Child born 31-1-21 - Male, weight 7¼ lbs. Dismissed 9-2-21, weight 6½ lbs. Attending G.R.M.H. Infant Consultations - child very cross and has a rash - Going to R.H.S.C. for treatment - blood tested there - W.R. = Negative.7-6-21. Mother herself not feeling well but nothing definite. 16-2-22 - Home visited - Both well-baby now one year old.
Prev. Preg. - = F.T., living, Forceps (31-3-17).

976. W.R. Mother = Negative (3-5-). 4-2-21.
Child = Negative (3-5-). 4-2-21.

1st Preg. Married. Age 29.
L.P. May, 1920. Normal pregnancy, premature labour (About 8 months). R.P. Child born 1-2-21, female, premature, weight 5¼ lbs., died 14-2-21.

977. W.R. Mother = Negative (3-5-). 4-2-21.

4th Preg. Married. Age 25.
L.P. ? Normal pregnancy. Contracted Pelvis (Diag. Conj. = 3¾"-, True Conj. = 3"-). Spontaneous delivery - child born alive 31-1-21, Female, weight 6¼ lbs. Dismissed 10-2-21, weight 6 lbs. 22-2-22 - Child aged 13 months and reported to be very well.
Prev. Pregs.- 1st = F.T., S.B.: 2nd = Miscarr. at 3 months: 3rd = F.T., living,(Forceps.).

Case No.

978. W.R. Mother = Negative (3-5-). 4-2-21.
Child = Negative (3-5-). 1-2-21.

9th Preg. Married. Age 40.
L.P. ?. Felt well throughout pregnancy till one month before admission when she noticed when she noticed swelling of feet and legs and felt very tired - no other complaint. Admitted 31-1-21 - impacted breech - very pale and anaemic: slight oedema: slight V.S. murmur at apex: no albuminuria: pelvis slightly contracted: Child born dead 31-1-21- male, mature, weight 7 lbs. Mother's blood examined and showed anaemia of pernicious type. Seen again a month after dismissal - improved but still considerable anaemia.
Previous pregs.- 1st = miscarriage at five months: All others full-time, living, normal (Last in Octr., 1917). No history of serious illness.

979. W.R. Mother = Negative (3-5-). 4-2-21.
Child = Negative (3-5-). 1-2-21.

1st Preg. Married. Age 29.
L.P. 20-4-20. Normal pregnancy. Impacted Breech. Contracted Pelvis (C.V. = 3½"). Albuminuria (0.2%). Fairly marked oedema of feet and legs. Breech pushed up and legs brought down. R.P. Some P.P.H. Child's arm fractured during delivery. Child born 30-1-21 - Female, weight 7½ lbs. Dismissed 2-4-21. Mother had parametritis during puerperium. No previous serious illness. Prolapse treated with pessaries. Patient was in bed for six weeks after dismissal from hospital - Peritonitis. Baby getting on well. 30-3-22 - Baby now aged 14 months - Both well. W.R. Mother = Neg. (3-5-).30-3-22.
Child = Neg. (3-5-).30-3-22.

980. W.R. Mother = Negative (3-5-). 9-2-21.
Child = Negative (3-5-). 1-2-21.

2nd Preg. Single. Age 22.
L.P. ? May, 1920. Normal pregnancy. Face presentation: Spontaneous delivery - child born 30-1-21, Female, alive, weight 7 lbs. Dismissed 8-2-21. No trace after dismissal.
Prev. Preg.- 1st = F.T., living - Instrs.

Case No.

981. W.R. Mother = Negative (3-5-). 4-2-21.
Child = Negative (3-5-). 1-2-21.

1st Preg. Single. Age 17.
L.P. ? 1-6-20. Normal pregnancy and labour. R.P. Child born alive 28-1-21, female, weight 5¾ lbs. Febrile puerperium - no uterine cause but thought to be influenzal. Dismissed 10-2-21, weight 5½ lbs. No further trace.

982. W.R. Mother = Negative (3-5-). 4-2-21.
Child = Negative (3-5-). 4-2-21.

1st Preg. Married. Age 26.
L.P. 27-4-20. Normal pregnancy and labour - Child born alive 1-2-21 - male, weight 5 lbs., mature. Mother was transferred to Ruchhill Hospital on 5-2-21 as suspected scarlet fever. Was in Bellfield Sanatorium for four months three years ago - had Haemoptysis - looked healthy on admission to G.R.M.H. and no sign of active disease in chest. Child dismissed from hospital on 9th Feby. but died at home on 10th Feby. Mother died in Ruchhill on 10-2-21.

983. W.R. Mother = Negative (3-5-). 4-2-21.
Child = Negative (3-5-). 1-2-21.

1st Preg. Single. Age 20.
L.P. March, 1920. Slight pain (intermittent) for one week before admission. Pregnancy was otherwise normal. Child born (normal labour) 27-1-21 - Female, weight 6¼ lbs. Dismissed 5-2-21, weight 6¼ lbs.
22-2-22 - Child now aged 13 months and reported to be well.

984. W.R. Mother = Negative (3-5-). 4-2-21.
Child = Negative (3-5-). 4-2-21.

1st Preg. Single. Age 21.
L.P. early April, 1920. Normal pregnancy and labour - Child born alive 1-2-21 - male, weight 8¼ lbs. Dismissed 10-2-21, wt. 9 lbs.
22-2-22 - Child now aged one year and very healthy - never any illness.

Case No.

985. W.R. Mother = Negative (3-5-). 4-2-21.
Child = Negative (3-5-). 1-2-21.

1st Preg. Married. Age 21.
L.P. April, 1920. Normal pregnancy. About 36 hours labour - Forceps: R.P. (delayed 2nd stage). Child born 28-1-21, female, weight 7 lbs. Dismissed 8-2-21. Mother and child both well when child was aged 13 months.

986. W.R. Mother = Negative (3-5-). 4-2-21.
Child = Negative (3-5-). 1-2-21.

5th Preg. Married. Age 27.
L.P. April, 1920. Patient has not felt well throughout present pregnancy. Vague pains but nothing definite. Normal labour - child born 28-1-21, male, weight 9½ lbs. Dismissed 7-2-21, weight 9 lbs. 21-2-22 - Child alive and well - now aged 13 months. Never any illness.
Prev. Pregs.- 1st = 7½ months, S.B.: 2nd = F.T., living, CH.clz. & Instrs.: 3rd = 7½ months, living, CH.clz. & Instrs.: 4th = F.T., living, normal delivery (May, 1918). Had T.B. abscess in neck as a child.

987. W.R. Mother = Negative (3-5-). 4-2-21.
Child = Negative (3-5-). 1-2-21.

1st Preg. Single. Age 26.
L.P. April, 1920. Feet and legs swollen for about six weeks. Albuminuria (+++) - marked oedema of feet and legs. Normal delivery - child born 31-1-21 - male, weight 7½ lbs. Dismissed 10-2-21, weight 7 lbs. Both well on dismissal. Child died - Enteritis - on 27-11-21.

Case No.

988. W.R. Mother = Positive (3+5-). 9-2-21.

1st Preg. Married. Age 24.
L.P. 16-3-20. Vomiting and pain in back - Attended Antenatal Dispensary 4-2-21. Husband on treatment (for what?). Admitted 26-2-21 - normal labour - Child born 26-2-21, female, weight 7¾ lbs. Dismissed 10-3-21, weight 8¼ lbs. No trace since dismissal.

989. W.R. Mother = Negative (3-5-). 9-2-21.

1st Preg. Married. Age 20.
L.P. 28-6-20. Attended Antenatal Dispensary 4-2-21 - pain in left side: Constipation: Had very slight haemorrhage at three months. Generally contracted pelvis (Intr. 9¼" Intrasp. 10¼"). Male child born at home on 27-3-21 - own doctor in attendance.

990. W.R. Mother = Negative (3-5-). 11-2-21.

5th Preg. Married. Age 26.
L.P. July, 1920. Attended Antenatal Dispensary 4-2-21 - painful scar. Contracted Pelvis (C.V. = 3"). Had operation for Hernia in G.R.I. in 1920. Admitted to Antenatal Dept. 14-2-21 - 6 months pregnant. Ventral hernia through abdominal scar - band in Pouch of Douglas from left side. Dismissed 16-2-21. Readmitted 29-3-21 - symptoms suggesting intestinal obstruction. Caesarean Section - child born 29-3-21, Female, weight 5¾ lbs. died 12-4-21.
Prev. Pregs.- 1st - 3rd = Normal, F.T., alive: 4th = miscarriage in Samaritan Octr., 1919 (3 months).

Case No.

991. W.R. Mother = Negative (3-5-). 9-2-21.
Child = Negative (3-5-). 9-2-21.

2nd Preg. Married. Age 24.
L.P. April, 1920. Normal pregnancy and labour - but had false labour for 2-3 days before. Child born alive 3-2-21, Female, weight 8 lbs. Dismissed 12-2-21, weight 8 lbs.
2-12-21 - Child now aged 10 months - had a bad attack of influenza and has never been quite well since.
Prev. Pregs.- 1st = normal, F.T., CH.clz. & Instrs. (Jany., 1919).

992. W.R. Mother = Strongly Positive (3+5+).9-2-21.
Child = Strongly Positive (3+5+).4-2-21.

3rd Preg. Single. Age 33.
L.P. May, 1920. Normal pregnancy and labour - Child born alive 1-2-21 - male, weight 6¼ lbs. Dismissed 10-2-21, weight 6½ lbs.
28-7-21 - Home visit paid - Child had Ophthalmia but otherwise well. No further trace.
Prev. Pregs.- 1st and 2nd. = F.T., normal, alive (Last in Novr., 1919).

993. W.R. Mother = Negative (3-5-). 9-2-21.

1st Preg. Married. Age 21.
L.P. April, 1920. Eclampsia: (B.B.A.). Felt well till last fortnight of pregnancy then had a good deal of vomiting - no headache or disturbance of vision. Child born 31-1-21 - male. Mother began to take fits after delivery. She had ten in all before admission at 3 a.m. on 1-2-21. Dismissed 12-2-21. 22-2-22 - Child now aged 13 months and reported to be very well: never any illness.

Case No.

994. W.R. Mother = Negative (3-5-). 9-2-21.
Child = Negative (3-5-). 4-2-21.

2nd Preg. Married. Age 24.
L.P. 10-7-21. Had morning sickness at commencement of pregnancy but was otherwise well. Twins born 1-2-21 - 1st = Breech presentation, Female, born alive, weight 3 lbs. died 3-2-21: 2nd = Transverse presentation, male, weight 4 lbs. born alive and died 4-2-21.
Prev. Preg. = normal, alive (8 months).

995. W.R. Mother = Negative (3-5-). 9-2-21.
Child = Strongly Positive (3+5+). 4-2-21.

1st Preg. Single. Age 20.
L.P. 1-7-20. Normal pregnancy and (7 months) labour. Child born 2-2-21 - female, weight 4 lbs., died 2-2-21. Mother dismissed 14-2-21. Patient's mother died of cancer: her father is alive: her only sister is alive and well. Patient was married soon after dismissal from hospital and was admitted to hospital again on 12-2-22 for 2nd confinement.
2nd Preg. Married. Age 21.
L.P. 20-4-21. Normal pregnancy and labour - child born alive 12-2-22, male, mature, weight 5½ lbs., died 20-2-22.
W.R. Mother = Strongly Positive (3+5+).17-2-22.
Child = Strongly Positive (3+5+).22-2-2w.

996. W.R. Mother = Strongly Positive (3+5+).9-2-21.
Child = Negative (3-5-). 4-2-21.

2nd Preg. Single. Age 22.
L.P. 14-6-20. Normal pregnancy. Pains in hips for last fortnight of pregnancy. Normal labour - child born 1-2-21 - male, weight 6 lbs., died 10-2-21, weight 4¼ lbs.
Prev. Preg.- = normal, F.T.

Case No.

997. W.R. Mother = Doubtfully Negative. 9-2-21.

1st Preg. Single. Age 26.
L.P. May or June, 1920. Contracted Pelvis (Diag. Conj. = 3¾" -, True Conj. = 3"-). Admitted to Antenatal Dept. 2-2-21 - marked rickets: V.S. murmur at ventral area : no albuminuria. Caesarean section after onset of labour - child born alive 21-2-21 - male, weight 8 lbs. Mother developed pulmonary symptoms - dulness and friction left base and dulness and rales right leg - died 2-3-21. P.M.- Chronic T.B. pneumonia with acute exacerbation: Mitral stenosis and syphilitic aortitis.

998. W.R. Mother = Strongly Positive (3+5+).

1st Preg. Married. Age 31. L.P. April, 1920. Normal pregnancy. Impacted Breech: ? Forceps outside. Contracted Pelvis (Diag. Conj. = 3¾" - True Conj. = 3¼" -). Fairly large child - difficulty in getting 2nd arm down. Perforation aftercoming head: Bad R.P. (went septic). Child - male, weight 8 lbs. 1 oz. - dead.

999. W.R. Mother = Negative (3-5-). 9-2-21.

2nd Preg. Married. Age 31.
L.P. 27-6-21. Admitted to Antenatal Dept. 3-2-21. Normal pregnancy. Contracted Pelvis (Diag. Conj. = 4½" -, True Conj. = 3¾" -. Outlet much contracted). Dismissed 5-2-21. Readmitted 27-2-21 - Caesarean Section 28-3-21 (patient sterilised) Child born 28-3-21 - male, weight 9¾ lbs. Dismissed 16-4-21, weight 10 lbs.
22-2-22 - Child now 11 months old and very healthy - never a day's illness.
Prev. Preg.- 1st = F.T., S.B. (craniotomy) 22-1-20. A healthy woman - irregular menstruation.

Case No.

1000. W. R. Mother = Negative. 1-2-21.
Mother = Negative. 1-5-21.
Child = Negative. 5-5-21.

1st Preg. Married. Age 23.
L.P. 13-6-20. Admitted Antenatal Dept.
2-2-21 - Debility. Felt well till 14 days before admission since when she has had several fainting turns - sometimes swelling of feet and legs : some headache: no vomiting. Dismissed, much improved, 11-2-21 (no albuminuria). Readmitted 27-4-21 - normal labour - child born alive 28-4-21, male, weight 7½ lbs. Dismissed 7-5-21, weight 8 lbs.
22-5-22 - Child one year old and very well- mother also well.
W.R. Mother = Negative (3-5-). 22-5-22.
Child = Negative (3-5-). 22-5-22.