

Lymph Node Metastasis in Auricular
Squamous Cell Carcinoma

MD Thesis

Richard R Clark

Faculty of Medicine
University of Glasgow

Acknowledgements

I am indebted to many people who have helped me in the preparation of this work. My posthumous appreciation goes to D Gordon MacDonald, Professor of Oral Pathology, University of Glasgow who was instrumental in the design and early work of this thesis. He unfortunately passed away before it was complete.

David Soutar has been my mentor throughout and has spent a great deal of time suggesting corrections and amendments. Taimur Shoaib and Stephen Morley have provided invaluable advice and help with sections of the work and assisted in proof reading. Keith Hunter, Alan McPhaden and Lorna Cooper and the staff of the pathology department at Glasgow Royal Infirmary, the many members of the Head and Neck team at Canniesburn Plastic Surgery Unit, the Outpatient department staff and the Operating department staff have my unreserved gratitude for their help and support.

Canniesburn Research Trust and Glasgow Royal Infirmary Research and Development fund have provided financial support. Without their funding none of this work would have been possible.

Summary

Introduction

Squamous cell carcinoma of the auricle has an unusually high rate of lymph node metastases when compared to similar tumours at other sites. The lymph nodes affected are close to the base of the skull and in the neck. Development of metastasis carries a poor prognosis and most patients will subsequently die of failure of loco-regional control. Despite the likelihood of a poor outcome nothing can be done for patients prior to development of metastasis, as the risk of spread is not sufficiently high to warrant intervention in all patients. They are therefore treated with a 'wait and see policy' and only offered treatment once clinical evidence of metastatic spread is detected.

This thesis sets out to examine what can be done, at the time of initial presentation with an auricular squamous cell carcinoma to identify patients who would benefit from treatment to the regional lymph node basins.

Materials and Methods

The thesis is divided into four separate studies. A systematic review examines the evidence available to date, an anatomical study examines the lymphatic drainage of the auricle in cadavers, a sentinel lymph node biopsy study examines the use of this technique to identify early tumour spread and a retrospective analysis of cases of auricular squamous cell carcinoma in our unit examines histopathological prognostic indicators of metastatic spread.

Results

The systematic review found that these tumours have a metastatic rate of about 11%. Patients developing metastasis usually die from

failure of loco-regional control. Depth of tumour invasion, tumour size and mode of invasion seem to be potential indicators of metastatic risk. There is a strong argument for prophylactic intervention to the regional lymph nodes but there is no consensus of opinion as to when this should be carried out

The anatomical study comprised 5 cadaveric dissections. They showed that the first echelon nodes draining the auricle lie in the superficial parotid gland, post-auricular/ mastoid nodal group and level II of the neck. There are anastamotic pathways around the mastoid and post-auricular nodes that could permit embolic tumour cells to bypass them. Five lymphatic pathways draining the auricle are described and some of these lie on the lateral and anterior surfaces of the mastoid bone and traverse the insertion of sternocleidomastoid.

28 cases of auricular squamous cell carcinoma were enrolled for sentinel lymph node biopsy. None of them were found to have any metastatic spread. One case showed non-viable tumour cells in a lymph node. There was a high incidence of complications (14%) directly related to the sentinel node biopsy procedure.

The retrospective analysis identified 229 cases of auricular squamous cell carcinoma treated in our unit from 1992 - 2004. 212 of these cases had the primary pathology available for analysis. 24 (of 212) patients developed metastasis. 17 patients died as a result of their disease usually due to failure of control at the regional lymph node basin. Primary tumours with a depth of invasion greater than 8mm have metastatic rate of 56%. Tumours with a depth of invasion between 2-8mm and evidence of cartilage destruction, lymphovascular invasion or a non-cohesive invasive front have 24% metastatic rate. Tumours outwith these high-risk groups did not metastasise.

Conclusions

Elective lymph node dissections of the superficial parotid gland, post-auricular/mastoid and level II nodes should be considered in patients with primary auricular squamous cell carcinomas with a depth of invasion >8mm or a depth of invasion between 2 - 8 mm and evidence of cartilage destruction, lymphatic invasion or a non-cohesive invasive front. This should ideally be done as part of an observational study to evaluate the cost / benefit ratio for these patients.

The neck dissection must clear the mastoid bone to a sub-periosteal level on its anterior and lateral surfaces. This will require the removal of the upper portion of sternocleidomastoid.

Sentinel lymph node biopsy requires further study to evaluate it as a method for early detection of metastatic spread in auricular squamous cell carcinoma. This could be done as part of an observational study of elective neck dissections.

ACKNOWLEDGEMENTS	2
SUMMARY	3
INDEX OF TABLES.....	11
INDEX OF FIGURES.....	12
GENERAL INTRODUCTION.....	15
GENERAL MATERIALS AND METHODS	22
PROGNOSTIC FACTORS IN DEVELOPMENT OF LYMPH NODE METASTASES FROM AURICULAR SQUAMOUS CELL CARCINOMA A SYSTEMATIC REVIEW.....	23
SUMMARY	24
INTRODUCTION	25
BACKGROUND	25
BURDEN OF DISEASE	26
MANAGEMENT OF DISEASE.....	28
THE AURICLE AS A SITE OF MALIGNANCY.....	30
MATERIALS AND METHODS	33
ELECTRONIC SEARCH STRATEGIES.....	35
RESULTS.....	37
WHAT IS THE METASTATIC RATE?	38
WHERE DO METASTASES DEVELOP?	41
SURVIVAL AND MORTALITY	43
MORBIDITY	44
TIME TO DEVELOPMENT OF METASTASES	45
DOES TUMOUR SIZE PREDICT DEVELOPMENT OF METASTASES?	46
DOES DEPTH OF INVASION PREDICT DEVELOPMENT OF METASTASES?	47
DOES MODE OF INVASION PREDICT DEVELOPMENT OF METASTASES?	48
DOES THE DEGREE OF CELLULAR DIFFERENTIATION PREDICT DEVELOPMENT OF METASTASES?	49

DOES LOCATION OF THE PRIMARY TUMOUR PREDICT DEVELOPMENT OF METASTASES?	49
DO EXCISION MARGINS PREDICT DEVELOPMENT OF METASTASES?	49
IS THERE GUIDANCE ON WHEN TO PROPHYLACTICALLY TREAT THE LYMPH NODE BASINS?	50
PROPHYLACTIC VERSUS THERAPEUTIC LYMPH NODE DISSECTIONS?	50
DISCUSSION	51
CONCLUSIONS	55
A CADAVERIC STUDY OF AURICULAR LYMPHATICS AND IMPLICATIONS FOR SENTINEL LYMPH NODE BIOPSY AND LYMPHADENECTOMY PROCEDURES.....	56
SUMMARY	57
INTRODUCTION	58
MATERIALS AND METHODS	63
SPECIMEN ONE	69
SPECIMEN TWO.....	72
SPECIMEN THREE.....	75
SPECIMEN FOUR	81
SPECIMEN FIVE.....	84
DISCUSSION	86
SUMMARY OF RESULTS	86
STRENGTHS AND WEAKNESSES OF THIS STUDY	89
COMPARISON WITH THE WORK OF OTHERS.....	91
MEANING OF THIS STUDY	92
UNANSWERED QUESTIONS AND FUTURE RESEARCH.....	93
CONCLUSIONS	94
SENTINEL LYMPH NODE BIOPSY FOR AURICULAR SQUAMOUS CELL CARCINOMA.....	95
SUMMARY	96
INTRODUCTION	97
THE SENTINEL NODE CONCEPT	98

HISTORY OF SENTINEL NODE BIOPSY	99
THE CURRENT USE OF SENTINEL LYMPH NODE BIOPSY	100
POTENTIAL USEFULNESS IN AURICULAR SCC	101
STUDY DESIGN	102
MATERIALS AND METHODS.....	105
PATIENT RECRUITMENT AND ENROLMENT	105
PRE-OPERATIVE LYMPHOSCINTIGRAPHY	107
OPERATIVE TECHNIQUE	109
HISTO-PATHOLOGICAL PROCESSING	110
POST-OPERATIVE MANAGEMENT	111
RESULTS.....	112
HISTO-PATHOLOGICAL FINDINGS	114
COMPLICATIONS OF TREATMENT	120
LOCATION OF SENTINEL NODES AND LYMPHATIC PATHWAYS.....	123
FOLLOW-UP PERIOD	129
DISCUSSION	130
SUMMARY OF FINDINGS	130
STRENGTHS AND WEAKNESSES OF THIS STUDY	131
COMPARISON WITH THE WORK OF OTHERS	132
MEANING OF THE STUDY	133
UNANSWERED QUESTIONS AND FUTURE RESEARCH.....	134
CONCLUSIONS.....	135
A RETROSPECTIVE ANALYSIS OF PROGNOSTIC FACTORS FOR DEVELOPMENT OF LYMPH NODE METASTASES FROM AURICULAR SQUAMOUS CELL CARCINOMA	136
SUMMARY	137
INTRODUCTION	138
THE SETTING OF THE STUDY	139
MATERIALS AND METHODS	140
HISTOPATHOLOGICAL ANALYSIS	141

STATISTICAL ANALYSIS	141
RESULTS.....	142
METASTASIS	145
TUMOUR DIMENSIONS.....	148
ADVERSE HISTOLOGICAL FEATURES.....	157
COMBINING TUMOUR VOLUME AND DEPTH WITH ADVERSE HISTOLOGICAL FEATURES	170
SURGICAL RESECTION MARGINS & LOCAL RECURRENCE.....	176
DEGREE OF HISTOLOGICAL DIFFERENTIATION	176
DISCUSSION	178
SUMMARY OF FINDINGS	178
STRENGTHS AND WEAKNESSES OF THIS STUDY	179
COMPARISON WITH THE WORK OF OTHERS.....	180
MEANING OF THIS STUDY	181
UNANSWERED QUESTIONS AND FUTURE RESEARCH.....	183
CONCLUSIONS.....	184
WHAT NECK DISSECTION FOR MALIGNANT TUMOURS OF THE AURICLE?	185
SUMMARY	186
INTRODUCTION	187
MATERIALS AND METHODS.....	189
RESULTS.....	190
DISCUSSION	192
GENERAL DISCUSSION	196
SUMMARY OF FINDINGS	196
STRENGTHS AND WEAKNESSES	197
MEANING OF THE THESIS	198
UNANSWERED QUESTIONS AND FUTURE RESEARCH	199
CONCLUSIONS.....	201
APPENDIX 1 – ETHICAL CONSIDERATIONS.....	203

APPENDIX 2 – NECK DISSECTION TERMINOLOGY	211
LYMPH NODE GROUPS FOUND WITHIN THE 6 LEVELS AND THE 6 SUBLEVELS.....	211
CLASSIFICATION OF NECK DISSECTION	214
<i>RADICAL NECK DISSECTION</i>	214
<i>MODIFIED RADICAL NECK DISSECTION</i>	214
<i>SELECTIVE NECK DISSECTION</i>	215
<i>EXTENDED NECK DISSECTION</i>	215
REFERENCES.....	216

Index of Tables

<i>Table 1 - Summary of Metastatic Rates.....</i>	<i>40</i>
<i>Table 2 - Location of metastatic disease.....</i>	<i>42</i>
<i>Table 3 - Summary of Deaths Directly Attributable to Disease.....</i>	<i>44</i>
<i>Table 4 - Time to Development of Metastases.....</i>	<i>45</i>
<i>Table 5 - Clark's levels.....</i>	<i>47</i>
<i>Table 6 - Scoring system for Mode of Invasion used by Afzelius.....</i>	<i>48</i>
<i>Table 7 - Summary of Specimen and embalming infiltration details.....</i>	<i>66</i>
<i>Table 8 - Inclusion and exclusion criteria.....</i>	<i>106</i>
<i>Table 9 - Histo-pathological features of primary tumours.....</i>	<i>115</i>
<i>Table 10 – Number of Tumours with Potentially Adverse Prognostic Indicators.....</i>	<i>119</i>
<i>Table 11 - Complications of Treatment.....</i>	<i>122</i>
<i>Table 12 - Distribution of nodal location.....</i>	<i>126</i>
<i>Table 13 - Identification of Nodes.....</i>	<i>127</i>
<i>Table 14 - Length of Follow Up.....</i>	<i>143</i>
<i>Table 15 - SPSS Output Table - Descriptive Statistics.....</i>	<i>150</i>
<i>Table 16 - SPSS Output Table - Ranks.....</i>	<i>151</i>
<i>Table 17 - SPSS Output Table - Test Statistics.....</i>	<i>152</i>
<i>Table 18 - Metastatic Rates Stratified by Tumour Volume.....</i>	<i>154</i>
<i>Table 19 - Metastatic Rates Stratified by Depth of Invasion.....</i>	<i>156</i>
<i>Table 20 - Combining Tumour Volume With Adverse Histological Parameters.....</i>	<i>171</i>
<i>Table 21 - Combining Tumour Depth of Invasion With Adverse Histological Parameters.....</i>	<i>172</i>
<i>Table 22 - Comparison of Metastatic Rates in High Risk Tumours Identified by Volume and Depth of Invasion.....</i>	<i>173</i>
<i>Table 23 - Mortality from Metastases Stratified by High Risk Categories.....</i>	<i>174</i>
<i>Table 24 - Dimensions and Pathological Features of Tumours That Metastasised ...</i>	<i>175</i>
<i>Table 25 - Metastatic Rates In Subgroups of Histological Differentiation.....</i>	<i>177</i>
<i>Table 26 – Lymph node basins involved with metastatic spread.....</i>	<i>191</i>

Index Of Figures

<i>Figure 1 - A Locally recurrent Auricular Squamous Cell Carcinoma with Metastatic Deposits Bulging below the Auricle</i>	<i>17</i>
<i>Figure 2 - The Resected Tissue. Brass tags Indicate Levels of The Neck Dissection ...</i>	<i>18</i>
<i>Figure 3 The Resulting Defect showing exposed Temporal Bone. The Mastoid process has been trimmed.....</i>	<i>19</i>
<i>Figure 4 - A Transverse Rectus Abdominus Myocutaneous Flap used to reconstruct the defect.....</i>	<i>20</i>
<i>Figure 5 - The flap Inset with a plastic tube to maintain the neo-auditory canal</i>	<i>21</i>
<i>Figure 6 - CSSC Registrations In Scotland 1980 - 2000</i>	<i>27</i>
<i>Figure 7 - Funnel Plot of Metastatic rates.....</i>	<i>39</i>
<i>Figure 8 - Diagrammatic representation of auricular lymphatics reproduced from Kubrick's Textbook of Lymphology</i>	<i>62</i>
<i>Figure 9 - An ear showing staining after injection and massage.....</i>	<i>65</i>
<i>Figure 10 - Flow Diagram of Specimen Processing</i>	<i>67</i>
<i>Figure 11 - Specimen One Lateral View.....</i>	<i>70</i>
<i>Figure 12 - Specimen One Closeup Lateral View Showing Stained Nodes And Connecting Lymphatics</i>	<i>71</i>
<i>Figure 13 - Specimen Two Lateral View.....</i>	<i>73</i>
<i>Figure 14 - Specimen Two Closeup Medial View</i>	<i>74</i>
<i>Figure 15 - Specimen Three Medial View.....</i>	<i>76</i>
<i>Figure 16 - Specimen Three Closeup Medial View Demonstrating The Proximity of First Echelon Nodes to The Mastoid Bone at The Insertion Of The Sternocleidomastoid Muscle</i>	<i>77</i>
<i>Figure 17 - Lymphatic Pathways In Specimen Three</i>	<i>78</i>
<i>Figure 18 - 3D Stereogram of Specimen 3 for Parallel Viewing</i>	<i>79</i>
<i>Figure 19 - 3D Stereogram of Specimen 3 for Cross-eyed Viewing</i>	<i>80</i>
<i>Figure 20 - Specimen Four Medial View.....</i>	<i>82</i>
<i>Figure 21 - Close up Medial View of Specimen Four.....</i>	<i>83</i>
<i>Figure 22 - Specimen Five Lateral View</i>	<i>85</i>

<i>Figure 23 - Diagrammatic representation of lymphatic pathways from the auricle to first echelon lymph nodes.....</i>	<i>88</i>
<i>Figure 24 - A typical Pre-operative Lymphoscintigram Showing Superiorly an Image with a lead mask over the Primary Tumour and Inferiorly an Image Without. Nodes are visible Pre and Post-Auricular and in the tail of the parotid gland.</i>	<i>108</i>
<i>Figure 25 - Location of Primary Tumours.....</i>	<i>113</i>
<i>Figure 26 – Cytokeratin stained cells at 40x Magnification</i>	<i>117</i>
<i>Figure 27 – Adjacent section stained with haematoxylin & eosin 40x</i>	<i>118</i>
<i>Figure 28 - Locations of Sentinel Nodes.....</i>	<i>125</i>
<i>Figure 29 – A flap raised showing the position of the greater auricular nerve and blue stained nodes.....</i>	<i>128</i>
<i>Figure 30 - Site of Primary Tumours</i>	<i>144</i>
<i>Figure 31 - Location of Metastases.....</i>	<i>147</i>
<i>Figure 32 - Boxplot of Depth of Invasion In Tumours That Metastasised and That Did Not Metastasise.....</i>	<i>149</i>
<i>Figure 33 - Tumour abutting cartilage with compression of the peri-chondrium. H&E stain.</i>	<i>158</i>
<i>Figure 34 - Close-up of tumour abutting cartilage.</i>	<i>158</i>
<i>Figure 35 - Tumour showing smooth erosion of the cartilage. H&E stain.</i>	<i>159</i>
<i>Figure 36 - Close-up of tumour erosion of cartilage.</i>	<i>159</i>
<i>Figure 37 - Superficial erosion of the cartilage. H&E stain.</i>	<i>160</i>
<i>Figure 38 - Close-up of superficial cartilage erosion.....</i>	<i>160</i>
<i>Figure 39 - Tumour showing destruction of cartilage with loss of perichondrium and destructive loss of bulk. H&E stain.</i>	<i>161</i>
<i>Figure 40 - Close-up of cartilage destruction.</i>	<i>161</i>
<i>Figure 41 - Tumour Invasion of a Lymphatic Vessel. H&E stain</i>	<i>163</i>
<i>Figure 42 - Tumour invasion of a vascular channel. H&E stain.</i>	<i>164</i>
<i>Figure 43 - Peri-neural invasion. H&E stain.....</i>	<i>166</i>
<i>Figure 44 - A non-cohesive invasive front. H&E stain.</i>	<i>168</i>
<i>Figure 45 - Close-up of non-cohesive invasive front.</i>	<i>168</i>
<i>Figure 46 - A focally non-cohesive invasive front. H&E stain.....</i>	<i>169</i>

<i>Figure 47 - Close-up of a focally non-cohesive invasive front.....</i>	<i>169</i>
<i>Figure 48 - Illustration of superficial level lymph nodes.....</i>	<i>194</i>
<i>Figure 49 - Illustration of deep level lymph nodes.....</i>	<i>195</i>

General Introduction

The need for the research that this thesis encompasses was born out of clinical experience in Canniesburn Plastic Surgery Unit. This unit frequently deals with patients who have Squamous Cell Cancer of the Auricle and some of these are unfortunate enough to develop lymph node metastases. This is not an unusual development following many forms of cancer but it is rare from cutaneous squamous cell carcinoma. The auricle has however been noted by many to be a site from which cutaneous squamous cell cancer is more likely to spread to the regional lymph nodes although the reasons for this are not clear.¹⁻³ The treatment for spread of the cancer to the regional lymph nodes is often surgical in the form of a lymphadenectomy procedure or neck dissection as it more commonly known. This can often be curative provided surgical resection is complete and no disease is left behind. Radiotherapy can be used in place of or as an adjunct to surgery in some cases.⁴⁻⁶

Surgical resection of lymph node metastases from auricular squamous cell carcinoma is complicated by the location of the lymph nodes to which it spreads. They are located in the post-auricular, mastoid, parotid and upper cervical lymph node basins. They are anatomically very close to the base of the skull, temporo-mandibular joint, the facial nerve, the internal jugular vein and the internal carotid artery. Their proximity to these structures means that resection of the lymph nodes can be difficult at best and life-threatening at worst. All too often spread of the cancer to the lymph nodes is not detected until the tumour has grown out of the lymph node and invaded the adjacent tissues. At this point surgical resection becomes much more complicated as in order to achieve loco-regional control of the disease, all invaded structures must be

removed whether it be nerve vessel or bone. This has lead to descriptions in published literature of massive resections for these tumours involving the temporal bone, mandible and associated soft tissue structures.⁷ Such surgery is obviously a major undertaking and causes significant morbidity to any patient undergoing such a procedure. Unfortunately in many patients because of the extent of disease it is not possible to achieve loco-regional control with surgery and post-operative radiotherapy. Treatment of these patients therefore becomes palliative. Squamous cell carcinoma of the auricle is more common in the elderly population where other medical conditions, particularly cardiac and respiratory, are also common. This compounds the problem of treatment of established metastasis.

It would be preferable if the spread of the disease to the lymph nodes could either be predicted or detected before invasion of important structures had occurred. This would allow for treatment of the lymph node basins only in those patients who would most benefit from it and would not require as extensive a resection as is required once disease had become established. Such treatment could be in the form of an elective neck dissection or radiotherapy which is effective in the treatment of early metastatic spread.^{5, 6}

The following pages show a series of photos of a patient who developed local recurrence and lymph node metastases from a primary auricular squamous cell carcinoma. (Figures 1-5) The patient underwent an extensive resection and was given post-operative radiotherapy to try to contain the disease. Unfortunately he developed an infection at the operative site, became septic and subsequently died during his radiotherapy treatment.

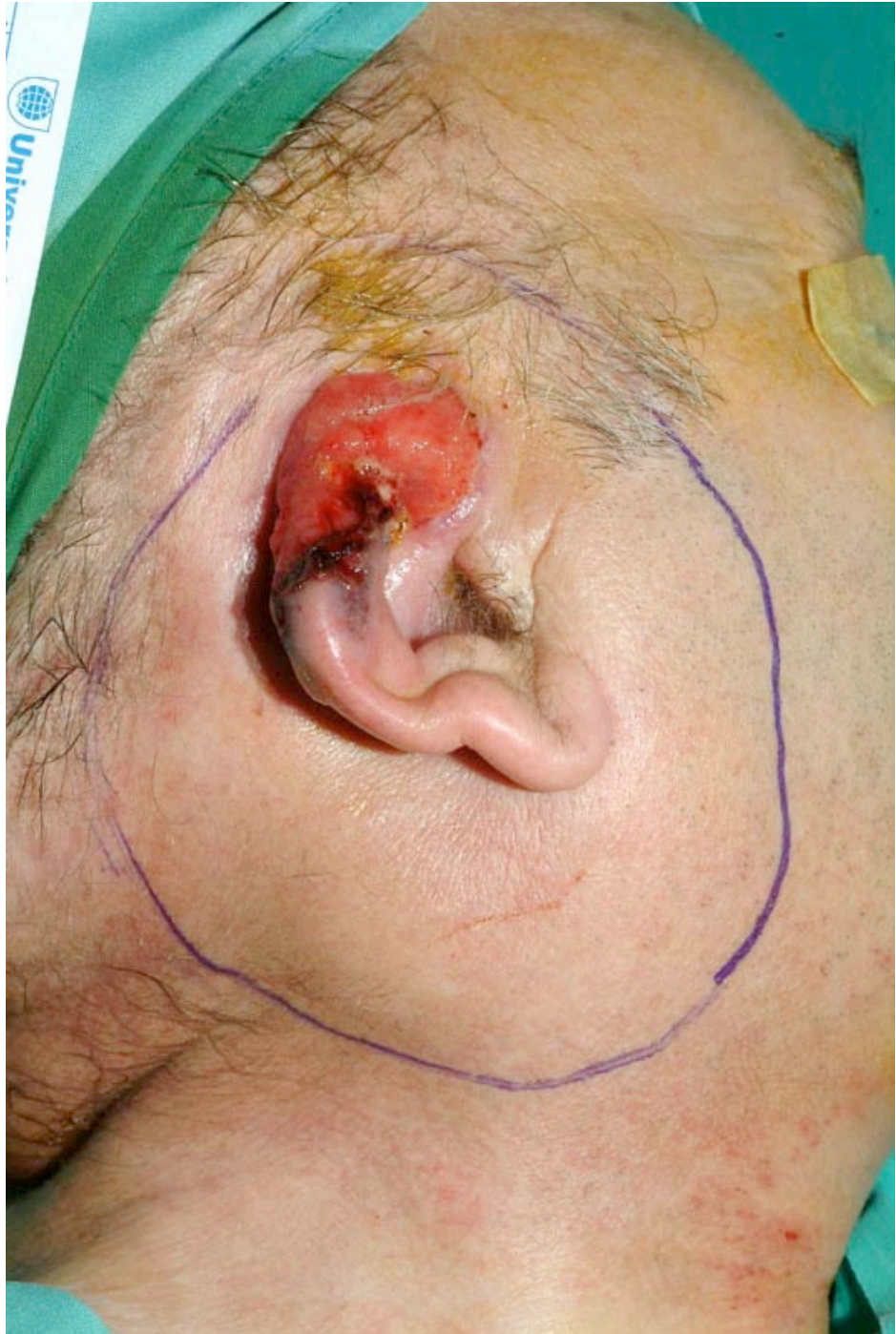

Figure 1 - A Locally recurrent Auricular Squamous Cell Carcinoma with Metastatic Deposits Bulging below the Auricle

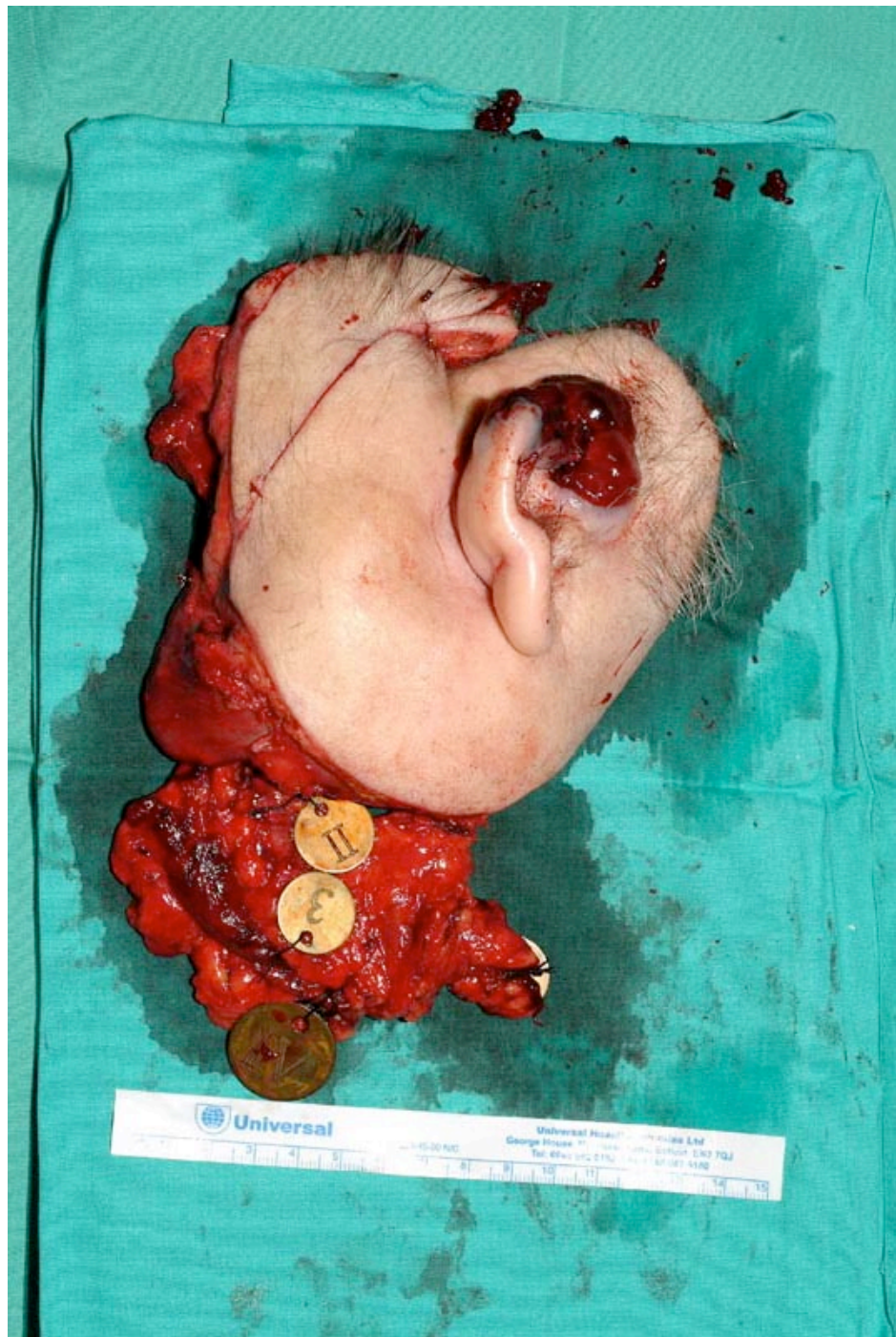

Figure 2 - The Resected Tissue. Brass tags Indicate Levels of The Neck Dissection

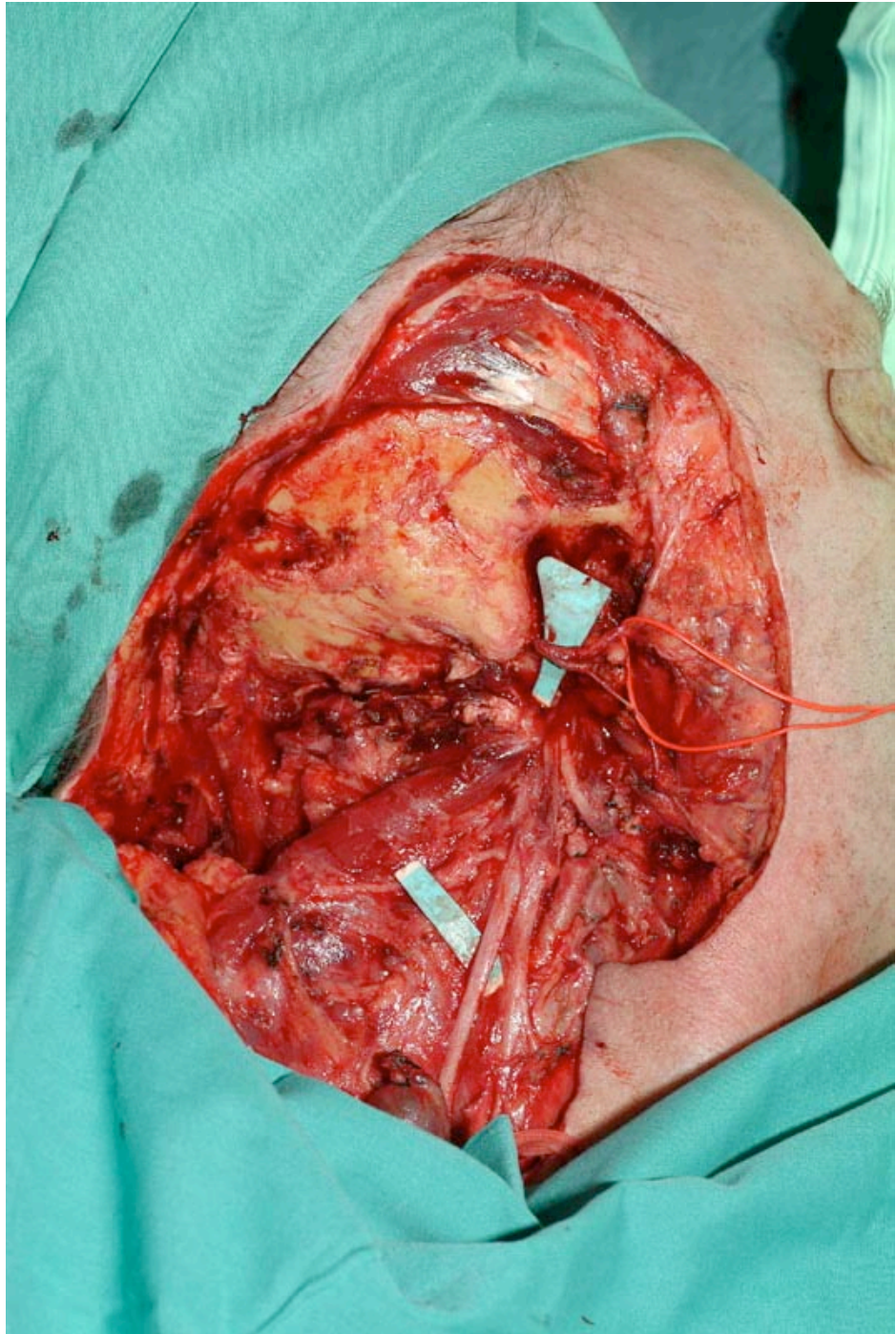


Figure 3 The Resulting Defect showing exposed Temporal Bone. The Mastoid process has been trimmed.

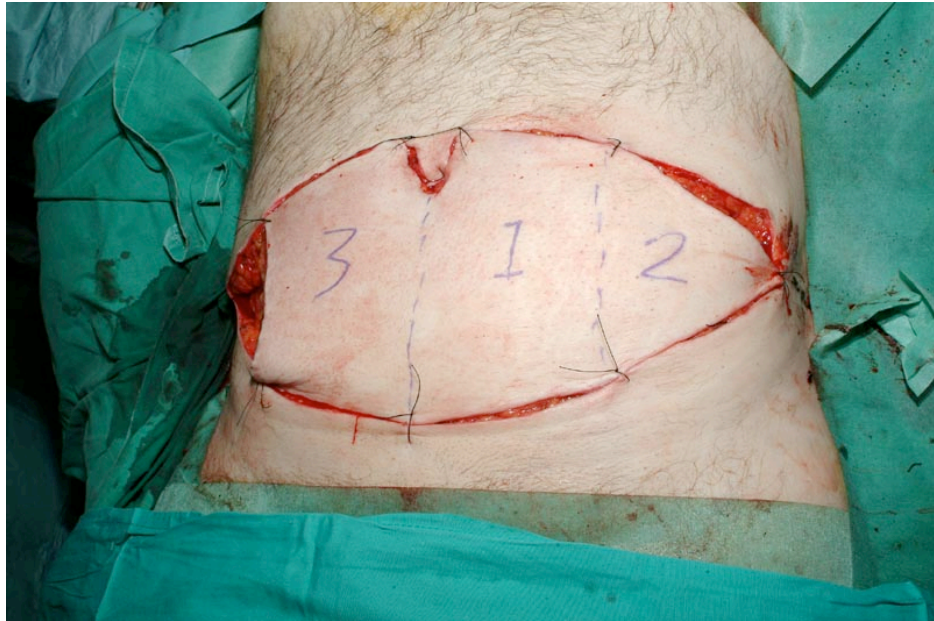

Figure 4 - A Transverse Rectus Abdominus Myocutaneous Flap used to reconstruct the defect.

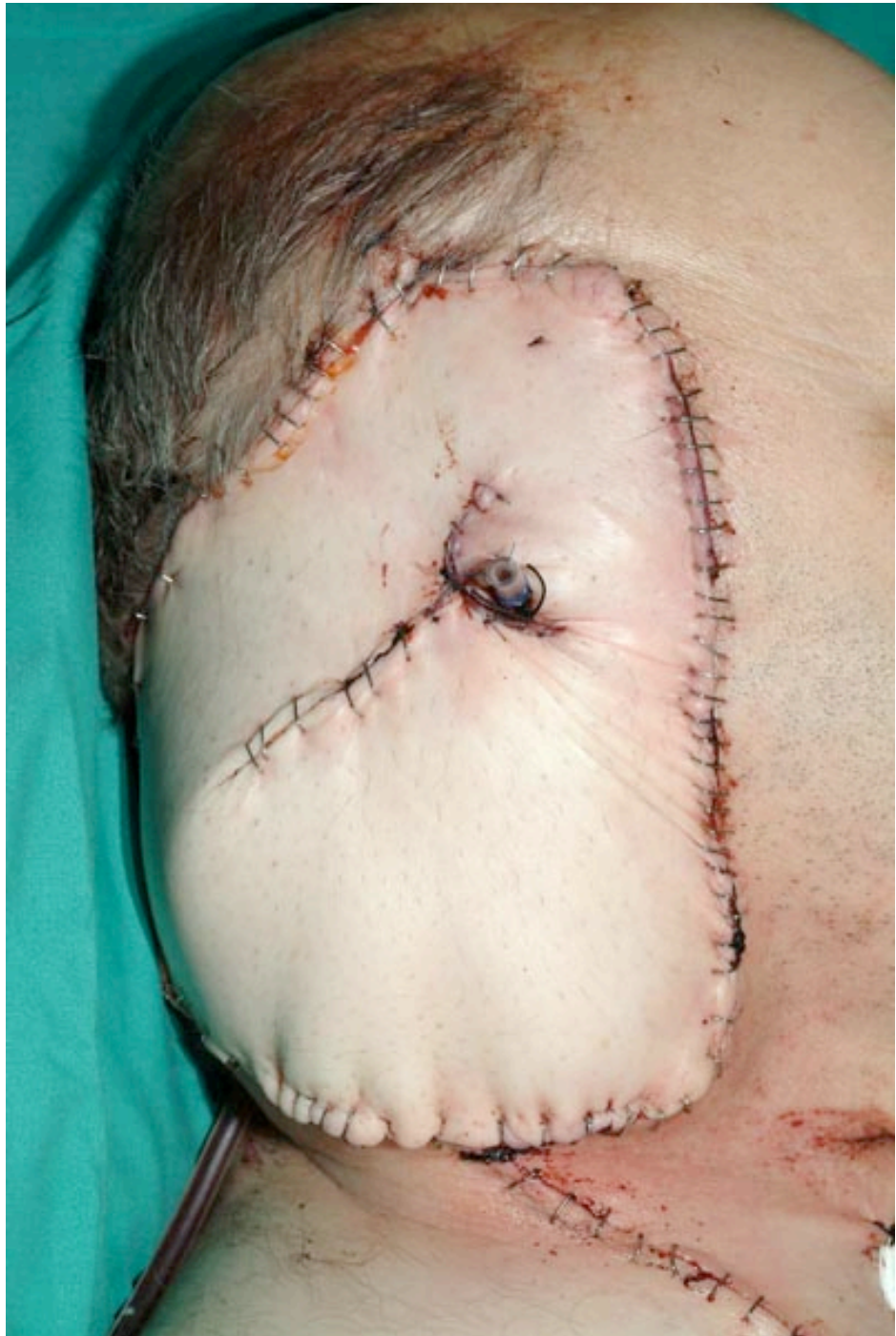

Figure 5 - The flap Inset with a plastic tube to maintain the neo-auditory canal

General Materials and Methods

In order to establish which patients would benefit from treatment to the lymph node basins at the time of initial presentation four separate studies were conceived. These four studies form the next four chapters of this thesis. The first of these studies is a systematic review conducted to examine what is already known about metastasis from auricular squamous cell carcinoma. Secondly a cadaveric study of auricular lymphatics examines the vessels and lymph nodes that drain the auricle to provide an anatomical basis for surgical intervention. Thirdly an interventional study examines the use of sentinel lymph node biopsy to detect early metastatic spread to the lymph nodes. Finally a retrospective analysis of all cases of auricular squamous cell carcinoma treated in our unit over a 12 years period examines histopathological tumour features as indicators of metastatic potential.

All four projects were undertaken at the same time and ran concurrently during the research period.

Prognostic Factors in Development of
Lymph Node Metastases from
Auricular Squamous Cell Carcinoma
A Systematic Review

Summary

Review Questions

- What is the metastatic rate?
- Where and when do Metastases Develop?
- What is associated with Survival, Mortality and Morbidity?
- What indicators predict the development of metastases?
- Is there evidence to support targeted prophylactic therapy to the lymph node basins at risk of developing metastases?

Design

A systematic review

Review Methods

A database search of Medline and Embase with cross referencing of articles.

Results

The metastatic rate is 11.2% with spread to the parotid and upper deep cervical chain most common. 85% of metastases develop within 12 months and 98% within 24. Death occurs in 6.2% of cases usually due to failure of loco-regional control. Depth of invasion, tumour size, degree of cellular differentiation and incomplete primary excision margins may be useful in identifying lesions most at risk of metastasising but there is insufficient evidence at present to allow targeted neck dissections.

Introduction

Background

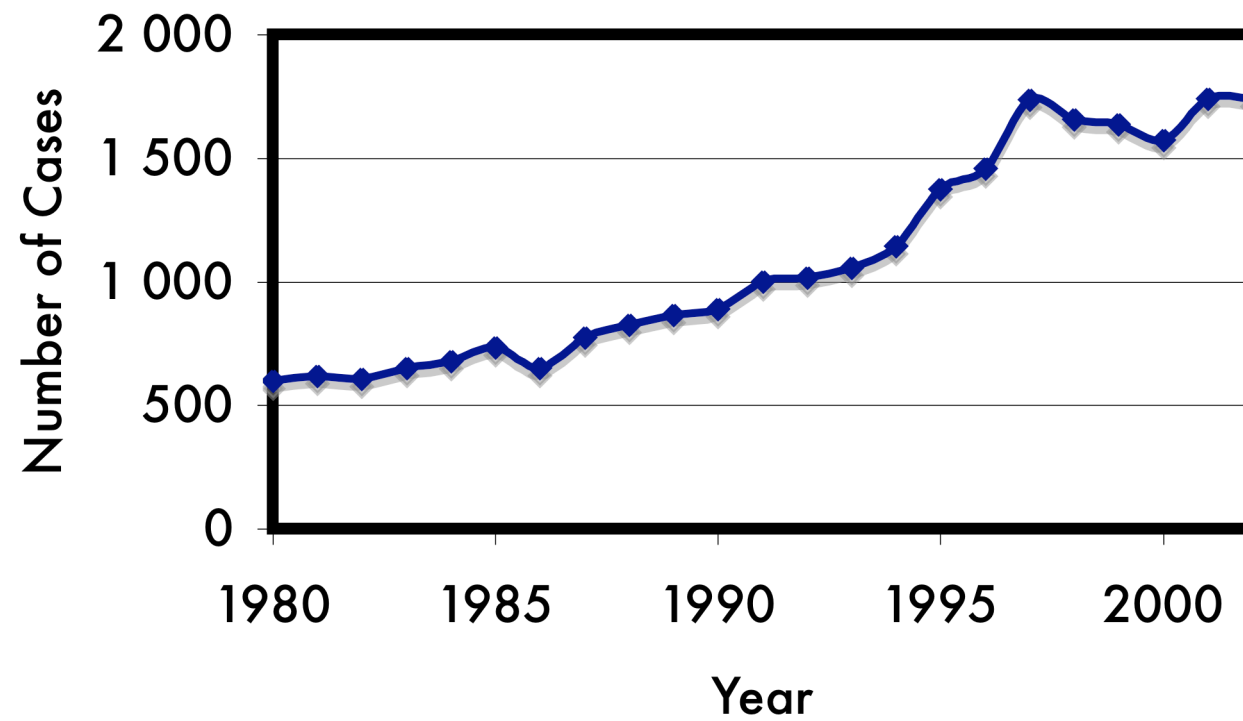
Lewis in 1960 was one of the first to recognise that squamous cell malignancy of the auricle (ASCC) has a high metastatic rate at 15%.⁸ Although the number of cases he reported was small (23) and he attached no special significance to this metastatic rate his findings have since been supported by several other authors with rates ranging from 12 to 16%.¹⁻³ ASCC stands apart from other sun induced cutaneous squamous cell carcinomas (CSCC) which have metastatic rates much lower at between 0.5 – 2%.⁹⁻¹² The reasons for this discrepancy remain unclear. SCC arising in scar and at areas on the body where there are muco-cutaneous junctions such as the lip, anus, vulva and penis are also noted to have an increased risk of metastases, although the aetiology at the anus, vulva and penis is likely to be different.¹³⁻¹⁵ Lewis also noted that ASCC is the leading cause of death in sun-induced non-melanoma skin cancers.¹⁴ Lymph node metastases from ASCC cause particular problems because they tend to occur in lymph nodes located adjacent to the base of the skull and therefore can rapidly involve bone, nerves and blood vessels making their treatment difficult and are often associated with significant morbidity and mortality.¹⁶⁻²⁰

Burden of Disease

Cutaneous neoplasms other than melanoma are often not perceived as high risk or life threatening and there is marked variation in their recording throughout the UK as noted by Goodwin.²¹ It is estimated that there are over 12,000 new cases of non-melanoma skin cancer per year within the United Kingdom.²² The reported incidence of all skin cancers has been rising dramatically in recent years.^{23, 24} This is believed to be not only due to an increase in reporting but also to reflect an underlying increase in the rate due to an increase in lifetime sun exposure in an ageing population.²¹⁻²⁵ Non-melanoma skin tumours especially are more common in the elderly population where cumulative lifetime exposure to sunlight seems to be an important risk factor.¹⁵

Iversen and Chuang have reported that ASCC is much more common in men than women. In men the auricle is the site of 11 - 25% of all CSCC and in women only 0.2 - 3%.^{26, 27} The Scottish Cancer Registry obtains information from patients' discharge summaries, pathology, radiotherapy and oncology departments throughout Scotland. Its published figures show a dramatic rise in the number of cases of CSSC from 599 in 1980 to 1741 in 2002.²⁴ (Figure 6) These figures are doubtless subject to the same problems as elsewhere in the UK with at least part of this increase due to increased reporting but the totals are still likely to be an underestimate.

Figure 6 - CSSC Registrations In Scotland 1980 - 2000



Management of Disease

Primary malignant tumours of the external ear are treated by a variety of different specialities. Plastic surgeons, General surgeons, Dermatologists, Otolaryngologists and Radiotherapists have all published series and each of them brings their own methods of treatment.^{2, 3, 8, 16, 17, 28-45} Surgeons such as Byers, Freedlander and Afzelius report series where the vast majority of lesions were surgically excised.¹⁻³ Dermatologists such as Mohs, Ceilley and Robins favour techniques such as micrographic surgery, electrodesiccation and liquid nitrogen ablation.^{43, 46-49} Radiotherapy has also been successfully used by authors such as Alexander and Caccialanza.^{29, 34} The various different methods have all been shown to have good rates of local tumour control and Cooper has shown that postoperative chemo-radiotherapy can improve this but at a significant cost to the patient.⁴

Surgical excision is the most common management in the published literature especially in recent years.^{2, 3, 48} It would, however, be rash to assume that this means that it is the most commonly employed technique. Nordin, a dermatologist, published a series in 1999 treated by curettage-cryosurgery, which may reflect current practice by many dermatologists.⁴⁹ There is no information available at present to indicate how many cases are treated by each speciality and what factors influence methods of treatment.

Management of the regional lymph nodes basins at the time of initial presentation remains controversial. Afzelius in 1980 published guidelines on elective lymphadenectomy based upon a relatively small series (65 of which 11 metastasised) but his indications have not been supported by Byers and Freedlander who have published larger series.¹⁻³ While all these authors have

reported excision of lymph nodes based upon clinical evidence of involvement either at the time of initial presentation or subsequently, Byers and Chen have performed elective lymph node dissection but unfortunately give no indication of the selection criteria used.^{2, 36} There is evidence from several sources to indicate that early excision of CSCC metastases to cervical nodes before multiple nodes become involved or extra-capsular spread has occurred confers a survival advantage but none of this refers specifically to auricle as the primary tumour site.^{4, 13, 19, 50-54}

The Auricle as a Site of Malignancy

The external ear, due to its location, is a site on the body that is exposed to sun on a regular basis. In females, however, the hairstyle determines the level of sun-exposure. Iversen, Ceilley, Byers, Freedlander and most other authors have noted a large male bias for auricular neoplasms with rates in females as low as 0.2 - 3%.^{3, 27, 48, 55} They also noted that the tumours usually occur in the elderly, particularly those with outdoor occupations. These factors have led the authors to conclude that sun-exposure is the primary aetiology for the development of malignancy in most cases. However the types of tumour that arise on the auricle differ considerably from that of other sun-exposed sites. Ahmed showed that for the head and neck the ratio of BCC to SCC was 4:1 but on the auricle this drops to 1.3:1.⁵⁶ This implies that the skin of the auricle behaves differently under exposure to solar radiation but there is as yet no obvious explanation for this.

The lymphatic drainage of this region is plentiful with at least three lymphatic territories draining the skin of the auricle as described in current anatomical textbooks based upon the work of Rouviere.^{57, 58} There is a slim anterior portion of the tragus and helical root that drains anteriorly to the pre-auricular nodes; posterior to this the territory is split into an upper and lower half with drainage to the post-auricular and deep cervical nodes respectively. It is easy to understand that a malignancy need not grow very large before it overlaps two or three lymphatic drainage pathways and it is possible that this diffuse lymphatic drainage may contribute to allowing tumour cells to spread easily.

In addition to considering the lateral growth of the tumour it is important to also consider the vertical growth of the tumour. The lymphatics of the skin begin just below the papillary dermis in

blind ending endothelial-lined tubes or loops that drain to a superficial plexus. This plexus drains through collecting ducts to a deeper plexus at the base of the dermis which in turn drains into larger subcutaneous channels.⁵⁷ The skin on the anterior part of the pinna is thin and tightly bound to the underlying cartilage. Tumours that arise in the epidermis and grow vertically down through the dermis encounter an increasing number and increasing calibre of lymphatic vessel. On the pinna this distance is less than at other sites due to the thinness of the skin.

The external ears are believed to play a function in the cooling of the body which leads them to have a disproportionately high blood flow. Production of lymphatic fluid is a largely passive process caused by the difference in hydrostatic and osmotic pressures between circulating blood and extra-cellular fluid.⁵⁹ It is possible that greater production of lymphatic fluid in the auricle could contribute to the ease with which tumour cells are carried away to lymph nodes from a tumour but again there is no direct evidence for this. These specific anatomical features may mean that it is useful to consider ASCC separately from other high risk SCC when looking for potential markers of metastatic potential.

Melanoma is another common skin malignancy induced by solar damage which frequently metastasises to regional lymph nodes. Ravin recently reported a series of 199 cases of auricular melanoma and reviewed previous evidence.⁶⁰ He concluded that with auricular melanoma the metastatic rate was greater (39.2%) and prognosis poorer than for other anatomical sites and that this was unaffected by conservative surgical margins that had been postulated by some as a reason. The fact that tumours from two different precursor cells both show increased metastatic spread from this site supports a hypothesis that there is something specific

about the lymphatic drainage of the auricle that permits or encourages tumour cells to metastasise.

Materials and Methods

The aim was to find all relevant published material on the topic of lymph node metastasis in ASCC. A search strategy was created based upon guidance published by the Centre for Reviews and Dissemination, the Cochrane Library and independent articles.⁶¹⁻⁶⁴

Three electronic databases were searched – Medline, Embase and The Cochrane Library. The reference lists from any articles of relevance found from these databases were then used to find further references. The search was not restricted to the English language but articles would only be translated in full if a native language reader was able to confirm the potential usefulness of the article.

The Cochrane Library contained no relevant material and subsequent searching was confined to Medline and Embase. The strategy used was identical for both databases. Initially the databases were searched for 'Squamous Cell Carcinoma' as a subject heading. Within this subset several groups of papers were defined. First all papers that were coded under the subject heading of 'External Ear' as this is where all references to pinna, auricle and external ear should be placed. Secondly all papers where the any of the words 'pinna', 'auricle' or 'ear' appeared in the title or abstract. The third and last group was papers from the 'Squamous Cell Carcinoma' heading also coded under 'Lymph node metastasis' and had either the word 'skin' or 'cutaneous' in the title or abstract. This last group was included because some papers that report information on lymph node metastases subdivided their data by anatomical site thus allowing information on ASCC to be extracted.

The results of this search were then read to establish papers of relevance. Copies of these papers were then obtained either

electronically or photocopied and read. The references of each paper were checked for additional papers that may be of relevance that had been missed by the original search. Copies of these were then obtained.

Electronic Search Strategies

Database: Ovid MEDLINE(R) <1966 to October Week 1 2006>

Search Strategy:

-

- 1 Carcinoma, Squamous Cell/ (76414)
- 2 Ear, External/ (8147)
- 3 1 and 2 (228)
- 4 pinna.m_titl. (226)
- 5 auricle.m_titl. (575)
- 6 ear.m_titl. (17117)
- 7 4 or 5 or 6 (17860)
- 8 1 and 7 (249)
- 9 skin.m_titl. (78416)
- 10 cutaneous.m_titl. (30592)
- 11 9 or 10 (107932)
- 12 1 and 11 (3689)
- 13 Lymphatic Metastasis/ (49475)
- 14 12 and 13 (154)
- 15 3 or 8 or 14 (532)

Database: EMBASE <1980 to 2006 Week 41>

Search Strategy:

-

- 1 Squamous Cell Carcinoma/ (32794)
- 2 External Ear/ (1223)
- 3 1 and 2 (41)
- 4 pinna.m_titl. (163)
- 5 auricle.m_titl. (328)
- 6 ear.m_titl. (10771)
- 7 4 or 5 or 6 (11219)
- 8 1 and 7 (113)
- 9 skin.m_titl. (53678)
- 10 cutaneous.m_titl. (24138)
- 11 9 or 10 (76934)
- 12 1 and 11 (2456)
- 13 Lymph Node Metastasis/ (28788)
- 14 12 and 13 (77)
- 15 3 or 8 or 14 (213)

Results

A total of 735 references were generated from the electronic databases. The vast majority of these were excluded by reading the title and or abstract. The most common reasons for exclusion of articles at this stage were:

- Articles focussing upon reconstructive techniques
- Reporting methods of excision only
- Case reports with no relevant information

Paper or electronic copies of 87 articles were then retrieved and read for relevance. Unfortunately many of these could not be used for the following reasons:

- Failure to separate SCC from other tumours affecting the auricle
- Failure to separate auricular SCC from SCC at other sites most commonly pre- and post-auricular SCC

Some of these papers were able to contribute information in some areas but not others due to the way the data had been presented.

The reference list of each of the 87 articles was then read to look for further articles of interest. A total of 10 further articles were then obtained. No further articles were recruited by reading the reference list of these 10 articles.

What is the metastatic rate?

A total of eleven papers were found that provided information on regional metastases.^{1-3, 16, 36, 38, 42, 45, 65-67} (One paper that did report this was excluded because it quoted the total number of cases inconsistently (335 versus 261) when calculating rates.⁴⁴) The results are summarised in table 1. The overall averaged metastatic rate was 11.2% and for those series with a minimum follow-up period of two years (the period during which most metastases would be likely to appear) 11.8%. A funnel plot of the metastatic rates against the number of patients is shown (Figure 7). The specialities of dermatology, general surgery, oncology, otolaryngology and plastic surgery have been represented in the publications.

Figure 7 - Funnel Plot of Metastatic rates

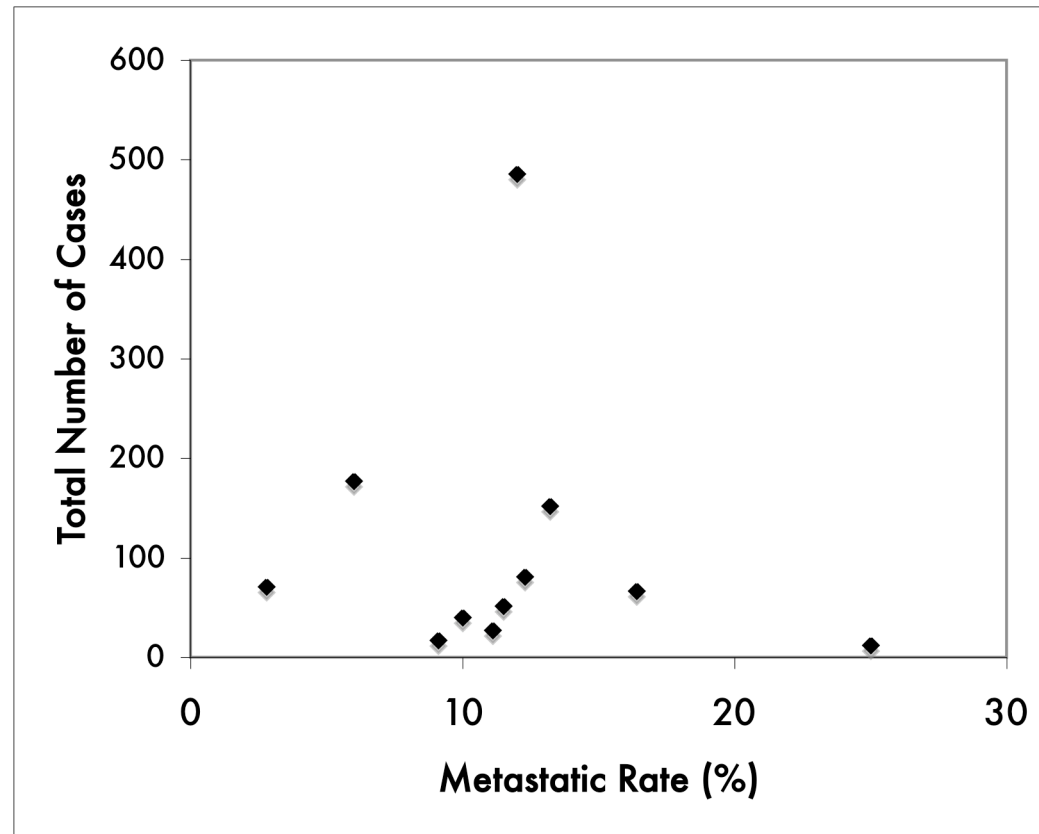


Table 1 - Summary of Metastatic Rates

Lead Author	Year	Total Number	Follow-up (Months)	Metastatic Rate (Number)
Afzelius	1980	67	> 15	16.4%(11)
Blake	1974	81	Unknown	12.3%(10)
Byers	1983	486	> 24	12%(58)
Chen	1978	17	18	9.1%(1)
Fredricks	1956	27	Unknown	11.1%(3)
Freedlander	1983	152	> 12	13.2%(23)
Leferink	1988	12	6-36	25%(3)
Lee	1996	71	>12	2.8%(2)
Pless	1976	177	Unknown	6%(10)
Shiffman	1975	52	15-36	13.5%(7)
Shockley	1987	40	> 24	10%(4)
Totals		1182		11.2%(132)
Total for Follow up >24 months		526		11.8%(62)

Where do Metastases Develop?

Of the eleven papers that gave information on regional metastases only three gave detailed information on the frequency of nodal metastases to different nodal basins. Two additional papers that looked at lymph node metastases from all head and neck CSCC also provided information on location of spread from auricular primaries although neither of these papers considered the post-auricular nodes as a separate group.^{19, 68} (Table 2) The parotid gland and upper deep cervical chain are the most common site of lymph node metastases.^{3, 38, 55} These nodal basins both seem to be involved in a significant number of cases when regional metastases develop.³ The post-auricular nodes are also frequently involved.^{2, 38} No author has reported involved lymph nodes in other parts of the neck without one of these areas being involved.

Table 2 - Location of metastatic disease

Lead Author	Total Number of Metastases	Post Auricular	Parotid	Upper Deep Cervical	Neck Other Levels
Byers	79	12	35	28	4
Freedlander	29		14	15	
Jol	17		6	6	5
Vauterin	49		28	8	13
Leferink	4	1	2	1	
Total	178	13(7.3%)	85(47.8%)	58(32.6%)	22(12.4%)

Survival and Mortality

Only two papers provided information on survival following primary diagnosis.^{27, 42} One paper noted the 3.5 year survival as 62% and 5 year survival at 55% to be only marginally shifted from normal survival for the population and another showed the relative survival rate to be 80%.^{27, 42} Both papers make comment on the fact that the cause of death is usually other than ASCC or its LNM. Neither paper made any comment about patients dying of intercurrent disease with active tumour. Seven quoted rates of death attributable to disease either locally invasive or metastatic disease.^{2, 3, 16, 38, 45, 65, 67} Most of these were relatively small numbers and the rates varied considerably. Byers reported a much higher rate of death attributable to local failure but has included parotid disease in this category.² Byers also showed a large difference in survival if there was more than one lymph node involved, parotid invasion or extra-capsular spread.⁵⁵ Despite this no difference in survival has been shown for those patients receiving prophylactic versus therapeutic lymphadenectomies.² Weinstock reported in a paper regarding non-melanoma skin cancer in Rhode Island in the USA that in 47% of deaths attributable to CSSC the primary tumour site was auricle.⁶⁹ The highest of any one site on the body.

Morbidity

It is difficult to quantify the morbidity associated with metastases due to the various reporting styles and emphasis of the authors. Byers reports that twenty patients required a radical neck dissection with sacrifice of the sternocleidomastoid muscle, internal jugular vein and XIth cranial nerve; 46 patients required sacrifice of the facial nerve; 11 require a partial mandibulectomy. Freedlander comments on bony involvement in six patients. (Table 3)

Table 3 - Summary of Deaths Directly Attributable to Disease

Lead Author	Total Number	Died of Disease (No)	Local Failure death rate (No)	Metastatic death rate (No)
Blake	81	9.9%(8)	1.2%(1)	8.6%(7)
Byers	486	5.1%(25)	2.5%(12)	2%(10)
Chen	17	5.9%(1)	5.9%(1)	0
Fredricks	27	3.7%(1)	0	3.7%(1)
Freedlander	152	7%(13)	0	7%(13)
Leferink	12	8.3%(1)	0	8.3%(1)
Shiffman	52	7.7% (4)	0	7.7% (4)
Shockley	40	2.5%(1)	0	2.5%(1)
Totals	867	6.2%(58)	1.6%(14)	4.2%(37)

Time to Development of Metastases

Five papers gave information on the time to develop LNMs following primary diagnosis.^{3, 36, 38, 45, 65} In most cases the majority of the LNMs appeared within one year. Less than 15% appeared after this and only 4 (1.6%) reported cases developing LNMs after two years. (Table 4)

Table 4 - Time to Development of Metastases

Lead Author	Total Number	Number of Metastases	Time to Nodal Mets Months
Chen	17	2	0-42
Fredricks	27	3	10-32
Freedlander	152	23	2-51
Leferink	12	3	3-27
Shiffman	52	7	7-18

Does Tumour Size Predict Development of Metastases?

Freedlander reported that 50% of tumours greater than 3cm diameter metastasised and that the mean size of tumour was 2.8cm in patients with metastases as opposed to 1.7cm in patients without.³ Afzelius reported that 44.4% of tumours greater than 12cm² (equivalent to a 3.9cm diameter round tumour) metastasised.¹ Neither of these authors has given a statistical significance of this.

In contrast to this Byers, in the largest series by far, has reported that there is no correlation between tumour size and development of metastases.² There is no indication in the paper of the variation in the size of the tumours they treated. Schockley commented that lesions greater than 3cm diameter conferred an adverse prognosis but not directly on the development of LNM.⁶⁷

Does Depth Of Invasion Predict Development of Metastases?

Afzelius found that the Clark level (Table 5) of lesions that metastasised was significantly higher than that of lesions that did not.¹ In that series of 36 tumours that had reached Clark level 5 (sub-cutaneous tissue) 11 metastasised – 30.6%. This dropped off quickly to 1 of 10 metastasising at level 4 and 1 of 12 at level 3. Despite this in Freedlander's series, which was twice as large, the authors looked at depth of invasion but were unable to correlate this development of LNM.³ Both these authors also felt that cartilage invasion was an important predictor in development of metastases. Byers has made a blanket comment that histological findings did not correlate with development of metastases but has not specified which specific histological features this referred to.²

Table 5 - Clark's levels

Clark's Level	Depth of Invasion
I	Confined to epidermis
II	invades papillary dermis
III	invades to papillary-reticular dermal interface
IV	invades the reticular dermis
V	invades subcutaneous tissue

Does Mode Of Invasion Predict Development of Metastases?

Afzelius again showed a significant difference between those tumours that had metastasised and those that had not using a four level scoring system of mode of invasion.¹ (Table 6) In level four 7 of 13 metastasised 53.8%; level three 4 of 16 25%; level two 2 of 30 6.7% and level one 0 of 10. Freedlander looked at this but found that despite a clear definition they could not readily reproduce comment on the tumour architecture.³

Table 6 - Scoring system for Mode of Invasion used by Afzelius

Score	Histological features
1	Tumour with a well defined border
2	Tumour with cords and a less well-marked borderline
3	Tumour with groups of cells and no distinct borderline
4	Tumour with diffuse growth pattern

Does the Degree of Cellular Differentiation Predict Development of Metastases?

Freedlander looked at this again but found that the same problem of reproducibility existed and therefore this could not be reliably used.³ Afzelius noted an insignificant difference between the differentiation of tumour that metastasised and those that did not.¹

Does Location of the Primary Tumour Predict Development of Metastases?

Only two papers have commented upon this and neither found any significant correlation between primary tumour site and development of metastases.^{2, 16}

Do Excision Margins Predict Development of Metastases?

Only Freedlander has commented on this and noted that 43% of the cases in his series who developed lymph node metastases had doubtful or incomplete primary excision margins.³

Is There Guidance on When to Prophylactically Treat The Lymph Node Basins?

Afzelius believed that a tumour size greater than 12cm², cartilage invasion, depth of invasion to Clark level 5 or a maximum score for mode of invasion should encourage treatment to the lymph nodes in the form of a neck dissection.¹ Freedlander suggested that any tumours greater than 3cm in diameter should warrant further therapy.³ No author has suggested the level of risk of occult metastases that should exist before an elective neck dissection is performed.

Several authors have commented on the debilitating nature of the surgery involved once the facial nerve or bone of the skull base become involved and the lesser potential for cure once the disease has reached this stage.^{2, 3}

Prophylactic versus Therapeutic Lymph Node Dissections?

Byers found no difference in survival if an elective neck dissection was performed or if a therapeutic neck dissection was performed but gave no indication of how many patients fell into these categories.² There are no papers comparing elective and therapeutic neck dissections.

Discussion

The overall metastatic rate for ASCC is slightly over 11%. This figure is maintained in series that have a minimum follow up of two years which should account for over 98% of all metastases. There is no bias in the funnel plot indicating that the series reviewed here are representative of the underlying level of disease in the population. This is further reinforced by the fact that all specialities that would be expected to treat this malignancy have contributed to the publications. This removes any suspicion that it is only the more advanced cases that are being reported which could have led to an artificially high metastatic rate.

The overall survival figures for the disease reflect to some degree the fact that the population affected by this condition are elderly. Those authors who reported survival figures commented upon the large number of patients who died of intercurrent disease but despite this the disease has been directly attributed to the death in 6.2% of cases. In the majority of cases this was due to failure of control at the level of local lymph node basins.

Parotid involvement and extra-capsular spread are known to be adverse prognostic indicators in LNM from CSCC.^{4, 13, 19, 50-54} This combined with the large decrease in survival noted by Byers once two or more nodes became involved suggests that early detection and treatment of LNM or prophylactic treatment is likely to confer a survival advantage. Given the small number of deaths attributable to this disease and the lack of a controlled randomised trial it is not surprising that there is no direct evidence for this. Similarly it is not possible to directly comment upon the influence that early treatment of the lymph node basins would have upon morbidity. Despite this LNMs must grow and spread outwith the capsule of the lymph node before they can invade

structures such as the facial nerve and bone. It is resection of structures such as these that makes curative resection difficult and causes permanent disability and disfigurement.

There were several factors that seemed to be possible indicators of an increased risk of developing LNM. Unfortunately despite support for these by some authors all have been contradicted by others. Byers published the largest series by some considerable margin and failed to find any pathological prognostic indicators. However Byers does not give any indication of the methods used to look for possible relationships nor any descriptive measures of the range of size, depth and differentiation of the tumours in the series. Without this information we cannot be sure that he has managed to refute the findings of the other authors.

In a cosmetically important structure such as the auricle it is easy to understand why excision margins of tumour excision may be intentionally kept relatively small when compared with other sites on the body. Freedlander is the only author to note the possible link between incompleteness of primary excision and the development of LNM, even in the absence of locally recurrent disease.³ This emphasises the need for adequate primary intervention in these tumours to prevent progression of disease.

Freedlander and Afzelius felt that tumour size gave an indication of metastatic potential. Their findings suggest that tumours with a diameter of 3 – 3.9cm or over have a metastatic potential of over 44%. Byers gives no indication of the number of tumours in his series over 3cm in diameter or 12cm² that would have met the criteria set by these other authors as high risk.

Depth of invasion (Clark Level) was found by Afzelius to be a significant indicator of development of metastases.¹ Freedlander is the only other author to comment on this and found no relationship although the wording of the paper is such that it

would seem they looked at cartilage invasion rather than a measured depth of invasion or Clark level. In CSSC in general and melanoma the depth of invasion has been shown to be one of the most significant prognostic indicators in the development of metastases.^{13, 70} It would seem logical that this should also be the case in ASCC.

Afzelius found a strong relationship between the mode of tumour invasion and development of LNM. In the scoring system used in his series, tumours with a diffuse growth pattern (score 4) were more likely to metastasise than those with a lower score and no tumours with a well defined border (score 1) metastasised. He further went on to publish a histological scoring system for cancers of the external ear.⁷¹ Freedlander and co-author found that between them they could not reliably reproduce comments upon the mode of tumour invasion. This lack of reproducibility is a significant problem that affects histo-pathological examination of ASCC, not just when examining mode of invasion but also when looking for degree of cellular differentiation. The use of subjective measures is subject to both intra- and inter-observer variation. The mode of invasion may vary across the invasive front of a tumour. Since the presence of any area of an aggressive invasive front would be enough to upgrade a tumour into an aggressive category, the higher the proportion of the tumour examined will increase the number of aggressive tumours. Similarly an area of poor differentiation may only be present in one part of the specimen. It can only be concluded that in the hands of one pathologist it may be possible to correctly identify the tumours with the most aggressive mode of invasion but that subjectivity and resources available to examine the specimen limit use of this.

In the 1970's it was suggested that for a neck dissection to be beneficial in head and neck cancer, the risk of occult metastases

should be greater than 20%.⁷² More recently it has been suggested that this figure should be lowered to 15%.⁷³ These figures are for malignancies of the upper aero-digestive tract that usually metastasise to lymph nodes that are more easily palpable and do not invade skull base or nerves and can therefore be detected earlier and resected more easily and with less morbidity. For that reason it would seem that 15% should be the minimum risk of occult LNM at which prophylactic therapy to the lymph node basins should be offered although a full cost benefit analysis would need to be carried out in order to determine the exact threshold. It is interesting to note that no-one has suggested using radiotherapy for prophylactic treatment of the lymph nodes despite its proven use in the treatment of micro-metastases.^{5, 6, 74}

Sentinel lymph node biopsy is an emerging technique that is being used successfully in melanoma and Head and Neck squamous cell carcinoma with great accuracy in determining the presence of occult lymph node metastases.^{75, 76} It is a technique with low morbidity and greater accuracy in comparison to elective neck dissections. It would therefore seem to be a potential avenue for further research in this field.

Conclusions

Auricular squamous cell carcinoma has a metastatic rate of 11%. This is significantly higher than other sun induced cutaneous squamous cell carcinomas. It is associated with a significant mortality at 6.2%, which is usually due to failure of control at the level of the local lymph node basins. It is likely that tumour size and depth of invasion are useful in stratifying the risk of occult metastases but more work should be done to confirm this. The histological parameters of mode of invasion and cellular differentiation are also likely related to risk of occult metastases but the difficulties associated with reproducibility and reliability of these subjective measures means that a great deal more evidence will be required from different sources to support their widespread use.

Treatment of the primary tumour should be thorough and re-excision or other treatment should be used when there is doubt about the excision margins.

It is not possible based upon the currently available evidence to confidently stratify patients into a high-risk category where prophylactic treatment of the lymph node basins would be deemed acceptable. Prophylactic treatment of the lymph node basins is, however, likely to confer a survival advantage and reduce morbidity when compared to therapeutic lymph nodes dissections. Prophylactic therapy should include at a minimum the post-auricular, parotid and upper cervical lymph nodes. Consideration should be given to the use of Sentinel Lymph Node Biopsy in these lesions.

A Cadaveric Study of Auricular
Lymphatics and Implications for
Sentinel Lymph Node Biopsy and
Lymphadenectomy Procedures

Summary

Introduction

Cutaneous tumours of the auricle are known to have a high rate of spread to the regional lymph nodes and for this reason removal of the lymph nodes for diagnostic or therapeutic purposes is often required. Recent work using sentinel node biopsy in cutaneous tumours of the head and neck has questioned the commonly described lymphatic pathways that are believed to exist and therefore further study is required.

Materials and Methods

A cadaveric model with Indian ink injection of auricles and dissection and clearing of specimens.

Results

Five distinct pathways are displayed leaving the auricle with five different locations for sentinel nodes. Two of these nodal locations have anastomotic pathways which would permit embolic tumour cells to bypass the nodes. Pathways descend adjacent to the mastoid bone periosteum and traverse the origin of the sternocleidomastoid muscle.

Conclusions

Sentinel lymph node biopsy for cutaneous tumours of the auricle should be possible but the presence of skip metastases should be considered. Lymphadenectomy procedures will require the resection of the sternocleidomastoid muscle and dissection to the periosteum of the mastoid bone.

Introduction

Malignant tumours of the skin of the auricle are known metastasise more commonly than comparable tumours at other sites.^{2, 3, 16, 30, 32, 55, 77-79} Because of this prophylactic lymphadenectomy is seen as a potentially useful procedure as it allows staging of the disease and removes small, sub-clinical deposits of metastatic disease before they involve important structures at the base of skull or spread further to cause distant metastases.^{1, 3} Prognosis is known to be better in squamous cell carcinoma when the tumour has reached fewer nodes and has not yet breached the capsule surrounding each node.^{2, 3, 53}

The classical procedure to remove lymph nodes for a head and neck cancer is the radical neck dissection. (Appendix 2 contains information on the terminology of neck dissection.) This procedure carries significant morbidity and because of this it is no longer the favoured procedure for staging of the cervical lymph nodes. Nowadays a selective node dissection is more popular. In this operation selected parts of the lymphatic chains are removed and important structures such as the sternocleidomastoid muscle, internal jugular vein and accessory nerve are preserved. This allows for staging of disease in the neck and removal of early metastases while minimising morbidity. This change from radical to selective neck dissections has come about through increased knowledge of the likely location of metastatic disease and the lymphatic pathways involved and it has undoubtedly caused a decrease in surgical mortality and morbidity.⁷³ The fact that these are safer operations with less complications coupled with advances in peri-operative medical care has also meant that patients with significant other diseases can now be offered this surgery.

Selective lymph node dissections have been successful in the treatment of cancers of the head and neck that are commonly associated with metastatic spread such as oral, pharyngeal, laryngeal, nasal and thyroid tumours. These cancers have all been studied in detail and there is significant information available which allows specific nodes to be excised in selected nodal basins. Auricular tumours, however, have not been studied in such great detail. A comprehensive neck dissection would include a complete parotidectomy in addition to the other cervical lymph node basins.^{1, 2} There is no established pattern of selective nodal dissection for this site. This is in part due to the fact that it has been difficult to categorise those auricular tumours most at risk of developing metastases and therefore most likely to benefit from lymphadenectomy. As a result many patients are only offered treatment if and when lymphatic deposits of tumour become clinically detectable.¹ Even in these cases there is no consensus of what constitutes a comprehensive neck dissection.

Sentinel lymph node biopsy is an emerging technique which aims to excise only specific lymph nodes draining a target area of tissue and therefore to reduce morbidity even further.⁷⁶ The technique has progressed from the originally described method of looking for specific lymph nodes at predetermined locations to the modern technique which involved dynamic localisation of lymph nodes pre- and intra-operatively. It relies on being able to identify target lymph nodes by means of a radioactively marked colloid and blue dye at the time of surgery. These nodes are the first lymph nodes that lymph from any tumour will travel to before progressing on to other nodes and are sometimes referred to as 'first echelon' nodes. Although this technique makes it easier to find target nodes, a sound understanding of the normal anatomical pathways is helpful to facilitate dissection and location of target nodes.

Current textbooks on the subject of auricular lymphatic drainage describe three different routes of lymphatic drainage: an anterior route draining the anterior auricle to pre-auricular and superficial cervical nodes; an inferior route from the lower auricle to infra-auricular and deep cervical nodes; and a posterior route draining the upper posterior part of the auricle to the post-auricular node(s) if present and onto deep cervical nodes. The efferent vessels described from the posterior part of the auricle are said to curl round the anterior edge of the sternocleidomastoid muscle to reach the deep cervical nodes.^{57, 59}

Despite what is known about the lymphatic pathways from previous work, there has been evidence from work done on sentinel lymph node biopsy in cutaneous melanoma of the head and neck to suggest that sentinel nodes do not always appear in the locations that would be expected.^{80, 81} This evidence questions our understanding of the lymphatic drainage pathways of the head and neck and the principals that both sentinel node biopsy and selective node dissection rely upon. In both these operations the assumption is made that the flow of lymph from a tumour follows a preset route to a specific lymph node or lymph node basin and that this is the route that tumour cells will take as they are shed of from the primary tumour and travel to the lymph nodes. Sentinel lymph node biopsy also relies on the assumption that the tracer materials used to identify the lymph nodes will also follow the same lymphatic pathway.

This shows that our understanding of lymphatic drainage of the head and neck is incomplete and there is not sufficient information available to allow the prediction of the possible locations of lymph nodes which are the drainage sites of specific tumours. There could be unknown lymphatic pathways and anastomoses that allow drainage of lymph to unexpected locations. Mustafa recently

carried out lymphoscintigraphy of the auricle in healthy subjects and found that lymph nodes were found in the expected locations.⁸² This work does not exclude the possibility that the flow of lymph can be directed by the lymphatic vessels in the living body.

In order to look for lymphatic vessels of the auricle a similar method can be used to that used to identify sentinel lymph nodes. A dye injected into the skin and sub-dermal tissues of the auricle could be made to flow along lymphatic vessels towards lymph nodes. A cadaveric model allows dissection and clearing of tissue such that lymphatic vessels can be identified and should also prevent dynamic re-direction of lymph flow as could occur in the living.

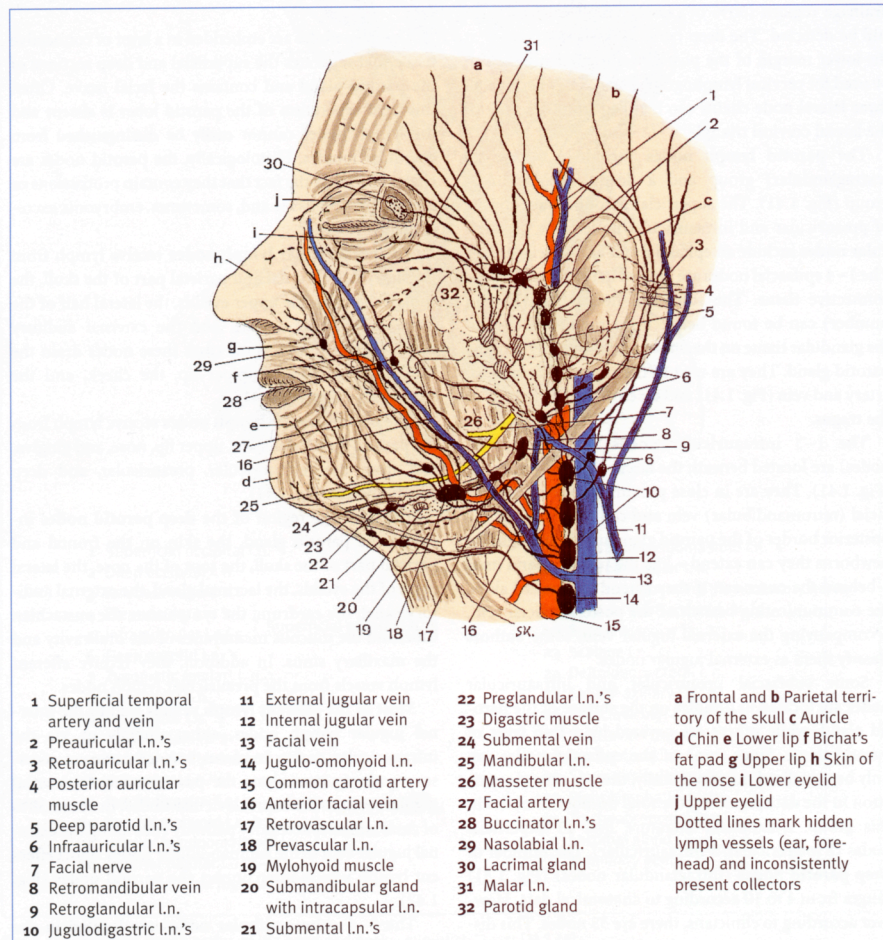


Fig. 1.42 Afferent and efferent lymph vessels of the retroauricular, parotid, submandibular, and submental lymph l.n.'s with intercalated l.n.'s in the facial region [M 124]

Figure 8 - Diagrammatic representation of auricular lymphatics reproduced from Kubrick's Textbook of Lymphology

Materials and Methods

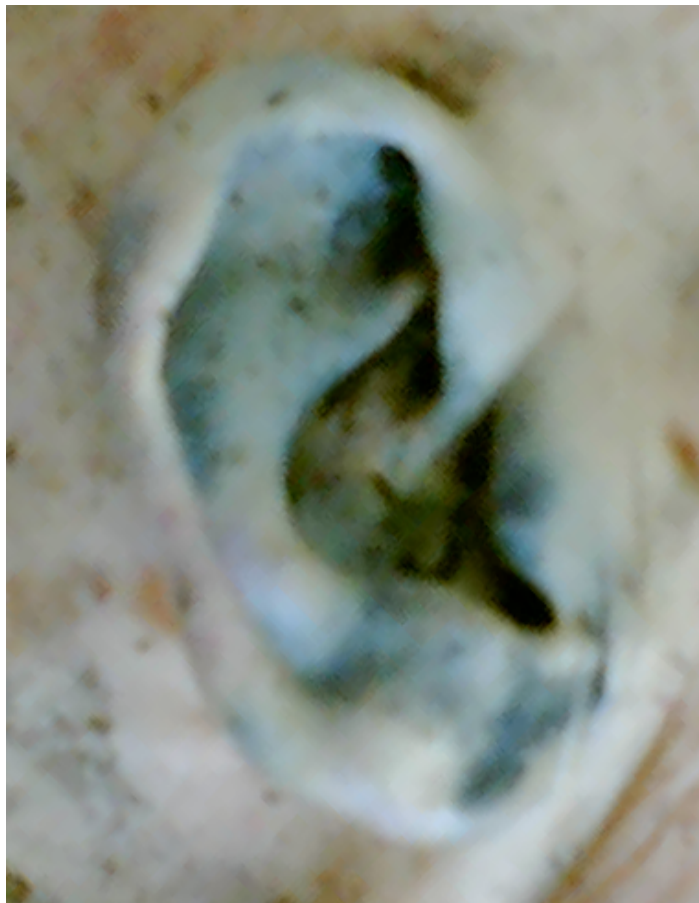
The methods used were based upon Jameson's and Dobson's methods for lymphatic mapping.⁸³ Cadavers for the study were provided by the University of Glasgow Anatomy Department. The donors had died 1-3 days previous and had been refrigerated after death. When a cadaver became available, which was deemed suitable for study, a solution of Indian ink diluted at a ratio of 1 to 5 with 0.9% saline was made up. This was injected intra-dermally and subcutaneously into the auricle through multiple injection points sufficient to render the entire external ear stained on both anterior and posterior surfaces. (Figure 9) Only the skin overlying the cartilage of the ear and the earlobe were infiltrated. Once the injection phase was completed, the ear was massaged and then in a progressive fashion the tissues overlying the skin surrounding the ear, the parotid and neck.

Once the massaging was complete the body was embalmed using a solution of ethanol, methanol and formaldehyde (Cantabrian Fluid, Vickers Laboratories). The embalming fluid was directed either centrally through a femoral artery or centrally or distally through a common carotid artery. (Table 7) After embalming the body was allowed to fix for between six to eight weeks per cadaver. Once this process was complete an en-bloc dissection of the auricle and lymphatics of the neck and parotid with overlying skin was carried out. Superiorly a 2cm margin of skin was taken and 5cm posteriorly. This was incised down to peri-osteum. The ear canal was detached at the junction between the cartilaginous and bony parts. The parotid gland was removed in its entirety. The sternocleidomastoid muscle was detached at its upper and lower ends from bone and included in the specimen along with the internal jugular vein and carotid artery. The deep muscles of the

neck formed the medial resection margin. No bone was included. The aim was to remove the auricle with the lymphatic pathways and nodes as one piece intact.

The dissected specimen was then cleared using a technique based upon the Spaltenholz method. This consisted of stepwise dehydration of the specimen in several solutions of methylated spirits increasing in concentration from 70% to 90% over two weeks, final dehydration in two baths of absolute alcohol (100% ethanol) and then clearing in methyl salicylate solution until the specimen became clear. (Figure 10) Once the specimens had cleared they were studied in detail and photographed.

Each specimen was examined to look for lymphatic pathways from the auricle and to try to identify the location of the first lymph node that these pathways encountered.

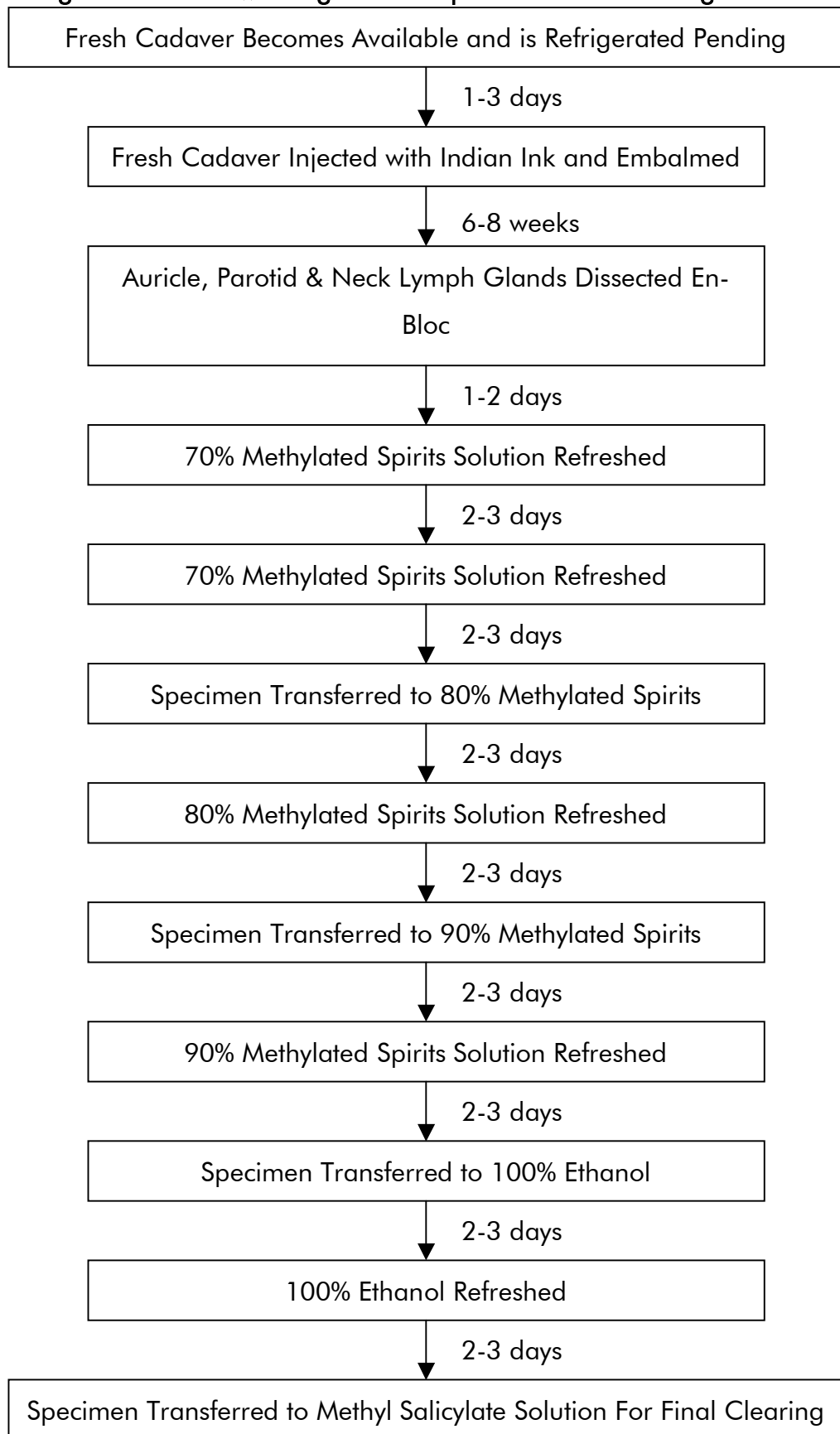


**Figure 9 - An ear showing staining after injection and
massage**

Table 7 - Summary of Specimen and embalming infiltration details

Specimen Number	Sex of donor	Age of donor	Side	Site of Embalming Fluid Infiltration	Direction of Embalming Fluid Infiltration
One	Female	83	Right	Femoral Artery	Centrally
Two	Male	68	Left	Contra-lateral Common Carotid Artery	Distally
Three	Male	68	Right	Ipsi-lateral Common Carotid Artery	Distally
Four	Female	73	Left	Ipsi-lateral Common Carotid Artery	Centrally
Five	Female	73	Right	Contra-lateral Common Carotid Artery	Centrally

Figure 10 - Flow Diagram of Specimen Processing



Results

A total of five specimens were obtained. These represented one right ear from an elderly female, a pair of ears from an elderly male with a rather short fat neck and a further pair of ears from another elderly female. Unfortunately part of the parotid gland was removed from the first specimen for another demonstration which somewhat reduced its usefulness. The Indian ink solution travelled to a varying degree in each specimen. In the specimens where the embalming solution was infused through the carotid artery on the ipsi-lateral side the ink travelled appreciably further than when the contra-lateral carotid or femoral artery was used. In addition to the information available from the cleared specimens there was additional information from dissecting the specimens. In three of the specimens a lymphatic vessel stained with ink was encountered while the specimens were being removed from the mastoid bone. The course of this vessel seems to be running from supero-lateral to infero-medial. So close and adherent was this vessel to the periostium of the mastoid that it was frequently damaged while the soft tissues of the specimen were being removed from the bone prior to clearing.

Specimen One

A right ear from an elderly female. (Figures 11 & 12) The upper majority of the parotid gland has been removed. This was done by dental students to demonstrate the temporo-mandibular joint. The dissection they carried out removed the skin as well and hence the lower part of the specimen is only loosely attached. This specimen demonstrates nodes in several locations which have been stained by the ink. Nodes are visible in the following locations:

- Deep to the insertion of sternocleidomastoid
- Anterior to the internal jugular vein in the deep cervical chain and adjacent tail of parotid
- Pre-mastoid
- Pre-tragal

It is difficult to comment on the lymphatic pathways in this specimen due the disruption caused by the dental dissection but pathways are clearly demonstrated between the nodes in the tail of the parotid gland and the deep cervical chain.

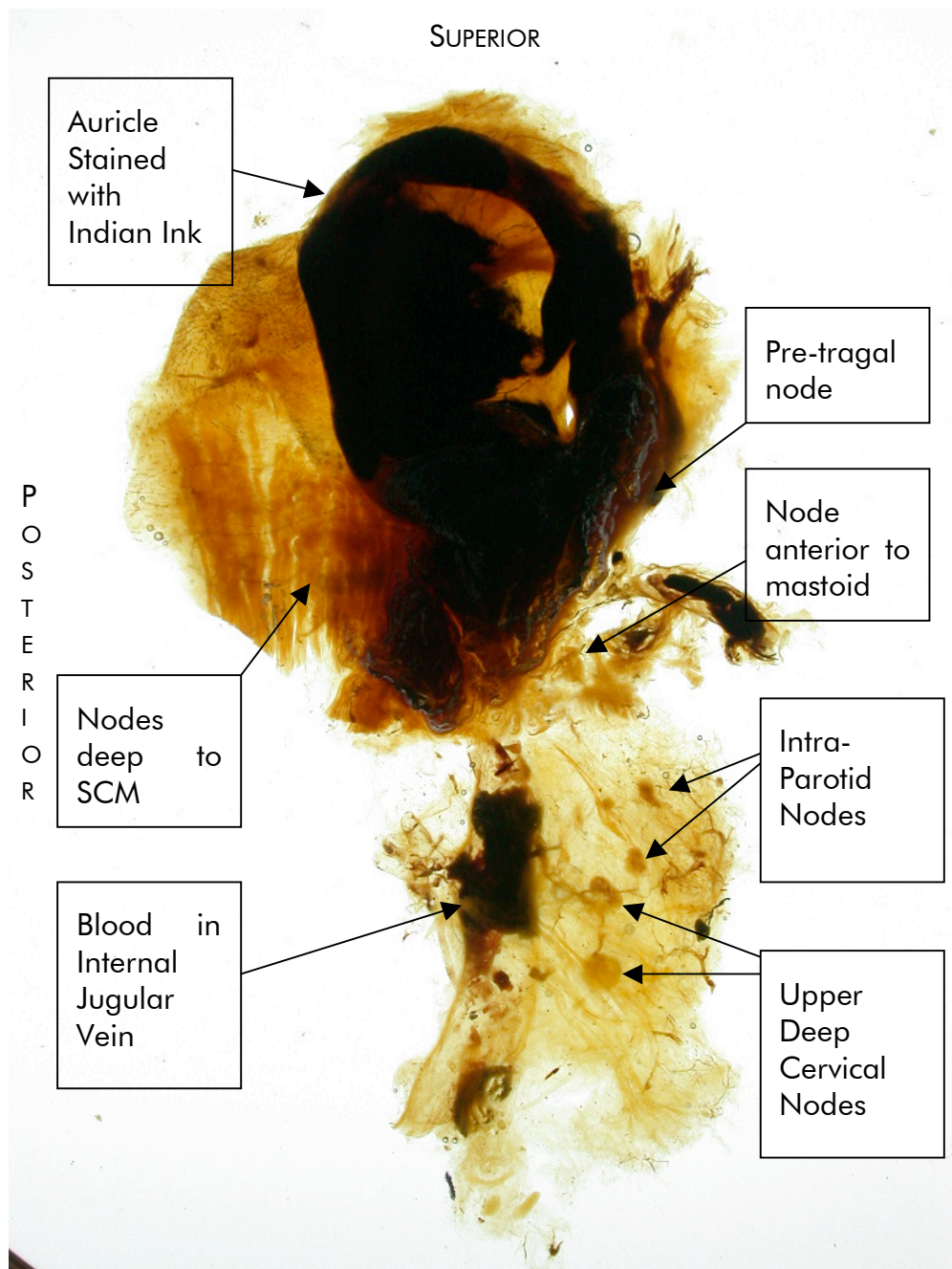


Figure 11 - Specimen One Lateral View

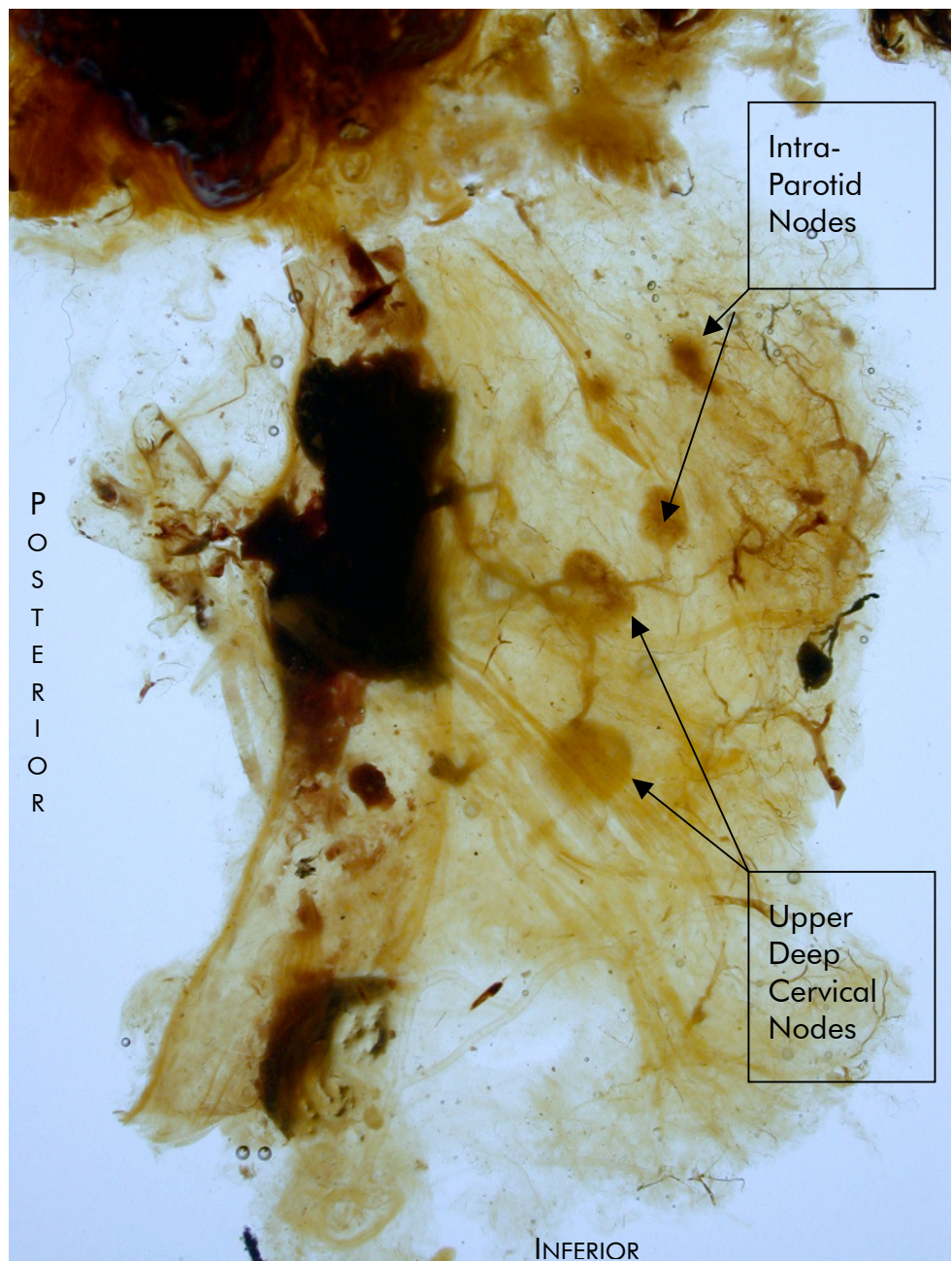


Figure 12 - Specimen One Closeup Lateral View
Showing Stained Nodes And Connecting Lymphatics

Specimen Two

A left ear. (Figures 13 & 14) This specimen shows staining of lymphatics and nodes in the parotid gland and upper deep cervical chain. Nodes are visible at the following locations:

- Superficial cervical adjacent to the external jugular vein
- Deep cervical around the internal jugular vein
- Anterior to sternocleidomastoid in the parotid gland

The tissue immediately anterior to the auricle has become heavily stained with ink preventing identification of any nodes or pathways in this area. Lymphatic pathways are evident at three points:

- From the anterior auricle to the superficial cervical node
- Traversing the insertion of sternocleidomastoid to deep cervical nodes
- Wrapping around the anterior border of sternocleidomastoid to deep cervical and parotid nodes

The upper part of the latter pathway is not visible. This is the region where the specimen was scraped off the mastoid bone and the pathways were damaged at that time.

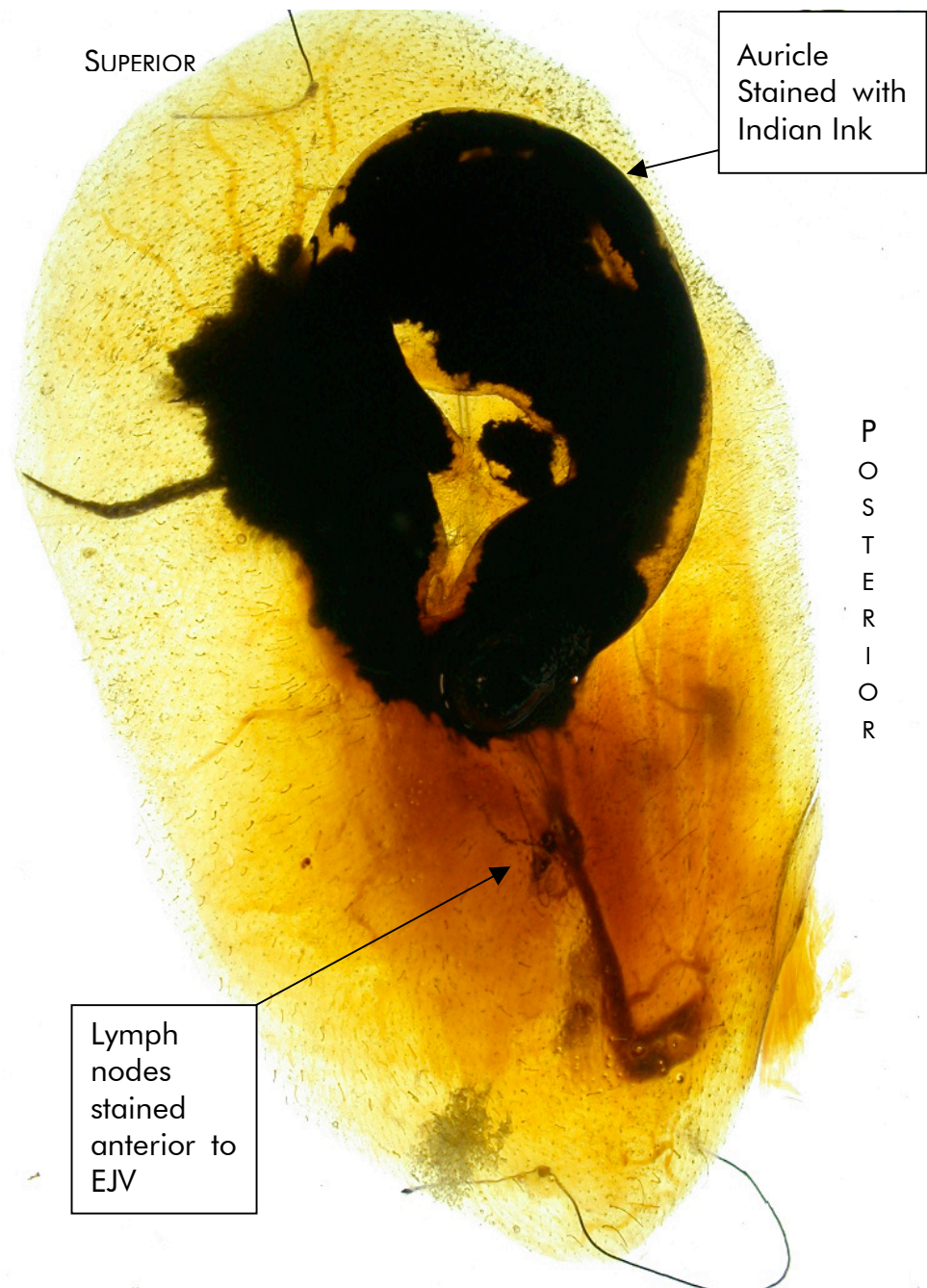

Figure 13 - Specimen Two Lateral View

(EJV – External Jugular Vein)




Figure 14 - Specimen Two Closeup Medial View

(SCM – Sternocleidomastoid muscle)

Specimen Three

This is a right ear (Figures 15-17) and shows stained lymph nodes at the following locations:

- Post-auricular
- Pre-mastoid
- Deep cervical chain
- Parotid gland

There is evidence of pathways descending from the auricle at four places:

- To the post auricular node
- Traversing the origin of sternocleidomastoid
- To the pre-mastoid node
- By passing the pre-mastoid node and running to the tail of the parotid gland

This specimen also demonstrates anastomoses of the lymphatic vessels around the post-auricular and pre-mastoid nodes.

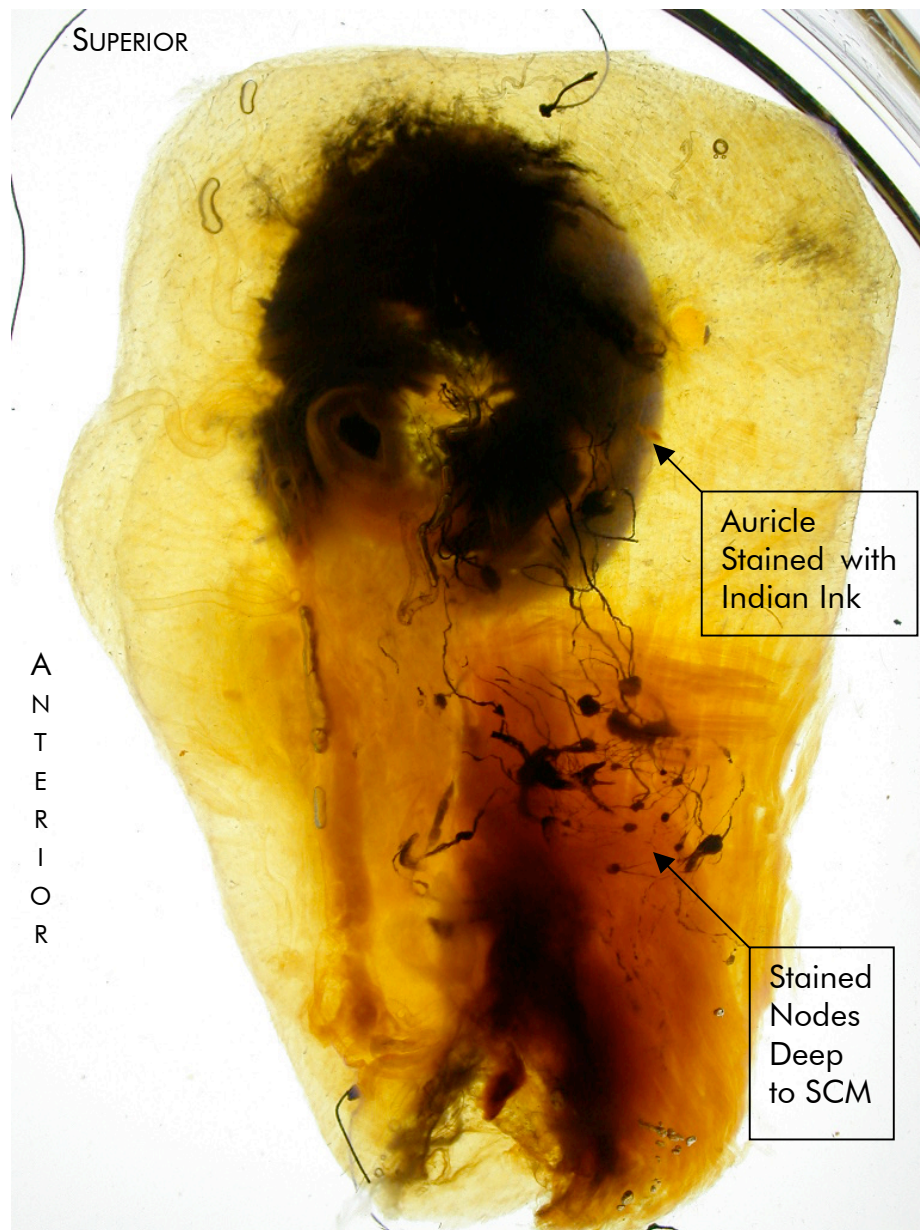
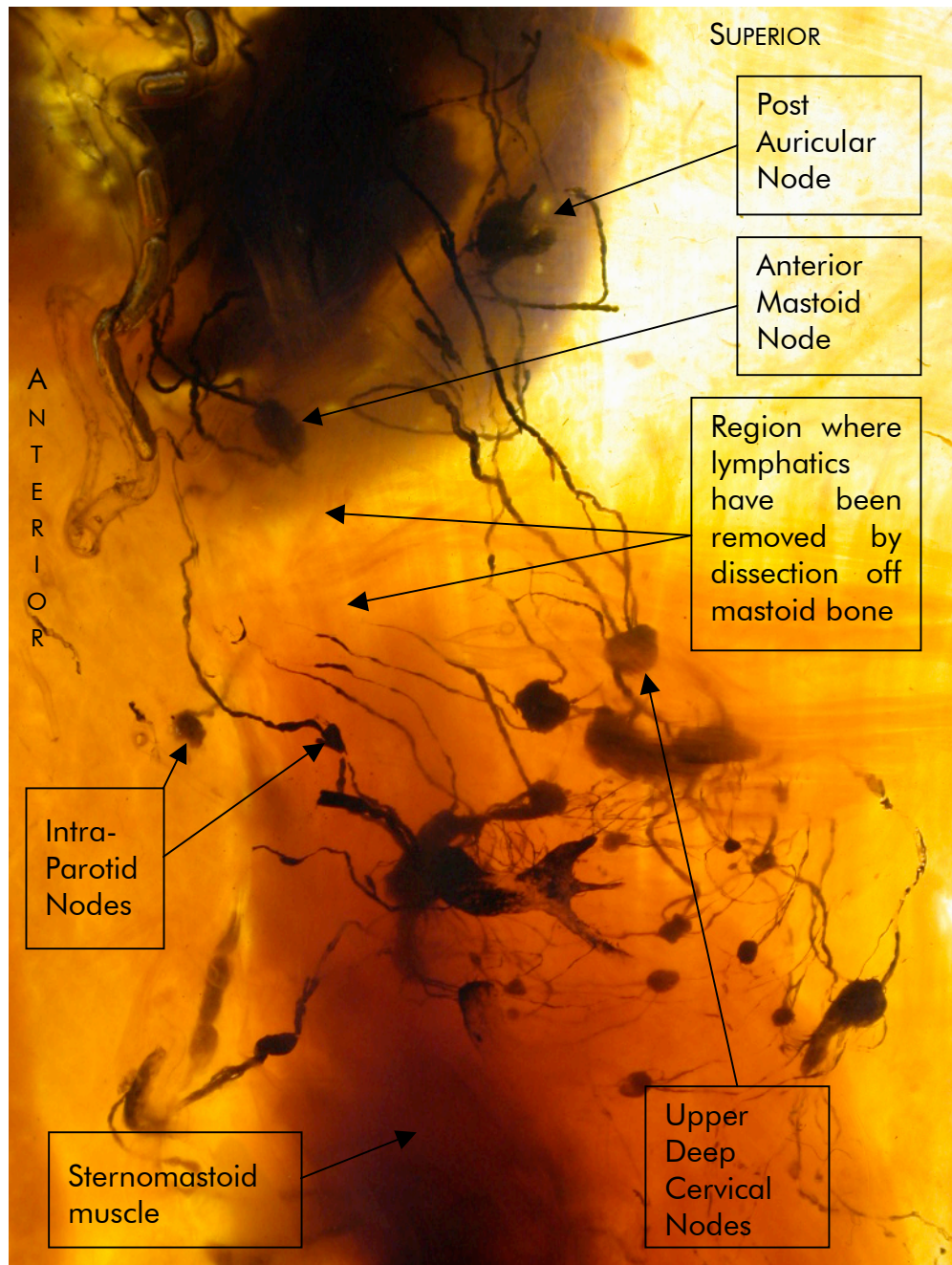


Figure 15 - Specimen Three Medial View



**Figure 16 - Specimen Three Closeup Medial View
Demonstrating The Proximity of First Echelon Nodes to
The Mastoid Bone at The Insertion Of The
Sternocleidomastoid Muscle**

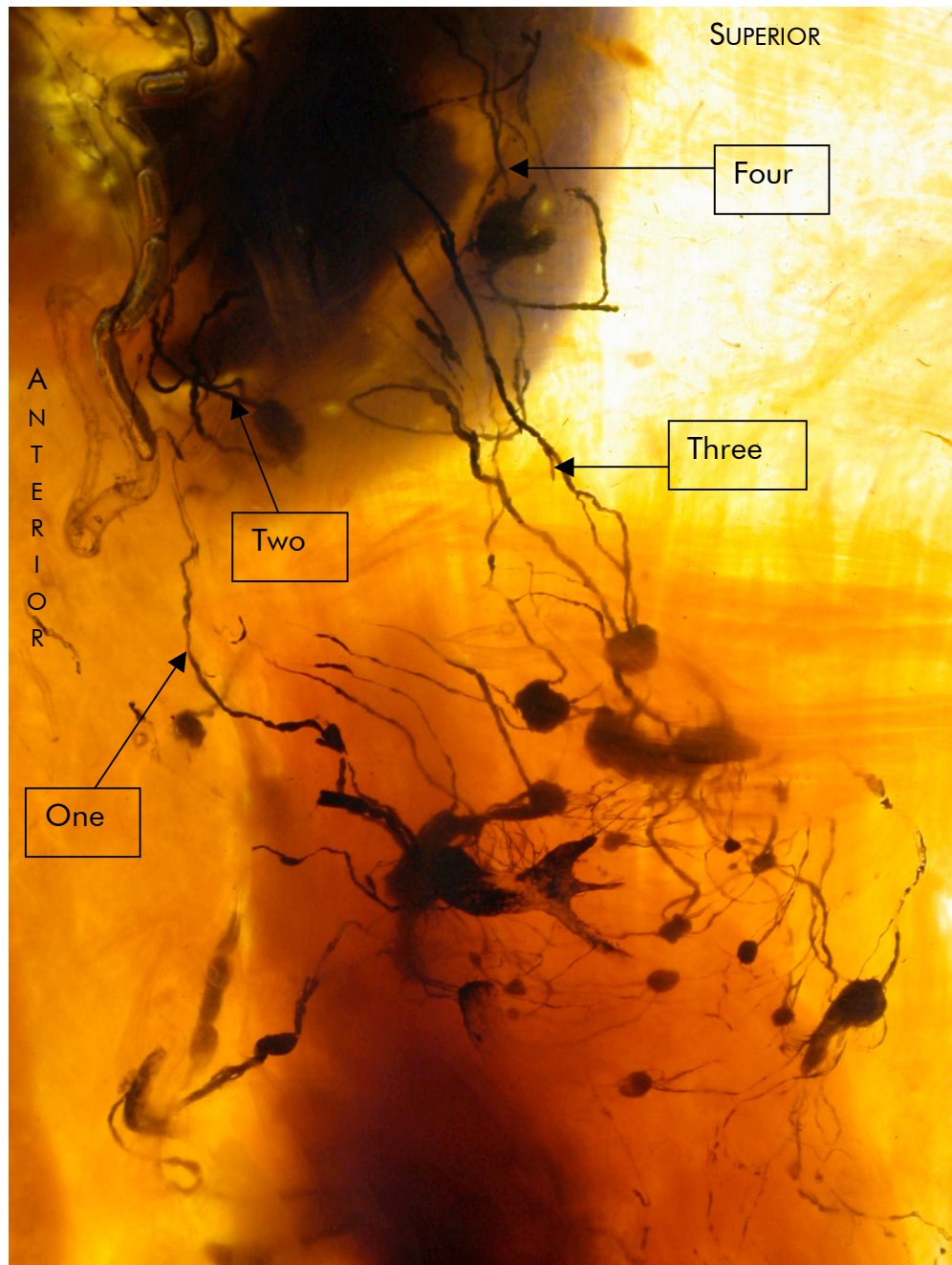


Figure 17 - Lymphatic Pathways In Specimen Three

One – Descending from the auricle to Intra-Parotid nodes

Two – Descending from the auricle to the anterior mastoid node. Lymphatics descending from this were damaged during dissection of the specimen and are believed to connect with lymphatics stained below this

Three - Descending from the auricle, traversing the origin of sternocleidomastoid to deep cervical nodes

Four – Descending from the Auricle to the post-auricular node. Lymphatics descend from this node to the deep cervical nodes




Figure 18 - 3D Stereogram of Specimen 3 for Parallel Viewing

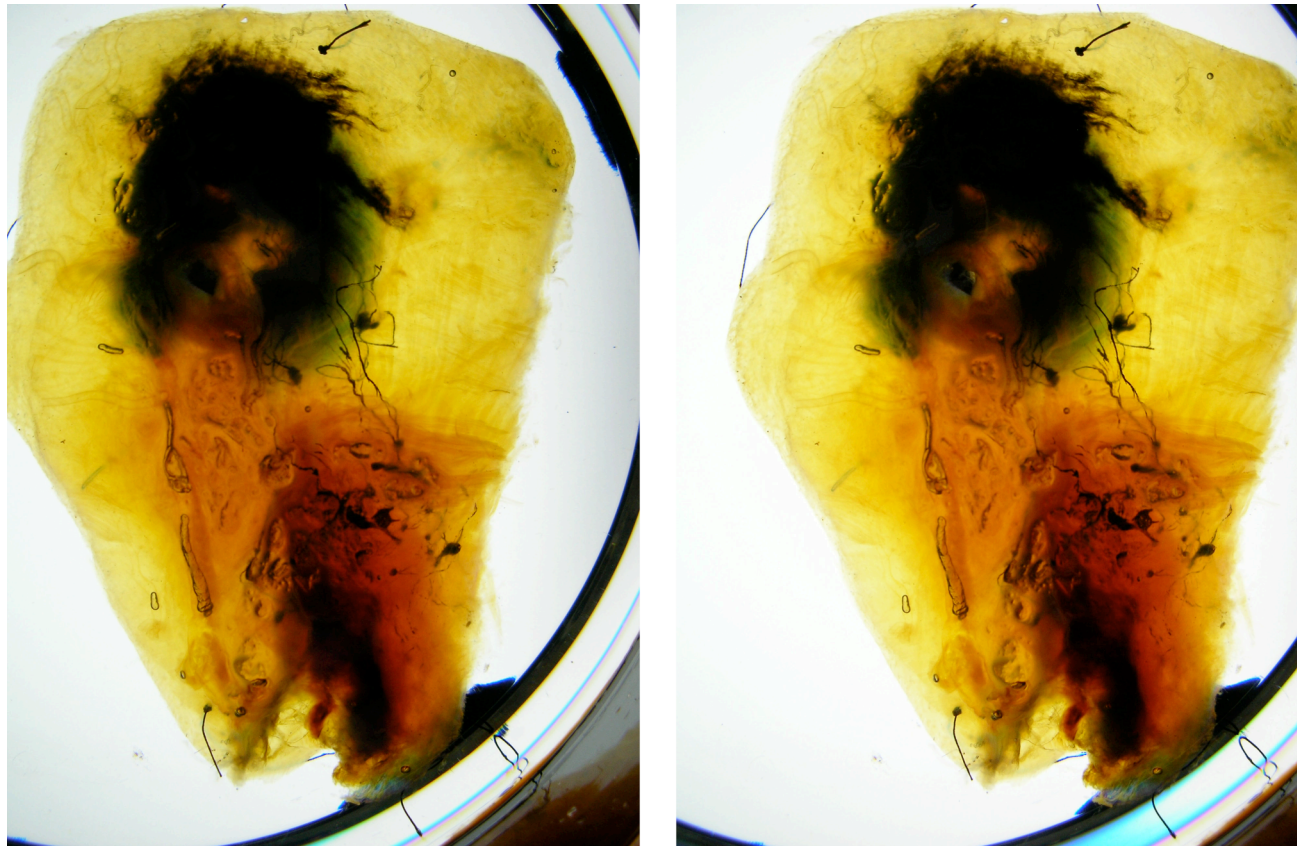


Figure 19 - 3D Stereogram of Specimen 3 for Cross-eyed Viewing

Specimen Four

This is a left ear. (Figures 18 & 19) The ink has travelled less far in this specimen than in others. The lymphatic vessels leaving the auricle have been stained and seem to be much finer than those encountered in previous specimens. Nodes are visible at the following locations:

- Post-auricular
- Pre-tragal

Two lymphatic pathways are visible in this specimen:

- From the auricle to the post-auricular node and then onwards to traverse the insertion of sternocleidomastoid
- From the auricle directly to traverse the insertion of sternocleidomastoid

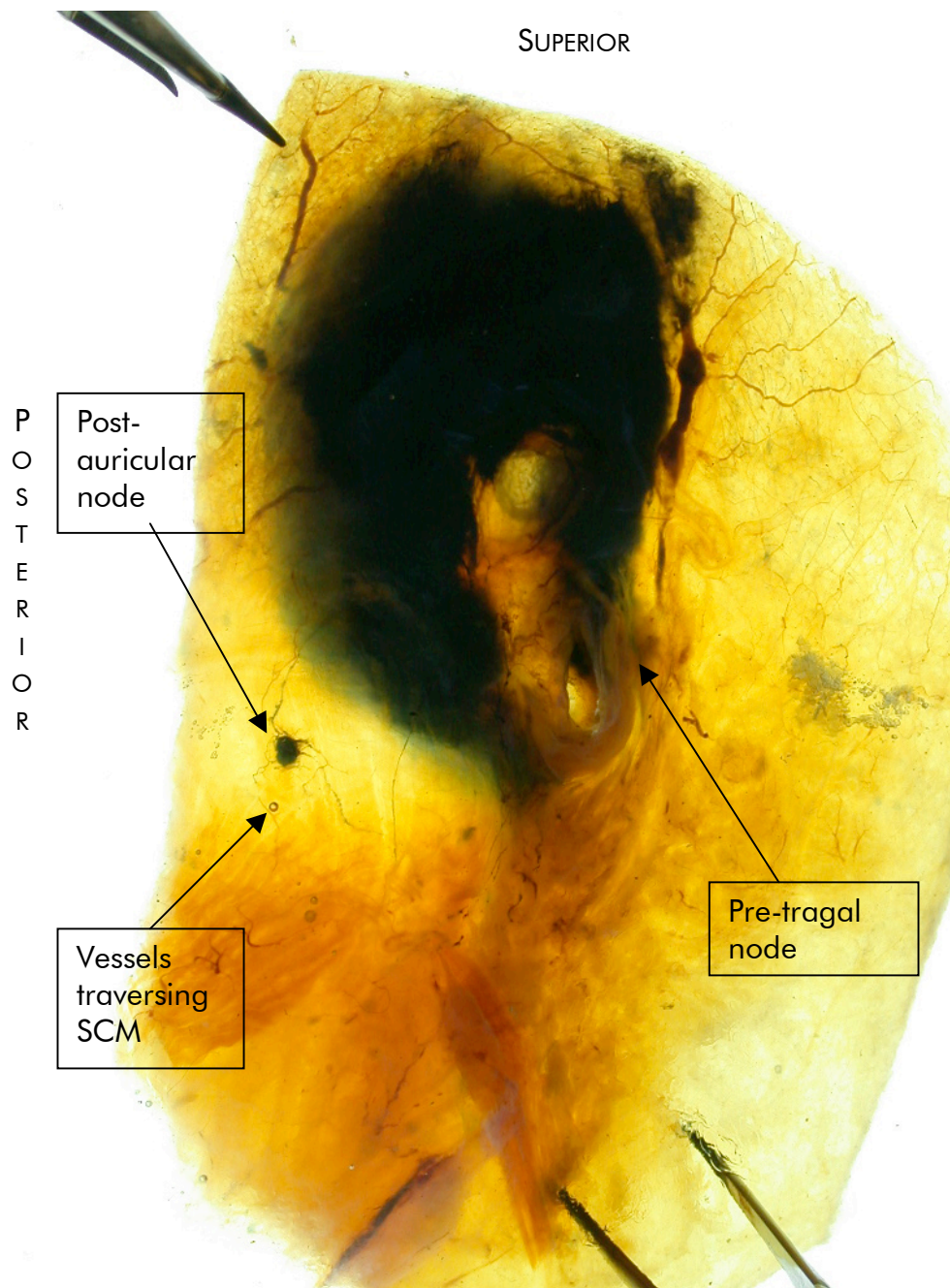


Figure 20 - Specimen Four Medial View

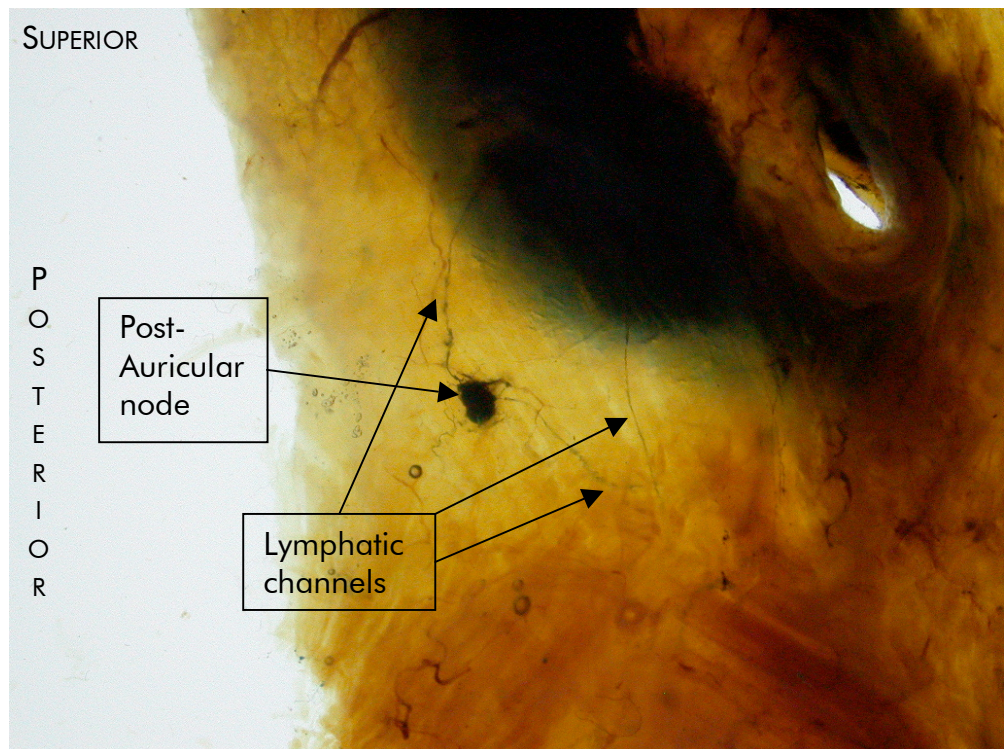


Figure 21 - Close up Medial View of Specimen Four

Lymphatics can be seen descending from the auricle and post-auricular node to traverse the insertion of sternocleidomastoid.

Specimen Five

This is a right ear (Figure 20) and demonstrates only one node in the pre-mastoid area with lymphatic vessels running from the auricle to the node and then inferiorly from the node.

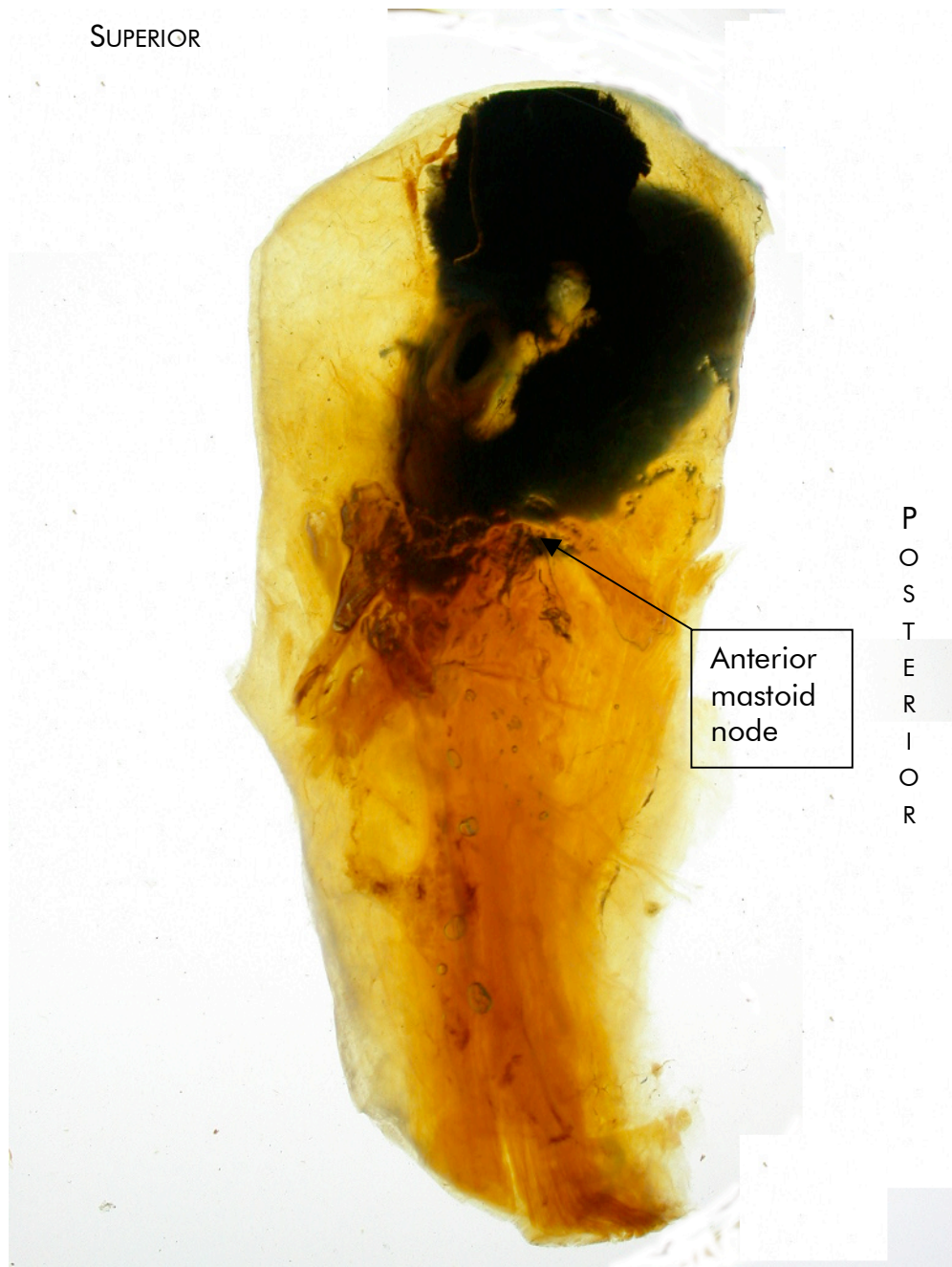

Figure 22 - Specimen Five Lateral View

Discussion

Summary of Results

There is clear demonstration that there are at least five potential lymphatic pathways draining the auricle to a first lymph node. (Figure 21) Working from anterior to posterior:

1. A pre-auricular pathway to pre-auricular or superficial cervical nodes.
2. A pathway from the lower auricle immediately posterior to the external auditory canal to a node lying immediately anterior to the mastoid bone.
3. There are vessels bypassing the anterior mastoid node to communicate directly with nodes in the lower parotid.
4. There is a pathway from further supero-posterior on the auricle which traverses the insertion of the sternocleidomastoid muscle to reach deep cervical nodes on the deep surface of the muscle.
5. Finally vessels descend from yet further supero-posterior on the auricle to a post-auricular node.

This gives five likely locations for potential sentinel nodes:

1. Pre-auricular or superficial cervical
2. Lower parotid
3. Anterior to the mastoid bone
4. Deep to the insertion of sternocleidomastoid inferior to the mastoid bone
5. Post-auricular

It is also apparent that there are vessels which form anastomoses around post-auricular and mastoid lymph nodes. This means that

embolic tumour cells have a pathway to bypass these nodes. There are no anastomoses apparent around the lymph nodes deep to sternocleidomastoid or in the parotid gland. This implies that embolic tumour cells should reach these nodes even if they bypass the mastoid or post-auricular nodes.

In three specimens (1,3&5) there is evidence of a lymph node in a position that prior to dissection would have been just anterior to the mastoid and inferior to the external auditory canal. The lymphatic channel that was encountered running next to the mastoid bone undoubtedly leads to this node which will be several centimetres under the skin. This node is not present in the rest of the specimens despite apparent penetration of ink to the required distance. This could indicate that this node is only present in a certain proportion of individuals and could explain why in the clinical setting some patients present with metastatic disease which has infiltrated the base of skull and adjacent nerves by the time it becomes clinically palpable, while others present with what are possibly more easily detectable metastases of the post-auricular, tail of parotid or cervical chain nodes. Curiously the three specimens in which this node is present are all right ears.

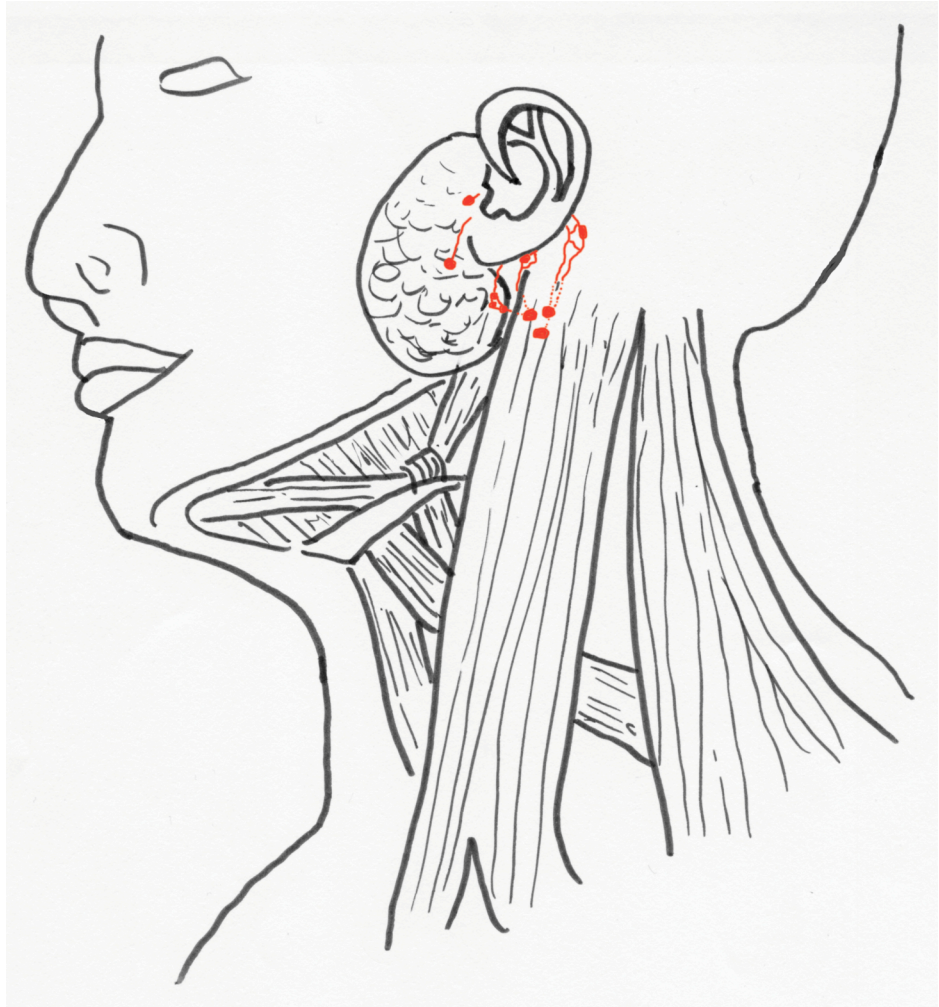


Figure 23 - Diagrammatic representation of lymphatic pathways from the auricle to first echelon lymph nodes

Strengths and Weaknesses of This Study

This study is limited by the small number of cases that have been examined with only five studies performed in three cadavers. These have all been of Caucasian origin. The distance travelled by the Indian ink through the lymphatic system has been variable and in several instances has failed to reach beyond the closest nodes. Thus there has been no demonstration of variability that may exist in lymphatic pathways in the general population or in different races.

There has been no demonstration of dynamic flow and no comment can be made about the direction that flow of lymphatic fluid and embolic tumour cells takes in the living. The demonstration of anastamotic pathways around lymph nodes could explain why some sentinel lymph nodes have been found in previous work to be in abnormal locations but it is not possible to know from this work what influences the direction and volume of flow in these. In the living such flow may be constrained by local vessel tone, valves or other mechanisms which become unapparent post-mortem. Conversely there may also exist lymphatic vessels which are kept open during life but collapse after death and have not been demonstrated here.

The lymphatic pathways that have been demonstrated in this study have appeared to come from certain parts of the auricle but no conclusions can be drawn about what part of the auricle they drain. This study has looked at the auricle as a whole and inferences about lymphatic drainage of any particular part of the auricle cannot be made upon the basis of this work.

Despite these weaknesses the study has effectively demonstrated several lymphatic pathways and identified nodal locations. The technique used in this study seems to have worked best when the

embalming fluid was infiltrated distally through the ipsilateral common carotid artery. This is conceivably due to the fact that it has caused some additional flow in the lymphatic vessels during the embalming process. The skin of the cadaver perceivably changes colour as the embalming fluid is infiltrated and is therefore likely to increase pressure inside the tissues and then forcing fluid through lymphatics.

Even with this apparent success of the technique it is impossible to know how effective this technique is in penetrating all the available lymphatics. Given that Indian ink solution is made up of a range of particle sizes in solution it may be that only certain lymphatic vessels permit entry of these particles and the massaging used to move the ink after injection may favour vessels of larger calibre.

Comparison With The Work of Others

This work confirms the described existing pathways of lymphatic drainage of the auricle to post-auricular, mastoid, pre-auricular, parotid, superficial and deep cervical lymph nodes.^{57, 59} However only one specimen demonstrated any flow to superficial cervical lymph nodes, which are commonly mentioned in textbooks.

The presence of this lymphatic channel crossing through the insertion of the sternocleidomastoid is absent from modern textbooks although its presence has been noted before by Rouviere in his early work on lymphatics.⁵⁸ This pathway has serious implications for the operative technique used and knowledge of its presence is paramount for head and neck surgeons.

The use of Indian ink solution for the staining of lymphatics has previously been discouraged by authors such as Turner-Warwick who felt that they were not diffusible enough to provide good staining of lymphatics.⁸⁴ This study has however demonstrated that they can be carried by lymphatics and provide excellent persistence after clearing.

Meaning of This Study

The findings of this study are useful in clinical practice in two areas: Firstly with reference to sentinel lymph node biopsy the potential five locations of sentinel nodes can be used with pre-operative lymphoscintigraphy to plan incision sites and dissection strategy. Knowledge of the lymphatic pathways is helpful when performing a sentinel node biopsy with blue dye to guide dissection. In particular knowing a pathway crosses the insertion of sternocleidomastoid means that the operator can look for sentinel nodes deep to the muscle rather than dissecting the muscle off the mastoid in order to follow the blue stained vessels. The dissection of blue stained lymphatics is a time consuming and delicate procedure and knowledge of where they are likely to terminate allows directed dissection of lymph nodes which can be localised with a gamma probe.

It is also important to be aware of the presence of anastamotic pathways around the most proximal nodes that drain the auricle. These nodes could easily be the first identified at a sentinel node procedure and the temptation to remove only these node(s) could lead to a false negative sentinel node biopsy.

Secondly with reference to lymphadenectomy procedures it is important when trying to surgically remove any lymphatic deposits of tumour to perform an oncologically sound procedure. This means complete removal of the efferent lymphatic pathways and lymph nodes. In order to achieve this it will be necessary to dissect in a sub-peri-osteal plane on the mastoid bone and remove the insertion of sternocleidomastoid.

Unanswered Questions and Future Research

Further work would be required to confirm the frequency with which these pathways and nodal locations occur in the general population and between different racial groups. It may be of value to try the technique with different dyes such as Pontamine Sky Blue or Direct Sky Blue which are believed to be more easily transported in lymphatics and less persistent at the injection site.⁸⁴

It would also be of great value to try to demonstrate these pathways in living tissue. This could be done at the time of sentinel node biopsy for auricular malignancies and would answer some of the questions about flow in these pathways. It may also be possible with a sufficient number of positive sentinel node biopsies to determine whether or not the anastamotic pathways around the post-auricular and mastoid nodes allow the passage of tumour cells to lower nodes – so called ‘skip metastases’.

Conclusions

In order to confidently remove the likely potential locations of sub-clinical metastatic disease in the lymph node basins any lymphadenectomy must include the pre-auricular nodes, post-auricular nodes, superficial parotid gland, upper deep cervical chain and special attention must be given to resecting the tissue between the mastoid and the mandible just inferior to the external auditory canal with at minimum sub-periosteal resection and possibly removal of the mastoid process. In addition the upper end of the sternocleidomastoid muscle must be sacrificed. In line with other selective neck dissection it would be standard to also remove the next level down the lymphatic chain and this would mean including levels two and three. In a clinically node negative patient this should provide adequate staging and if small metastatic deposits are found on pathological examination they would likely be confined to the upper part of the specimen and therefore not likely to require further surgery.

When performing sentinel node biopsy the sentinel nodes may be found at any one of these locations but it must not be assumed that the node(s) closest to the auricle are the first nodes to which tumour may travel due to the presence of anastamotic pathways around these nodes.

Sentinel Lymph Node Biopsy for Auricular Squamous Cell Carcinoma

Summary

Introduction

Sentinel lymph node biopsy is an emerging technique which has gained much favour in the treatment of malignancies such as breast cancer and melanoma because it allows accurate staging of the regional lymph nodes with minimum morbidity. Early accurate staging of the regional lymph nodes in auricular squamous cell carcinoma is desirable because of the difficulty in treating established metastases.

Materials and Methods

28 cases of auricular squamous cell carcinoma in 27 patients were recruited for sentinel lymph node biopsy.

Results

No patient was found to have evidence of metastases in the regional lymph nodes. One patient proved to have non-viable tumour cells in one node. There was a high complication rate of the sentinel node biopsy procedure. No patient has developed evidence of regional metastases in the follow up period.

Conclusions

Sentinel lymph node biopsy for these tumours seems to be technically possible but care has to be taken to minimise complications. The results do not support the routine use of sentinel lymph node biopsy in auricular squamous cell carcinoma. The lymphatic drainage patterns discovered with this technique have significant implications for performing neck dissections for spread of these tumours.

Introduction

Sentinel lymph node biopsy is an emerging surgical tool in the management of malignancies that develop lymph node metastases. The technique was born out of a need for accurate staging of the regional lymph node basins to allow treatment to be directed only where and when it is needed. Prior to the development of this technique there were two previous accepted methods for the management of the local lymph node basins in patients with no clinical evidence of lymphatic metastases; the 'wait and see' policy where regular clinical assessment or radiological imaging was used to direct therapy to the lymph node basins and the prophylactic treatment policy either by elective lymphadenectomy, radiotherapy, chemotherapy or a combination of these. Electively removing the lymph nodes had the combined benefit of providing histo-pathological staging of disease that could direct other therapy or provide prognostic information for the patient.

Historically patients were allocated to one management policy or another based upon a cost benefit balance between the risks and morbidity associated with the treatment and the potential for the primary tumour to develop metastases based upon what was known about the primary tumour staging. There has been no cost benefit analysis of this kind done specifically for auricular squamous cell carcinoma but malignancy of the upper aerodigestive tract drains to similar lymph node basins and therefore morbidity and risks of elective lymphadenectomy are similar. For malignancies at this site a 15 to 20% risk of development of lymph node metastases is accepted as sufficient to direct elective neck dissection.^{72, 85, 86}

Auricular squamous cell carcinoma has a metastatic rate of around 11% and there is insufficient information available to stratify the risks of specific tumours.¹⁻³ This means that elective lymphadenectomy or other treatment to the lymph node basins cannot be determined.

Sentinel lymph node biopsy is a less invasive technique than a formal lymph node dissection and is believed to have less morbidity. Therefore it is applicable in tumours with a reduced risk of development of metastases when compared to elective neck dissection.⁸⁷

The Sentinel Node Concept

The technique of sentinel lymph node biopsy relies upon the assumption that lymphatic fluid and tumour cells from the region of the body where the tumour lies drains consistently to one or more lymph nodes. The first lymph node(s) encountered by the efferent lymphatics from the tumour site are termed the first echelon nodes and represent the most likely location for embolic tumour cells to become seeded once they leave the primary tumour. Since lymph nodes lie in chains and drain from one to another before eventually draining towards a central collecting system and into the venous circulation, there are also second echelon nodes, third and so on. The early sentinel node work relied upon knowing the anatomical location of the first echelon node and removing it for histological examination.

The technique used now is a dynamic method for locating these first echelon nodes which allows for variations in lymphatic drainage patterns between individuals and can be applied to any tumour site for which there may not be information about the first location of metastases. Two types of tracer material can be injected around the edge of a tumour, which help to locate the

sentinel nodes. Firstly radioactively labelled colloid can be injected. This is taken up by efferent lymphatics and travels to the lymph nodes where it becomes bound and hence concentrates the radioactivity. This allows dynamic or static images to be taken with a gamma camera and a gamma probe to be used to locate the nodes. Secondly coloured dyes such as patent blue are similarly injected and taken up in lymphatic vessels. These act as a visual guide when dissecting tissue and allow easy identification of target nodes.

History of Sentinel Node Biopsy

The term was originally introduced for a surgical technique for harvesting lymph nodes at specific locations which were known to be the first location for lymphatic metastases for specific malignancies.⁸⁸ Gould is credited with the first description of this for tumours of the parotid gland where frozen section examination of a node that lay at the junction of the anterior and posterior facial vein would be used to decide upon the need for a neck dissection or not. This prompted others such as Cabañas and Chiappa who studied the lymphatics of the penis and the testicle respectively to find sentinel node locations for tumours at these sites.^{89, 90}

The use of dynamic location of nodes was pioneered by Morton, for melanoma, who injected gold to locate lymph nodes and later added blue dye.⁹¹ Guiliano introduced the use of blue dye for breast cancer but the use of these dyes in tracing lymphatics can be traced much further back to earlier anatomical work such as that of Turner-Warwick.^{84, 92}

Reintgen and Kapteijn published work to show that metastatic spread followed a stepwise progression starting in the first echelon

node(s) and this validated sentinel lymph node biopsy as a staging tool in melanoma and breast cancer.^{93, 94}

Recently our own unit has pioneered the use of this technique in malignancies of the upper aero-digestive tract and so far it has proved to be a reliable and accurate method of staging the lymph nodes.^{75, 95}

The Current Use of Sentinel Lymph Node Biopsy

Despite the validation of the technique its use in melanoma remains controversial. It is the most useful prognostic indicator and recently there has been some suggestion that patients who have elective lymph node dissections based upon sentinel lymph node biopsy may have some survival advantage over a wait and see policy but this is far from established fact.⁹⁶⁻⁹⁹ Certainly in centres where elective lymph node dissections were performed for melanoma it has reduced the morbidity. The presence of lymph node metastases is an indicator of systemic disease and warrants therapeutic lymph node dissection.⁹⁷ More work is being carried out at present to determine if there is a survival advantage for those patients with micro-metastases in sentinel lymph nodes. This may be a group of patients whose only metastatic spread is to the regional lymph nodes and not associated with distant metastases. Many clinicians will still offer patients sentinel lymph node biopsy because of the prognostic information which may be of value to the patient and current SIGN guidelines recommend that it should be considered in all patients.¹⁰⁰ In some cases it can allow a patient to be entered into a clinical trial because of upstaging of disease.

Potential Usefulness In Auricular SCC

Lymph node metastases from auricular squamous cell carcinoma are associated with specific problems due to their proximity to the skull base and associated nerves and vessels. Resection of these lymph node metastases once established is associated with significant morbidity and it is often failure to control loco-regional disease that leads to death.^{2, 3, 45} Accurate and early staging of the local lymph nodes in auricular squamous cell carcinoma is beneficial as usually loco-regional control is curative. In auricular squamous cell carcinoma distant metastases are exceedingly rare with only one case reported.⁴⁵

It would seem therefore an inviting disease for sentinel lymph node biopsy but there are several features of the auricle that require special consideration before employing this technique. The auricle is known to drain to three different lymph node basins – the parotid, post-auricular and deep cervical.^{58, 101} There are several different pathways for a rather small area of skin and this is different to the rest of the skin of the body. It is likely that the lymphatic drainage territories overlap and even if they did not a tumour would not need to grow to a particularly large size to affect two or even three different drainage pathways. This possibility for tumour spread may explain to some degree why auricular squamous cell carcinoma has a metastatic rate of 11% when compared to the rate of 0.5-2% for the skin of the body as a whole.^{9, 13} However this choice of pathways may lead to discrepancies with sentinel node biopsy as it assumes that they are all patent at all times – there is no direct evidence for this. In addition the proximity of the primary tumour to the expected location of lymph nodes will make pre-operative imaging with a gamma camera difficult. This has in the past lead to a failure of the technique in accurately staging disease in the neck.⁷⁵

Study Design

Canniesburn Plastic Surgery Unit has in recent years excised approximately 50 auricular squamous cell carcinomas per annum. This figure was obtained by reviewing pathology reports, copies of which are collected centrally. The time allocated to this project was two years giving a maximum of 100 cases. Patients with auricular squamous cell carcinoma are known to be elderly and often have co-morbidities. Many of these co-morbidities include conditions that would significantly increase the risk of a general anaesthetic to the patient and therefore would exclude them from any sentinel node trial.¹⁰² It was estimated that approximately 40 patients could be recruited over two years.

One possible study design was to randomise patients into two groups with one group of patients having SNB and the other group acting as controls. This would allow the comparison of SNB and targeted therapy to affected lymph node basins with clinical observation and subsequent treatment of affected lymph node basins. The end-point of such a trial would be evidence of lymph node recurrence in controls or sentinel node negative patients. A simple power calculation shows that even if sentinel lymph node biopsy detected all metastatic spread, i.e. the recurrence rate in that group was nil, then 67 patients would be required in each group for a power of 0.80 and a probability of 0.05.

Power Calculation

$p_1 = 0.11$ – 11% expected recurrence in control group

$p_2 = 0$ – 0% expected recurrence in sentinel node group

$\alpha = 0.05$

power = 0.80

group size = 67 in each group

A reverse power calculation shows that if 40 potential patients were recruited and split in to 2 groups of 20 then the power of the study would be 0.27 which is too low to provide any meaningful results.

For these reasons a non-randomised observational study was designed which would allow the evaluation of sentinel lymph node biopsy as a staging tool for the lymph node basins potentially involved in auricular squamous cell carcinoma. The histopathological processing that sentinel lymph nodes are subjected to is believed to make it highly unlikely that any metastatic spread is missed. This means that patients could act as their own controls with evidence of lymphatic spread outwith the sentinel nodes taken to be a failure of the technique. It is possible to perform completion lymphadenectomy procedures after sentinel node harvesting as is done for melanoma of the head and neck.⁹⁷ For auricular carcinoma this would require a neck dissection, superficial parotidectomy and post-auricular node resection. This is not the current standard of care and would subject the majority of patients in the study (expected 89%) to lengthy unnecessary procedures with associated significant morbidity. Furthermore in order to be sure that none of the non-sentinel nodes in the specimens contained tumour they would all have to be meticulously dissected out and subjected to the same histopathological analysis as the sentinel nodes.

The alternative was to perform sentinel lymph node biopsy without completion lymphadenectomy and then monitor the patient for clinical signs of recurrence. Previous reported series have shown that 85% of metastases declared within 12 months of the initial tumour and only a few isolated cases have occurred after 24 months.^{3, 36, 38, 45, 65} This design has the advantage that patients are not subject to additional unnecessary surgery and treatment is similar to current practice.

Materials and Methods

Patient Recruitment and Enrolment

Ethical approval was obtained for the study from Glasgow Royal Infirmary's local ethics committee. Patients were recruited from a weekly clinic held every Monday morning in outpatient department of Canniesburn Plastic Surgery Unit. All plastic surgery consultants and registrars were written to and personally canvassed to refer all new cases of auricular squamous cell carcinoma to this clinic. All dermatology consultants in Glasgow and surrounding area were also written to request referral of appropriate patients.

Patients were included in the trial if they had histological evidence of auricular squamous cell carcinoma. (Table 8) This could be by incisional, punch or excision biopsy. Patients were excluded if they were deemed to be at risk from the procedure due to the nature of the surgery and anaesthetic involved. For the purposes of the study this was defined as an American Society of Anaesthesia Grade 3 or higher. Pregnant patients were to be excluded on the grounds that radioactivity could damage a foetus and under 18 year olds were excluded on ethical grounds.

Table 8 - Inclusion and exclusion criteria

Inclusion Criteria	Biopsy proven Auricular SCC
Exclusion criteria	ASA Grade 3 or over
	Clinical Evidence of Lymph Node Metastases
	Age < 18 years
	Pregnancy

(ASA- American Society of Anesthesiologists)

Pre-operative Lymphoscintigraphy

The radio-colloid (Tc-99 labelled Nanocol) was injected around the edge and deep margin of the tumour within the 24 hours preceding surgery. Local anaesthesia was not used as it was felt this may affect blood flow and hence lymph flow. The dose used was between 20-30mBq in line with ARSAC guidelines in a volume of 0.2 to -0.3 ml. The patient was imaged with a gamma camera 15 minutes after injection. A cobalt 57 flood was used to provide an outline of the patient's head in order to ease with image orientation and node localisation at the time of surgery. Lateral images were obtained with the primary injection site obscured with a lead mask. (Figure 22) In cases where it was felt possible that the lead mask may have been overlying the possible site of target nodes, a second image was taken without the lead mask and software masking used. Anterior images were obtained in the first few cases but were thereafter abandoned, as they provided no useful information. Images were printed and used to guide surgery. A permanent marker was used to place a mark over the target node guided by a radioactive tipped pen.

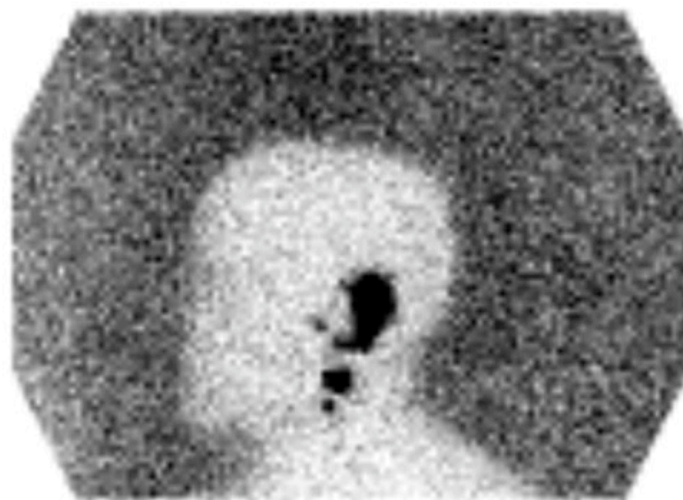
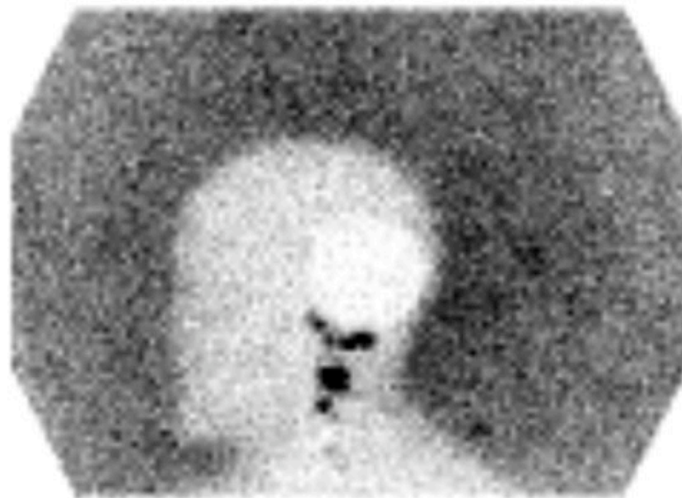
Figure 24 - A typical Pre-operative Lymphoscintigram Showing Superiorly an Image with a lead mask over the Primary Tumour and Inferiorly an Image Without. Nodes are visible Pre and Post-Auricular and in the tail of the parotid gland.

Operative Technique

Within the next 24 hours the patient's operation was performed. This was usually done under general anaesthesia although in two cases regional anaesthesia and sedation was used. After induction of anaesthesia blue dye (Patente Blue) was injected in a similar fashion to the radio-colloid around the edges of the tumour. The position of the radioactive nodes was then checked with a hand held collimated gamma probe (Neoprobe) to ensure the skin markings were accurate after the positioning of the patient. The probe was then systematically swept at a slow speed over the parotid gland, post-auricular region and upper neck to look for possible sites of radioactivity that had been missed or obscured by the primary tumour site during the imaging phase. Any additional areas of radioactivity were marked. A skin incision was then designed to give access to the target areas in such a fashion that it could be incorporated into any incisions made for further surgery for completion lymphadenectomy. Dissection to identify nodes guided by blue stained lymphatics and the hand held probe then followed with careful attention to the preservation of nerves particularly the facial and greater auricular. Nodes were labelled as hot or cold depending on whether the level of radioactivity in them was above background and blue or pale if there was evidence of blue staining or not. Once all target nodes had been removed and the wound closed then the primary tumour was excised. Nodes were identified by location and this was subdivided into parotid, superficial cervical, deep cervical, mastoid (nodes immediately anterior to the mastoid bone but not in the parotid), post-auricular, pre-auricular (not in parotid).

Histo-pathological Processing

The primary tumour specimens were processed according to our pathology department's standard protocol with blocks taken to study the morphology of the tumour and assess margins. The sentinel lymph nodes were analysed according to a protocol, which was set up previously in our unit for oral and oropharyngeal squamous cell carcinoma. It is known from this previous sentinel node work that the use of additional histology such as step serial sectioning and immunohistochemical stains increases the detection rate of metastases by up to 20% when compared with conventional histological examination.^{95, 103} Sentinel nodes were initially inspected grossly and measurements taken, they were then bisected longitudinally through the hilum and initial sections taken from the surface of each half and stained with haematoxylin and eosin staining (H&E). If no tumour was found at this stage the remaining tissue was divided at 150 micron intervals working outwards from the initial bisection and in the same plane. Two sections were then taken from each side of this division giving four sections from every 150 micron interval. These sections were numbered 1 to 4 from the centre of the node outwards. Section numbered 2 was then stained with H&E and examined. If no tumour was evident then sections numbered 3 were stained with a cytokeratin 8 and 18 marker (AE1/AE3, Mouse Anti-Human Cytokeratin Clone, Dakocytomation). These sections were then examined. Sections 1 and 4 were kept in reserve in case further examination was required because of technical failure or diagnostic dubiety.

Post-operative Management

No specific treatment protocol was defined for those patients who showed evidence of tumour within the lymph nodes. There are several treatment options and the decision to use any or all of these would be based upon the level of disease present in the sentinel nodes, the co-morbidities and wishes of the patient. Our unit presents weekly at a multidisciplinary head & neck cancer meeting and it was proposed that any patients with positive sentinel nodes would be discussed at this venue to plan treatment options.

Patients without evidence of tumour in sentinel nodes would be followed up in clinics every three months for the first two years and six monthly thereafter till five years had passed since they had active disease. A clinical examination of lymph node basins would be carried out at each clinic visit and any suspicion of disease would be investigated by ultrasound scan with fine needle aspiration cytology where appropriate.

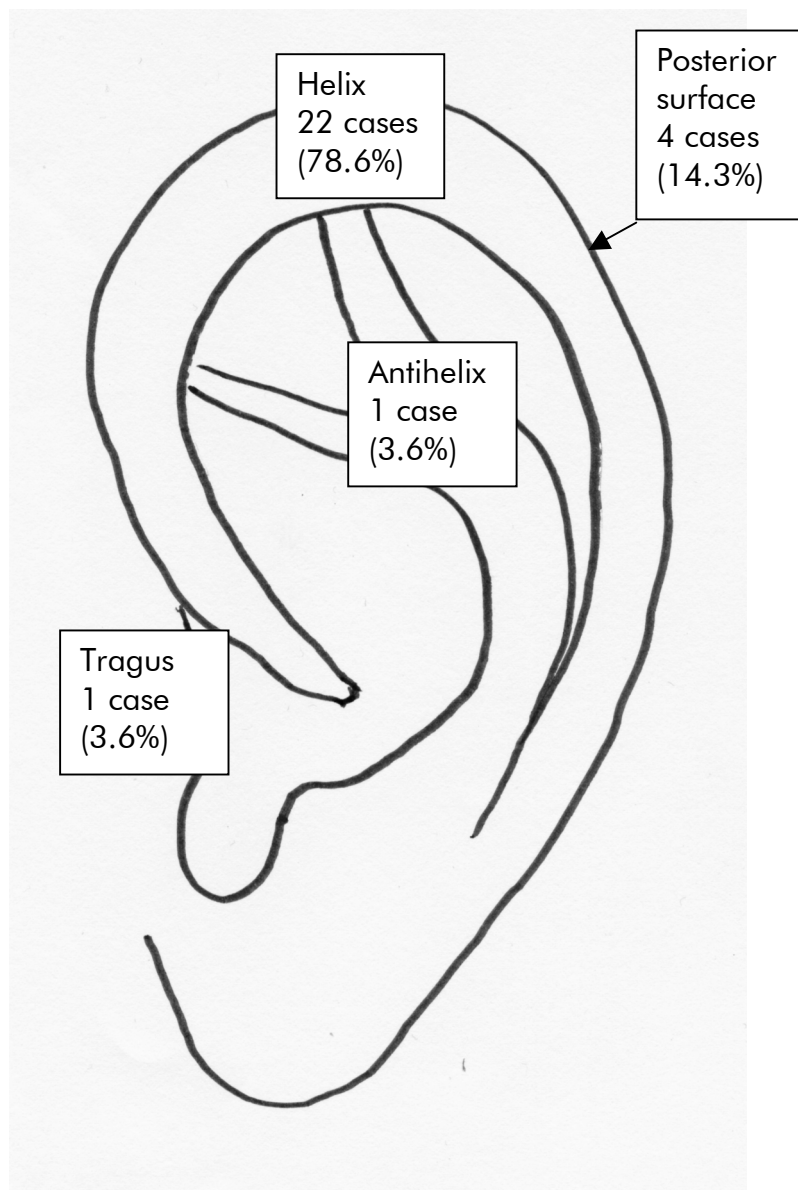
Results

A total of 29 instances of auricular squamous cell carcinoma were diagnosed by biopsy in 28 patients who consented to be enrolled in the study. One case was bilateral and a simultaneous procedure was carried out on both sides. One case was diagnosed as SCC on the basis of an incisional biopsy and enrolled in the study. However upon formal excision of the lesion and sentinel node biopsy the diagnosis was changed to basal cell carcinoma with areas of squamous differentiation. This reduced the total number of definitive cases of auricular squamous cell carcinoma to 28 in 27 patients. 16 of these were on the right and 12 on the left.

Of the 28, 8 (29%) had their tumour diagnosed by excision biopsy prior to referral for the study the remainder had an incisional biopsy to confirm diagnosis.

The commonest location of primary tumours was on the helical rim that accounted for 22 tumours (78.6%), followed by the posterior surface with 4 tumours (14.3%) and tragus and anti-helix each accounted for one case (3.6%). (Figure 23)

Figure 25 - Location of Primary Tumours



Histo-pathological Findings

Primary Tumours

The primary tumours varied in their size and histological features (Table 9) both of which have been suggested as possible indicators of increased metastatic potential. (Table 10) The maximum diameter ranged from 5 to 36mm with a mean of 16.3. Depth of invasion ranged from 1 to 10mm with a mean of 3.7. Four tumours were felt to be well differentiated, 13 moderately well differentiated and 11 poorly differentiated. Six had non-cohesive invasive fronts and four displayed evidence of peri-neural invasion. No tumours were found to have evidence of vascular or lymphatic channel invasion. All tumours were completely excised at peripheral and deep excision margins. At no point in any of the examined margins was the completeness of excision thought to be in question.

Sentinel Lymph Nodes

One patient had two cytokeratin positive cells at the periphery of one lymph node located in the tail of the parotid gland. (Figure 24) There were no nuclei visible in these cells. (Figure 25) These were interpreted to be non-viable tumour cells. No further treatment was given to this patient. This patient's primary tumour was a 5mm thick poorly differentiated SCC with evidence of peri-neural invasion on the left helix.

No patients had evidence of viable metastatic tumour cells in sentinel lymph nodes after full examination with the sentinel node protocol. This gives a metastatic rate of 0% in this series (95% confidence interval 0-12%).

Table 9 - Histo-pathological features of primary tumours

Case Number	Maximum diameter	Depth of invasion	Degree of Histological Differentiation	Invasive front	Structure invasion
1	20	5	poor	Cohesive	None
2	14	3	moderate	Cohesive	None
3	12	1.8	well	Cohesive	None
4	14	3	poor	Non-cohesive	Peri-neural
5	13	3	moderate	Cohesive	None
6	13	4	moderate	Cohesive	None
7	12	2	moderate	Cohesive	None
8	12	1.8	well	Cohesive	None
9	15	1	moderate	Cohesive	None
10	15	2	moderate	Cohesive	Peri-neural
11	36	6	poor	Cohesive	None
12	13	2.5	poor	Non-cohesive	None
13	25	4	moderate	Cohesive	Peri-neural
14	5	5	poor	Non-cohesive	Peri-neural
15	18	4.4	poor	Cohesive	None
16	22	4	moderate	Cohesive	None
17	14	2.5	moderate	Cohesive	None
18	20	5	poor	Non-cohesive	None
19	15	5	moderate	Cohesive	None

20	10	2	moderate	Cohesive	None
21	22	3	well	Cohesive	None
22	12	2	moderate	Cohesive	None
23	25	3	well	Cohesive	None
24	15	6.5	poor	Non-cohesive	None
25	10	4	poor	Cohesive	None
26	20	10	poor	Non-cohesive	None
27	14	4	moderate	Cohesive	None
28	20	3	poor	Cohesive	None
Maximum	36	10			
Average	16.3	3.7			
Minimum	5	1			

Figure 26 – Cytokeratin stained cells at 40x Magnification

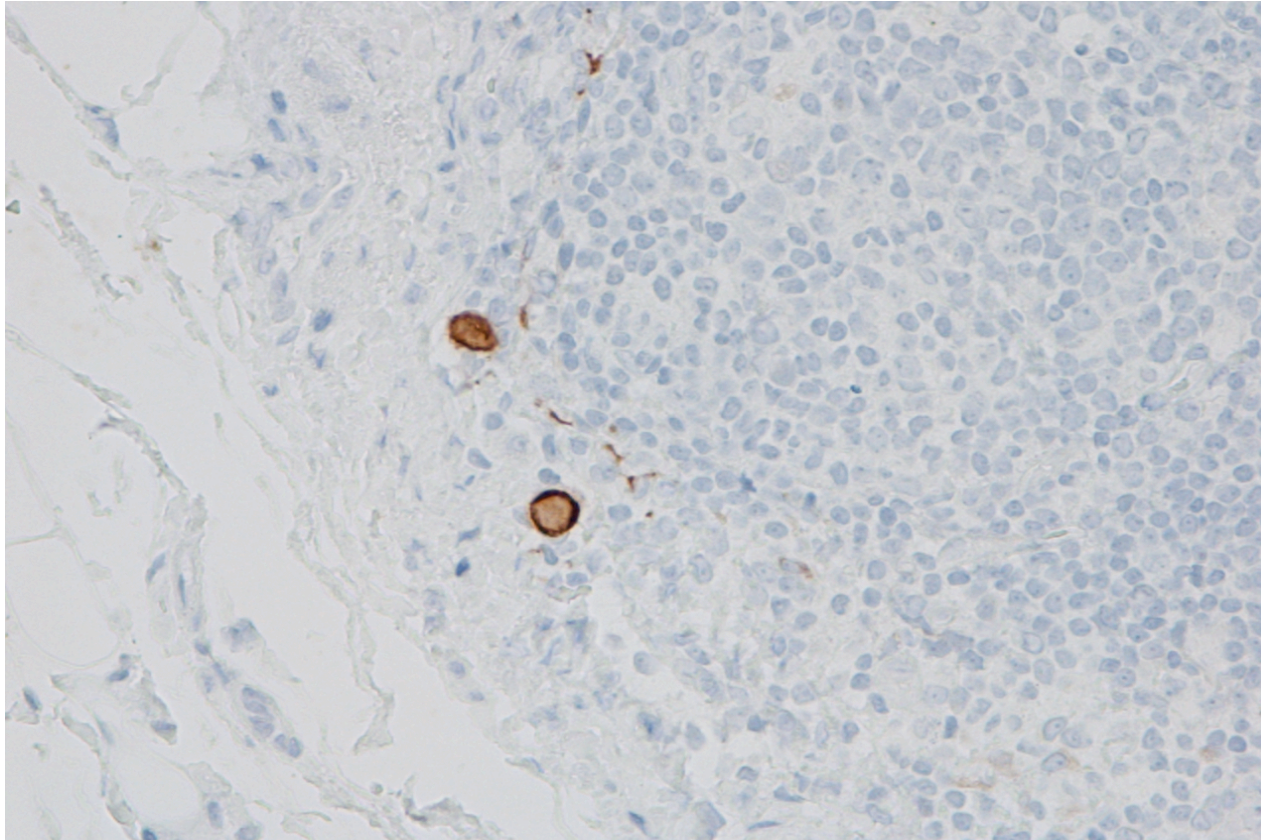


Figure 27 – Adjacent section stained with haematoxylin & eosin 40x

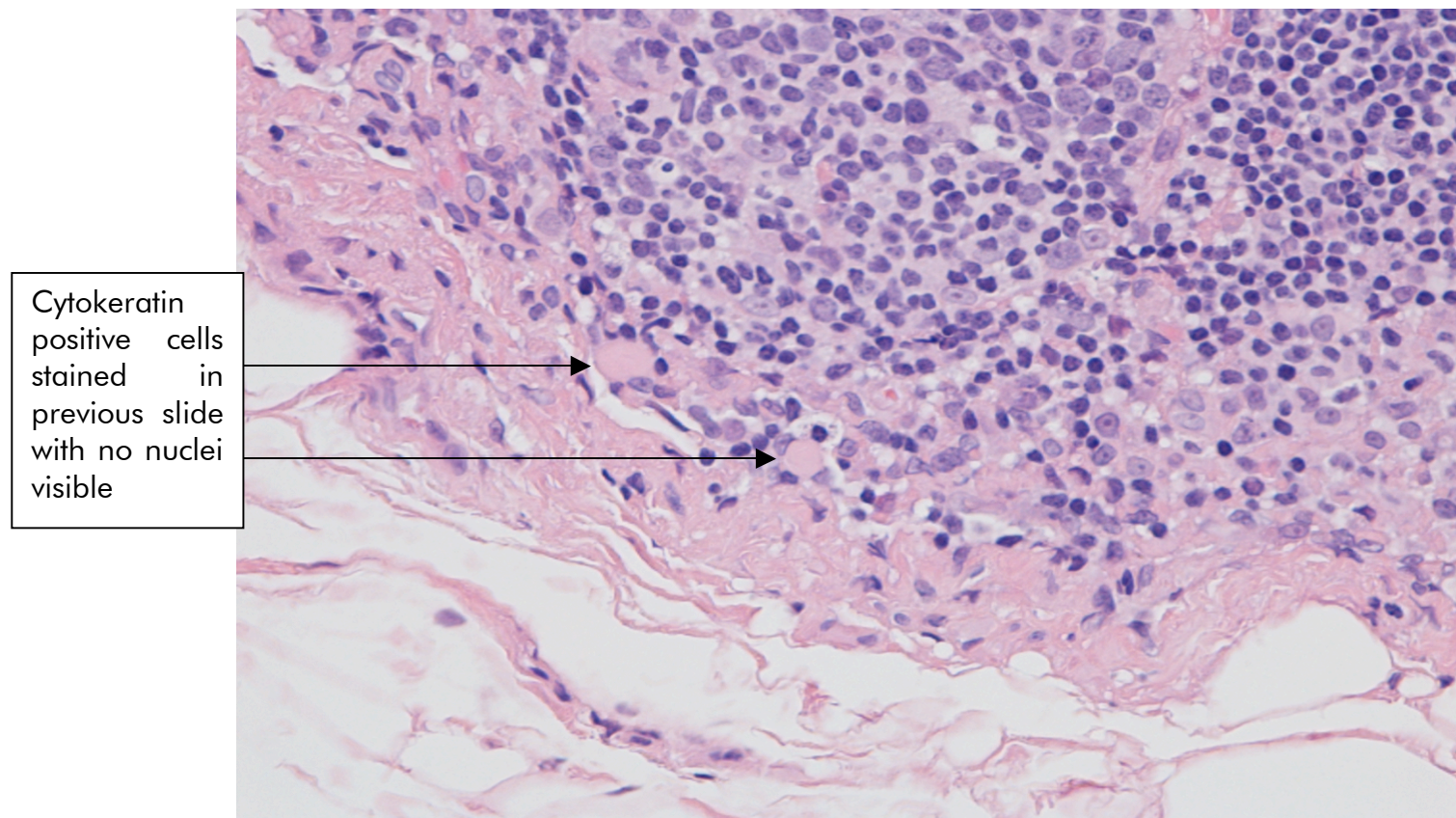


Table 10 – Number of Tumours with Potentially Adverse Prognostic Indicators

Non-cohesive invasive front	6 (21%)
Poorly Differentiated	10 (36%)
Peri-neural Invasion	4 (14%)
Depth > 4mm	8 (29%)
Diameter > 20mm	5 (18%)

Complications of Treatment

Infection was a commonly encountered complication. Two patients developed infection at the site of resection of the primary tumour. In one of these cases the site of sentinel lymph node biopsy also became infected. Isolated infection of the lymph node biopsy site occurred in two patients. Only the case with infection at both sites required re-admission and use of intra-venous anti-microbials to treat the infection. This was an infection due to a methicillin resistant staphylococcus aureus. The defect of the primary tumour was covered by a full thickness skin graft which was lost as a result of infection. The patient opted to allow the wound to heal by secondary intention rather than re-grafting after the infection had been treated. All other infections were treated as outpatients with oral antibiotics.

Four of the patients with infection occurred relatively early in the series including two of the sentinel node wound infections. These patients had not been given prophylactic antibiotics and the neck wounds had been noted to be slightly swollen of the first post-operative day. This resulted in a change of policy and all subsequent patients were given prophylactic intravenous antibiotics (co-amoxiclav 1.2G) at the start of the procedure. Additionally a small suction drain was placed in the sentinel node wound. These drains were invariably removed the morning following surgery with less than 20ml of fluid in them. Only one of the infections occurred after this policy was instituted.

One patient who had a wedge resection carried out for helical tumour developed a wound dehiscence. There was no obvious infection of the wound and the patient elected not to have further surgery to correct the resultant deformity.

One patient developed a temporary parasthesia in the distribution of the Greater Auricular nerve. This resolved gradually over the course of 4 months. This nerve was frequently encountered during surgery and often had to be retracted to allow access to target nodes located within the parotid gland.

Another patient complained of a firm 3cm diameter subcutaneous mass overlying the vastus medialis muscle on the thigh 4 months after the sentinel node biopsy. This had apparently appeared spontaneously at least 3 months after the procedure. This was treated by excision biopsy and histopathology reported an area of fat necrosis without obvious cause. No link has been established between this and the sentinel node biopsy procedure nor has any other cause such as precedent trauma been identified.

One patient developed a sore painful and inflamed scar over the antihelix following wedge resection of a helical tumour. This was diagnosed clinically as chondrodermatitis nodularis helicis. This diagnosis was confirmed by excision biopsy of the scar at which time the shape of the cartilage of the antihelix was refashioned.

One patient who had a total amputation of the auricle as a treatment for a primary tumour which involved the external auditory canal developed meatal stenosis which was treated by dilation.

This gives a total of 10 patients (35.7%) with some complication of treatment. Four of these (14.3%) are directly related to the sentinel node procedure. These were three neck wound infections and one temporary parasthesia of the greater auricular nerve. (Table 11)

Table 11 - Complications of Treatment

Complication	Number of Patients Affected
Wound Infection	5 (17.9%)
Of auricle	3 (10.7%)
Of neck	3 (10.7%)
Wound dehiscence	1 (3.6%)
Greater Auricular Nerve Palsy	1 (3.6%)
Chondro-deratitis	1 (3.6%)
Fat necrosis in thigh	1 (3.6%)
Meatal stenosis	1 (3.6%)
Total	10 (35.7%)

Location of Sentinel Nodes and Lymphatic Pathways

The commonest location of sentinel nodes was in the tail of the parotid gland with over half of the total number of nodes being found at this location. (Figure 26 & Table 12) Six nodes were harvested in direct contact with the periostium of the mastoid bone. Three of these lay anterior to the mastoid, two directly inferior and one on the lateral surface deep to the fascia at the superior end of the insertion of sternocleidomastoid (SCM). These nodes lay on two lymphatic pathways which were frequently encountered during the procedure. The anterior of these pathways ran subcutaneously in the post-auricular sulcus before turning medially to run along the mastoid just inferior to the external auditory canal then turned inferior still running along the mastoid before then descending towards the tail of the parotid gland. Nodes were encountered at various points along this pathway as it was in close contact with the mastoid, though never more than one node in any patient.

Posterior to this lay a second pathway which sometimes started at a post-auricular node, superior to the upper limit of SCM, then ran directly under the fascia of the SCM insertion and lying directly on the periosteum descended infero-medially across the insertion of the muscle to the upper end of the deep cervical chain. Again nodes were encountered at various points along this tract one under the SCM fascia and two deep to the SCM just inferior to the mastoid bone. Access to these last two nodes required SCM to be split along the line of its fibres, as it was not possible to gain access to this region from anterior or posterior by retracting the muscle.

The third commonly encountered pathway ran from the anterior auricle around the level of the tragus and drained to pre-auricular and superficial cervical lymph nodes.

Figure 28 - Locations of Sentinel Nodes

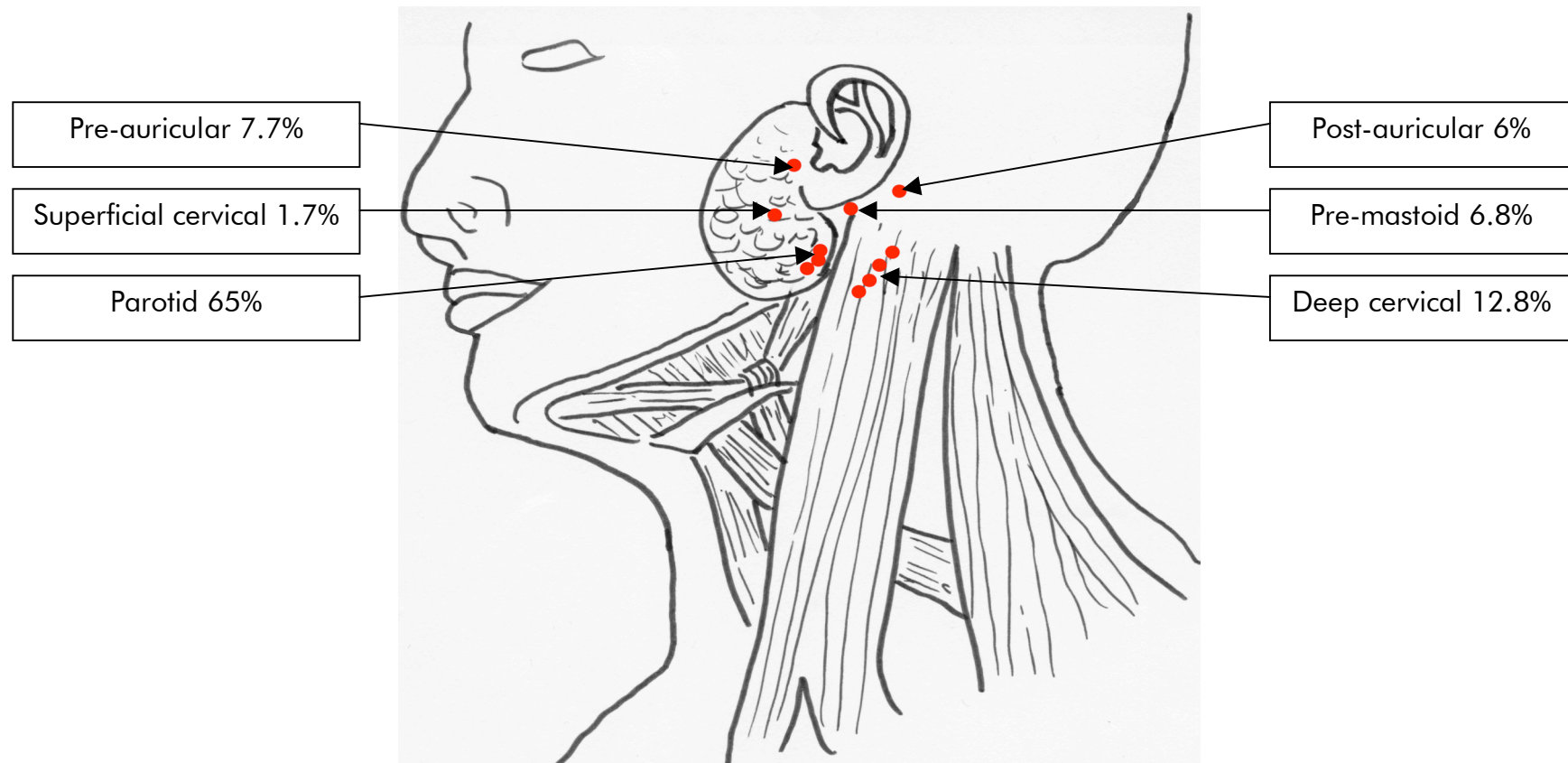


Table 12 - Distribution of nodal location

	Total Nodes	post-auricular	mastoid	parotid	pre-auricular	deep cervical	superficial cervical
Max	10	2	2	7	3	6	2
Average	4.2	0.2	0.3	2.7	0.3	0.5	0.1
Min	2	0	0	0	0	0	0
Total	117 (100%)	7 (6.0%)	8 (6.8%)	76 (65%)	9 (7.7%)	15 (12.8%)	2 (1.7%)
Cases present	28 (100%)	6 (21%)	6 (21%)	26 (93%)	7 (25%)	9 (32%)	1 (3.6%)

Table 13 - Identification of Nodes

	Hot and Blue	Cold and Blue	Hot and Pale	Cold and Pale
Maximum per patient	10	1	6	1
Average per patient	3	0.07	0.89	0.14
Minimum per patient	1	0	0	0
Total in all patients	84	2	25	4

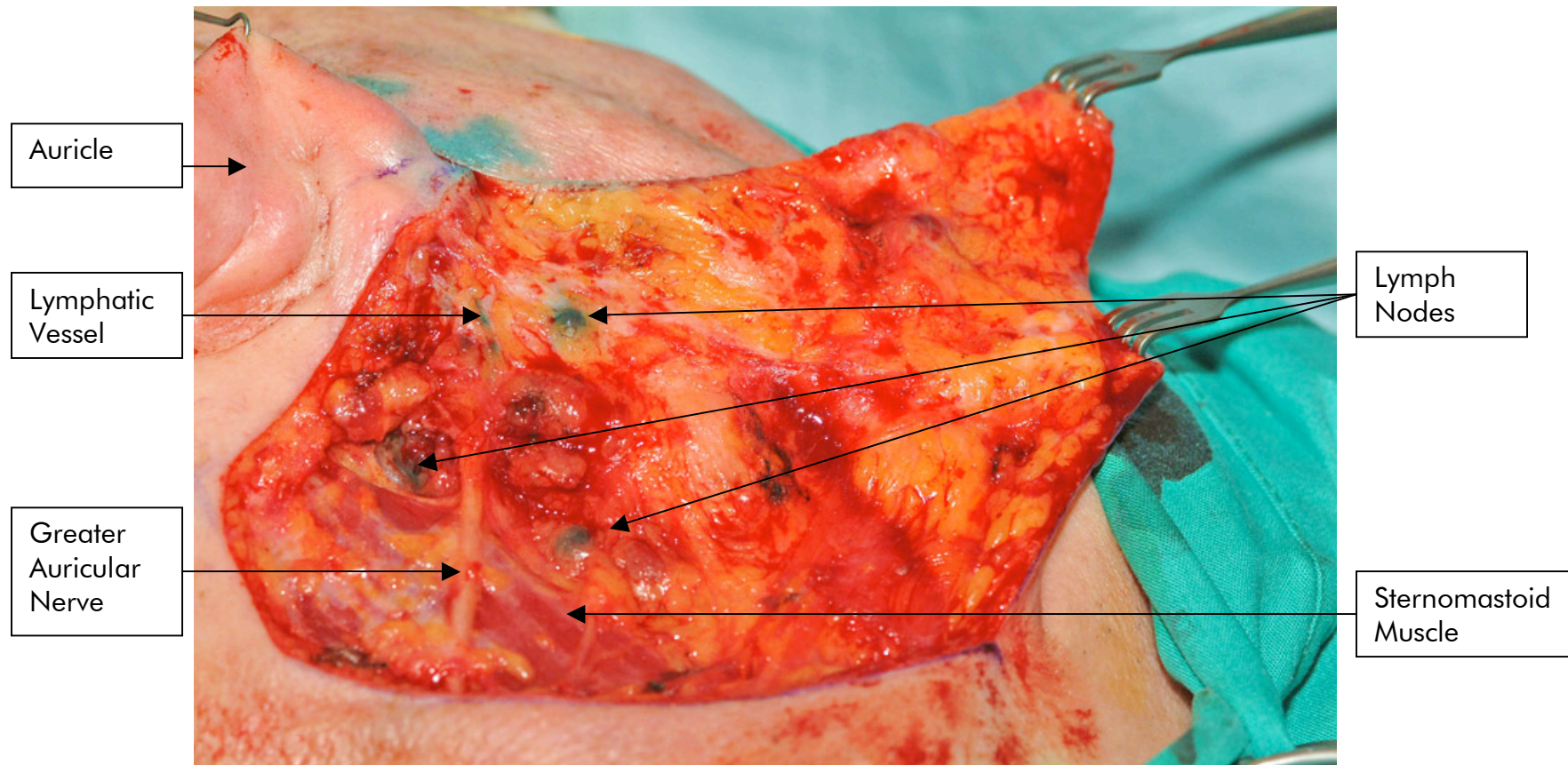


Figure 29 – A flap raised showing the position of the greater auricular nerve and blue stained nodes

Follow-up Period

No patients have to date developed evidence of lymph node metastases. Four have completed 36 months follow-up, seven have completed 30 months, ten have completed 24 months and seven, 18 months.

One patient has developed a second primary tumour on the same auricle. This tumour is 2cm distant to the site of the previous tumour and for that reason is not believed to be local recurrence. This was treated with local excision only.

Discussion

Summary of Findings

The metastatic rate in this series is 0 with a 95% confidence interval of 0-12%. No patient has subsequently developed evidence of lymph node metastases in the follow up period.

The finding of non-viable tumour cells in one lymph node demonstrates that the correct identification of target nodes has been achieved with this technique.

Three lymphatic pathways were encountered one draining from the anterior auricle to pre-auricular and superficial cervical nodes; a second one draining from behind the auricle to pre-mastoid and parotid nodes and thirdly posterior to this a pathway to post-auricular and deep cervical nodes which traverses the insertion of sternocleidomastoid.

Lymph nodes were encountered at various points along these pathways. The commonest location of lymph nodes was in the parotid gland.

The complication rate is high mainly due to wound infections. The use of suction drains and peri-operative antibiotics significantly reduced post-operative infection.

Strengths and Weaknesses of this Study

The zero rate of metastatic spread detected in this study is both a strength and a weakness. On one hand it had shown that the routine use of sentinel lymph node biopsy in these tumours is not justified. On the other hand one or more positive results would have given greater validation to the technique and provided information about whether early detection of metastatic spread conferred long-term benefit to the patient. A larger number of patients recruited to the study would eventually have yielded positive sentinel nodes and with this may have come some information about the characteristics of the primary tumour that correlated with a high risk of metastatic spread. The high complication rate re-enforces the argument against sentinel lymph node biopsy unless there is a high risk of metastatic spread.

Useful information has been provided on the technical aspects of the procedure including the likely location of nodes. This is applicable to all malignant tumours of the auricle to which sentinel lymph node biopsy can be applied notably melanoma. Additionally the specific details of the lymphatic drainage of these tumours have significant implications for performing either elective or therapeutic neck dissections for potential or definitive metastatic spread. To excise the lymph nodes identified here will require an extended neck dissection encompassing the superficial parotid gland, the post-auricular and mastoid nodal groups. Complete removal of these latter two groups will require the removal of the upper portion of sternocleidomastoid from the mastoid and clearing of the mastoid to a sub-periosteal level on the lateral, inferior and anterior surfaces.

It impossible to currently exclude the possibility that one of the patients in this series will subsequently develop metastases as not

all have yet achieved two years of follow up although follow-up for all patients is continuing.

Comparison With The Work Of Others

The metastatic rate of zero is not comparable with the previously reported retrospective series looking at squamous cell carcinoma of the auricle nor the historic rate within our unit.^{2, 3, 36, 38, 66} It is possible that the metastatic rate in this series has in some way been influenced by the study. All patients in this study were treated somewhat more quickly than would have normally been expected within our unit. This has happened because the research was carried out by a dedicated research fellow with dedicated theatre time allocated to research cases. This meant that all cases were usually seen within a week of referral and operated on within a further week. This compares with our normal protocol for referrals such as these that would have a clinic appointment 2 – 4 weeks from referral and be scheduled for surgery in 3 – 4 weeks following this.

Byers previously noted in his retrospective review of ASCC that a previous history of cutaneous malignancy conferred a lower risk of developing LNM.² There are several possible explanations for this and no conclusions were drawn from it at the time. It is possible that patients with a previous history of skin malignancy were able to be treated earlier because they were already under the care of a dermatologist or surgeon and knew the nature of the lesion. There is not sufficient information available about ASCC to determine whether a delay in treatment of a few weeks is sufficient to alter the metastatic rate. Mackie did however show that early referral for melanoma, within three months of first noticing the lesion, did significantly reduce the Breslow thickness of the tumour

which is a well established and accurate predictor of metastases.¹⁰⁴

Unlike other authors who have previously performed sentinel node work involving the parotid gland we have not found it necessary to perform superficial parotidectomies in order to harvest the nodes.¹⁰⁵ In our series we found it possible to achieve dissection of the sentinel node(s) and reduction of radiation levels in the basin to a background level without the need to remove additional tissue. This confirms what has recently been reported by Loree et al in melanoma where SNB did not complicate a further completion superficial parotidectomy with sparing of the facial nerve.¹⁰⁶

Meaning of the Study

This study has demonstrated that sentinel lymph node biopsy for auricular squamous cell carcinoma is technically possible but does have a complication rate. This means that if this intervention is to be offered to patients that the potential benefits of the procedure must be weighed against these complications as well as the additional hospital stay, operation length and wound size. The only benefit that any patient in this series has had is the reassurance that a negative sentinel node biopsy can offer. The reassurance can now be based on the fact that to date there have been no false negative results.

This study shows that there is no case for the routine use of sentinel lymph node biopsy in auricular squamous cell carcinoma. Currently sentinel lymph node biopsy remains a potentially interesting research tool in the management of these tumours but more work would need to be carried out to validate its routine clinical use. Particularly any method of stratifying patients into a

high-risk group as this could alter the cost-benefit ratio for the patient.

The lymphatic pathways encountered in this study and the location of the sentinel nodes have implications for performing elective or therapeutic neck dissections for primary squamous cell carcinoma of the auricle. A comprehensive resection in addition to a standard modified radical neck dissection should include the superficial parotid gland and overlying superficial nodes, the post-auricular node(s), the mastoid nodes, the sternocleidomastoid muscle and the periosteum from all sides of the mastoid bone. The resection could be facilitated by removal of the mastoid process and the upper end of sternocleidomastoid.

Unanswered Questions and Future Research

Future research in this field should concentrate on identifying patients most at risk of developing metastatic spread from these tumours. If this could be done and high-risk patients identified then a further study could re-evaluate the use of sentinel lymph node biopsy in these patients. The number of patients required for such a study would either require a long recruitment period or a multi-centre study.

It may be that if tumours can be identified as having a significant risk of metastatic spread that a staging neck dissection should be carried out instead of sentinel lymph node biopsy. This has the advantage of potentially being therapeutic for early lymphatic spread and prevents the need for secondary procedures in the event of a positive sentinel node biopsy. It would be interesting to compare the complication rate of such an approach with that of sentinel node biopsy as a perceived lower complication rate is one of the main reasons that sentinel node biopsy has gained favour in recent years.

Conclusions

Sentinel lymph node biopsy should not be routinely used in squamous cell carcinoma of the auricle. The technique is validated but the high complication rate and low detection of metastatic spread means that the cost outweighs the benefit. If patients at high risk of metastatic spread can be identified it could be used in place of an elective neck dissection and target specific nodes.

The location of the sentinel nodes and lymphatic drainage pathways of the auricle mean that a standard neck dissection is not an adequate operation for elective staging or therapeutic treatment in cases of metastatic spread and it must be extended to encompass specific nodal locations.

A Retrospective Analysis of
Prognostic Factors For Development
of Lymph Node Metastases From
Auricular Squamous Cell Carcinoma

Summary

Introduction

Squamous cell carcinoma is known to be associated with a high risk of metastatic spread which is often fatal. Identification of high-risk tumours would allow prophylactic treatment to the lymph node basins but there are not yet any agreed criteria for this.

Materials and Methods

A retrospective analysis of 229 cases of squamous cell carcinoma of the auricle and histological features of the tumours.

Results

Metastasis occurred in 10.5% of cases. 66.7% of patients who developed metastases died as a result of them despite multi-modality treatment. Tumours with a depth of invasion greater than 8mm or a depth of invasion between 2-8mm in conjunction with evidence of cartilage invasion, lymphovascular invasion or a non-cohesive invasive front are at high risk of metastasis.

Conclusions

Patients with high risk tumours should be considered for prophylactic therapy to or staging of the regional lymph nodes carried out.

Introduction

Squamous cell carcinoma of the auricle has long been recognised as a malignancy with specific problems.⁸ It is known to metastasise to the regional lymph nodes more frequently than comparable tumours at other sites.^{1-3, 16, 36, 38, 42, 45, 65-67} It is also recognised that patients commonly die as a result of this metastatic spread and auricular squamous cell carcinoma is a leading cause of death from non-melanoma skin cancer.¹⁰⁷ Despite the high mortality from metastasis there is no consensus of opinion as to when prophylactic treatment should be carried out in the clinically node negative patient¹⁰⁸ and previous publications that have suggested indications such as cartilage invasion, aggressive mode of invasion and tumour size have not been supported in large series.¹⁻³

In our practice we accept a 20 % risk of metastasis as sufficient indication to offer prophylactic treatment to the lymph node basins. This is based upon previous cost-benefit analyses carried out for malignancies of the upper aero-digestive tract which although not directly comparable to cutaneous malignancies do spread to similar nodal locations.^{72, 85} More recent publications have suggested that this threshold should be lowered to 15% because advances in peri-operative care have decreased the morbidity and mortality associated with neck dissections.⁷³ Thus in order to provide useful prognostic value any indicators for prophylactic treatment should carry a risk of at least 15% but preferably 20%.

The current treatment policy in our unit is to treat metastases only when they become clinically apparent, as we do not believe there is sufficient evidence to support the use of elective lymph node dissections in these patients.

The Setting of The Study

It is important to understand the setting in which this study took place as this is key to understanding and interpreting the results. Canniesburn Plastic Surgery Unit is a regional service which provides both secondary and tertiary referrals for plastic surgery for the West of Scotland. It serves a population of approximately 3.5 million or 60% of the Scottish population. The unit operates on a 'hub and spoke' configuration with one central unit at Glasgow Royal Infirmary where in-patient work is carried out. Outpatient clinics and operating sessions are held in multiple hospitals around the West of Scotland. Patient casenotes are maintained independently in each hospital.

The design of the service is such that patients with auricular squamous cell carcinoma could initially be seen and have all treatment and follow-up in the base unit or at one of the peripheral hospitals. They may also have been transferred to the base unit for treatment but had follow-up in a peripheral hospital. There is also a sub-speciality multidisciplinary head and neck clinic held in the base unit to which it would be expected that all patients who develop lymph node metastasis from a primary auricular squamous cell carcinoma are referred from peripheral clinics.

Patients for this study were identified from the pathology database at Glasgow Royal Infirmary and therefore represent only a subset of all patients referred to our service. The pathology department recorded all specimen reports in one computer database that ran from 1992 to 2006. This database is coded for diagnosis and anatomical site. Unfortunately skin is one anatomical site and no subdivision is made of this in the coding. This design makes it easy to find all squamous cell carcinomas from the skin but not specifically from the auricle.

Materials and Methods

Ethical approval was obtained from the local ethics committee. The study aimed to identify as many patients as possible with auricular squamous cell carcinoma. A computer script was written to interrogate the pathology database that identified all cutaneous squamous cell malignancies from inception of the database until August 2004. This cut-off date allowed for two year follow up during which time the majority of metastases would be expected to present. The script then searched the text of each report for a matching word from the following list; auditory, auricular, auricle, concha, conchal, ear, helical, helix, scapha, scaphoid, tragal, tragus and triangular. The script was design in such a way that helix would also pick up antihelix or anti-helix, etc. Since the information provided on the request form stating the location of the excision was included in the text of the report we could be reasonable certain that this method would identify most cases of auricular squamous cell carcinoma. It was inevitable that this list would also include some cases that were not of interest e.g. where a patient had undergone excision of a 'dog ear' or 'pre-auricular' lesion. Peri-auricular tumours were not included in this study. All cases were believed to have an origin on the auricle itself.

The database provided a list of patients whose case notes were then obtained and pathology reports examined to ensure that the patient had been correctly identified. At this stage any incorrectly identified patients were removed from the study. A spreadsheet was then set up to record pertinent details about the patient and primary tumour. Cases of Fergusson-Smith disease were excluded. A note was also made if the patient was on immunosuppressive medication or was known to suffer from a haematological malignancy.

Histopathological Analysis

It quickly became apparent while processing case notes that many of the original pathology reports were lacking in sufficient detail to allow meaningful analyses to be carried out. Details such as depth of invasion and invasion of nerves and vessels were often missing from reports. The original pathology of all primary specimens that had been processed at Glasgow Royal Infirmary pathology department was therefore reviewed by one pathologist (Keith Hunter – Lecturer in Pathology, University of Glasgow). No additional pathological processing or staining of any specimens was carried out. The aim was to fully report the original specimen as if it had originally been processed in accordance with the minimum dataset in the Royal College of Pathologist guidelines for skin SCC.¹⁰⁹ The specific details recorded were length and breadth of the tumour (excluding any adjacent dysplasia), overall tumour thickness, depth of invasion (from level of original epidermal surface), any histological subtype, degree of histological differentiation, presence of tumour invasion of nerves, vessels or cartilage. Cartilage invasion was sub-classified into tumour that had caused smooth erosion in the cartilage as if by tumour expansion and tumour that was clearly invading destructively into the cartilage. The tumour was also categorised as having a cohesive or non-cohesive invasive front based upon the criteria set out in Royal College of Pathologists Guidelines for Head and Neck Malignancy.¹¹⁰ Completeness of excision was also reported and categorised as completely excised, tumour extending to margin or margins felt to be close, where completeness of excision was in doubt usually less than 0.5mm.

Statistical Analysis

Statistical analysis was carried out using SPSS software.

Results

A total of 393 records were identified from the pathology database. 42 sets of case notes were not obtainable. 7 cases of Fergusson-Smith disease were excluded. 229 cases of squamous cell carcinoma in 221 patients had the primary site confirmed as being on the auricle. 9 of these cases were referred to our central unit with recurrent disease having had a previous auricular tumour excised elsewhere. Only 5 patients were female giving a male to female ratio of 23:1. Only one case was treated by primary radiotherapy after having a diagnostic biopsy. All remaining 228 cases were treated initially by surgical excision. One case received immediate post-operative radiotherapy because of involved resection margins. Age ranged from 47.9 to 93.5 years old with a median of 78.

The helix was by far the most common sub-site with 57% of cases occurring here. (Figure 28) The sub-site was not able to be accurately determined in 38 cases. It was not possible to correlate site of primary tumour with development of metastases or the location at which metastases appeared.

Forty patients died during follow up. (Table 14) Follow up information was available for a minimum two years in 66. A significant number of patients were followed up in peripheral hospitals.

Table 14 - Length of Follow Up

Length of Follow up	Number of patients
>24 months	66 (14 died during follow up)
12-24 months	40 (12 died during follow up)
6-12 months	28 (5 died during follow up)
< 6 months or followed up in peripheral unit	87 (9 died during follow up)
Total	221 (40 died during follow up)

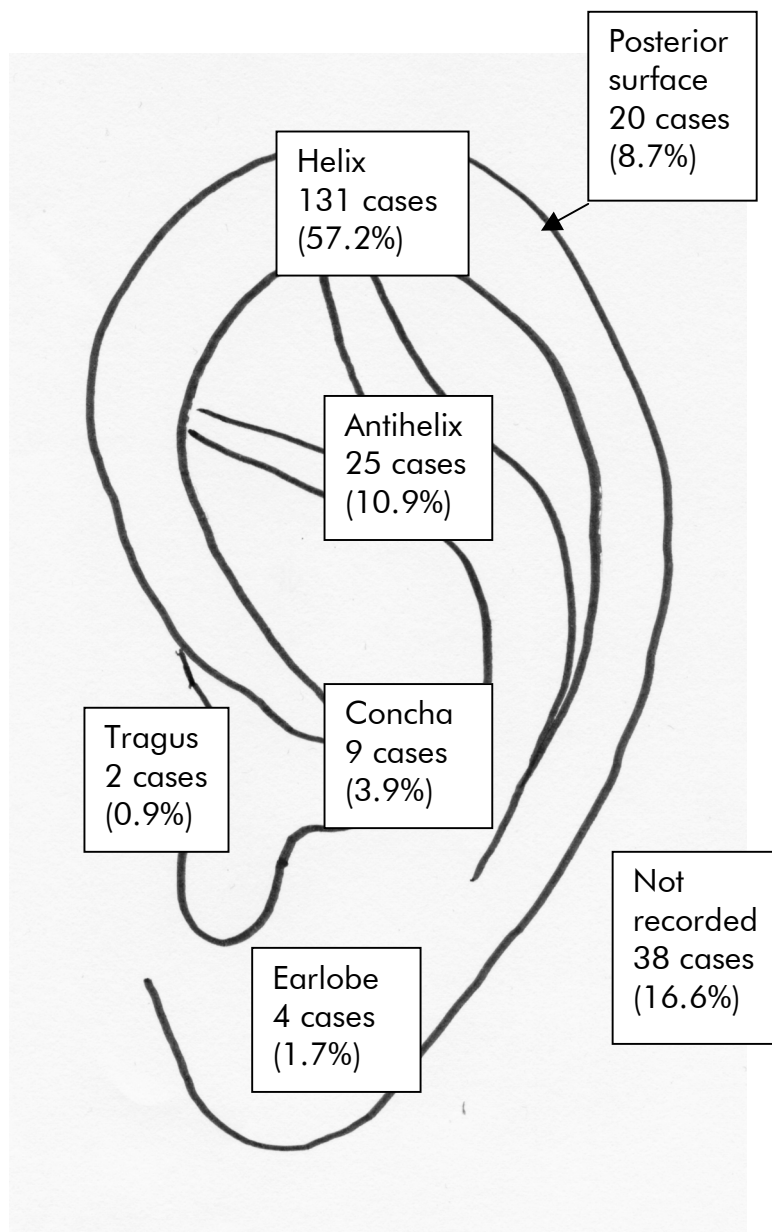


Figure 30 - Site of Primary Tumours

Metastasis

25 cases developed lymph node metastases. One of these had a confounding primary tumour on the temple, which was felt to be the likely source of metastases reducing the number of cases where the definite source was a primary auricular tumour. This gives a rate of 24 in 229 or 10.5%. Six of these cases were among the 9 referred from other units with recurrent disease. 18 of the 220 (7.9%) cases where the primary tumour was excised in our central unit developed metastases.

Of the 24 patients with lymph node metastases from an auricular primary, 8 had metastases at the time of presentation. Time to presentation of metastases for the remaining 16 ranged from 10 to 149 weeks with a median time of 36 weeks. 11 presented within 1 year of original surgery. Only one case developed metastases after two years from initial presentation.

The parotid gland was the commonest site of lymph node metastases followed by level II of the neck and the mastoid/post-auricular nodal group. (Figure 29) Disease initially presented at one of these sites prior to progression elsewhere in the neck. Disease was subsequently found in Levels I & III – V of the neck.

Four patients (1.7%) developed distant metastatic spread following the development of lymph node metastases. The sites where distant metastases occurred were the brain, lung, lumbar spine and skin of the shoulder. No patient developed distant metastases without first developing regional lymph node metastases. All patients with distant metastases died of disease.

Treatment of the lymph node metastases varied considerably. One patient was palliated only; two were treated with radiotherapy only. Ten were treated with surgery only and eleven received combination treatment with surgery and post-operative

radiotherapy. A total of 12 parotidectomies were carried out 8 in combination with a neck dissection. 9 neck dissections not including the parotid were carried out. It was not possible to correlate treatment modalities with survival. Two patients treated initially with only superficial parotidectomies subsequently required neck dissections.

Mortality

15 patients died as a direct result of Auricular Squamous Cell Carcinoma, 1 as a result of locally invasive disease, 9 as a result of failure of loco-regional control and 4 who developed distant metastases. An additional 2 patients died as a complication of their treatment. Therefore 17 of 229 (7.5%) died as a consequence of auricular squamous cell carcinoma. 16 of the 24 (66.7%) patients who developed lymph node metastases died as a result of their disease.

It is not possible to provide accurate figures of mortality from other causes due to the number and geographical spread of patients in the series who were followed up in peripheral hospitals.

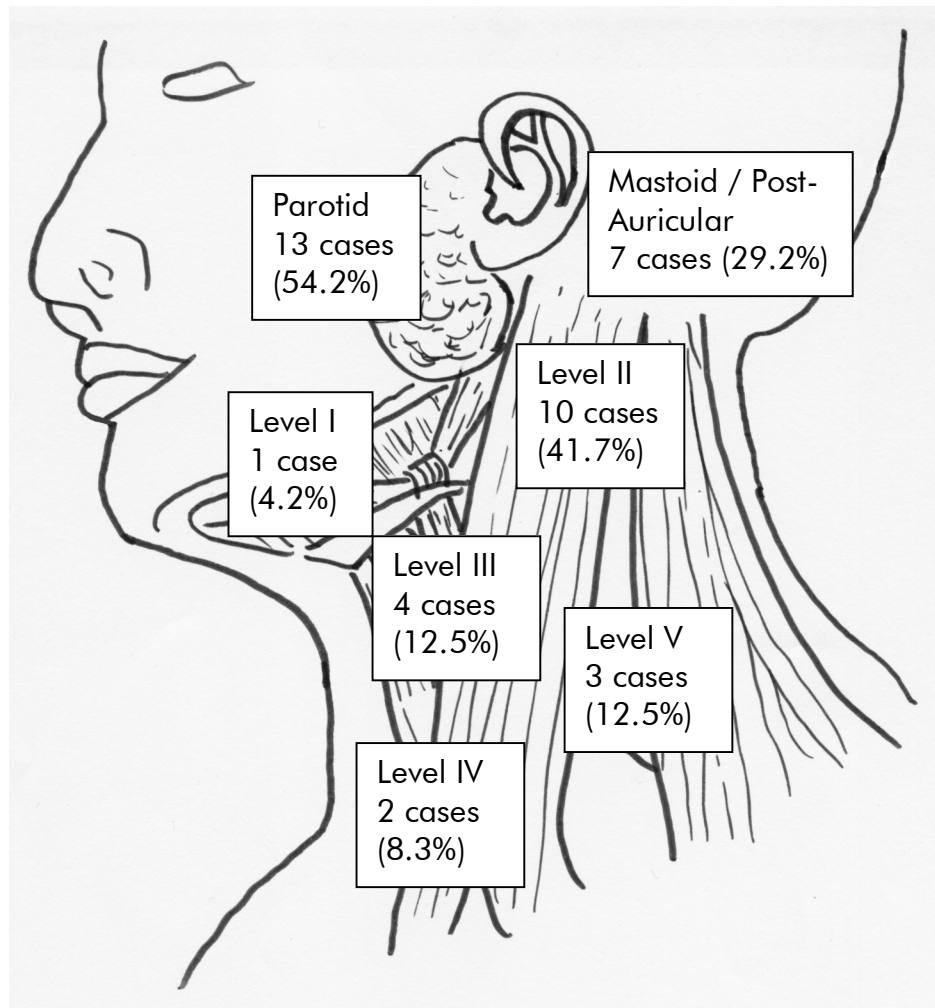


Figure 31 - Location of Metastases

The percentages show the rate of involvement of each nodal basin in the 24 cases with lymph node metastasis.

Tumour Dimensions

A total of 219 cases had the pathology of the primary specimen reviewed. This represented 228 cases treated by initial surgical resection minus 9 cases referred with recurrent disease after resection of primary tumour. 6 cases were excluded from this analysis because the tumour dimensions were unobtainable due to fragmentation or processing of the specimen. This left 213 cases of which 18 had metastasised. One patient with metastasis had a confounding primary tumour on his temple that was felt likely to be the source of metastasis and was removed from the analysis leaving a total of 212 cases (in 207 patients). The 17 remaining cases were metastases from primary untreated auricular squamous cell carcinoma.

Initial examination of the data showed that the tumours that had metastasised tended to be larger and invade deeper. It was also obvious that there were several large superficial tumours that did not metastasise and several small tumours that invaded deeply that did not metastasise. Two calculated figures were created in the data; the product of the length and the breadth; and the product of the length breadth and depth of invasion. These figures are proportional to the tumour area and volume respectively but not exact calculations of them.

Statistical analysis of these factors was carried out using a Mann-Whitney U test as the data was not normally distributed. (Figure 30 & Tables 15 - 17)

Tumour length, breadth, depth of invasion and volume were all predictive of development of metastases with p values of <0.001 . Tumour thickness was also predictive with a p value of 0.013. (Table 17)

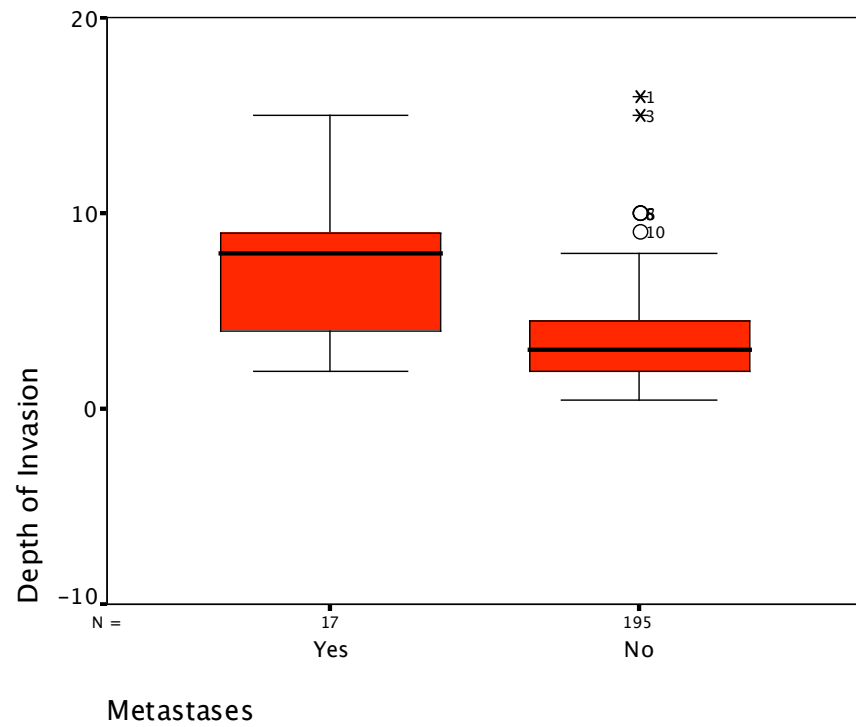


Figure 32 - Boxplot of Depth of Invasion In Tumours That Metastasised and That Did Not Metastasise

Table 15 - SPSS Output Table - Descriptive Statistics

	N	Mean	Std. Deviation	Minimum	Maximum	Percentiles		
						25th	50th (Median)	75th
LENGTH	212	16.8	10.8	1.00	70.0	9.00	15.0	23.8
BREADTH	212	12.5	7.64	1.00	40.0	7.00	10.0	17.0
DEPTH	212	3.75	2.55	.50	16.0	2.00	3.00	5.00
THICKNESS	212	5.05	3.35	.50	20.0	2.50	4.50	6.50
AREA	212	278	340	1.00	2400	60.0	144	400
VOLUME	212	1410	2850	1.00	21600	150	441	1290

Table 16 - SPSS Output Table - Ranks

	Metastases	Number	Mean Rank	Sum of Ranks
LENGTH	Yes	17	159.88	2718.00
	No	195	101.85	19860.00
	Total	212		
BREADTH	Yes	17	157.65	2680.00
	No	195	102.04	19898.00
	Total	212		
DEPTH	Yes	17	162.68	2765.50
	No	195	101.60	19812.50
	Total	212		
THICKNESS	Yes	17	141.53	2406.00
	No	195	103.45	20172.00
	Total	212		
AREA	Yes	17	161.76	2750.00
	No	195	101.68	19828.00
	Total	212		
VOLUME	Yes	17	167.00	2839.00
	No	195	101.23	19739.00
	Total	212		

Table 17 - SPSS Output Table - Test Statistics

	LENGTH	BREADTH	DEPTH	THICKNESS	AREA	VOLUME
Mann-Whitney U	750.000	788.000	702.500	1062.000	718.000	629.000
Wilcoxon W	19860.000	19898.000	19812.500	20172.000	19828.000	19739.000
Z	-3.748	-3.593	-3.959	-2.461	-3.874	-4.240
Asymp. Sig. (2-tailed)	.000	.000	.000	.014	.000	.000

Grouping Variable: Metastases

Tumour Volume

Tumour volume (length x breadth x depth of invasion) was the most predictive of metastases with the lowest Mann-Whitney U, Wilcoxon W and Z values (Table 16). There was a sharp cut off in the data at 2500mm³ with 12 of 31 tumours (38.7%) greater than this in volume having metastasised. (Table 18) The five remaining cases of metastases ranged in volume from 189 to 836mm³. All five of these tumours had adverse histological features that are discussed later.

Table 18 - Metastatic Rates Stratified by Tumour Volume

Tumour Volume (Length x breadth x depth)	Total Cases	Metastatic Cases (Rate)
>10,000mm ³	5	3 (60%)
5,000 – 10,000mm ³	9	5 (55.6%)
2,500 – 5,000mm ³	17	4 (23.5%)
1,000 – 2,500mm ³	38	0
500 – 1,000	28	1 (3.5%)
250 - 500	37	2 (5.4%)
150 - 250	26	2 (7.7%)
<150	52	0

Depth of invasion

Depth of invasion was the next most useful measure. A useful cut-off occurred at 7 mm. (Table 19) 10 of 21 (47.6%) tumours greater than 7mm thick had metastasised.

All 10 metastatic cases that would have been predicted by using the 7mm depth cut off were also predicted by the volume cut off at 2500mm³ but the volume method also included the two metastases that occurred in large tumours between 5 and 7mm deep.

Table 19 - Metastatic Rates Stratified by Depth of Invasion

Depth of Invasion	Total Cases	Metastatic cases (Rate)
10mm +	8	3 (37.5%)
9-9.9mm	4	3 (75%)
8-8.9mm	4	3 (75%)
7-7.9mm	5	1 (20%)
6-6.9mm	12	1 (8.3%)
5-5.9mm	23	1 (4.3%)
4-4.9mm	37	1 (2.7%)
3-3.9mm	32	1 (3.1%)
2-2.9mm	52	2 (3.8%)
<2mm	35	0

Adverse Histological Features

Cartilage Invasion

29 tumours showed definite destructive invasion of the auricular cartilage. 7 (24.1%) of these metastasised. A further 9 tumours showed superficial erosion of the cartilage only. None of these metastasised. 174 remaining tumours did not invade the cartilage 10 (5.7%) of these metastasised. (Figures 31 -38) For the purposes of analysis the tumours with superficial erosion only were grouped with tumours that did not invade cartilage. A Fisher's Exact test showed a positive correlation between Cartilage Destruction and development of metastases p-value = 0.003.

	Cartilage Destruction	No Destruction	Cartilage Destruction	Total
Metastases	7	10		17
No Metastases	22	173		195
Total	29	183		212

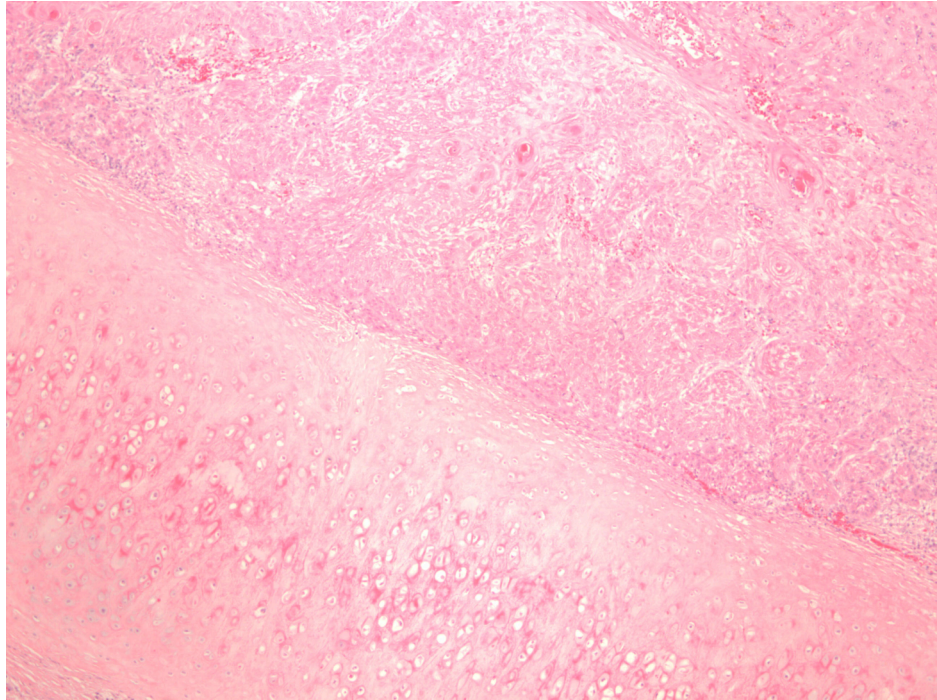


Figure 33 - Tumour abutting cartilage with compression of the peri-chondrium. H&E stain.

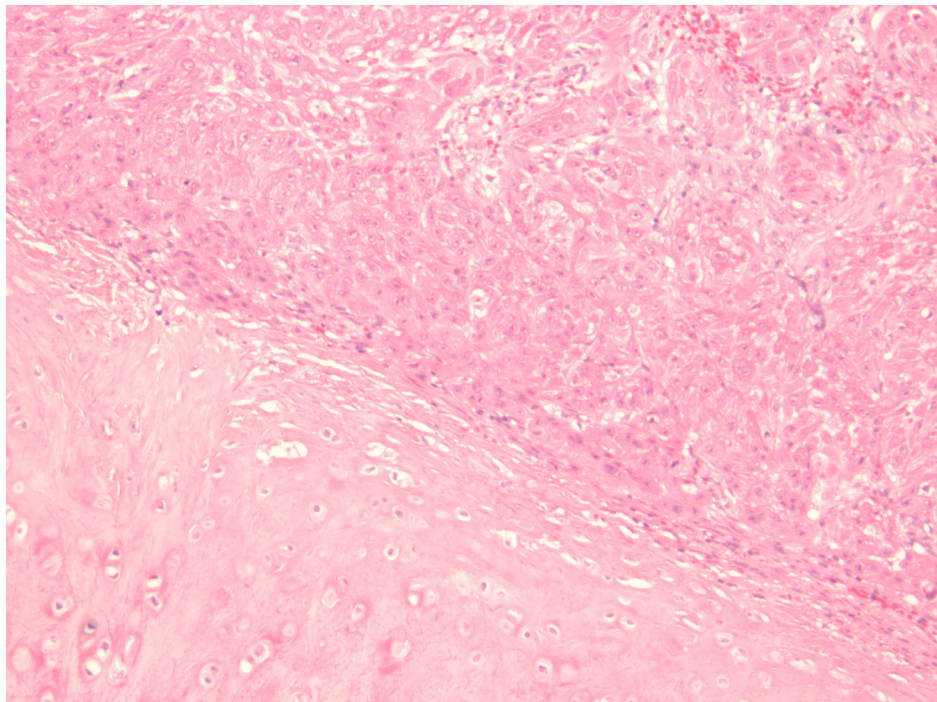


Figure 34 - Close-up of tumour abutting cartilage.

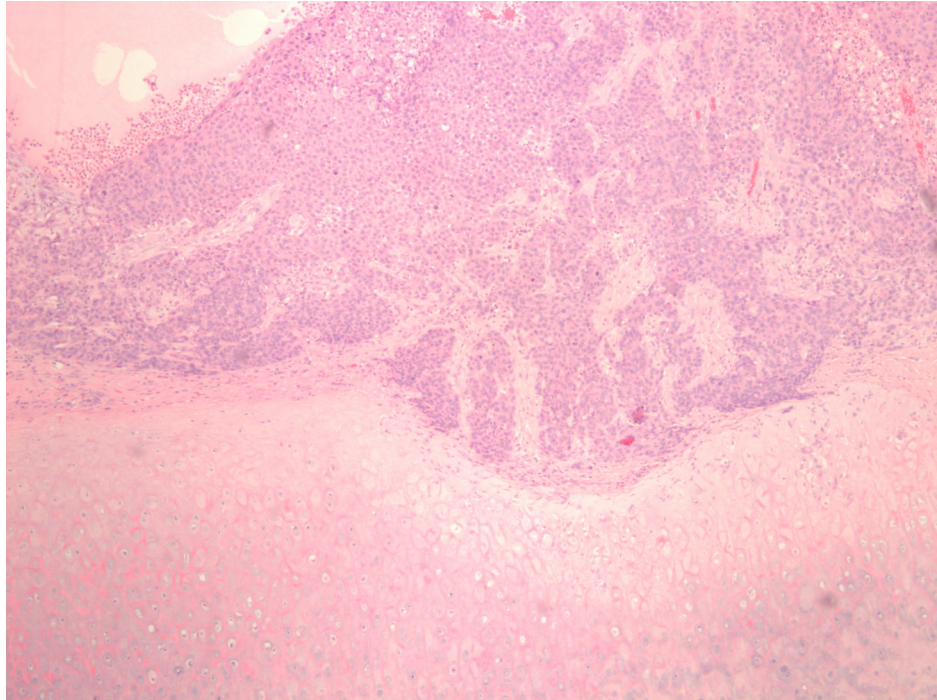


Figure 35 - Tumour showing smooth erosion of the cartilage. H&E stain.

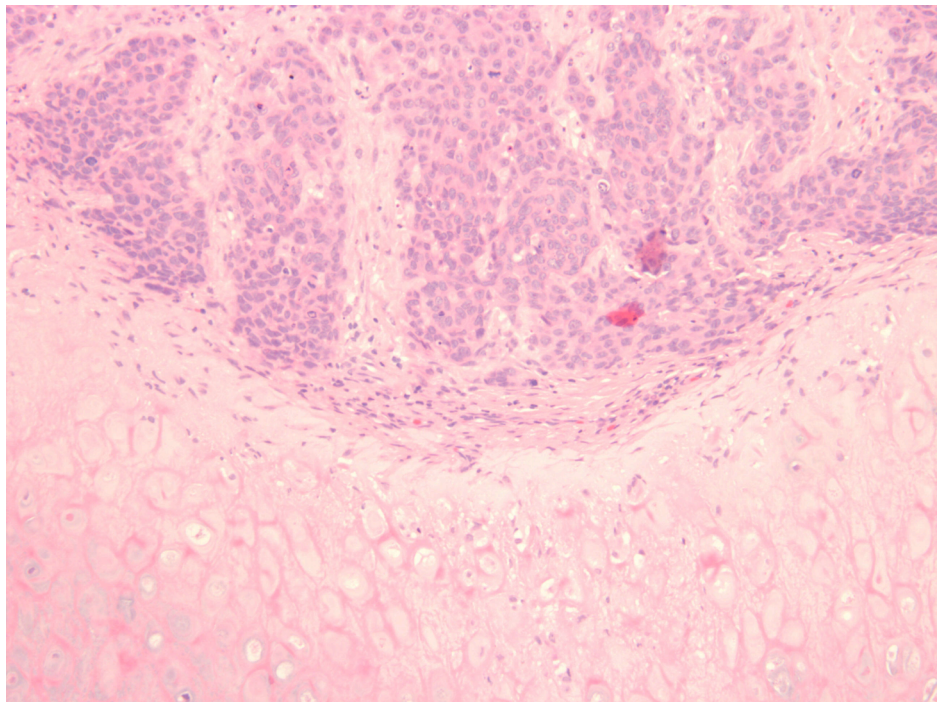


Figure 36 - Close-up of tumour erosion of cartilage.

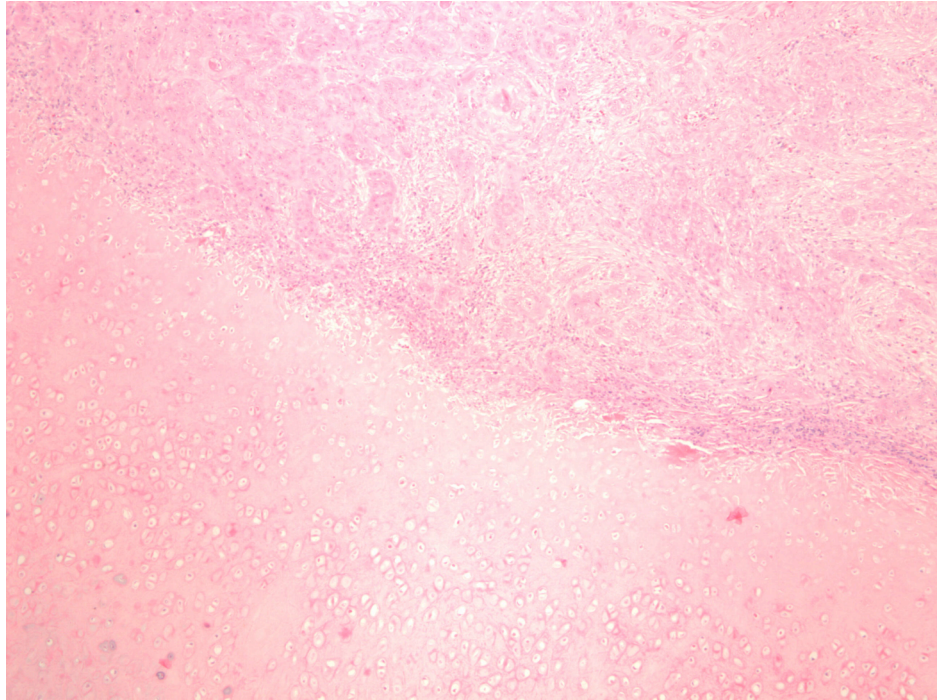


Figure 37 - Superficial erosion of the cartilage. H&E stain.

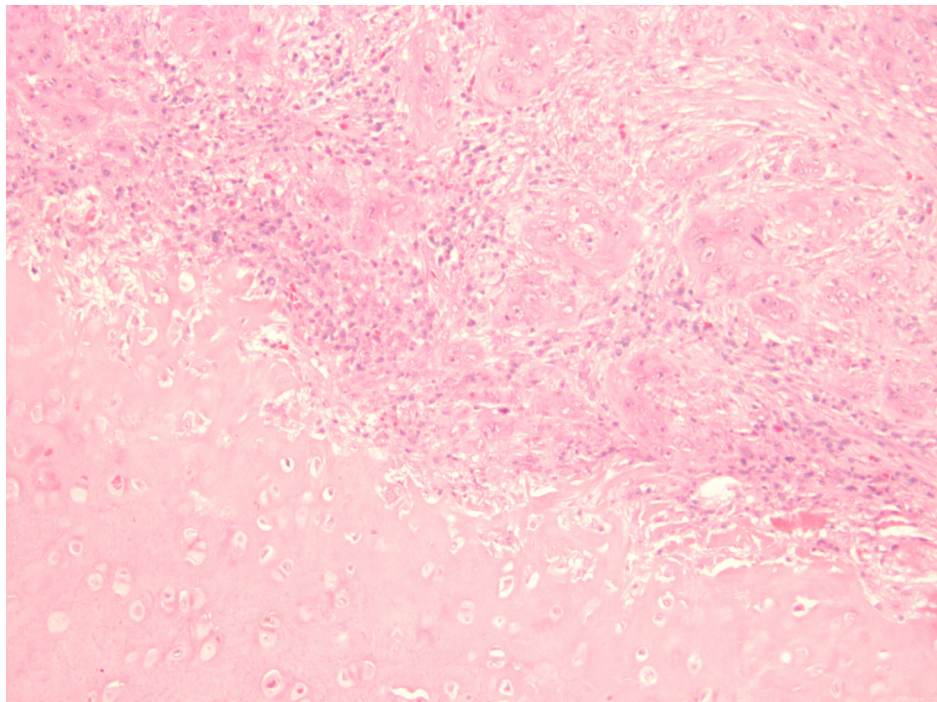


Figure 38 - Close-up of superficial cartilage erosion.

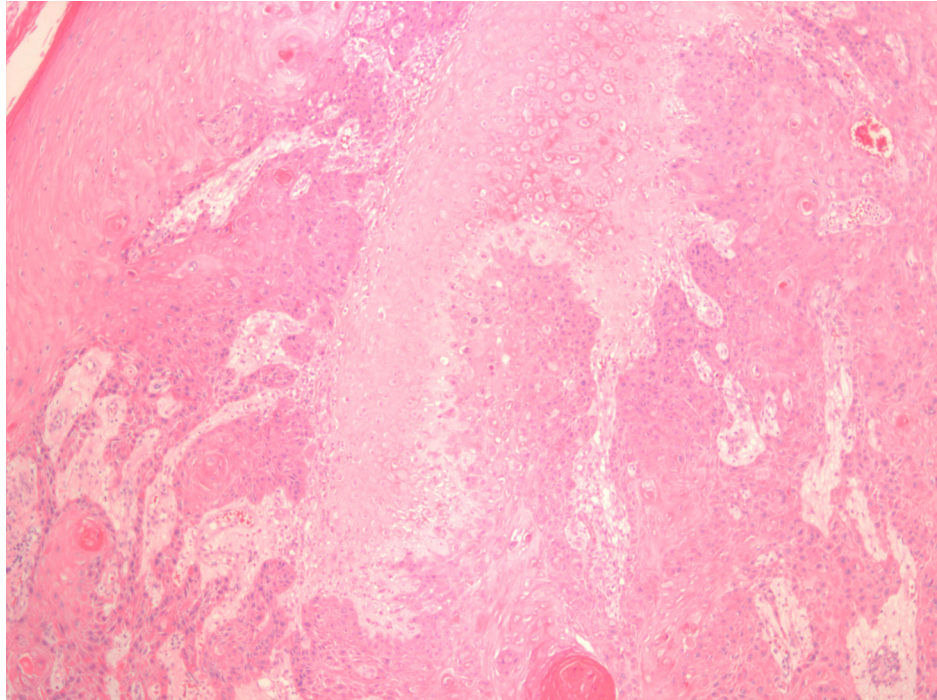


Figure 39 - Tumour showing destruction of cartilage with loss of perichondrium and destructive loss of bulk. H&E stain.

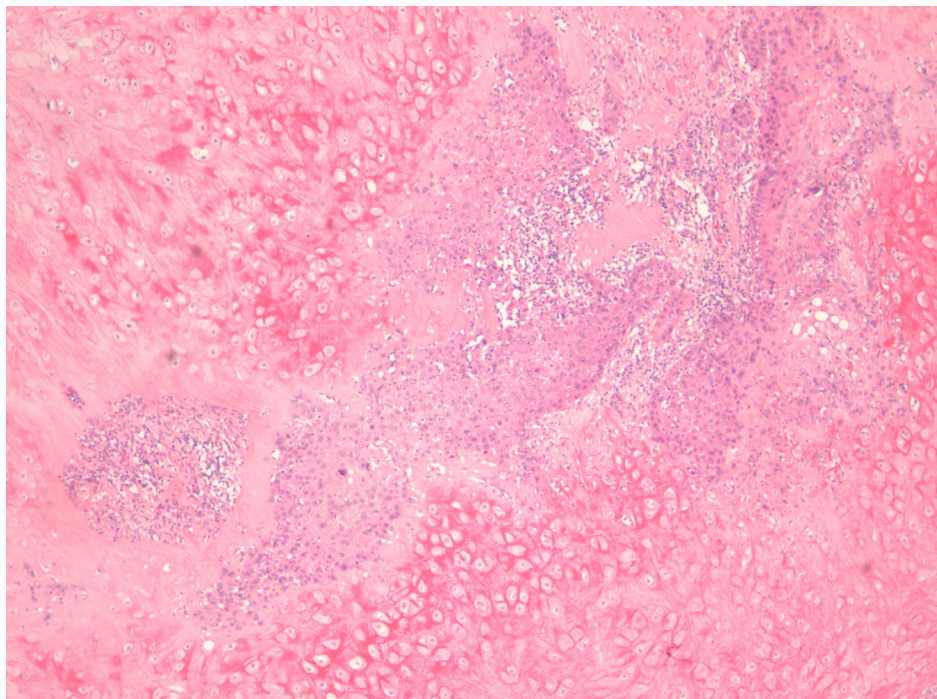
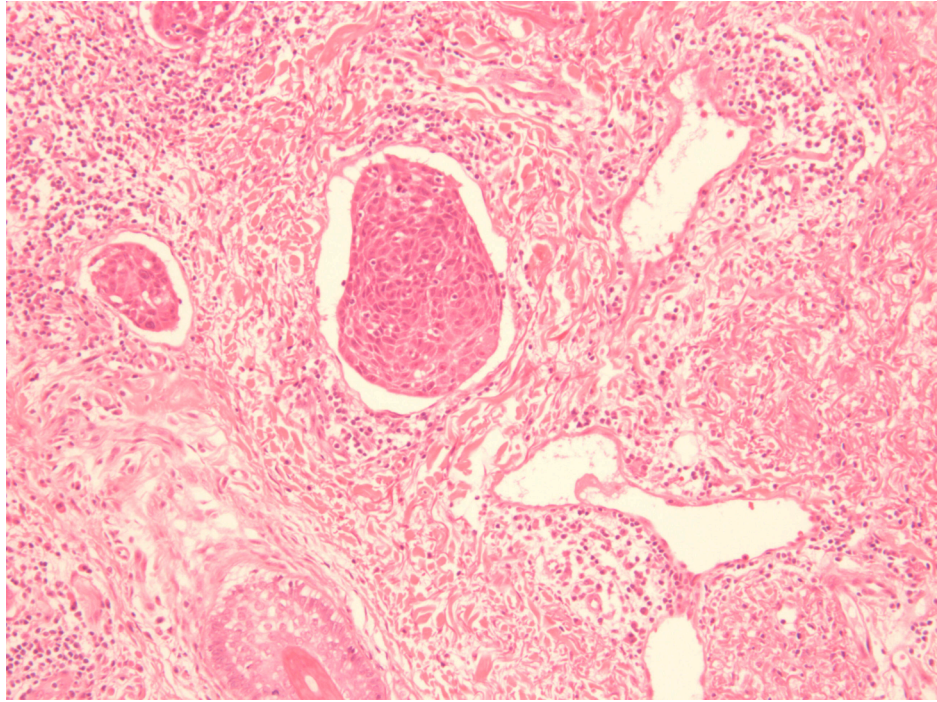


Figure 40 - Close-up of cartilage destruction.

Lymphovascular Invasion

Four cases showed evidence of lymphovascular invasion. Two of these metastasised and both patients died as a result of the disease with distant metastatic spread. There was only one other case in the series that developed distant metastases. Both of these tumours were small with volumes of 210 and 300mm³ and both invaded to a depth of 2mm. The vessels in both metastasising cases were felt to be to be lymphatic vessels (Figure 39) as only endothelial structures were seen and in contrast the vessels in the non-metastasising cases was felt to be vascular as there was a more obvious vascular structure (Figure 40). In three other cases lymphovascular invasion was thought to be possible but not definitely identified. None of these cases metastasised. A Fisher's Exact test showed a positive correlation between Lymphovascular Invasion and development of metastases with a p-value = 0.0331.

	Lymphatic Invasion	No Invasion	Lymphatic Invasion	Total
Metastases	2	15		17
No Metastases	2	193		195
Total	4	208		212



**Figure 41 - Tumour Invasion of a Lymphatic Vessel.
H&E stain**

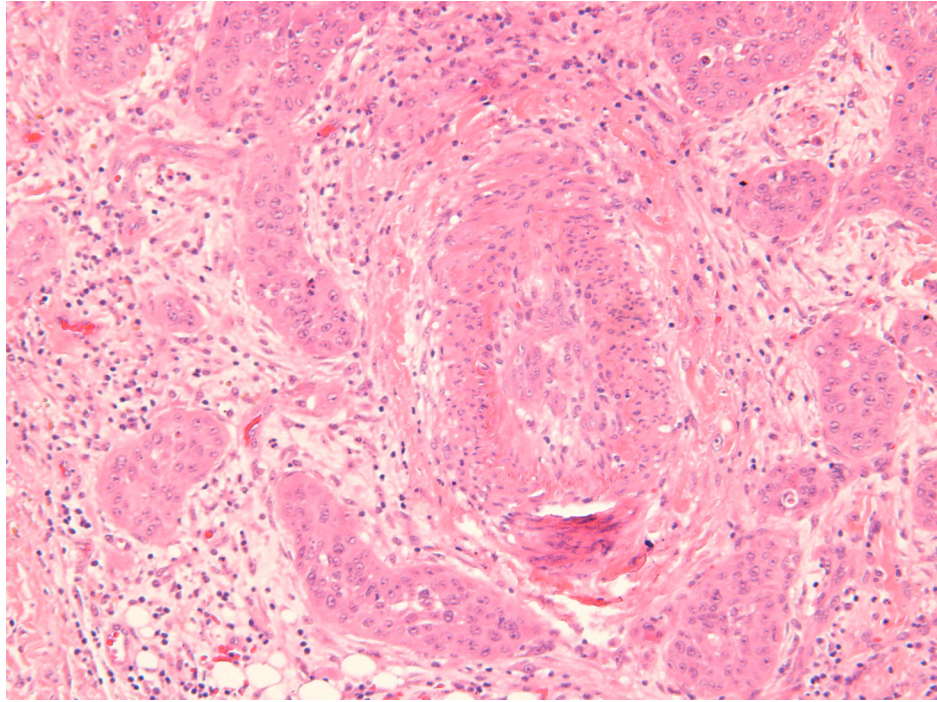


Figure 42 - Tumour invasion of a vascular channel. H&E stain.

Perineural Invasion

A total of 16 cases showed definite perineural invasion. (Figure 41) Three (18.8%) of these metastasised. A further four showed possible but not confirmed perineural invasion of which one metastasised. A Fisher's Exact test did not show a correlation between Perineural Invasion and development of metastases with a p-value = 0.124.

	Perineural Invasion	No Perineural Invasion	Total
Metastases	3	14	17
No Metastases	13	182	195
Total	16	196	212

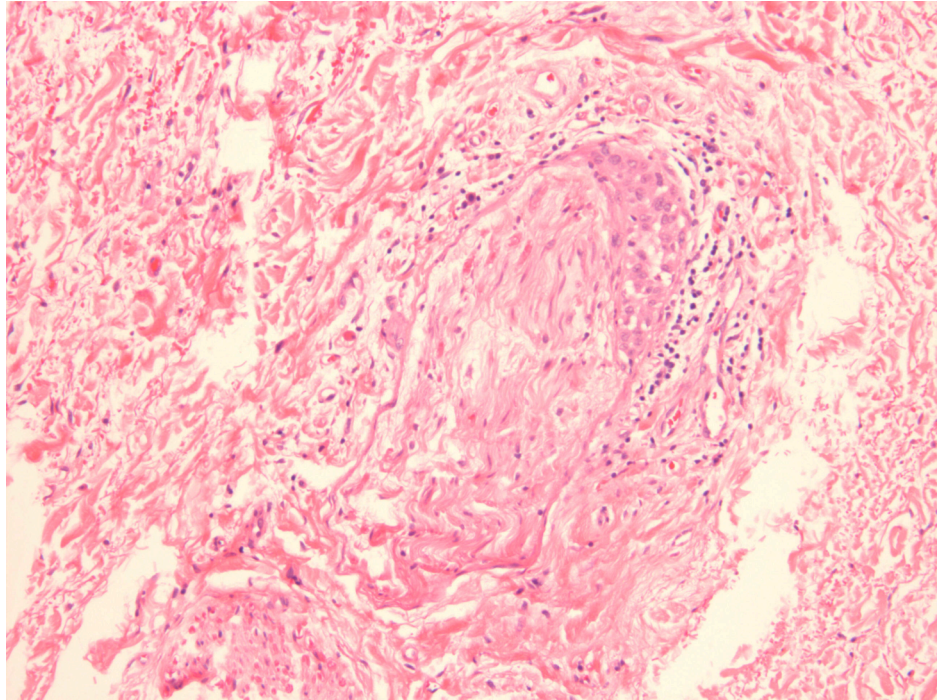


Figure 43 - Peri-neural invasion. H&E stain.

Non-cohesive Invasive Front

A total of 23 cases had a non-cohesive invasion front. (Figures 42 & 43) In 10 of these this was only present focally. (Figures 44 & 45) Six of the 23 (26.1%) metastasised including 2 of 10 (20%) where the non-cohesive front was only present focally. A Fisher's Exact test showed a positive correlation between a non-cohesive invasive front and development of metastases with p-value = 0.005.

	Non-cohesive front	Cohesive front	Total
Metastases	6	11	17
No Metastases	17	178	195
Total	23	189	212

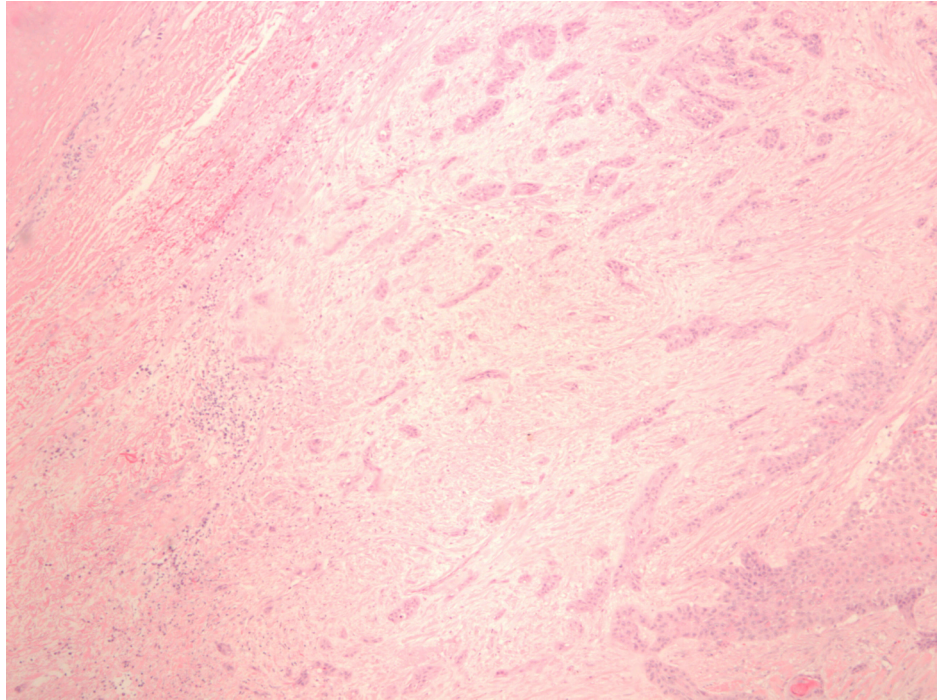


Figure 44 - A non-cohesive invasive front. H&E stain.

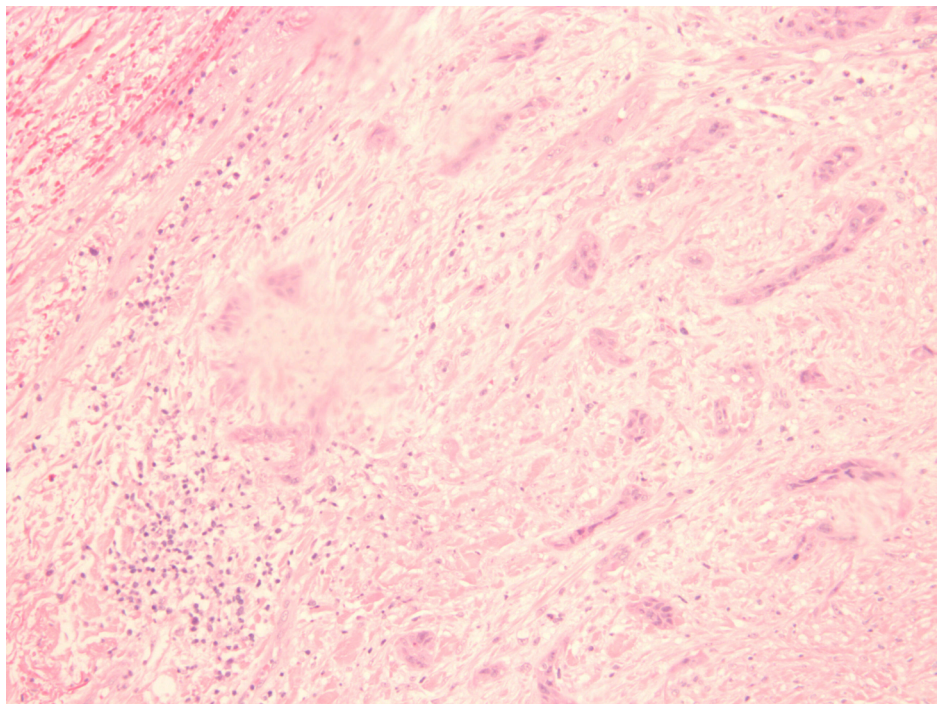


Figure 45 - Close-up of non-cohesive invasive front.

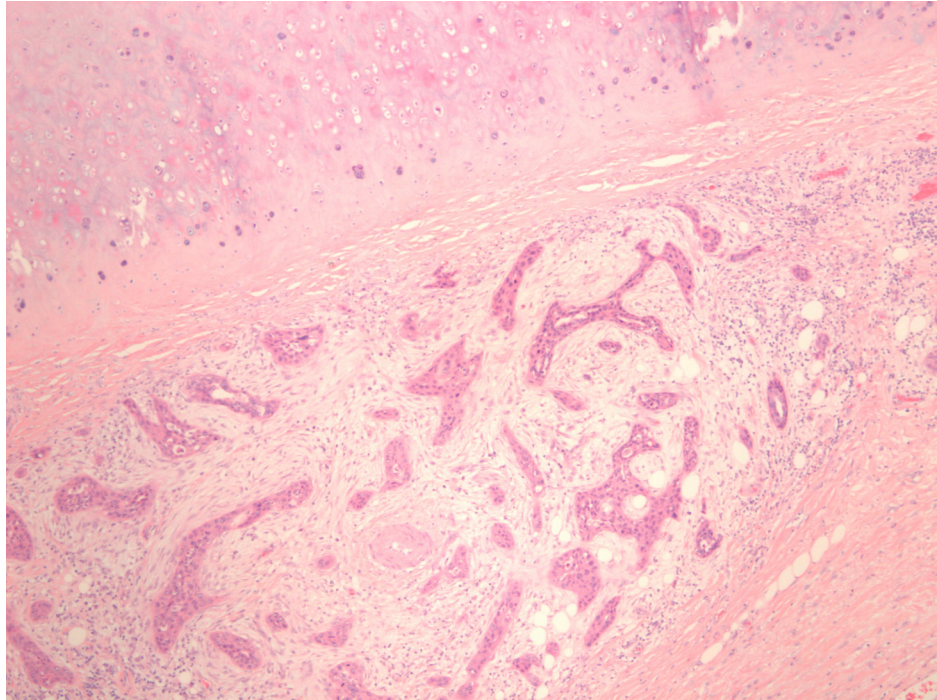


Figure 46 - A focally non-cohesive invasive front. H&E stain.

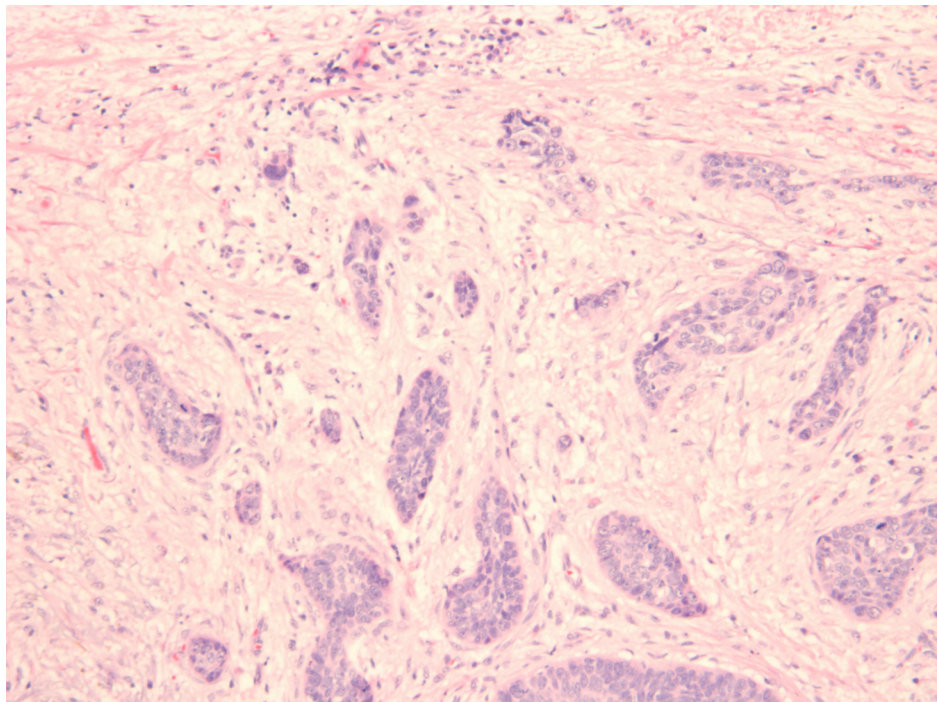


Figure 47 - Close-up of a focally non-cohesive invasive front.

Combining Tumour Volume and Depth With Adverse Histological Features

Only tumours greater than 2500mm³ in volume metastasised without evidence of cartilage invasion, lymphovascular invasion or a non-cohesive invasive front. No tumours less than 150mm³ metastasised despite adverse histological features. It was therefore possible to stratify tumours into three volume groups and subdivide them by adverse histological features. (Table 20)

Similarly it was possible to stratify tumours on the basis of depth of invasion. Tumours over 8mm deep metastasised without evidence of cartilage invasion, lymphatic invasion or a non-cohesive invasive front. No tumours below 2mm deep metastasised despite adverse histological features. (Table 21)

The combination of depth of invasion over 8mm and depth of invasion 2-8mm with adverse histological features included all 17 cases in this series that metastasised and another 32 cases that did not spread to the lymph nodes. This was better than the combination of volume and adverse histological features which also included all metastatic cases and another 38 non-metastatic cases. (Table 22)

The mortality was worse in the tumours that were included on the basis of intermediate volume or depth with adverse histological features. Mortality from these tumours was 87.5% - 100% compared with 41% - 44% for tumours that were included on the basis of volume or depth of invasion alone. (Table 23)

Table 20 - Combining Tumour Volume With Adverse Histological Parameters

	Total Number of Cases	Metastatic Cases (Rate)
Tumours > 2,500mm³	31	12 (38.7%)
With cartilage destruction, lymphovascular invasion or non-cohesive front	17	7 (41.2%)
Without cartilage destruction, lymphovascular invasion or non-cohesive front	14	5 (35.7%)
Tumours 150 – 2,500mm³	129	5 (3.9%)
With cartilage destruction, lymphovascular invasion or non-cohesive front	24	5 (20.8%)
Without cartilage destruction, lymphovascular invasion or non-cohesive front	105	0
Tumours <150mm³	52	0

Table 21 - Combining Tumour Depth of Invasion With Adverse Histological Parameters

	Total Number of Cases	Metastatic Cases (Rate)
Tumours > 8mm	16	9 (56.2%)
With cartilage destruction, lymphovascular invasion or non-cohesive front	10	4 (40%)
Without cartilage destruction, lymphovascular invasion or non-cohesive front	6	5 (83.3%)
Tumours 2 -8mm	161	8 (5.0%)
With cartilage destruction, lymphovascular invasion or non-cohesive front	33	8 (24.2%)
Without cartilage destruction, lymphovascular invasion or non-cohesive front	128	0
Tumours < 2mm	35	0

Table 22 - Comparison of Metastatic Rates in High Risk Tumours Identified by Volume and Depth of Invasion

	Total Number of Cases	Metastatic Cases (Rate)
Tumours > 2,500mm ³ & tumours 150 – 2,500mm ³ with cartilage destruction, lymphovascular invasion or non-cohesive invasive front	55	17 (30.9%)
Tumours > 8mm deep & tumours 2-8mm deep with cartilage destruction, lymphovascular invasion or non-cohesive invasive front	49	17 (34.7%)

Table 23 - Mortality from Metastases Stratified by High Risk Categories

	Number of Cases With Metastases	Number Died of Disease
Tumours > 2,500mm ³	12	5 (41.7%)
Tumours 150 – 2,500mm ³ with cartilage destruction, lymphovascular invasion or non-cohesive front	5	5 (100%)
Tumours > 8mm deep	9	4 (44.4%)
Tumours 2 - 8mm deep with cartilage destruction, lymphovascular invasion or non-cohesive front	8	7 (87.5%)

Table 24 - Dimensions and Pathological Features of Tumours That Metastasised

cartilage invasion	lymphovascular invasion	perineural invasion	non-cohesive invasive front	Length (mm)	Breadth (mm)	Depth of invasion (mm)	Thickness (mm)	Area (mm ²)	Volume (mm ³)
no	yes	no	no	15	10	2	2	150	300
no	yes	no	no	15	7	2	2	105	210
yes	no	no	no	13	10	2	2	130	260
yes	no	no	no	9	7	3	3	63	189
no	no	yes	yes	19	11	4	4	209	836
no	no	no	yes	25	25	5	5	625	3125
yes	no	no	yes	22	21	6	6	462	2772
yes	no	no	no	22	22	7	7	484	3388
yes	no	no	yes focally	40	20	8	8	800	6400
no	no	no	no	25	25	8	8	625	5000
no	no	yes	no	40	35	8	8	1400	11200
yes	no	no	no	30	25	9	9	750	6750
no	no	no	yes	60	40	9	9	2400	21600
yes	no	yes	yes focally	30	27	9	9	810	7290
no	no	no	no	34	24	10	10	816	8160
no	no	no	no	24	9	12	12	216	2592
no	no	possibly	no	42	25	15	15	1050	15750

Surgical Resection Margins & Local Recurrence

In 24 cases the resection margin was found to be involved and in a further 8 the margin was felt to be close and completeness of excision was in doubt. 11 cases underwent wider excision and only one of these (9.1%) recurred locally. Four of 13 (30.8%) cases that did not receive further surgery recurred locally. Two cases (15.4%) with dubious resection margins recurred at the level of the regional lymph nodes only.

Six of 180 (3.3%) tumours that were thought to be fully excised developed local recurrence. A total of 11 tumours recurred locally. Four of these occurred in patients with lymphatic metastases. One synchronously, one after treatment of lymph nodes and two predated the lymphatic disease.

Degree of Histological Differentiation

Of the 17 metastasising primary tumours of the auricle, 2 were regarded as well differentiated (one of which had features suggestive of a keratoacanthoma), 9 moderately differentiated, 3 moderate to poorly differentiated and 3 poorly differentiated. In total there were 39 well differentiated, 16 well to moderately differentiated, 116 moderately differentiated, 20 moderate to poorly differentiated and 21 poorly differentiated tumours. (Table 25)

Histological subtypes present were acantholytic, spindle cell, clear cell, basoloid, sebaceous and sarcomatoid. 2 of 3 tumours with spindle cell features metastasised. No other subtypes showed a relationship with metastases.

Table 25 - Metastatic Rates In Subgroups of Histological Differentiation

Degree of Differentiation	Total Number of Cases	Metastatic Cases
Well	39	2 (5.1%)
Well-moderate	16	0
Moderate	116	9 (7.8%)
Moderate-poor	20	3 (15%)
Poor	21	3 (14.3%)
Total	212	17 (8.0%)

Discussion

Summary of Findings

Auricular squamous cell carcinoma metastasises to the regional lymph nodes in 10.5% of cases. Spread to these nodes is associated with a high mortality (66.7%) despite the common use of combined modality treatment once metastases are detected. The commonest cause of mortality is failure of loco-regional control.

Tumours at high risk of development of metastasis can be identified on the basis of the depth of invasion or tumour volume in conjunction with evidence of cartilage destruction, lymphovascular invasion or a non-cohesive invasive front. Depth of invasion greater than 8mm or depth of invasion 2 - 8mm in conjunction with one of the adverse histological features includes all cases that have metastasised and a minimum number of non-metastasising cases. The overall risk of metastasis from tumours identified by this method is 34.7%.

Tumours between 2 – 8mm deep with adverse histological features carry a higher mortality than those over 8mm deep.

Lymph node metastases appear initially in the parotid gland, level II of the neck or the mastoid/post-auricular nodal group. After appearing at one of these sites further spread can occur to levels I and III-V. Regional lymph node metastases always predate the development of distant metastases which occurs in 1.7% of all cases and is uniformly fatal.

Evidence of lymphovascular invasion on primary histopathology is strongly correlated with the subsequent development of distant metastases.

Strengths and Weaknesses of This Study

This study has provided a sufficient sample size to allow meaningful statistical analysis of tumour pathological features to be carried out. It has allowed the development of strategic thresholds where treatment of the regional lymph nodes should be considered.

The metastatic rate in this series is probably not a true representation of the rate in the general population as the unit is a tertiary referral service and is likely to have accumulated the most severe cases.

It has not been possible to identify which treatments of lymph node metastases are of benefit nor is it possible to determine from this work if prophylactic treatment of the lymph nodes confers a survival advantage.

Some of the histological features have occurred in small numbers and specific features may prove of significance if a sufficiently larger sample size was available.

Comparison With The Work of Others

Previous studies on these tumours have been unable to correlate depth of tumour invasion with the development of metastasis.^{2, 3} This may be due to the fact that they looked at Clark's levels rather than a measured depth. If that system had been used in this study then there would have been no relationship shown. A measured depth of invasion has been shown to be a particularly useful prognostic indicator in melanoma.^{70, 111}

Cartilage invasion in auricular squamous cell carcinoma is a disputed prognostic indicator.^{1-3, 112} Only Afzelius has suggested that this is sufficiently predictive of metastasis to warrant therapy to the lymph nodes and these finding were not upheld by larger series by Byers and Freedlander.¹⁻³ In this study cartilage invasion has been subdivided into two groups on the basis of whether or not the tumour appears to be actively destroying cartilage or simply causing erosion as the tumour expands. It can be understood why many tumours on the auricle cause some erosion of the cartilage given its proximity to the skin but we believe that active destruction of the cartilage by the tumour is a distinct feature suggestive of a more aggressive malignancy.

Afzelius also promoted mode of tumour invasion as a useful prognostic indicator with a four level scoring system but other authors have not found this useful.¹⁻³ There is guidance on the classification of cohesive and non-cohesive invasive tumour fronts¹¹⁰ and in this series in intermediate depth tumours it has identified tumour with an increased metastatic potential.

Meaning Of This Study

Given the high mortality associated with the development and subsequent treatment of lymph node metastases prophylactic treatment to the lymph node basins or staging of them should be done at the time of initial presentation in order to try to contain the disease.

All tumours with a depth of invasion of over 8mm should have therapy directed at the neck as should all tumours with a depth of invasion between 2-8mm with evidence of cartilage destruction, lymphovascular invasion or a non-cohesive invasive front on histological examination of the primary tumour. The latter group are at higher risk of death due to disease.

Treatment of the neck could consist of initial staging of the lymph nodes followed by therapy if metastases are detected or prophylactic therapy could be carried out with a complete neck dissection or radiotherapy. Since the site of first presentation of lymph node metastases is the parotid gland, level II of the neck or the mastoid/post-auricular nodal group, a staging neck dissection would need to include these nodal groups at a minimum. A therapeutic neck dissection would need to include these regions plus levels I and III-V of the neck. Sentinel lymph node biopsy could also be considered as an alternative staging method although this is not a proven technique for this malignancy.

Radiotherapy as an alternative treatment for primary auricular tumours does not allow full examination of the histological tumour features. In such cases a diagnostic biopsy should be done to confirm the depth of the lesion. Treatment of the neck should be done on the same criteria as listed above but also tumours between 2-8mm deep where the product of the tumour length x

breadth x depth of invasion exceeds 2,500mm³ should also have treatment extended to the neck.

Where there is doubt about the excision margins of the primary tumour a wider excision should be performed as this reduces to rate of local recurrence from 30.8% to 9.1%. Doubtful primary excision margins have also been associated with subsequent development of lymph node metastases.

Unanswered Questions and Future Research

The primary aim of future research should be to prophylactically treat the regional lymph node basins in new cases of auricular squamous cell malignancy meeting the defined high-risk criteria. It should determine if the criteria are valid, establish if prophylactic treatment confers a survival advantage and establish the 'cost' in terms of morbidity and mortality of prophylactic treatment to the lymph nodes. Given the high mortality associated with the development of lymph node metastases prophylactic treatment is likely to be of benefit.

Conclusions

Lymph node metastases occur in around 10% of cases of auricular squamous cell carcinoma. They are usually fatal. Tumours with a depth of invasion > 8mm have a 56.2% risk of metastatic spread. Tumours with a depth of invasion between 2 – 8mm and with evidence of cartilage destruction, lymphovascular invasion or a non-cohesive invasive front have a 24.2% risk of metastatic spread. Prophylactic therapy to or staging of the regional lymph nodes should be carried out for patients with tumours in these high-risk groups. Evidence of lymphatic invasion is predictive of subsequent development of distant metastasis.

What Neck Dissection For Malignant Tumours Of The Auricle?

Summary

Malignant tumours of the auricle are known to have a higher metastatic rate than other skin tumour sites and surgical removal of the lymph nodes is often required. There is not yet any clearly defined or accepted elective or therapeutic neck dissection. This study analyses the evidence from several clinical series together with static and dynamic lymphatic studies to provide a structured approach to surgical resection of cervical lymphatics involved in metastases from auricular tumours.

Introduction

Malignant tumours of the skin of the auricle are known metastasise more commonly than comparable tumours at other sites.^{2, 3, 16, 30, 32, 55, 60, 77-79} Squamous cell carcinoma at this site is thought to have a metastatic rate of around 11% and melanoma a rate of around 39.2%.⁶⁰ In our own unit the metastatic rate for SCC is 10.5% and two thirds of our patients died as a result of the metastatic spread. Surgical removal of metastases is a commonly required procedure and failure of loco-regional control in auricular squamous cell carcinoma remains the leading cause of death from these lesions which can invade the bone of the base of the skull and adjacent nerves and blood vessels. If a neck dissection is to be of benefit, it is vital to ensure that all potential areas of metastatic disease are removed.

The therapeutic procedure to remove involved lymph nodes for a head and neck cancer is a comprehensive neck dissection. When applied to malignant tumours of the auricle this would be extended to include the parotid gland in addition to the other cervical lymph node basins.^{1, 2} This procedure carries significant morbidity and, although acceptable for involved nodes, it is no longer the favoured procedure for staging in the N0 neck.

Selective lymph node dissections have been successful in staging cancers of the head and neck that are commonly associated with metastatic spread such as oral, pharyngeal, laryngeal, nasal and thyroid tumours. These cancers have all been studied in detail and there is significant information available, which allows specific nodes to be excised in selected nodal basins. Auricular tumours, however, have not been studied in such great detail and there is no established pattern of selective nodal dissection for them.

The high incidence of metastases has prompted several authors to promote elective lymph node dissections for squamous cell carcinoma of the auricle on the basis of tumour size, depth and mode of invasion but there is no clear consensus of opinion.^{1, 3} Elective lymphadenectomy is a potentially useful procedure as it allows staging of the disease and removes small, sub-clinical deposits of metastatic disease before they involve important structures at the base of skull or spread further to cause distant metastases.^{1, 3} However elective lymphadenectomy for melanoma has not shown to have any benefit for patients and has therefore fallen out of favour in recent years.⁶⁰

Materials and Methods

Information on the lymphatic drainage of the auricle and metastatic spread of auricular tumours was analysed from four different sources. A systematic review was carried out which found three papers that were able to give detailed information on the location of spread of squamous cell carcinoma of the auricle. An internal retrospective study of squamous cell carcinoma of the auricle treated in the Canniesburn Plastic Surgery Unit over a twelve year period produced 24 cases with spread to the regional lymph nodes available for study. A cadaveric static lymphatic study in five auricles was examined and dynamic lymphatic drainage information was available from a study of sentinel lymph node biopsy in a further 28 cases of auricular squamous cell carcinoma.

Results

The systematic review and the retrospective study has shown that the commonest locations for metastatic spread are the parotid gland, upper cervical chains (level II) and the mastoid and post-auricular nodal groups.^{2, 3, 38} (Table 26) These studies also demonstrated that disease had to be present at one of these sites before it occurred elsewhere in the neck with further spread in the neck to levels I and III-V. The same pattern of spread also holds true for melanoma which supports a model of stepwise metastatic progression from first echelon nodes.^{55, 60}

Disease is commonly present in both the parotid gland and cervical chains or post auricular nodes. Tumours originating on the posterior auricle may metastasise anteriorly to the parotid gland while tumours originating on the anterior auricle may spread posteriorly.

The static and dynamic lymphatic mapping studies have shown that first echelon lymph nodes draining the auricle can lie in the superficial parotid gland, superficial cervical chains overlying the parotid, in the post-auricular and mastoid region and upper deep cervical chain. The lymph nodes in the post-auricular and mastoid group represent specific surgical problems as the lymphatics and nodes lie adjacent to the periosteum of the mastoid bone on its anterior and lateral surfaces. The lymphatics traverse the insertion of sternomastoid and lymph nodes may be located deep to the sternomastoid fascia on the lateral surface of the mastoid. Lymph nodes are also found on the anterior surface of the mastoid. The lymphatics that traverse the insertion of sternomastoid communicate with the deep cervical chain on the deep surface of the muscle immediately inferior to the mastoid bone.

Table 26 – Lymph node basins involved with metastatic spread

Lead Author	Total Number of Cases With Metastases	Post-Auricular / Mastoid	Parotid	Upper Cervical	Neck Other Levels
Byers	79	12 (15.2%)	35 (44.3%)	28 (35.4%)	4 (5.0%)
Freedlander	29		14 (48.3%)	15 (51.7%)	
Leferink	4	1 (25%)	2 (50%)	1 (25%)	
Clark	24	7 (29.2%)	13 (54.2%)	10 (41.7%)	4 (16.7%)

Discussion

Since lymphatic metastases commonly affect both the parotid gland and cervical chains it cannot be assumed that the presence of disease in one of these basins is an indication that the other is not affected and both must be resected. This study suggests that a therapeutic neck dissection for tumours arising on the auricle should include the parotid gland superficial, inferior and posterior to the facial nerve. The parotid should be removed with the fascia and overlying superficial lymph nodes (Figure 46) and the greater auricular nerve will be sacrificed. The post-auricular and mastoid nodal groups should be removed by clearing the mastoid bone on the anterior, lateral and inferior surfaces to the sub-periosteal plane, as this will ensure complete removal of all lymphatic tissue. In cases where there is gross evidence of disease in this area it may be desirable to remove the mastoid process to ensure tumour free resection margins. The only way to ensure the complete clearing of the peri-mastoid lymph nodes is to remove the upper portion of sternocleidomastoid muscle with overlying superficial cervical nodes. Level IIa and IIb (Figure 47) need to be cleared in their entirety from the stylohyoid anteriorly to the posterior border of sternocleidomastoid and from the skull base to the level of the hyoid bone inferiorly. The accessory nerve and internal jugular vein should be preserved unless they are felt to be compromised by disease. Levels I and III to V of the neck can then be cleared in a standard fashion.¹¹³

Skin incisions for neck dissections are a matter of debate.¹¹³ It is our preference for this operation to use an incision which starts anterior to the helical root runs down in front of the tragus to the earlobe and then into the post-auricular sulcus. The incision is

carried on to the superior margin of the mastoid process before curving posteriorly and then inferiorly to run along and in line with the centre of the sternocleidomastoid muscle before running anteriorly at least 2cm below the mandible in a skin crease and onto the midpoint of the mandible. A flap is raised in the subcutaneous plane anteriorly above the superficial cervical nodes. The upper posterior portion of this flap is often trimmed before it is re-inset at the end of the procedure. This area of skin that is trimmed is the skin that would have been overlying the lateral surface of the mastoid bone and its removal gives further reassurance that no post-auricular lymph nodes have been missed in the subcutaneous tissue. A second incision is made running inferiorly from this incision to the clavicle to form a tri-radiate incision. This allows access to the lower levels of the neck. No matter what type of incision is used it should take into consideration the fact that there will be exposed mastoid bone at the end of the procedure and good quality coverage of this is required to prevent wound breakdown and subsequent exposed bone especially if post-operative radiotherapy is being considered.

Based on our results an elective or staging neck dissection for auricular tumours should include the superficial parotid gland, level II, mastoid and post-auricular nodes as described above. The indications for such a procedure remain unclear but it may be that on an individual case it could be justified. Such a procedure would need to be undertaken in the knowledge that therapy would need to be directed to levels I and III to V of the neck if metastatic disease was found on histopathological processing.

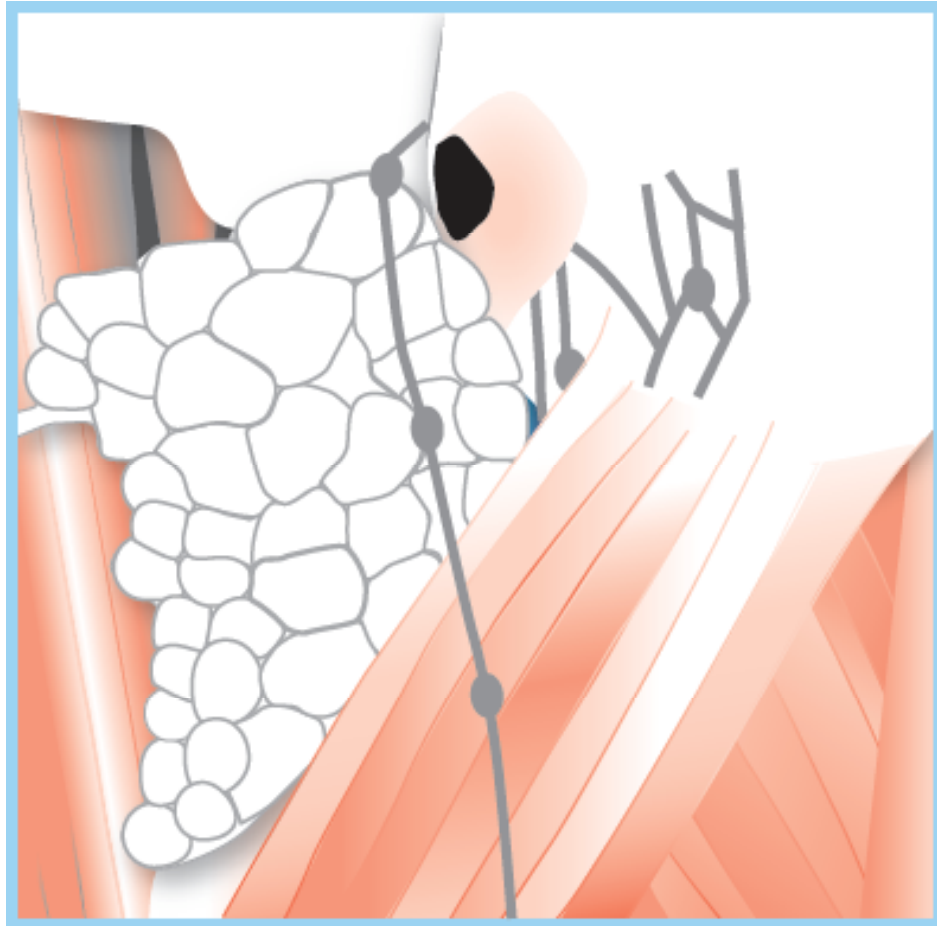


Figure 48 - Illustration of superficial level lymph nodes

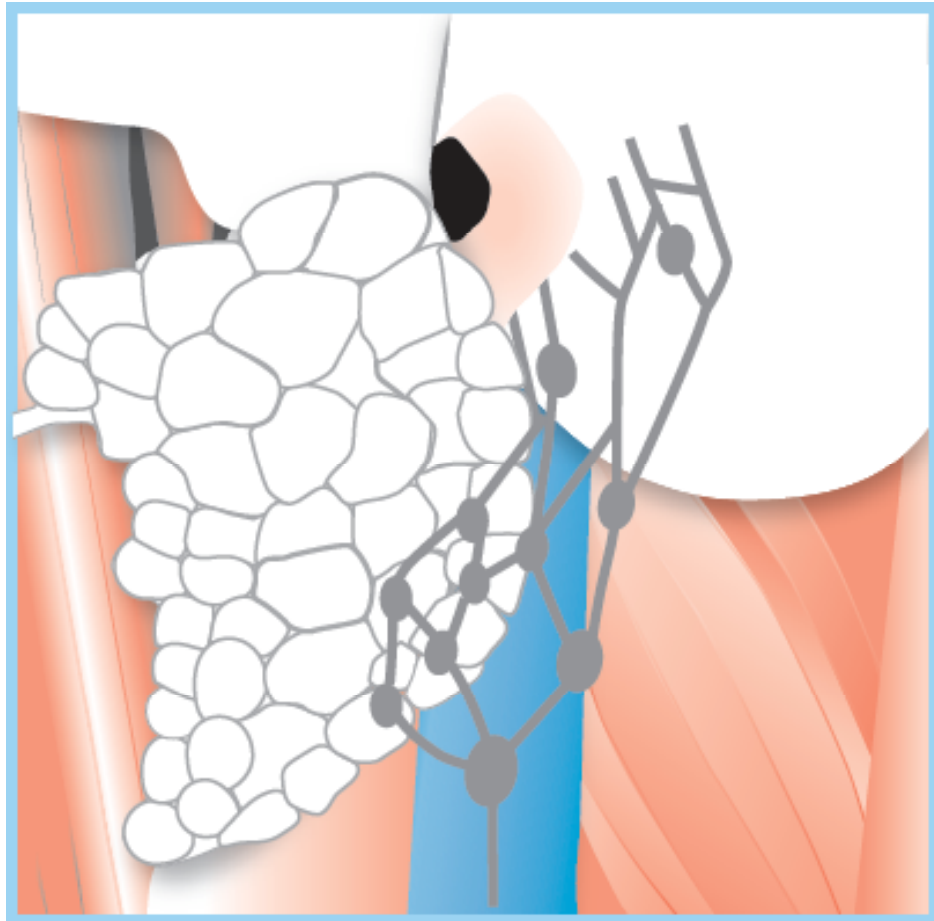


Figure 49 - Illustration of deep level lymph nodes

General Discussion

Summary of Findings

In this thesis we have examined possible strategies that could be used at the time of initial diagnosis of auricular squamous cell carcinoma to direct therapy to the regional lymph nodes basins. The two approaches taken have been to identify tumours most at risk of metastatic spread and to detect early metastatic spread. It is clear from the sentinel node study that although the technique may be possible, it should not be routinely used in clinical practice. The reasons for this are due to the difficulty in identifying patients most at risk of metastatic spread which makes the complication rate unacceptably high. This is in contrast to other head and neck cancers where the technique is used to lower the morbidity of a neck dissection which is generally applied to tumours with a greater than 20% metastatic risk.

In the systematic review several authors have recognised the problem caused by lymphatic metastasis and tried to devise criteria to direct prophylactic therapy to the neck. Unfortunately there has been no clear consensus of opinion as to when this is warranted. There is no published work where elective lymph node dissections have been carried out to validate their use. Our own retrospective analysis has added to this information and the use of a measured depth of invasion rather than Clark's levels seems to provide a more useful method by which high-risk tumours can be identified. In combination with the adverse histological features of lymphatic invasion, cartilage destruction and a non-cohesive invasive front it is possible to identify tumours with a sufficiently high metastatic rate to warrant intervention to the regional lymph nodes.

The anatomical study and the sentinel node study have shown that first echelon nodes can lie in the post-auricular/mastoid, parotid or level II neck nodes. There are several anastamotic pathways around the post-auricular/ mastoid nodes that could permit embolic tumour cells to bypass them. These areas must be treated fully if any prophylactic therapy to the neck is to be of benefit. It is known from the retrospective study and the systematic review that once disease is present at one of the first echelon locations it can spread to levels I and III to V of the neck.

It should also be emphasised that where completeness of primary excision is doubtful, further excision should be carried out.

Strengths and Weaknesses

There is as yet no evidence that early intervention to the lymph nodes is of advantage to patients. On the other hand the evidence available from the review shows that prognosis is poorer once more than one node is involved and there is evidence of extra-capsular spread. Also the majority of patients who die of this disease do so as a result of failure of loco-regional control. Early and directed intervention as suggested in the neck dissection study should be able to provide better loco-regional control and improve outcome. However given the age group of patients involved such intervention is likely to carry a significant morbidity.

The place of sentinel lymph node biopsy in treatment of this malignancy is not yet clear. It has not yet demonstrated early detection of lymphatic metastasis and therefore its use cannot be justified outside a clinical trial.

Meaning Of The Thesis

There is now evidence to identify auricular squamous cell carcinomas with a sufficiently high metastatic potential to warrant intervention to the regional lymph nodes, specifically the nodal basins at highest risk of metastatic spread. Patients with these lesions should in future be considered for a lymphadenectomy procedure and/or radiotherapy. The current policy of treatment only when metastasis becomes clinically apparent carries a high mortality.

A staging or elective neck dissection for auricular squamous cell carcinoma should include the superficial parotid gland, post-auricular/mastoid and level II nodes. Treatment should be extended to levels I and III to V of the neck once there is evidence of lymph node metastasis.

Unanswered Questions And Future Research

Future research should concentrate on establishing the cost and benefits associated with early intervention to the regional lymph nodes in high risk cases of auricular squamous cell carcinoma. Ideally a randomised trial would divide patients between a prophylactic neck dissection and a wait and see policy. However given the number of patients likely to be enrolled in such a study it will be difficult to obtain a sufficient number to allow a meaningful analysis to be carried out. Our unit has only seen 50 cases over a 12 year period that would be regarded as high risk and many of these would likely be excluded from a trial because of co-morbidities.

An observational study where all patients sufficiently well to undergo neck dissection were offered this if they had a high risk tumour would be able to provide information on the costs and benefits of this procedure and establish if the metastatic rate in this group of tumours is as high as expected.

It is now clear how extensive an elective or staging neck dissection should be. It is easy to argue the case for only resecting the superficial parotid gland, post-auricular/mastoid and level II nodes as this keeps the surgical procedure to a minimum and will provide staging information. However if metastases were detected in this specimen further treatment would need to be given to the rest of the neck either in the form of a completion neck dissection or radiotherapy. Such further treatment would be expected to be necessary in about 1 in 3 cases.

Sentinel lymph node biopsy remains a potentially useful tool in auricular squamous cell carcinoma although it now needs to be evaluated as a staging tool in comparison to a staging neck dissection. Such evaluation could be carried out in conjunction

with an observational study of elective neck dissections. Sentinel lymph nodes could be identified and harvested at the start of an elective lymph node dissection and then undergo histological examination. If the procedure does correctly identify nodes with early metastatic spread then its use could be justified in place of elective lymph node dissection.

Conclusions

Auricular squamous cell carcinoma is known to metastasise to the regional lymph nodes in about 11% of cases. The development of metastasis is an adverse prognostic indicator and the majority of patients in whom they develop will subsequently die usually as a result of failure of loco-regional control. The current treatment policy for these tumours is to wait for clinical evidence of metastatic spread before treatment of the lymph node basins because there has been insufficient evidence to define which tumours are of sufficiently high risk to warrant elective intervention. Recent work has shown that tumours at high-risk of metastatic spread have a depth of invasion over 8mm or a depth of invasion between 2 – 8mm and evidence of cartilage destruction, lymphovascular invasion or a non-cohesive invasive front. The metastatic rate in these groups of tumours is 34.7%.

Treatment of established metastases in the regional lymph node basins is difficult because of the proximity to vital structures around the base of skull. This makes surgical clearance by means of a neck dissection to clear all draining lymph nodes difficult to achieve. However surgical clearance of sub-clinical deposits by means of an elective lymph node dissection of specific lymph node groups should be more easily carried out as the locations of the lymph nodes where disease will first present and spread from is now documented. It is not yet established if elective lymph node dissections for auricular squamous cell carcinoma carries a survival benefit to the patient and a cost benefit analysis is required to support its routine clinical use.

Sentinel lymph node biopsy can provide accurate information on specific lymph nodes draining primary auricular neoplasms but needs further evaluation before it can be accepted into routine

clinical practice. It would be possible to evaluate this at the same time as performing elective neck dissections.

Appendix 1 – Ethical Considerations

Both the retrospective review and the sentinel node trial required approval from an ethics committee. This was obtained from the local ethics committee at Glasgow Royal Infirmary. The sentinel node trial required Patient Information Sheet, GP Information Sheets and consent forms. These are appended on the following pages.

PATIENT INFORMATION FORM

Version 2 29th July 2004

TITLE OF PROJECT:

Early detection of spread of skin cancer of the ear

INVITATION

You are being invited to take part in a research study. Before you decide it is important for you to understand why the research is being done and what it will involve. Please take time to read the following information carefully and discuss it with others if you wish. Ask us if there is anything that is not clear or if you would like more information. Take time to decide whether or not you wish to take part. Thank you for reading this.

What is the purpose of the study?

We are always looking for ways to improve the treatment and investigations we offer people. Currently, we are performing a new technique to determine whether we can make improvements to the care of patients with cancer of their ear. We would like to invite you to enter a clinical trial of a procedure called 'Sentinel lymph node biopsy'. Lymph nodes are small glands in your neck and near your ear which drain fluid away from the tissues of your body. They are commonly referred to as lymph glands. The 'sentinel lymph node' is the first place to which we believe the cancer would spread before it spreads anywhere else. Sentinel lymph node biopsy is a procedure that has been performed for patients since the early 1990's. In patients with other types of cancer it has been shown to be a very good way of telling whether spread of the cancer has occurred or not.

Cancer of the ear usually spreads through the lymphatic channels (small tubes which drain fluid from all the areas of the body) to lymph nodes. In patients with cancer of the ear, we always examine the lymph nodes in the neck for signs of spread. This relies on the cancer having spread and then grown large enough to be felt under the skin. The earliest spread is not always detectable by this method since the lymph nodes may not be big enough to feel. If we can detect enlarged nodes we perform an operation called a 'neck dissection'. This is an operation to remove a large proportion of the lymph nodes in the neck and is considered major surgery. Since major surgery carries some risks, we are reluctant to perform neck dissections on patients whom we think will not benefit from it.

In your case, we will not be performing a 'neck dissection' at the moment, because we cannot yet detect any cancer in your neck. Our normal practice for patients, such as you, is to observe and examine you every few months. By doing this, if spread has occurred we will be able to detect this early, and give you the treatment you need quickly.

Why have I been chosen?

You have been chosen because you have cancer of the ear and we cannot detect any spread by examining your neck.

Do I have to take part?

It is up to you to decide whether or not to take part. If you do decide to take part you will be given this information sheet to keep and be asked to sign a consent form. If you decide to take part you are still free to withdraw at any time and without giving a reason. A decision to withdraw at any time, or a decision not to take part, will not affect the standard of care you receive.

What will happen to me if I take part?

Sentinel node biopsy is a technique that involves two injections and a small operation under general anaesthesia. This may be combined with the surgery to your ear or may mean an additional operation. One of these injections will be given while you are awake and one while you are under anaesthesia. The first injection is given into the ear and the substance injected is a radioactive. This then travels to the 'sentinel node' through the lymphatic channels. The injection will be given in the Nuclear Medicine Department at the Royal Infirmary. The dose of radioactivity used is very low. After the injection, a picture will be of your neck with a special camera which will show us where the sentinel lymph node is. The scan takes about half an hour to one hour in total.

The second injection is given while you are asleep under anaesthesia. The injection given is a blue dye and colours the lymph channels and lymph nodes blue. When we perform a sentinel node biopsy, we can find blue stained lymph nodes and trace radioactivity with a special probe to find the sentinel node. The sentinel nodes are sent to be looked at under a microscope. If any tumour is seen in the sentinel node, we will offer you further treatment to the lymph nodes in the neck.

What do I have to do?

If there is any possibility that you are pregnant you should inform us immediately and not take part in this study.

What are the alternatives for diagnosis or treatment?

Standard treatment would be to examine your neck every few months in the clinic for signs of spread and offer surgery if spread was detected.

What are the side effects of taking part?

Sentinel node biopsy has been performed for several years, and there are very few side effects associated with it. These are:

1. Blue staining of the urine. Since we inject blue dye into the tissues around your tumour, and since the dye is removed by your kidneys, for about one day after your operation, your urine will be stained blue.

2. Hypersensitivity. There have been a few reports of people being allergic to the blue dye we inject. This is more common in people who suffer allergies to other things. If you tend to suffer from allergies, please let us know.

What are the possible disadvantages and risks of taking part?

Your surgery and anaesthetic will be slightly longer than would normally be the case and you will have a small additional scar. For some patients it will mean an additional operation.

What are the possible benefits of taking part?

If you agree to take part in this research project it may be of little or no benefit to you but the results may help other patients in the future. Should you not wish to take part in the project or at any time should you wish to stop taking part, you may do so. The care which you receive and your proposed treatment protocol will not be affected in any way. If you agree to take part in this research project, your own general practitioner will be told and will be given detailed information about the care you will receive. Should you require more detailed information concerning this project, please do not hesitate to ask and we will provide a more detailed description of the project. By agreeing to enter our trial, you are agreeing to have a sentinel node biopsy performed. The rest of your treatment and investigations will be performed according to our usual schedule. Sentinel node biopsy is an investigation which will be performed in addition to your usual treatment. Since it is an unproven theory in squamous cell cancer of the ear, we cannot guarantee that it will be successful in identifying cancer spread.

What if new information becomes available?

Sometimes during the course of a research project, new information becomes available about the treatment/drug that is being studied. If this happens, your research doctor will tell you about it and discuss with you whether you want to continue in the study. If you decide to withdraw your research doctor will make arrangements for your care to continue. If you decide to continue in the study you will be asked to sign an updated consent form.

What happens when the research study stops?

You will continue to be seen in clinic as we normal would for someone with squamous cell carcinoma of the ear and offer you any further treatment that may be required.

What if something goes wrong?

If you are harmed by taking part in this research project, there are no special compensation arrangements. If you are harmed due to someone's negligence, then you may have grounds for a legal action but you may have to pay for it. Regardless of this, if you wish to complain, or have any concerns about any aspect of the way you have been approached or treated during the course of this study, the normal

National Health Service complaints mechanisms may be available to you.

Will my taking part in this study be kept confidential?

All information which is collected about you during the course of the research will be kept strictly confidential. Any information about you which leaves the hospital/surgery will have your name and address removed so that you cannot be recognised from it. Your GP will be informed of your participation in this trial.

What will happen to the results of the research study?

The results of the study will be published in scientific journals. You will not be identified in any way in the published material.

Who is organising and funding the research?

The research is being organised by Canniesburn Plastic Surgery Unit and funded by charities and endowments.

FURTHER INFORMATION

If you or your family have any questions or require any further information, please contact: Mr R. Clark (Head and Neck Research Fellow) or Mr D.S. Soutar (Consultant Plastic Surgeon) at Canniesburn Plastic Surgery Unit, Glasgow Royal Infirmary, Glasgow G4 0SF. Tel 0141 211 5776

GP INFORMATION FORM (Version 1, 30th June 2004)

Your patient has agreed to be included in this study.

TITLE OF PROJECT:

Sentinel node biopsy to upstage clinically false negative necks in patients with squamous cell cancer of the ear

INTRODUCTION

Squamous cell cancer spreads by the lymphatic channels to lymph nodes located in the neck. In patients with squamous cell cancer of the ear, we always examine the neck for signs of metastases and if spread has occurred we would usually perform a neck dissection. Since a neck dissection is major surgery and carries some risks, we usually do not perform neck dissections on patients whom we think will not benefit from it. At the moment, however, the only way of determining whether spread to the neck has occurred or not is to perform a neck dissection and sometimes we perform a neck dissection for the sole reason to find out if spread has occurred or not.

In your patient's case, we will not be performing a neck dissection at the moment, because we feel that spread to the lymph nodes has not occurred. Our normal practice for such patients, is to observe and examine you every few months.

We are always looking for ways to improve the treatment and investigations we offer people. Currently, we are performing a new technique to determine whether we can make improvements to the care of patients with squamous cell cancer called "Sentinel node biopsy".

Sentinel node biopsy is a procedure that has been performed for patients since the early 1990's. In patients with malignant melanoma (a type of skin cancer) and breast cancer, sentinel node biopsy has been shown to be a very good way of telling whether spread of the cancer has occurred or not. We would like to see if sentinel node biopsy can tell us whether spread has occurred in patients with squamous cell cancer of the ear.

Sentinel node biopsy is a technique that involves two injections both around the tumour to help localise the target lymph node. The first injection is a radioactive protein given in the Nuclear Medicine Department at the Royal Infirmary. The dose of radioactivity used is very low in comparison to the doses we use for other investigations in Nuclear Medicine (0.4mSv). The sentinel nodes are sent to the pathology laboratory and examined for the presence of tumour cells. If any tumour is seen in the sentinel node, we will offer further treatment to the lymph nodes in the neck.

The rest of your patient's treatment and investigations will be performed according to our usual schedule. Sentinel node biopsy is an investigation which will be performed in addition to the usual treatment. Since it is an unproven theory in squamous cell cancer, we cannot guarantee that it will be successful in identifying metastatic spread.

SIDE EFFECTS

Sentinel node biopsy has been performed for several years, and there are very few side effects associated with it. These are:

1. Blue staining of the urine for a few days. Patent blue is renally excreted
2. Hypersensitivity. There have been a few reports of people being allergic to the blue dye we inject. This is more common in people who suffer allergies to other things. If you tend to suffer from allergies, please let us know.

BENEFITS TO YOUR PATIENT

Agreeing to take part in this research project it may be of little or no benefit to your patient but the results may help other patients in the future. Should they not wish to take part in the project or at any time wish to stop taking part, they may do so. The care which they receive and proposed treatment protocol will not be affected in any way.

FURTHER INFORMATION

If you have any questions or require any further information, please contact:

Mr R. Clark (Head and Neck Research Fellow) or Mr D.S. Soutar (Consultant Plastic Surgeon) at Canniesburn Plastic Surgery Unit.

Study Number: 04/S0705/24

Patient Identification Number for this trial:

CONSENT FORM

Title of Project: Early detection of spread of skin cancer of the ear

Name of Researcher:

Please initial box

1. I confirm that I have read and understand the information sheet dated 30 June 2004 (version 1) for the above study and have had the opportunity to ask questions. ☐
2. I understand that my participation is voluntary and that I am free to withdraw at any time, without giving any reason, without my medical care or legal rights being affected. ☐
3. I understand that sections of any of my medical notes may be looked at by responsible individuals from regulatory authorities where it is relevant to my taking part in research. I give permission for these individuals to have access to my records. ☐
4. I agree to take part in the above study. ☐

Name of Patient

Date

Signature

Name of Person taking consent
(if different from researcher)

Date

Signature

Researcher

Date

Signature

1 for patient; 1 for researcher; 1 to be kept with hospital notes

Form Version 2 29th July 2004

Appendix 2 – Neck Dissection Terminology

There has been a great deal of variation in the approach to neck dissection over the past few decades and as a result the terminology has changed. The description of specific nodal groups or chains has given way to the concept of levels as an increasing amount of evidence became available to establish patterns of nodal spread of disease. These levels are well defined anatomical regions and the development of this terminology has allowed consistent reporting and management of disease. The American Head and Neck Society and the American Academy of Otolaryngology – Head and Neck Surgery published the last update of the classification of neck dissection in 2002.¹¹⁴ These revisions are widely accepted and are used throughout this thesis.

Lymph Node Groups Found Within the 6 Levels and the 6 Sublevels

Submental (sublevel IA)

Lymph nodes within the triangular boundary of the anterior belly of the digastric muscles and the hyoid bone. These nodes are at greatest risk for harboring metastases from cancers arising from the floor of mouth, anterior oral tongue, anterior mandibular alveolar ridge, and lower lip.

Submandibular (sublevel IB)

Lymph nodes within the boundaries of the anterior belly of the digastric muscle, the stylohyoid muscle, and the body of the mandible. It includes the pregladular and the postgladular nodes and the prevascular and postvascular nodes. The

submandibular gland is included in the specimen when the lymph nodes within the triangle are removed. These nodes are at greatest risk for harboring metastases from cancers arising from the oral cavity, anterior nasal cavity, soft tissue structures of the midface, and submandibular gland.

Upper jugular (includes sublevels IIA and IIB)

Lymph nodes located around the upper third of the internal jugular vein and adjacent spinal accessory nerve extending from the level of the skull base (above) to the level of the inferior border of the hyoid bone (below). The anterior (medial) boundary is the stylohyoid muscle (the radiologic correlate is the vertical plane defined by the posterior surface of the submandibular gland) and the posterior (lateral) boundary is the posterior border of the sternocleidomastoid muscle. Sublevel IIA nodes are located anterior (medial) to the vertical plane defined by the spinal accessory nerve. Sublevel IIB nodes are located posterior (lateral) to the vertical plane defined by the spinal accessory nerve. The upper jugular nodes are at greatest risk for harboring metastases from cancers arising from the oral cavity, nasal cavity, nasopharynx, oropharynx, hypopharynx, larynx, and parotid gland.

Middle jugular (level III)

Lymph nodes located around the middle third of the internal jugular vein extending from the inferior border of the hyoid bone (above) to the inferior border of the cricoid cartilage (below). The anterior (medial) boundary is the lateral border of the sternohyoid muscle, and the posterior (lateral) boundary is the posterior border of the sternocleidomastoid muscle. These nodes are at greatest risk for harboring metastases from cancers arising from the oral cavity, nasopharynx, oropharynx, hypopharynx, and larynx.

Lower jugular (level IV)

Lymph nodes located around the lower third of the internal jugular vein extending from the inferior border of the cricoid cartilage (above) to the clavicle below. The anterior (medial) boundary is the lateral border of the sternohyoid muscle and the posterior (lateral) boundary is the posterior border of the sternocleidomastoid muscle. These nodes are at greatest risk for harboring metastases from cancers arising from the hypopharynx, thyroid, cervical esophagus, and larynx.

Posterior triangle group (includes sublevels VA and VB)

This group is composed predominantly of the lymph nodes located along the lower half of the spinal accessory nerve and the transverse cervical artery. The supraclavicular nodes are also included in posterior triangle group. The superior boundary is the apex formed by convergence of the sternocleidomastoid and trapezius muscles, the inferior boundary is the clavicle, the anterior (medial) boundary is the posterior border of the sternocleidomastoid muscle, and the posterior (lateral) boundary is the anterior border of the trapezius muscle. Sublevel VA is separated from sublevel VB by a horizontal plane marking the inferior border of the anterior cricoid arch. Thus, sublevel VA includes the spinal accessory nodes, whereas sublevel VB includes the nodes following the transverse cervical vessels and the supraclavicular nodes with the exception of the Virchow node, which is located in level IV. The posterior triangle nodes are at greatest risk for harboring metastases from cancers arising from the nasopharynx, oropharynx, and cutaneous structures of the posterior scalp and neck.

Anterior compartment group (level VI)

Lymph nodes in this compartment include the pretracheal and paratracheal nodes, precricoid (Delphian) node, and the perithyroidal nodes including the lymph nodes along the recurrent laryngeal nerves. The superior boundary is the hyoid bone, the inferior boundary is the suprasternal notch, and the lateral boundaries are the common carotid arteries. These nodes are at greatest risk for harboring metastases from cancers arising from the thyroid gland, glottic and subglottic larynx, apex of the piriform sinus, and cervical esophagus.

Classification of Neck Dissection

RADICAL NECK DISSECTION

Radical neck dissection refers to the removal of all ipsilateral cervical lymph node groups extending from the inferior border of the mandible to the clavicle, from the lateral border of the sternohyoid muscle, hyoid bone, and contralateral anterior belly of the digastric muscle medially, to the anterior border of the trapezius muscle. Included are all lymph nodes from levels I through V. The SAN, internal jugular vein, and SCM are also removed. Radical neck dissection does not include removal of the suboccipital nodes, periparotid nodes (except intraparotid nodes located in the posterior aspect of the submandibular triangle), buccinator nodes, retropharyngeal nodes, and midline visceral (anterior compartment) nodes.

MODIFIED RADICAL NECK DISSECTION

Modified radical neck dissection refers to the excision of all lymph nodes routinely removed by the radical neck dissection with

preservation of 1 or more nonlymphatic structures (ie, the SAN, internal jugular vein, and SCM). The structure(s) preserved should be specifically named (eg, modified radical neck dissection with preservation of the SAN).

SELECTIVE NECK DISSECTION

Selective neck dissection refers to a cervical lymphadenectomy in which there is preservation of 1 or more of the lymph node groups that are routinely removed in the radical neck dissection. The lymph node groups removed are based on the patterns of metastases, which are predictable relative to the primary site of disease. For oral cavity cancers, the lymph nodes at greatest risk are located in levels I, II, and III. The lymph nodes at greatest risk for oropharyngeal, hypopharyngeal, and laryngeal cancers are located in levels II, III, and IV, whereas for thyroid cancer, the lymph nodes in VI are at the greatest risk.

EXTENDED NECK DISSECTION

Extended neck dissection refers to the removal of 1 or more additional lymph node groups or nonlymphatic structures, or both, not encompassed by the radical neck dissection. Examples of such lymph node groups include the parapharyngeal (retropharyngeal), superior mediastinal, perifacial (buccinator), and paratracheal lymph nodes. Examples of nonlymphatic structures include the carotid artery, hypoglossal nerve, vagus nerve, and paraspinal muscles. All additional lymphatic and/or nonlymphatic structure(s) to be removed should be identified in parentheses.

References

1. Afzelius LE, Gunnarsson M, Nordgren H. Guidelines for prophylactic radical lymph node dissection in cases of carcinoma of the external ear. *Head & Neck Surgery* 1980; 2: 361-5.
2. Byers R, Kesler K, Redmon B, Medina J, Schwarz B. Squamous carcinoma of the external ear. *American Journal of Surgery* 1983; 146: 447-50.
3. Freedlander E, Chung FF. Squamous cell carcinoma of the pinna. *British Journal of Plastic Surgery* 1983; 36: 171-5.
4. Cooper JS, Pajak TF, Forastiere AA, et al. Postoperative concurrent radiotherapy and chemotherapy for high-risk squamous-cell carcinoma of the head and neck. [see comment]. *New England Journal of Medicine* 2004; 350: 1937-44.
5. Withers HR, Suwinski R. Radiation dose response for subclinical metastases. *Seminars in Radiation Oncology`* 1998; 8: 224-28.
6. Fletcher GH. Elective irradiation of subclinical disease in cancers of the head and neck. *Cancer* 1972; 29: 1450-4.
7. Mladick RA, Horton CE, Adamson JE, Carraway JH. The core resection for malignant tumors of the auricular area and subjacent bones. *Plastic & Reconstructive Surgery* 1974; 53: 281-7.
8. Lewis JS. Cancer of the ear: a report of 150 cases. *Laryngoscope* 1960; 70: 551-79.
9. Katz AD, Urback F, Lilienfeld AM. The frequency and risk of metastases in squamous cell carcinoma of the skin. *Cancer* 1957; 10: 1162-66.
10. Broders AC. Squamous-cell epithelioma of the skin. *Ann Surg* 1921; 73: 141-60.
11. Lund HZ. Metastasis from sun-induced squamous-cell carcinoma of the skin: an uncommon event. *Journal of Dermatologic Surgery & Oncology* 1984; 10: 169-70.
12. Lund HZ. How often does squamous cell carcinoma of the skin metastasize? *Archives of Dermatology* 1965; 92: 635-7.
13. Rowe DE, Carroll RJ, Day CL, Jr. Prognostic factors for local recurrence, metastasis, and survival rates in squamous cell carcinoma of the skin, ear, and lip. Implications for treatment modality selection. [see comment]. *Journal of the American Academy of Dermatology* 1992; 26: 976-90.
14. Lewis KG, Weinstock MA. Nonmelanoma skin cancer mortality (1988-2000): the Rhode Island follow-back study. *Archives of Dermatology* 2004; 140: 837-42.
15. Swanbeck G, Hillstrom L. Analysis of etiological factors of squamous cell skin cancer of different locations. 4. Concluding remarks. *Acta Dermato-Venereologica* 1971; 51: 151-6.

16. Blake GB, Wilson JS. Malignant tumours of the ear and their treatment. I. Tumours of the auricle. *British Journal of Plastic Surgery* 1974; 27: 67-76.
17. Estrem SA, Renner GJ. Special problems associated with cutaneous carcinoma of the ear. *Otolaryngologic Clinics of North America* 1993; 26: 231-45.
18. Go KG, Annyas AA, Vermey A, et al. Evaluation of results of temporal bone resection. *Acta Neurochirurgica* 1991; 110: 110-5.
19. Jol JA, van Velthuysen ML, Hilgers FJ, et al. Treatment results of regional metastasis from cutaneous head and neck squamous cell carcinoma. *European Journal of Surgical Oncology* 2003; 29: 81-6.
20. Lehnerdt G, Metz KA, Peine L, Jahnke K, Dost P. [Squamous cell carcinoma of the external ear. A carcinoma of old age which requires individualized therapy planning]. *HNO* 2004; 52: 518-24.
21. Goodwin RG, Holme SA, Roberts DL. Variations in registration of skin cancer in the United Kingdom. *Clinical & Experimental Dermatology* 2004; 29: 328-30.
22. Skin Cancer in the UK Factsheet. 2004.
23. Glass AG, Hoover RN. The emerging epidemic of melanoma and squamous cell skin cancer. [see comment]. *JAMA* 1989; 262: 2097-100.
24. Scottish Health Statistics. 2006: 2006.
25. Staples M, Marks R, Giles G. Trends in the incidence of non-melanocytic skin cancer (NMSC) treated in Australia 1985-1995: are primary prevention programs starting to have an effect? *International Journal of Cancer* 1998; 78: 144-8.
26. Chuang TY, Popescu NA, Su WP, Chute CG. Squamous cell carcinoma. A population-based incidence study in Rochester, Minn. *Archives of Dermatology* 1990; 126: 185-8.
27. Iversen T, Tretli S. Trends for invasive squamous cell neoplasia of the skin in Norway. *British Journal of Cancer* 1999; 81: 528-31.
28. Alexander LL, Medina A, Camiel MR, Benninghoff DL. Radiotherapy of the Ear. *J Natl Med Assoc* 1963; 61: 491-2.
29. Alexander LL, Medina A, Camiel MR, Benninghoff DL. Radiotherapy of the ear. *Journal of the National Medical Association* 1969; 61: 491-2.
30. Avila J, Bosch A, Aristizabal S, Frias Z, Marcial V. Carcinoma of the pinna. *Cancer* 1977; 40: 2891-5.
31. Bailin PL, Levine HL, Wood BG, Tucker HM. Cutaneous carcinoma of the auricular and periauricular region. *Archives of Otolaryngology* 1980; 106: 692-6.
32. Bumsted RM, Ceilley RI. Auricular malignant neoplasms. Identification of high-risk lesions and selection of method of reconstruction. *Archives of Otolaryngology* 1982; 108: 225-31.

33. Bumsted RM, Ceilley RI, Panje WR, Crumley RL. Auricular malignant neoplasms. When is chemotherapy (Mohs' technique) necessary? *Archives of Otolaryngology* 1981; 107: 721-4.
34. Caccialanza M, Piccinno R, Kolesnikova L, Gnecci L. Radiotherapy of skin carcinomas of the pinna: a study of 115 lesions in 108 patients. *International Journal of Dermatology* 2005; 44: 513-7.
35. Caccialanza M, Piccinno R, Sopelana N, Beretta M, Gnecci L. Radiotherapy of skin carcinomas of the ear. *Skin Cancer* 1997; 12: 105-10.
36. Chen KT, Dehner LP. Primary tumors of the external and middle ear. I. Introduction and clinicopathologic study of squamous cell carcinoma. *Archives of Otolaryngology* 1978; 104: 247-52.
37. Jeppson PH, Lindstrom J. Carcinoma of the external ear. *Orl; Journal of Oto-Rhino-Laryngology & its Related Specialties* 1973; 35: 336-41.
38. Leferink VJ, Nicolai JP. Malignant tumors of the external ear. *Annals of Plastic Surgery* 1988; 21: 550-4.
39. Levine HL, Kinney SE, Bailin PL, Roberts JK. Cancer of the periauricular region. *Dermatologic Clinics* 1989; 7: 781-95.
40. Lewis JS. Squamous carcinoma of the ear. *Archives of Otolaryngology* 1973; 97: 41-2.
41. Morrison WH, Garden AS, Ang KK. Radiation therapy for nonmelanoma skin carcinomas. *Clinics in Plastic Surgery* 1997; 24: 719-29.
42. Pless J. Carcinoma of the external ear. *Scandinavian Journal of Plastic & Reconstructive Surgery* 1976; 10: 147-51.
43. Robins P. Chemosurgery: my 15 years of experience. *Journal of Dermatologic Surgery & Oncology* 1981; 7: 779-89.
44. Schewe EJ PC. Cancer of The External Ear. *American Journal of Surgery* 1962; 104: 753-6.
45. Shiffman NJ. Squamous cell carcinomas of the skin of the pinna. *Canadian Journal of Surgery* 1975; 18: 279-83.
46. Mohs FE. Chemosurgical treatment of cancer of the ear: a microscopically controlled method of excision. *Surgery* 1947; 21: 605-22.
47. Mohs F, Larson P, Iriondo M. Micrographic surgery for the microscopically controlled excision of carcinoma of the external ear. *Journal of the American Academy of Dermatology* 1988; 19: 729-37.
48. Ceilley RI, Bumsted RM, Smith WH. Malignancies on the external ear: methods of ablation and reconstruction of defects. *Journal of Dermatologic Surgery & Oncology* 1979; 5: 762-7.
49. Nordin P. Curettage-cryosurgery for non-melanoma skin cancer of the external ear: excellent 5-year results. *British Journal of Dermatology* 1999; 140: 291-3.

50. Veness MJ, Morgan GJ, Palme CE, Gebiski V. Surgery and adjuvant radiotherapy in patients with cutaneous head and neck squamous cell carcinoma metastatic to lymph nodes: combined treatment should be considered best practice. *Laryngoscope* 2005; 115: 870-5.
51. Veness MJ, Palme CE, Smith M, et al. Cutaneous head and neck squamous cell carcinoma metastatic to cervical lymph nodes (nonparotid): a better outcome with surgery and adjuvant radiotherapy. *Laryngoscope* 2003; 113: 1827-33.
52. Johnson JT, Barnes EL, Myers EN, et al. The extracapsular spread of tumors in cervical node metastasis. *Archives of Otolaryngology* 1981; 107: 725-9.
53. Johnson JT, Myers EN, Bedetti CD, et al. Cervical lymph node metastases. Incidence and implications of extracapsular carcinoma. *Archives of Otolaryngology* 1985; 111: 534-7.
54. O'Brien CJ. The parotid gland as a metastatic basin for cutaneous cancer. *Archives of Otolaryngology -- Head & Neck Surgery* 2005; 131: 551-5.
55. Byers RM, Smith JL, Russell N, Rosenberg V. Malignant melanoma of the external ear. Review of 102 cases. *American Journal of Surgery* 1980; 140: 518-21.
56. Ahmad I, Das Gupta AR. Epidemiology of basal cell carcinoma and squamous cell carcinoma of the pinna. *Journal of Laryngology & Otology* 2001; 115: 85-6.
57. Standring S. *Gray's Anatomy*. 39th ed.: Churchill Livingstone, 2004.
58. Rouviere H. *Anatomie des Lymphatiques de l'Homme*. Libraires de l'Academie de Medecine, 1932.
59. Kubrik S. *Textbook of Lymphology*. 1st ed.: Urban & Fischer, 2003.
60. Ravin AG, Pickett N, Johnson JL, et al. Melanoma of the ear: Treatment and survival probabilities based on 199 patients. *Annals of Plastic Surgery* 2006; 57: 70-76.
61. Berry E, Kelly S, Hutton J, Harris KM, Smith MA. Identifying studies for systematic reviews. An example from medical imaging. *International Journal of Technology Assessment in Health Care* 2000; 16: 668-72.
62. Dickersin K, Scherer R, Lefebvre C. Identifying relevant studies for systematic reviews. [see comment]. *BMJ* 1994; 309: 1286-91.
63. Helmer D, Savoie I, Green C, Kazanjian A. Evidence-based practice: extending the search to find material for the systematic review. *Bulletin of the Medical Library Association* 2001; 89: 346-52.
64. Centre for Reviews and Dissemination - *Finding Studies for Systematic Reviews*. 2005.
65. Fredricks S. External ear malignancy. *Br J Plast Surg* 1956; 9: 136-60.

66. Lee D, Nash M, Har-El G. Regional spread of auricular and periauricular cutaneous malignancies. *Laryngoscope* 1996; 106: 998-1001.
67. Shockley WW, Stucker FJ, Jr. Squamous cell carcinoma of the external ear: a review of 75 cases. *Otolaryngology - Head & Neck Surgery* 1987; 97: 308-12.
68. Vauterin TJ, Veness MJ, Morgan GJ, Poulsen MG, O'Brien CJ. Patterns of lymph node spread of cutaneous squamous cell carcinoma of the head and neck. *Head & Neck* 2006; 28: 785-91.
69. Weinstock MA, Bogaars HA, Ashley M, et al. Nonmelanoma skin cancer mortality. A population-based study. *Archives of Dermatology* 1991; 127: 1194-7.
70. Breslow A. Prognostic factors in the treatment of cutaneous melanoma. *Journal of Cutaneous Pathology* 1979; 6: 208-12.
71. Afzelius LE, Nordgren H. [Histologic scoring system for various cancers of the external ear]. *HNO* 1984; 32: 63-4.
72. Lee JG, Krause CJ. Radical neck dissection: Elective, therapeutic, and secondary. *Archives of Otolaryngology* 1975; 101: 656-9.
73. Pitman KT, Johnson JT, Myers EN. Effectiveness of selective neck dissection for management of the clinically negative neck. *Archives of Otolaryngology -- Head & Neck Surgery* 1997; 123: 917-22.
74. Mendenhall WM, Million RR. Elective neck irradiation for squamous cell carcinoma of the head and neck: analysis of time-dose factors and causes of failure. *International Journal of Radiation Oncology, Biology, Physics* 1986; 12: 741-6.
75. Ross GL, Soutar DS, Gordon MacDonald D, et al. Sentinel node biopsy in head and neck cancer: preliminary results of a multicenter trial. [see comment]. *Annals of Surgical Oncology* 2004; 11: 690-6.
76. Tanis PJ, Nieweg OE, Valdes Olmos RA, Th Rutgers EJ, Kroon BB. History of sentinel node and validation of the technique. *Breast Cancer Research* 2001; 3: 109-12.
77. Alvi A, Johnson JT. Extracapsular spread in the clinically negative neck (N0): implications and outcome. *Otolaryngology - Head & Neck Surgery* 1996; 114: 65-70.
78. Conley J, Schuller DE. Malignancies of the ear. *Laryngoscope* 1976; 86: 1147-63.
79. Dolan KD. Malignant lesions of the ear. *Radiologic Clinics of North America* 1974; 12: 585-600.
80. Lin D, Franc BL, Kashani-Sabet M, Singer MI. Lymphatic drainage patterns of head and neck cutaneous melanoma observed on lymphoscintigraphy and sentinel lymph node biopsy. *Head & Neck* 2006; 28: 249-55.

81. MacNeill KN, Ghazarian D, McCready D, Rotstein L. Sentinel lymph node biopsy for cutaneous melanoma of the head and neck. *Annals of Surgical Oncology* 2005; 12: 726-32.
82. Mustafa A, Inodot, m A, et al. Lymphoscintigraphic drainage patterns of the auricle in healthy subjects. *Head & Neck* 2005; 27: 893-900.
83. Jameson J, Dobson I. The lymphatics of the colon. *Proceeding of The Royal Society of Medicine* 1909; 2: 149-72.
84. Turner-Warwick RT. Intravital Techniques For The Demonstration Of Lymphatics. *Annals of The Royal College of Surgeons of England* 1959; 24: 101-09.
85. Ogura JH, Biller HF, Wette R. Elective neck dissection for pharyngeal and laryngeal cancers. An evaluation. *Annals of Otolaryngology & Rhinology* 1971; 80: 646-50.
86. Pitman KT. Rationale for elective neck dissection. *American Journal of Otolaryngology* 2000; 21: 31-7.
87. Pitman KT. Sentinel node localization in head and neck tumors. *Seminars in Nuclear Medicine* 2005; 35: 253-6.
88. Weissbach L, Boedefeld EA. Localization of solitary and multiple metastases in stage II nonseminomatous testis tumor as basis for a modified staging lymph node dissection in stage I. *Journal of Urology* 1987; 138: 77-82.
89. Cabanas RM. An approach for the treatment of penile carcinoma. *Cancer* 1977; 39: 456-66.
90. Chiappa S, Uslenghi C, Bonadonna G, Marano P, Ravasi G. Combined testicular and foot lymphangiography in testicular carcinomas. *Surgery, Gynecology & Obstetrics* 1966; 123: 10-4.
91. Morton DL, Wen DR, Wong JH, et al. Technical details of intraoperative lymphatic mapping for early stage melanoma. *Archives of Surgery* 1992; 127: 392-9.
92. Giuliano AE, Kirgan DM, Guenther JM, Morton DL. Lymphatic mapping and sentinel lymphadenectomy for breast cancer. [see comment]. *Annals of Surgery* 1994; 220: 391-8; discussion 98-401.
93. Kaptijn BA, Nieweg OE, Petersen JL, et al. Identification and biopsy of the sentinel lymph node in breast cancer. *European Journal of Surgical Oncology* 1998; 24: 427-30.
94. Reintgen D, Cruse CW, Wells K, et al. The orderly progression of melanoma nodal metastases. *Annals of Surgery* 1994; 220: 759-67.
95. Ross GL, Shoaib T, Soutar DS, et al. The First International Conference on Sentinel Node Biopsy in Mucosal Head and Neck Cancer and adoption of a multicenter trial protocol. *Annals of Surgical Oncology* 2002; 9: 406-10.
96. Morton DL, Cochran AJ, Thompson JF, et al. Sentinel node biopsy for early-stage melanoma: accuracy and morbidity in MSLT-I, an international multicenter trial. *Annals of Surgery* 2005; 242: 302-11; discussion 11-3.

97. Thompson JF, Scolyer RA, Uren RF. Surgical management of primary cutaneous melanoma: excision margins and the role of sentinel lymph node examination. *Surgical Oncology Clinics of North America* 2006; 15: 301-18.
98. Kettlewell S, Moyes C, Bray C, et al. Value of sentinel node status as a prognostic factor in melanoma: prospective observational study. *BMJ* 2006; 332: 1423.
99. Morton DL, Cochran AJ, Thompson JF. Sentinel-Node Biopsy in Melanoma. *New England Journal of Medicine* 2007; 356: 418-21.
100. SIGN. Cutaneous Melanoma. 2004: 2007.
101. Gray H. Gray's Anatomy. 39th ed.: Churchill Livingstone, 2004.
102. Prause G, Ratzenhofer-Comenda B, Pierer G, et al. Can ASA grade or Goldman's cardiac risk index predict peri-operative mortality? A study of 16 227 patients. *Anaesthesia* 1997; 52: 203-06.
103. Ross GL, Shoaib T, Scott J, et al. The impact of immunohistochemistry on sentinel node biopsy for primary cutaneous malignant melanoma. *British Journal of Plastic Surgery* 2003; 56: 153-5.
104. MacKie RM, Bray CA, Leman JA. Effect of public education aimed at early diagnosis of malignant melanoma: Cohort comparison study. *British Medical Journal* 2003; 326: 367.
105. Eicher SA, Clayman GL, Myers JN, Gillenwater AM. A prospective study of intraoperative lymphatic mapping for head and neck cutaneous melanoma.[see comment]. *Archives of Otolaryngology -- Head & Neck Surgery* 2002; 128: 241-6.
106. Loree TR, Tomljanovich PI, Cheney RT, Hicks WL, Jr., Rigual NR. Intraparotid sentinel lymph node biopsy for head and neck melanoma. *Laryngoscope* 2006; 116: 1461-4.
107. Weinstock MA. Epidemiologic investigation of nonmelanoma skin cancer mortality: the Rhode Island Follow-Back Study. *Journal of Investigative Dermatology* 1994; 102: 6S-9S.
108. Motley R, Kersey P, Lawrence C, British Association of D, British Association of Plastic S. Multiprofessional guidelines for the management of the patient with primary cutaneous squamous cell carcinoma. *British Journal of Plastic Surgery* 2003; 56: 85-91.
109. Williams G. Minimum dataset for histopathological reporting of skin cancers. 2002: 2007.
110. Lee PJA. Datasets for histopathology reports on head and neck carcinomas and salivary neoplasms. 2005: 2007.
111. Breslow A. Thickness, cross-sectional areas and depth of invasion in the prognosis of cutaneous melanoma. *Annals of Surgery* 1970; 172: 902-8.

- 112. Lehnerdt G, Schmitz KJ, Dost P, Koch DA, Jahnke K. [Histological criteria and metastasis of squamous cell carcinoma of the pinna]. Laryngo- Rhino- Otologie 2005; 84: 482-6.**
- 113. Chummun S, McLean NR, Ragbir M. Surgical education: neck dissection. British Journal of Plastic Surgery 2004; 57: 610-23.**
- 114. Robbins KT, Clayman G, Levine PA, et al. Neck dissection classification update: revisions proposed by the American Head and Neck Society and the American Academy of Otolaryngology-Head and Neck Surgery. Arch Otolaryngol Head Neck Surg 2002; 128: 751-8.**