



<https://theses.gla.ac.uk/>

Theses Digitisation:

<https://www.gla.ac.uk/myglasgow/research/enlighten/theses/digitisation/>

This is a digitised version of the original print thesis.

Copyright and moral rights for this work are retained by the author

A copy can be downloaded for personal non-commercial research or study, without prior permission or charge

This work cannot be reproduced or quoted extensively from without first obtaining permission in writing from the author

The content must not be changed in any way or sold commercially in any format or medium without the formal permission of the author

When referring to this work, full bibliographic details including the author, title, awarding institution and date of the thesis must be given

Enlighten: Theses

<https://theses.gla.ac.uk/>
research-enlighten@glasgow.ac.uk

*Lymph node mapping and
identification of sentinel
nodes in oral and
oropharyngeal cancer*

Taimur Shoaib

University of Glasgow

M.D. Thesis

Plastic Surgery Unit

Canniesburn Hospital

September 2002

ProQuest Number: 10390625

All rights reserved

INFORMATION TO ALL USERS

The quality of this reproduction is dependent upon the quality of the copy submitted.

In the unlikely event that the author did not send a complete manuscript and there are missing pages, these will be noted. Also, if material had to be removed, a note will indicate the deletion.



ProQuest 10390625

Published by ProQuest LLC (2017). Copyright of the Dissertation is held by the Author.

All rights reserved.

This work is protected against unauthorized copying under Title 17, United States Code
Microform Edition © ProQuest LLC.

ProQuest LLC.
789 East Eisenhower Parkway
P.O. Box 1346
Ann Arbor, MI 48106 – 1346

GLASGOW
UNIVERSITY
LIBRARY:

13011

copy-2

ACKNOWLEDGEMENTS

I am indebted to the several people, without whom this thesis would not have been possible. In particular, I am grateful to Mr D.S. Soutar, Prof. D.G. MacDonald, Dr H.W. Gray and Dr R.G. Bessent for proof reading the thesis and suggesting invaluable improvements. All errors within this thesis are mine.

All the following people and groups have my unreserved gratitude: Canniesburn Research Trust, The White Lily Trust, David Soutar, Rona MacKie, Harry Gray, Gordon MacDonald, David Dunaway, Ivan Camilleri, Stephen Hickey, Alec Patrick, Ken James, Rodney Bessent, Joanne Prosser, Graham McCurrach, Frances McPherson, Susan Clark, all staff of the Nuclear Medicine Department at the Glasgow Royal Infirmary the staff of wards 2, 3, 4 and 6 at Canniesburn Hospital, the staff of the Oral Pathology Unit at the Glasgow Dental Hospital and School and all staff of the operating suite at Canniesburn Hospital.

DEDICATION

This thesis is dedicated to my children, Maliha and Karim. Their charm is only exceeded by their beauty.

SUMMARY

INTRODUCTION

Sentinel node biopsy (SNB) is a new technique in the management of cancers. The technique, which has been studied most in melanoma and breast cancer, involves the identification of the first lymph node draining a tumour and the examination of that node for the presence of nodal metastases. If the sentinel lymph node (SLN) does not contain tumour, the implication is that the whole regional lymph node basin is free from tumour and a formal lymph node dissection can be avoided.

Prior to the start of this study, few studies had been performed on patients with head and neck cancer and those that were published were either in very low numbers or had failed in their aims. This study was performed to determine whether the SLN could be identified in patients with head and neck cancer and to determine if the SLN was an accurate reflector of the pathological status of the neck. If these aims were met, the technique could be applied as a staging procedure, and avoid an elective neck dissection.

METHODS

Patients with biopsy proven, single focus, mucosal malignancies of the upper aerodigestive tract were included in the study.

Initially, patients undergoing a neck dissection as part of their routine treatment were included in the study. SLN's were firstly identified by injection of Patent Blue V dye only. Subsequently patients were injected with radiocolloid and blue dye. The radiocolloid initially used was Albures (a large diameter colloid) for all primary tumour sites. Subsequently, Albures was reserved for tumours of the tongue and

floor of mouth while Nanocoll (a small diameter colloid) was used for tumours at other sites. The presence of SLN's in the neck was recorded, as was the levels within the neck, the presence of blue dye and amount of radioactivity within the SLN's. The pathological stage of the remaining neck dissection specimen was also noted.

The SNB procedure was subsequently applied to a group of patients who would otherwise undergo observation of the neck or an elective neck dissection, to determine whether the procedure could be applied in a clinical context.

RESULTS

A total of 103 necks were explored in 96 patients with head and neck cancers. Each neck side was considered a single case.

SNB using blue dye alone was performed in 16 cases (in 16 patients). SNB in the blue dye group was unsuccessful. SLN's were found in only seven cases of 16 and no SLN's contained tumour by routine pathology. In these seven cases, tumour was present in the remaining neck specimen in three cases, and in each case the SLN's did not contain tumour.

SNB using a combination of blue dye and radiocolloid was performed in 40 clinically N0/x necks (from 37 patients). Twenty necks were staged pathologically N0 (pN0) and 20 were pathologically involved with metastases (pN+). In the pN+ cases, SLN's were found in 36 cases and the SLN's was found to contain tumour, using routine pathology, in 16 cases of 17 where a sentinel node was found.

SNB was performed in 27 clinically N+ necks (from 25 patients) in patients where neck dissections were also performed, using blue dye and radiocolloid. In 18 cases Albures was the radiocolloid used and in 9 cases Nanocoll was used. In the group injected with Albures,

SLN's were identified in 15, tumour was found in the neck dissection in 12 cases, and the SLN's contained tumour in two of these 12. In the group injected with Nanocoll, SLN's were found in eight of nine, the neck contained tumour in eight and the SLN's also contain tumour in seven of eight.

SNB using radiocolloid and blue dye was performed in 16 patients (17 neck sides) who did not initially undergo a neck dissection. SLN's were found in all but one patient and contained tumour by routine pathology in two cases. These two patients subsequently underwent therapeutic neck dissection and post operative radiotherapy.

The amount of radioactivity within SLN's and the size of SLN's was studied. This was performed to determine whether all blue and radioactive nodes should be harvested in a sentinel node procedure. In cases where more than one blue or radioactive node was identified, the two largest SLN's and the three most radioactivity SLN's were sufficient to stage the neck for tumour metastases

Three necks were explored for sentinel nodes in two patients with oral melanoma. SLN's were found in both patients, and melanin containing macrophages were found in the SLN of one patient.

CONCLUSIONS

In head and neck cancer, SNB to stage the neck is best performed in the clinically N0 neck using a combination of radiocolloid and blue dye injection. The use of the SNB procedure in the clinically involved neck is not accurate but the sensitivity of the procedure increases when a small diameter colloid is used. The presence of radioactivity in the neck is a reflection of lymphatic transport from the injection site to the SLN's and the choice of radiocolloid should be dependent on the anatomical site of the primary malignancy. It is possible to locate

SLN's in the neck, when no other elective neck surgery is performed, using a smaller incision than that for a neck dissection. The true sensitivity of SNB in this context is unknown but will become apparent with time. In patients with head and neck cancer, with tumours accessible to injection without the need for general anaesthesia, the SLN accurately stages the neck and should be investigated in larger multicentre trials. Such a trial has been initiated as a result of the work within this thesis.

TABLE OF CONTENTS

ACKNOWLEDGEMENTS.....	2
DEDICATION.....	3
SUMMARY	4
INTRODUCTION.....	4
METHODS	4
RESULTS	5
CONCLUSIONS.....	6
TABLE OF CONTENTS.....	8
LIST OF FIGURES	13
LIST OF TABLES	16
CHAPTER 1: INTRODUCTION.....	17
GENERAL INTRODUCTION TO ORAL AND OROPHARYNGEAL CANCER	17
THE CERVICAL LYMPH NODES IN HEAD AND NECK CANCER	19
MANAGEMENT OF THE NECK	21
NECK DISSECTION.....	23
SENTINEL NODE BIOPSY	26
HISTORY OF SENTINEL NODE BIOPSY	27
LYMPHOSCINTIGRAPHY IN SENTINEL NODE BIOPSY	29
THE SENTINEL NODE IN HEAD AND NECK CARCINOMA	31
LYMPH NODE HISTOPATHIOLOGY IN HEAD AND NECK CARCINOMA	32
AIMS.....	33
TABLES AND FIGURES	34

CHAPTER 2: INITIAL METHOD WITH BLUE DYE ALONE.....	48
INTRODUCTION.....	48
MATERIALS AND METHODS	48
RESULTS	50
DISCUSSION	50
TABLES AND FIGURES	54
CHAPTER 3: CHOICE OF COLLOID IN HEAD AND NECK	
CANCER SENTINEL NODE BIOPSY	55
INTRODUCTION.....	55
METHODS	56
RESULTS	59
DISCUSSION	60
TABLES AND FIGURES	65
CHAPTER 4: SENTINEL NODE BIOPSY PATHOLOGY USING	
RADIOCOLLOID AND BLUE DYE IN THE CLINICALLY N0	
NECK	74
INTRODUCTION.....	74
METHODS	74
RESULTS	76
DISCUSSION	79
CONCLUSIONS.....	84
TABLES AND FIGURES	85
CHAPTER 5: SENTINEL NODE BIOPSY PATHOLOGY USING	
BLUE DYE AND RADIOCOLLOID IN THE CLINICALLY	
INVOLVED NECK.....	87
INTRODUCTION.....	87
METHODS	88
RESULTS	89
DISCUSSION	91

TABLES AND FIGURES	93
CHAPTER 6: SENTINEL NODE BIOPSY IN HEAD AND NECK MUCOSAL MELANOMA.....	94
INTRODUCTION.....	94
METHODS	95
RESULTS	97
DISCUSSION	97
TABLES AND FIGURES	101
CHAPTER 7: SENTINEL NODE DIMENSIONS AND QUANTIFICATION OF RADIOACTIVITY WITHIN THE SENTINEL NODE	105
INTRODUCTION.....	105
METHODS	106
RESULTS	107
DISCUSSION	110
TABLES AND FIGURES	113
CHAPTER 8: THE ANATOMICAL SITE OF SENTINEL LYMPH NODES IN THE NECK	121
INTRODUCTION.....	121
METHODS	122
RESULTS	123
DISCUSSION	125
TABLES AND FIGURES	128
CHAPTER 9: SENTINEL NODE BIOPSY TO TARGET NECK DISSECTION AT THE CLINICALLY FALSE NEGATIVE NECK	136
INTRODUCTION.....	136
METHODS	137
RESULTS	139

DISCUSSION	140
TABLES AND FIGURES	143
CHAPTER 10: OVERALL RESULTS.....	145
INTRODUCTION.....	145
BLUE DYE SENTINEL NODE BIOPSY	145
SENTINEL NODE BIOPSY WITH BLUE DYE AND RADIOCOLLOID.....	146
CHOICE OF COLLOID IN HEAD AND NECK CANCER SENTINEL NODE BIOPSY	146
THE CLINICALLY N0 NECK.....	147
THE CLINICALLY INVOLVED NECK	147
SENTINEL NODE BIOPSY IN ORAL MELANOMA.....	148
SENTINEL NODE SIZE AND RADIOACTIVITY	149
THE ANATOMICAL SITE OF SENTINEL NODES IN THE NECK	149
SENTINEL NODE BIOPSY TO UPSTAGE THE CLINICALLY N0 NECK.....	150
CHAPTER 11: OVERALL DISCUSSION.....	152
CHAPTER 12: FUTURE STUDIES OF SENTINEL NODE BIOPSY IN HEAD AND NECK CANCER	163
INTRODUCTION.....	163
STUDY PROTOCOL	163
FURTHER TREATMENT FOR PATIENTS WITH SENTINEL LYMPH NODES CONTAINING TUMOUR.....	168
FOLLOW-UP.....	169
CONCLUSIONS.....	170
APPENDIX 1: ETHICAL CONSIDERATIONS.....	171

PATIENT INFORMATION AND CONSENT FORM FOR PATIENTS UNDERGOING SENTINEL NODE BIOPSY AND NECK DISSECTION	172
PATIENT INFORMATION AND CONSENT FORM FOR PATIENTS UNDERGOING SENTINEL NODE BIOPSY ONLY.....	174
APPENDIX 2: PUBLICATIONS AND PRESENTATIONS.....	180
PUBLICATIONS.....	180
PEER REVIEWS	181
PERSONAL PRESENTATIONS TO LEARNED SOCIETIES	181
REFERENCES.....	185

LIST OF FIGURES

Figure 1: Incidence of Oral Cancer in Scotland 1975-1996	34
Figure 2: Neck Dissection Levels.....	35
Figure 3: An MRND-III. The specimen has been marked to indicate the dissection levels.....	36
Figure 4 : The sentinel node concept.....	37
Figure 5: Patient with parotid malignancy and nodal metastases in the angular node.....	38
Figure 6: Patent Blue V Dye	39
Figure 7: The Neoprobe 1500 and probes	40
Figure 8: Metastatic disease in the subcapsular sinus of a lymph node.....	41
Figure 9: Skin flap raising during a neck dissection	54
Figure 10: Sentinel node biopsy in the axilla.....	65
Figure 11: Gamma camera and collimator used during lymphoscintigraphy	66
Figure 12: Lymphoscintigraphy image showing asymmetrical bilateral drainage from a centrally placed anterior floor of mouth tumour	67
Figure 13: Cobalt-57 marker pen	68
Figure 14: Blue dye injection to surround a tumour.....	69
Figure 15: Hot blue node found during a neck dissection	70
Figure 16: Masking of the injection site to highlight the sentinel nodes	71

Figure 17: The use of lead shields intraoperatively to prevent shine through from the injection site.....	72
Figure 18: Swallowed colloid passing from mouth to stomach and liver	73
Figure 19: Tongue melanoma.....	101
Figure 20: Lymphoscintigraphy of patient with tongue melanoma showing bilateral drainage	102
Figure 21: Palatal melanoma with invasive component to the left of the midline	103
Figure 22: Lymphoscintigraphy of patient with palatal melanoma..	104
Figure 23: Confirming radioactivity of nodes ex-vivo.....	113
Figure 24: The maximum diameters of lymph nodes	114
Figure 25: Box plot comparing the maximum diameter of positive and negative nodes, showing statistical significant differences	115
Figure 26: Comparison of maximum nodal diameters from nodes containing and free from tumour.....	116
Figure 27: A comparison of nodal volume and amount of radioactivity, showing the best fit curve	117
Figure 28: Comparison of tumour radioactivity by positive and negative sentinel nodes	118
Figure 29: Cadaveric studies demonstrating tongue lymphatic drainage (from Human Anatomy, Churchill Livingstone, 3rd Edition, 1982).....	128
Figure 30: Lymphoscintigraphy image of sentinel nodes from a lateral tongue tumour – the highest hot spot was found to be located in the tonsillar region at operation.....	129
Figure 31: Tongue cancer sentinel node distribution	130

Figure 32: FOM cancer sentinel node distribution.....	131
Figure 33: RMT cancer sentinel node distribution.....	132
Figure 34: Lymphoscintigraphy highlighting two sentinel nodes in the neck and one sentinel node in the tonsillar region	133
Figure 35: Soft palate cancer sentinel node distribution	134
Figure 36: Number of sentinel nodes per patient in those undergoing sentinel node biopsy only	143
Figure 37: Sentinel node locations in patients undergoing sentinel node biopsy only.....	144

LIST OF TABLES

Table 1: ICD-9 codes for head and neck cancer.....	42
Table 2: TNM clinical staging of SCC of the oral cavity and oropharynx ¹⁵⁵	43
Table 3: Stage Grouping.....	44
Table 4: Neck dissection levels.....	45
Table 5: Neck Dissection Terminology.....	46
Table 6: Properties of the ideal colloid ¹⁴⁰	47
Table 7: Number of sentinel nodes found by lymph node level and involvement by SCC	85
Table 8: Number of lymph nodes examined and containing tumour by lymph node level.....	85
Table 9: Sentinel nodes in the pN+ neck according to presence of tumour, dye and radiocolloid.....	86
Table 10: The anatomical location of non-sentinel nodes containing tumour, when non-sentinel nodes were found to harbour metastases	86
Table 11: Sentinel nodes by colour and radioactivity	93
Table 12: The rank (per patient) of radioactive nodes with their pathology	119
Table 13: The rank of the maximum diameter of the sentinel node per case compared with the pathology of the node	120
Table 14: Distribution of tumour and nodes where sentinel node pathology reflected that of the remaining neck nodes.....	135

CHAPTER 1: INTRODUCTION

GENERAL INTRODUCTION TO ORAL AND OROPHARYNGEAL CANCER

Oral cancer and oropharyngeal cancers are malignant transformations of the mucosa of the oral cavity and oropharynx. The commonest malignant transformation of the mucosa in these areas is a squamous cell carcinoma (SCC). SCC's of these anatomical sites behave similarly to SCC's of other sites within the mucosa of the upper aerodigestive tract and are commonly termed "Head and neck cancers" (Table 1).

Within this Thesis, the terms "head and neck cancer", "oral cancer" and "oropharyngeal cancer" refer only to cancers that can be visualised through the oral cavity and will include oral cavity and some oropharyngeal malignancies. These terms will be used interchangeably.

Head and neck cancer represents approximately 2-5% of all tumours^{1;2}. In Scotland the incidence of oral cancer is rising. In 1975, there were 88 cases of oral cancer in Scotland; by 1996 there were 204 cases (Figure 1). In Scotland, oral cancer trends are collected by the Scottish Cancer Intelligence Unit which produces cancer registration statistics for Scotland and publishes the data on the internet (http://www.show.scot.nhs.uk/isd/cancer/facts_figures/types/oral.htm).

Worldwide, the incidence of oral cancer is also increasing. In 1994, Macfarlane and co-workers examined World Health Organization data. Cancer registry data was available from 24 countries and a rising incidence in men was noted in 19³ but not in women⁴. The

incidence in women is likely to rise, since the use of tobacco, an important aetiological factor, in women is rising.

Aetiological factors are well documented for oral cancer. Tobacco use has a synergistic effect with alcohol use and in the Western world, these are the most important causative factors. In many countries, use of the areca or betel nut is associated with oral cancer and less common factors include human papilloma virus infection, syphilis and sideropaenic dysphagia⁵. Poor socio-economic status, poor oral health and poor diet are common associations.. Pre-malignant lesions are well recognised in oral cancers and these include leukoplakia and erythroleukoplakia^{5;6}.

The management of oral cancer is continually evolving^{7;8}. Surgery to the primary lesion either alone or in combination with radiotherapy is the most effective form of treatment for head and neck cancer. However, despite a greater understanding of the natural history of the disease⁹, survival for oral cancer has not improved over the past few decades¹⁰⁻¹⁴. The suggestion is that there is a deficiency of public and professional awareness and education regarding the early diagnosis of oral cancer and oral health information in general. Continued smoking and drinking increases the risk of developing metachronous second primary cancers of the upper aerodigestive tract, an important cause of death in survivors of more minor head and neck cancers¹⁵.

Late presentation of oral cancer is associated with poor survival rates for many reasons. Mainly, however, local and regional recurrence follows initial treatment¹⁶ or the disease is untreatable at the time of presentation¹⁷. Approximately 50% of patients that die from oral cancer die with local recurrence and 70% with neck metastasis. Regional metastasis with carotid erosion is the direct cause of death in approximately 10% of patients¹⁸.

If loco-regional failure can be improved, overall survival rates can also be improved. It is thought that one means of improving subsequent regional disease is the early treatment of neck metastasis¹⁹⁻²³ and this has brought about the concept of elective treatment of the neck.

THE CERVICAL LYMPH NODES IN HEAD AND NECK CANCER

Head and neck cancer spreads via lymphatics to the regional draining lymph nodes in the neck. This spread is thought to be embolic in nature²⁴. The presence of lymph node metastasis is one of the most important prognostic factors in head and neck cancer, decreasing five year survival by 50%, from approximately 90% in those patients with no lymph node disease to 40% for those with nodal metastasis²⁵. Reliable staging of the neck is important in determining appropriate management. If nodal metastasis is present, aggressive treatment protocols are followed²⁶, with the patient undergoing surgical ablation of the nodal basin and post operative external beam radiotherapy. However, if nodal metastasis is absent, by definition the patient does not require treatment of the regional nodal basin and can avoid surgery and radiotherapy. Accurate knowledge of the presence of nodal disease thus alters prognosis, staging information and disease management.

There is no accurate non surgical method for determining the presence or absence of nodal metastasis²⁷. The only consistently reliable means of detecting lymph node disease is by pathological examination of the lymph nodes. Physical examination of the neck is an unreliable means of assessing nodal involvement²⁸ as are radiological imaging techniques²⁹. These include computed tomography (CT), ultrasound scanning (USS), and magnetic

resonance imaging (MRI), all of which have recognised margins of error and their use as staging modalities remains controversial^{30,31}.

Neck staging using USS, MRI and CT assumes that large nodes are cancerous and small nodes are free of cancer³². Whilst this is generally true, other criteria used to assess the presence of tumour within lymph nodes include the presence of extracapsular spread and a heterogeneous attenuation within the node³³. The presence of these factors, even within small lymph nodes, would upstage the neck by radiological imaging³⁴. The size range of normal lymph nodes varies with the anatomical position of the node within the neck. The critical size for predicting tumour involvement is greater than 1cm except for level II nodes, the upper jugular region, where a critical size of 1.5cm is used^{35,36}.

By combining USS with fine needle aspiration cytology (USGFNAC) of the neck, the sensitivity of USS of the neck rises to 82%³⁷, however, to achieve these figures it is necessary for an experienced radiologist to perform the procedure³⁸ and structures immediately adjacent to bone and air lose definition on scanning.

In a recent meta-analysis of lymph node metastases detected by CT and clinical examination³⁹, Merritt and co-workers found that the sensitivity of CT scanning of the neck to identify a neck with nodal disease was 83%, whereas that for physical examination was 74%; the specificity of CT was 83%, whereas that for physical examination was 81%. MRI scanning adds little additional diagnostic information compared to CT scanning of the neck,^{30,40,41} but has the additional disadvantages of greater motion sensitivity, patient intolerance from claustrophobia, greater expense and time requirement and interference from metallic bodies.

Positron emission tomography (PET) with 18-fluorodeoxyglucose (18-FDG) has been used as a research tool since the early 1990's⁴². 18-FDG-PET scanning is a functional imaging technique, which relies on the greater metabolism of glucose by malignant cells than by normal cells. The increased metabolism by tumour cells is seen as an increased area of radioactivity during a PET scan. Potentially, PET scanning overcomes the inherent anatomical limits of imaging modalities such as CT, MRI and USS since small metastases may still be detected and large lymph nodes that do not contain tumour will not be highlighted as malignant. Reports on its success have been variable in detecting lymph node metastases. The sensitivity of PET varies from 50% - 100% and the specificity varies from 89% - 99%⁴³⁻⁵⁰. PET scanning has the advantage of being able to scan the whole body for distant as well as regional metastases. However, the sensitivity of PET scanning in melanoma when compared with sentinel node biopsy is only 17%⁵¹ because of the minute tumour volumes in the sentinel nodes of melanoma patients. Additionally, because of the prohibitive expense of the cyclotron required to generate the radiopharmaceuticals used during PET scans, the technique is only available in a few centres. In 2000, Scotland had a single PET scanner in Aberdeen, set up as research equipment and not for routine clinical use.

MANAGEMENT OF THE NECK

Approximately one-third of patients with cervical lymph nodes apparently free of tumour contain metastases in neck dissection specimens⁵². This varies with anatomical site, T-classification and tumour depth of invasion.

The treatment of early neck disease carries a better prognosis than the treatment of late neck disease⁵³.

Because of the high rate of occult nodal metastasis, and because the treatment of early nodal disease is prognostically better than the treatment of late nodal disease, a clinical decision to treat the neck electively is often made.^{54,55}

A "wait-and-see" approach to all patients with clinically clear necks would result in a high proportion of patients subsequently developing late stage, possibly unsalvageable, nodal disease, arising from their occult metastases⁵⁶. Conversely, performing neck dissections on all patients with clinically clear (N0) necks would lead to a high proportion of unnecessary lymph node dissections.

Finally, approximately 10-33% of clinically node positive patients are found to be free of tumour in the neck following a neck dissection and pathological examination of their lymph nodes^{57, 58}.

Thus, the management of the neck in patients with head and neck cancer is controversial

Current protocols for the management of the neck are locally determined⁵⁹. At Canniesburn Hospital, if the patient is medically fit enough to undergo a neck dissection, it will be performed for palpable lymphadenopathy or if it is thought that the chances of occult metastasis is greater than 20%; this includes patients with T1 tongue tumours with a maximum tumour thickness greater than 4 mm determined by initial incisional biopsy and for stage 2, 3 and 4 disease. Thus all patients with nodal metastases on palpation will undergo a therapeutic neck dissection, and patients who are thought likely to harbour covert metastases will undergo an elective neck dissection.

NECK DISSECTION

History credits Warren as first describing the excision of a neck carcinoma in 1847⁶⁰, Kocher first describing the excision of the submandibular lymph nodes in a case of tongue carcinoma⁶¹ and in 1888, the Polish surgeon Jawdyski described a procedure which detailed the removal of the cervical lymph nodes⁶². However, it was not until the neck dissection was first described in English by Crile in 1906⁶³ and later popularised by Martin in 1944⁶⁴ that the technique for surgical excision of the lymph nodes in the neck for a cancer gained acceptance.

Morbidity following a classical radical neck dissection (RND) can be fairly considerable^{65;66}, with complications including shoulder and neck pain and immobility, lymphocoele formation, wound complications and aesthetic imbalance⁶⁷. In addition, bilateral classical RND's will lead to severe plethora, facial oedema and poor neck movement⁶⁸⁻⁷⁰. Surgeons are reluctant to perform elective neck dissections for patients with suspected early disease to avoid unnecessary surgery, yet the treatment of early neck disease carries a better prognosis than the treatment of late neck disease⁵⁶. Accordingly, the decision to perform a radical lymph node dissection on a patient with no evidence of metastases can be difficult^{71;72}.

Surgical philosophy has evolved over the past few decades. Less radical surgery has developed to reduce morbidity and the surgical insult but be equally effective⁷³. Neck dissections have evolved in a similar way following its popularisation by Martin⁷⁴. Bocca described the functional neck dissection in 1980, realising that less radical surgery was not necessarily less effective⁷⁵.

The neck dissection procedure has been modified extensively since its original description by Crile to reduce morbidity and a host of

confusing terms applied to the variations. A review of neck dissection terminology was performed by Robbins^{76;77} in which he outlined the consensus report on neck dissection terminology by the American Academy of Otolaryngology – Head and Neck Surgery. These more accurate and descriptive terms are used throughout this Thesis and the terminology is summarised in tables 3 and 4. A radical neck dissection is the standard neck dissection from which all others are compared and is similar to that described by Crile and Martin. A modified radical neck dissection (MRND) is a neck dissection which excises the same lymph nodes as a radical neck dissection, but preserves one or more of the internal jugular vein, the sternocleidomastoid muscle and the spinal accessory nerve, usually removed in a radical neck dissection. A MRND is often used in patients with mobile lymphadenopathy. A selective neck dissection (SND) is one in which some of the nodes are deliberately left behind in the neck, a procedure often used in elective neck dissections. Finally, an extended neck dissection is one in which the nodal dissection goes beyond the nodal groups described by Crile and is often used when palpable lymphadenopathy is present outside the nodal areas of a radical neck dissection.

Radical neck dissection reduces quality of life for patients more than a MRND, which in turn is a greater burden than a SND⁷⁸. Shoulder dysfunction, in particular, is significantly worse following a RND compared with a MRND and SND and the more radical procedures are associated with greater pain post operatively.

The neck is divided into levels for convenience and to permit a common language for head and neck surgeons (Figure 2). Level I nodes are found in the submental and submandibular triangles, levels II, III and IV are the upper, middle and lower internal jugular chain of lymph nodes and level V is the posterior triangle. Level II is

further divided into level IIa and IIb. Level IIb is the area of the upper jugular lymph nodes bound inferiorly by the spinal accessory nerve and level IIa is defined as the nodes inferior to the spinal accessory nerve. Level IIb nodes are more difficult to excise in a neck dissection and there is controversy surrounding the need for its exploration during a neck dissection⁷⁹.

The consensus report on neck dissection terminology states that a RND is as described by Crile, excising the lymph nodes in levels I-V and including the spinal accessory nerve (SAN), sternocleidomastoid muscle (SCM) and internal jugular vein (IJV). A comprehensive neck dissection is one which removes all draining nodal tissue. Those procedures in which levels I-V are excised but one or more of the three non-lymphatic structures are spared are called modified radical neck dissections (MRND). A neck dissection which excises nodal tissue beyond levels I-V is termed an extended RND. A neck dissection which leaves one or more of the nodal tissue from levels I-V within the neck is called a selective neck dissection, and usually spares the IJV, SAN and SCM. Selective neck dissections may be described according to the levels that are removed or may be termed descriptively.

Controversies exist amongst clinicians as to which type of neck dissection is most appropriate for varying disease patterns. The management of the clinically NO neck⁶⁷ is more controversial than that of the clinically N+ neck⁸⁰. The more radical the dissection, the greater the likelihood of significant morbidity arising from the procedure⁸¹. Conversely, the less nodal tissue removed, the more likely it is to leave nodal tissue possibly infiltrated with malignancy⁸². Also, sparing of non-nodal structures is technically more demanding than a traditional RND, and therefore increases the time spent by the patient under general anaesthesia. Cadaveric studies which have

detailed anatomical drainage pathways of the mucosa of the head and neck⁸³ as well as retrospective clinical data⁸⁴ suggest that an elective lymph node dissection clearing levels I-III will remove the lymph nodes most at risk of harbouring occult metastasis for oral cancers²⁶. Additionally, retrospective studies examining the patterns of lymph node metastases in head and neck cancer have confirmed the rarity of nodal disease within levels IV and V in cases where nodal involvement of levels I-III is absent⁸⁵. This is confirmed clinically, where tumour recurrence has been found to be approximately 5% following a SOHND for clinically N0 disease⁸⁶.

At Canniesburn Hospital, suspected malignancy is treated, if possible, with an MRND-III (Figure 3, Table 5) and a level I-IV selective neck dissection is often used as a staging procedure. Sparing of as many non-nodal structures as possible for functional preservation remains one of the principles of the Canniesburn management philosophy, especially in the management of the clinically N0 neck.

SENTINEL NODE BIOPSY

The sentinel node concept (Figure 4) states that when a tumour metastasises via lymphatics, it does so firstly to one of the lymph nodes directly draining the tumour⁸⁷. These lymph nodes are termed the sentinel nodes and these nodes are the first echelon lymph nodes in the regional lymph node basin draining that particular tumour⁸⁸. There may be one or several sentinel nodes for a patient and a particular tumour. For clarity and to avoid clumsy terminology, hereafter sentinel nodes will be referred to in the singular, acknowledging that several sentinel nodes may be found in one patient.

The concept also states that if the sentinel node can be identified and retrieved, and if detailed pathological examination of the sentinel node is performed, it will be a true reflector of the positivity or negativity of the presence of lymph node metastases in the regional drainage basin⁸⁹. A sentinel node free of tumour indicates the lack of regional tumour metastases.

By implication, it can be seen that a patient with a carcinoma need only undergo sampling of the sentinel node to determine the presence or absence of lymph node metastases, rather than a formal regional lymph node dissection. The concept is illustrated in Figure 4.

HISTORY OF SENTINEL NODE BIOPSY

The sentinel node concept was first postulated by Gould in 1960 in a presentation to the James Ewing Society, the forerunner of the Society of Surgical Oncology. He suggested that parotid cancers spread initially to what he termed an "angular node" located at the junction of the anterior and posterior facial veins, and that this lymph node could be sampled for frozen section histological analysis (Figure 5). The absence of metastasis in this node would negate the need for further treatment or investigation of the regional lymph nodes.

The sentinel node concept was revisited by Cabanas in 1977⁹⁰, unaware of Gould's previous experience. His work on penile SCC permitted the identification of the site of the first draining lymph nodes in the groin from a primary carcinoma on the skin of the penis. Cabanas found the position of the sentinel node by performing lymphoscintigraphy of the dorsal penile lymphatics. The nodal group was identified near the superficial epigastric vein in the groin and the recommendation of Cabanas was selective lymphadenectomy of this group of nodes to determine the presence or absence of lymph node

metastases. Cabanas' work fell into disrepute after further studies highlighted the unreliability of the sentinel node as a predictor of the remaining basin, with reports of false negative results, and criticism of his follow-up methodology⁹¹⁻⁹⁴.

It was not until 1992 when Morton described a technique for identifying the sentinel node in cutaneous malignant melanoma (MM)⁹⁵, following experimental work in a feline model⁹⁶, that the concept of sentinel node biopsy became more firmly established. Morton's fundamental conceptual difference was that the location of the sentinel node was dependant on the individual's lymphatic drainage pattern and the site of the primary malignancy. Unlike Gould and Cabanas, Morton suggested that the position of the sentinel node varied with each individual and that a tracer injection would be required for each patient undergoing the procedure.

The sentinel node was successfully identified, after a learning curve, by injection of a vital blue dye (lymphazurin blue or Patent Blue V, Figure 6) into the dermis around the excised tumour, following blue stained lymphatics to the first lymph node and harvesting that node for routine and immunohistochemical histological evaluation. For areas of equivocal lymph drainage, a radiocolloid was injected pre-operatively to identify the regional basin by lymphoscintigraphy. Subsequent work at the Moffit Cancer Institute in Florida showed that the sentinel node was a highly accurate reflector of the remaining lymph node basin and that melanoma metastases progressed through the regional lymph nodes in an orderly manner⁹⁷.

The method described by Morton for sentinel node biopsy in malignant melanoma was subsequently adapted to improve the detection of potentially elusive nodes. Originally, per-operative blue dye injection was used to identify sentinel nodes and in cases where there was equivocal lymphatic drainage of the primary tumour,

Morton's team used pre-operative lymphoscintigraphy to identify the drainage basin. However, even when using pre-operative lymphoscintigraphy, difficulties with this procedure arose when blue stained lymphatics were not visualised. Intra-operative use of a hand held gamma counter (Figure 7) was shown to be an alternative means to identify the sentinel node in humans⁹⁸, following work on a feline model⁹⁸. The accepted current method for sentinel node biopsy involves the administration of both blue dye and radiocolloid, especially in head and neck melanoma⁹⁹. When using 99m-Tc labelled colloids in the sentinel node procedure, radiation doses to surgeons and pathologists are documented as being minimal¹⁰⁰⁻¹⁰². Since its successful application in cutaneous melanoma, the technique has been applied to a host of different tumours. In particular in breast carcinoma, where the technique was first described in 1993 by Krag¹⁰³, the sentinel node concept has been extensively studied. Other tumours which have been investigated with sentinel node biopsies include: Merkel cell tumours¹⁰⁴⁻¹¹¹, colorectal carcinoma¹¹²⁻¹¹⁵, vulval cancer¹¹⁶⁻¹²⁹, penile carcinoma¹³⁰, cutaneous lymphoma¹³¹ and cutaneous squamous cell carcinoma¹³².

LYMPHOSCINTIGRAPHY IN SENTINEL NODE BIOPSY

Lymphoscintigraphy and gamma probe guided localisation have emerged as useful additional techniques for identification of the sentinel node, since Morton's original description with blue dye alone¹³³⁻¹³⁵. A radioisotope labelled colloid is injected into or around a tumour or its excision site; in the case of lymphoscintigraphy, a scintillation counter is used to identify areas of radioactivity within the regional lymph node basin and in the case of gamma probe localisation, a small hand held Geiger counter isolates radioactive

lymph nodes during surgery. The use of a radiocolloid does not prevent the use of blue dye.

Dynamic lymphoscintigraphy produces real time images of radiocolloid as it passes through lymphatic vessels to sentinel lymph nodes and static lymphoscintigraphy permits the identification and localisation of lymph nodes where the colloid collects¹³⁶⁻¹³⁸. The investigation, when used in conjunction with a 99m-Technetium (^{99m}Tc) labelled colloid, is performed up to 24 hours prior to surgery, although the exact timing is a matter of debate¹³⁹. In gamma probe guided surgery, a hand held radioactivity detector, such as the Neoprobe[®] (Neoprobe Corp, Dublin, Ohio, USA) is used to locate radioactive lymph nodes within the operating field for excision.

Different radioactive colloids have varying pharmacokinetic and pharmacodynamic properties but no available radiocolloid achieves the properties of the ideal colloid¹⁴⁰. Small diameter colloids easily enter the terminal lymphatics and travel quickly to the sentinel node. However they are likely to pass from the sentinel node to second, third and subsequent echelon lymph nodes¹⁴¹. Examples of small diameter colloids include Nanocoll (with a mean particle size diameter of 80nm), Filtered Sulphur Colloid (mean particle size diameter of 200nm) and Antimony Sulphur Colloid (5nm mean particle size diameter). Nanocoll is available in the European Community, Filtered Sulphur Colloid is available in the United States of America and Antimony Sulphur Colloid is available in Australia. Conversely, a large diameter colloid is slow moving, and so remains within the first echelon lymph node. However, the colloid is less likely to pass into lymphatic vessels. Examples of large diameter colloids include Albures, and Unfiltered Sulphur Colloid, with mean particle size diameters of 500nm. Currently, Albures is only available in the

European Community and Sulphur Colloid is only available in the USA.

Until the ideal colloid is developed the arguments for using different colloids will persist. Two radiocolloids of human serum albumin were available for use in this study: Albures and Nanocoll.

THE SENTINEL NODE IN HEAD AND NECK CARCINOMA

Prior to the start of this study, initial results of the sentinel node procedure in head and neck cancer had been reported with mixed success. Pitman et al were unable to find any blue nodes in patients injected with blue dye alone¹⁴², and in a series of five cases using radiocolloid alone, Koch et al remained unconvinced of its role in the management of head and neck cancer patients¹⁴³. The first case report of a successful sentinel node biopsy in head and neck cancer using radiocolloid to trace the first echelon node was performed in 1996 by Alex and Krag on a patient with a supraglottic carcinoma¹⁴⁴ and in 1998, Bilchik et al reported the use of sentinel node biopsy in a variety of neoplasms, including five patients with head and neck cancer¹⁴⁵.

Since lymph node metastasis in Head and Neck carcinoma is thought to be embolic in nature, the concept of identifying the first node to which the tumour spreads, harvesting and subsequently examining that node in detail for the presence or absence of metastasis and using this as an indicator for the remaining cervical nodes is an appealing prospect. The technical aspects of the procedure require validation.

LYMPH NODE HISTOPATHOLOGY IN HEAD AND NECK CARCINOMA

Lymph node metastasis is initially seen at the subcapsular sinus of pathologically involved lymph nodes (Figure 8)¹⁴⁶. Flow of lymph and cancer cells within the lymph node is then directed to the more central regions of the node¹⁴⁷. As the node becomes infiltrated with carcinoma, a response to the tumour cells is thought to occur and the lymph node undergoes reactive enlargement^{148;149}. Multiple serial sections of a node will identify a greater proportion of nodes with metastatic disease¹⁵⁰, and the greater the search for cancer cells, the greater the chance of finding them. Following a lymph node neck dissection, approximately 20-30 nodes on average are removed from the regional basin⁸². Each node requires examination. The method for routine pathological examination of lymph nodes can vary between institutes. In the Oral Pathology Unit at the Glasgow Dental Hospital and School, lymph nodes from a neck dissection specimen are bisected through their hilum or largest diameter if the hilum is not obvious. One half of the node is processed and cut for routine staining with Haematoxylin and Eosin (H&E). Microscopic examination of the bisected node is used to detect squamous cells, which initially manifest themselves at the peripheral sinus. Greater sampling of the node and the use of immunohistochemistry will lead to greater detection of lymph node metastases and will upstage the neck of the patient from N0 to N+ in approximately 10%^{151;152}. However, it is not known whether this is prognostically significant, when performed in the context of a neck dissection^{148;153}. In other carcinomas, however, applying special staining techniques to multiple blocks of the sentinel node is a requirement to accurately examine the sentinel node¹⁵⁴.

AIMS

The sentinel node concept is an attractive one to apply to head and neck cancer. The main aim of this study was to develop a standardised, effective and reproducible technique for sentinel node biopsy in head and neck cancer. Specifically, the aims were:

- To formulate a method for the identification of the sentinel lymph node in patients with squamous cell carcinoma or malignant melanoma affecting accessible areas of the upper aerodigestive tract.
- To determine whether sentinel node biopsy can be used as a means to accurately determine the presence or absence of lymph node metastases in patients with oral cancer.
- To map the anatomical site of the sentinel node in head and neck carcinoma in a graphical format for various sites of primary lesion.
- To perform sentinel node biopsy on patients undergoing no elective treatment to the neck, after refinement of the initial methodology.

TABLES AND FIGURES

Figure 1: Incidence of Oral Cancer in Scotland 1975-1996

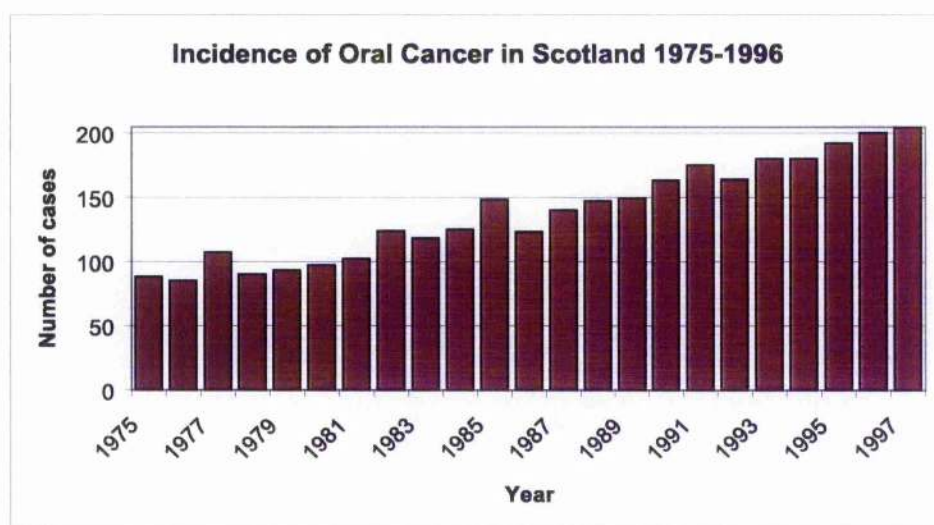


Figure 2: Neck Dissection Levels

(original in colour)

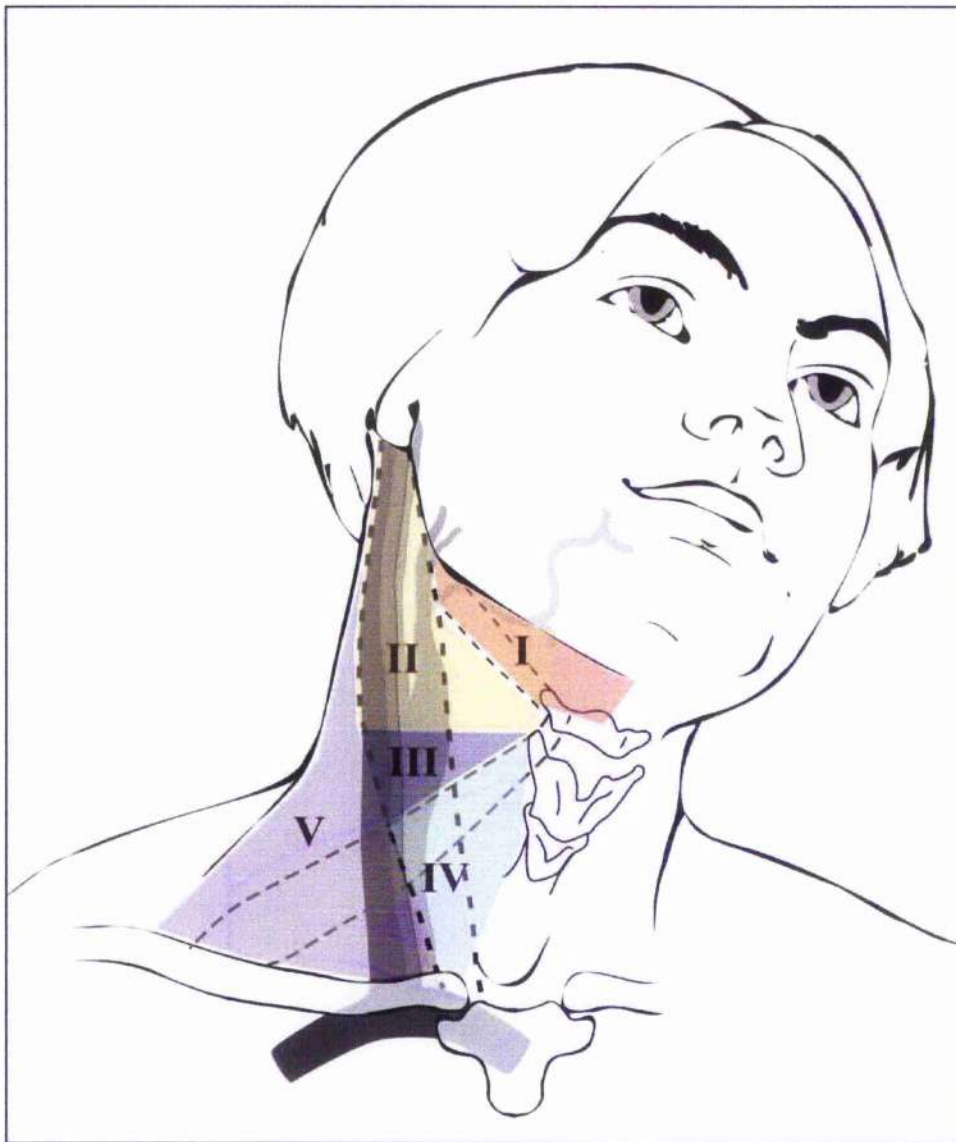


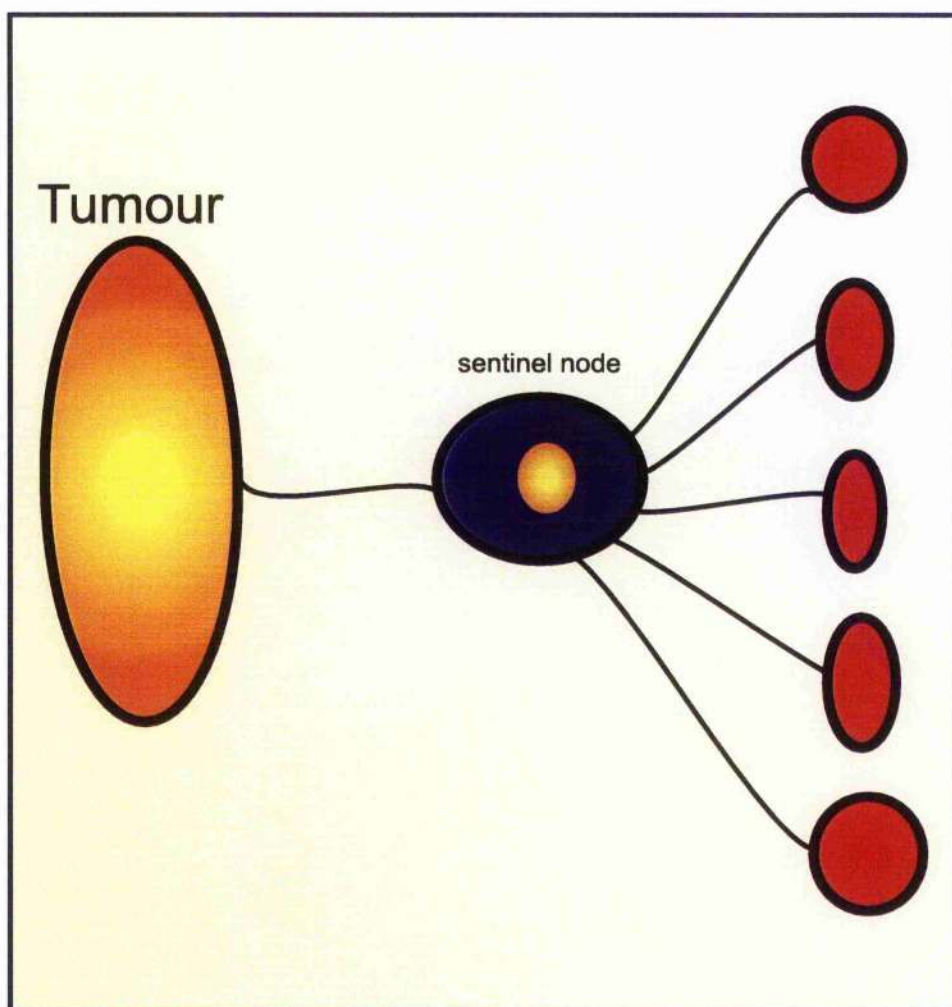
Figure 3: An MRND-III. The specimen has been marked to indicate the dissection levels.

(original in colour)

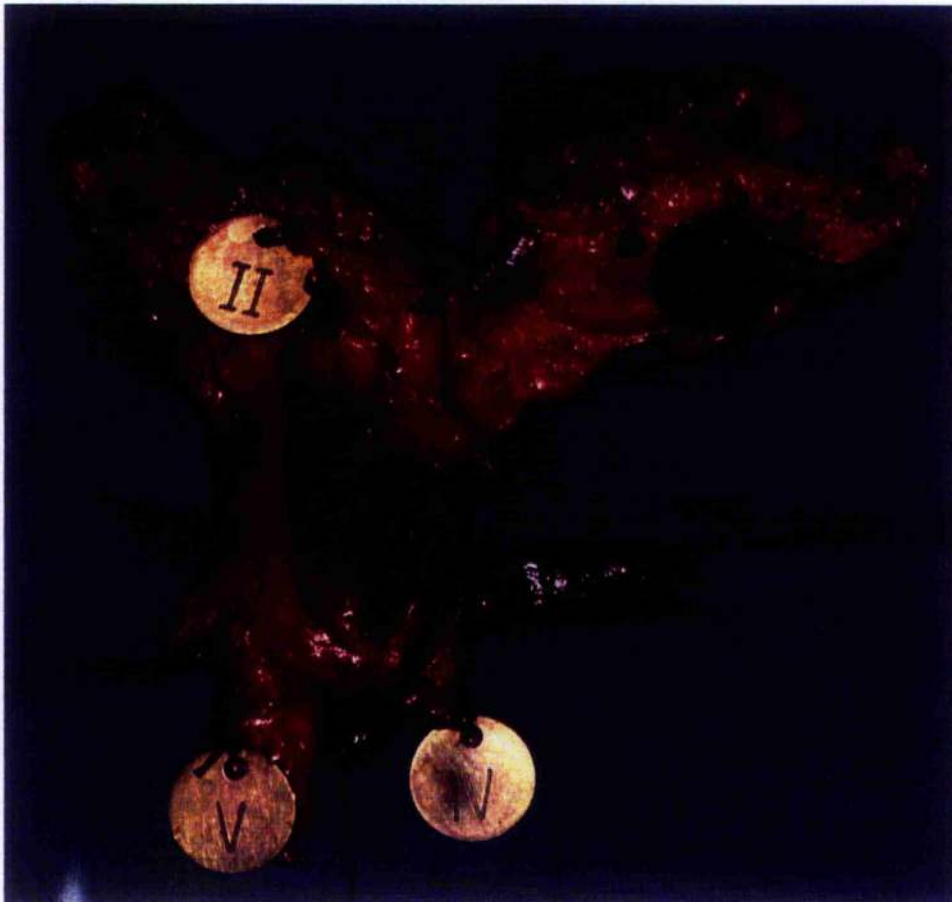

Figure 4 : The sentinel node concept

(original in colour)



**Figure 5: Patient with parotid malignancy and nodal metastases
in the angular node**

(original in colour)

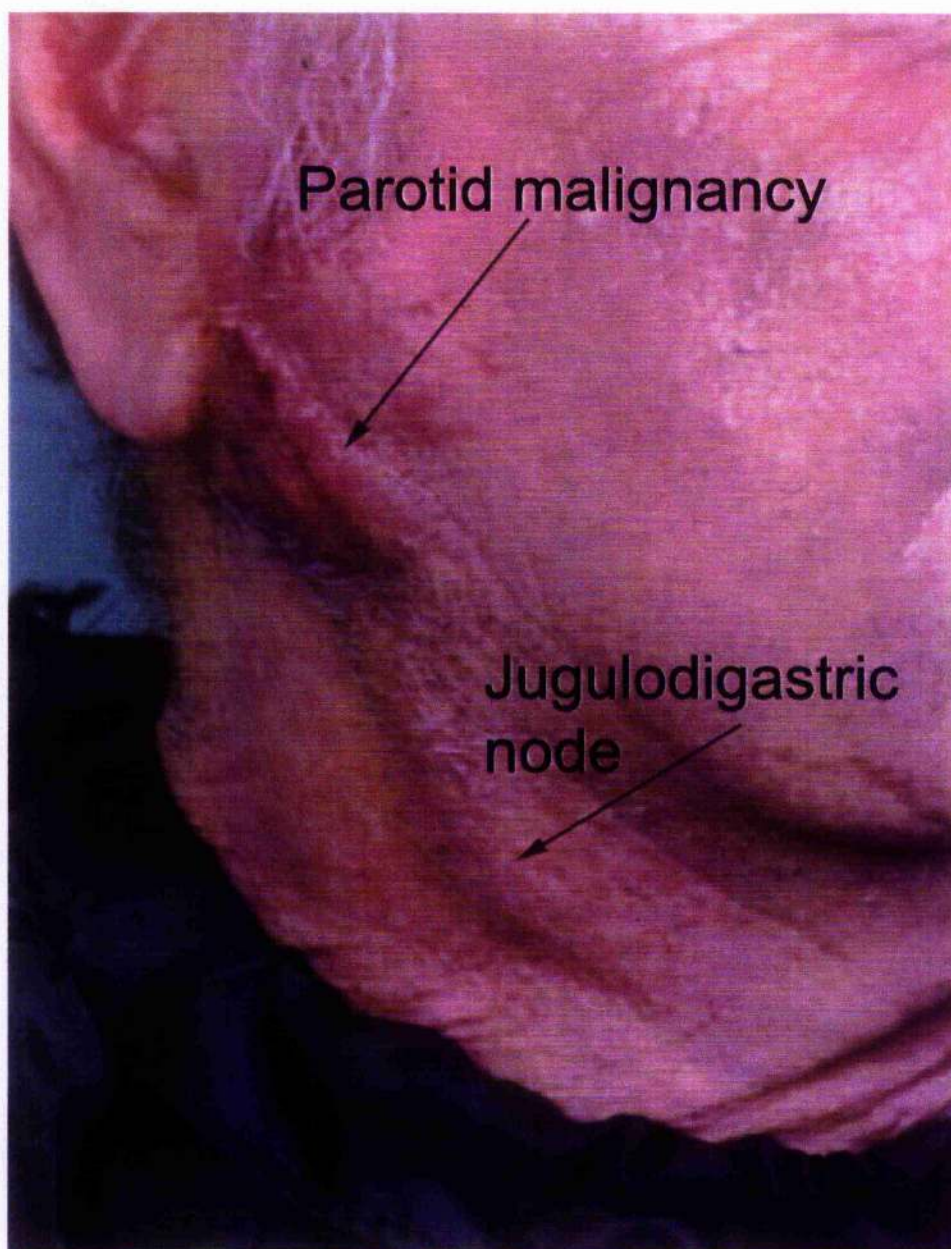


Figure 6: Patent Blue V Dye

(original in colour)

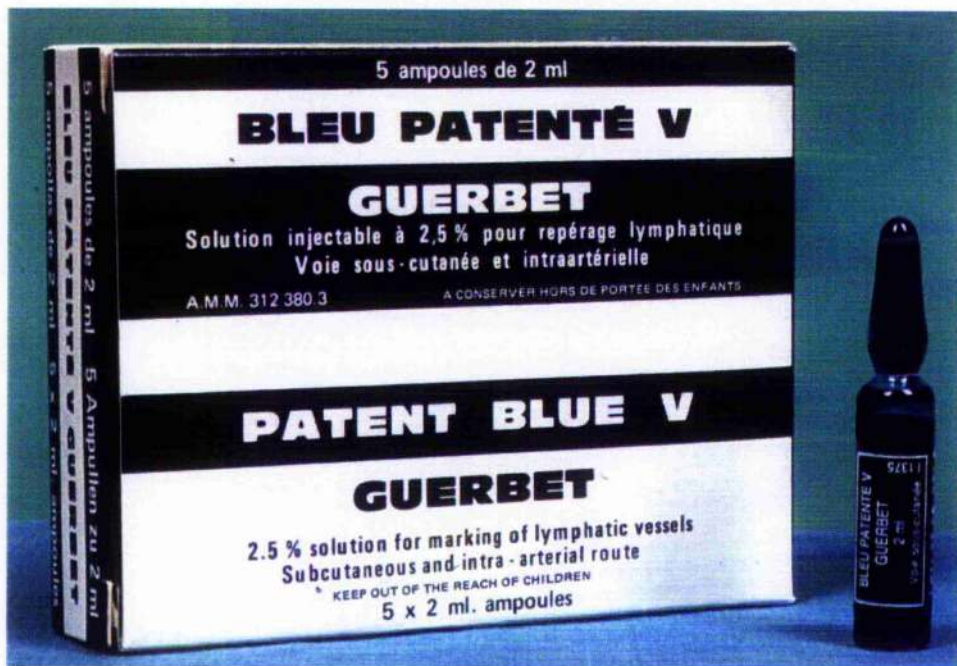

Figure 7: The Neoprobe 1500 and probes

(original in colour)

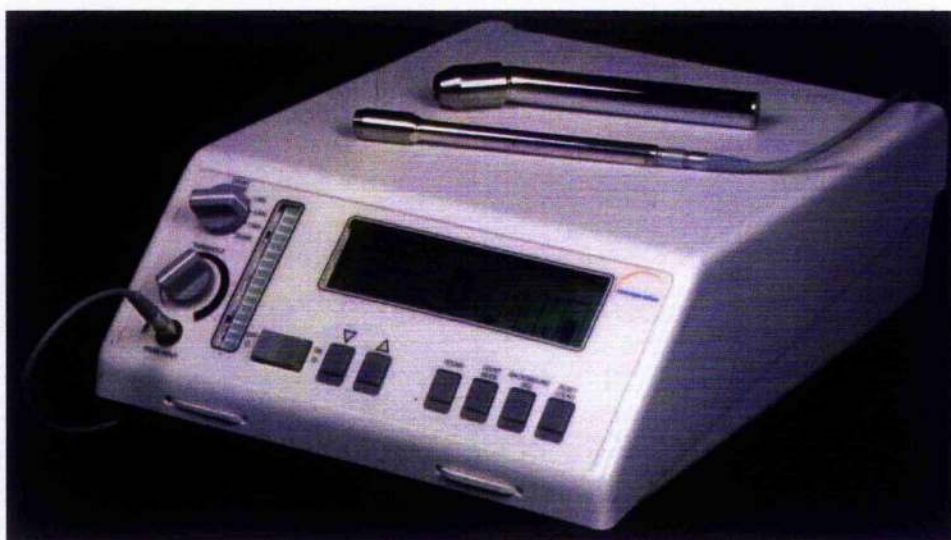

Figure 8: Metastatic disease in the subcapsular sinus of a lymph node

(original in colour)

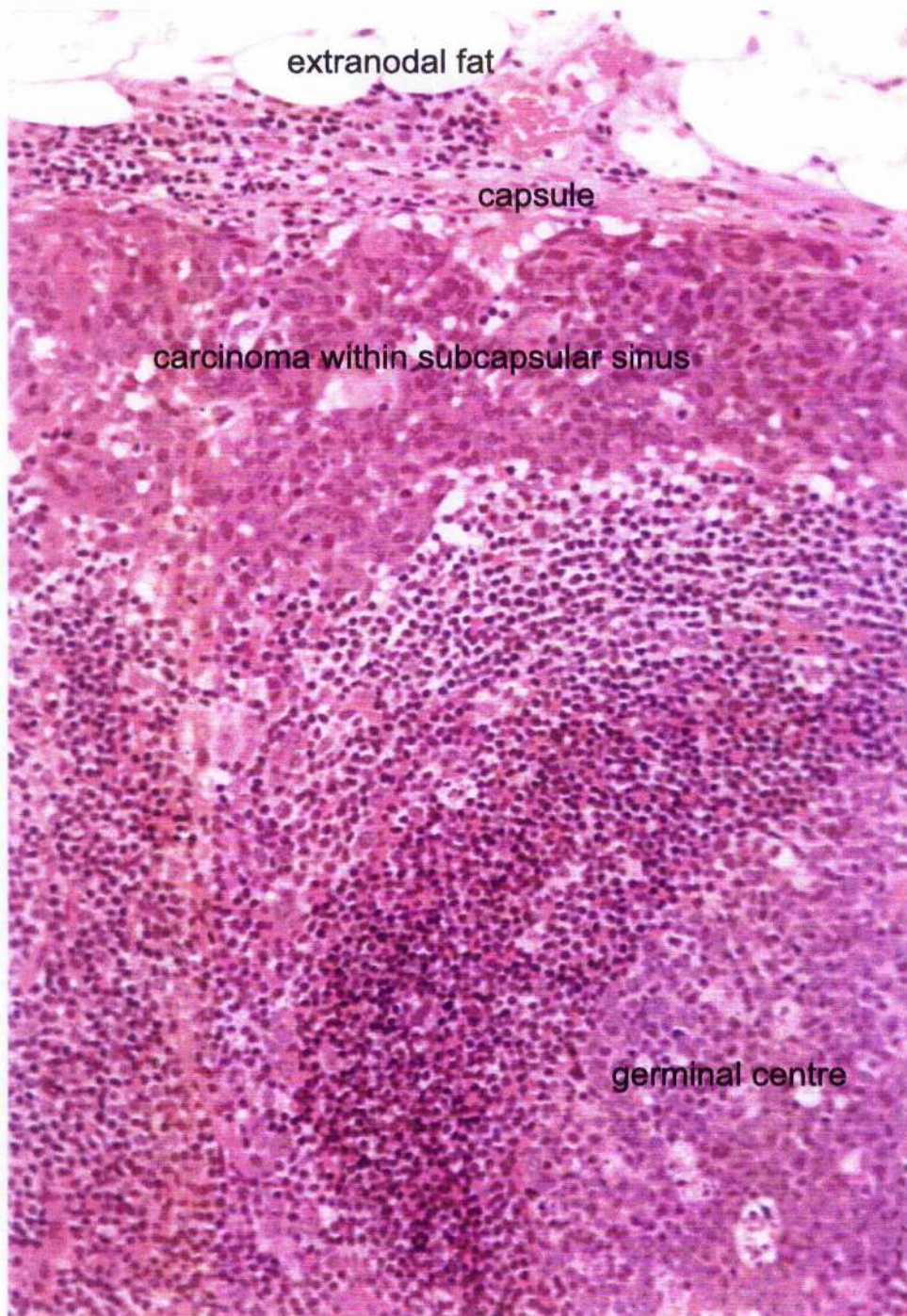


Table 1: ICD-9 codes for head and neck cancer

140	Malignant neoplasm of lip
141	Malignant neoplasm of tongue
142	Malignant neoplasm of major salivary glands
143	Malignant neoplasm of gum
144	Malignant neoplasm of floor of mouth
145	Malignant neoplasm of other and unspecified parts of mouth
146	Malignant neoplasm of oropharynx
147	Malignant neoplasm of nasopharynx
148	Malignant neoplasm of hypopharynx
149	Malignant neoplasm of other and ill-defined sites within the lip, oral cavity, and pharynx
150	Malignant neoplasm of oesophagus
160	Malignant neoplasm of nasal cavities, middle ear, and accessory sinuses
161	Malignant neoplasm of larynx
193	Malignant neoplasm of thyroid gland

Table 2: TNM clinical staging of SCC of the oral cavity and oropharynx¹⁵⁵.

T	x	Tumour size cannot be assessed, e.g. unknown primary
	is	Carcinoma in-situ
	1	Tumour size ≤2cm
	2	Tumour size 2-4cm
	3	Tumour size >4cm
	4	Tumour invading deeper structures
N	x	Regional lymph node status cannot be assessed
	0	No nodal metastases
	1	Metastasis in single ipsilateral node, ≤3cm in greatest dimension
	2a	Metastasis in single ipsilateral node >3cm but ≤6cm in greatest dimension
	2b	Metastases in multiple ipsilateral nodes, none >6cm
	2c	Metastases in bilateral or contralateral nodes, none >6cm
	3	Metastasis in a node >6cm in maximum dimension
M	x	Distant metastases cannot be assessed
	0	No distant metastases
	1	Distant metastases present

Table 3: Stage Grouping

Stage I	T1N0M0
Stage II	T2N0M0
Stage III	T3N0M0, T1/2/3N1M0
Stage IV	T4N0M0, T4N1M0, anyTN2/3M0, anyT anyN M1

Table 4: Neck dissection levels

Level of Neck Dissection	Anatomical Description
I	Submandibular triangle and submental triangle. Anatomical borders: lower border of the mandible and the bellies of the digastric muscle; hyoid bone and the midline.
II	Upper jugular nodes. Anatomical borders: skull base to bifurcation of common carotid artery at the level of the hyoid bone; lateral border of sternohyoid muscle to posterior border of sternocleidomastoid.
III	Middle jugular: Anatomical borders: inferior border of level II to the omohyoid muscle at the level of the cricothyroid membrane; lateral border of sternohyoid muscle to posterior border of sternocleidomastoid.
IV	Lower jugular: Anatomical borders: from the inferior border of level III to the clavicle; lateral border of sternohyoid muscle to posterior border of sternocleidomastoid.
V	Posterior triangle

Table 5: Neck Dissection Terminology

Terminology	Description
RND	Radical neck dissection excising levels I-V, including the SAN, IJV and SCM
MRND-I	Excising levels I-V, including the IJV and SCM
MRND-II	Excising levels I-V, including the IJV
MRND-III	Excising levels I-V, all three non-lymphatic structures spared
Extended Neck Dissection	Excision of levels I-V with further dissection continued to deeper structures (e.g. pharyngo-laryngeal nodes, tracheo-oesophageal nodes, parotid nodes, etc)
Selective Neck Dissection	Excision of up to four levels of cervical nodes, usually sparing some or all non-lymphatic structures
SOHND	Supraomohyoid neck dissection, excising levels I-III, sparing all non-lymphatic structures
Anterolateral Neck Dissection	Excision of levels II-IV
Posterolateral Neck Dissection	Excision of levels II-V

Table 6: Properties of the ideal colloid¹⁴⁰

Licensed product
Narrow particle size range
^{99m} Tc label
Stable on storage
Lymph channel transport
Rapid transport
Retention in sentinel node
Stable in blood (no shrinkage or growth)

CHAPTER 2: INITIAL METHOD WITH BLUE DYE ALONE

INTRODUCTION

The original method for sentinel node biopsy in the field of cutaneous malignant melanoma described a technique using blue dye alone⁹⁵. The dermis surrounding the melanoma or the site of excision biopsy was injected with blue dye. An incision was made into the regional lymph node basin and blue stained lymphatics were followed to blue stained lymph nodes. In areas of the skin with uncertain lymphatic drainage, preoperative lymphoscintigraphy identified the nodal basin to be explored. Using the blue dye technique, sentinel node biopsy was found to be a reliable method for identifying sentinel nodes in regional lymph node basins. The technique using blue dye alone has been used for both melanoma and breast cancer. In a study of cutaneous head and neck melanoma sentinel node biopsy, blue dye was used to locate a sentinel node in 90% of cases¹⁵⁶.

Our initial study was performed to investigate the possibility of performing sentinel node biopsy with blue dye alone, in patients with squamous carcinoma of the head and neck. The aims of the study were to determine whether the sentinel node was identifiable following blue dye injection and to determine if the absence of tumour within the sentinel node implied the absence of tumour within the whole lymph node basin.

MATERIALS AND METHODS

Patients undergoing a neck dissection as part of the surgical treatment for histologically proven single focus primary SCC, were invited to enter the study between April 1998 and July 1998. All patients had biopsy confirmed SCC and had undergone examination

of the tumour and neck under anaesthesia for assessment of clinical stage, resectability and the presence of multi-focal disease.

At operation a tri-radiate incision was made in the neck and subplatysmal skin flaps raised (Figure 9). 0.5-1.0 ml of Patent Blue V dye (Laboratoire Guerbet, Aulnay-Sous-Bois, France) was then injected throughout the normal mucosa and submucosa surrounding the tumour. If the sternomastoid muscle was to be preserved, this was separated from its investing fascia and retracted posteriorly to expose the deep cervical chain of lymph nodes. Blue stained lymphatics, if seen, were followed to a blue lymph node, which was harvested. The remainder of the neck dissection then continued as normal. Following the procedure the dissected specimen and the neck wound bed were examined for residual blue dye in an attempt to ensure the successful harvesting of all blue stained sentinel nodes. Dissected neck specimens were marked for orientation by the pathologist and placed in formalin.

The sentinel nodes were fixed in 10% neutral buffered formalin and after fixation were bisected through the hilum or largest diameter if the hilum was not identifiable. As per the departmental policy for examining lymph nodes from regional lymph node dissection specimens, if the thickness of the halves was more than approximately 2mm the slices were further trimmed to provide additional 2mm thick blocks, thereby increasing the chance of finding metastatic tumour. The remainder of the neck specimen was dissected and all nodes over approximately 2.5mm in maximum diameter were identified in their anatomic groups. Each node was bisected and one half was processed for histological examination. One H&E stained section was prepared from each block and was examined for the presence of nodal involvement by tumour.

RESULTS

16 necks were explored for sentinel nodes. Each neck side was considered a single case. Eight cases were classified clinically as N0 and eight were clinically involved with tumour (N+).

In the N0 group, four cases were pathologically N0 (pN0) and four were pathologically involved with metastases (pN+). In the pN0 group, a single sentinel node was found in each of the four necks, and the sentinel node was free of tumour (by definition). In the clinically N0 group that was pN+, a sentinel node was found in two cases, but no tumour was found in the sentinel nodes when examined using conventional histology.

In the N+ group, seven cases were confirmed as pN+ and one case was pN0. In the pN+ group, a sentinel node was found in one neck, and did not contain tumour. In the pN0 case no sentinel node was found.

In all cases, when the neck dissection specimen was examined *ex-vivo* for further evidence of blue nodes, none were seen. Additionally, no blue stained lymphatics were seen in the neck following completion of the surgical procedure.

In summary, sentinel nodes, identifiable by blue dye alone, were found in seven cases out of 16 and no sentinel node contained tumour, despite the presence of nearby metastasis in 11.

DISCUSSION

This study was undertaken to determine whether blue dye sentinel node biopsy could be used as a method of identifying sentinel nodes in the neck for head and neck cancer patients. The technique of using Patent Blue V dye alone was unsuccessful not only in the identification of sentinel nodes within the neck in all patients but also

in identifying involved sentinel nodes in the presence of neck metastasis.

The main difficulty encountered with the blue dye technique was in failing to identify blue nodes and blue lymphatics. Since these were not identified in the majority of cases, the majority of first echelon nodes were not harvested. When sentinel nodes were seen and harvested, the blue nodes did not reflect the pathology of the neck.

The reasons for this failure could have been in the surgical technique or the pathological technique.

Blue nodes could have been present in the neck, but may have been missed during the biopsy part of the procedure. Only seven sentinel nodes were identified in our initial study, and sentinel nodes were not seen in nine cases – clearly all first echelon nodes were not identified in all necks. Even in cases where a sentinel node was found, other first echelon nodes remained unidentified and false negative results were obtained.

The sentinel nodes identified may have contained small deposits of tumour, but not in the sections examined histologically. In melanoma and breast cancer sentinel node biopsy, the sentinel node is only an accurate reflector of the regional nodal basin when it is examined in detail¹⁵⁷⁻¹⁵⁹. This may or may not be the case in head and neck cancer sentinel node biopsy, however, in order to determine whether this were true, sentinel node biopsy was subsequently performed using a radiocolloid tracer in addition to blue dye to determine whether the reason for failure was the failure to see the blue sentinel nodes.

Although the technique for sentinel node biopsy using blue dye alone has been used successfully in melanoma and breast cancer^{160;161}, the technique in head and neck cancer may be more technically

demanding. The fibrofatty tissues of the axilla and groin, where lymph nodes are located, are relatively easy to explore. Both regions have fewer structures of vital importance than the neck and it may be that dissection of the fibrofatty parenchyma of the groin and axilla, searching for blue stained lymphatics, is more straightforward than exploration of the neck.

Injection of blue dye is simpler for cutaneous lesions, where there is a well defined and semi rigid dermis with abundant lymphatic concentration. No such layer exists for mucosa and blue dye can be taken up by the venous drainage rather than the lymphatic drainage.

Pathologically involved nodes may not take up blue dye because the increase in hydrostatic pressure as a result of tumour metastases diverts lymphatic flow to non-involved nodes.

There is a well recognised learning curve for sentinel node biopsy in cutaneous melanoma. If a single surgeon compares the rate of sentinel node identification in his first 30 cases with that of his subsequent 30 cases, he will see an increase. The learning curve flattens after this number of cases and so it has been suggested that approximately 30 cases should be performed by surgeons learning the procedure¹⁶²⁻¹⁶⁵, although the exact figure varies with individual surgeons, type of cancer and technique used for sentinel node biopsy.

Our experience with blue dye alone was our first experience with sentinel node biopsy in head and neck cancer. In view of the learning curve, another reason for failure could have been the inexperience of the team performing the sentinel node biopsies.

With initial failure, the literature was searched to determine the methods employed by other groups to improve sentinel node retrieval and accuracy rates. In particular, Albertini reported that the use of

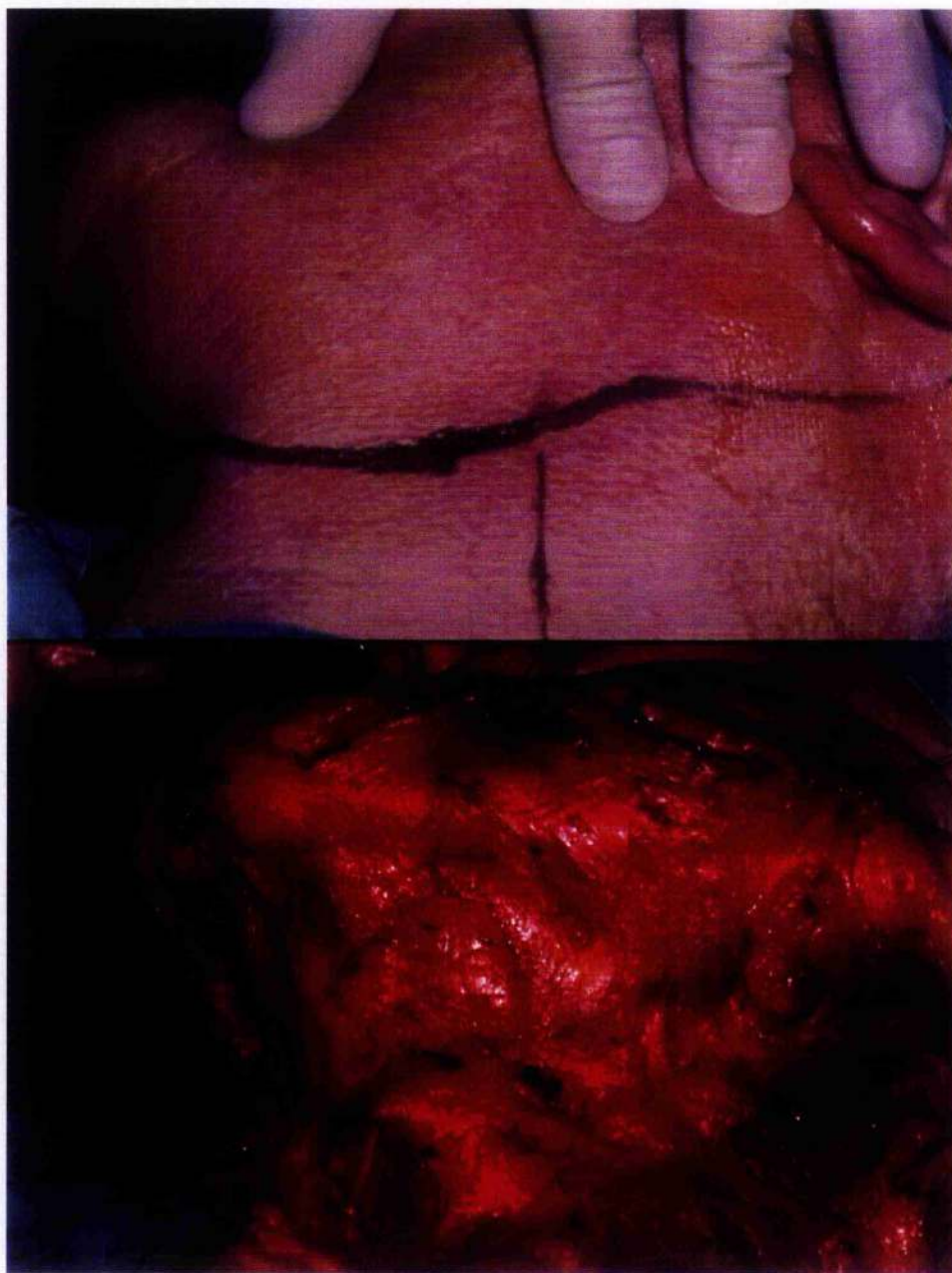
radiocolloid injection with blue dye increased sentinel node identification rates from 70% to 96% in melanoma patients who underwent preoperative lymphoscintigraphy and the use of a hand held gamma probe¹⁶⁶. Additionally, Morton, who first described the sentinel node technique, recommended the combination of blue dye and radiocolloid use in cutaneous head and neck melanoma sentinel node biopsy¹⁶⁷, despite initially performing sentinel node biopsy using blue dye alone.

Accordingly, the technique used to identify the sentinel nodes in head and neck cancer was modified to include pre-operative radiocolloid injection and lymphoscintigraphy, following an application to the Department of Health for a certificate from the Administration of Radioactive Substances Approval Committee (ARSAC).

TABLES AND FIGURES

Figure 9: Skin flap raising during a neck dissection

(original in colour)



CHAPTER 3: CHOICE OF COLLOID IN HEAD AND NECK CANCER SENTINEL NODE BIOPSY

INTRODUCTION

Following the initial failure of sentinel node biopsy with blue dye alone, it was decided to perform sentinel node biopsy using additionally radiocolloid injection and lymphoscintigraphy.

Sentinel node biopsy in breast cancer and melanoma has been shown to be more effective and reliable when using a combination of blue dye and radiocolloid¹⁶⁸. In particular, in head and neck melanoma sentinel node biopsy, where sentinel nodes are located in the neck, routine use of pre-operative lymphoscintigraphy and the intraoperative use of the hand held gamma probe leads to successful identification of the sentinel node^{169,170} more often than when blue dye alone is used. Sentinel node biopsy of mucosal cancer of the head and neck had not been investigated with success or in a reasonable population group, prior to our study, and in order to perform the technique using radiocolloid in addition to blue dye a technique was developed and subsequently refined during the course of the period of study.

Two colloids are available for lymphoscintigraphy in the UK: Nanocoll and Albures¹⁴¹. Albures has a mean diameter particle size of 500nm and passes slowly from the interstitium to the lymphatic vessels and thence to sentinel nodes, but remains within the first echelon node. Nanocoll has a mean diameter particle size of 80nm, passes quickly from interstitium to the lymphatic vessels but passes from first echelon node to non-sentinel nodes in the regional lymph node basin¹⁷¹.

In melanoma and breast cancer sentinel node biopsy (Figure 10), choice of colloid remains a continuing debate¹⁷²⁻¹⁷⁵. In the UK and Europe, the choice remains between Albures and Nanocoll.

In our study of head and neck cancer sentinel node biopsy, Albures was chosen as the colloid to inject initially, and later in the study, Nanocoll was introduced to specific sub-groups of cases when initial results with Albures were disappointing. The aim of this part of the study was to develop a technique to locate and to determine which colloid should be used to locate sentinel nodes in the neck. The end point of the study was the presence or absence of radioactivity in the sentinel lymph nodes harvested from the neck, as this was thought to be a reflection of the ability of radiocolloid to pass from the interstitium of the injected tissue into the lymphatic vessels and thence the lymph nodes in the regional draining basin.

METHODS

Patients undergoing prophylactic or therapeutic neck dissections for oral cancers between July 1998 and March 2000 were invited to enter our study to perform a sentinel node biopsy in addition to a neck dissection.

Prior to surgery, patients were transferred from the regional Plastic Surgery Unit at Canniesburn Hospital and attended the Nuclear Medicine Department at the Glasgow Royal Infirmary for lymphoscintigraphy to identify regional lymph node drainage. Because of the distance between the two units, this was performed the day prior to surgery.

LYMPHOSCINTIGRAPHY

The patient was offered a local anaesthetic spray if oral pain from the carcinoma pre-existed, and up to 40MBq of Tc-99m-labelled Albures

or Nanocoll was injected into the tissues surrounding the tumour, on both the deep and lateral aspects in an attempt to completely surround the tumour. Colloid was drawn up into an insulin syringe in a 2ml solution. The patient was given a mouthwash with which to rinse their mouth following injection and lymphoscintigraphy commenced. In the first half of the study, dynamic lymphoscintigraphy commenced with the acquisition of 60 frames at 15 second intervals in the anteroposterior (AP) plane. A 20% window centred on the 140keV photopeak was selected and the camera interfaced to a Bartec Micas X computing system. Either an IGE CamStar or IGE Maxi400A gamma camera fitted with a low energy, general purpose (LEGP) collimator was used (Figure 11). In the second half of the study, dynamic lymphoscintigraphy was abandoned in favour of static lymphoscintigraphy only.

Static imaging was performed on all patients both in the AP plane and the lateral plane. The images were acquired at 15 minutes, 30 minutes and 60 minutes following injection of colloid or until the first sign of sentinel lymph nodes in the neck. Each static lymphoscintigraphy image was acquired for 60 seconds. In the second half of the study, only static lymphoscintigraphy was performed. For midline tumours left and right lateral images were obtained and for well lateralised tumours only ipsilateral images were acquired unless the AP image suggested otherwise (as seen in Figure 12). To mark the location of the sentinel node, during static lymphoscintigraphy a 1cm thick lead plate was applied to the patient's skin to shield the injection site from the gamma camera. The image was viewed on the camera's persistence display to highlight radioactive nodes which were located by aligning a ^{57}Co solid source with the hot spot in the neck. The position of the node was marked on the skin with indelible ink. Following image acquisition, software

enhancement of the image was performed by drawing a region of interest around the injection site. The injection site was effectively deleted from the image in this way and the contrast of the image increased to highlight sentinel nodes. A patient outline or silhouette was obtained either with a solid source ^{57}Co pen marker (Figure 13), or by placing the patient between the gamma camera and a flood source of gamma radiation.

GAMMA PROBE GUIDED SURGERY

The following day during surgery, the patient was anaesthetised and prepared for surgery. Blue dye was injected into the same site as the radiocolloid (Figure 14), and the patient's head was rotated to expose the side being dissected.

The Neoprobe-1500 (Neoprobe Corp, Columbus, Ohio) hand held gamma probe with a 14mm collimated probe was directed toward the previously marked radioactive sentinel node to confirm the approximate position of the lymph node. If necessary, the position of the marker was replaced to consider the effects of rotating the head.

Incisions were made to expose the neck field for a neck dissection. The sternocleidomastoid muscle was retracted posteriorly to reveal the internal jugular chain of lymph nodes and the Neoprobe was draped in a sterile sheath to permit its intra-operative use. The probe was passed along the possible anatomical positions of lymph nodes to identify radioactive nodes and blue staining lymphatic channels were followed to blue stained sentinel nodes (Figure 15).

To reduce detection of radiation scatter and shine through from the injection site, a sterilised 1mm thick lead plate was used to mask the injection site, thus aiding in-vivo identification of radioactive nodes. All sentinel nodes were harvested and the Neoprobe was used to confirm the presence of radiocolloid within the sentinel node *ex-vivo*.

Following completion of the neck dissection the specimen excised and the exposed neck wound were scanned with the Neoprobe to determine any residual radioactive nodes.

RESULTS

Between July 1998 and March 2000, 67 necks were explored for sentinel nodes in 62 patients undergoing elective or therapeutic neck dissections. Each neck was considered a single case. 40 necks were classified as clinically N0 and 27 as clinically N+.

Injected radioactivity varied from 18MBq to 40MBq. The amount of activity was determined by placing the 2ml solution within an enclosed Geiger counter and radioactivity measured. If measured radioactivity was greater than 18MBq it was considered adequate to perform lymphoscintigraphy. All "hot spots" identified as lymph nodes at lymphoscintigraphy were seen within 30 minutes. In those patients where no nodes were seen within this time, a delayed image at 60 minutes did not lead to the identification of a hot spot, suspicious of a lymph node.

TUMOURS OF THE FLOOR OF MOUTH

Eighteen necks were explored for sentinel nodes for floor of mouth (FOM) carcinomas. Alburess was used in all 18 cases. At least one sentinel node contained radioactivity in 14 of these 18. There were three cases where no hot node was found but where a blue node was found. There was one case where no sentinel lymph node (either hot or blue) was found in the neck. In summary a "hot neck" was found in 14 of 18 (78%) cases of carcinoma of the FOM and in combination with blue dye a sentinel node was found in 17 of 18 cases.

TUMOURS OF THE TONGUE

Twenty-six necks were explored for sentinel nodes for clinically N0 tongue carcinomas. Albures was used in 25 cases and Nanocoll in one. When Albures was used, a hot neck was found in 21 of the 25 necks. In the four necks in which a radioactive node was absent, blue nodes were also absent. A "hot neck" was therefore present in 84% of cases and addition of blue dye did not increase the sentinel node retrieval rate.

TUMOURS OF OTHER ANATOMICAL SITES

Patients with lesions other than those of the floor of mouth or tongue were initially injected with Albures and later, in our series, with Nanocoll. Albures was used in eight cases and Nanocoll was used in 15 cases.

In the eight cases where Albures was used, a hot node was found in three of eight necks, no sentinel nodes were found in three and a blue node was found in two. In the 15 cases where Nanocoll was used, at least one hot node was found in 13 necks and no sentinel nodes (either hot or blue) were found in the other two cases. This difference was not statistically significant using the Mann-Witney U test ($p=0.13$)

DISCUSSION

This chapter details our experience in performing preoperative lymphoscintigraphy and peroperative gamma probe directed sentinel node biopsy in oral SCC. During the course of our experience, we have aimed to refine the technique to allow easier identification of radioactive lymph nodes both prior to surgery in the Nuclear Medicine Department and during surgery. Our main initial difficulties were sumping and swallowing of colloid through leakage from an oral

ulcer, the proximity of the injection site to the neck, the choice of colloid, and the timing of image acquisition.

DYNAMIC LYMPHOSCINTIGRAPHY

The images obtained from dynamic lymphoscintigraphy were inspected with a view to distinguishing first echelon nodes from second and subsequent echelon nodes. In all patients with more than one hot spot on lymphoscintigraphy, lymph nodes appeared simultaneously after injection. We therefore concluded that dynamic lymphoscintigraphy was an unnecessary waste of resources and patient time, and proceeded to perform static lymphoscintigraphy at 15 minutes, 30 minutes and one hour post injection in two planes or until the appearance of radioactive nodes. In our experience hot spots appear 15 minutes post injection. If nodes are still absent one hour after injection, the lymph nodes are either too close to the injection site or radiocolloid has leaked out of the injection site.

If a sentinel node biopsy is to be performed as the only procedure in the neck in cases with absent lymphoscintigraphy nodes, it is likely that the surgical procedure with blue dye alone will be technically challenging and no sentinel node may be found.

CHOICE OF COLLOID

Choice of colloid has not been previously investigated for patients with oral cancers. Although the differences in colloids has been discussed previously, it is worth repeating here in the context of the reasons for choosing Albures over Nanocoll in oral cancer sentinel node studies. Initially the colloid used was Albures since this remains within the first lymph node it encounters¹⁷⁶, and all radioactive nodes would thus be first echelon nodes. Since hot nodes were only seen consistently with floor of mouth and tongue lesions, our choice of colloid in this group of patients remains as Albures. Nanocoll is used

for tumours at all other sites, since there was a trend towards increasing sensitivity of hot node identification following injection at these sites with the smaller diameter colloid.

The properties of the ideal colloid have been previously described. The ideal colloid should be a licensed product, with a narrow particle size range, with a ^{99m}Tc label. It should be stable on storage and be transported by lymphatic channels quickly to the sentinel node, where it should remain¹⁴⁰.

Albures is a large and slowly moving colloid with a mean particle size of 500nm but has the advantage of remaining in first echelon lymph nodes. Conversely, Nanocoll is a faster moving smaller diameter colloid with a mean particle size of 80nm but moves more readily from sentinel nodes to second and subsequent echelon nodes. The tongue and floor of mouth may have a higher concentration of terminal lymphatics^{177,178} and larger diameter colloids are more likely to move from lymphatic vessels to sentinel nodes. If Albures is used in areas of low lymphatic density, the injection will remain in the interstitium of the injected tissue and if Nanocoll is used in the tongue or floor of mouth a greater number of hot nodes will be found in the neck, some of which will not be true first echelon nodes.

SOFTWARE MASKING

A few studies have previously highlighted the difficulties in performing lymphoscintigraphy in head and neck malignancies¹⁷⁹⁻¹⁸³. One of the difficulties quoted in head and neck cancer lymphoscintigraphy is the closeness of the injection site to the sentinel nodes. This prevents areas of relatively low radioactivity (for example sentinel nodes) from being seen in the presence of areas of much higher radioactivity (for example the injection site). Sentinel nodes sited close to the injection site are difficult to distinguish during

lymphoscintigraphy, however, by defining a region of interest around the injection site, and masking the region, the areas of relatively low radioactivity may subsequently be seen. The process of software marking is shown in Figure 16.

INTRAOPERATIVE LEAD SHIELDING

The combination of software masking and intraoperative lead shielding minimises the difficulties caused by the proximity of the sentinel nodes to the injection site. During surgery with the gamma probe, a series of 1mm thick lead plates were used to surround the injection site, if possible. This minimises shine-through and scatter of radioactivity from the injection site to the neck. This is shown in Figure 17.

SUMPING AND SWALLOWING OF COLLOID

Since malignant oral lesions are commonly ulcerated, injections of radiocolloid (and blue dye) will easily leak through to the oral cavity. Although blue dye can be seen leaking from the injection site during surgery, unless a dye is added to the colloid, any leaked radiocolloid will remain unseen until imaging. We ask patients to use a mouthwash following injection of radiocolloid, however, if the pharynx, oesophagus and stomach are seen during lymphoscintigraphy (as seen in Figure 18) the patient is asked to swallow a drink. This passes much of the radiocolloid to the stomach, permitting successful lymphoscintigraphy in some cases.

BILATERAL NECK DRAINAGE

Sentinel nodes are occasionally found in both necks, especially in tumours that are close to, or cross, the midline. Since shine-through may cause confusion in interpreting lymphoscintigraphy images with bilateral sentinel nodes, we suggest the patient adopts an oblique view, laterally rotating the neck to the opposite side. Hot sentinel

nodes from the contralateral neck appear more anterior to the sentinel nodes in the neck being investigated, and shine through is avoided.

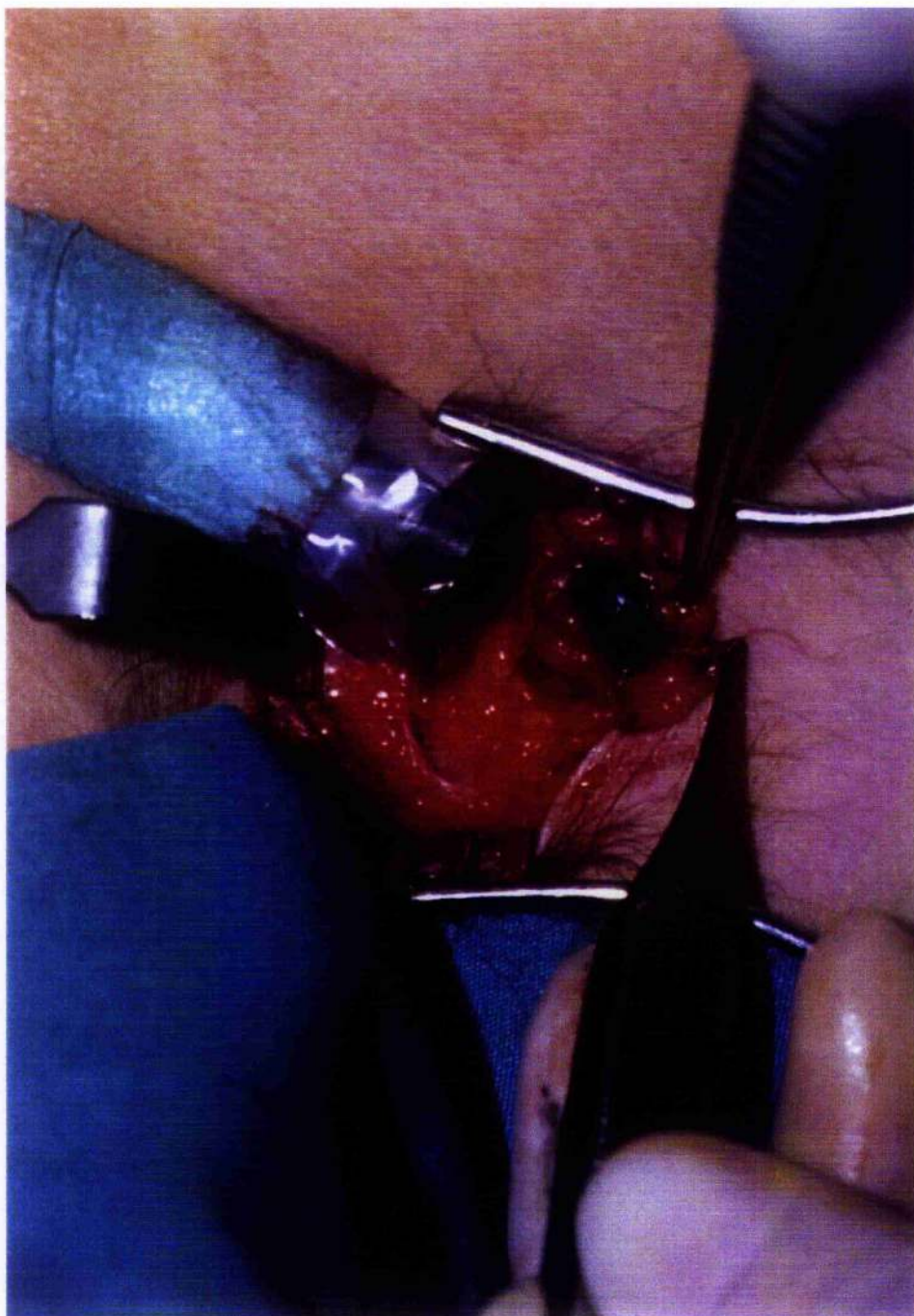CONCLUSIONS

In summary, the use of nuclear medicine techniques is vital to the successful identification of sentinel nodes in head and neck cancer. Blue dye should be used in addition to radiocolloid for several reasons: it may provide a second method to find sentinel nodes in the "cold neck"; it is the means to distinguish the sentinel node from non-sentinel nodes which have taken up radiocolloid; finally, because of the differences in pharmacodynamics and pharmacokinetics of blue dye and radiocolloid, there may be cold blue nodes and hot pale nodes found in the neck, some of which may contain tumour. Sentinel nodes can be successfully identified during lymphoscintigraphy imaging but the technique can provide challenges to the sentinel node team.

TABLES AND FIGURES

Figure 10: Sentinel node biopsy in the axilla

(original in colour)



**Figure 11: Gamma camera and collimator used during
lymphoscintigraphy**
(original in colour)



Figure 12: Lymphoscintigraphy image showing asymmetrical bilateral drainage from a centrally placed anterior floor of mouth tumour

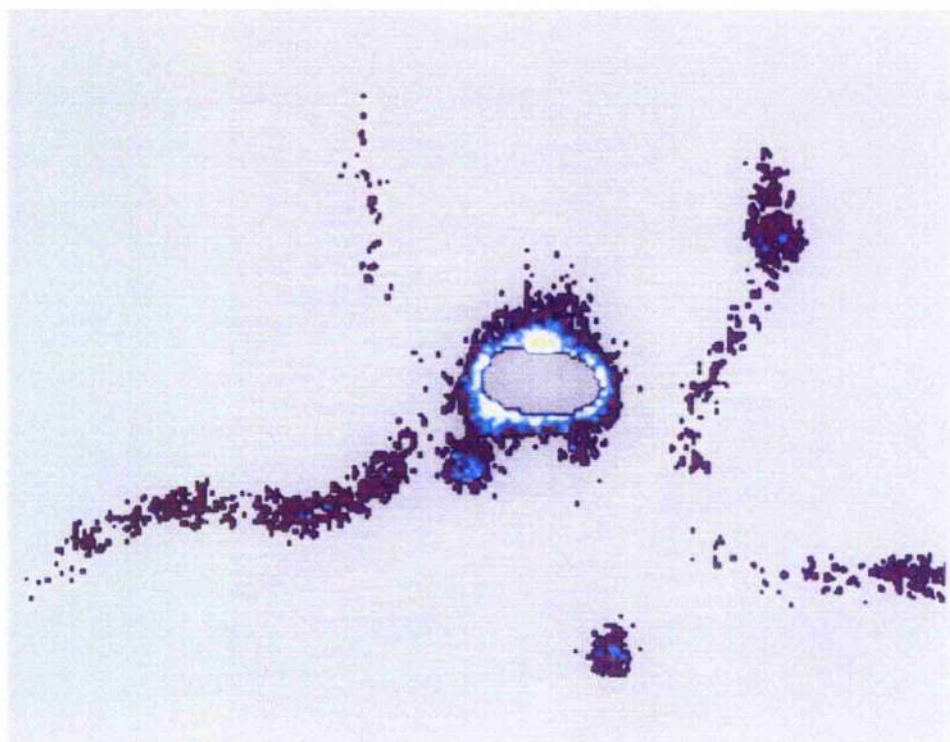


Figure 13: Cobalt-57 marker pen

(original in colour)




Figure 14: Blue dye injection to surround a tumour

(original in colour)

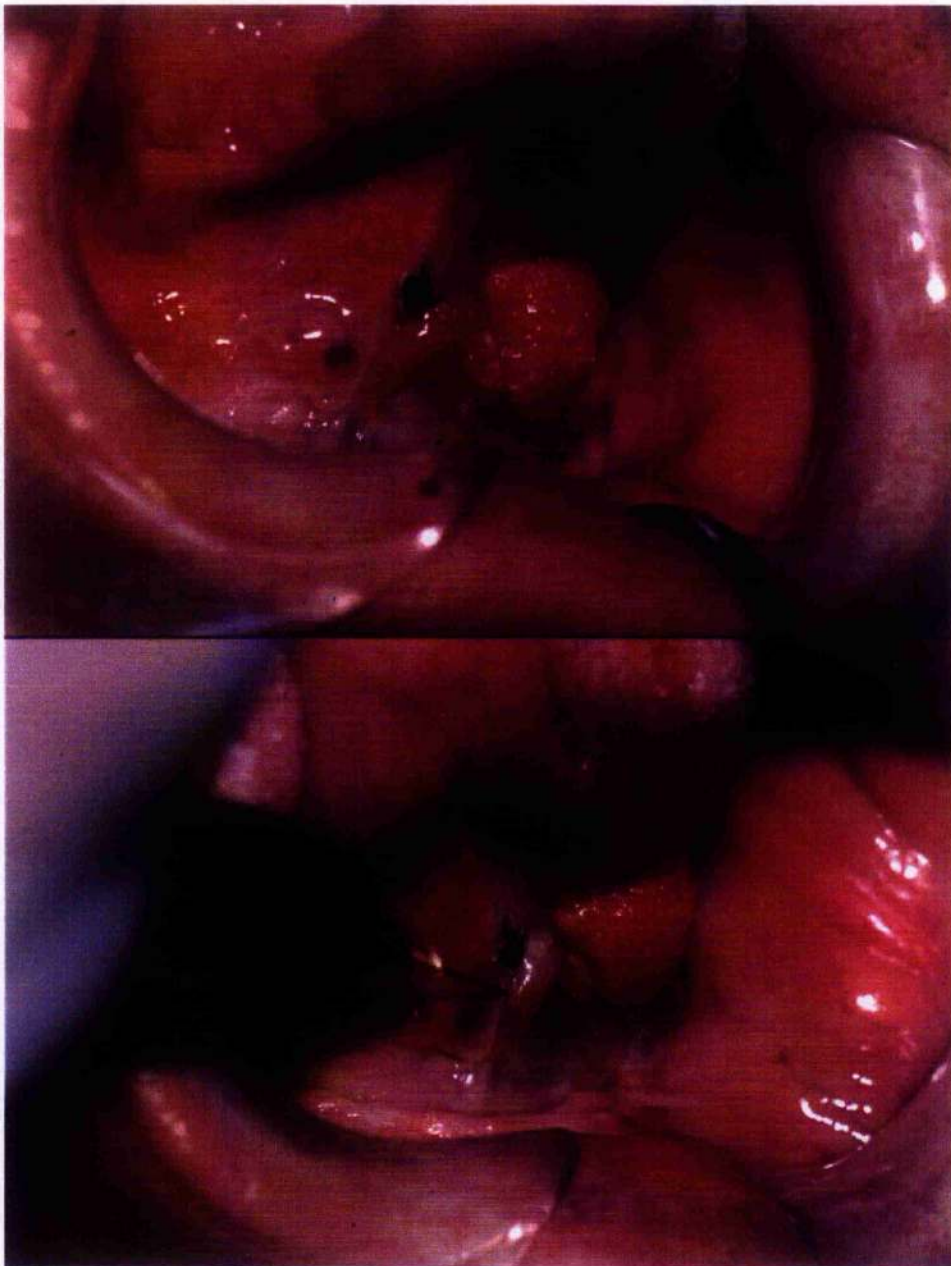


Figure 15: Hot blue node found during a neck dissection

(original in colour)

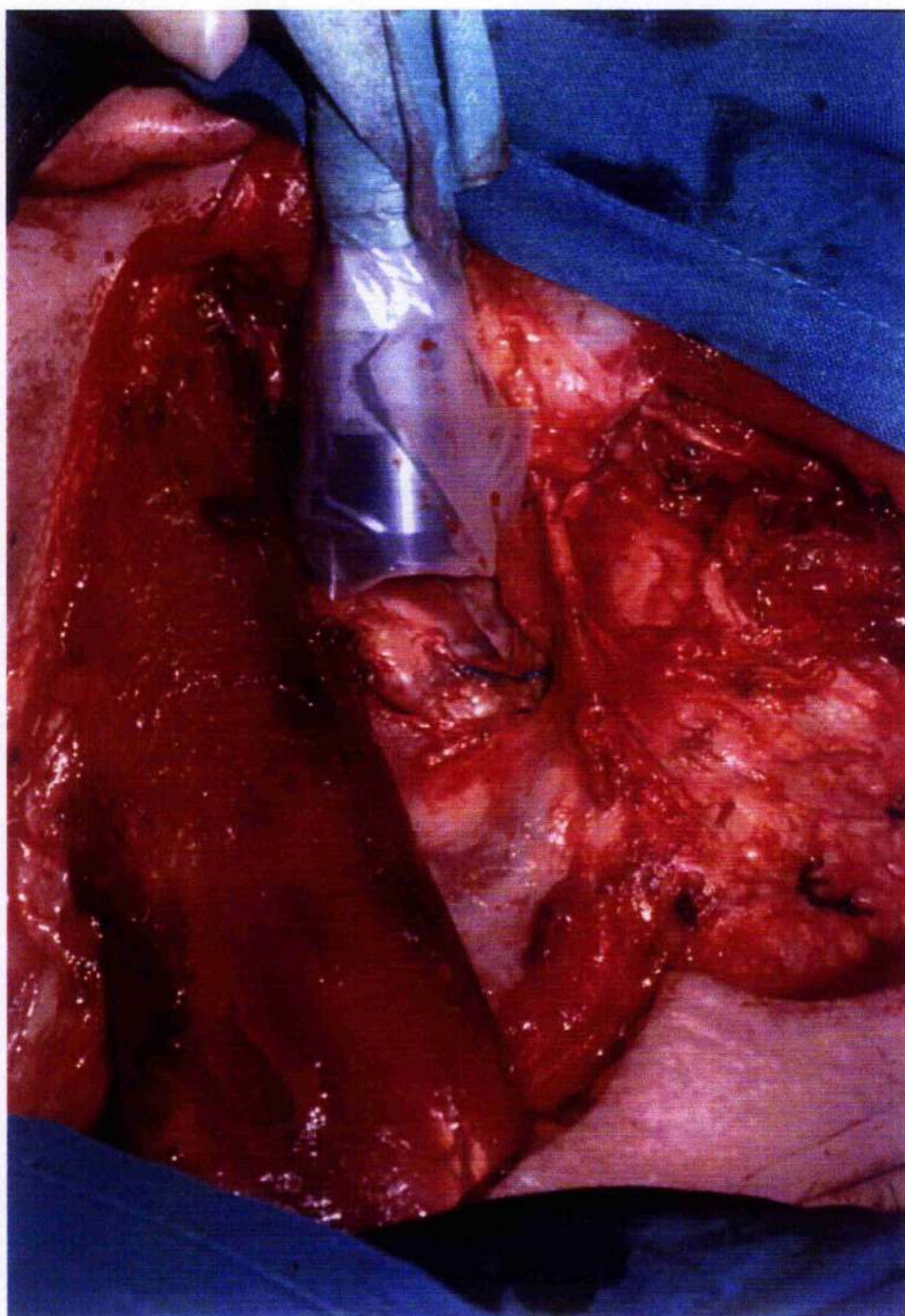


Figure 16: Masking of the injection site to highlight the sentinel nodes

(original in colour)

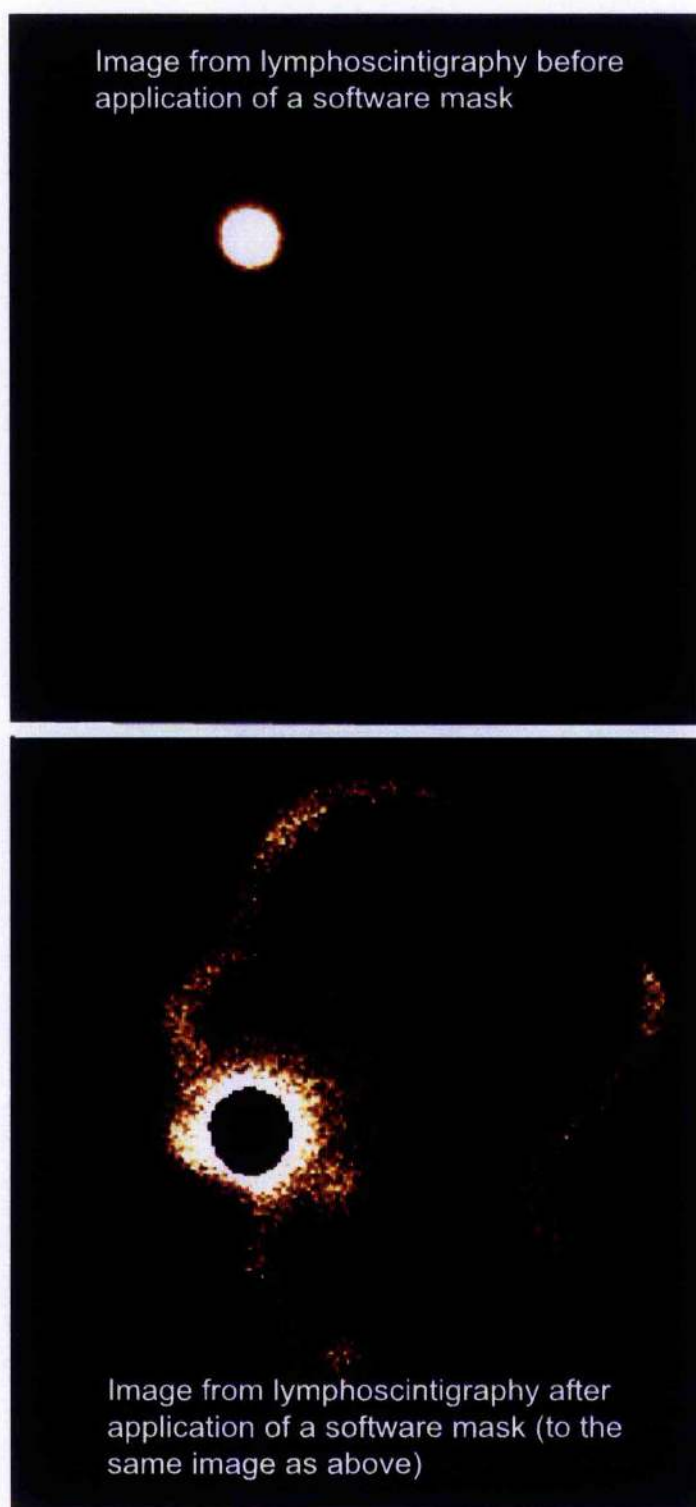


Figure 17: The use of lead shields intraoperatively to prevent shine through from the injection site

(original in colour)

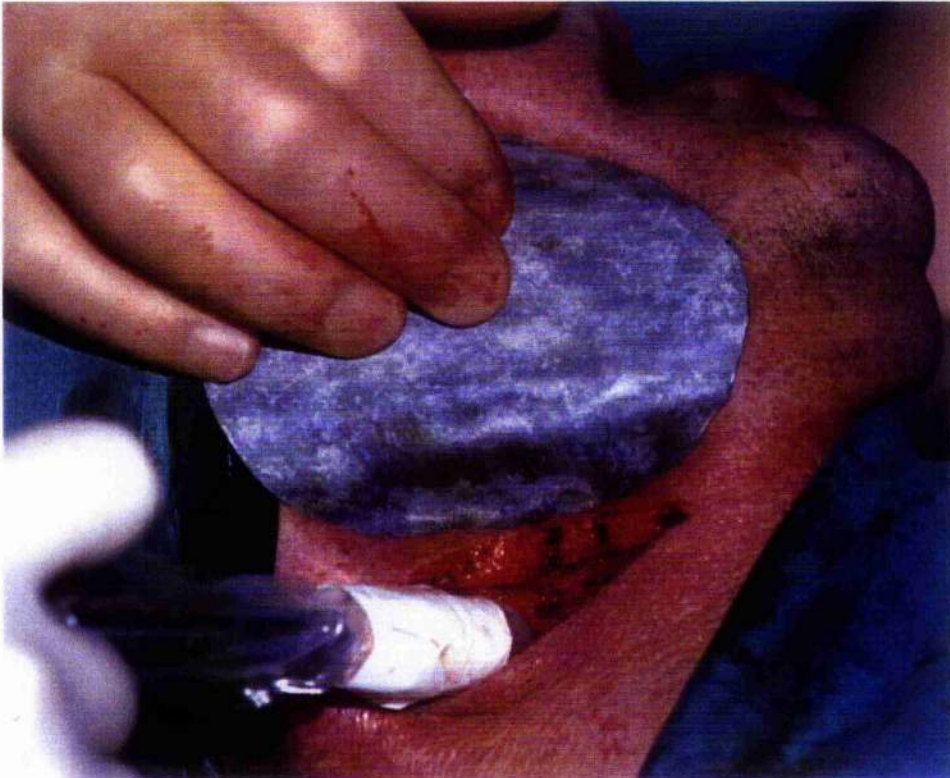
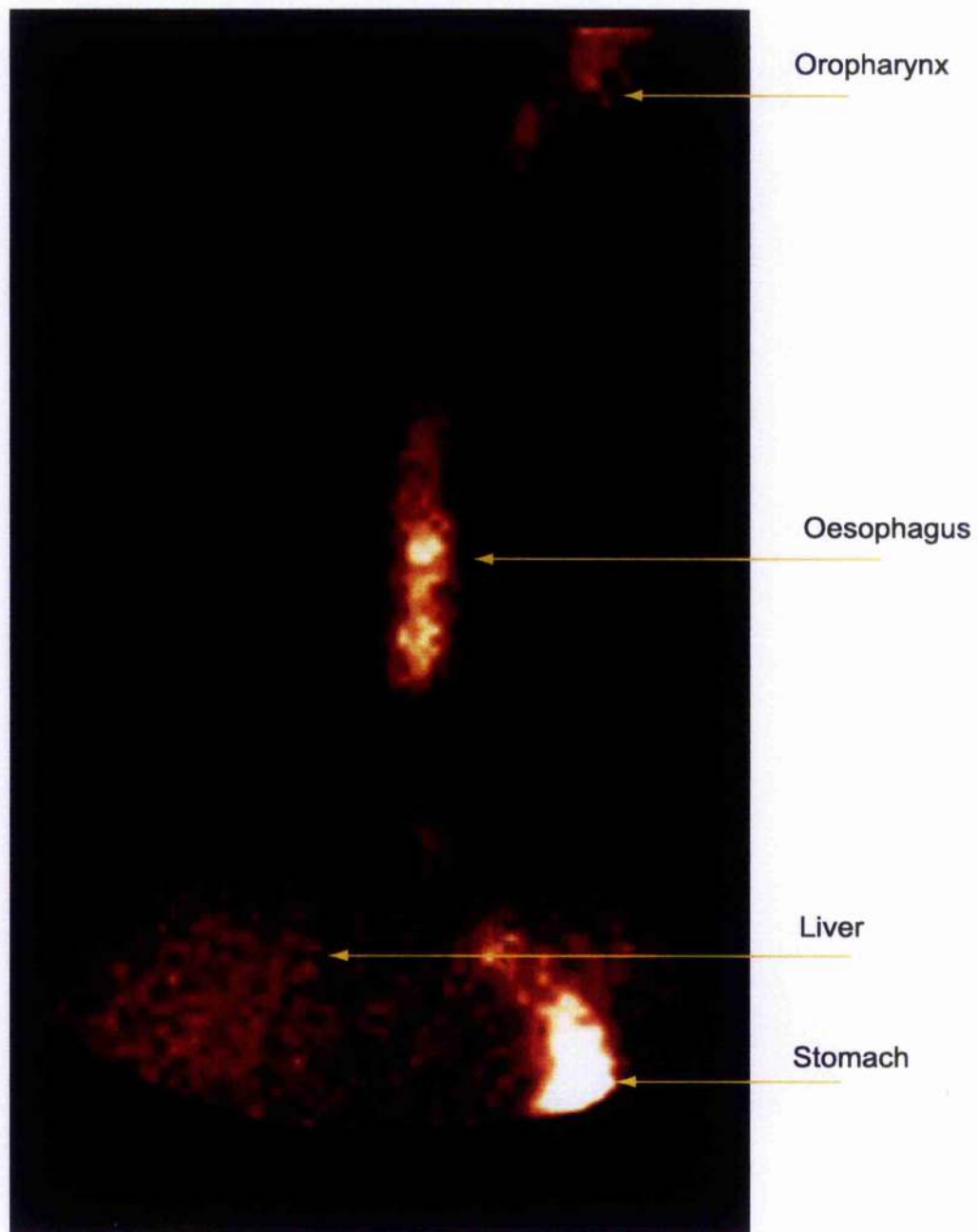


Figure 18: Swallowed colloid passing from mouth to stomach and liver

(original in colour)



CHAPTER 4: SENTINEL NODE BIOPSY PATHOLOGY USING RADIOCOLLOID AND BLUE DYE IN THE CLINICALLY NO NECK

INTRODUCTION

The sentinel node concept states that tumour spread is embolic in nature – tumour metastasises in an orderly and progressive manner through the regional node basin and metastatic emboli will seed initially in the first echelon node within the basin⁹⁷. In order to determine whether the concept was applicable to head and neck cancer, a method was required in which the first echelon node could be identified consistently. Having used the technique using blue dye alone with little success, both in terms of identifying the sentinel node and in terms of accurately staging the neck, the methodology was changed to assess the ability to identify the sentinel node in patients with head and neck cancer.

METHODS

Patients with oral or oropharyngeal carcinomas undergoing an elective neck dissection were invited to enter our study. Tumours were amenable to injection without the need for general anaesthesia and only patients whose planned primary treatment included a formal elective neck dissection were enrolled. Ethical approval was obtained from the local ethics committee prior to commencing our study.

The day prior to surgery, patients attended the Nuclear Medicine Department, where up to 40MBq of Tc-99m labelled colloidal human serum albumin – either Nanocoll or Albures (Nycomed Amersham, High Wycombe, Bucks, UK) in approximately ½-1 ml of saline – was injected at as many points as necessary in an attempt to completely

surround the tumour on its deep and lateral aspects. Initially, Albures was the colloid used in all cases, but following our initial learning curve, Albures, with a mean particle size of 500nm, was subsequently only used for primaries of the tongue and floor of mouth and Nanocoll, with a mean particle size of 80nm, was used for tumours at other sites. Static lymphoscintigraphy for 60 seconds was performed at 15 minutes, 30 minutes and 60 minutes following injection, or until the first appearance of sentinel nodes within the neck. During surgery, approximately ½-2 ml of Patent Blue V dye (Laboratoire Guerbet, Aulnay-Sous-Bois, France) was injected into the same site as radiocolloid, and skin flaps suitable for a neck dissection were raised. The sternomastoid muscle was retracted posteriorly to expose the deep chain of cervical lymphatics and attempts were made at identifying sentinel nodes. Blue stained lymphatics were followed to blue lymph nodes, and radioactive lymph nodes were identified with a Neoprobe 1500 hand held gamma probe (Neoprobe Corp, Ohio, USA). Sentinel nodes were identified in their lymph node level and were labelled according to colour and presence of radioactivity. Radioactivity was confirmed within the sentinel node *ex-vivo*. An appropriate neck dissection completed the surgical procedure. At the time of surgery, lymph node levels were marked with metal disks. The sentinel nodes were fixed in 10% neutral buffered formalin and after fixation were bisected through their longest axis. If the thickness of the halves was more than 2mm the slices were further trimmed to provide additional 2mm thick blocks. The remainder of the neck specimen was dissected following fixation and all nodes over approximately 2.5mm in maximum diameter were identified in their anatomic groups. Each node was bisected through its longest axis and one half was processed for histological examination. One Haematoxylin and Eosin (H&E) stained section

was prepared from each block and was examined for the presence of nodal involvement by tumour.

RESULTS

Between July 1998 and March 2000, 40 necks were explored for sentinel nodes in 37 patients with biopsy proven squamous cell carcinoma. Each neck side was considered a single case. Thirty-nine necks were staged N0 and one patient was staged clinically as Nx, because of palpable cervical lymphadenopathy from longstanding non-Hodgkin's lymphoma. The clinical stage of the primary was T1 in 14, T2 in 14, T3 in three and T4 in nine. The site of the primary squamous carcinoma was the tongue in 21, floor of mouth in ten, soft palate in four, retromolar trigone in three, the buccal mucosa in one and lower alveolus in one. The male to female ratio was 2:1. The mean age of patients was 59 (range 29-84).

Sentinel nodes were found in 36 of the 40 necks (90%). Ninety sentinel nodes were found in total. Forty-one nodes were both radioactive and blue ("hot blue" nodes), 35 were hot only, and 14 were blue only. The median number of sentinel nodes per neck was two with a mean of 2.2 (range 0-6).

Sentinel nodes were found in lymph node levels I to V and are summarised in Table 7. Two sentinel nodes were found in level IIb, in the triangle bordered by the skull base, sternomastoid muscle and the spinal accessory nerve.

In the four necks where sentinel nodes were not identified one was a patient with a T2 anterior floor of mouth tumour undergoing bilateral neck dissections with palpable lymphadenopathy from SCC on one side of the neck and no sentinel node was identified in the uninvolved neck. Three were patients with well lateralised tongue carcinomas

undergoing unilateral neck dissections. These three tongue carcinomas were classified as T2 in one case and T4 in two. In all four cases the neck dissection specimens were examined for blue and radioactive nodes *ex-vivo*, however none were found.

Two patients had areas of radioactivity, suggestive of sentinel nodes, identified out with the neck during lymphoscintigraphy. One patient had a T1 left body of tongue SCC, and the other had a T2 left soft palate carcinoma. In both cases, lymphoscintigraphy identified the left tonsillar region as the site, but tonsillectomies were not performed. The necks of both patients were classified as pN0.

A total of 849 lymph nodes, including sentinel nodes, was examined from 40 necks. A radical or modified radical neck dissection was performed in 22 cases, a supraomohyoid neck dissection in three, and a selective neck dissection excising levels I-IV in 15. In two cases of floor of mouth carcinomas, the planned procedure of a supraomohyoid neck dissection was converted to one which included level IV, since the sentinel nodes were located inferior to the omohyoid muscle and in one of these cases the sentinel node in level IV contained tumour. Table 8 summarises the number of lymph nodes examined and containing tumour from the neck dissections.

Twenty necks were pathologically staged as N0 and 20 as pathologically N-positive (nine were pN1, eight were pN2b and three were pN2c). In the N-positive group (pN+), sentinel nodes were found in 17 and contained tumour with conventional histology in 16, equating to a sensitivity of 94% (95% confidence interval: 82-100%). In three pN+ cases no sentinel node was found and the sentinel node biopsy procedure was considered a technical failure. Accordingly, a total of 16 of 20 cases were correctly identified by the technique with metastasis in the sentinel node. Thus, the sensitivity when considered on an "intention to treat" basis, rather than by

considering whether the procedure was technically competent, was 80% (16/20).

Forty-one sentinel nodes were harvested in total from the 20 pN+ necks, and tumour was found in 18 nodes. Table 9 summarises the presence of tumour, radioactivity and blue dye within all sentinel nodes harvested from pN+ necks.

In the 16 necks from which sentinel nodes containing tumour were harvested, the sentinel nodes were the only lymph nodes containing tumour in 12. Additional (non-sentinel) lymph nodes contained tumour in four necks. In three of these four necks, one additional lymph node was found to contain tumour and the levels of the neck in which sentinel and non-sentinel nodes were found, are shown in Table 9.

In three of four cases where sentinel nodes were not detected, the neck was staged pN+. In two cases, the primary tumour was a T4 tongue carcinoma and the third was a T2 tongue tumour. One was staged pathologically as pN2b and two were pN1. In the case staged N2b, two nodes were involved with tumour, one of which was extensively replaced by squamous cells and showed early extracapsular spread. In the two cases staged as N1, early lymphatic spread was seen in one node and in the other case, one small tumour deposit of approximately 200 microns in maximum diameter was seen within a lymphatic channel in the nodal capsule. In these three cases where sentinel nodes were not identified and the neck contained metastasis, lymphoscintigraphy images were examined. In two cases, no hot spots were seen and in one patient a single hot spot was seen in level I from a patient with a tongue tumour. Two pathologically involved nodes were identified in this patient in level II.

Twenty cases were staged pathologically as pN0 and a sentinel node was found in 19. In these cases, the sentinel node did not contain tumour, by definition.

There was one "false negative" sentinel node, in a patient with an extensive T4 SCC of the floor of mouth in whom negative sentinel nodes were found in levels I and II, and tumour was found within a "non-sentinel" level II node. In this case, a sentinel node was found, and the procedure considered a technical success, hence we considered this to be an indisputable false negative result.

DISCUSSION

This study was performed to determine if the sentinel node concept was valid for head and neck squamous cell carcinoma in necks with impalpable metastases undergoing elective neck dissections. We conclude that the sentinel node, when identified, using a combination of the hand held gamma probe and blue dye visualization, reflects the positivity or negativity of the neck with a high degree of accuracy. We found that sentinel node pathology using conventional H&E stains reflected that of the neck dissection in 94% of cases with impalpable disease, when the SLN was found.

There were four cases (10%) where the sentinel node was not identified. If no sentinel node is found in the neck, the procedure is considered a technical failure and the sentinel node procedure cannot be considered a reliable technique. In our series, three of the four cases of sentinel node biopsy technical failure revealed lymph nodes in the neck dissection specimen containing metastasis (75%). If a sentinel node procedure is planned for a patient, and no sentinel node identified, an elective neck dissection should be strongly considered as an alternative.

Sentinel node biopsy is technically challenging and difficulties with identifying sentinel nodes may be encountered during lymphoscintigraphy and surgery. Sentinel nodes may be too close to the primary injection site to be discernible by the gamma camera and this is particularly troublesome for sentinel nodes in level I for a primary located in the floor of mouth. Although the use of lead shields and software masking may highlight level I sentinel nodes, if the procedure is to find a role in the management of the clinically N0 neck for floor of mouth lesions, we would recommend exploration of level I in all cases where the primary is located in the floor of mouth. During surgical exploration of level I, the hand held gamma probe will detect scatter and shine-through from the primary site; the use of sterilized lead plates will aid in isolating radioactivity from lymph nodes. Blue dye visualisation may be the primary means of identifying nodes in level I, with the hand held probe being used to confirm the presence of radiocolloid within the node *ex-vivo*. Lastly, removal of the primary does not remove all radioactivity from the injection site, despite adequate tumour resection margins, although the reduction in radioactivity within the primary site can aid in the subsequent identification of hot nodes close to the primary.

Both blue dye and radiocolloid are required for sentinel node biopsy to be successful. Two sentinel nodes containing tumour were blue but contained no radiocolloid and six sentinel nodes containing tumour were hot but had no blue dye within them. In finding the blue nodes, pre-operative lymphoscintigraphy aided in localizing the presence of blue dye. Since the pharmacodynamics of blue dye will be different from radiocolloid, it is not surprising that some sentinel nodes are identified with one modality or the other.

Sentinel nodes have been identified in clinically unpredictable sites. This is a similar finding to that in melanoma and breast cancer

sentinel node biopsy^{137;184-192}. Traditional anatomical teaching from cadaveric studies has suggested that lymph drainage may be sequential from level I to the upper jugular chain and thence to the lower jugular chain. This has given rise to the misconception of "skip metastases"¹⁹³⁻¹⁹⁶, where tumour metastases by-pass upper lymph nodes in levels I and II and are found in lower levels. If the anatomical location of sentinel nodes is a reflection of direct lymphatic drainage, the findings that sentinel nodes may be located at various levels in the neck indicates that tumour drainage is dependent on individual anatomical pathways in some cases.

In most cases, sentinel nodes have been the only lymph nodes with tumour in the involved neck (12/16 cases). This is similar to the experience of those performing sentinel node biopsy for breast cancer and melanoma^{197;198}. When non sentinel nodes are also involved with tumour, these have occasionally been identified at higher anatomical levels in the neck. This phenomenon may be a reflection of tumour spread from the sentinel node to a second echelon node at a higher anatomical level.

In one case of a patient with long standing cervical lymphadenopathy from a low grade non-Hodgkin's lymphoma, the neck was staged clinically Nx. The primary was a T1 lateral tongue carcinoma, and the neck was found to contain squamous cell carcinoma in three nodes in levels II, III and IV. Three sentinel nodes were found in levels III and IV, with one of the two "cold blue" nodes from level IV contained tumour. Despite the presence of palpable lymphadenopathy from a different pathological process, sentinel node biopsy correctly identified nodal disease from the squamous cell carcinoma. In such cases, lymph nodes with increased hydrostatic pressure may divert lymphatic flow, so that sentinel nodes are found at clinically aberrant

locations. In these cases, the sentinel node location may reflect the true anatomic drainage pathway of the primary site.

On average, more than one sentinel node will be found in a single neck. In cutaneous melanoma sentinel node biopsy, approximately two-thirds of patients will have one sentinel node, one-quarter will have two sentinel nodes and the remainder will have three or more sentinel nodes¹⁹⁹. Since the oral cavity has a rich plexus of lymphatic vessels, these findings may reflect the diverse lymphatic drainage pathways to the neck.

Sentinel nodes were not found in four cases. One of the cases was a neck from a patient undergoing bilateral neck dissections for a tumour close to the midline. The lack of sentinel nodes on the contralateral neck was most likely a reflection of the true drainage pattern of the tumour. The remaining cases were tongue tumours: in all cases, the tumours were indurated and ulcerated. Blue dye was seen to leak out of the injection site into the oral cavity at the time of surgery. We presume the colourless injected colloid followed the same pathway, preventing lymphatic uptake of both dye and radioactivity. In three of the four cases where sentinel nodes were not identified, the neck dissection specimen was found to contain tumour. If sentinel node biopsy finds a role in the management of the clinically N0 neck, then in cases where a sentinel node is not identified a formal elective neck dissection should be considered for staging purposes – similar recommendations are made for the absence of detectable sentinel nodes in breast cancer cases.²⁰⁰ In those cases where sentinel nodes were not identified, the procedure was considered a failure. The sensitivity of the sentinel node procedure was 94% when successful; however, if all cases are considered on an intention-to-treat basis, where the sentinel node procedure has been considered a technical failure, then the

sensitivity of the procedure falls to 80% (16/20 compared with 16/17). These results are similar to the failure rate of approximately 5% seen following a SOHND²⁰¹, in those cases where the SOHND procedure has been deemed a technical success.

Sentinel node pathology did not reflect that of the remaining neck dissection in one case of successful "sentinel" node biopsy. There was, thus, one false negative sentinel node. In this case, the patient had an extensive T4 tumour of the floor of mouth, invading into the tongue, mandible and skin. In this case, the injection site of colloid and dye was not at the metastasising edge of the tumour, since the small volume of injection was insufficient to completely surround the tumour on its deep and lateral aspects. If sentinel node biopsy is to be used as a staging tool for head and neck cancers, it is important to inject around the whole tumour periphery.

CONCLUSIONS

In conclusion, the sentinel node concept appears to be valid in head and neck cancer. Patients with small carcinomas of the upper aerodigestive tract that are accessible to injection without the need for general anaesthesia may potentially undergo sentinel node localisation to stage the neck with a high degree of accuracy. Although there are technical limitations to the procedure and harvesting of the node can occasionally be challenging, the procedure is worth investigating as a tool to upstage the clinically N0 neck. A study was therefore started to perform sentinel node biopsy in patients who would otherwise undergo regular observation of their neck only. In the study, patients would undergo sentinel node biopsy and appropriate treatment to their primary lesion. If the sentinel node was found to contain tumour metastases, the patient would subsequently undergo a therapeutic modified radical neck dissection. Details of the initial results from this study are presented in Chapter 9.

TABLES AND FIGURES

Table 7: Number of sentinel nodes found by lymph node level and involvement by SCC

Lymph node level	Number of sentinel nodes	Number of sentinel nodes containing tumour
I	13	3
II	50	10
III	22	3
IV	4	2
V	1	0

Table 8: Number of lymph nodes examined and containing tumour by lymph node level

Lymph node level	Number of nodes examined	Number of nodes containing tumour
Level I	148	7
Level II	261	16
Level III	188	4
Level IV	170	2
Level V	94	0

Table 9: Sentinel nodes in the pN+ neck according to presence of tumour, dye and radiocolloid

	nodes with tumour	nodes without tumour	Total
Hot Blue	10	11	21
Hot only	6	9	15
Blue only	2	3	5
Total	18	23	41

Table 10: The anatomical location of non-sentinel nodes containing tumour, when non-sentinel nodes were found to harbour metastases

Level of sentinel node containing tumour	Level of non sentinel node in same neck with tumour
II	II
II	I
III	II
IV	II, III

CHAPTER 5: SENTINEL NODE BIOPSY PATHOLOGY USING BLUE DYE AND RADIOCOLLOID IN THE CLINICALLY INVOLVED NECK

INTRODUCTION

One of the concerns of sentinel node biopsy is that lymph nodes grossly involved with tumour will not take up either blue dye or radiocolloid²⁰². These grossly involved nodes may have been the first echelon nodes to which tumour had initially metastasised but are no longer the "sentinel nodes" identified by blue dye or radiocolloid. If blue dye and radiocolloid are diverted to uninvolved lymph nodes, a biopsy of such a radioactive or blue node would be misleading and inappropriate. In these cases, it is thought that the hydrostatic pressure within involved nodes diverts lymphatic fluid to nearby nodes that are uninvolved with tumour. Recently, however, in a group of patients with melanoma, it was shown that the sentinel node biopsy technique was valid in patients with grossly involved lymph nodes, and the sentinel node did indeed contain tumour, albeit in a limited number of cases²⁰³.

This part of the study was performed to investigate whether the sentinel node concept was valid in patients with head and neck cancer and palpable lymphadenopathy. Approximately 10% of patients with palpable cervical lymphadenopathy have no tumour metastases and the lymphadenopathy is from another cause²⁰⁴, however these patients are still staged as N+.⁵⁷ Since there is a well recognised learning curve for sentinel node biopsy in melanoma and breast cancer sentinel node biopsy^{164;165;205;206}, and a possibly longer learning curve for head and neck cancer, performing the procedure on patients undergoing therapeutic neck dissection may also aid in

the learning process. In addition, the study was performed to determine if the choice of colloid used for lymphoscintigraphy and radioguided surgery determined the accuracy of the procedure in identifying involved nodes.

Finally, if sentinel node biopsy is to find a role in the management of the neck in patients with head and neck cancer, its limitations should be defined. If the procedure is limited by the overt presence of nodal metastases, then this should be realised prior to formal studies to evaluate the procedure as a staging tool in clinical trials.

METHODS

Between July 1998 and March 2000, patients with squamous cell carcinoma of the upper aerodigestive tract, undergoing therapeutic neck dissections were enrolled. Ethical approval from the local ethics committee and an ARSAC certificate from the Department of Health was granted prior to starting the study. Each neck side from a patient with palpable lymphadenopathy was considered a single case.

Patients underwent lymphoscintigraphy prior to surgery. Up to 40 MBq (mean 30 MBq, range 18-40MBq) of radiocolloid was injected at the deep and lateral aspects of the primary tumour or its site of previous excision to completely surround the tumour or scar. Patients were asked to rinse their mouth immediately following injection to prevent sumping and swallowing of the colloid. A one minute static lymphoscintigraphy image was obtained at 15 minute intervals post injection in the anteroposterior and lateral planes until identification of the first hot spot within the neck, or for up to one hour. In the first year of the study, patients were injected with Albures (Nycomed Amersham, Buckinghamshire, UK), and from August 1999 – March 2000 the radiocolloid used was Nanocoll (Nycomed Amersham, Buckinghamshire, UK).

During surgery, 2ml of Patent Blue V dye (Laboratoire Guerbet, Aulnay-Sous-Bois, France) was injected at the same sites as radiocolloid. The neck dissection proceeded and if blue stained lymphatics were seen, these were followed to blue lymph nodes and their position marked. Following excision of the neck dissection specimen, radioactive nodes were identified with a hand held gamma probe (Neoprobe 1500, Neoprobe Corp., Columbus, Ohio, USA). The neck was scanned with the gamma probe *ex-vivo* after dissection of the neck to maintain oncological safety and prevent inadvertent spillage of tumour from potentially neoplastic lymph nodes. Radioactive and blue nodes were dissected free from the specimen and were labelled as "sentinel". The anatomical level within the neck was noted as was the colour (blue or pale) and radioactivity (hot or cold). Neck dissection levels were marked on the specimen with metal discs and all specimens were fixed in 10% formalin.

"Sentinel" nodes were bisected through the hilum, if identifiable, or long axis. If the thickness of the two halves exceeded 2mm, further sections were taken at 2mm intervals to provide additional blocks. The remainder of the neck specimen was dissected and all nodes with a maximum diameter greater than approximately 2.5mm were identified in their anatomical levels. Each node was bisected through the hilum and one half was processed for histological examination. One H&E stained section was prepared from each block and was examined for the presence of nodal involvement by tumour.

RESULTS

Twenty seven necks were explored for "sentinel" nodes. Between June 1998 and May 1999 18 necks were explored in 17 patients injected with Albures and between June 1999 and March 2000, nine necks were explored in eight patients injected with Nanocoll. One

patient from each group underwent bilateral neck dissections for suspected metastatic lymphadenopathy. The mean age of patients was 61 (range 48-87) and the male: female ratio was 25:2. The type of neck dissection performed was a modified radical neck dissection in 19, a radical neck dissection in four and a selective neck dissection in four.

Five cases were T1 tumours, eight were T2, two were T3, seven were T4 and five were classified as Tx, for patients undergoing metachronous neck dissection after previous treatment for their primary tumour. Six necks were pathologically clear of tumour (pN0) and 21 were found to contain metastases (pN+) in at least one lymph node (78%).

A "sentinel" node was found in 23 of 27 necks. In the group injected with Albures a node was found in 15 of 18 cases and in the group injected with Nanocoll, a node was found in eight of nine cases. In the four cases where a sentinel node was absent, three were injected with Albures and one with Nanocoll. The latter case was subsequently found to be a pN0 neck from a primary midline tumour of the soft palate. The primary site of the three cases injected with Albures was the right mandible in one case (pT4N2b), right tongue in one case (pTxN1) and right buccal mucosa in one (pT4N2b). Lymphoscintigraphy failed to identify any radioactive nodes in these four cases.

When Albures was used, 27 "sentinel" nodes were harvested from 15 necks in which a node was found (mean per case: 1.8). When Nanocoll was used, 19 "sentinel" nodes were harvested from eight necks in which a node was found (mean per case 2.4). The presence of radioactivity and presence of blue dye in the 23 cases where a "sentinel" node was found is shown in Table 11.

In 23 cases, where a "sentinel" node was found, the neck contained tumour in 21. When using Albures, a "sentinel" node contained tumour in only two of 12 cases (14%, 95% C.I. 0-35%). When using Nanocoll, "sentinel" nodes contained tumour in six of seven cases (86%, 95% C.I. 51-100%).

DISCUSSION

This study was performed to determine if the sentinel node concept was valid for patients with clinically involved nodes in head and neck cancer. In those patients injected with Albures, the radioactive or blue nodes did not reflect the lymph node status of the grossly involved neck. Large diameter colloids, such as Albures, appear to be diverted away from the first echelon node to uninvolved lymph nodes elsewhere in the neck²⁰⁷. It is likely that the large particles are unable to overcome the high hydrostatic pressure within grossly metastatic lymph nodes to enter the lymph node or be taken up by the antigen presenting cells within the nodes²⁰⁸. Even if there were blue sentinel nodes that contained tumour, but which were not seen, identification of the approximate position of sentinel nodes using preoperative lymphoscintigraphy is a prerequisite to successful sentinel node biopsy in head and neck cancer, in our experience²⁰⁹. If the radioactive nodes are not in the close vicinity of blue first echelon nodes, containing tumour, blue stained lymphatics and nodes will not be seen. The successful identification of first echelon lymph nodes by radiocolloid is thus important when applying the sentinel node concept to patients with head and neck cancer.

In those patients injected with Nanocoll, the sentinel nodes were more likely to contain tumour and this is an interesting finding. In our series, Nanocoll-guided sentinel node biopsy correctly identified tumour in six of seven cases. In the single case where Nanocoll

failed to identify a radioactive or blue node with tumour, the neck was classified as pN1, the involved node was found in level II and contained extracapsular spread. The "sentinel" nodes in this case were found in levels I and III, both were radioactive, and the level I node was additionally blue. In this case, radiocolloid was most likely diverted from the true sentinel node to lymph nodes free from tumour. There was also the possibility that small deposits of tumour were present in these "sentinel" nodes, but were not seen as a result of pathological sampling error, however, this has not been further investigated.

In view of the limited accuracy of the technique in the clinically and pathologically involved neck, there appears to be no role for sentinel node biopsy in the clinically node positive neck. Sentinel node pathology does not reflect the pathological status of the lymph nodes within the neck with a high degree of accuracy, even when using Nanocol, since the lower 95% confidence interval was only 51%. Although this may be a reflection of our low number of cases, it is unlikely that patients with palpable lymphadenopathy will undergo a sentinel node biopsy instead of a therapeutic neck dissection, with a decision to perform a neck dissection based upon the histology of the sentinel node.

TABLES AND FIGURES

Table 11: Sentinel nodes by colour and radioactivity

	Albures	Nanocoll	Total
Cold blue	8	1	9
Hot pale	15	13	28
Hot blue	4	5	9
Total	27	19	46
No. of cases	n=15	n=8	n=23

CHAPTER 6: SENTINEL NODE BIOPSY IN HEAD AND NECK MUCOSAL MELANOMA

INTRODUCTION

Sentinel node biopsy has emerged as an accurate method for determining the presence or absence of nodal metastases in the management of patients with cutaneous malignant melanoma^{156;210-213}. The technique involves the injection of a blue dye and radiocolloid, either alone or in combination, at the site of the tumour or its excision biopsy. These are traced to the first draining lymph node which is termed the sentinel lymph node and is harvested for detailed histological examination. A sentinel node free of tumour is likely to indicate the absence of nodal metastases elsewhere in the regional lymph node basin⁹⁷. Although the technique using a tracer to identify the sentinel node was originally described for cutaneous malignant melanoma⁹⁵, it is now being applied to different malignancies and initial results in patients with breast cancer²¹⁴⁻²¹⁷ and head and neck squamous cell carcinoma^{209;218-220} are encouraging.

Oral cavity malignant melanoma is relatively rare²²¹. It spreads via lymphatics to the regional lymph nodes in the neck and knowledge of the presence or absence of nodal metastases affects management. Patients with known nodal disease are treated more aggressively, however, the management of the clinically negative neck in oral malignant melanoma is the subject of surgical controversy²²²⁻²²⁴.

This paper describes the use of sentinel node biopsy in two patients with oropharyngeal melanomas and clinically disease free necks, who underwent excision of the primary tumour and sentinel node biopsy.

METHODS

Two patients were studied as part of larger trials of sentinel node biopsy in oral malignancies. Both patients were entered into different ethically approved trials. The first patient presented with a tongue melanoma and the second with a palatal melanoma.

Case 1: Tongue melanoma

A 47 year old male presented with an area of pigmentation of the left side of his tongue, approximately 1.5cm in diameter. Figure 19 shows the lesion in the patient.

An incisional biopsy confirmed the diagnosis of invasive melanoma and a decision was made to excise the lesion and perform an ipsilateral type 3 modified radical neck dissection at the same time. His cervical nodes were palpably clear of metastases. He agreed to enter our study of sentinel node biopsy on patients with oral malignancies undergoing neck dissections as part of the primary treatment for their lesions. Preoperative lymphoscintigraphy was performed by injecting 35MBq of 99m-technetium labelled colloidal albumin with a large mean particle diameter (Albures) into the tongue around the melanoma to completely surround the tumour. Subsequent scintigraphy images, obtained with an IGE Maxi 400A gamma camera fitted with a low energy general purpose collimator demonstrated drainage to both sides of the neck (Figure 20) and the positions of the lymph nodes were marked on the skin with indelible ink.

The presence of aberrant sites of sentinel nodes was discussed with the patient, and it was decided to continue with a neck dissection on the left but to include sentinel node biopsies on the right. During surgery, 1ml of Patent Blue V dye was injected into the same site as Albures. A tri-radiate incision was made on the left side of the neck,

sternomastoid was retracted posteriorly and the sentinel nodes were harvested using a combination of following blue stained lymphatics to blue stained lymph nodes and localisation with the Neoprobe-1500 (Neoprobe Corp, Dublin, Ohio) hand held gamma probe. One blue stained radioactive node and two pale but radioactive nodes were retrieved. On the right side, a smaller incision was made overlying the sentinel nodes, sternomastoid was retracted posteriorly to expose the deep cervical chain of lymph nodes and three pale-radioactive sentinel nodes were harvested. A neck dissection on the left side completed his surgical procedure.

Case 2: Palatal melanoma

A 64 year old lady presented with an area of diffuse melanosis on the hard palate, extending to the soft palate (Figure 21).

An incisional biopsy confirmed the presence of invasive melanoma and a decision was made to excise the entire palatal mucosa and reconstruct the defect with a skin graft. Her cervical nodes were palpably clear of tumour. She agreed to enter our interventional study of sentinel node biopsy on patients with oral malignancies who would not otherwise undergo staging neck surgery. Preoperative lymphoscintigraphy was performed by injecting 35MBq of 99m-technetium labelled colloidal albumin with a small mean particle diameter (Nanocoll) into the normal mucosa and submucosa surrounding the tumour at four points around the area of diffuse melanosis. Subsequent lymphoscintigraphy demonstrated a single area of radioactivity in the right side of the neck in the submandibular region (Figure 22).

During surgery, blue dye was not injected, since it was felt that blue staining of the palatal mucosa would compromise the oncological safety of the excision. A skin crease incision was made to identify

and harvest a single radioactive sentinel lymph node in level one, immediately deep to the right submandibular gland.

RESULTS

Case 1: Tongue Melanoma

Three sentinel nodes were harvested from the left side and three sentinel nodes were harvested from the right. All sentinel nodes were free of tumour by both conventional and immunohistochemical stains. A further 12 non-sentinel nodes from the left neck dissection specimen were examined and none contained tumour. The tumour had a maximum diameter of 1.5 cm and a depth of 1.35 mm. The patient continues to be followed-up every three months initially, and twelve months following surgery, remains free of locally invasive or regional metastatic melanoma.

Case 2: Palatal melanoma

One sentinel node was harvested from the right submandibular group of nodes, and was visibly pigmented at the time of surgery. Histological examination revealed the presence of iron pigment, in the form of haemosiderin, and melanin within macrophages, though no melanocytes were easily identifiable. Examination of the primary site confirmed an invasive component through the full thickness of mucosa but not invading maxilla. Since the node was located on the right side from a midline tumour, the patient subsequently underwent a right sided neck dissection in which a further seven lymph nodes were excised and none contained melanoma.

DISCUSSION

This chapter describes the management of two patients with oral cavity melanoma, in whom sentinel node biopsies were performed to

predict their nodal status. Although sentinel node biopsy has been previously described for cutaneous malignant melanoma and oral squamous cell carcinoma, to our knowledge it has not been previously described for use in oral cavity malignant melanoma.

Sentinel nodes were harvested in both patients from clinically unpredictable sites. In the case of the tongue melanoma, although the lesion was well lateralised and situated on the anterior tongue, lymphatic drainage was demonstrated in both sides of the neck. In the case of the palatal melanoma, injection of radiocolloid was directed at four points to surround the lateral margins of the melanosis and a single sentinel node was found in the right submandibular triangle. In addition, the invasive component of the melanoma was located in the mucosa of the left palate, yet the sentinel node in the right neck contained melanin pigment, which presumably originated from the melanoma. Melanin is not normally found in lymph nodes and the most likely explanation for this phenomenon is that some of the macrophages from the lamina propria area associated with the melanoma migrated to the lymph node after melanin uptake following the initial biopsy.

Since sentinel lymph nodes have been found in unpredictable sites for patients with cutaneous melanoma^{134,137,184,186-189,225}, it is perhaps not unexpected that unusual patterns of lymphatic drainage were seen in our two cases. We assume that the locations of the sentinel nodes reflected the true lymphatic drainage of the tumours. Without the benefit of pre-operative lymphoscintigraphy, prophylactic lymph node dissections would have been misdirected, to the left neck in the case of the tongue melanoma and both neck sides in the case of the palatal melanoma.

The management of the clinically negative neck in oropharyngeal malignant melanoma is subject of surgical controversy. The condition

is relatively rare, neck metastases are a common feature, with approximately 30% of patients harbouring nodal disease and there is no consensus of opinion regarding the optimal management of the clinically N0 neck²²⁴. Although staging neck dissections may be performed to determine the presence of nodal disease, they are not without potential complications and bilateral neck dissections carry greater morbidity than unilateral surgery²²⁶⁻²³¹.

The tongue is an uncommon site for malignant melanoma, and little is known of its natural history²³²⁻²⁴⁰. Our experience with tongue squamous cell carcinoma suggests that an aggressive approach to the neck is warranted, even for relatively early stage disease⁵⁸ but it is not known whether melanoma of the tongue carries a high rate of subclinical nodal disease and whether the prognosis is worse than melanomas of other sites within the oral cavity, as is the case with tongue squamous cell carcinoma. In the management of our patient with early tongue melanoma, the advantages and disadvantages of a staging neck dissection were discussed pre-operatively, and a joint decision was made with the patient to perform a left sided neck dissection. Following the discovery of sentinel nodes in the contralateral neck during pre-operative lymphoscintigraphy, a further joint decision with the patient was made to perform selective lymphadenectomies of the sentinel nodes from the right neck.

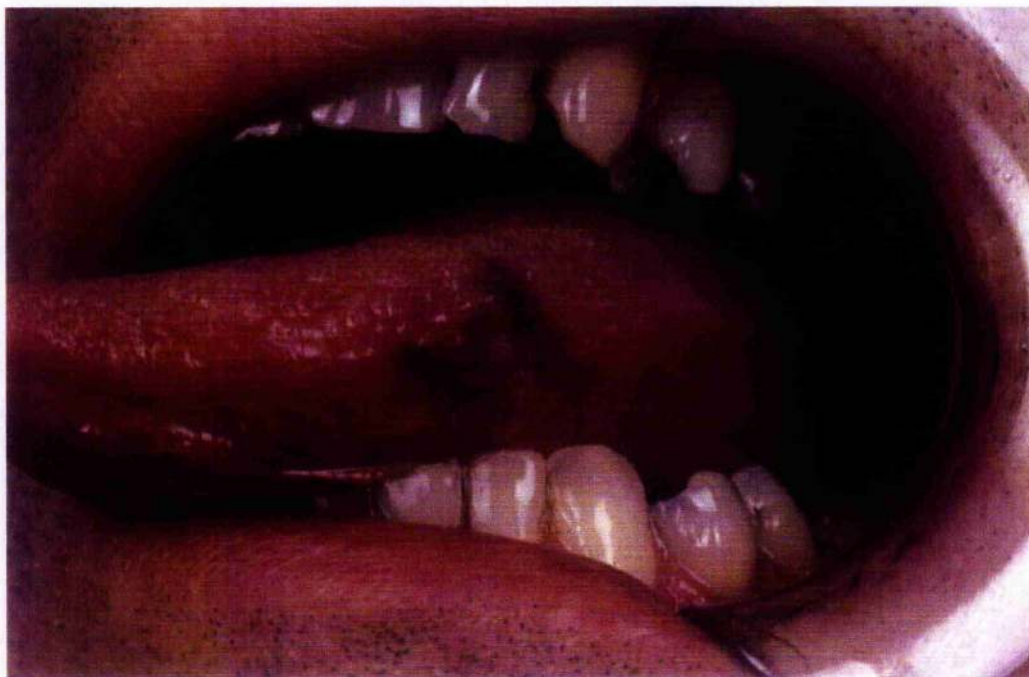Although it is unclear whether regional lymph node metastases significantly alters prognosis in oral cavity melanoma²²⁴, it may be that earlier treatment of involved lymph nodes confers a survival benefit. Should this be the case then sentinel node biopsy may prove to be a useful means of determining the nodal stage of patients with oral melanoma. In addition, sentinel node biopsy may be an alternative to a unilateral or bilateral staging neck dissection, thereby avoiding the associated morbidity of the procedure. Also, because of

the variability of lymphatic drainage within the oral cavity, elective lymph node dissection of the most likely involved lymph node group may not remove the correct nodal groups for accurate disease staging.

Although our experience is limited to these two cases, our early experiences show that sentinel node biopsy is technically possible to perform in oral cavity melanoma. This is aided by our experience in performing sentinel node biopsy for patients with oral cavity squamous cell carcinoma. Clearly, larger multicentre studies are required to further evaluate the procedure as a management option in clinically node negative patients with melanoma of the oral cavity.

TABLES AND FIGURES**Figure 19: Tongue melanoma**

(original in colour)



**Figure 20: Lymphoscintigraphy of patient with tongue
melanoma showing bilateral drainage**

(original in colour)

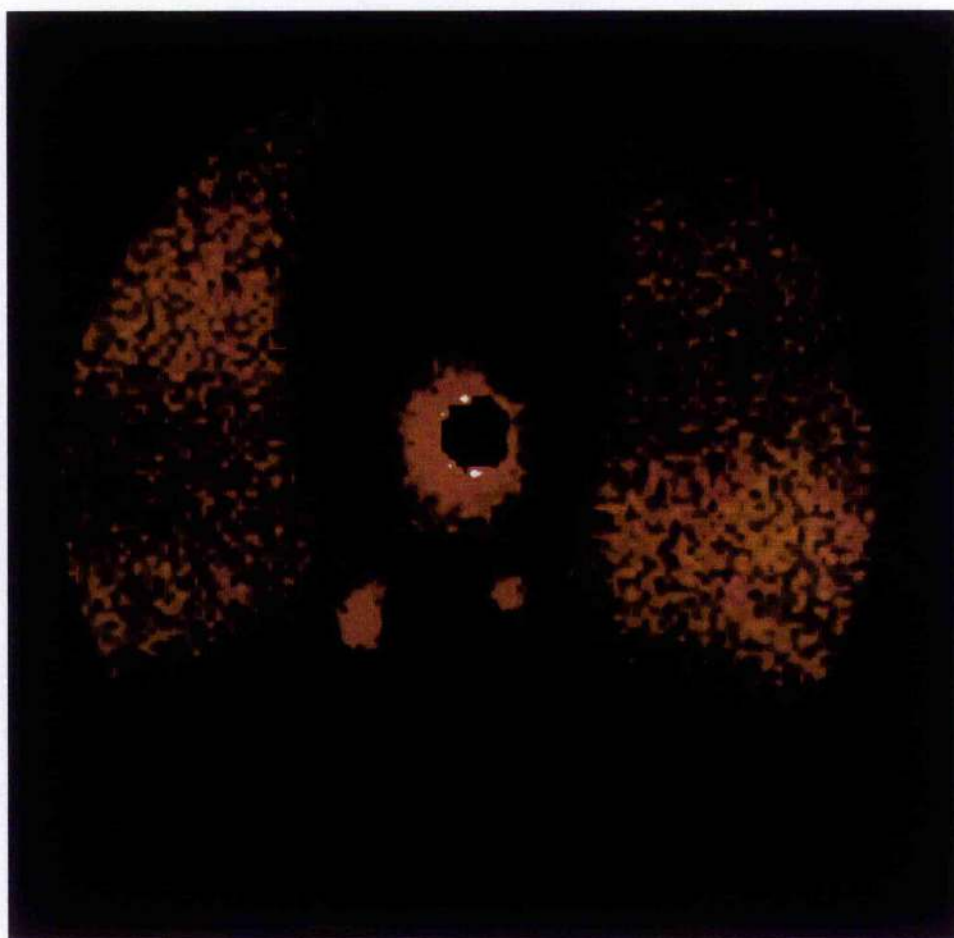


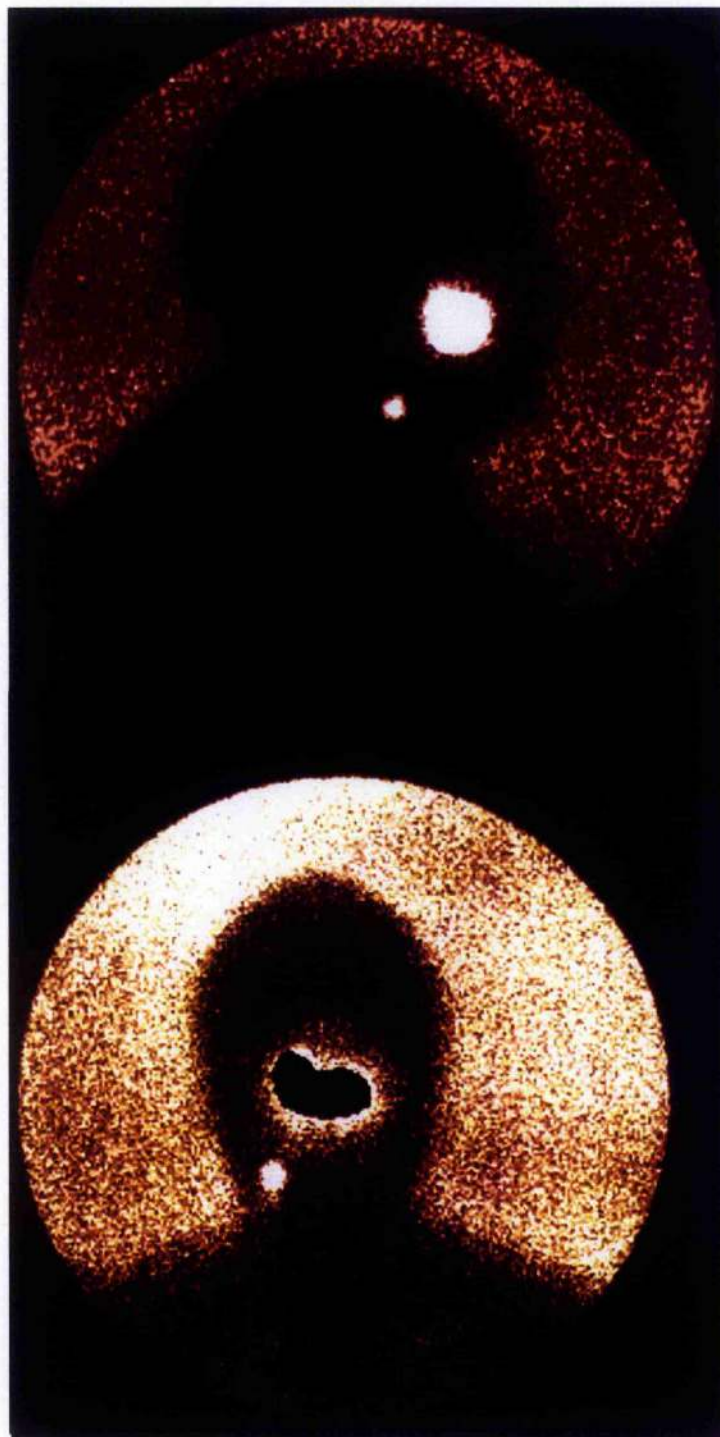
Figure 21: Palatal melanoma with invasive component to the left of the midline

(original in colour)

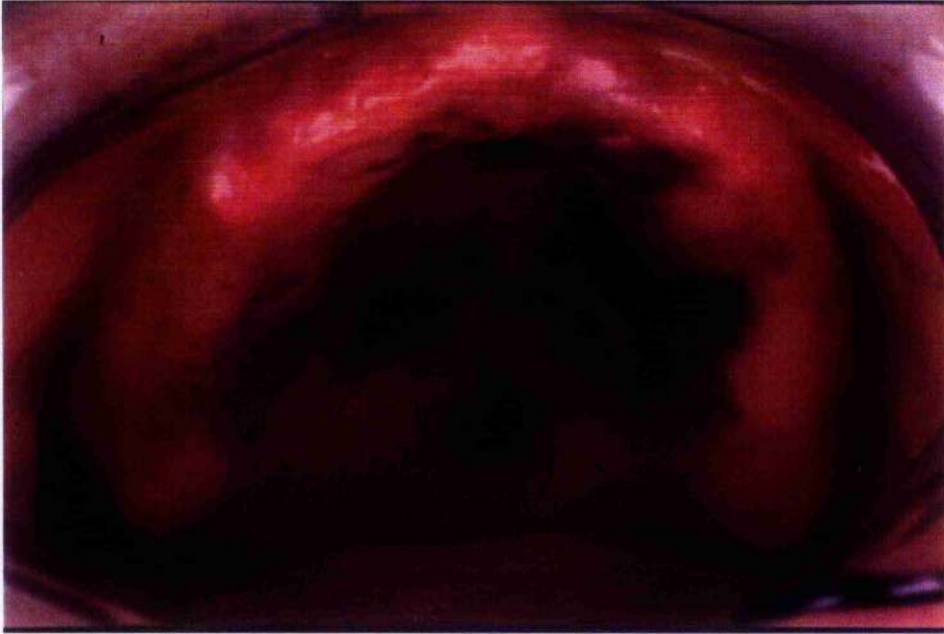

Figure 22: Lymphoscintigraphy of patient with palatal melanoma

(original in colour)



CHAPTER 7: SENTINEL NODE DIMENSIONS AND QUANTIFICATION OF RADIOACTIVITY WITHIN THE SENTINEL NODE

INTRODUCTION

The sentinel node is the first lymph node that receives lymphatic drainage from a tumour located at a particular anatomical site⁹⁷. One of the controversies surrounding sentinel node biopsy is whether all nodes identified as "sentinel" by radiocolloid should be excised as true sentinel nodes²⁴¹. Since some colloids move from sentinel node to lymph nodes lower in the draining lymphatic basin¹⁷⁶, if all radioactive nodes are excised then in some cases second and subsequent echelon nodes will be harvested as "sentinel nodes". One of the uses of blue dye in the sentinel node biopsy procedure is to distinguish first echelon nodes from non sentinel radioactive nodes²⁴², thus some radioactive nodes should remain within the lymph node basin, since they are not the first echelon nodes. In melanoma sentinel node biopsy, little information is gained by following the radiotracer more distal to the primary site and removing more than two sentinel nodes²⁴³.

Since this study has shown that sentinel lymph nodes can be located in levels I-IV in the neck for oral cavity tumours, it is not possible to determine whether a blue or radioactive node is truly first echelon by mere location. For example, a node highlighted by radiocolloid in level IV is as likely to be the first echelon node as is a lymph node in level II. Anatomically lower nodes are not necessarily second echelon nodes, unless efferent lymphatics can be seen draining from a node at a higher level to one in a lower level and these efferents are usually seen with Patent Blue V dye.

In head and neck cancer sentinel node biopsy, if several nodes are required to be removed from several lymph node levels, the complexity of the procedure may approach that of a limited selective neck dissection. Large lymph nodes are more likely to contain tumour than small lymph nodes and if only lymph nodes that are large and highly radioactive should be sampled as sentinel nodes, this may ease the complexity of the procedure, the operating time and pathology cost. Conversely, if lymph nodes with low amounts of radioactivity within them are found to contain tumour, then it is important that these nodes are removed during the sentinel node procedure.

This section of the study was performed on the cases already outlined. The study was performed to determine if the size and amount of radioactivity within sentinel nodes was an indicator of the likelihood of nodal metastases. Although the actual amount of radioactivity within a sentinel node can only be estimated with a hand held gamma probe, such as the Neoprobe, this was sufficient for the purposes of this study, since the hand held gamma probe is used clinically to determine both whether nodes are radioactive and whether these nodes are highly radioactive or only slightly radioactive.

METHODS

Sentinel nodes were harvested from patients with clinically N0 necks, undergoing neck dissection, using the procedure described in Chapter 3. Radioactive sentinel nodes were placed against the tip of the 14mm collimated probe of the Neoprobe-1500 and a 10 second count was made to estimate the amount of radioactivity in the sentinel node. Figure 23 shows the Neoprobe confirming the presence of radioactivity in a sentinel node *ex-vivo*.

A 10 second count of estimated radioactivity was also made of the primary site of the tumour. Radioactive sentinel nodes were fixed in formalin and the dimensions of the node measured in millimetres (mm). Three measurements were taken of the node: the maximum diameter, the middle diameter and the minimum diameter. The volume of the lymph node was calculated using the formula: volume (in mm^3) = $\frac{4}{3} (\pi r_1 r_2 r_3)$, where r_1 , r_2 and r_3 were the radii of the three dimensions of the sentinel node. Lymph nodes were bisected, and if the two halves were thicker than 2mm, further sections were processed at 2mm intervals. A single block from each section was examined using Haematoxylin and Eosin stain for the presence of tumour within the sentinel node. The presence of tumour within the sentinel node was correlated with the dimensions and volume of the sentinel node. Only radioactive nodes were examined in the study. If sentinel nodes were blue but not radioactive, they were not included in the results of this section. Statistical significance was assumed for the probability that the differences were seen by chance was less than or equal to 5% ($p \leq 0.05$).

The exact time of the injection and the exact time of the sentinel node harvesting was not recorded. However, all cases were injected with radioactivity the afternoon before surgery and all neck dissections were completed between 20 and 24 hours following injection.

RESULTS

Thirty-four necks were identified in which a hot node was found. A total of 76 sentinel nodes were found to be radioactive, of which 35 were hot only and 41 were hot and blue. Tumour was identified in 16 of 76 nodes (positive nodes), and the remaining 60 nodes were free from overt tumour (negative nodes). One hot node was found in 14

cases, two hot nodes were found in eight, three hot nodes were found in six, four hot nodes were found in three, five hot nodes were found in one and six hot nodes were found in two.

The maximum diameter of lymph nodes varied from 3 mm to 40 mm and the mean maximum diameter was 12.7 mm (95% C.I.: 11.0 – 14.3 mm). The volume of sentinel nodes varied from 3 mm³ to 6409 mm³ and the mean volume was 457 mm³ (95% C.I.: 249 – 664 mm³). The mean minimum and mean middle diameter of sentinel nodes was 5.2 mm and 7.4 mm respectively.

Figure 24 shows the maximum diameter of lymph nodes and the number of nodes with this maximum diameter.

Lymph nodes that contained tumour had a greater maximum diameter than non metastatic sentinel nodes, as seen in Figure 25 and Figure 26. The mean maximum diameter of positive nodes was 18 mm (range 7 – 40 mm; 95% C.I. of mean: 13.4 – 22.3 mm) and that for negative nodes was 11 mm (range 3 – 34 mm; 95% C.I. of mean: 9.7 – 12.8 mm). This difference was highly statistically significant ($p=0.001$), using the T-test. A box-plot of the results is shown in Figure 25.

Figure 26 shows the distribution of maximum diameters of positive and negative sentinel nodes.

When comparing middle diameters of sentinel nodes for positive and negative sentinel nodes, the mean of the middle nodal dimension was 9.5 mm and 6.8 mm, respectively. This difference was also significant ($p=0.05$) using the T-test.

However, when comparing the minimum diameter and the volume of sentinel nodes for positive and negative nodes, the differences were not statistically significant. The mean minimum diameter for positive and negative nodes was 6.3 mm and 4.9 mm, respectively, ($p=0.07$)

and the mean volume for positive and negative sentinel nodes was 789 mm³ and 368 mm³, respectively, ($p=0.1$). Even though the difference in the latter analysis was large, it was not statistically significant.

In those patients with positive sentinel nodes, the hottest nodes were not always the nodes that contained tumour. Table 12 shows the nodes (ranging from the hottest to coldest radioactive nodes per patient) and examines their pathology. There were two patients with more than one positive sentinel node. In these two, the 2nd and 4th hottest nodes and the 1st and 4th hottest nodes contained tumour. In the rest of the 16 sentinel nodes that contained tumour, no more than one node per patient contained metastases. In 9 of 16 cases, the hottest node contained metastases and in 5 cases, the hottest sentinel node did not contain tumour despite the presence of tumour in another radioactive sentinel node. All patients would have been staged accurately if only the hottest three sentinel nodes had been retrieved.

The node with the largest maximum diameter was not always the sentinel node that contained metastases. Table 13 shows that although in 12 cases the node with the largest maximum diameter was the node containing metastases, in four cases, smaller nodes were the sentinel nodes which contained tumour. There were two cases where more than one sentinel node per case contained tumour. In one of these two cases metastases were found in the largest and second largest nodes and in the other case metastases were found in the largest and smallest (the fourth largest) nodes.

The amount of radioactivity in the node was compared with the volume of the node. Figure 27 shows the comparison of nodal volume and radioactivity content, and demonstrates almost no correlation (Pearson's rank correlation coefficient (r) = 0.008). The

correlation coefficient was similarly unimpressive for maximum nodal diameter and radioactivity content ($r = 0.28$)

The amount of radioactivity in a node was compared for positive and negative sentinel nodes. The mean radioactivity count for positive nodes was 980 counts/10 seconds and that for negative nodes was 1554 counts/10 seconds. This difference was not significant ($p = 0.45$).

The amount of radioactivity in the sentinel node was compared with the radioactivity count for the injection site at the tumour. Again, no correlation was found ($r = 0.08$).

When the tumour radioactivity was compared with the pathology of the node, no statistically significance in the mean tumour radioactivity was seen. The mean tumour radioactivity for negative nodes was 18042 counts/10 seconds and that for positive nodes was 18900 counts/10 seconds ($p=0.8$). This is demonstrated in Figure 28.

DISCUSSION

This part of the study was undertaken to determine whether tissue radioactivity levels and sentinel node size could be used to predict sentinel node pathology. The most radioactive sentinel nodes within an individual case with large maximum diameters were more likely to contain tumour than smaller, less radioactive nodes within the case.

Nodes containing tumour had significantly larger maximum diameters than those nodes free from metastases (18 mm versus 11 mm). This represented a difference of approximately 7mm, or 64% of the tumour free node.

The total volume of the lymph node was not significantly different between the two groups. This apparent paradox is probably due to the power of the study sample – sixteen sentinel nodes were found to

contain tumour, in comparison to 60 which were free from metastases. The comparative difference in total volume of nodes was larger than that for maximum nodal diameter (789 mm^3 versus 368 mm^3). This difference represents a difference of 421 mm^3 , or 114%, of the tumour free nodal volume however, the variability (standard deviation) of the volumes was much greater and accounts for the difference in significance. Thus, the paradox in significance may be explained by the low power of the study.

The amount of radioactivity within a sentinel node was no guide to the size of the node or the probability that the node contained tumour. However, within a single patient the converse was true – to accurately stage the neck, merely sampling the three hottest nodes or the two largest nodes were sufficient for diagnostic purposes. More than one hot node was found in 20 cases. When the amount of radioactivity within sentinel nodes was analysed in each patient with positive sentinel nodes, it was seen that the hottest nodes were more likely to contain tumour and the largest nodes were most likely to be metastatic. Thus, in the 16 tumour containing sentinel nodes, nine were the hottest nodes, four were the second hottest nodes and one was the third hottest node. The remaining two hot nodes were weakly radioactive, but were found in patients with more than one hot positive node. Also, 12 of the 16 positive nodes were the largest sentinel nodes and three of the 16 were the second largest nodes. In the one remaining case, the 4th largest node contained tumour in a case where a larger node also contained tumour.

We conclude that if a sentinel node biopsy procedure suggests harvesting many small nodes that are weakly radioactive, additional information might not be gained by harvesting more than the three hottest and the two largest lymph nodes. Clearly, with the low power of this study, this conclusion must be interpreted with caution.

Limiting sentinel node biopsy to large and highly radioactive nodes might be necessary but only in the context of a complex neck exploration for sentinel nodes.

TABLES AND FIGURES

Figure 23: Confirming radioactivity of nodes ex-vivo

(original in colour)

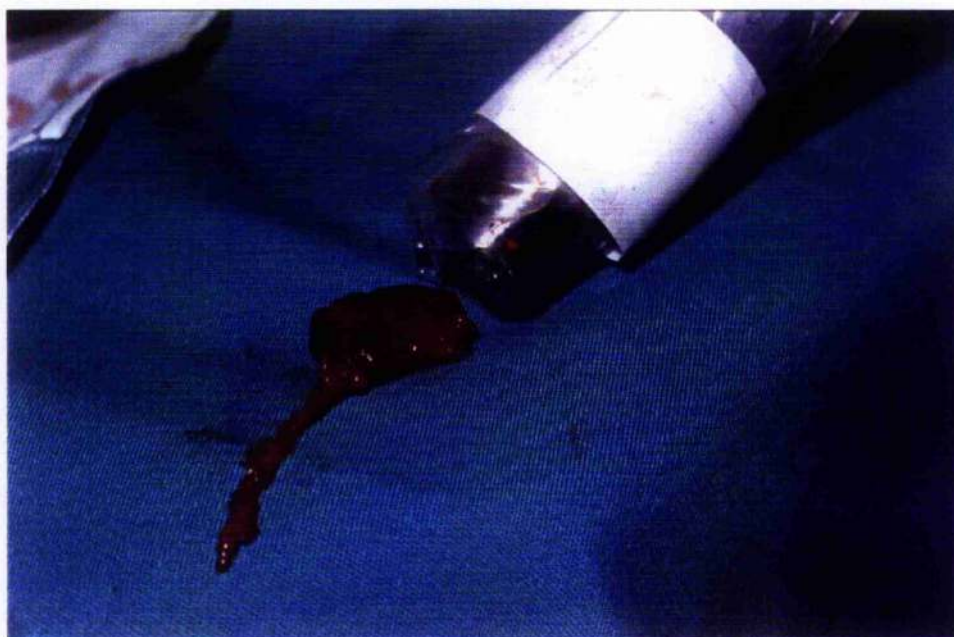


Figure 24: The maximum diameters of lymph nodes

(original in colour)

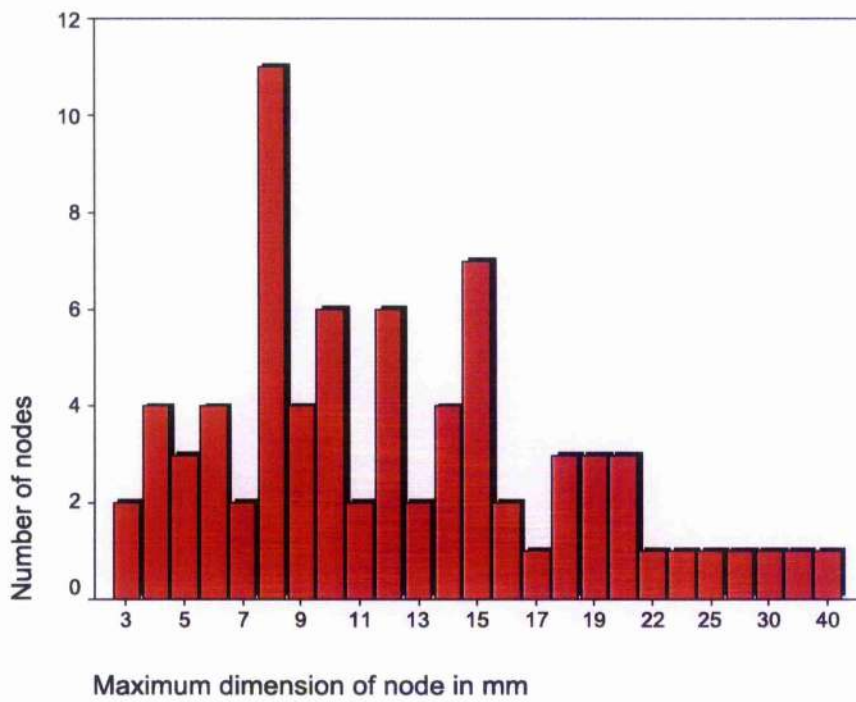


Figure 25: Box plot comparing the maximum diameter of positive and negative nodes, showing statistical significant differences

(original in colour)

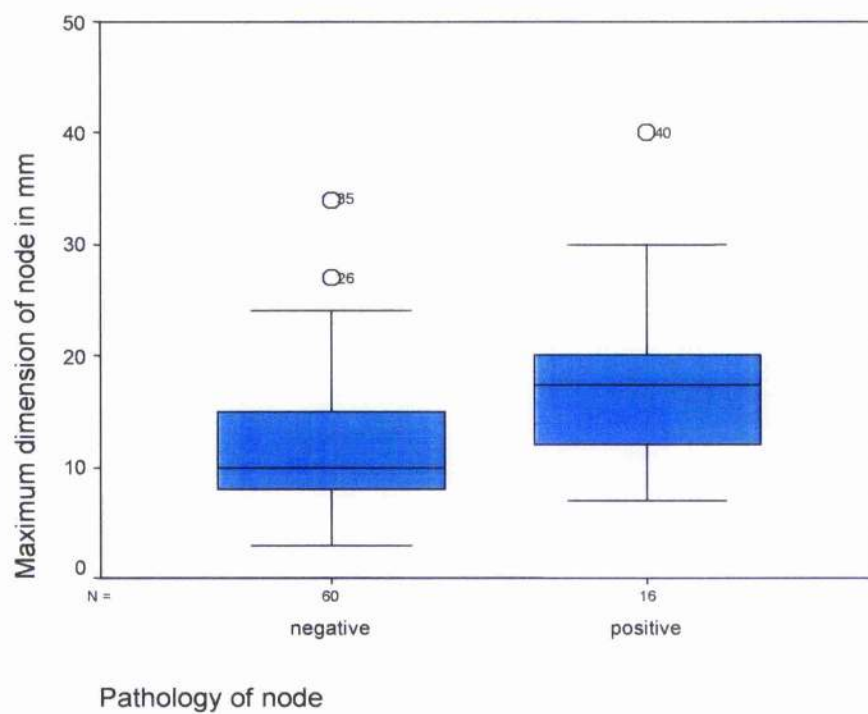


Figure 26: Comparison of maximum nodal diameters from nodes containing and free from tumour

(original in colour)

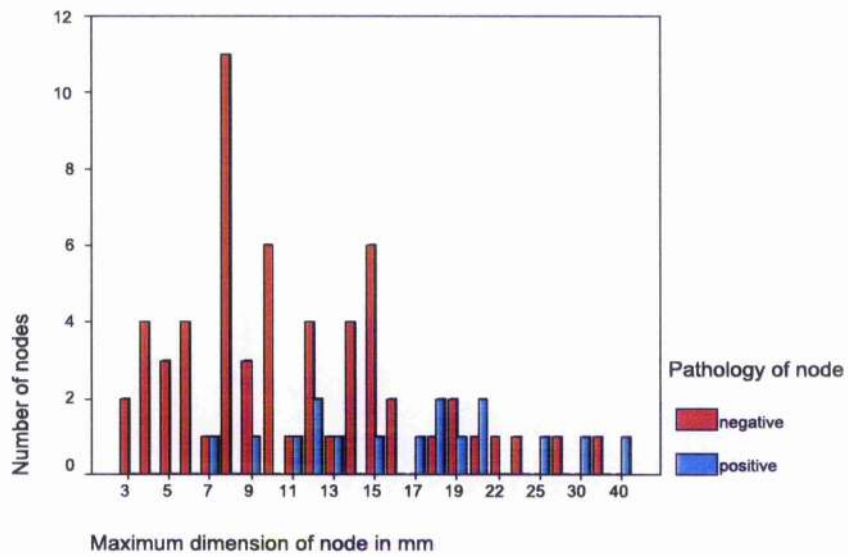


Figure 27: A comparison of nodal volume and amount of radioactivity, showing the best fit curve

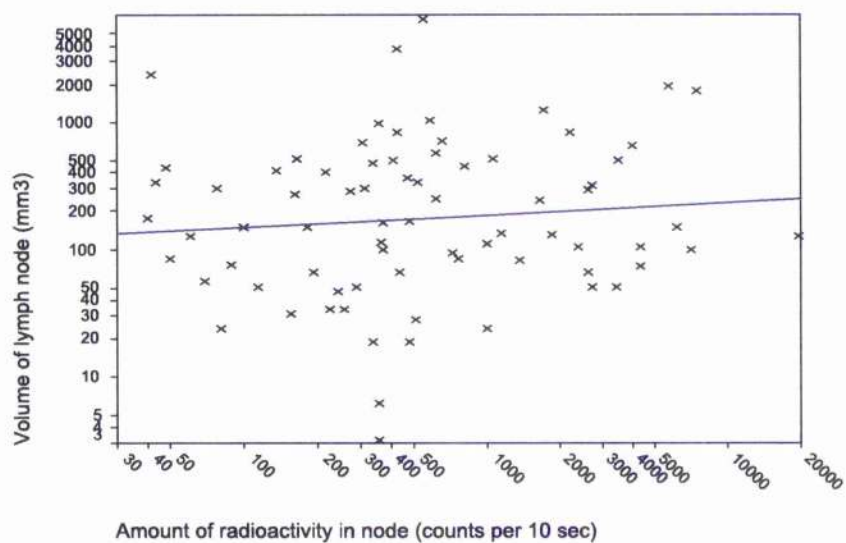


Figure 28: Comparison of tumour radioactivity by positive and negative sentinel nodes

(original in colour)

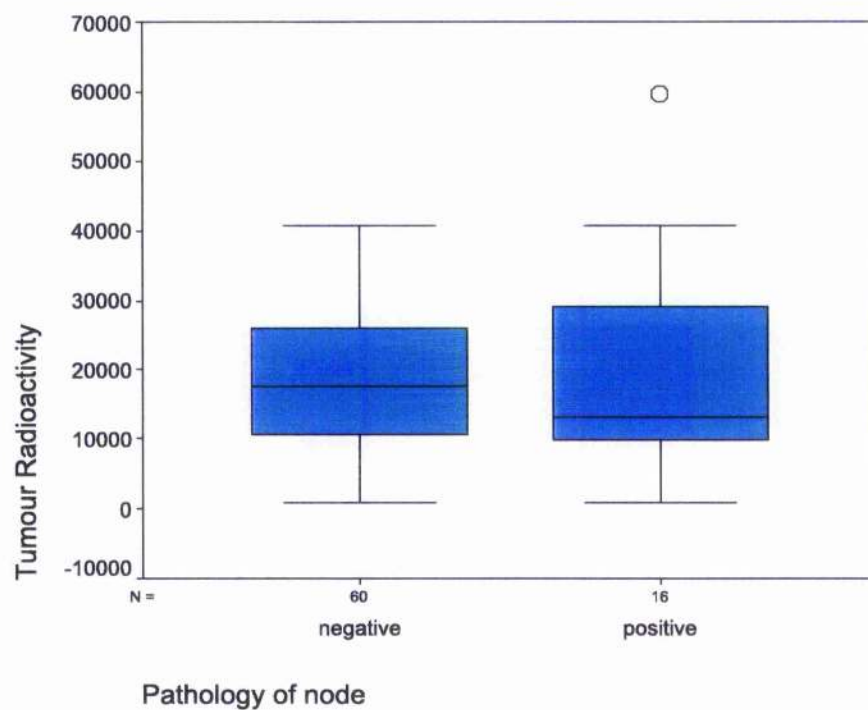


Table 12: The rank (per patient) of radioactive nodes with their pathology

Hottest Node in Patient	Pathology of node		Total
	negative	Positive	
Hottest node in patient	25	9	34
2 nd hottest node in pt	15	4	19
3 rd hottest node in pt	11	1	12
4 th hottest node in pt	4	2	6
5 th hottest node in pt	3		3
6 th hottest node in pt	2		2
Total	60	16	76

Table 13: The rank of the maximum diameter of the sentinel node per case compared with the pathology of the node

Maximum diameter of node per patient	Pathology of node		Total
	negative	positive	
Largest node in patient	25	12	37
2 nd largest node in pt	13	3	16
3 rd largest node in pt	13	0	13
4 th largest node in pt	5	1	6
5 th largest node in pt	2		2
6 th largest node in pt	2		2
Total	60	16	76

CHAPTER 8: THE ANATOMICAL SITE OF SENTINEL LYMPH NODES IN THE NECK

INTRODUCTION

Lymphoscintigraphy and sentinel node biopsy have identified first echelon nodes at clinically unpredictable sites in breast cancer and melanoma. These nodes are first echelon nodes but represent the varied direct lymphatic drainage of tumours.

In cutaneous melanoma, the sentinel nodes are found at unpredictable sites in up to 25% of reports^{137;184;185;187;189;244;245}. For example, lymph node drainage of the skin of the back has been described to the intra-abdominal region¹⁸⁸, drainage from the forearm has been seen to go directly to the supraclavicular nodes¹⁸⁶, head and neck melanoma has been seen to bypass nodes in close proximity to the tumour to pass into nodes located at unusual sites¹³⁴, and finally, lymph nodes in the neck have received drainage from tumours located in the upper thorax²⁴⁶.

In breast cancer sentinel node biopsy, a similar, though less varied pattern has been seen. Lesions located laterally in the breast have drained directly to the intercostal nodes and first echelon nodes have been seen in the supraclavicular region, the infraclavicular region and even to the contralateral chain of internal mammary or axillary nodes²⁴⁷.

In head and neck cancer, the nodes most likely to be involved in cancer are those located in levels I-III²⁴⁸. Level IV nodes are involved in approximately 5% of clinically node negative necks and level V involvement in the clinically N0 neck is exceedingly rare^{24;52;249}. Thus, a supraomohyoid neck dissection is often used for staging purposes²⁵⁰. Regional failure following a pathologically negative

supraomohyoid neck dissection occurs in approximately 5% of cases, and these can be both within the operated field or out with the operated field⁸⁶. If the recurrence is out with the operated field, the node dissection failed to include the first echelon nodes for the tumour.

Although the patterns of lymph node metastases for head and neck cancer are known from both retrospective studies and from cadaveric studies little is known on the dynamic drainage of lymph from the upper aerodigestive tract. For example, Figure 29 shows the drainage of the tongue to be to nodes situated in levels I-III, and as such a neck dissection is used in many centres for staging tongue cancers.

This part of the study was performed to map the anatomical location of sentinel nodes from various anatomical sites to the neck to determine the pattern of lymph flow from primary site to sentinel nodes, in those cases where sentinel node pathology accurately reflected that of the remainder of the neck.

METHODS

Patients included in the study were those who had sentinel node biopsy performed using a combination of radiocolloid and blue dye. Only those cases where the sentinel node pathology was a true indicator of the neck pathology were included. Thus, all true positive and true negative sentinel node biopsies were included. Patients with pN+ necks were included in the study if the sentinel node also contained tumour. Excluded were those cases where the sentinel node did not reflect the neck pathology. This included patients with clinically N0 (cN0) and clinically node positive (cN+) necks where the sentinel node was apparently free from tumour. Patients were excluded if they had undergone a sentinel node biopsy in the

absence of a neck dissection since the sensitivity of the procedure is currently unknown and will only emerge with extended follow-up.

Patients were categorised by primary site. The tumour location was recorded as floor of mouth (FOM), tongue, retromolar trigone, soft palate, hard palate, buccal mucosa, tonsil and lip. The level within the neck site of the sentinel nodes was recorded to obtain the position of the sentinel nodes. Each neck explored for a sentinel node was considered a single case.

RESULTS

One hundred and twenty four sentinel nodes were harvested from 52 necks. The distribution of primary tumours is shown in Table 14. Results were considered by tumour site.

TONGUE TUMOURS

Twenty-three necks were explored for sentinel nodes in patients with tongue malignancies. Four cases of ventral tongue tumours which encroached onto the anterior floor of mouth were included as tongue tumours. In all cases, the sentinel node pathology reflected that of the neck. Twenty-one cases were squamous cell carcinomas and two were melanomas. Sixty-five nodes were found in total. Six sentinel nodes were found in level I, 34 were found in level II, 21 were found in level III and four in level IV. Lymphoscintigraphy identified one "hot spot" within the tonsils from a mid-lateral oral tongue tumour (Figure 30); a tonsillectomy was not performed to harvest a sentinel node in the patient, who was subsequently staged as pN0.

Three sentinel nodes from well lateralised tongue cancers were found in the contralateral neck and one sentinel node in level II was found in level IIb. Two of the level IV nodes contained tumour but the

nodes in level IIb and in the contralateral neck did not contain metastases. Figure 31 summarises the percentages of the locations of sentinel nodes.

FLOOR OF MOUTH TUMOURS

Fourteen necks were explored for sentinel nodes in patients with FOM cancers. In all cases, the sentinel node pathology reflected that of the neck. Twenty-eight nodes were found in total. Five nodes were found in level I, 15 nodes were found in level II and eight nodes were found in level III. Figure 32 shows the percentage distribution of sentinel node locations from cancers of the FOM.

RETROMOLAR TRIGONE TUMOURS

Five necks were explored for sentinel nodes in patients with RMT cancers. In all cases, the sentinel node pathology reflected that of the neck. Thirteen nodes were found in total. Two nodes were found in level I and 11 nodes were found in level II, this included one node in level IIb. The node from level IIb did not contain metastases. Figure 33 shows the percentage distribution of sentinel node locations from cancers of the RMT.

SOFT PALATE TUMOURS

Four necks were explored for sentinel nodes in patients with soft palate cancers. In all cases, the sentinel node pathology reflected that of the neck. Seven nodes were found in total. One node was found in level I, three nodes were found in level II, two nodes were found in level III, no nodes were found in level IV and one node was found in level V. The node in level V did not contain metastases. One "hot spot" on lymphoscintigraphy was found to be an area within the tonsils (Figure 34). The tonsils were not explored in this case, and no sentinel node from the tonsil was harvested.

Figure 35 shows the percentage distribution of sentinel node locations from cancers of the soft palate.

BUCCAL MUCOSA TUMOURS

Two necks were explored for sentinel nodes in patients with buccal mucosa cancers. In both cases, the sentinel node pathology reflected that of the neck. Five nodes were found in total. Two nodes were found in level I, one node was found in level II and two nodes were found in level III.

HARD PALATE TUMOURS

Two necks were explored for sentinel nodes in two patients with hard palate cancers. One case was a squamous cell carcinoma and one was a malignant melanoma. Two nodes were found, both in level I but in one case the node was found in the contralateral side of the neck to the tumour. The node found on the contralateral side of the neck was found in a patient with oral melanoma and contained melanin pigmentation within macrophages.

TONSILLAR TUMOURS

Two necks were explored for sentinel nodes in patients with tonsillar tumours. Three sentinel nodes were found in level II.

LIP TUMOURS

In one case of a lip tumour, the sentinel node was found in level II.

DISCUSSION

This part of the study was performed to map the spread of colloid and blue dye from primary site to sentinel node in the 52 cases of true positive or true negative sentinel node biopsy. Although there were some unexpected sites of first echelon nodes most sentinel nodes were found as clinically expected in levels I-III. Of the 124

sentinel nodes that were harvested, 113 (91%) were found in the ipsilateral levels I-III.

Sentinel nodes were found in level IIb. Although level IIb is part of a neck dissection in which level II is removed, there has been recent debate over the need for exploration of this, the most technically challenging part of dissecting level II²⁵¹. Since sentinel nodes were found in this regions, if a neck dissection is to be performed to accurately stage the neck, then all sentinel node regions should be dissected. The nodes in level IIb did not, however, contain metastases.

Sentinel nodes were found at unexpected sites. Nodes were located in level IV, level V, in the contralateral neck from well lateralised tumours and in the tonsils, though in the latter case tonsillectomies were not performed. Four nodes were located in level IV, one node was found in level V, four nodes were found in the contralateral neck and two nodes were identified during lymphoscintigraphy in the tonsils. One contralateral node was found to contain evidence of possible early tumour spread and two of the sentinel nodes in level IV were found to contain tumour. Thus, in total there were 11 nodes (including the tonsillar sentinel nodes) found at unpredictable sites. With the addition of two tonsillar sentinel nodes, the total number of nodes would have been 126 and so 9% of nodes were at unusual sites. It is unusual to see tonsillar metastases from tumours located in the oral cavity and level V nodal involvement is exceedingly rare in the cN0 neck^{24;52;252}.

Sentinel node biopsy is redefining lymphatic flow from our traditional belief. There is considerable variability of lymphatic drainage between individuals, even from those sites where it was thought to be highly predictable. This study has confirmed that the variability in lymphatic drainage seen in sentinel node biopsy of breast cancer and

cutaneous melanoma is also seen in oral and oropharyngeal cancer sentinel node biopsy.

TABLES AND FIGURES

Figure 29: Cadaveric studies demonstrating tongue lymphatic drainage (from Human Anatomy, Churchill Livingstone, 3rd Edition, 1982)

(original in colour)

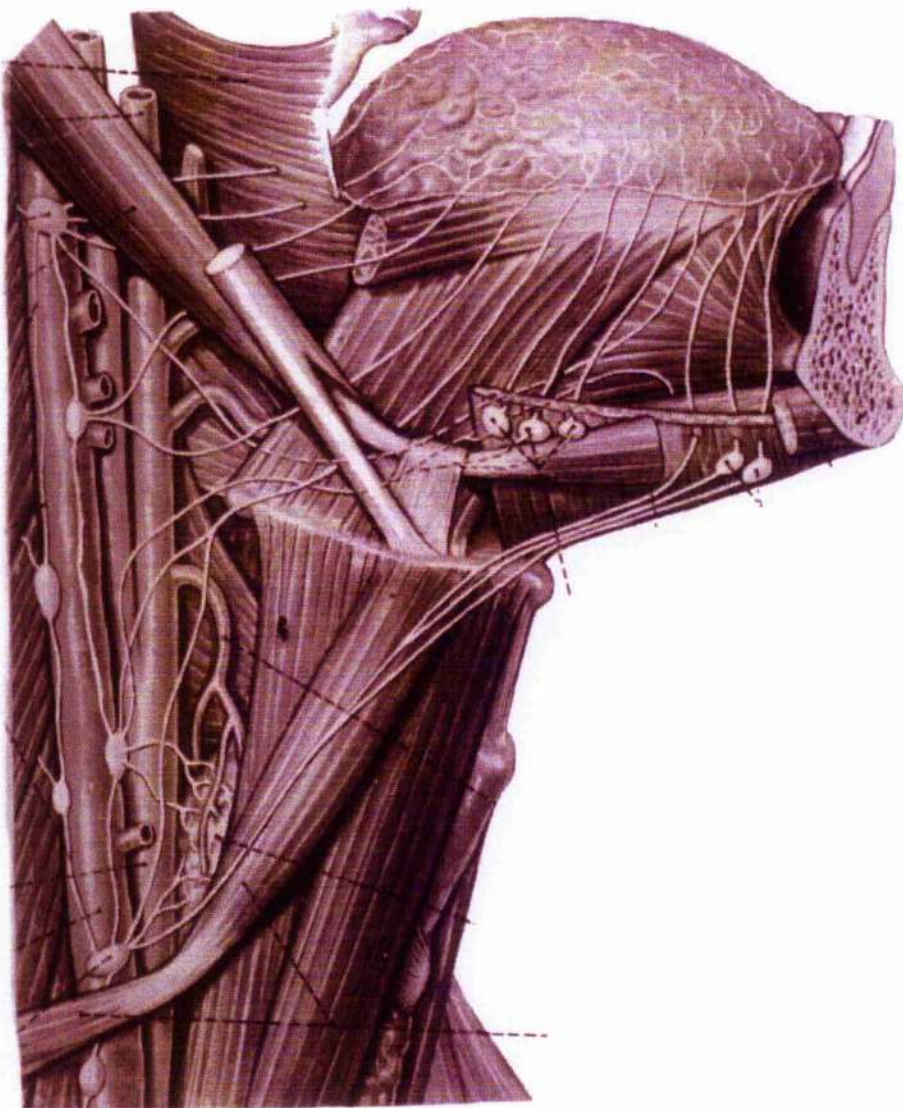


Figure 30: Lymphoscintigraphy image of sentinel nodes from a lateral tongue tumour – the highest hot spot was found to be located in the tonsillar region at operation
(original in colour)

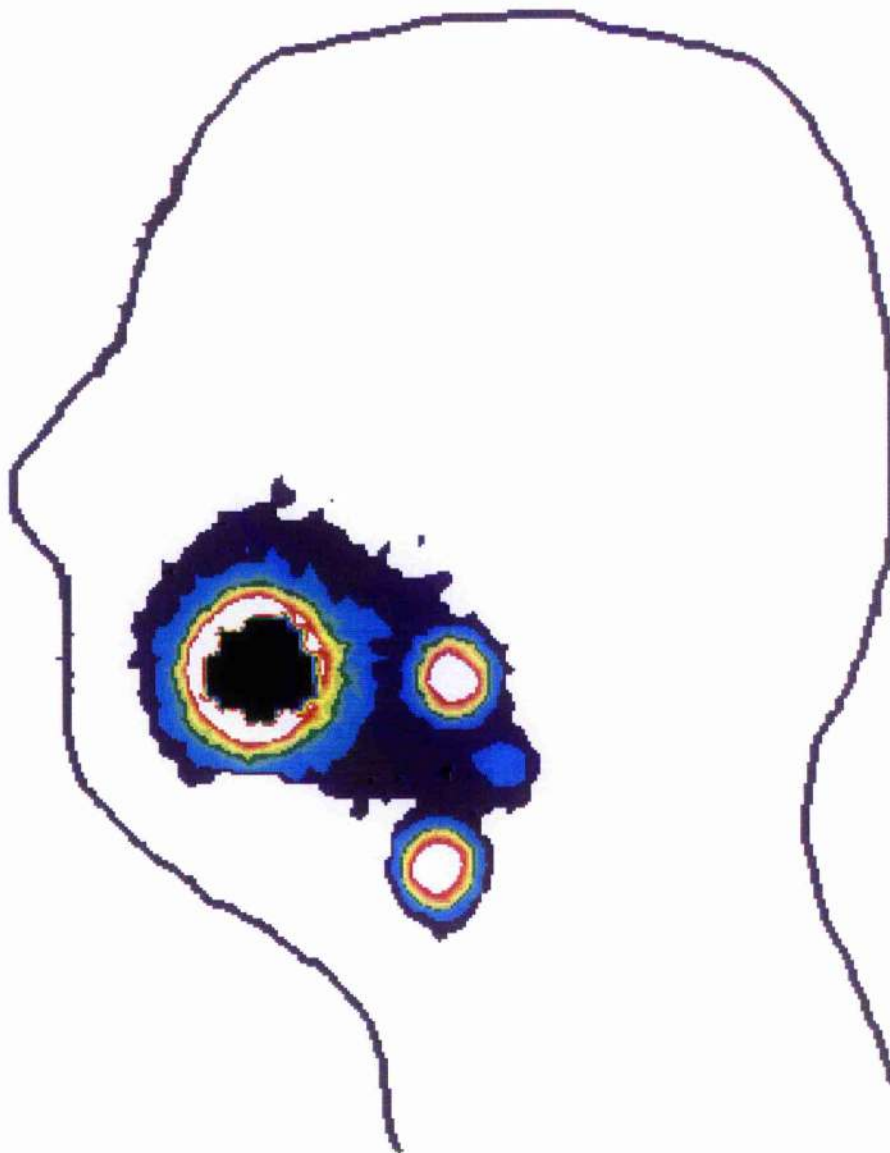


Figure 31: Tongue cancer sentinel node distribution

(original in colour)

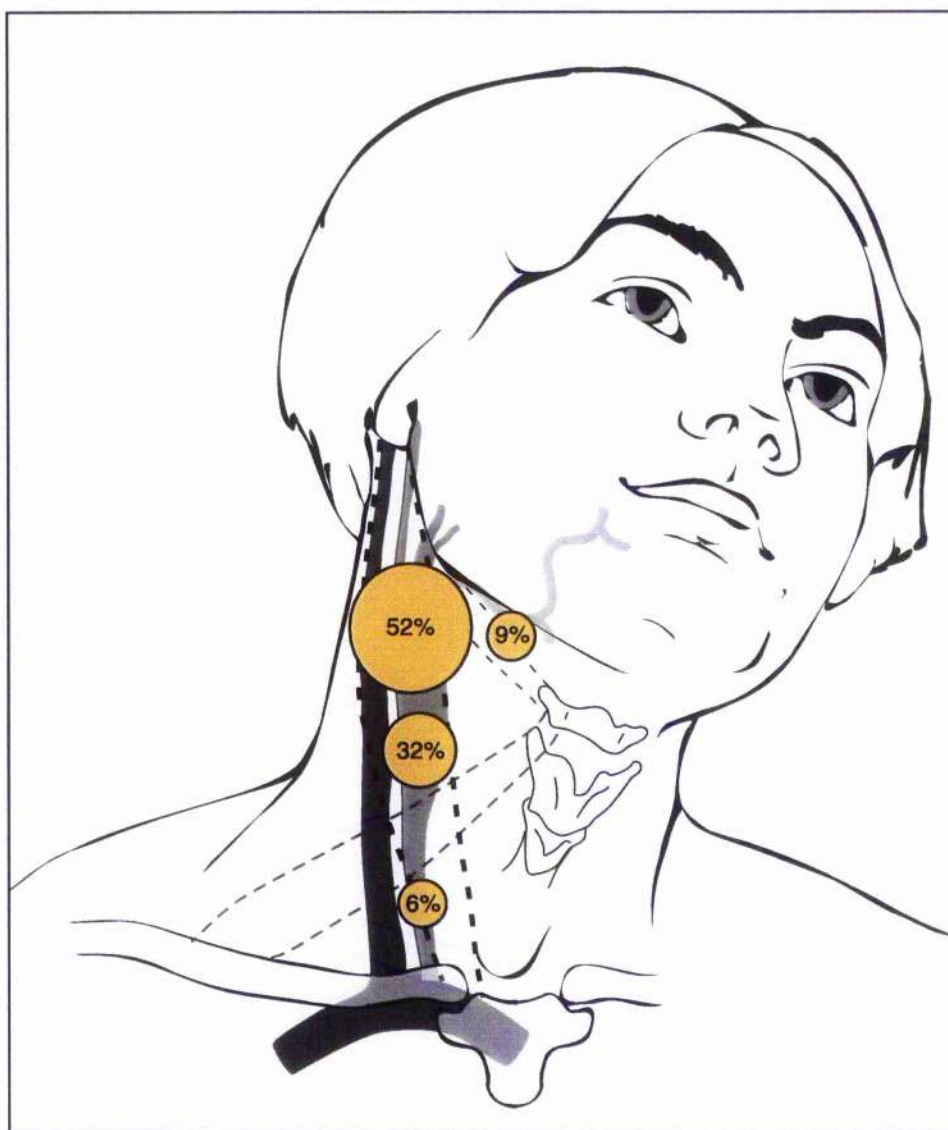


Figure 32: FOM cancer sentinel node distribution

(original in colour)

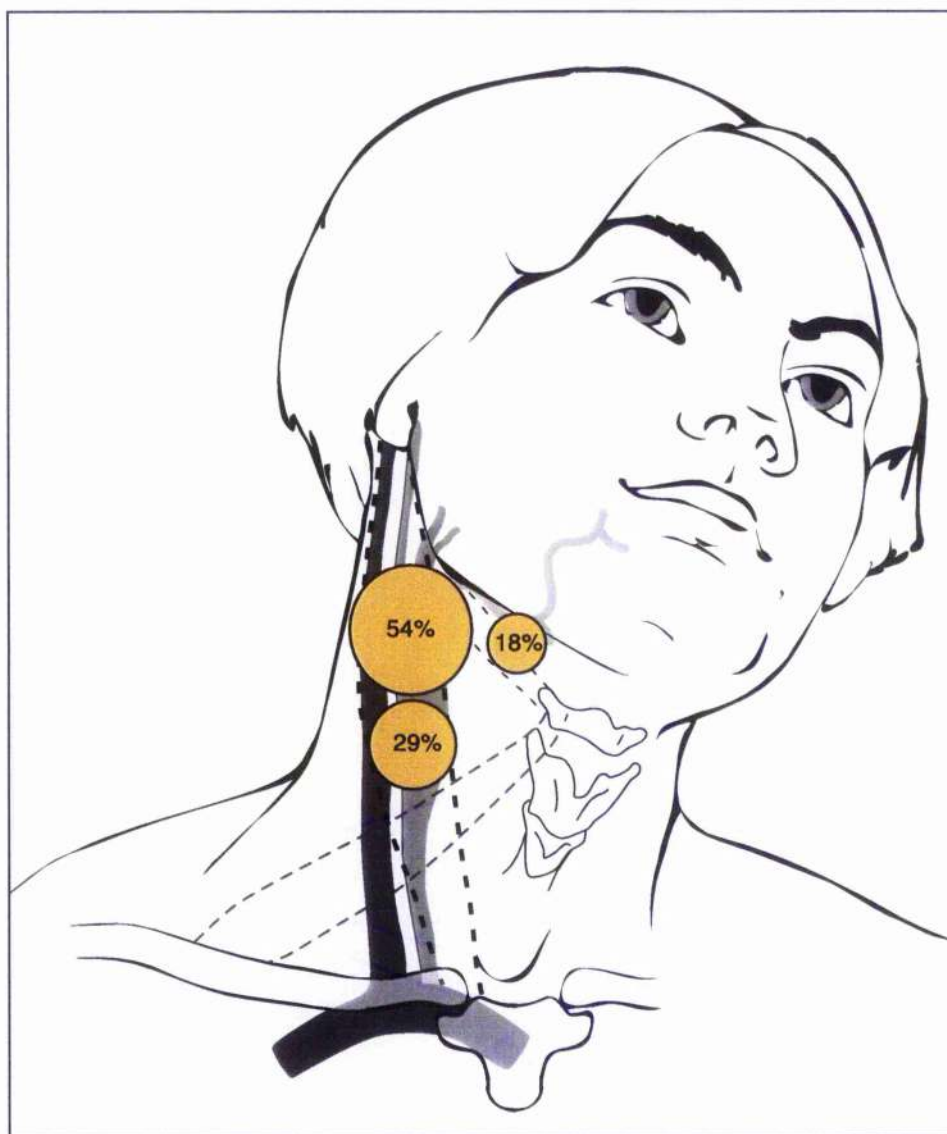


Figure 33: RMT cancer sentinel node distribution

(original in colour)

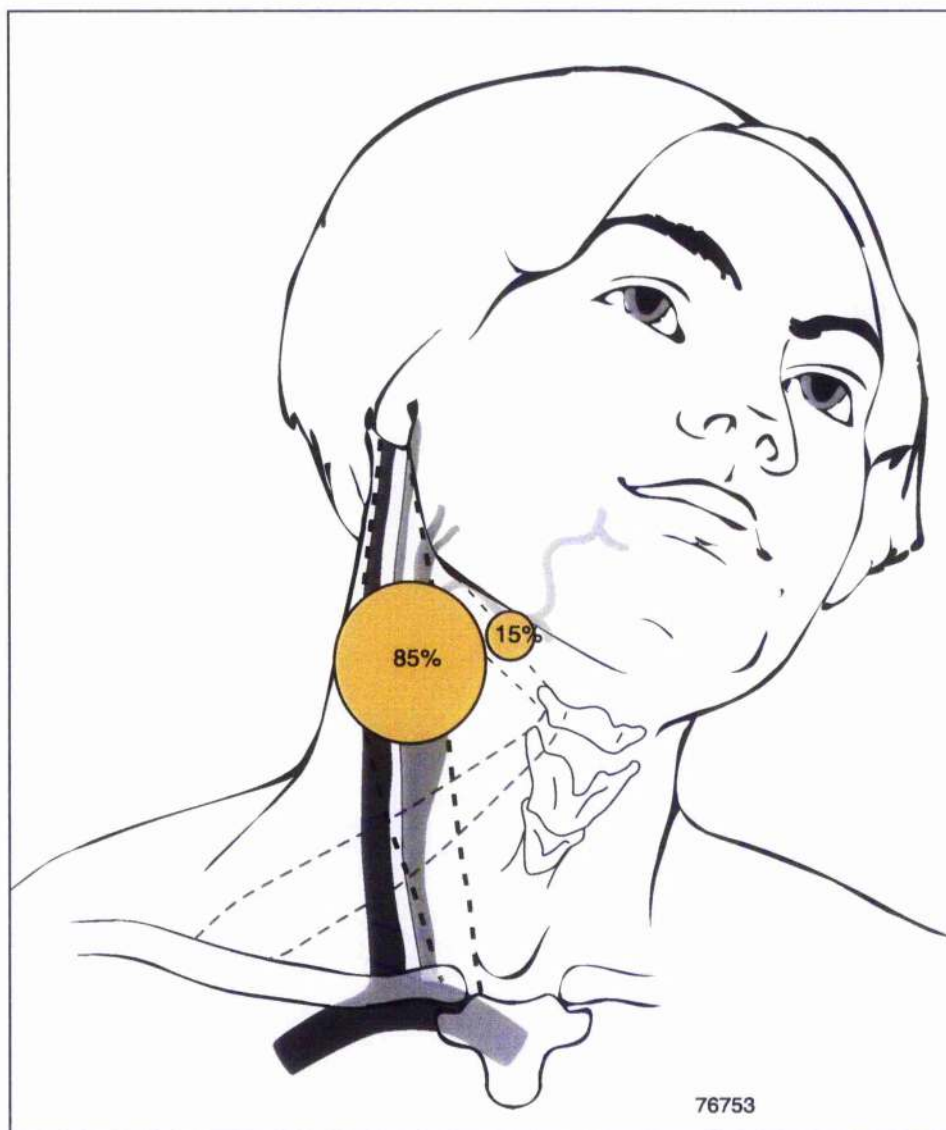


Figure 34: Lymphoscintigraphy highlighting two sentinel nodes in the neck and one sentinel node in the tonsillar region

(original in colour)

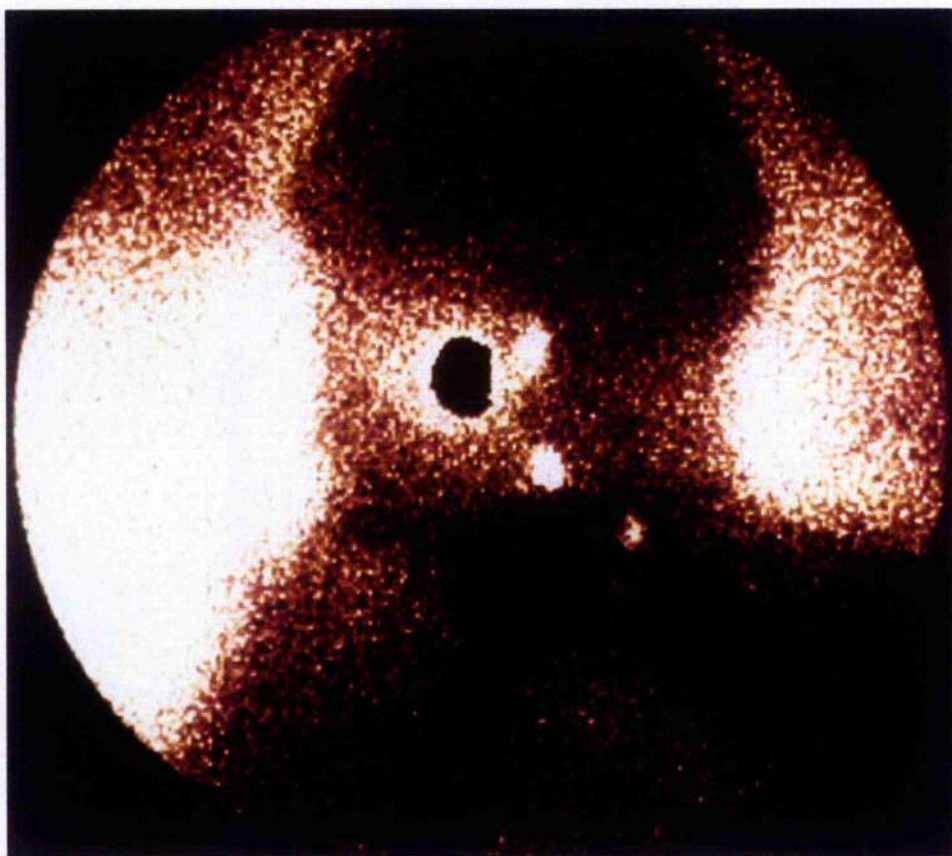


Figure 35: Soft palate cancer sentinel node distribution

(original in colour)

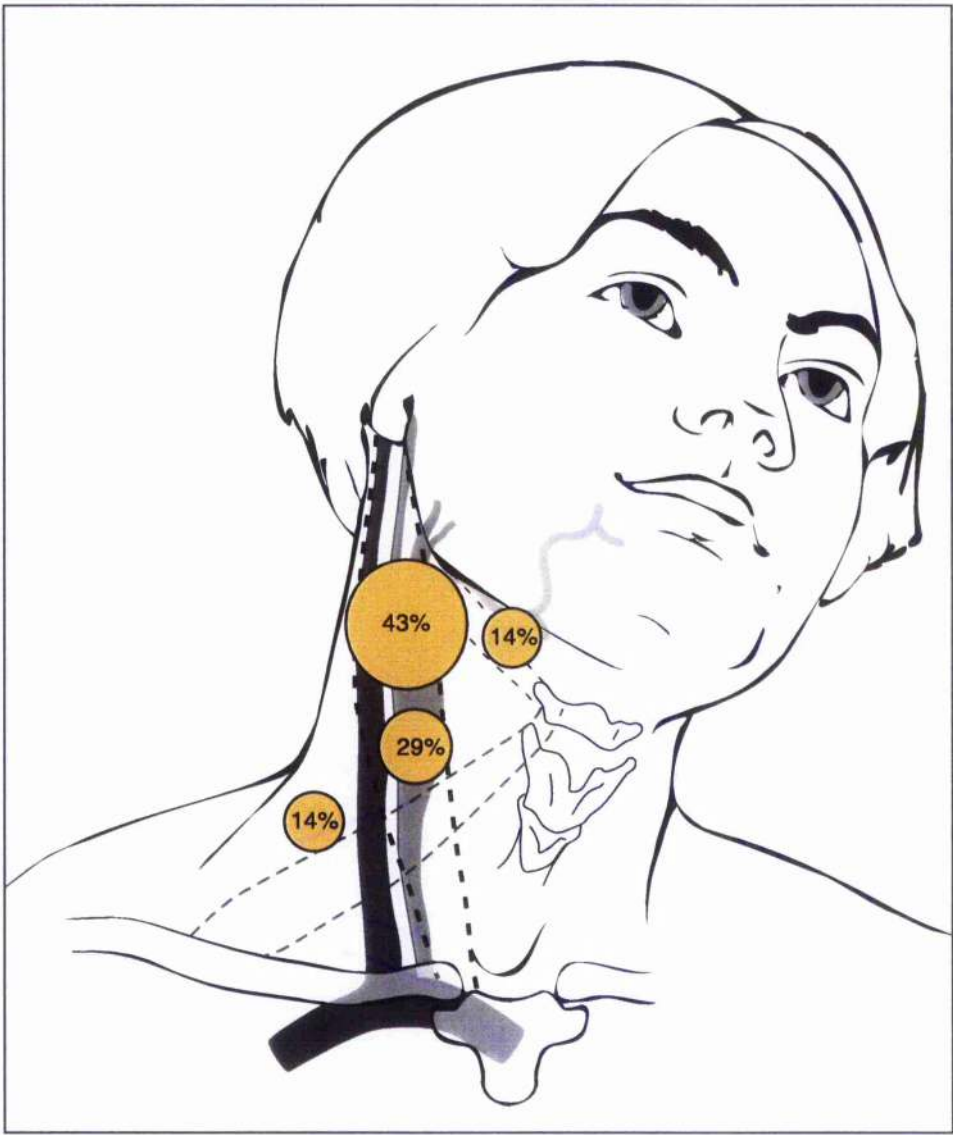


Table 14: Distribution of tumour and nodes where sentinel node pathology reflected that of the remaining neck nodes

TUMOUR SITE	NUMBER OF CASES	NUMBER OF SENTINEL NODES	MEAN NUMBER OF NODES PER CASE
Tongue	23	65	2.8
FOM	14	28	2
RMT	5	13	2.6
Soft palate	4	7	1.75
Buccal mucosa	2	5	2.2
Hard Palate	2	2	1
Tonsil	2	3	1.3
Lip	1	1	1

CHAPTER 9: SENTINEL NODE BIOPSY TO TARGET NECK DISSECTION AT THE CLINICALLY FALSE NEGATIVE NECK

INTRODUCTION

Sentinel node biopsy has become the standard of care in cutaneous melanoma in the USA, although in breast cancer it has not yet replaced axillary node sampling²⁵³⁻²⁵⁶. In the USA, it was common practice to perform elective neck dissections on patients with melanomas, since one randomised controlled trial had shown elective lymph node dissection to be of possible benefit in a subgroup of patients²⁵⁷.

Sentinel node biopsy has now replaced elective node dissection as the standard of care in cutaneous melanoma²⁵⁸. The pathological status of the sentinel node is the most accurate prognostic indicator of recurrence^{259;260}, and patients with a sentinel node free of tumour are unlikely to develop further regional recurrence²⁶¹. This is reflected in the new American Joint Committee on Cancer (AJCC) staging system that has been proposed for melanoma which will be used from 2002²⁶². In the new system, patients with subclinical nodal metastases will be upstaged. Subclinical disease may be determined with a sentinel node biopsy in the new AJCC TNM classification.

The concern that a surgical procedure to excise a lymph node containing tumour within the regional lymph node basin will compromise the oncological management of the patient has been addressed recently²⁶³. The results of this study suggest that subsequent regional failure following a positive sentinel node biopsy and lymph node dissection is a function of tumour aggression rather than surgical interruption of metastatic lymphatics, although this

study was performed in melanoma patients and the results may not necessarily be transferable to oral SCC patients. Additionally, the follow up in this paper is somewhat limited.

Thus it can be seen that sentinel node biopsy has been successfully applied to other cancers, particularly cutaneous malignant melanoma, and the procedure can accurately stage the regional lymph node basin without compromising the oncological safety of patient management. This section of the study was performed to determine whether the sentinel node could be identified in head and neck cancer patients, out with the context of a neck dissection. The aims were to harvest the sentinel node and examine the node for pathological evidence of tumour. The sensitivity of the procedure was not one of the aims of the study, since this would require long term follow-up, and forms the basis of another study.

METHODS

Patients were entered into our study following ethical approval from the local ethics committee and informed consent. Up to 24 hours prior to surgery, patients were injected with up to 40MBq of colloidal human serum albumin (HSA) in a volume of up to 1ml to completely surround the tumour on the lateral and deep aspects. The colloid used varied with anatomical site of primary. Albures (Nycomed Amersham, High Wycombe, Bucks, UK) was used for primaries of the tongue and floor of mouth. Nanocoll (Nycomed Amersham, High Wycombe, Bucks, UK) was used for primaries of other anatomical sites. Following injection of colloid, patients were given a mouthwash to prevent pooling and swallowing of radioactivity. Static lymphoscintigraphy was performed using a gamma camera fitted with a low energy, general purpose collimator and a 20% window was selected at the 140keV photopeak. Lymphoscintigraphy was

performed at 15 minute intervals up to one hour following injection, or until the first appearance of radioactivity within the neck. The site of the radioactive nodes were marked on the skin of the neck and images were acquired.

During surgery, Patent Blue V dye (Laboratoire Guerbet, Aulnay-Sous-Bois, France) was injected at the same sites as radiocolloid, in a volume of up to 2ml. A neck incision was made from the anterior border of the sternomastoid muscle to the lateral border of the strap muscles of the neck and subplatysmal flaps were raised to explore the neck. The hand held gamma probe was used to identify radioactive nodes and blue lymphatics were traced to blue lymph nodes. All sentinel nodes were identified in their anatomical groups. All blue and radioactive nodes were harvested as sentinel nodes and the presence of radioactivity within sentinel nodes was confirmed *ex-vivo*. The surgical procedure was completed by suitable treatment of the primary and the insertion of a small drain into the neck. No nerve damage occurred to the spinal accessory nerve in this series of patients.

Frozen section analysis of the sentinel node was used in one case only. In the remaining cases, following fixation, lymph nodes were bisected through their hilum, if identifiable, or long axis. Both sections from each half was processed for evidence of tumour on H&E staining. If nodal metastases were identified, the patient was informed and was advised to undergo a modified radical neck dissection. The neck dissection was therapeutic and permitted formal pathological staging of neck disease. If the sentinel node was free of tumour, no further treatment to the neck was performed. Patients were followed for 6-14 months following their procedure.

No patient required access to the neck and mandibulotomy for access to the tumour, as is occasionally required in retromolar

trigone tumour ablation. A laser was not used for surgical excision, and all patients underwent scalpel tumour excision. One patient underwent free flap reconstruction to the resulting defect of a floor of mouth tumour. All remaining patients underwent either direct closure, local flap or skin grafting to the ablative defect.

RESULTS

Sixteen patients were investigated. The male: female ratio was 3:1 and the mean age was 58 years (range 33-88). Sentinel nodes were found in 15 of 16 patients. One patient with a T2 midline SCC of the dorsum of tongue had lymph drainage to both necks and so 16 neck sides were explored for sentinel nodes. Eleven patients were classified as T1, three as T2 and 2 as T4. The size of the T4 tumours was not measured by CT scanning, but determined clinically at examination under anaesthesia by an experienced consultant.

Carcinoma of the tongue comprised seven cases, seven cases were carcinomas of the floor of mouth, one was a T2 SCC of the retromolar trigone and one case was a T4 SCC of the upper alveolus.

The total number of sentinel nodes harvested was 34 (mean per patient 2.1) Eleven nodes were hot, 2 nodes were blue and 21 nodes were hot and blue. The figure below shows the number of sentinel nodes harvested from each patient and the figure below shows the neck levels from which sentinel nodes were harvested.

Two sentinel nodes contained tumour from two patients and a modified radical neck dissection was subsequently performed in each case. In the first case, the sentinel node was a hot blue node from level III in a patient with a T1 floor of mouth tumour. A modified radical neck dissection was subsequently and a further two nodes

(from levels I and II) were found to contain tumour. In the second case, the sentinel node containing tumour was a hot blue node from level I in a patient with a clinically T1 lateral tongue tumour, which was pathologically classified as T4. A subsequent neck dissection was performed and no other nodes contained tumour. Frozen section pathological examination of the sentinel node was used in one patient, in whom a decision was made to minimise the number of potential surgical procedures. Sentinel node pathology was negative and no neck dissection was performed.

No patient has subsequently developed nodal disease within the very short follow-up time. No patient with a sentinel node free of tumour metastases has undergone any elective treatment to the neck in the form of surgery or radiotherapy and long term follow-up is being performed on all patients entered into our on-going study.

DISCUSSION

This study was performed to determine if the sentinel node could be identified in patients undergoing no elective treatment to the neck. When using a combination of blue dye and radiocolloid injection, our success rate in identifying sentinel nodes within the neck is 15/16 (94%). This compares favourably with the rate of sentinel node identification in patients undergoing sentinel node biopsy for cutaneous lesions of the head and neck^{89;156;170;264;265}.

The procedure in head and neck cancer may be more technically demanding than in head and neck melanoma. Oral SCC lesions are usually ulcerated and are close to the primary site. Ulceration allows leakage of radiocolloid from the injection site into the mouth, where radioactivity may be pooled in the floor of mouth, or swallowed. In either situation, lymphoscintigraphy will identify areas of radiocolloid out with sentinel nodes. The close proximity of sentinel nodes to the

primary site, especially when the primary site is the floor of mouth, renders gamma probe identification of radioactive nodes in the submandibular and submental triangles difficult. By using a series of malleable lead plates to shield the injection site, shine through and scatter from the primary site is reduced and radiolocalisation is aided. The use of blue dye for level I exploration also aids in the identification of sentinel nodes.

Human serum albumin (HSA) is available in two preparations, Albures and Nanocoll. Albures has a mean particle size of 500nm and that of Nanocoll is 80nm. The former passes from injection site to lymph nodes slowly and requires a high density of terminal lymphatics within the tissues to enter the sentinel node but remains within the first echelon node, whereas Nanocoll passes easily from injection site to lymphatic vessels but also passes from the first echelon lymph node to non-sentinel nodes. The choice of colloid was determined by the site of primary disease. Lesions of the tongue and floor of mouth were injected with Albures and primaries at other sites were injected with Nanocoll. There is no consensus of opinion as to which is better for sentinel node localisation in head and neck SCC, however our experience suggests that the choice of colloid can be determined with the site of the primary, particularly in view of the density of terminal lymphatics within the differing oral tissues. Future studies should explore the use of different colloids as part of a randomised controlled trial.

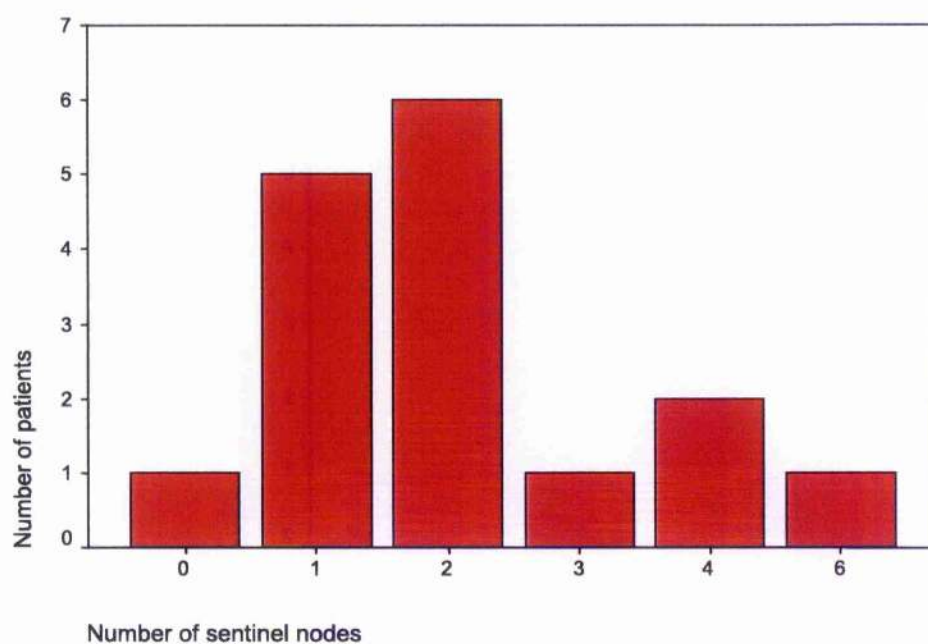
Using these colloids with pre-operative lymphoscintigraphy and per-operative use of the hand held gamma probe in addition to blue dye visualisation, sentinel node biopsy may ultimately become an alternative to a "wait-and-see" approach to the clinically N0 neck. Clearly, however, sentinel node biopsy will require further studies

before it becomes the standard of care in patients with early cancers of the oral cavity rather than elective "staging" neck dissection.

TABLES AND FIGURES

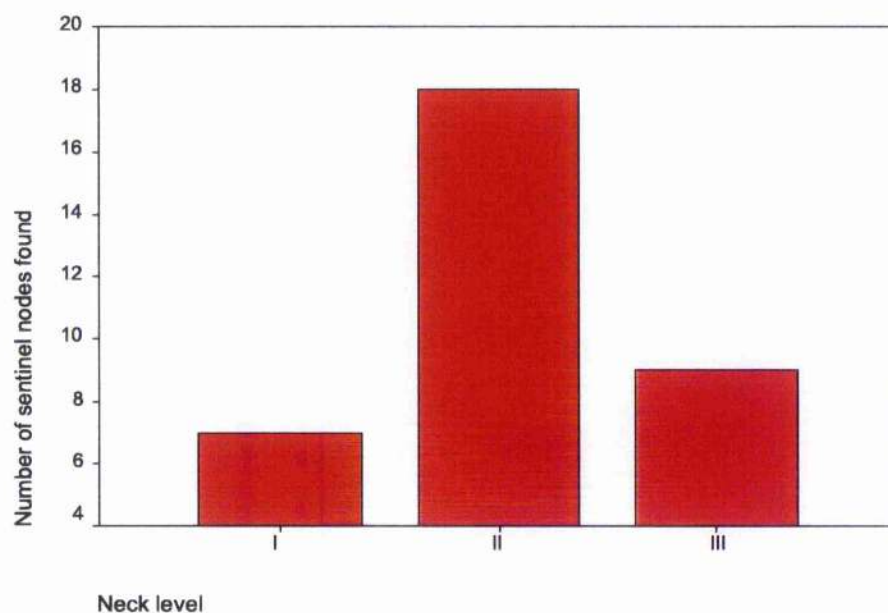
Figure 36: Number of sentinel nodes per patient in those undergoing sentinel node biopsy only

(original in colour)



**Figure 37: Sentinel node locations in patients undergoing
sentinel node biopsy only**

(original in colour)



CHAPTER 10: OVERALL RESULTS

INTRODUCTION

In this study, sentinel node biopsies have been performed on patients with mucosal head and neck cancers. Each neck side explored for sentinel node biopsy has been considered a single case, since one of the main aims of the project was to determine whether the sentinel node could correctly identify the presence of tumour in the neck of patients with head and neck cancer.

Sentinel node biopsy using blue dye alone was performed in 16 cases (in 16 patients), sentinel node biopsy using a combination of blue dye and radiocolloid was performed in 40 clinically N0 necks (from 37 patients) and 27 clinically N+ necks (from 25 patients) in patients where neck dissections were also performed. Additionally, 17 necks were explored in 16 patients for sentinel nodes who did not initially undergo a neck dissection and three necks were explored for sentinel nodes in two patients with oral melanoma. In total, 103 necks were explored for sentinel nodes in 96 patients.

BLUE DYE SENTINEL NODE BIOPSY

Sentinel node biopsy using blue dye alone was performed in 16 cases. Eight of these were in the clinically N0 neck and eight were in the clinically N+ neck.

In the clinically N0 group, four patients were pN0 and four were pN+. In the pN+ group, a blue node was found in two cases but these blue nodes did not contain tumour. In the pN0 group, a sentinel node was found in all four cases and the sentinel node was free from apparent metastases, by definition.

In the clinically N+ group, seven cases were pN+ and one case was pN0. In the pN+ group, a blue node was found in one case but did not contain tumour. In the one pN0 case, no sentinel node was found.

Thus, sentinel nodes were found in seven cases of 16 and none of these contained tumour by routine pathology. In these seven cases, tumour was present in the neck in three cases, and in each case a sentinel node did not contain tumour. In conclusion, sentinel node biopsy using blue dye alone was not successful as a staging procedure.

SENTINEL NODE BIOPSY WITH BLUE DYE AND RADIOCOLLOID

Sentinel node biopsy using radiocolloid in addition to blue dye injection was performed in 86 of the remaining 87 cases. In one patient with oral melanoma, the sentinel node was harvested using only radiocolloid, since it was felt that injection of blue dye into the mucosa would potentially compromise the oncological safety of the excision of the primary tumour, by blurring its margins.

CHOICE OF COLLOID IN HEAD AND NECK CANCER SENTINEL NODE BIOPSY

Sixty-seven necks were explored for sentinel nodes, in 62 patients undergoing a neck dissection for squamous cell carcinoma of the oral cavity or oropharynx. Each neck side was considered a single case. In patients with floor of mouth cancer 18 necks were explored and the colloid used was Albures in all cases. A radioactive node was found in 14 of these 18 (78%). In patients with tongue cancer, 26

necks were explored and the colloid used was Albures in all cases. A radioactive node was found in 21 of the 25 necks (84%).

In patients with tumours of other sites within the head and neck, Albures was used in eight cases and Nanocoll was used in 15. When Albures was used a hot node was found in three of eight cases (38%) and when Nanocoll was used a hot node was found in 13 of 15 (87%). This difference was statistically significant using the Mann-Whitney U test ($p=0.15$).

THE CLINICALLY N0 NECK

Using a combination of blue dye and radiocolloid injection, 40 cases of sentinel node biopsy were performed on 37 patients with cervical nodes clinically clear of metastases. One case was staged clinically as Nx in a patient with long standing cervical lymphoma and was included in the results of the clinically N0 group. Sentinel nodes were found in 35 of these 40 cases (88%). Twenty cases were pathologically N0 and 20 were pN+. In the 20 pN0 cases, sentinel nodes were found in 19 cases (95%) and, by definition, the sentinel node was free from apparent tumour. The remaining 20 cases were staged pN+ with routine histology. In these cases, a sentinel node was found in 17 cases (85%) and contained tumour in 16 (94%). In 12 of these 16, the sentinel node was the only node containing tumour. In these 16 cases, 18 sentinel nodes contained tumour, of which the node was hot and blue in 10, hot only in six and blue only in two. In three of four cases where sentinel nodes were not identified in the neck, the neck nodes contained tumour.

THE CLINICALLY INVOLVED NECK

Sentinel node biopsy was performed in 25 patients undergoing 27 therapeutic neck dissections. In 18 cases (17 patients), sentinel node

biopsy was performed using the large diameter radiocolloid Albures and in 9 cases (8 patients), sentinel node biopsy was performed using the smaller diameter radiocolloid Nanocoll. In the 17 cases in which Albures was used, a sentinel node was found in 15. Of these 15, tumour was found in the neck in 12 and the "sentinel" node contained tumour in two of these 12 (14%). In the nine cases in which Nanocoll was used, a sentinel node was found in eight. The neck contained metastases in seven of these eight cases and the sentinel node was involved with overt metastases in six cases (86%). In conclusion, sentinel node biopsy using Albures was unsuccessful in the clinically N+ group, but when using Nanocoll, the procedure was more promising.

SENTINEL NODE BIOPSY IN ORAL MELANOMA

Sentinel node biopsy was performed in two patients with oral melanoma. One patient was suffering from a melanoma of the tongue and the other a melanoma of the hard palate mucosa. Sentinel nodes were found in both cases. Albures and blue dye was used for sentinel node biopsy in the tongue melanoma whereas Nanocoll was used to harvest the sentinel node in the palatal melanoma.

In the patient with a tongue melanoma, sentinel nodes were found in both sides of the neck despite the tumour being well lateralised. Six sentinel nodes were found, and none contained metastases. Three of the sentinel nodes were found in the ipsilateral neck and three in the contralateral neck but none contained tumour metastases.

In the patient with a palatal melanoma, the tumour was located to the left of the midline, and one sentinel node was found in the right submandibular region. Although the sentinel node did not contain

viable tumour, macrophages within the node were stained with melanin.

SENTINEL NODE SIZE AND RADIOACTIVITY

In patients undergoing a neck dissection, 34 necks were identified in which at least one radioactive node was present. Within these 34 necks, 76 sentinel nodes were radioactive. Tumour was present within 16 nodes and 60 nodes were free from tumour. In 14 cases a single hot node was found, two hot nodes were found in eight cases, three hot nodes were found in six necks, four hot nodes were found in three necks, five hot nodes were found in one neck and six hot nodes were found in two necks.

Lymph nodes containing tumour had a greater maximum diameter than those free from tumour. The mean maximum diameter of positive nodes was 18 mm and that for negative nodes was 11 mm.

Although there was no correlation between the amount of radioactivity in the node and likelihood of that node containing tumour, the hottest and largest nodes within each patient were the most likely to contain metastases. The three hottest sentinel nodes in each patient gave enough staging information for the neck of each patient to be accurately staged, as did the two largest sentinel nodes within the neck.

THE ANATOMICAL SITE OF SENTINEL NODES IN THE NECK

There were 124 sentinel nodes harvested from 52 necks in which the sentinel node pathology reflected that of the neck. Twenty three cases were of tongue tumours and 65 sentinel nodes were obtained from this group. Fourteen cases were of floor of mouth tumours and 28 sentinel nodes were obtained from this group. Five cases were of

retromolar trigone tumours and 13 nodes were obtained from this group. Four cases were of soft palate tumours and seven nodes were obtained from this group. The remaining cases were from tumours of the buccal mucosa (two cases, five nodes), hard palate (two cases, two nodes), tonsil (two cases, three nodes) and lip (one case, one node).

The sentinel nodes from tongue tumours were found mainly in levels I (six nodes), II (34 nodes) and III (21) within the neck. Sentinel nodes were also found in level IV (four nodes) within the tonsil (one node identified at lymphoscintigraphy but not excised), in the contralateral neck and in level IIB.

The sentinel nodes from floor of mouth tumours were found in levels I (five nodes), II (15 nodes) and III (eight nodes). No unusual sites of sentinel nodes were found in floor of mouth cancers.

The sentinel nodes from retromolar trigone tumours were found in levels I (two nodes) and II (eleven nodes). One node was found within level IIB.

The sentinel nodes from soft palate tumours were found in levels I (one node), II (three nodes), III (two nodes) and level V (one node). One node was also found in the tonsils during lymphoscintigraphy, but was not excised.

Sentinel nodes from tumours of the buccal mucosa, hard palate, tonsils and lip were found in levels I, II and III only.

SENTINEL NODE BIOPSY TO UPSTAGE THE CLINICALLY NO NECK

In 16 patients, 17 necks were explored for sentinel nodes. Sentinel node biopsy was performed using a combination of blue dye and

radiocolloid injection. In this setting, it was thought more appropriate to consider each patient as a single case, rather than each neck. Sentinel nodes was found in 15 of 16 patients (94%) and a tumour containing sentinel node was present in two patients. And these two patients underwent therapeutic neck dissections. Since follow up for this group of patients was short, the overall sensitivity of the procedure is not yet known.

CHAPTER 11: OVERALL DISCUSSION

In the studies enclosed within this Thesis, the sentinel node concept has been investigated in patients with head and neck cancer. The technique was initially applied with a view to formulate a method with which to identify the sentinel node. The technique with blue dye was discarded in favour of sentinel node biopsy using a combination of lymphoscintigraphy, blue dye and the hand held gamma probe. Subsequently, the Nuclear Medicine and Surgical techniques were refined to enable the harvesting of the sentinel node from the neck. Finally, the technique was applied to a group of patients in whom the clinical decision would have been to observe their neck. In this group, a neck dissection was only performed if the sentinel node was found to harbour subclinical metastases. The protocol for a multicentre trial was then written to formally evaluate and validate the accuracy and reproducibility of the procedure.

The sentinel node concept has recently become accepted as a means of identifying the presence of nodal metastases in a variety of cancers¹⁴⁵. The idea that lymph node metastases are embolic in nature and that nodal spread is both orderly and progressive has been shown to be valid in the context of many carcinomas that spread initially via the lymphatic system²⁶⁸.

The cancers most investigated are breast cancer²⁶⁷ and cutaneous melanoma²⁶⁸ where there is little debate over the accuracy of the technique. In both malignancies, the sentinel node accurately stages the regional lymph node basin in over 90% of cases^{175;269}. Additionally, in melanoma, the pathological status of the sentinel node is the most accurate prognostic indicator for regional recurrence. The chance of recurrence in patients with a sentinel node free of tumour, is approximately 10%²⁶¹, whereas that for patients

with a sentinel node containing tumour, despite the tumour thickness, is approximately 35%^{263,270}. This prognostic accuracy is reflected in the new proposed American Joint Committee on Cancer staging classification for melanoma, which will be used from 2002²⁵⁹, in which a patient with sentinel node metastases is upstaged. Whether knowledge of the status of the sentinel node pathology makes a difference to patient outcome is unknown but unlikely²⁷¹. However, this is being investigated in a large multicentre international study, co-ordinated at the John Wayne Cancer Institute in Santa Monica, California²⁷². This is a trial of primary excision alone versus wide excision and sentinel node biopsy. If the sentinel node is found to contain tumour in the group of patients that undergo a sentinel node biopsy, the patient undergoes a therapeutic lymph node dissection, and a therapeutic dissection is only performed in the group undergoing wide excision alone if subsequent clinical examination reveals lymphadenopathy. The end points of the trial are survival to five years, regional recurrence and death; the results of the trial will become available within a few years. Further trials are now emerging with patient stratification into various therapeutic arms depending on the status of the sentinel node²⁷³. If the sentinel node is merely an indicator of widespread disease, then patients with known metastases can be entered into trials of systemic therapy if the sentinel node contains tumour. Also, since approximately 75% of patients with nodal micrometastases in the sentinel node are free of metastases in the remaining lymph node basin²⁷⁴, further trials are underway to determine if a complete lymph node dissection is necessary following a positive sentinel node biopsy²⁷⁵, especially in patients with thin primaries, where the rate of non sentinel metastases in the presence of a pathologically involved sentinel node is even lower²⁷⁶. Again, the results of these trials will emerge with time.

Several controversies still exist surrounding the methodology of sentinel node biopsy in melanoma²⁷⁷ and breast cancer patients^{267;278}. In the nuclear medicine part of the procedure, unanswered questions include whether the patient should undergo dynamic as well as static lymphoscintigraphy, which colloid should be used, how often should scintillation images be taken and where should the injection be given (i.e. into the tumour, to surround the tumour or into the skin overlying the tumour in the case of breast cancer), the quantity of radiocolloid (in ml) and the amount of radioactivity in the colloid (in MBq) are also a matter for debate. Similarly, the controversies in the surgical technique include the amount of blue dye to use, whether the procedure can be performed with blue dye or radiocolloid only, which gamma probe should be used, whether all blue and radioactive nodes need to be excised or whether the hottest or first nodes encountered should only be removed. Controversial aspects of pathology include whether the sentinel nodes should be examined with multiple serial sections and with immunohistochemistry. If immunochemical stains are to be used, which stains should be used and on what levels remains unanswered, as does the role of molecular analysis of the sentinel node using reverse transcriptase polymerase chain reactions looking for messenger RNA to tyrosinase²⁷⁹⁻²⁸³ (in the case of melanoma) or a keratin protein^{278;284-286} (in the case of breast cancer). Lastly, if the sentinel node is found to contain tumour, it is unknown whether to remove the remaining non sentinel nodes from the lymph node basin, especially for early primary disease.

The most controversial area surrounding sentinel node biopsy is in its ability to alter survival for patients^{271;287}. In the USA, where elective lymph node dissection was often performed for cutaneous melanoma²⁸⁸, the idea of performing a sentinel node biopsy instead

of an elective node dissection was more acceptable than in Europe, where lymph node dissections were only performed for melanoma patients with palpable lymphadenopathy. However, since no randomised controlled trial in melanoma has shown that elective lymph node dissection can consistently and reliably alter patient survival, sentinel node biopsy remains controversial as a therapeutic procedure. If the presence of melanoma within the lymph nodes is merely an indicator of distant disease then early treatment of regional disease will make no difference to overall survival, although there may be a reduction in disease free survival. In head and neck cancer, however, patient mortality is most often due to local or regional failure and less so from distant metastases^{56;289}. Management of head and neck cancer patients should initially be directed at adequate control of local and regional disease. If regional disease can be more effectively controlled by the treatment of early lymph node disease, then sentinel node biopsy may lead to a survival benefit for head and neck cancer patients. Since some patients with subclinical metastases undergo observation of the lymph node group and develop late stage regional disease^{290;291} it is highly possible that sentinel node biopsy may confer a survival benefit. When locoregional control in head and neck cancer improves, the presence of distant metastases becomes more relevant in determining survival.

In head and neck cancer sentinel node biopsy, all the above questions remain unanswered. Since the sentinel node concept has only recently been applied to this group of patients, the controversies are likely to remain for several years.

In our experience, we have found that the sentinel node is identifiable in patients with head and neck cancer, and that the sentinel node accurately reflects the pathological status of the neck, when

successfully harvested. We have also applied the new technology to patients with early cancers who would otherwise undergo no elective treatment to the neck, and have found that the technique can upstage the neck in some patients. Although the exact sensitivity of the procedure is unknown, in the context of an elective neck dissection, the overall accuracy of the pathological status of the node is high.

During the sentinel node biopsy procedure, when the radiocolloid is used according to the anatomical site of the lesion, lymphoscintigraphy and the hand held probe will identify the position of the sentinel node in approximately 90% of cases. This rate compares favourably with cutaneous head and neck melanoma sentinel node biopsy, where the rate is between 90-100%^{99,156,170,264,265}. For primary cancers located in the tongue or floor of mouth, the colloid we chose to use was Albures and for primaries located elsewhere in the oral cavity or oropharynx, the colloid was Nanocoll. If Albures is used in non-floor of mouth and non-tongue lesions, the colloid does not pass from injection site to the lymph nodes in the neck; conversely, if Nanocoll is used for lesions of the floor of mouth or tongue, the colloid would theoretically pass from first echelon node to non sentinel nodes, and a large number of radioactive nodes would be found in the neck. Although at least one of these nodes would be the sentinel node, unnecessary exploration of the neck would be performed in order to retrieve the true sentinel nodes. If Albures is used to investigate lymphatic flow in the clinically involved neck, the colloid bypasses grossly involved nodes to enter uninvolved, and therefore non-sentinel, nodes. The increased hydrostatic pressure within the grossly involved lymph node appears to be too high to permit the in flow of large diameter colloids. When using low diameter colloids, the sentinel node

involved with tumour seems to take up the radiocolloid more often. In these cases, the increase in hydrostatic pressure within the involved node is not so high as to prevent the small colloid from passing into the node.

In those cases where a radioactive node is not found in the neck, the additional use of blue dye will aid in localising the sentinel node. Some blue nodes will contain metastases yet will have no clinically detectable amounts of radioactivity within them, therefore blue dye should be used in addition to radiocolloid to identify the sentinel node. Since blue dye and radiocolloid are different pharmaceuticals, they will have different pharmacokinetics and pharmacodynamics. Accordingly, it is not surprising that some sentinel nodes are blue only or hot only. Sentinel nodes can be found in clinically unpredictable sites, or those sites within the neck that are technically challenging to approach (for example level IIb). Thus, the use of lymphoscintigraphy pre-operatively is a prerequisite to successful sentinel node identification and gives an indication to where to search for the sentinel nodes. Lymphoscintigraphy does not appear to be sensitive enough to locate the exact site of the sentinel node in terms of neck level. In our initial study using blue dye alone, one of the main problems in retrieving sentinel nodes was the lack of knowledge of where to search for blue dye. Although the neck is conveniently divided into levels according to the likely site of nodal metastasis, and although patients with oral and oropharyngeal cancers are likely to harbour metastases initially in levels I, II or III, exploring the neck for blue dye is technically difficult if there is doubt as to whether the sentinel node will be present in the level being explored. There is also a learning curve associated with all sentinel node techniques^{95,165}, and this may have been reflected in our later success with successful identification of blue nodes in the absence of

radioactivity within the neck. As our experience with the procedure increased the success rate in identification rose, particularly when the exploration of the sentinel node was guided to the upper, middle or lower neck by lymphoscintigraphy.

Our experience suggests that the sentinel node pathology accurately reflects the status of the neck in the clinically N0 neck, when the sentinel node is found. Lymph node metastases are thought to be embolic in nature and these are thought to travel within lymphatics to the first echelon lymph node draining the tumour. The sentinel node concept of injecting traceable compounds into the metastasising edge of a tumour, and following these compounds to the first echelon node which is then removed and examined for the presence of tumour, seems to apply to head and neck cancer to the same degree that it does for breast cancer and melanoma. In our series, the accuracy of the procedure was 94%, (95% confidence interval 82-100%, when a sentinel node was successfully identified), when performed in the context of an elective lymph node dissection. Since the presence of nodal disease in a sentinel node upstages the neck, by definition the specificity of the procedure is 100% – there can be no false positive sentinel node pathology results when using conventional H&E techniques. The overall accuracy of the procedure, in the context of an elective neck dissection, is therefore very high, when technically successful. If a sentinel node is not found, there remains a high possibility that lymph node disease is present in the neck and clinicians should strongly consider performing an elective neck dissection in such cases.

In melanoma and breast cancer, sentinel node pathology is the most accurate way of staging the regional nodes and in our experience with head and neck cancer sentinel node biopsy, it seems that the sentinel node status is also the most accurate means of staging the

neck. The accuracy in our series was higher than that for clinical examination or radiological investigative techniques²⁹², other than the results from the Amsterdam group where ultrasound guided fine needle aspiration is performed with greater sensitivity. However, the Dutch group's experience is not reflected in any other head and neck unit. This being the case, it is a logical progression that the technique is used, in the context of a clinical trial, as a means of staging the neck in patients who would otherwise undergo no elective treatment to the neck (either in the form of elective radiotherapy or an elective neck dissection).

We have applied the technique of sentinel node biopsy to patients instead of a "wait and see" policy to the neck. Once our initial results were available and accepted for publication, we were able to obtain ethical approval to perform such a trial in order to validate the accuracy of the technique in a group of patients who were to undergo no other treatment to the neck. Since the presence of lymph node metastases rises with increased efforts to search for nodal disease¹⁵⁰, when performing a neck dissection there is probably little need to search exhaustively for lymph node metastases in a sentinel node. In such a case, if the sentinel node contains tumour, but is not seen by conventional pathological techniques, the presence of tumour is probably clinically insignificant. However, if sentinel node biopsy is to be used as a technique to upstage the neck, then the presence of small tumour deposits may be more significant. In order to search more exhaustively for small tumour deposits, the sentinel node was examined in more detail during our interventional study. Sentinel nodes were bisected, and both halves were processed for H&E staining. If the thickness of the two halves were greater than 2mm, further sections were obtained for examination. In our planned future studies, immunocytochemistry will be used on sentinel nodes

to further increase the detection rate of nodal metastases²⁹³, as is the case with melanoma and breast cancer sentinel node biopsy.

Frozen section was used in our series in only one patient. In this case, the patient underwent sentinel node biopsy only, and no neck dissection. Additionally, the patient underwent free tissue transfer for reconstruction of the defect following tumour ablation. The sentinel node did not contain tumour either at frozen section or at subsequent formalin staining. The use of frozen section for sentinel node examination is a controversial topic. Arguments against the technique are that tissue is lost during preparation and only a small proportion of the node is examined. Additionally, special staining techniques are not performed on frozen section specimens, and it may be that subsequent studies in head and neck cancer show that the sentinel node is only an accurate means of staging the neck when special stains, such as immunohistochemistry and polymerase chain reactions to epithelial DNA are used. Accordingly, in our studies, we chose not to investigate frozen section other than in one case.

The type of case likely to benefit from a sentinel node biopsy instead of a wait and see policy is probably limited. Patients with small oral cancers with a low likelihood of metastasis are likely to benefit – this group of patients would include T1/2, N0 oral cancers. Additionally, patients with oral cancers close to or crossing the midline in which a bilateral neck dissection would be planned could undergo sentinel node biopsy on the contralateral neck side. Lastly, patients unlikely to benefit from a sentinel node biopsy include those patients in which neck access was required at the time of primary surgery, either for access to the tumour (eg for retromolar trigone tumours) or for access to vessels for microvascular reconstruction (eg lateral tongue/floor of mouth T2 tumours where tongue mobility would be

compromised without a free flap reconstruction), since subsequent surgery to the neck in case of a pathologically positive sentinel node may compromise the viability of the free tissue transfer. We performed sentinel node biopsy without a neck dissection in one patient, and vessels were identified in the neck with relative ease without performing a neck dissection. However, if the sentinel nodes had contained tumour, the subsequent neck dissection would have been technically challenging.

The morbidity of the sentinel node procedure was not measured. In the initial studies, the sentinel node was harvested during the course of a neck dissection and it would be difficult to know whether any adverse effects of surgery were due to the sentinel node procedure or the neck dissection, reconstruction and tumour ablation surgery. In the group of patients where a neck dissection was only performed if the sentinel node was positive, the aims of the study were to determine whether the procedure was technically possible. Future studies should be directed at identifying both the morbidity and the cost of the procedure. In particular, shoulder function should be determined by using the University of Washington quality of life scoring system in patients undergoing sentinel node biopsy only. Once these studies are completed, we will have a better indication of the cost and morbidity associated with the procedure.

During the course of this study, other researchers have also performed sentinel node biopsy procedures on patients and have published their results^{218-220;294}. Most centres investigating the procedure have performed the technique on low numbers of cases and to our knowledge, our series is the largest to date in oral cancer. Prior to this study, sentinel node biopsy had been investigated by a few centres with mixed success and in limited cases^{144;145;295;296}.

In an attempt to standardise the procedure and to prevent the situation in breast cancer where sentinel node biopsy is performed by different techniques according to local preferences, we have commenced a multicentre study in which the methodology is relatively fixed. From the results of this study, it will be possible to determine, in a homogenous group of patients who undergo a similar procedure, the true sensitivity of the procedure.

The protocol of our study reproduced in Chapter 12, is on the Canniesburn Hospital web site and forms the basis for an M.D. thesis for another researcher.

CHAPTER 12: FUTURE STUDIES OF SENTINEL NODE BIOPSY IN HEAD AND NECK CANCER

INTRODUCTION

In this study, we have determined a method by which sentinel node biopsy can be performed in patients with head and neck cancer. Having determined the method of choice for us, we have applied the technique as an interventional procedure in patients to determine the status of the neck nodes to confirm that the procedure may be performed successfully out-with the context of a neck dissection. During this latter study, patients have undergone a therapeutic neck dissection and a course of post operative radiotherapy only if the sentinel node contained overt tumour. Following this pilot study, confirming the ability to harvest sentinel nodes out-with a neck dissection procedure, sentinel node biopsy should now be investigated as a means to stage the positivity or negativity of the regional lymph nodes. To achieve this aim, a study protocol has been written.

STUDY PROTOCOL

In the protocol, the primary aim is to determine whether sentinel node biopsy can accurately determine the presence or absence of lymph node metastases in patients with T1/T2N0 oral and oropharyngeal cancer. Secondary aims are: to map the anatomical site of the sentinel node in head and neck carcinoma for various sites of primary lesion in the oral cavity and oropharynx, and to determine the role of immunohistochemistry and multiple step sectioning in identifying micrometastases in the sentinel node in the absence of visible metastases by conventional staining methods.

Patients will be invited to participate in the study if a clinical decision is made in the head and neck clinic for a wait and see policy to the neck is adopted in their management plan for clinical reasons. If the patient is not fit enough for a subsequent neck dissection and adjuvant radiotherapy, they will be ineligible for entry into the trial. Lastly, if the tumour is small in size but invades deeply to the extent that a neck dissection is warranted, then an elective neck dissection will be performed as is our current policy.

Patients will undergo lymphoscintigraphy up to one day prior to surgery, as described in the Discussion section of Chapter 3. A maximum of 40MBq ^{99m}Tc -labelled Human Serum Albumin (Albures or Nanocoll) will be injected throughout the normal mucosa surrounding the tumour edge and submucosa on the deep aspect of the tumour in a volume of approximately 0.5-1.0ml. A syringe with a permanently secured needle will be used for injection, to prevent inadvertent spillage of colloid into the mouth. Colloid will be injected at as many points as necessary in an attempt to completely surround the tumour. A mouthwash will be used immediately following injection to prevent pooling or swallowing of residual radioactivity by the patient.

Static lymphoscintigraphy will be performed at 15 minutes, 30 minutes and one hour post injection in two planes or until the appearance of radioactive nodes. It is usual to see hot spots 15 minutes post injection. If nodes are still absent one hour after injection, the lymph nodes are either too close to the injection site or radiocolloid has leaked out of the injection site.

Either a ^{57}Co marker will be employed to trace the patient outline or a flood source of a ^{57}Co or ^{99m}Tc will be placed behind the patient to produce a silhouette of the patient outline. From the point of view of radiation dose the marker pen is preferable. A gamma camera

fitted with a low energy, general purpose (LEGP) collimator will be used to image the patient. A 20% window centred on the 140keV photopeak will be selected and the camera interfaced to a suitable computing system. The locations of radioactive lymph nodes will be marked on the patients' skin: the position of a ^{57}Co solid source pen will be observed on the cameras' persistence display and the pen moved until its position overlies that of a radioactive node. This position will be then marked on the skin using indelible ink. During the skin marking, a lead plate of an appropriate thickness (e.g. 3mm) will be used to shield the injection site.

Following image acquisition a software mask will be applied to all images to eliminate radioactivity from the injection site. A region of interest, drawn around the image of the site of injection, will be used as the basis for the mask applied.

Two colloids are commonly used for lymphoscintigraphy in Europe: Albures and Nanocoll. Albures has a mean particle size of 500nm and is a slower moving particle that remains in first echelon (sentinel) nodes but requires a high density of terminal lymphatic vessels at the injection site. For these reason, Albures will be the colloid of choice in the tongue and floor of mouth. Nanocoll has a mean particle size of 80nm and is a faster moving colloid which finds lymphatic vessels despite injection into tissues with low densities of terminal lymphatics. However, it moves readily from sentinel nodes to subsequent echelon nodes and for these reasons Nanocoll will be the colloid of choice in non-floor of mouth/non-tongue primaries. The choice of colloid should be recorded.

At operation, 1-2 ml of Patent Blue V dye will be injected throughout the normal mucosa and submucosa surrounding the tumour. Patent Blue V dye will be injected prior to the skin incision to minimise the risk of disrupting lymphatic channels draining the primary tumour. In

order to approximate the same injection sites as for radiocolloid, all injections should be made by one person. A suitable incision is made in the neck in such a position as to facilitate excision of the incision scar should a subsequent neck dissection be necessary. The hand held gamma probe will be used to identify radioactive sentinel nodes, including those marked pre-operatively during lymphoscintigraphy. To reduce detection of radiation from the injection site, a series of malleable sterilised lead plates may be used to mask the injection site, thus aiding in-vivo identification of radioactive nodes. Radioactive nodes will be excised and radioactivity within the node is confirmed *ex-vivo*. Blue stained lymphatics, if seen, will be followed to the first draining lymph node, which will be harvested. Sentinel nodes will be labelled according to their colour and radioactivity. The anatomical neck level of sentinel nodes will be noted. Although sentinel nodes should be harvested prior to treatment of the primary, the proximity of the sentinel node to the injection site may require a further search for sentinel nodes following excision of the primary. If sentinel nodes are sought after excision of the injection site, the nodes are unlikely to be blue stained.

Because of the relatively high radioactivity still present in the injection sites and the proximity to the sentinel node, detection of scattered radiation must be avoided as far as possible. As well as the use of lead plates as above, the gamma probe must have a well collimated detector which excludes gamma radiation except over a small angle in front of it. The pulse height analysis window should be set just to include the ^{99m}Tc photopeak with a cut-off on the low energy side at about 130 keV. The calibration should be checked at regular interval of not more than one month (depending on make and model of instrument) and a quick check of calibration should be devised to be carried out before each use. It may be necessary to call on

appropriate scientific/technical assistance to ensure that the gamma probe is at its optimum settings and to make an estimate of its sensitivity at these settings.

Sentinel nodes will be fixed in 10% neutral buffered formalin and after fixation will be bisected through the hilum, if this is identifiable, or through the long axis of the node. If the thickness of the halves is more than 2mm the slices will be further trimmed to provide additional 2mm thick blocks. If sentinel nodes are found to be free from tumour on initial histological examination step-serial sections will be prepared at an additional six levels in the block at approximately 150 micron intervals. One H&E stained section will be prepared at each level. If the nodes still appear histologically negative, an immediately adjacent section from each level will be examined by immunocytochemistry using the multi-cytokeratin antibody AE1/AE3. (It is advisable to mount two or more short sequences of serial sections at each level to allow for possible technical problems with section preparation).

If a neck dissection is subsequently performed during the period of the study, all non-sentinel nodes over approximately 2.5mm in maximum diameter will be identified in their anatomical groups. Each node will be bisected through the hilum (or long axis, if the hilum is not identifiable) and both halves will be processed for histological examination. Larger nodes will be trimmed in the manner detailed above for sentinel nodes. One H&E stained section will be prepared from each block and will be examined for the presence of nodal involvement by tumour. The accuracy of the primary resection and pathological staging and grading will be performed according to Royal College of Pathologists guidelines.

The interpretation of the histopathology and immunocytochemistry of sentinel lymph nodes will be categorised as follows:-

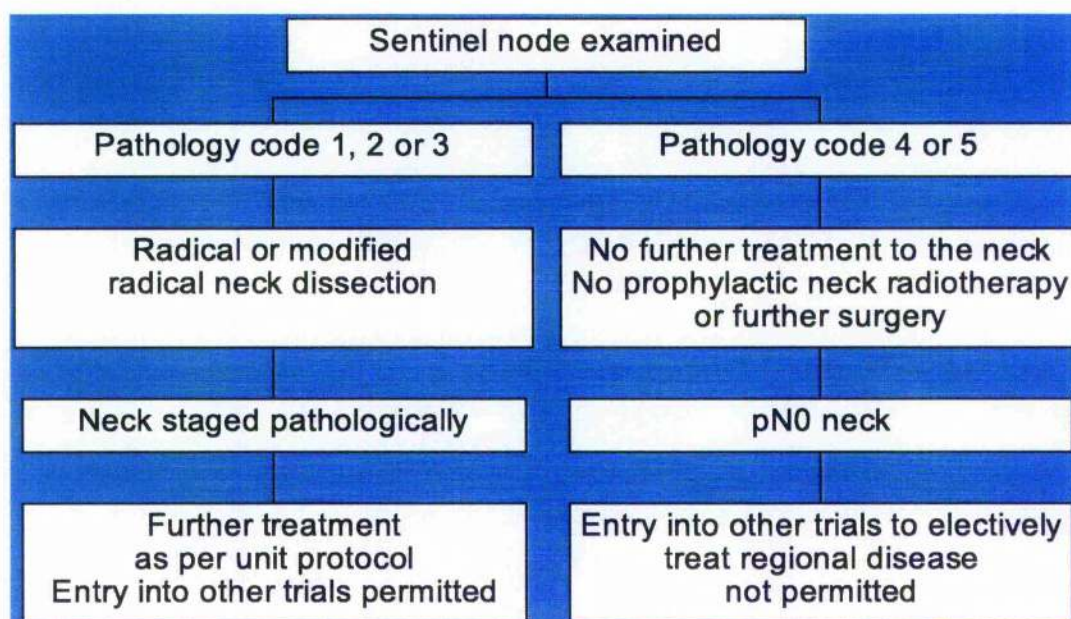
PATHOLOGY CODE	DESCRIPTION
1	Tumour positive on first H&E examination
2	Initially tumour negative, but tumour positive on examination of H&E of step serial sections
3	Negative at stages 1 and 2 but positive by immunohistochemistry. To be categorised as tumour positive there must be cells which are both positive by immunocytochemistry and are cytologically seen to be nucleated cells with the characteristics of viable epithelial cells in both the immunocytochemical preparation and the serial H&E section. Cytokeratin positivity lacking the cytological features of viable tumour cells is categorised as 4.
4	Cytokeratin positivity not showing the features of viable tumour cells. This positivity is likely to represent either dying tumour cells, possibly apoptotic cells, characterised by being eosinophilic bodies lacking normal nuclei, or macrophages with phagocytosed tumour products. Usually these cells will be single and not small cohesive groups. The decision to allocate nodes to this category requires careful comparison of the serial H&E and immunocytochemical preparations.
5	Negative at all stages.

FURTHER TREATMENT FOR PATIENTS WITH SENTINEL LYMPH NODES CONTAINING TUMOUR

In the event that any lymph node contains viable tumour either by routine histology or through immunohistochemistry and multiple

sectioning, the patient will undergo a radical or modified radical neck dissection. For tumours that drain to lymph nodes on both sides of the neck, a neck dissection will only be performed on the side of the neck in which a sentinel node containing tumour was found. The neck dissection should take place within four weeks of the sentinel node biopsy, and any adjuvant radiotherapy should start within six weeks of the neck dissection. Radiotherapy should not be administered prior to neck dissections.

Patients will undergo further treatment to the neck following sentinel node biopsy according to the following flow chart:



FOLLOW-UP

Follow-up will take place for all patients entered into the trial. Patients will be seen three monthly for the first year, four monthly for the following two years and six monthly until 5 years post sentinel node biopsy.

At any stage, if nodal disease is detected, patients will be offered treatment to the neck in the form of surgery. All other treatments for metastatic disease will be given according to local protocols, however, patients with regional failure must undergo a neck dissection, if fit for surgery.

Should the technique prove to be valuable in determining the pathological status of the lymph nodes in the neck, it may be used as an alternative to elective lymph node dissections.

CONCLUSIONS

Sentinel node biopsy is an exciting new development in head and neck cancer. Our initial results indicate that the technique may be able to identify early nodal metastases in clinically N0 necks. This should be investigated further in formal clinical trials. Since the number of cases which any individual centre is able to perform is low, trials for head and neck cancer sentinel node biopsy should be conducted using strict protocols and should be multicentre trials.

Single unit trials will inevitably have low patient numbers recruited. Accordingly, it is difficult to organise a randomised controlled trial to initially investigate sentinel node biopsy as an alternative to a wait and see policy and subsequently as an alternative to neck dissections. Nevertheless, to fully investigate the technique, large scale multicentre trials should be organised with control groups, and with survival and recurrence end points.

By researching the technique in this manner, meaningful results from studies with reasonable statistical power will emerge with time.

APPENDIX 1: ETHICAL CONSIDERATIONS

Ethical approval was obtained from the local ethics committee at the Royal Infirmary, 84 Castle Street, Glasgow, prior to starting this study (approval reference numbers: BU98006 and BU99001). An Administration of Radioactive Substances Approval Committee (ARSAC) certificate was obtained to inject radiocolloid into patients entered into the study. Dr H.W Gray was the lead consultant in charge of administering the radiopharmaceuticals, and, within the remit of the certificate, permission was given to Mr T Shoalb to administer radiocolloid.

All patients entered into this study were given full informed consent prior to sentinel node biopsies being performed. There were two groups of patients on whom sentinel node biopsies were performed, and each was counselled differently. The first group underwent sentinel node biopsy in addition to a neck dissection, whereas the second group underwent a neck dissection only if the sentinel node was subsequently found to contain tumour. The patient information and consent forms for these two groups are reproduced.

**PATIENT INFORMATION AND CONSENT FORM FOR PATIENTS
UNDERGOING SENTINEL NODE BIOPSY AND NECK
DISSECTION**

**TITLE OF PROJECT: LYMPH NODE MAPPING AND IDENTIFICATION OF
SENTINEL LYMPH NODE IN HEAD AND NECK CANCER**

You have been diagnosed as suffering from either a squamous cell carcinoma or malignant melanoma of the skin in your head and neck region or squamous cell carcinoma in your oral cavity. You are shortly to be admitted to undergo surgery for this cancer and as part of this you will be undergoing a neck dissection (removal of a group of lymph nodes from one side of your neck).

It is well recognised that head and neck cancers, both of the skin and of the oral cavity, can spread to lymph nodes although at the present time the exact mechanism by which this occurs is unknown. We would like to try and establish the mechanism by which tumours spread in this manner so that it may be possible in the future to improve the treatment of cancers such as the one you have. Prior to surgery, we would like to inject a small quantity (0.5ml) of blue dye and a small dose of a radioactive drug (40MBq in 0.5ml-1.0ml) around your tumour. The radioactive drug will be injected at the Nuclear Medicine Department at the Royal Infirmary and will be followed by a scan of your head and neck. As a result injecting blue dye into your tumour, your skin colour and urine may be tinged blue for a day or so after your surgery. This possible colour change will have settled by the time you are ready for discharge home. Also, it will be necessary for you to avoid close contact with pregnant women for 24 hours following the injection of the radioactive drug. The

remainder of your routine assessments and your treatment will be then undertaken according to our normal schedule.

If you agree to take part in this research project it may be of little or no benefit to you but the results may help other patients in the future. Should you not wish to take part in the project or at any time should you wish to stop taking part, you may do so. The care which you receive and your proposed treatment protocol will not be affected in any way. If you agree to take part in this research project, your own general practitioner will be told and will be given detailed information about the care you will receive. Should you require more detailed information concerning this project, please do not hesitate to ask and we will provide a more detailed description of the project.

If you are pregnant or likely to become pregnant, you should not take part in this research study.

Consent

I, (Name).....of
(Address).....
agree to take part in the Research Project/Study Programme
described above.

Dr/Mr.....has
explained to me what I have to do, how it might affect me and the
purpose of the Research Project/Study Programme.

Signed.....

Date.....

Witness.....

Date.....

**PATIENT INFORMATION AND CONSENT FORM FOR PATIENTS
UNDERGOING SENTINEL NODE BIOPSY ONLY**

CONSENT FORM

TITLE OF PROJECT: Sentinel node biopsy to upstage clinically false negative necks in patients with oral cancer

You have been diagnosed as suffering from a squamous cell carcinoma of your oral cavity and are shortly to undergo surgery for this cancer.

It is well recognised that head and neck cancers of the oral cavity, can spread to lymph nodes although at the present time the exact mechanism by which this occurs is unknown. We would like to try and establish the mechanism by which tumours spread in this manner so that it may be possible in the future to improve the treatment of cancers such as the one you have. Prior to surgery, we would like to inject a small quantity (0.5ml) of blue dye and a small dose of a radioactive marker (40MBq in 0.5ml-1.0ml) around your tumour. The radioactive marker will be injected at the Nuclear Medicine Department at the Royal Infirmary and will be followed by a scan of your head and neck. As a result of injecting blue dye into your tumour, your mouth colour and urine will be stained blue for a day or so after your surgery. This colour change will have settled by the time you are ready for discharge home. The remainder of your routine assessments and your treatment will be then undertaken according to our normal schedule.

If you agree to take part in this research project it may be of little or no benefit to you but the results may help other patients in the future. Should you not wish to take part in the project or at any time should you wish to stop taking part, you may do so. The care which you receive and your proposed treatment protocol will not be affected in

any way. If you agree to take part in this research project, your own general practitioner will be told and will be given detailed information about the care you will receive. Should you require more detailed information concerning this project, please do not hesitate to ask and we will provide a more detailed description of the project.

If you are pregnant or likely to become pregnant, you should not take part in this research study.

CONSENT

I, (Name).....of
(Address).....
.....
.....

agree to take part in the Research Project/Study Programme described above.

Dr/Mr.....has
explained to me what I have to do, how it might affect me and the purpose of the Research Project/Study Programme.

Signed.....

Date.....

Witness.....

Date.....

PATIENT INFORMATION FORM**TITLE OF PROJECT:**

Sentinel node biopsy to upstage clinically false negative necks in patients with oral cancer

INTRODUCTION

Oral cancer spreads by the lymphatic channels to lymph nodes located in the neck. In patients with oral cancer, we always examine the neck for signs of spread, and if spread has occurred we perform an operation called a neck dissection. A neck dissection is an operation to remove a large proportion of the lymph nodes in the neck and is considered major surgery. Since major surgery carries some risks, we are reluctant to perform neck dissections on patients whom we think will not benefit from it. At the moment, however, the only way of determining whether spread to the neck has occurred or not is to perform a neck dissection and sometimes we perform a neck dissection for the sole reason to find out if spread has occurred or not.

In your case, we will not be performing a neck dissection at the moment, because we feel that spread to the lymph nodes has not occurred. Our normal practice for patients, such as you, is to observe and examine you every few months. By doing this, if spread has occurred we will be able to detect this early, and give you the treatment you need quickly.

We are always looking for ways to improve the treatment and investigations we offer people. Currently, we are performing a new technique to determine whether we can make improvements to the care of patients with oral cancer. We would like to invite you to enter a clinical trial of a procedure called "Sentinel node biopsy". This

leaflet will explain the procedure, tell you how it is performed and will answer some of the questions you may have.

SENTINEL NODE BIOPSY

Sentinel node biopsy is a procedure that has been performed for patients since the early 1990's. In patients with malignant melanoma (a type of skin cancer) and breast cancer, sentinel node biopsy has been shown to be a very good way of telling whether spread of the cancer has occurred or not. We would like to see if sentinel node biopsy can tell us whether spread has occurred in patients with oral cancer.

Sentinel node biopsy is a technique that involves two injections. One of these injections will be given while you are awake and one while you are under anaesthesia. The first injection is given into the mouth and the substance injected is a radioactive protein. The injection will be given in the Nuclear Medicine Department at the Royal Infirmary. The dose of radioactivity used is very low in comparison to the doses we use for other investigations in Nuclear Medicine. After the injection, a scan will be performed of your neck to image the injection as it travels from your mouth to the glands in the neck. The scan takes about half an hour to one hour in total.

The second injection is given while you are asleep under anaesthesia. The injection given is a blue dye and colours the lymph channels and lymph nodes blue. When we perform a sentinel node biopsy, we can find blue stained lymph nodes and trace radioactivity with a gamma-probe to find the sentinel node. The sentinel nodes are sent to the pathology laboratory where the Pathologist examines the node for the presence of tumour cells. If any tumour is seen in the sentinel node, we will offer you further treatment to the lymph nodes in the neck.

CHANGES TO YOUR TREATMENT

By agreeing to enter our trial, you are agreeing to have a sentinel node biopsy performed. The rest of your treatment and investigations will be performed according to our usual schedule. Sentinel node biopsy is an investigation which will be performed in addition to your usual treatment. Since it is an unproven theory in oral cancer, we cannot guarantee that it will be successful in identifying cancer spread, if spread has already occurred.

SIDE EFFECTS

Sentinel node biopsy has been performed for several years, and there are very few side effects associated with it. These are:

Blue staining of the urine. Since we inject blue dye into the tissues around your tumour, and since the dye is removed by your kidneys, for about one day after your operation, your urine will be stained blue.

Hypersensitivity. There have been a few reports of people being allergic to the blue dye we inject. This is more common in people who suffer allergies to other things. If you tend to suffer from allergies, please let us know.

BENEFITS TO YOU

If you agree to take part in this research project it may be of little or no benefit to you but the results may help other patients in the future. Should you not wish to take part in the project or at any time should you wish to stop taking part, you may do so. The care which you receive and your proposed treatment protocol will not be affected in any way. If you agree to take part in this research project, your own general practitioner will be told and will be given detailed information about the care you will receive. Should you require more detailed

information concerning this project, please do not hesitate to ask and we will provide a more detailed description of the project.

FURTHER INFORMATION

If you or your family have any questions or require any further information, please contact:

Mr T. Shoaib (Head and Neck Research Fellow) or Mr D.S. Soutar (Consultant Plastic Surgeon) at Canniesburn Hospital.

APPENDIX 2: PUBLICATIONS AND PRESENTATIONS

The following publications and presentations have been produced as a result of the work within this thesis.

PUBLICATIONS

A suggested method for sentinel node biopsy in squamous cell carcinoma of the head and neck. Shoaib T. Soutar DS. Prosser JE. Dunaway DJ. Gray HW. McCurrach GM. Bessent RG. Robertson AG. Oliver R. MacDonald DG. *Head & Neck*. 21(8):728-733, 1999 Dec. *Head & Neck*, 22(7): 733-735, 2000 Oct (Author's reply to comments)

Sentinel node biopsy in head and neck cancer. Shoaib T. Soutar DS. *Current opinion in otolaryngology and head and neck surgery*. 9(2):79-84, 2001 Apr.

The accuracy of head and neck cancer sentinel node biopsy in the clinically N0 neck. Shoaib T, Soutar DS, MacDonald DG, Camilleri IG, Dunaway DJ, Gray HW, McCurrach GW, Bessent RG, McLeod TIF, Robertson AG. *Cancer*, 91(11):2077-2083, 2001 June

Cost effectiveness of SNB as an alternative to elective neck dissections in patients clinically N0 head and neck squamous cell carcinoma. Ross GL, Soutar DS, Shoaib T, Camilleri I, Gray HW, Bessent RG, MacDonald DG. *Oral Oncology* 2001(7):400-404

Sentinel node biopsy to target lymph node dissection at the clinically false negative neck in head and neck. G Ross , D Soutar, T Shoaib, HW Gray, IG Camilleri, RG Bessent, DG MacDonald. *cancer. Oral Oncology* 2001(7):393-396

The history of sentinel node biopsy in Canniesburn. G Ross, D Soutar, T Shoaib, HW Gray, IG Camilleri, RG Bessent, DG MacDonald. Oral Oncology 2001;(7)405-408

The first international conference on sentinel node biopsy in mucosal head and neck cancer and adoption of a multicenter trial protocol. Ross GL, Shoaib T, Soutar DS, MacDonald DG, Camilleri IG, Bessent RG, Gray HW. Ann Surg Oncol 2002 May;9(4):406-10

Sentinel node biopsy: the technique and the feasibility in head and neck cancer. C. Von Buchwald, A. Bilde, T. Shoaib, and G. Ross. ORL J.Otorhinolaryngol.Relat Spec. 64 (4):268-274, 2002.

The use of sentinel node biopsy to upstage the clinically N0 neck in head and neck cancer. Ross G, Shoaib T, Soutar DS, Camilleri IG, Gray HW, Bessent RG, Robertson AG, MacDonald DG. Arch Otolaryngol Head Neck Surg. 2002 Nov;128(11):1287-91.

PEER REVIEWS

In autumn 2001 I performed peer review for the British Journal of Cancer on the following manuscript: Sentinel node biopsy in N0 cancer of the larynx and pharynx. JA Werner, A-A Dunne, A Ramaswamy, BJ Folz, BM Lippert, R Moll, Th Behr

PERSONAL PRESENTATIONS TO LEARNED SOCIETIES

INTERNATIONAL CONFERENCES

Initial Results of Sentinel Node Biopsy in Oral Cancer. Abstract in: Eur J Nucl Med (1999) 26(suppl):S70. T. Shoaib*, D.S. Soutar, J.E. Prosser, D.J. Dunaway, H.W. Gray, G.M. McCurrach, R.G. Bessent, R. Oliver, D.G. MacDonald. "1st International Congress on the

Sentinel Node in the Diagnosis and Treatment of Cancer", Amsterdam, April 7th-10th, 1999. Oral presentation.

Success with sentinel node biopsy in head and neck cancer using blue dye and radiocolloid. T. Shoaib, D.S. Soutar, D.J. Dunaway, I.G. Camilleri, H.W. Gray, D.G. MacDonald. European Association of Plastic Surgeons. Berlin. June 2, 2000. Oral Presentation

The accuracy of sentinel node biopsy in the clinically N0 neck. T. Shoaib*, D.S. Soutar, D.J. Dunaway, I.G. Camilleri, H.W. Gray, G.M. McCurrach, R.G. Bessent, T.I.F. MacLeod, D.G. MacDonald. The 5th International Conference on Head and Neck Cancer. San Francisco, July, 2000. Oral Presentation

Sentinel node biopsy in patients undergoing neck dissection (invited presentation). International Symposium on Metastases in Head and Neck Cancer: Advances in Experimental and Clinical Oncology, Marburg, Germany. January 25th-27th, 2001

The History of sentinel node biopsy (invited presentation). The 1st International Conference on Sentinel Node Biopsy in Mucosal Head and Neck Cancer, Glasgow. June 25, 2001.

Sentinel node biopsy in patients undergoing neck dissection (invited presentation). The 1st International Conference on Sentinel Node Biopsy in Mucosal Head and Neck Cancer, Glasgow. June 25, 2001.

Sentinel node biopsy in patients undergoing neck dissection. Canniesburn Reunion Conference, Glasgow. July 1, 2001.

NATIONAL

Initial Success In Performing Sentinel Node Biopsy In Patients With Head and Neck Cancer. T. Shoaib, D.S. Soutar, J.E. Prosser, D.J. Dunaway, A.G. Robertson., H.W. Gray, G.M. McCurrach, R.G. Bessent, D.G. MacDonald. British Association of Head and Neck

Oncologists, Annual General Meeting, Royal College of Physicians, London, April 30th 1999. Oral presentation.

Sentinel Node Biopsy in Oral Cancer: Initial Results. J. Prosser, T. Shoaib, D.S. Soutar, G.M. McCurrach, D.J. Dunaway, H.W. Gray. British Nuclear Medicine Society. Brighton, May 11th, 1999. Oral presentation.

Techniques to assist sentinel node biopsy in head and neck cancers. Abstract in: Nucl Med Commun (2000);21(4):387. T. Shoaib, D.S. Soutar, I.G. Camilleri, D.J. Dunaway, G.M. McCurrach, R.G. Bessent, H.W. Gray. British Nuclear Medicine Society. Brighton April 12th, 2000. Oral Presentation. PRIZE WINNING PRESENTATION: 3RD BEST ORAL PRESENTATION

Future studies of sentinel node biopsy in head and neck cancer. T. Shoaib, D.S. Soutar, I.G. Camilleri, H.W. Gray, A.G. Robertson, D.G. MacDonald. British Association of Head and Neck Oncologists Annual General Meeting, London. April 28, 2000. Oral Presentation

Sentinel node biopsy in head and neck cancer. T. Shoaib, D.S. Soutar, D.J. Dunaway, I.G. Camilleri, H.W. Gray, G.M. McCurrach, R.G. Bessent, T.I.F. MacLeod, D.G. MacDonald. British Association of Plastic Surgeons (3rd European Appointed Meeting). Birmingham, July 6th, 2000. Oral Presentation

The anatomical site of sentinel nodes in mucosal head and neck cancer. T. Shoaib, D.S. Soutar, D.G. MacDonald. British Association of Plastic Surgeons. July 4, 2001. Oral Presentation

REGIONAL

Sentinel node biopsy in malignant melanoma and head and neck cancer. T. Shoaib, J. Prosser, D.S. Soutar, D.J. Dunaway, H.W. Gray, G.M. McCurrach, R.G. Bessent, D.G. MacDonald, R.M.

Mackie. "The Scottish Scientific Meeting", Royal College of Physicians of Edinburgh, March 5th, 1999. Poster presentation.

Pathological aspects of sentinel node biopsies in oral cancer. D.G. MacDonald, T. Shoaib, D.S. Soutar. Scottish Science Meeting. Stirling, September 1 2000. Poster presentation. WINNER OF BEST POSTER PRIZE

REFERENCES

1. Rapidis AD, Keramidas T, Panagiotopoulos H, Andressakis D, Angelopoulos AP. Tumours of the head and neck in the elderly: analysis of 190 patients. *J.Craniomaxillofac.Surg.* 1998;**26**:153-8.
2. Heng C, Rossi EP. A report on 222 cases of oral squamous cell carcinoma. *Mil.Med.* 1995;**160** :319-23.
3. Macfarlane GJ, Boyle P, Evstifeeva TV, Robertson C, Scully C. Rising trends of oral cancer mortality among males worldwide: the return of an old public health problem. *Cancer Causes Control* 1994;**5**:259-65.
4. Macfarlane GJ, Evstifeeva TV, Robertson C, Boyle P, Scully C. Trends of oral cancer mortality among females worldwide. *Cancer Causes Control* 1994;**5**:255-8.
5. Sciubba JJ. Oral cancer. The importance of early diagnosis and treatment. *Am.J.Clin.Dermatol.* 2001;**2**:239-51.
6. Wright JM. Oral precancerous lesions and conditions. *Semin.Dermatol.* 1994;**13**:125-31.
7. Brown AE, Langdon JD. Management of oral cancer. *Ann.R.Coll.Surg.Engl.* 1995;**77**:404-8.
8. Marks SC. Surgical management of head and neck cancer. *Hematol.Oncol.Clin.North Am.* 1999;**13**:655-78, v.

9. Haddadin KJ, Soutar DS, Webster MH, Robertson AG, Oliver RJ, MacDonald DG. Natural history and patterns of recurrence of tongue tumours. *Br.J.Plast.Surg.* 2000;**53**:279-85.
10. Goldberg HI, Lockwood SA, Wyatt SW, Crossett LS. Trends and differentials in mortality from cancers of the oral cavity and pharynx in the United States, 1973-1987. *Cancer* 1994;**74**:565-72.
11. Kurumatani N, Kirita T, Zheng Y, Sugimura M, Yonemasu K. Time trends in the mortality rates for tobacco- and alcohol-related cancers within the oral cavity and pharynx in Japan, 1950-94. *J.Epidemiol.* 1999;**9**:46-52.
12. Macfarlane GJ, Sharp L, Porter S, Franceschi S. Trends in survival from cancers of the oral cavity and pharynx in Scotland: a clue as to why the disease is becoming more common? *Br.J.Cancer* 1996;**73**:805-8.
13. O'Hanlon S, Forster DP, Lowry RJ. Oral cancer in the North-East of England: incidence, mortality trends and the link with material deprivation. *Community Dent.Oral Epidemiol.* 1997;**25**:371-6.
14. Shiboski CH, Shiboski SC, Silverman S Jr. Trends in oral cancer rates in the United States, 1973-1996. *Community Dent.Oral Epidemiol.* 2000;**28**:249-56.
15. Wolfensberger M, Krause M. [Significance of distant metastases and secondary cancers as a cause of death in patients with ENT cancers]. *HNO* 1986;**34**:296-300.

16. Eckel HE, Volling P, Pototschnig C, Zorowka P, Thumfart W. Transoral laser resection with staged discontinuous neck dissection for oral cavity and oropharynx squamous cell carcinoma. *Laryngoscope* 1995;**105**:53-60.
17. Lipkin A, Miller RH, Woodson GE. Squamous cell carcinoma of the oral cavity, pharynx, and larynx in young adults. *Laryngoscope* 1985;**95**:790-3.
18. Takagi M, Kayano T, Yamamoto H, Shibuya H, Hoshina M, Shioda S *et al.* Causes of oral tongue cancer treatment failures. Analysis of autopsy cases. *Cancer* 1992;**69**:1081-7.
19. Califano L, Zupi A, Mangone GM, Longo F, Coscia G, Piombino P. Surgical management of the neck in squamous cell carcinoma of the tongue. *Br.J.Oral Maxillofac.Surg.* 1999;**37**:320-3.
20. Majoufre C, Faucher A, Laroche C, De Bonfils C, Siberchicot F, Renaud-Salls JL *et al.* Supraomohyoid neck dissection in cancer of the oral cavity. *Am.J.Surg.* 1999;**178**:73-7.
21. Shingaki S, Nomura T, Takada M, Kobayashi T, Suzuki I, Nakajima T. The impact of extranodal spread of lymph node metastases in patients with oral cancer. *Int.J.Oral Maxillofac.Surg.* 1999;**28**:279-84.
22. Persky MS, Lagmay VM. Treatment of the clinically negative neck in oral squamous cell carcinoma. *Laryngoscope* 1999;**109**:1160-4.

23. Yip NW, Patel SG, Rhys-Evans PH, Breach NM. Management of the N0 neck in early cancer of the oral tongue. *Clin.Otolaryngol.* 1999;**24**:75-9.
24. Shah JP, Candela FC, Poddar AK. The patterns of cervical lymph node metastases from squamous carcinoma of the oral cavity. *Cancer* 1990;**66**:109-13.
25. Noguchi M, Kido Y, Kubota H, Kinjo H, Kohama G. Prognostic factors and relative risk for survival in N1-3 oral squamous cell carcinoma: a multivariate analysis using Cox's hazard model. *Br.J.Oral Maxillofac.Surg.* 1999;**37**:433-7.
26. Mamelle G, Pampurik J, Luboinski B, Lancar R, Lusinch A, Bosq J. Lymph node prognostic factors in head and neck squamous cell carcinomas. *Am.J.Surg.* 1994;**168**:494-8.
27. Woolgar JA, Vaughan ED, Scott J, Brown JS. Pathological findings in clinically false-negative and false-positive neck dissections for oral carcinoma. *Ann.R.Coll.Surg.Engl.* 1994;**76**:237-44.
28. Watkinson JC, Johnston D, Jones N, Coady M, Laws D, Allen S *et al.* The reliability of palpation in the assessment of tumours. *Clin.Otolaryngol.* 1990;**15**:405-9.
29. O'Brien CJ, Traynor SJ, McNeil E, McMahon JD, Chaplin JM. The use of clinical criteria alone in the management of the clinically negative neck among patients with squamous cell carcinoma of the oral cavity and oropharynx. *Arch.Otolaryngol.Head Neck Surg.* 2000;**126**:360-5.

30. Anzai Y, Brunberg JA, Lufkin RB. Imaging of nodal metastases in the head and neck. *J.Magn Reson.Imaging* 1997;**7**:774-83.
31. Watkinson JC, Lazarus CR, Todd C, Maisey MN, Clarke SE. Metastatic squamous carcinoma in the neck: an anatomical and physiological study using CT and SPECT 99Tcm (V) DMSA. *Br.J.Radiol.* 1991;**64**:909-14.
32. van den Brekel MW, Castelijns JA. Radiologic evaluation of neck metastases: the otolaryngologist's perspective. *Semin.Ultrasound CT MR* 1999;**20**:162-74.
33. van den Brekel MW. Lymph node metastases: CT and MRI. *Eur.J.Radiol.* 2000;**33**:230-8.
34. van den Brekel MW, Castelijns JA. Imaging of lymph nodes in the neck. *Semin.Roentgenol.* 2000;**35**:42-53.
35. Giron J, Chisin R, Paul JL, Senac JP, Bonafe A, Manelfe C *et al.* Multimodality imaging of cervical adenopathies. *Eur.J.Radiol.* 1996;**21**:159-66.
36. Som PM. Detection of metastasis in cervical lymph nodes: CT and MR criteria and differential diagnosis. *AJR Am.J.Roentgenol.* 1992;**158**:961-9.
37. van den Brekel MW, Castelijns JA, Reitsma LC, Leemans CR, van dW, I, Snow GB. Outcome of observing the N0 neck using ultrasonographic-guided cytology for follow-up. *Arch.Otolaryngol.Head Neck Surg.* 1999;**125**:153-6.

38. Murthy P, Laing MR, Palmer TJ. Fine needle aspiration cytology of head and neck lesions: an early experience. *J.R.Coll.Surg.Edinb.* 1997;**42**:341-6.
39. Merritt RM, Williams MF, James TH, Porubsky ES. Detection of cervical metastasis. A meta-analysis comparing computed tomography with physical examination. *Arch.Otolaryngol.Head Neck Surg.* 1997;**123**:149-52.
40. Atula TS, Varpula MJ, Kurki TJ, Klemi PJ, Grenman R. Assessment of cervical lymph node status in head and neck cancer patients: palpation, computed tomography and low field magnetic resonance imaging compared with ultrasound-guided fine-needle aspiration cytology. *Eur.J.Radiol.* 1997;**25**:152-61.
41. Atula TS, Grenman R, Varpula MJ, Kurki TJ, Klemi PJ. Palpation, ultrasound, and ultrasound-guided fine-needle aspiration cytology in the assessment of cervical lymph node status in head and neck cancer patients. *Head Neck* 1996;**18**:545-51.
42. Ballet JW, Abemayor E, Jabour BA, Hawkins RA, Ho C, Ward PH. Positron emission tomography: a new, precise imaging modality for detection of primary head and neck tumors and assessment of cervical adenopathy. *Laryngoscope* 1992;**102**:281-8.
43. Di Martino E, Nowak B, Krombach GA, Sellhaus B, Hausmann R, Cremerius U *et al.* [Results of pretherapeutic lymph node diagnosis in head and neck tumors. Clinical value of 18-FDG

- positron emission tomography (PET)]. *Laryngorhinootologie* 2000;**79**:201-6.
44. Stokkel MP, ten Broek FW, Hordijk GJ, Koole R, van Rijk PP. Preoperative evaluation of patients with primary head and neck cancer using dual-head 18fluorodeoxyglucose positron emission tomography. *Ann.Surg.* 2000;**231**:229-34.
 45. Nowak B, Di Martino E, Janicke S, Cremerius U, Adam G, Zimny M *et al.* Diagnostic evaluation of malignant head and neck cancer by F-18-FDG PET compared to CT/MRI. *Nuklearmedizin* 1999;**38**:312-8.
 46. Mattei R, Rubello D, Ferlin G, Bagatella F. [Positron emission tomography (PET) with 18-fluorodeoxyglucose (FDG) in the diagnosis and preoperative staging of head and neck tumors: a prospective study]. *Acta Otorhinolaryngol.Ital.* 1998;**18**:387-91.
 47. Stokkel MP, ten Broek FW, van Rijk PP. Preoperative assessment of cervical lymph nodes in head and neck cancer with fluorine-18 fluorodeoxyglucose using a dual-head coincidence camera: a pilot study. *Eur.J.Nucl.Med.* 1999;**26**:499-503.
 48. Hanasono MM, Kunda LD, Segall GM, Ku GH, Terris DJ. Uses and limitations of FDG positron emission tomography in patients with head and neck cancer. *Laryngoscope* 1999;**109**:880-5.
 49. Paulus P, Sambon A, Vivegnis D, Hustinx R, Moreau P, Collignon J *et al.* 18FDG-PET for the assessment of primary head and neck tumors: clinical, computed tomography, and

- histopathological correlation in 38 patients. *Laryngoscope* 1998;**108**:1578-83.
50. Benchaou M, Lehmann W, Slosman DO, Becker M, Lemoine R, Rufenacht D *et al.* The role of FDG-PET in the preoperative assessment of N-staging in head and neck cancer. *Acta Otolaryngol.* 1996;**116**:332-5.
 51. Wagner JD, Schauwecker D, Davidson D, Coleman JJ, III, Saxman S, Hutchins G *et al.* Prospective study of fluorodeoxyglucose-positron emission tomography imaging of lymph node basins in melanoma patients undergoing sentinel node biopsy. *J.Clin.Oncol.* 1999;**17**:1508-15.
 52. Shah JP, Andersen PE. The impact of patterns of nodal metastasis on modifications of neck dissection. *Ann.Surg.Oncol.* 1994;**1**:521-32.
 53. Decroix Y, Ghossein NA. Experience of the Curie Institute in treatment of cancer of the mobile tongue: II. Management of the neck nodes. *Cancer* 1981;**47**:503-8.
 54. Shasha D, Harrison LB. Elective irradiation of the N0 neck in squamous cell carcinoma of the upper aerodigestive tract. *Otolaryngol.Clin.North Am.* 1998;**31**:803-13.
 55. The N0 neck in head and neck cancer patients [editorial]. *Eur.Arch.Otorhinolaryngol.* 1993;**250**:423.
 56. Haddadin KJ, Soutar DS, Oliver RJ, Webster MH, Robertson AG, MacDonald DG. Improved survival for patients with

- clinically T1/T2, N0 tongue tumors undergoing a prophylactic neck dissection. *Head Neck* 1999;**21**:517-25.
57. Ratcliffe RJ, Soutar DS. Unexpected lymph node pathology in neck dissection for head and neck cancer. *Head Neck* 1990;**12**:244-6.
 58. Shaha AR, Spiro RH, Shah JP, Strong EW. Squamous carcinoma of the floor of the mouth. *Am.J.Surg.* 1984;**148**:455-9.
 59. Nilssen EL, McClymont L, Denholm S. Radiological staging for squamous carcinoma of the head and neck: a standardised practice? *J.R.Coll.Surg.Edinb.* 1999;**44**:303-6.
 60. Martin H, Del Valle B, Ehrlich H, Cahan WG. Neck dissection. *Cancer* 2000;**4**:441-99.
 61. Kocher. ueber Radicalheilung des Krebses. *Dtsch.Z.Chir* 1880;**13**:134-66. (reference cited by D.S. Soutar, ChM Thesis)
 62. Jawdynski F. I. Przypadek raka pierwotnego szyi. T. z. raka skrzelowego volkamnn`a. Wyciecie nowotworu wraz z rezekcja tetnicy syjowej wspolnej i zyly szjowej wewnetrznej. *Gaz.Lek* 1888;**28**:530-5. (reference cited by A.A. Dunne, PhD Thesis)
 63. Crile G. Landmark article Dec 1, 1906: Excision of cancer of the head and neck. With special reference to the plan of dissection based on one hundred and thirty-two operations. By George Crile [classical article]. *JAMA* 1987;**258**:3286-93.

64. Martin H. The case for prophylactic neck dissection. 1951 [classical article]. *CA Cancer J.Clin.* 1990;**40**:245-51.
65. Terrell JE, Welsh DE, Bradford CR, Chepeha DB, Esclamado RM, Hogikyan ND *et al.* Pain, quality of life, and spinal accessory nerve status after neck dissection. *Laryngoscope* 2000;**110**:620-6.
66. Saffold SH, Wax MK, Nguyen A, Caro JE, Andersen PE, Everts EC *et al.* Sensory changes associated with selective neck dissection. *Arch.Otolaryngol.Head Neck Surg.* 2000;**126**:425-8.
67. Results of a prospective trial on elective modified radical classical versus supraomohyoid neck dissection in the management of oral squamous carcinoma. Brazilian Head and Neck Cancer Study Group. *Am.J.Surg.* 1998;**176**:422-7.
68. Ahn C., Sindelar WF. Bilateral radical neck dissection: report of results in 55 patients. *J.Surg.Oncol.* 1989;**40**:252-5.
69. Dodd FM. Blindness following bilateral neck dissection. *Eur.J.Anaesthesiol.* 1993;**10**:37-9.
70. McGuirt WF, McCabe BF. Bilateral radical neck dissections. *Arch.Otolaryngol.* 1980;**106**:427-9.
71. Pitman KT. Rationale for elective neck dissection. *Am.J.Otolaryngol.* 2000;**21**:31-7.
72. Lam KH. The role of neck dissection in head and neck mucosal squamous cancer. *Aust.N.Z.J.Surg.* 1999;**69**:865-70.

73. Johansen H, Kaae S, Schiodt T. Simple mastectomy with postoperative irradiation versus extended radical mastectomy in breast cancer. A twenty-five-year follow-up of a randomized trial. *Acta Oncol.* 1990;**29**:709-15.
74. Werner JA. [Historical outline on the nomenclature of neck lymph nodes as a basis of neck dissection classification]. *Laryngorhinootologie* 2001;**80**:400-9.
75. Bocca E, Pignataro O, Sasaki CT. Functional neck dissection. A description of operative technique. *Arch.Otolaryngol.* 1980;**106**:524-7.
76. Robbins KT, Medina JE, Wolfe GT, Levine PA, Sessions RB, Pruet CW. Standardizing neck dissection terminology. Official report of the Academy's Committee for Head and Neck Surgery and Oncology . *Arch.Otolaryngol.Head Neck Surg.* 1991;**117**:601-5.
77. Robbins KT. Classification of neck dissection: current concepts and future considerations. *Otolaryngol.Clin.North Am.* 1998;**31**:639-55.
78. Kuntz AL, Weymuller EA, Jr. Impact of neck dissection on quality of life. *Laryngoscope* 1999;**109**:1334-8.
79. Talmi YP, Hoffman HT, Horowitz Z, McCulloch TM, Funk GF, Graham SM *et al.* Patterns of metastases to the upper jugular lymph nodes (the "submuscular recess"). *Head Neck* 1998;**20**:682-6.

80. Kolli VR, Datta RV, Omer JB, Hicks WL, Jr., Loree TR. The role of supraomohyoid neck dissection in patients with positive nodes. *Arch.Otolaryngol.Head Neck Surg.* 2000;**126**:413-6.
81. O'Brien CJ, Urist MM. Current status of neck dissection in the management of squamous carcinoma of the head and neck. *Aust.N.Z.J.Surg.* 1987;**57**:501-9.
82. Friedman M, Lim JW, Dickey W, Tanyeri H, Kirshenbaum GL, Phadke DM *et al.* Quantification of lymph nodes in selective neck dissection. *Laryngoscope* 1999;**109**:368-70.
83. Rouviere H. Anatomie des lymphatiques de l'homme. Thesis, 1932. (reference cited by O.E. Niewig, personal communication)
84. Lindberg R. Distribution of cervical lymph node metastases from squamous cell carcinoma of the upper respiratory and digestive tracts. *Cancer* 1972;**29**:1446-9.
85. Medina JE, Byers RM. Supraomohyoid neck dissection: rationale, indications, and surgical technique. *Head Neck* 1989;**11**:111-22.
86. Carvalho AL, Kowalski LP, Borges JA, Aguiar S, Jr., Magrin J. Ipsilateral neck cancer recurrences after elective supraomohyoid neck dissection. *Arch.Otolaryngol.Head Neck Surg.* 2000;**126**:410-2.
87. Ross MI, Reintgen D, Balch CM. Selective lymphadenectomy: emerging role for lymphatic mapping and sentinel node biopsy

- in the management of early stage melanoma. *Semin.Surg.Oncol.* 1993;**9**:219-23.
88. Morton DL, Wen DR, Wong JH, Economou JS, Cagle LA, Storm FK *et al.* Technical details of intraoperative lymphatic mapping for early stage melanoma. *Arch.Surg.* 1992;**127**:392-9.
 89. Reintgen D, Cruse CW, Wells K, Berman C, Fenske N, Glass F *et al.* The orderly progression of melanoma nodal metastases. *Ann.Surg.* 1994;**220**:759-67.
 90. Cabanas RM. An approach for the treatment of penile carcinoma. *Cancer* 1977;**39**:456-66.
 91. Perinetti E, Crane DB, Catalona WJ. Unreliability of sentinel lymph node biopsy for staging penile carcinoma. *J.Urol.* 1980;**124**:734-5.
 92. Fowler JE, Jr. Sentinel lymph node biopsy for staging penile cancer. *Urology* 1984;**23**:352-3.
 93. Wespes E, Simon J, Schulman CC. Cabanas approach: is sentinel node biopsy reliable for staging penile carcinoma? *Urology* 1986;**28**:278-9.
 94. Srinivas V, Joshi A, Agarwal B, Mundhada U, Shah A, Phadke AG. Penile cancer--the sentinel lymph node controversy. *Urol.Int.* 1991;**47**:108-9.
 95. Morton DL, Wen DR, Wong JH, Economou JS, Cagle LA, Storm FK *et al.* Technical details of intraoperative lymphatic mapping for early stage melanoma. *Arch.Surg.* 1992;**127**:392-9.

96. Wong JH, Cagle LA, Morton DL. Lymphatic drainage of skin to a sentinel lymph node in a feline model. *Ann.Surg.* 1991;**214**:637-41.
97. Reintgen D, Cruse CW, Wells K, Berman C, Fenske N, Glass F *et al.* The orderly progression of melanoma nodal metastases. *Ann.Surg.* 1994;**220**:759-67.
98. Alex JC, Weaver DL, Fairbank JT, Rankin BS, Krag DN. Gamma-probe-guided lymph node localization in malignant melanoma. *Surg.Oncol.* 1993;**2**:303-8.
99. Bostick P, Essner R, Sarantou T, Kelley M, Glass E, Foshag L *et al.* Intraoperative lymphatic mapping for early-stage melanoma of the head and neck. *Am.J.Surg.* 1997;**174**:536-9.
100. Miner TJ, Shriver CD, Flicek PR, Miner FC, Jaques DP, Maniscalco-Theberge ME *et al.* Guidelines for the safe use of radioactive materials during localization and resection of the sentinel lymph node . *Ann.Surg.Oncol.* 1999;**6**:75-82.
101. Waddington WA, Keshtgar MR, Taylor I, Lakhani SR, Short MD, Ell PJ. Radiation safety of the sentinel lymph node technique in breast cancer . *Eur.J.Nucl.Med.* 2000;**27**:377-91.
102. Stratmann SL, McCarty TM, Kuhn JA. Radiation safety with breast sentinel node biopsy. *Am.J.Surg.* 1999;**178**:454-7.
103. Krag DN, Weaver DL, Alex JC, Fairbank JT. Surgical resection and radiolocalization of the sentinel lymph node in breast cancer using a gamma probe. *Surg.Oncol.* 1993;**2**:335-9.

104. Messina JL, Reintgen DS, Cruse CW, Rappaport DP, Berman C, Fenske NA *et al.* Selective lymphadenectomy in patients with Merkel cell (cutaneous neuroendocrine) carcinoma. *Ann.Surg.Oncol.* 1997;**4**:389-95.
105. Ames SE, Krag DN, Brady MS. Radiolocalization of the sentinel lymph node in Merkel cell carcinoma: a clinical analysis of seven cases. *J.Surg.Oncol.* 1998;**67**:251-4.
106. Hill AD, Brady MS, Coit DG. Intraoperative lymphatic mapping and sentinel lymph node biopsy for Merkel cell carcinoma. *Br.J.Surg.* 1999;**86**:518-21.
107. Sian KU, Wagner JD, Sood R, Park HM, Havlik R, Coleman JJ. Lymphoscintigraphy with sentinel lymph node biopsy in cutaneous Merkel cell carcinoma. *Ann.Plast.Surg.* 1999;**42**:679-82.
108. Wasserberg N, Feinmesser M, Schachter J, Fenig E, Gutman H. Sentinel-node guided lymph-node dissection for merkel cell carcinoma. *Eur.J.Surg.Oncol.* 1999;**25**:444-6.
109. Zeitouni NC, Cheney RT, Delacure MD. Lymphoscintigraphy, sentinel lymph node biopsy, and mohs micrographic surgery in the treatment of merkel cell carcinoma . *Dermatol.Surg.* 2000;**26**:12-8.
110. Wasserberg N, Schachter J, Fenig E, Feinmesser M, Gutman H. Applicability of the sentinel node technique to merkel cell carcinoma . *Dermatol.Surg.* 2000;**26**:138-41.

111. Kuruł S, Mudun A, Aksakal N, Aygen M. Lymphatic mapping for Merkel cell carcinoma. *Plast.Reconstr.Surg.* 2000;**105**:680-3.
112. Cserni G, Vajda K, Tarjan M, Bori R, Svebis M, Baltas B. Nodal staging of colorectal carcinomas from quantitative and qualitative aspects. Can lymphatic mapping help staging? *Pathol.Oncol.Res.* 1999;**5**:291-6.
113. Joosten JJ, Strobbe LJ, Wauters CA, Pruszczynski M, Wobbes T, Ruers TJ. Intraoperative lymphatic mapping and the sentinel node concept in colorectal carcinoma . *Br.J.Surg.* 1999;**86**:482-6.
114. Ota DM. Is intraoperative lymph node mapping and sentinel lymph node biopsy for colorectal carcinoma necessary? [editorial; comment]. *Ann.Surg.Oncol.* 2000;**7**:82-4.
115. Saha S, Wiese D, Badin J, Beutler T, Nora D, Ganatra BK et al. Technical details of sentinel lymph node mapping in colorectal cancer and its impact on staging . *Ann.Surg.Oncol.* 2000;**7**:120-4.
116. DiSaia PJ, Creasman WT, Rich WM. An alternate approach to early cancer of the vulva. *Am.J.Obstet.Gynecol.* 1979;**133**:825-32.
117. Levenback C, Burke TW, Gershenson DM, Morris M, Malpica A, Ross MI. Intraoperative lymphatic mapping for vulvar cancer. *Obstet.Gynecol.* 1994;**84**:163-7.

118. Levenback C, Burke TW, Morris M, Malpica A, Lucas KR, Gershenson DM. Potential applications of intraoperative lymphatic mapping in vulvar cancer. *Gynecol.Oncol.* 1995;**59**:216-20.
119. Decesare SL, Florica JV, Roberts WS, Reintgen D, Arango H, Hoffman MS *et al.* A pilot study utilizing intraoperative lymphoscintigraphy for identification of the sentinel lymph nodes in vulvar cancer. *Gynecol.Oncol.* 1997;**66**:425-8.
120. Terada KY, Coel MN, Ko P, Wong JH. Combined use of intraoperative lymphatic mapping and lymphoscintigraphy in the management of squamous cell cancer of the vulva. *Gynecol.Oncol.* 1998;**70**:65-9.
121. de Hullu JA, Doting E, Piers DA, Hollema H, Aalders JG, Koops HS *et al.* Sentinel lymph node identification with technetium-99m-labeled nanocolloid in squamous cell cancer of the vulva. *J.Nucl.Med.* 1998;**39**:1381-5.
122. Echt ML, Finan MA, Hoffman MS, Kline RC, Roberts WS, Florica JV. Detection of sentinel lymph nodes with lymphazurin in cervical, uterine, and vulvar malignancies. *South.Med.J.* 1999;**92**:204-8.
123. Ansink AC, Sie-Go DM, van d, V, Sijmons EA, de Barros LA, Monaghan JM *et al.* Identification of sentinel lymph nodes in vulvar carcinoma patients with the aid of a patent blue V injection: a multicenter study. *Cancer* 1999;**86**:652-6.

124. Rodier JF, Janser JC, Routiot T, David E, Ott G, Schneegans O *et al.* Sentinel node biopsy in vulvar malignancies: a preliminary feasibility study. *Oncol.Rep.* 1999;**6**:1249-52.
125. De Cicco C, Sideri M, Bartolomei M, Grana C, Cremonesi M, Fiorenza M *et al.* Sentinel node biopsy in early vulvar cancer. *Br.J.Cancer* 2000;**82**:295-9.
126. Terada KY, Shimizu DM, Wong JH. Sentinel node dissection and ultrastaging in squamous cell cancer of the vulva. *Gynecol.Oncol.* 2000;**76**:40-4.
127. Levenback C, Coleman RL, Ansink A, van der Zee AG. Re: Terada et al.: Sentinel node dissection and ultrastaging in squamous cell cancer of the vulva. *Gynecol Oncol* 76:40-44, 2000 [letter]. *Gynecol.Oncol.* 2000;**77**:484-5.
128. de Hullu JA, Hollema H, Piers DA, Verheijen RH, van Diest PJ, Mourits MJ *et al.* Sentinel lymph node procedure is highly accurate in squamous cell carcinoma of the vulva . *J.Clin.Oncol.* 2000;**18**:2811-6.
129. Cady B. Sentinel lymph node procedure in squamous cell carcinoma of the vulva . *J.Clin.Oncol.* 2000;**18**:2795-7.
130. Horenblas S, Jansen L, Meinhardt W, Hoefnagel CA, de Jong D, Nieweg OE. Detection of occult metastasis in squamous cell carcinoma of the penis using a dynamic sentinel node procedure. *J.Urol.* 2000;**163**:100-4.

131. Starz H, Balda BR, Bachter D, Buchels H, Vogt H. Secondary lymph node involvement from primary cutaneous large B-cell lymphoma of the leg: sentinel lymph nodeectomy as a new strategy for staging circumscribed cutaneous lymphomas. *Cancer* 1999;**85**:199-207.
132. Stadelmann WK, Javaheri S, Cruse CW, Reintgen DS. The use of selective lymphadenectomy in squamous cell carcinoma of the wrist: a case report. *J.Hand Surg.[Am.]* 1997;**22** :726-31.
133. Uren RF, Howman-Giles R, Thompson JF, Shaw HM, Quinn MJ, O'Brien CJ *et al.* Lymphoscintigraphy to identify sentinel lymph nodes in patients with melanoma. *Melanoma Res.* 1994;**4**:395-9.
134. O'Brien CJ, Uren RF, Thompson JF, Howman-Giles RB, Petersen-Schaefer K, Shaw HM *et al.* Prediction of potential metastatic sites in cutaneous head and neck melanoma using lymphoscintigraphy. *Am.J.Surg.* 1995;**170**:461-6.
135. Pijpers R, Collet GJ, Meijer S, Hoekstra OS. The impact of dynamic lymphoscintigraphy and gamma probe guidance on sentinel node biopsy in melanoma. *Eur.J.Nucl.Med.* 1995;**22**:1238-41.
136. Pijpers R, Borgstein PJ, Teule GJ, Meijer S. Vital dye and radiolabelled colloids--complement or alternative? . *Recent Results Cancer Res.* 2000;**157** :130-7.

137. Uren RF, Howman-Giles RB, Thompson JF, Roberts J, Bernard E. Variability of cutaneous lymphatic flow rates in melanoma patients. *Melanoma Res.* 1998;**8**:279-82.
138. Uren RF, Thompson JF, Howman-Giles R. Sentinel nodes. Interval nodes, lymphatic lakes, and accurate sentinel node identification [letter; comment]. *Clin.Nucl.Med.* 2000;**25**:234-6.
139. Schneebaum S, Städler J, Cohen M, Yaniv D, Baron J, Skornick Y. Gamma probe-guided sentinel node biopsy--optimal timing for injection. *Eur.J.Surg.Oncol.* 1998;**24**:515-9.
140. Keshtgar MRS, Eli PJ. Sentinel lymph node detection and imaging . *Eur.J.Nucl.Med.* 1999;**26**:57-67.
141. Wilhelm AJ, Mijnhout GS, Franssen EJ. Radiopharmaceuticals in sentinel lymph-node detect. *Eur.J.Nucl.Med.* 1999;**26**:S36-S42.
142. Pitman KT, Johnson JT, Edington H, Barnes EL, Day R, Wagner RL *et al.* Lymphatic mapping with isosulfan blue dye in squamous cell carcinoma of the head and neck. *Arch.Otolaryngol.Head Neck Surg.* 1998;**124**:790-3.
143. Koch WM, Choti MA, Civelek AC, Eisele DW, Saunders JR. Gamma probe-directed biopsy of the sentinel node in oral squamous cell carcinoma. *Arch.Otolaryngol.Head Neck Surg.* 1998;**124**:455-9.

144. Alex JC, Krag DN. The gamma-probe-guided resection of radiolabeled primary lymph nodes. *Surg.Oncol.Clin.N.Am.* 1996;**5**:33-41.
145. Bilchik AJ, Giuliano A, Essner R, Bostick P, Kelemen P, Foshag LJ *et al.* Universal application of intraoperative lymphatic mapping and sentinel lymphadenectomy in solid neoplasms. *Cancer J.Sci.Am.* 1998;**4**:351-8.
146. Broil R, Schauer V, Schimmelpenning H, Strik M, Woltmann A, Best R *et al.* Prognostic relevance of occult tumor cells in lymph nodes of colorectal carcinomas: an immunohistochemical study. *Dis.Colon Rectum* 1997;**40**:1465-71.
147. Abu-Hijleh MF, Scothorne RJ. Studies on haemolymph nodes. IV. Comparison of the route of entry of carbon particles into parathymic nodes after intravenous and intraperitoneal injection. *J.Anat.* 1996;**188 (Pt 3)**:565-73.
148. Kamperdijk EW, Dopp EA, Dijkstra CD. Transport of immune complexes from the subcapsular sinus into the lymph node follicles of the rat. *Adv.Exp.Med.Biol.* 1988;**237**:191-6.
149. Carr I. Lymphatic metastasis. *Cancer Metastasis Rev.* 1983;**2**:307-17.
150. Wilkinson EJ, Hause L. Probability in lymph node sectioning. *Cancer* 1974;**33**:1269-74.
151. van den Brekel MW, van dW, I, Meijer CJ, Freeman JL, Castelijns JA, Snow GB. The incidence of micrometastases in

- neck dissection specimens obtained from elective neck dissections. *Laryngoscope* 1996;**106**:987-91.
152. Woolgar JA. Micrometastasis in oral/oropharyngeal squamous cell carcinoma: incidence, histopathological features and clinical implications. *Br.J.Oral Maxillofac.Surg.* 1999;**37**:181-6.
 153. van den Brekel MW, Stel HV, van d, V, van dW, I, Meyer CJ, Snow GB. Micrometastases from squamous cell carcinoma in neck dissection specimens. *Eur.Arch.Otorhinolaryngol.* 1992;**249**:349-53.
 154. Cochran AJ. The pathologist's role in sentinel lymph node evaluation. *Semin.Nucl.Med.* 2000;**30**:11-7.
 155. American Joint Committee on Cancer: Cancer Staging Manual. Philadelphia,Lippincott-Raven, 1998.
 156. Morton DL, Wen DR, Foshag LJ, Essner R, Cochran A. Intraoperative lymphatic mapping and selective cervical lymphadenectomy for early-stage melanomas of the head and neck. *J.Clin.Oncol.* 1993;**11**:1751-6.
 157. Cserni G. Metastases in axillary sentinel lymph nodes in breast cancer as detected by intensive histopathological work up . *J.Clin.Pathol.* 1999;**52**:922-4.
 158. Czerniecki BJ, Scheff AM, Callans LS, Spitz FR, Bedrosian I, Conant EF *et al.* Immunohistochemistry with pancytokeratins improves the sensitivity of sentinel lymph node biopsy in patients with breast carcinoma. *Cancer* 1999;**85**:1098-103.

159. Messina JL, Glass LF. Pathologic examination of the sentinel lymph node. *J.Fla.Med.Assoc.* 1997;**84**:153-6.
160. Giuliano AE, Kirgan DM, Guenther JM, Morton DL. Lymphatic mapping and sentinel lymphadenectomy for breast cancer . *Ann.Surg.* 1994;**220**:391-8.
161. Nieweg OE, Kapteijn BA, Peterse JL, Rutgers EJ, van Dongen JA, Kroon BB. [Identification of the sentinel node in patients with breast carcinoma]. *Ned.Tijdschr.Geneeskd.* 1996;**140**:2235-9. (reference by O.E. Niewig, personal communication)
162. Alazraki NP, Styblo T, Grant SF, Cohen C, Larsen T, Aarsvold JN. Sentinel node staging of early breast cancer using lymphoscintigraphy and the intraoperative gamma-detecting probe. *Semin.Nucl.Med.* 2000;**30**:56-64.
163. Bass SS, Cox CE, Ku NN, Berman C, Reintgen DS. The role of sentinel lymph node biopsy in breast cancer. *J.Am.Coll.Surg.* 1999;**189**:183-94.
164. Orr RK, Hoehn JL, Col NF. The learning curve for sentinel node biopsy in breast cancer: practical considerations . *Arch.Surg.* 1999;**134**:764-7.
165. Testori A, Bartolomei M, Grana C, Mezzetti M, Chinol M, Mazzarol G *et al.* Sentinel node localization in primary melanoma: learning curve and results. *Melanoma Res.* 1999;**9**:587-93.

166. Albertini JJ, Cruse CW, Rapaport D, Wells K, Ross M, DeConti R *et al.* Intraoperative radio-lympho-scintigraphy improves sentinel lymph node identification for patients with melanoma. *Ann.Surg.* 1996;**223**:217-24.
167. Bostick P, Essner R, Sarantou T, Kelley M, Glass E, Foshag L *et al.* Intraoperative lymphatic mapping for early-stage melanoma of the head and neck. *Am.J.Surg.* 1997;**174**:536-9.
168. Kapteijn BA, Nieweg OE, Liem I, Mooi WJ, Balm AJ, Muller SH *et al.* Localizing the sentinel node in cutaneous melanoma: gamma probe detection versus blue dye. *Ann.Surg.Oncol.* 1997;**4**:156-60.
169. Bostick P, Essner R, Sarantou T, Kelley M, Glass E, Foshag L *et al.* Intraoperative lymphatic mapping for early-stage melanoma of the head and neck. *Am.J.Surg.* 1997;**174**:536-9.
170. Jansen L, Koops HS, Nieweg OE, Doting MH, Kapteijn BA, Balm AJ *et al.* Sentinel node biopsy for melanoma in the head and neck region. *Head Neck* 2000;**22**:27-33.
171. Frier M. Radiopharmaceuticals for sentinel node detection. *Nucl.Med.Comm.* 1999;**20**:306-8.
172. Liu TJ, Wang SJ, Tsai SC. Lymphoscintigraphy using larger colloid particles may enhance visualization of the sentinel node in breast cancer: a case report. *Clin.Nucl.Med.* 2000;**25**:191-2.
173. Moffat FL, Jr., Gulec SA, Sittler SY, Serafini AN, Sfakianakis GN, Boggs JE *et al.* Unfiltered sulfur colloid and sentinel node

- biopsy for breast cancer: technical and kinetic considerations. *Ann.Surg.Oncol.* 1999;**6**:746-55.
174. Bombardieri E, Crippa F, Maffioli L, Draisma A, Chiti A, Agresti R *et al.* Nuclear medicine approaches for detection of axillary lymph node metastases. *Q.J.Nucl.Med.* 1998;**42**:54-65.
 175. McIntosh SA, Purushotham AD. Lymphatic mapping and sentinel node biopsy in breast cancer. *Br.J.Surg.* 1998;**85**:1347-56.
 176. Holmberg SB, Hafstrom L, Jacobsson L. Phagocytosis and dynamic RES scintigraphy: an evaluation of commercial colloids in rats [published erratum appears in Nucl Med Commun 1987 Dec;8(12):1090]. *Nucl.Med.Comm.* 1987;**8**:335-46.
 177. Onizawa K, Schmelzeisen R, Berens vR, Schelomenzew J. Micro-anatomy of primary lymphatics in oral mucosa: a scanning electron microscopic study. *Br.J.Oral Maxillofac.Surg.* 1997;**35**:177-9.
 178. Werner JA. [The lymph vessel system of the mouth cavity and pharynx]. *Laryngorhinootologie* 1995;**74**:622-8. (reference by A.A. Dunne, personal communication and PhD Thesis)
 179. Klutmann S, Bohuslavizki KH, Brenner W, Hoft S, Kroger S, Werner JA *et al.* Lymphoscintigraphy in tumors of the head and neck using double tracer technique. *J.Nucl.Med.* 1999;**40**:776-82.

180. Trizna Z, Sinkovics I, Banhidy F, Kasler M, Karika Z. [Possibilities of the use of lymphoscintigraphy in head and neck surgery: introductory studies]. *Orv.Hetil.* 1990;**131**:2033-5.
181. Sri-Pathmanathan R, Railton R. Lymphoscintigraphy in the detection of cervical metastases from oral carcinoma: a pilot study. *Ann.R.Coll.Surg.Engl.* 1989;**71**:281-4.
182. Fernholz HJ. [Lymphoscintigraphy in the head-neck region]. *Fortschr.Geb.Rontgenstr.Nuklearmed.* 1967; **106**:524-33. (reference by A.A. Dunne, PhD Thesis)
183. Fiori-Ratti L, Ventura S, Senin U, Nardi S. [Study of the lymphatic system of the head and neck with Au-198 in normal conditions and in oncologic pathology. I. Lymphoscintigraphy of the tongue and floor of the mouth]. *Valsalva.* 1966;**42**:182-212. (reference translated by G. Nicoletti)
184. Leong SP, Achtem TA, Habib FA, Steinmetz I, Morita E, Allen RE *et al.* Discordancy between clinical predictions vs lymphoscintigraphic and intraoperative mapping of sentinel lymph node drainage of primary melanoma. *Arch.Dermatol.* 1999; **135**:1472-6.
185. Uren RF, Howman-Giles RB, Thompson JF, Shaw HM, McCarthy WH. Lymphatic drainage from peri-umbilical skin to internal mammary nodes. *Clin.Nucl.Med.* 1995;**20**:254-5.
186. Uren RF, Howman-Giles R, Thompson JF, Quinn MJ. Direct lymphatic drainage from the skin of the forearm to a supraclavicular node. *Clin.Nucl.Med.* 1996;**21**:387-9.

187. Uren RF, Howman-Giles R, Thompson JF, Quinn MJ, O'Brien C, Shaw HM *et al.* Lymphatic drainage to triangular intermuscular space lymph nodes in melanoma on the back. *J.Nucl.Med.* 1996;**37**:964-6.
188. Uren RF, Howman-Giles R, Thompson JF. Lymphatic drainage from the skin of the back to retroperitoneal and paravertebral lymph nodes in melanoma patients. *Ann.Surg.Oncol.* 1998;**5**:384-7.
189. Uren RF, Howman-Giles R, Thompson JF, McCarthy WH. Exclusive lymphatic drainage from a melanoma on the back to intraabdominal lymph nodes. *Clin.Nucl.Med.* 1998;**23**:71-3.
190. Noguchi M, Tsugawa K, Miwa K. Internal mammary chain sentinel lymph node identification in breast cancer. *J.Surg.Oncol.* 2000;**73**:75-80.
191. Sugg SL, Ferguson DJ, Posner MC, Heimann R. Should internal mammary nodes be sampled in the sentinel lymph node era? *Ann.Surg.Oncol.* 2000;**7**:188-92.
192. Bale A, Gardner B, Shende M, Fromowitz F. Can interpectoral nodes be sentinel nodes? *Am.J.Surg.* 1999;**178**:360-1.
193. Borges AM, Shrikhande SS, Ganesh B. Surgical pathology of squamous carcinoma of the oral cavity: its impact on management. *Semin.Surg.Oncol.* 1989;**5**:310-7.

194. Candela FC, Kothari K, Shah JP. Patterns of cervical node metastases from squamous carcinoma of the oropharynx and hypopharynx. *Head Neck* 1990;**12**:197-203.
195. Rao RS, Deshmane VH, Parikh HK, Parikh DM, Sukthankar PS. Extent of lymph node dissection in T3/T4 cancer of the alveolo-buccal complex. *Head Neck* 1995;**17**:199-203.
196. Woolgar JA. Detailed topography of cervical lymph-node metastases from oral squamous cell carcinoma. *Int.J.Oral Maxillofac.Surg.* 1997;**26**:3-9.
197. Thompson JF, McCarthy WH, Bosch CM, O'Brien CJ, Quinn MJ, Paramaesvaran S *et al.* Sentinel lymph node status as an indicator of the presence of metastatic melanoma in regional lymph nodes. *Melanoma Res.* 1995;**5**:255-60.
198. Albertini JJ, Lyman GH, Cox C, Yeatman T, Balducci L, Ku N *et al.* Lymphatic mapping and sentinel node biopsy in the patient with breast cancer . *JAMA* 1996;**276**:1818-22.
199. Cascinelli N, Belli F, Santinami M, Fait V, Testori A, Ruka W *et al.* Sentinel lymph node biopsy in cutaneous melanoma: the WHO Melanoma Program experience . *Ann.Surg.Oncol.* 2000;**7**:469-74.
200. Cox CE, Pendas S, Cox JM, Joseph E, Shons AR, Yeatman T *et al.* Guidelines for sentinel node biopsy and lymphatic mapping of patients with breast cancer . *Ann.Surg.* 1998;**227**:645-51.

201. Carvalho AL, Kowalski LP, Borges JA, Aguiar S Jr, Magrin J. Ipsilateral neck cancer recurrences after elective supraomohyoid neck dissection. *Arch.Otolaryngol.Head Neck Surg.* 2000; **126**:410-2.
202. Guenther JM. Axillary dissection after unsuccessful sentinel lymphadenectomy for breast cancer. *Am.Surg.* 1999;**65**:991-4.
203. Kamath D, Brobeil A, Stall A, Lyman G, Cruse CW, Glass F *et al.* Cutaneous lymphatic drainage in patients with grossly involved nodal basins . *Ann.Surg.Oncol.* 1999;**6**:345-9.
204. Gallo O, Boddi V, Bottai GV, Franchi A, Storch O. Prognostic significance of clinically false positive cervical lymph nodes in patients with laryngeal carcinoma. *Cancer* 1995;**75**:1077-83.
205. Cody HS, III. The learning curve for sentinel lymph node biopsy in breast cancer [letter; comment]. *Arch.Surg.* 2000;**135**:605-6.
206. Morrow M, Rademaker AW, Bethke KP, Talamonti MS, Dawes LG, Clauson J *et al.* Learning sentinel node biopsy: results of a prospective randomized trial of two techniques. *Surgery* 1999;**126**:714-20.
207. Blakeslee DB, Becker GD, Simpson GT, Patten DH, Sprengelmeyer J. Lymphoscintigraphy of the neck. *Otolaryngol.Head Neck Surg.* 1985;**93**:361-5.
208. Faries MB, Bedrosian I, Reynolds C, Nguyen HQ, Alavi A, Czerniecki BJ. Active macromolecule uptake by lymph node

- antigen-presenting cells: a novel mechanism in determining sentinel lymph node status . *Ann.Surg.Oncol.* 2000;**7**:98-105.
209. Shoaib T, Soutar DS, Prosser JE, Dunaway DJ, Gray HW, McCurrach GM *et al.* A suggested method for sentinel node biopsy in squamous cell carcinoma of the head and neck. *Head Neck* 1999;**21**:728-33.
 210. Krag DN, Meijer SJ, Weaver DL, Loggie BW, Harlow SP, Tanabe KK *et al.* Minimal-access surgery for staging of malignant melanoma. *Arch.Surg.* 1995;**130**:654-8.
 211. Miliotes G, Albertini J, Berman C, Heller R, Messina J, Glass F *et al.* The tumor biology of melanoma nodal metastases. *Am.Surg.* 1996;**62**:81-8.
 212. Leong SP, Steinmetz I, Habib FA, McMillan A, Gans JZ, Allen RE, Jr. *et al.* Optimal selective sentinel lymph node dissection in primary malignant melanoma. *Arch.Surg.* 1997;**132**:666-72.
 213. Belli F, Lenisa L, Clemente C, Tragni G, Mascheroni L, Gallino G *et al.* Sentinel node biopsy and selective dissection for melanoma nodal metastases. *Tumori* 1998;**84**:24-8.
 214. Dowlatshahi K, Fan M, Bloom KJ, Spitz DJ, Patel S, Snider HC, Jr. Occult metastases in the sentinel lymph nodes of patients with early stage breast carcinoma: A preliminary study . *Cancer* 1999;**86**:990-6.
 215. Glass EC, Essner R, Giuliano AE. Sentinel node localization in breast cancer. *Semin.Nucl.Med.* 1999;**29**:57-68.

216. Kinne DW. Axillary clearance in operable breast cancer: still a necessity? *Recent Results Cancer Res.* 1998;**152**:161-9.
217. Kuerer HM, Sahin AA, Hunt KK, Newman LA, Breslin TM, Ames FC *et al.* Incidence and impact of documented eradication of breast cancer axillary lymph node metastases before surgery in patients treated with neoadjuvant chemotherapy. *Ann.Surg.* 1999;**230**:72-8.
218. Alex JC, Sasaki CT, Krag DN, Wenig B, Pyle PB. Sentinel lymph node radiolocalization in head and neck squamous cell carcinoma. *Laryngoscope* 2000;**110**:198-203.
219. Werner JA, Dunne AA, Brandt D, Ramaswamy A, Kulkens C, Lippert BM *et al.* [Studies on significance of sentinel lymphadenectomy in pharyngeal and laryngeal carcinoma]. *Laryngorhinootologie* 1999;**78**:663-70.
220. Chiesa F, Mauri S, Grana C, Tradati N, Calabrese L, Ansarin M *et al.* Is there a role for sentinel node biopsy in early N0 tongue tumors? *Surgery* 2000;**128**:16-21.
221. Catlin D. Mucosal melanomas of the head and neck. *Am.J.Roentgenol.Radium.Ther.Nucl.Med.* 1967;**99**:809-16.
222. Loree TR, Mullins AP, Spellman J, North JH, Jr., Hicks WL, Jr. Head and neck mucosal melanoma: a 32-year review. *Ear Nose Throat J.* 1999;**78**:372-5.
223. Iversen K,Robins RE. Mucosal malignant melanomas. *Am.J.Surg.* 1980;**139**:660-4.

224. Shah JP, Huvos AG, Strong EW. Mucosal melanomas of the head and neck. *Am.J.Surg.* 1977;**134**:531-5.
225. Uren RF, Howman-Giles RB, Shaw HM, Thompson JF, McCarthy WH. Lymphoscintigraphy in high-risk melanoma of the trunk: predicting draining node groups, defining lymphatic channels and locating the sentinel node. *J.Nucl.Med.* 1993;**34**:1435-40.
226. Parnell FW. Complications of radical neck dissection. *Arch.Otolaryngol.* 1968;**88**:180-3.
227. Razack MS, Sako K, Baffi R, Patel J. Simultaneous bilateral neck dissection. *J.Surg.Oncol.* 1980;**15**:387-92.
228. Razack MS, Baffi R, Sako K. Bilateral radical neck dissection. *Cancer* 1981;**47**:197-9.
229. Olofsson J, Tytor M. Complications in neck dissection. *ORL J.Otorhinolaryngol.Relat Spec.* 1985;**47**:123-30.
230. Smullen JL, Lejeune FE, Jr. Complications of neck dissection. *J.La State Med.Soc.* 1999;**151**:544-7.
231. Talmi YP. Minimizing complications in neck dissection. *J.Laryngol.Otol.* 1999;**113**:101-13.
232. Misawa H, Yanagita N, Iwagaki T, Asahi Y, Yokoi H, Kato K *et al.* Primary malignant melanoma arising from the base of the tongue . *ORL J.Otorhinolaryngol.Relat Spec.* 2000;**62**:134-9.

233. Spiegel JH, Singer MI. Primary malignant melanoma of the tongue. *Otolaryngol. Head Neck Surg.* 1999;**121**:163.
234. Folz BJ, Niemann AM, Lippert BM, Werner JA. [Primary mucous membrane melanoma of the base of the tongue]. *Laryngorhinootologie* 1998;**77**:226-30.
235. Tanaka N, Kohama G. Melanoma of the tongue: case report. *J. Oral Maxillofac. Surg.* 1997;**55**:1469-71.
236. Bovo R, Farruggio A, Agnoletto M, Galceran M, Polidoro F. [Primitive malignant melanoma of the base of the tongue]. *Acta Otorhinolaryngol. Ital.* 1996;**16**:371-4.
237. Kalemieris GC, Rosenfeld L, Gray GF, Jr., Glick AD. Malignant melanoma of the tongue following low-dose radiation. *Arch. Pathol. Lab Med.* 1985;**109**:290-1.
238. Lukacs L. Malignant melanoma at unusual sites. *Acta Chir Acad. Sci. Hung.* 1980;**21**:319-27. (reference unobtainable – abstract only read)
239. Kumar KM, Ramachandran P, Varier PS, Ramachandran G. Primary malignant melanoma of the tongue--a case report. *Indian J. Cancer* 1972;**9**:86-8. (reference unobtainable – abstract only read)
240. Principato JJ, Sika JV, Sandler HC. Primary malignant melanoma of the tongue. A case report and review of the literature. *Cancer* 1965;**18**:1641-5.

241. Morton DL, Bostick PJ. Will the true sentinel node please stand? [editorial; comment] . *Ann.Surg.Oncol.* 1999;**6**:12-4.
242. Kapteijn BA, Nieweg OE, Muller SH, Liem IH, Hoefnagel CA, Rutgers EJ *et al.* Validation of gamma probe detection of the sentinel node in melanoma. *J.Nucl.Med.* 1997;**38**:362-6.
243. Porter GA, Ross MI, Berman RS, Sumner WE, III, Lee JE, Mansfield PF *et al.* How many lymph nodes are enough during sentinel lymphadenectomy for primary melanoma? *Surgery* 2000;**128**:306-11.
244. Thompson JF, Uren RF, Shaw HM, McCarthy WH, Quinn MJ, O'Brien CJ *et al.* Location of sentinel lymph nodes in patients with cutaneous melanoma: new insights into lymphatic anatomy . *J.Am.Coll.Surg.* 1999;**189**:195-204.
245. Bianchi C, Habib FA, Morita E, Leong SP. Identification of bilateral breast sentinel lymph nodes draining primary melanoma of the back by preoperative lymphoscintigraphy and intraoperative mapping . *Clin.Nucl.Med.* 1999;**24**:501-3.
246. Wagner JD, Park HM, Coleman JJ, III, Love C, Hayes JT. Cervical sentinel lymph node biopsy for melanomas of the head and neck and upper thorax. *Arch.Otolaryngol.Head Neck Surg.* 2000;**126**:313-21.
247. Uren RF, Howman-Giles RB, Thompson JF, Malouf D, Ramsey-Stewart G, Niesche FW *et al.* Mammary lymphoscintigraphy in breast cancer . *J.Nucl.Med.* 1995;**36**:1775-80.

248. Majoufre C, Faucher A, Laroche C, De Bonfils C, Siberchicot F, Renaud-Salis JL *et al.* Supraomohyoid neck dissection in cancer of the oral cavity. *Am.J.Surg.* 1999;**178**:73-7.
249. Shah JP, Andersen PE. Evolving role of modifications in neck dissection for oral squamous carcinoma. *Br.J.Oral Maxillofac.Surg.* 1995;**33**:3-8.
250. Mamelle G. Selective neck dissection and sentinel node biopsy in head and neck squamous cell carcinomas . *Recent Results Cancer Res.* 2000;**157**:194-200.
251. Talmi YP, Hoffman HT, Horowitz Z, McCulloch TM, Funk GF, Graham SM *et al.* Patterns of metastases to the upper jugular lymph nodes (the "submuscular recess"). *Head Neck* 1998;**20**:682-6.
252. Fujitani T, Takahara T, Inoue K, Osamu K, Hattori H, Mizojiri G *et al.* Recurrence patterns of mobile tongue cancer after radical neck dissection. *Nippon Gan Chiryō Gakkai Shi* 1986;**21**:1008-15. (reference unobtainable – abstract only read)
253. Morton DL, Chan AD. Current status of intraoperative lymphatic mapping and sentinel lymphadenectomy for melanoma: is it standard of care? *J.Am.Coll.Surg.* 1999;**189**:214-23.
254. Alazraki N, Grant S, Styblo T. Is sentinel node staging for breast cancer standard care? The role of imaging [editorial]. *Nucl.Med.Comm.* 1999;**20**:1089-91.

255. McMasters KM, Giuliano AE, Ross MI, Reintgen DS, Hunt KK, Byrd DR *et al.* Sentinel-lymph-node biopsy for breast cancer— not yet the standard of care. *N.Engl.J.Med.* 1998;**339**:990-5.
256. Emilia JC, Lawrence W, Jr. Sentinel lymph node biopsy in malignant melanoma: the standard of care? [editorial]. *J.Surg.Oncol.* 1997;**65**:153-4.
257. Balch CM, Soong SJ, Bartolucci AA, Urist MM, Karakousis CP, Smith TJ *et al.* Efficacy of an elective regional lymph node dissection of 1 to 4 mm thick melanomas for patients 60 years of age and younger. *Ann.Surg.* 1996;**224**:255-63.
258. Williams BS, Hinkle GH, Douthit RA, Fry JP, Pozderac RF, Olsen JO. Lymphoscintigraphy and intraoperative lymphatic mapping of sentinel lymph nodes in melanoma patients. *J.Nucl.Med.Technol.* 1999;**27**:309-17.
259. Balch CM, Buzaid AC, Atkins MB, Cascinelli N, Coit DG, Fleming ID *et al.* A new American Joint Committee on Cancer staging system for cutaneous melanoma. *Cancer* 2000;**88**:1484-91.
260. Gershenwald JE, Mansfield PF, Lee JE, Ross MI. Role for lymphatic mapping and sentinel lymph node biopsy in patients with thick (> or = 4 mm) primary melanoma. *Ann.Surg.Oncol.* 2000;**7**:160-5.
261. Gershenwald JE, Colome MI, Lee JE, Mansfield PF, Tseng C, Lee JJ *et al.* Patterns of recurrence following a negative sentinel

- lymph node biopsy in 243 patients with stage I or II melanoma. *J.Clin.Oncol.* 1998;**16**:2253-60.
262. Balch CM, Buzaid AC, Atkins MB, Cascinelli N, Coit DG, Fleming ID *et al.* A new American Joint Committee on Cancer staging system for cutaneous melanoma. *Cancer* 2000;**88**:1484-91.
263. Gershenwald JE, Berman RS, Porter G, Mansfield PF, Lee JE, Ross MI. Regional nodal basin control is not compromised by previous sentinel lymph node biopsy in patients with melanoma. *Ann.Surg.Oncol.* 2000;**7**:226-31.
264. Alex JC, Krag DN, Harlow SP, Meijer S, Loggie BW, Kuhn J *et al.* Localization of regional lymph nodes in melanomas of the head and neck . *Arch.Otolaryngol.Head Neck Surg.* 1998;**124**:135-40.
265. Carlson GW, Murray DR, Greenlee R, Alazraki N, Fry-Spray C, Poole R *et al.* Management of malignant melanoma of the head and neck using dynamic lymphoscintigraphy and gamma probe-guided sentinel lymph node biopsy. *Arch.Otolaryngol.Head Neck Surg.* 2000;**126**:433-7.
266. Koops HS, Doting MH, de Vries J, Tiebosch AT, Plukker JT, Hoekstra HJ *et al.* Sentinel node biopsy as a surgical staging method for solid cancers. *Radiother.Oncol.* 1999;**51**:1-7.
267. Sandrucci S, Casalegno PS, Percivale P, Mistrangelo M, Bombardieri E, Bertoglio S. Sentinel lymph node mapping and

- biopsy for breast cancer: a review of the literature relative to 4791 procedures. *Tumori* 1999;**85**:425-34.
268. Morton DL, Chan AD. The concept of sentinel node localization: how it started. *Semin.Nucl.Med.* 2000; **30**:4-10.
269. Cox CE, Bass SS, McCann CR, Ku NN, Berman C, Durand K *et al.* Lymphatic mapping and sentinel lymph node biopsy in patients with breast cancer. *Annu.Rev.Med.* 2000;**51**:525-42.
270. Gadd MA, Cosimi AB, Yu J, Duncan LM, Yu L, Flotte TJ *et al.* Outcome of patients with melanoma and histologically negative sentinel lymph nodes. *Arch.Surg.* 1999;**134**:381-7.
271. Essner R, Conforti A, Kelley MC, Wanek L, Stern S, Glass E *et al.* Efficacy of lymphatic mapping, sentinel lymphadenectomy, and selective complete lymph node dissection as a therapeutic procedure for early- stage melanoma . *Ann.Surg.Oncol.* 1999;**6**:442-9.
272. Morton DL, Thompson JF, Essner R, Elashoff R, Stern SL, Nieweg OE *et al.* Validation of the accuracy of intraoperative lymphatic mapping and sentinel lymphadenectomy for early-stage melanoma: a multicenter trial. Multicenter Selective Lymphadenectomy Trial Group. *Ann.Surg.* 1999;**230**:453-63.
273. Eggermont AM. Adjuvant therapy of malignant melanoma and the role of sentinel node mapping . *Recent Results Cancer Res.* 2000;**157**:178-89.

274. Landi G, Polverelli M, Moscatelli G, Morelli R, Landi C, Fiscelli O *et al.* Sentinel lymph node biopsy in patients with primary cutaneous melanoma: study of 455 cases . *J.Eur.Acad.Dermatol.Venereol.* 2000;**14**:35-45.
275. 1st International Congress on the Sentinel Node in Diagnosis and Treatment of Cancer. Amsterdam, The Netherlands, April 7-10, 1999. Proceedings and abstracts. *Eur.J.Nucl.Med.* 1999;**26**:S1-103.
276. Haddad FF, Stall A, Messina J, Brobeil A, Ramnath E, Glass LF *et al.* The progression of melanoma nodal metastasis is dependent on tumor thickness of the primary lesion. *Ann.Surg.Oncol.* 1999;**6**:144-9.
277. Brady MS, Coit DG. Sentinel lymph node evaluation in melanoma. *Arch.Dermatol.* 1997;**133**:1014-20.
278. Noguchi M, Tsugawa K, Bando E, Kawahara F, Miwa K, Yokoyama K *et al.* Sentinel lymphadenectomy in breast cancer: identification of sentinel lymph node and detection of metastases. *Breast Cancer Res.Treat.* 1999;**53**:97-104.
279. Bieligg SC, Ghossein R, Bhattacharya S, Coit DG. Detection of tyrosinase mRNA by reverse transcription-polymerase chain reaction in melanoma sentinel nodes . *Ann.Surg.Oncol.* 1999;**6**:232-40.
280. Blaheta HJ, Schitteck B, Breuninger H, Sotlar K, Ellwanger U, Thelen MH *et al.* Detection of melanoma micrometastasis in sentinel nodes by reverse transcription-polymerase chain

- reaction correlates with tumor thickness and is predictive of micrometastatic disease in the lymph node basin. *Am.J.Surg.Pathol.* 1999;**23**:822-8.
281. Bostick PJ, Morton DL, Turner RR, Huynh KT, Wang HJ, Elashoff R *et al.* Prognostic significance of occult metastases detected by sentinel lymphadenectomy and reverse transcriptase-polymerase chain reaction in early-stage melanoma patients. *J.Clin.Oncol.* 1999;**17**:3238-44.
282. Li W, Stall A, Shivers SC, Lin J, Haddad F, Messina J *et al.* Clinical relevance of molecular staging for melanoma: comparison of RT-PCR and immunohistochemistry staining in sentinel lymph nodes of patients with melanoma. *Ann.Surg.* 2000;**231**:795-803.
283. Shivers SC, Wang X, Li W, Joseph E, Messina J, Glass LF *et al.* Molecular staging of malignant melanoma: correlation with clinical outcome. *JAMA* 1998;**280**:1410-5.
284. Bostick PJ, Huynh KT, Sarantou T, Turner RR, Qi K, Giuliano AE *et al.* Detection of metastases in sentinel lymph nodes of breast cancer patients by multiple-marker RT-PCR. *Int.J.Cancer* 1998;**79**:645-51.
285. Cox CE, Haddad F, Bass S, Cox JM, Ku NN, Berman C *et al.* Lymphatic mapping in the treatment of breast cancer. *Oncology (Huntingt)* 1998;**12**:1283-92.

286. Kataoka A, Mori M, Sadanaga N, Ueo H, Tsuji K, Rai Y *et al.* RT-PCR detection of breast cancer cells in sentinel lymph nodes. *Int.J.Oncol.* 2000;**16**:1147-52.
287. Peralta EA, Yarrington CT, Glenn MG. Malignant melanoma of the head and neck: effect of treatment on survival. *Laryngoscope* 1998;**108**:220-3.
288. Reintgen DS, Brobeil A. Lymphatic mapping and selective lymphadenectomy as an alternative to elective lymph node dissection in patients with malignant melanoma. *Hematol.Oncol.Clin.North Am.* 1998;**12**:807-21, vii.
289. Takagi M, Kayano T, Yamamoto H, Shibuya H, Hoshina M, Shioda S *et al.* Causes of oral tongue cancer treatment failures. Analysis of autopsy cases. *Cancer* 1992;**69**:1081-7.
290. Ho CM, Lam KH, Wei Wf, Lau SK, Lam LK. Occult lymph node metastasis in small oral tongue cancers. *Head Neck* 1992;**14**:359-63.
291. Lehman RH, Cox JD, Beison TP, Yale RS, Byhardt RW, Toohill RJ *et al.* Recurrence patterns by treatment modality of carcinomas of the floor of the mouth and oral tongue. *Am.J.Otolaryngol.* 1982;**3**:174-81.
292. Leslie A, Fyfe E, Guest P, Goddard P, Kabala JE. Staging of squamous cell carcinoma of the oral cavity and oropharynx: a comparison of MRI and CT. *J.Comput.Assist.Tomogr.* 1999;**23**:43-9.

293. Ferlito A, Rinaldo A. False negative conventional histology of lymph nodes in patients with head and neck cancer. *ORL J.Otorhinolaryngol.Relat Spec.* 2000;**62**:112-4.
294. Zitsch RP, III, Todd DW, Renner GJ, Singh A. Intraoperative radiolymphoscintigraphy for detection of occult nodal metastasis in patients with head and neck squamous cell carcinoma. *Otolaryngol.Head Neck Surg.* 2000;**122**:662-6.
295. Pitman KT, Johnson JT, Edington H, Barnes EL, Day R, Wagner RL *et al.* Lymphatic mapping with isosulfan blue dye in squamous cell carcinoma of the head and neck. *Arch.Otolaryngol.Head Neck Surg.* 1998;**124**:790-3.
296. Koch WM, Choti MA, Civelek AC, Eisele DW, Saunders JR. Gamma probe-directed biopsy of the sentinel node in oral squamous cell carcinoma. *Arch.Otolaryngol.Head Neck Surg.* 1998;**124**:455-9.

