



University
of Glasgow

<https://theses.gla.ac.uk/>

Theses Digitisation:

<https://www.gla.ac.uk/myglasgow/research/enlighten/theses/digitisation/>

This is a digitised version of the original print thesis.

Copyright and moral rights for this work are retained by the author

A copy can be downloaded for personal non-commercial research or study,
without prior permission or charge

This work cannot be reproduced or quoted extensively from without first
obtaining permission in writing from the author

The content must not be changed in any way or sold commercially in any
format or medium without the formal permission of the author

When referring to this work, full bibliographic details including the author,
title, awarding institution and date of the thesis must be given

Enlighten: Theses

<https://theses.gla.ac.uk/>
research-enlighten@glasgow.ac.uk

Studies on the Δ^5 - 3β - Hydroxysteroid Dehydrogenases
in the Sebaceous Glands of Skin

A thesis submitted to the University of Glasgow in
candidature for the degree of

Doctor of Philosophy

in the

Faculty of Medicine

by

Anita Vera Muir, B.Sc.,

Department of Dermatology,
Anderson College,
The University,
Glasgow

ProQuest Number: 10647735

All rights reserved

INFORMATION TO ALL USERS

The quality of this reproduction is dependent upon the quality of the copy submitted.

In the unlikely event that the author did not send a complete manuscript and there are missing pages, these will be noted. Also, if material had to be removed, a note will indicate the deletion.



ProQuest 10647735

Published by ProQuest LLC (2017). Copyright of the Dissertation is held by the Author.

All rights reserved.

This work is protected against unauthorized copying under Title 17, United States Code
Microform Edition © ProQuest LLC.

ProQuest LLC.
789 East Eisenhower Parkway
P.O. Box 1346
Ann Arbor, MI 48106 – 1346

INDEX

	<u>Page</u>
Acknowledgements	1.
List of Tables	3.
List of Figures	5.
List of Publications enclosed	7.
Convention for Citing References	8.
Abbreviations used	9.
General Introduction	11.
Purpose of Research	45.
Introduction to the Experimental Work	46.
Part I Techniques	46.
Part II Semiquantitation	56.
Part III Survey of Distribution	63.
Part IV Experimental Animal Studies	64.
Part V Iodoacetate Trials	69.
Part VI Abnormal Skins	71.
Part VII Other Experiments	71.
Methods	77.
Results	117.
Discussion	179.
Summary and Conclusion	203.
Bibliography	205.
Publications enclosed	232.

ACKNOWLEDGEMENTS

I would like to express my sincere appreciation to the many people who helped me in the course of my work.

Firstly to Professor J.A. Milne of the Department of Dermatology, Glasgow University, for his ever present wise counsel, kind advice and helpful criticism.

Also Dr. J.K. Grant of the Steroid Biochemistry Department, Glasgow University who has so patiently, on so many occasions explained and discussed the biochemical aspect of this project.

Professor J.N. Davidson of the Biochemistry Department, Glasgow University for the kind help and encouragement which he extended together with the permission to use some of the equipment in his department.

Professor G.P. Talwar of the Biochemistry Department, All India Institute of Medical Science, New Delhi for his kind help and advice during that part of my work which I carried out in his department.

Professor Aitchison of the Department of Statistics, Glasgow University for his kind help with the statistical considerations regarding the quantitation of the technique used.

Also Dr. J. Thomson, Dr. R. Thompson, Mr. H. Young, and my friends and colleagues who were kind enough to advise and encourage me during the course of this work.

I/

I should also wish to thank the Wellcome Fund for their financial assistance towards a part of this work and the editor of the British Journal of Dermatology for his kind permission to allow me to endorse some of the tables and data previously printed and also submitted for printing in the enclosed publications (4).

I also wish to express my sincere appreciation to Miss L. Banks for the presentation and typing of the thesis and to Mr. I. McKie for the photographic preparations and diagrams.

TABLES

<u>Table</u>		<u>Page</u>
1.	Histochemical assays using inhibitors	128
2.	Effect of preincubation in buffer on several dehydrogenases	128
3.	Advantages and disadvantages associated with various methods of incubation	130
4.	Comparison of numbers of granules/sq. μ in stained and unstained sections	133
5.	Variation of one field counted by one observer by the Wild M20 microscope method	136
6.	Variation of counting between two observers	138
7.	Fluorimetric estimations of NADH	143
8.	Age and sex distribution of specimens	145
9.	Distribution of sebaceous glands in different regions of the body	146
10.	Age distribution of 3β HSD activity	147
11.	Sex distribution	148
12.	Enzyme activity associated with body area of skin	149
13.	Syrian hamster experiments	160
14.	Iodoacetate trials	164
15. /		

<u>Table</u>		<u>Page</u>
15.	Abnormal skins	166
16.	NAD and NADP in histochemical incubations of human skin sections	171
17.	NAD and NADP in histochemical incubations of animal skin sections	172
18.	DHA-SO ₄ as steroid substrate in histochemical tests of 3 β HSD activity in human skin	174
19.	Histochemical assays using other steroid substrates in human and in rat skin sections	176

FIGURES

<u>Figure</u>	<u>Page</u>
1. General metabolism of some steroid compounds	16
2. Possible routes of synthesis of testosterone from DHA	21
3. 3β HSD in pregnenolone-progesterone metabolism	30
4. 3β HSD in DHA metabolism	34
5. Enzymes involved in the histochemical method described	36
6. The cryostat, showing knife, slide and a sample of skin mounted on chuck	47
7. The two pathways proposed for the conversion of Δ^4 -3 keto-steroids to Δ^5 - 3β alcohols	50
8. Skin section showing diaphorase activity after incubation with NADH	55
9. Diagrammatic representation of 3β HSD distribution in the sebaceous gland (traced with the aid of the Wild M20 microscope)	60
10. The Mongolian gerbil (<u>Meriones unguiculatus</u>) with shaved abdomen showing centrally situated glandular pad	66
11. Deep staining of hair-shaft resulting from histochemical incubation	70
12. Incubation techniques 1 - 4	82
13. Incubation technique No. 5 perspex chamber	84
14. /	

<u>Figure</u>		<u>Page</u>
14.	Wild M20 microscope with drawing tube attachment	92
15.	Diagrammatic representation of the spectrophotometer (by courtesy of Aminco-Bowman)	96
16.	NAD concentration curve	118
17.	DHA concentration curve	119
18.	Effect of magnesium	120
19.	Effect of nicotinamide	121
20.	Effect of Vitamin K	122
21.	Time course of reaction (a)	123
22.	Time course of reaction (b)	124
23.	Skin section counterstained following incubation showing the deposition of diformazan granules in the sebaceous gland	131
24.	Distribution of 3β HSD in the sebaceous gland of human skin	141
25.	Distribution of 17β HSD in the sebaceous gland of human skin	141
26.	Rat skin showing 3β HSD activity in sebaceous glands	153
27.	Rat preputial gland showing 3β HSD activity	154
28.	Guinea pig lip skin section showing 3β HSD activity in the sebaceous glands	156
29.	Gerbil glandular pad section <u>before</u>	159
30.	and <u>after</u> treatment of animal with testosterone	159
31.	Hamster costovertebral organ section <u>before</u>	162
32.	and <u>after</u> treatment of animal with androgens	162
33.	Section of human scalp skin showing 6β HSD activity only in the sebaceous gland duct	177

LIST OF PUBLICATIONS ENCLOSED

1. Muir, A.V., Calman, K.C., Thomson, J., MacSween, M.P.,
Milne, J.A., Chakraborty, J., and Grant, J.K.,
Hydroxysteroid Dehydrogenase Activity in Human Skin
I Histochemical Techniques for the Demonstration of Hydroxysteroid
Dehydrogenase and a Method for the Semi-quantitation of
its Activity.
Br. J. Derm., 80, 594, 1968
2. Muir, A.V., Calman, K.C., Thomson, J., MacSween, M.P.,
Milne, J.A., Chakraborty, J., and Grant, J.K.,
Hydroxysteroid Dehydrogenase Activity in Human Skin
II Factors Influencing Hydroxysteroid Dehydrogenase Activity in
Sebaceous Glands of Human Skin.
Br. J. Derm., 80, 652, 1968
3. Calman, K.C., Muir, A.V., Milne, J.A., and Young, H.,
Survey of the Distribution of Steroid Dehydrogenases in Sebaceous
Glands of Human Skin.
Br. J. Derm., 1970 (in press)
4. Muir, A.V., Hodgins, M.B., Milne, J.A., and Young, H.,
The Presence of Hydroxysteroid Dehydrogenases in Mammalian
Sebaceous Structures.
Br. J. Derm., 1970 (in press)

CONVENTION FOR STEROID NOMENCLATURE

Steroid Nomenclature used in accordance with IUPAC Commission on the Nomenclature of Organic Chemistry and IUPAC - IUB Commission on Biochemical Nomenclature, 1969.

CONVENTION FOR CITING REFERENCES

The rules followed of citing references in the bibliography of the thesis obey the rules of ISO Recommendation R4 accepted in the Geneva Meeting of July 1953 and stated in World Medical Periodicals of the World Medical Association reprinted in 1968.

References cited within the text of the thesis give only the name of the author, or the first author in the case of a publication having multiple authors and the year of publication.

ABBREVIATIONS USED

HSD	Hydroxysteroid dehydrogenase
3 β -HSD	Δ^5 -3 β -Hydroxysteroid dehydrogenase
DHA	Dehydroepiandrosterone whose full name is 3 β Hydroxy-5-androsten-17-one
NAD	Nicotinamide-adenine dinucleotide (also known as DPN: Diphosphopyridine nucleotide)
NADH	Reduced form of NAD as above
NADP	Nicotinamide-adenine dinucleotide phosphate (also known as TPN: triphosphopyridine nucleotide)
NADPH	Reduced form of NADP as above
Nitro BT	Nitro blue tetrazolium
DMF	Dimethyl formamide
Testosterone	17 β Hydroxy-4-androsten-3-one
Oestradiol	1, 3, 5 (10) Oestratriene-3, 17 β -diol
Cyproterone-acetate	6-Chloro-17-acetoxy-1 α , 2 α -methylene-4, 6-pregnadiene- 3, 20-dione
PVP	Polyvinylpyrrolidone
DHA-SO ₄	Dehydroepiandrosterone sulfate
Dihydrotestosterone	17 β Hydroxy 5 α androstan-3-one
Oestriol	1, 3, 5 (10)-Oestratrien-3, 16 α , 17 β -triol
Oestrone /	

Oestrone	3-Hydroxy-1, 3, 5 (10)-oestratrien-17-one
Androsterone	3 α -Hydroxy-5 α -androstan-17-one
Androstenedione	4-Androsten-3, 17-dione
Androstenediol	3 β , 17 β -Dihydroxy-5-androsten
Pregnenolone	3 β Hydroxy-5-pregnan-20-one
Progesterone	4-Pregnene-3, 20-dione
Aldosterone	11 β , 21-Dihydroxy-3, 20-dioxo-4-pregnene-18-al
Cortisone	(Compound E) 17 α 21-Dihydroxy-4-pregnene-3, 11, 20-trione
Cortisol	(Hydrocortisone) (Compound F) 11 β , 17 α , 21-Trihydroxy-4-pregnene-3, 20-dione
Corticosterone	(Compound B) 11 β , 21-Dihydroxy-4-pregnene-3, 20-dione
Deoxycorticosterone	(DOC) 21-Hydroxy-4-pregnene-3, 20-dione
Epiandrosterone	3 β -Hydroxy-5 α -androstan-17-one
Etiocholanolone	3 α -Hydroxy-5 β -androstan-17-one

GENERAL INTRODUCTION

Introduction

Skin, the largest single organ of the human body covering as it does a total area of 15000 sq.in. in the adult human has, because of the technical difficulties hitherto associated with working with this tissue, received comparatively little attention from medical research workers.

The skin is composed of various components or parts and is made up of many different populations of cells. It can be subdivided into the epidermis and the dermis. The skin appendages arise from the epidermis embryologically but lie in the dermal layer. These appendages consist of the pilosebaceous follicle and the sweat glands and the apocrine glands, the latter arising embryologically from the pilosebaceous unit. Below the epidermis and the dermis, which go to make up the skin, lies the subcutaneous tissue through which the skin is supplied with nerves and blood vessels. Different types of cells are found in the skin. The epidermis is made up of squamous cells while in the dermis are found fibroblasts and collagen. The sebaceous gland cells arising as they do from the epidermis, are therefore modified squamous cells.

Sebaceous glands were first described by Eichorn in 1826. They are characteristic of mammals, display species difference and although structurally similar, they show some degree of variation over the surface of the body. Sebaceous gland develops early in the embryo (at $3\frac{1}{2}$ - 4 months) as part of the pilosebaceous unit: it forms as the upper of two swellings which appear on the posterior side of the hair follicle. This/

This swelling grows and develops into a sebaceous gland, whose duct opens inside the pilosebaceous canal. Sebaceous glands which are functionally dormant in the prepubertal child, become active at the onset of puberty and are found in the adult to be distributed throughout the area of the skin except on the palms of the hands and the soles of the feet. They vary between the different regions of the body in their size and number, but are found to be largest and most numerous on the face and forehead. The sebaceous glands of the face are large and multiacinar. They open either into a widely dilated follicular canal through a short duct, or some on the face open directly on to the surface of the skin. These extra large sebaceous glands are called sebaceous follicles (Kligman and Shelley 1958). Large and numerous sebaceous glands are also found on the scalp so that the head region in general is particularly richly endowed with sebaceous glands. To a lesser extent the upper back and chest region possesses large sebaceous glands while over the remainder of the body they are much smaller and less densely distributed (Montagna 1963, Benfenati and Brilli, 1939).

Sebaceous glands are holocrine usually multiple acinar glands in which the cells show a centripetal enlargement. The cells towards the centre of the gland become laden with lipid droplets and swell until they become fragmented and form the sebum which fills the lumen of the gland and travels out through the duct. The process of development which the sebaceous gland cells undergo is called "sebaceous differentiation".

The/

The functions attributed to sebum are many and mostly speculative ones as very little of its biological significance is known for certain. The uses assigned to it include antibacterial and antifungal effects, inhibition of water loss and the implementation of barrier function (Kligman in *Advances of Biology of Skin*, 1963). It has also been suggested that it plays a part in the synthesis of Vitamin D and also that it is responsible for that cholesterol synthesis which is thought to occur in the skin (Baillie, 1964). What is certain is that sebaceous gland development and the secretion of sebum is closely related to the androgenic metabolism and sexual maturity of the individual. This can be ascertained in man where sebaceous glands are undifferentiated and inactive throughout childhood only to begin growing rapidly at the onset of puberty, this effect being accompanied by considerable increase in the amount of sebum excreted on the skin surface (Strauss and Pochi, 1964). It can also be reflected in the development of special sebaceous structures such as preputial gland in rat (Ebling and Skinner, 1967) or the territorial marking in the gerbil (Thiessen 1968) which develop fully with the onset of sexual maturity and are clearly associated with the androgenic hormones. The function of the sebaceous gland as the target organ of androgenic hormones has aroused considerable interest in medical research.

The nature of the stimulation which the sebaceous gland receives at puberty is not very well understood, especially in the female. In the male sebaceous gland hyperfunction has been established (Hamilton, 1941) for the following reasons:-

- 1./

1. Prepubertal individuals, castrates and eunachoid males do not develop acne or seborrhoea.
2. If the above mentioned individuals are treated with large doses of testosterone they do develop acne (providing the pituitary gland is intact).
3. Normal males and females when treated with large doses of testosterone may develop acne. (Strauss et al., 1962)
4. Also the administration of testosterone to normal rats produces a pronounced enlargement of the sebaceous gland (Haskin et al., 1953).

It has in fact often been suggested that acne vulgaris may be associated with excessive androgen production, particularly since acne lesions may result from the administration of androgens. The exact causes of acne vulgaris are still far from clear but it is accepted that sebaceous gland hyperfunction occurring at the onset of puberty, may lead to the development of juvenile acne vulgaris (Vadasz and Debreczeni, 1966) and thus in any considerations as to the causes and cure of acne one has to approach via a study of the sebaceous gland. The attention of dermatologists has long been directed to the obvious association between acne and puberty. The fact that acne is absent in eunochs followed by the observation of the stimulating effect of testosterone on the sebaceous gland (Rony and Zakon, 1943) suggests a connection between the occurrence of acne and sebaceous gland activity, when stimulated by androgens.

Sebaceous/

1

Sebaceous gland activity is recognised to be the result of androgenic stimulation in the presence of the pituitary (Ebling, 1948, 1951, Hamilton, 1941, 1947, Hooker and Pfeiffer, 1943, Lapière, 1953, Haskin et al., 1953 etc.). The pituitary must be present for androgenic stimulation of the sebaceous gland to take effect. Hypophysectomised rats do not show any marked changes in sebaceous gland size or sebum secretion after treatment with testosterone, even given in large amounts (0.2 mg/day for 3 weeks) (Ebling, 1957). It has been suggested that the pituitary effects a permissive action through a "sebotropic factor". (Lorincz and Lancaster, 1957). To consider the further implications of androgenic control of sebaceous glands, it is necessary to discuss some of the known facts about the androgens in the context of steroid metabolism in general. Figure I sets out briefly some of the metabolic pathways of the steroid hormones, their synthesis, transformation and some of the breakdown reactions they undergo in the body. The figure shows the major pathways which occur in the adrenal gland, the testis and the ovary. The testis and the ovary are responsible for the synthesis of the androgens and the oestrogens, while the adrenal glands accounts for the other steroid derivatives.

Testosterone was implicated first as an agent capable of causing enlargement of sebaceous glands by Montagna in 1941. It is testosterone, the most active androgenic substance which is still considered of fundamental importance in the observations regarding sebaceous gland activity and therefore in the discussion which follows, testosterone will be primarily considered. In/

In the male this hormone is formed by the testis and therefore its origins present no problem. In the female however the sudden development of the sebaceous glands at puberty remains to be explained. Both dehydroepiandrosterone (DHA) and Δ^4 -androstenedione which are synthesised by the adrenal glands are known to be precursors of testosterone (Neher and Wettstein, 1960, Kahut 1961). It is thought that DHA or dehydroepiandrosterone sulfate (DHA-SO₄) (Korenman and Lipsett, 1961) is converted to testosterone or testosterone-glucuronide,

In the male testosterone is mainly of testicular origin and testosterone levels fall after orchiectomy (Rosner and Conte 1966). In the female the source of testosterone is, as mentioned earlier not quite clear, but as some conversion of Δ^4 -androstenedione to testosterone occurs in women, both these steroids must be considered. Some light is thrown on the subject of androgen production in women by considering abnormal situations such as arise in hirsutism, which may be an accompaniment of certain adrenocortical or ovarian diseases. In hirsutism caused by the Stein-Leventhal Polycystic Ovary Syndrome, one finds that 17-keto steroid excretion patterns are not greatly raised above normal values (Goldzieher and Axelrod, 1962) while plasma and urinary testosterone levels are higher than normal (Bardin and Lipsett, 1967) and Futterweit *et al.*, (1964). Plasma Δ^4 -androstenedione levels are also higher than normal (Horton and Neisler, 1968). Both testosterone and Δ^4 -androstenedione production rates are increased but less Δ^4 -androstenedione is converted to testosterone than in normal women. (Bardin/

(Bardin, Hembree and Lipsett, 1968).

There is evidence that both the ovary and the adrenal gland act as source of androgen in this syndrome as in vitro synthesis of Δ^4 - androstenedione and testosterone from various steroid substrates is greater in polycystic ovarian tissue than in normal ovaries (Jeffcoate et al., 1968). Savard et al., (1965) claim that there are no abnormal pathways of metabolism in the polycystic ovary but that the resultant manifestation of hirsutism is due to an excess of ovarian stroma causing a shift in the pattern of secretory products and a consequent excessive accumulation of testosterone.

All these considerations would explain the difference which is found between testosterone production rates as measured by urinary and blood testosterone. Mahesh and Greenblast (1959) demonstrated a rise in plasma testosterone after administration of DHA. Horton and Tait (1958) showed that in females a large proportion of Δ^4 -androstenedione is converted into testosterone. The role of DHA-SO₄ in pregnancy and its significance in the plasma will be described more fully under the special introductory section dealing with DHA-SO₄.

The correlation between metabolic clearance rate and the dilution of intravenously administered labelled testosterone is found to be good in the male as would be expected in view of the direct metabolic synthesis of this hormone in the male, and it is found to be bad in the female where as explained most of the circulating testosterone originates from other steroid compounds.

Testosterone/

Testosterone is also formed from progesterone and 17α -hydroxypregnenolone (Slaunwhite and Samuels, 1956). In the blood, testosterone and Δ^4 -androstenedione are at equilibrium. While in the male there is more testosterone formed, in the female there is more Δ^4 -androstenedione. This explains the rise in circulating androgens which occurs in both males and females at puberty when the glands mature giving rise to testosterone in the male and oestrogens and progesterone (thus also testosterone) in the female.

The whole problem of androgen balance has only recently become fully understood since modern methods for measuring the levels of testosterone in plasma and urine have been developed. These methods include double isotope dilution techniques (Dulmanis et al., 1964) and direct assays using gas liquid chromatography (Futterweit et al., 1964). The accurate measurements of the amounts of testosterone in plasma and urine have given us new insight into the metabolic pathways of the androgens and their transformations in males and females. The studies of Horton and Tait (1966) for instance have done much to elucidate the question of Δ^4 -androstenedione-testosterone conversions in males and females which by proving conclusively the derivation of testosterone in the female from Δ^4 -androstenedione has explained the pubertal development of the sebaceous gland which has been mentioned above. There is now evidence that androgens are produced directly by the ovaries. Both androstenedione and testosterone are produced *in vitro* by ovarian homogenates (Savard et al., 1965). In ovariectomized women, plasma testosterone levels fall (Lamb et al., 1964). It/

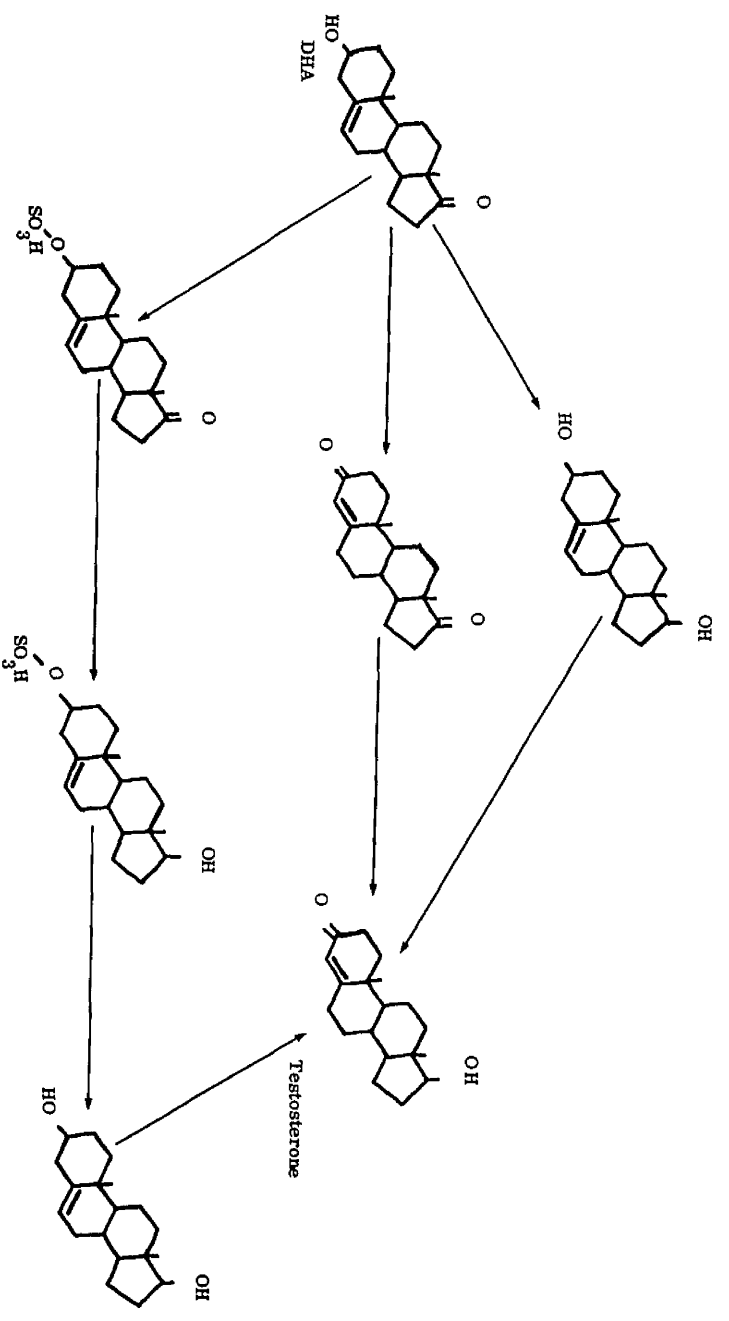
It can now be conclusively stated that in the female just as in the male there occurs at puberty an increase in circulating androgens, arising from the ovary and from the adrenal cortex which is now known to synthesise Δ^4 -androstenedione and testosterone (Kase and Kowal, 1962).

Besides these three basic sites: adrenal cortex, testis and ovary, it had been suggested that peripheral tissues may also play a part in androgen metabolism. It was therefore an important breakthrough when in 1965/66 Baillie *et al.*, demonstrated the presence of hydroxysteroid dehydrogenases in the skin. This demonstration was histochemical, but at about the same time Rongone (1966) showed that skin metabolized testosterone *in vitro* giving rise to 5α -androstane- 3α -ol, 17-one, 5α -androstane-3, 17-dione, Δ^4 -androstenedione, and 5β -androstane- 3α -ol, 17-one, while Cameron, 1966 and Faredin, 1967 presented evidence that skin can metabolize DHA *in vitro* with the formation of several steroids. Figure 2 illustrates possible pathways of DHA metabolism resulting in the formation of some steroid compounds mentioned above.

Various groups of workers (Cook and Lorincz, 1963, Julesz *et al.*, 1966, Dubovyi, 1967) tried to show the presence of androgenic steroids in skin surface lipids. Among the steroids identified *in vitro* studies of incubating skin with testosterone or Δ^4 -androstenedione was dihydrotestosterone (Gomez and Hsia 1968). This androgen (5α -androstane- 17β -ol-3-one) is an interesting compound which is thought to be the active androgen at the nuclear site of action in certain target tissues in some species (Bruchovsky and Wilson, 1968).

In/

Figure 2 Possible routes of synthesis of testosterone from DHA



In connection with this recent development in androgen metabolism, one may consider another disease which though rare provides an interesting connection with the study of the skin. In patients suffering from testicular feminization, the testis can synthesize oestrogens and androgens in vitro when incubated with steroid precursors (Griffiths, et al., 1963). Plasma testosterone levels and testosterone production rates are in the range of the normal male (Southern et al., 1965). The testosterone is apparently available to the peripheral target organs since no abnormal urinary androgens have been found after injections of labelled testosterone (French et al., 1965, 1966). It seems therefore that the defect in this disease is due to an inability of target tissues to respond to androgen. Decreased conversion of testosterone to dihydrotestosterone in some tissues of patients suffering from this disease has been shown in vitro by Northcutt et al., 1969. In vitro studies involving the skin of these patients provide further support for this theory (Heinrick et al., 1969, Wilson and Walker, 1969). In vivo studies by Mauvais-Jarvis (1969) provide evidence that normal skin has a 5α -reductase responsible for the conversion of testosterone to dihydro-testosterone and that this enzyme is absent in patients with testicular feminization.

Sebum production in patients with this disease is much lower than in normal individuals (Gwinup et al., 1966) and it would seem that the sebaceous gland reflects the general lack of response to androgen stimulation which characterises this condition.

Results are accumulating from recent work mentioned above, that the skin plays an active part in steroid metabolism. So far there is no agreement as to the precise site of activity of steroid metabolism in the skin.

Histochemical/

Histochemical work beginning with the observations reported by Baillie et al., and the investigations carried on from there by this group of co-workers, points to the sebaceous gland as being this active site. Gallegos and Berliner (1967) however in their work on tissue culture of the dermis have demonstrated the presence of Δ^5 - 3β -ol-steroid dehydrogenase (3β HSD) system activity in L - 929 fibroblasts in tissue culture, and they stress the importance of fibroblasts in steroid biotransformations in the skin.

Endocrine factors have been known since a long time to regulate the size and the sebum producing activity of sebaceous glands. Various groups of investigators have carried out studies on the effect of steroidal hormones on the skin of man (Strauss and Pochi, 1963) and rat (Ebling, 1957) - Testicular androgen has been unequivocally implicated in the direct stimulation of sebaceous gland activity. Orchiectomy leads to reduction of sebaceous gland activity (Pochi and Strauss, 1963).

It has been established that increase in the rate of sebum secretion is achieved by the androgens by -

1. an increase in cell division of sebaceous glands
2. an increase in sebum synthesis within each sebaceous cell.

In contrast to this oestrogens are found to suppress sebaceous glands (Bullough and Laurence, 1960) and decrease sebum production perhaps by increasing the turnover rate of cells of the sebaceous gland.

The/

The administration of testosterone causes an enlargement of the sebaceous glands, while the administration of oestradiol causes the sebaceous gland to decrease in size. Simultaneous administration of testosterone and oestradiol has no overall effect on the sebaceous glands and it is thought that there is no direct antagonism between oestrogens and androgens as to their peripheral effect on sebaceous glands. (Strauss, Kligman and Pochi, 1962).

The effect of androgens on the sebaceous gland is thought to be direct because topical application leads to a local response (Dorfman, 1961). As evidenced by the enlargement of the sebaceous gland in the mouse skin following local application of testosterone (Lapière, 1953) as well as increased sebum production in areas of skin subjected to local application of testosterone in man (Strauss et al., 1962).

Both oestrogens and antiandrogenic substances have been found in experimental systems to inhibit sebaceous gland activity (Strauss et al., 1969, Saunders and Ebling, 1969). Progesterone does not seem to have any effect on the sebaceous gland if administered in physiological amounts (Strauss and Kligman, 1961). If administered in large amounts it does lead to enlargement of the sebaceous glands. This is thought to be due possibly to some metabolic conversion to androgens (Haskin et al., 1953).

Adrenal steroids are thought to have an additional function in mediating sebaceous gland activity. Sebum production decreases after adrenalectomy. Cortisone and hydrocortisone therapy increase sebum production. DHA is the adrenal steroid hormone thought to be principally involved in stimulating sebaceous gland activity (Pochi et al., 1963). The/

The administration of Δ^4 -androstenedione also results in sebaceous gland stimulation (Pochi and Strauss, 1969). Cortisone and hydrocortisone therapy increase sebum production. Moreover other hormones than the steroids are thought to play a role in the control of sebaceous gland function.

Removal of the pituitary from ovariectomized rats results in the atrophy of sebaceous glands. (Lasher et al., 1954). It is therefore clear that the sebaceous glands are affected by hormones. They are stimulated by androgens (though not in the absence of the pituitary) and inhibited by oestrogens. Simultaneous administration of androgens and oestrogens indicates that they do not antagonise each other's action (Strauss et al., 1962) suggesting that they have different modes of action on the sebaceous gland. While the most important effect of androgens is to increase cell proliferation and the size of sebaceous cells as well as to decrease turnover time, oestrogens reduce sebaceous gland volume, seemingly by increasing turnover time, but not by any effect on mitotic division rate. Androgens show no effect in hypophysectomized rats while oestrogens are equally effective in intact, hypophysectomized or adrenalectomized rats: their effect is independent of mediation through the pituitary, gonads and adrenals (Ebling, 1957).

If it is assumed that acne is related to an increased activity of the sebaceous gland, then the administration of large doses of androgens would be thought to provoke the development of acne - which it does (Strauss et al., 1962) while oestrogen treatment would be expected to give rise to an improvement in acne - which in fact is reported to happen (Ebling, 1967).
Haskin/

Haskin et al., suggested in 1953 that adolescent seborrhoea and acne in the male is caused by an excessive production of testicular androgens and in the female by androgens from the adrenals. Hamilton (1941) presented evidence that androgen is an incitant of pubertal acne as prepubertal subjects to whom testosterone was administered in large doses, develop acneform eruptions. Normally, however, in individuals suffering from acne, one does not find higher blood testosterone levels. In considering the influence of steroid hormones on sebaceous glands and on acne Kalz, (1958) recognised the stimulating effects of androgens on sebaceous gland (Hamilton, 1941) and at the same time reported the successful results of testosterone therapy in acne. He also described the poor results obtained in oestrogen therapy in spite of the fact that oestrogens cause atrophy of the sebaceous gland (Ebling, 1948).

And so although it is coming on to thirty years since the important work of Hamilton in describing the part which androgens play in acne (Hamilton, 1941) it is only within the last few years that an explanation seems to become available. Since the elucidation of the metabolic pathways of the vast network of steroid substances in the human body and the recognition of the important role played by hydroxysteroid dehydrogenases have come to light, the realisation has grown that it is within the sebaceous gland that we must look for the elucidation of many problems. The answers to such questions as the peripheral transformations of androgenic substances in the correlation between hormonal action and metabolic activity and the search for a sensitive test point for androgenic activity, may be found in the understanding of the sebaceous gland.

The/

The connection which is established between androgenic hormones and acne does not imply that acne is caused directly by an excess of androgens. The cause of acne is unknown. All that can be said is that androgens in the presence of the pituitary stimulate the sebaceous gland activity. Sebaceous glands seem to be the major site of bacterial growth on the skin. (Evans et al., 1950). There exists a hypothesis that at puberty the higher levels of circulating androgens appear to cause follicular hyperkeratosis which results in the pilosebaceous duct becoming blocked. This blockage sets up in the duct anaerobic conditions suitable for bacterial development and this gives rise to the development of the acneform eruption.

Strauss and Pochi (1965) studied the effect of injecting lipid material taken from the skin surface and from comedones into human skin of scalp or back. From their studies it appears that sebaceous lipids gaining access to the dermis elicit a response similar to that in acne and moreover free fatty acids play a major role in this response. When these authors injected freshly formed sebum into the skin they got no response. When, however, they injected fresh sebum + free fatty acids, the response of the skin resembled acne. Although sebum freshly formed by the sebaceous gland contains no free fatty acids, these are formed by the action of bacterial lipases on the sebum and the injection of Corynebacterium acnes into keratinous cysts initially devoid of free fatty acids, induces an inflammatory reaction (Nicolaidis and Wells, 1957, Strauss and Kligman, 1960). It may be that this accounts for the formation of an acneform eruption which implies an absence of direct correlation between androgenic stimulation and acne, and may explain why acne does not appear before puberty and yet why in acne patients testosterone levels are not necessarily higher than in normal patients.

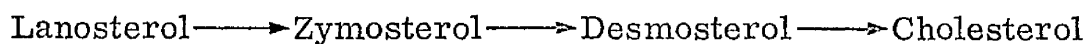
In/

2

In recognising the important part played by androgens in the activity of the sebaceous gland, only the first step is accomplished. It is now necessary to elucidate the manner of the processes involved. And here many hypothesis have been put forward. Already in 1948 Lederer and Mercier examined the constituents of skin surface fats in the sheep with the view of elucidating the nature of the substances synthesised in the sebaceous gland. In 1955 Nicolaides and Rothman thought that the sebaceous gland is the main site of squalene synthesis. Fentenstein et al., (1955) failed to show the presence of Provitamin D in the skin but other workers (Kandutsch and Russell, 1960) presented a strong case for the function of the sebaceous gland in the synthesis of Vitamin D. Gaylor and Sault (1964) suggested the formation of 7-dehydro-cholesterol in the skin. Skin is known to synthesise squalene and the main site of this synthesis is the sebaceous gland (Nicolaides and Rothman, 1955). A certain amount of this squalene is converted to sterol esters.

Squalene was first shown to be an intermediate in cholesterol synthesis by Nicolaides et al., (1955) in human scalp skin. Squalene is hydroxylated and cyclized to form lanosterol, the first sterol in the synthetic chain. Lanosterol synthesis is thought to be the same in all organisms and all tissues but further metabolism of lanosterol is thought to proceed along two alternative pathways. Both pathways lead to the synthesis of cholesterol, one involving saturated and the other unsaturated intermediates.

1. The Bloch pathway (Bloch 1959) is the most important pathway of synthesis in the mammal.



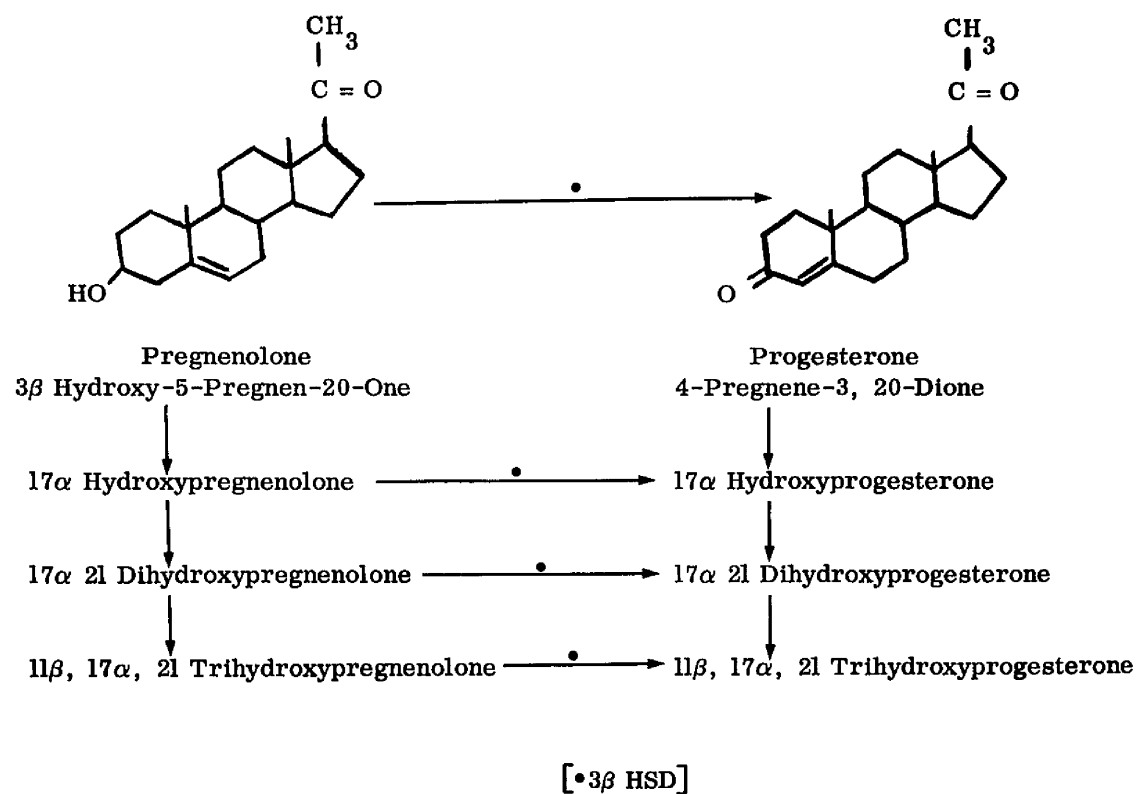
2./

2. The Kandutsch-Russell pathway (1960) involves a series of reactions leading to the formation of cholesterol. It is not a widely distributed pathway of cholesterol synthesis but is thought to occur in some tissues (Kandutsch and Russell, 1960). The pathway involves the compound Δ^7 -cholesterol which by a shift of the double bond to the 5 position gives rise to cholesterol. It is thought that 7-dehydro-cholesterol which is Provitamin D₃ is an intermediate in this reaction (Schroepfer and Frantz, 1961) and the pathway is therefore thought to be involved in Vitamin D synthesis. This hypothesis has recently been corroborated by the findings of Ranschkolb et al., 1969)

Although α and β hydroxysteroid dehydrogenases were demonstrated by Marcus and Talalay in micro-organism as far back as 1956 and inspite of the fact that Wattenberg developed in 1958 a histochemical method for demonstrating 3 β -hydroxysteroid dehydrogenase (3 β HSD) in tissue sections, it was not till 1966 that Baillie et al., first showed this enzyme to be present in the sebaceous glands of human skin. This breakthrough led to a vast field of investigations by this and other groups on the skin of man and smaller animals and both histological and biochemical methods came to be used in subsequent work on the subject.

The importance of 3 β HSD in steroid metabolism can be observed from looking at Figure 3. Many/

Figure 3 3β HSD in pregnenolone-progesterone metabolism



Many essential reactions in the metabolic pathways linking adrenal steroids with androgens and oestrogens, reactions involved in the synthesis, the interconversions and in the breakdown of steroid substances are reactions involving this enzyme, (Kahnt, 1961) both in target organs and at peripheral sites. Following the histochemical demonstration of 3β HSD in the skin by Baillie et al., (1966) Cameron et al., (1966) showed in experiments involving the incubation of skin in the presence of labelled DHA that labelled testosterone was formed and about the same time Horton and Tait (1966) put forward the hypothesis that the skin constitutes the possible site of androstenedione production and interconversion with testosterone.

Since then biochemical research has brought to light the presence of many more steroid substances in the skin, some of which are active metabolites such as testosterone, DHA, androstenedione and others which are comparatively inactive, by products such as androstandiol, etiocholanolone, epiandrosterone, androsterone which suggests that skin is active in both anabolic and katabolic pathways of steroid metabolism. Moreover there is now evidence (Gomez and Hsia, 1968) that testosterone can be metabolized in vitro by the skin to give rise to (see Figure 1) the active product 5α -androstan- 17β -ol-3-one to be the active androgenic product, rather than testosterone, at the target organ site. This conversion indicates the presence of 5α -reductase in the skin. Neonatal foreskin was found to be most metabolically active and ^{dihydrotestosterone} was found in a higher concentration than any other metabolite of testosterone.

Since/

Since DHA-SO₄ is quantitatively one of the predominantly circulating (protein-bound) steroid sulfates, whose role is unknown except during pregnancy, it may be thought to be involved in a regulatory mechanism of hormonal requirements to sensitive tissues. The site of such biological synthesis which would serve this important regulatory function is naturally of great interest. Berliner et al., (1968) have studied in tissue culture experiments, the formation of DHA sulfate and androstenediol sulfate in the skin and they have shown that skin participates actively in steroid biotransformations. They consider these biotransformations to occur in the fibroblasts. Kim and Hermann have described in vitro metabolism of DHA-SO₄ in some samples of skin and they consider this secretory product of adrenal glands and ovaries to constitute the precursor of biologically active androgens. It is definitely known that most of the circulating DHA is in the water soluble DHA-sulfate form bound strongly to proteins. The significance of this in relationship to androgen metabolism in general is however unknown. DHA-SO₄ seems to play an important role only during pregnancy. It is thought that sulfatase might play a part in the regulation of the androgen metabolisms in target tissues by changing the proportions of free and conjugated steroids. Warren et al., (1967) however, find no steroid sulfatase activity in the human skin.

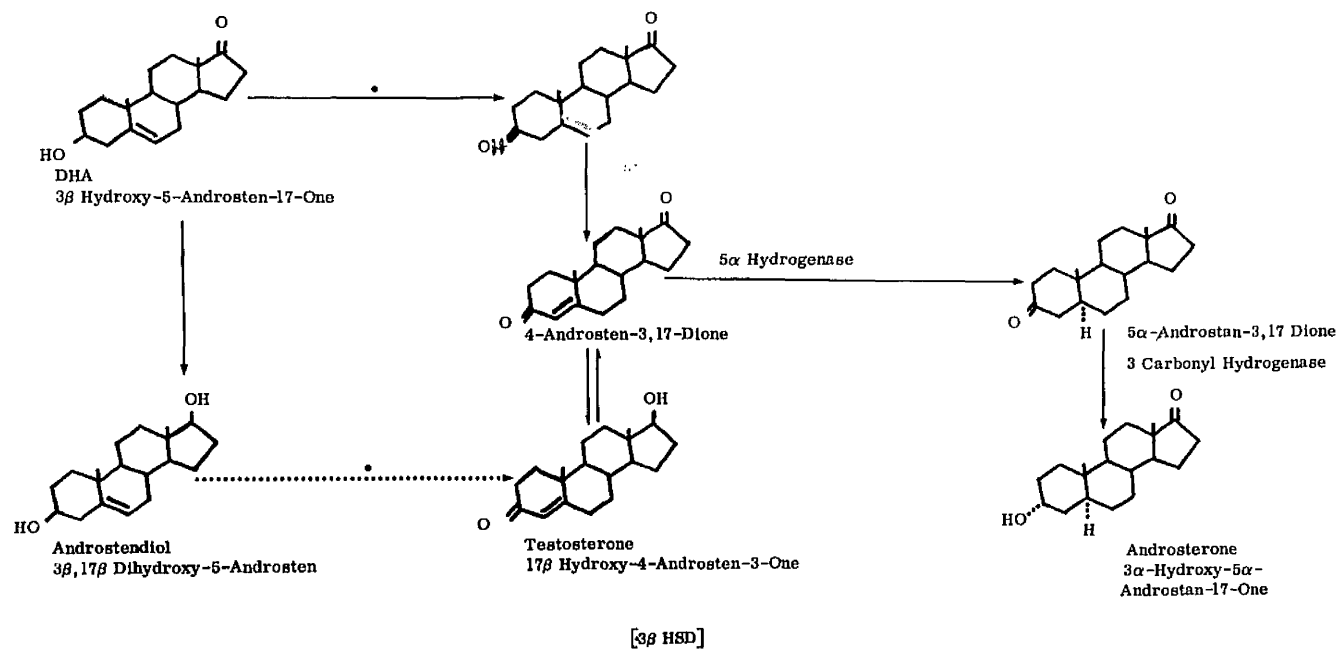
The importance of androgens in connections with the sebaceous glands has been established, the finding that 3 β HSD is present in the sebaceous gland and consequent investigations into the metabolic reactions which this enzyme controls has been shown. Interconversion/

Interconversion of hydroxyl and ketone groups were among the first described metabolic transformations of steroids in animal tissues and micro-organisms.

Chemically some HSD enzymes were isolated and purified from micro-organisms (Talalay, 1953, 1956) and kinetic studies were carried out to ascertain the substrate specificity, factors influencing reaction equilibria and the velocity of the reaction as a function of substrate structure and concentration (Talalay, 1957).

From 1958 when Wattenberg made histological localization of the reaction possible in tissue sections, as will be described later, distribution of various hydroxysteroid dehydrogenases in animal tissues was established. Wattenberg (1958) showed the presence in a tissue section of 3β HSD, Pearson and Grose (1959) 3α and 17β HSD Balogh (1964) 20α HSD, Baillie et al., (1965, 1966) 6β , 11β , 12α , 16α , 16β and 20β HSD. Certain of these enzymes have so far poorly defined biochemical roles and although their localization in a tissue can be demonstrated, their presence is sometimes difficult to interpret. Among the HSD enzymes listed above some, such as 3β HSD have a well recognised position in an established biochemical pathway (such as in DHA metabolism shown in Figure 4) and therefore the demonstration of its presence in a particular tissue leads to possible interpretation of its significance there. Reactions catalysed by dehydrogenases interconverting hydroxyl and ketone groups of steroid transformations were among the earliest to be studied in micro-organisms and in animal tissues (Liebermann and Teich, 1953). 3β HSD/

Figure 4 3β HSD in DHA metabolism

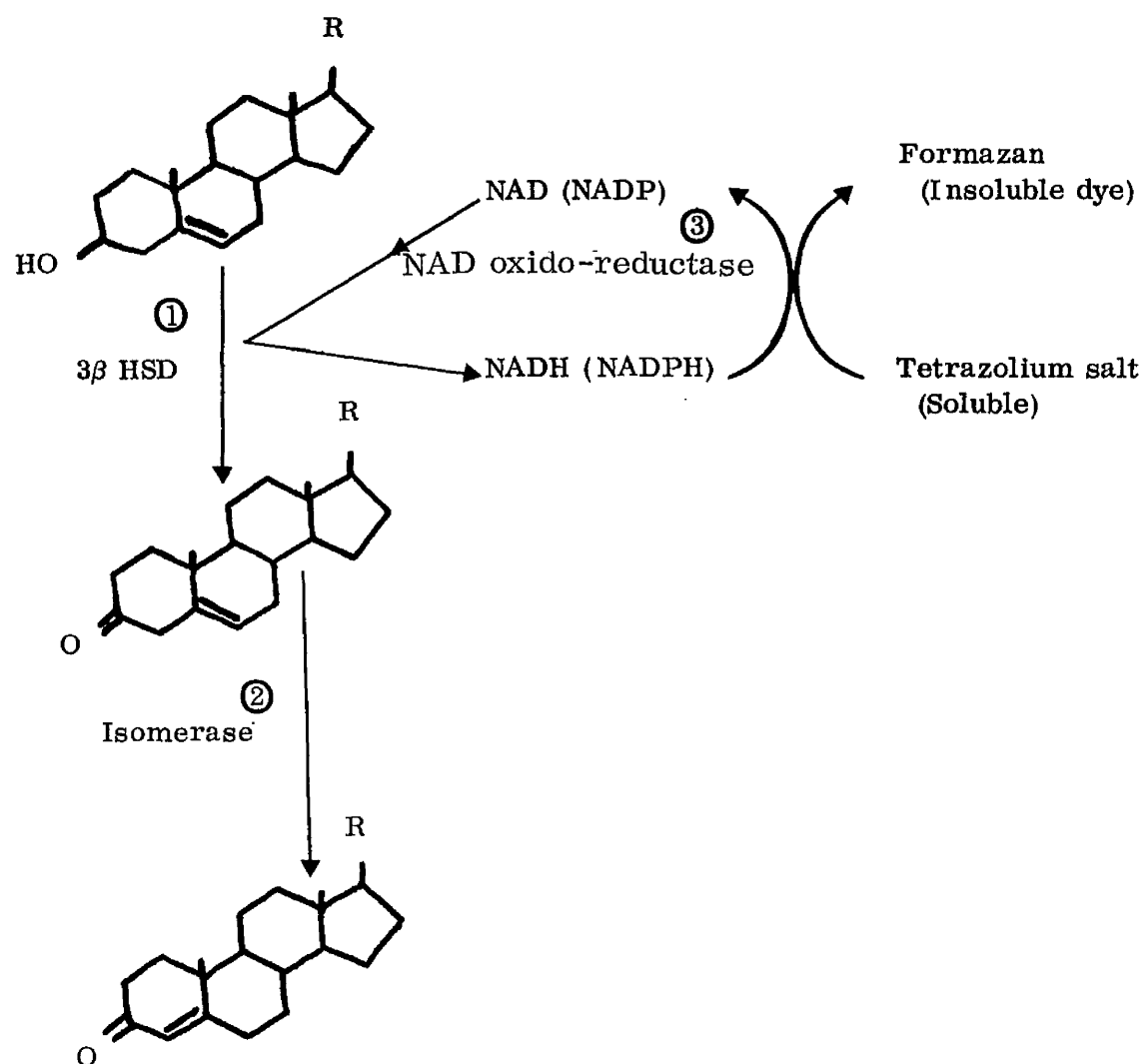


3 β HSD was first isolated and purified in micro-organisms (Talalay and Dobson, 1953).

This reaction involves two separate enzymatic steps: a primary oxidation of the hydroxyl group by a pyridine nucleotide linked hydroxysteroid dehydrogenase proper, followed by a rearrangement of the double bond, this isomerisation being catalysed by an enzymatic protein distinct from the oxidising enzyme (see Figure 5). The isomerase has been purified from micro-organisms. It is a very active enzyme, showing no specific co-enzyme or metal requirement. It has also been identified in mammalian tissue: adrenal, ovary, testis, liver and skin. The reaction catalysed by the isomerase is thought to consist of a direct transfer of hydrogen from C4 to C6 (Turfitt, 1946). It is a reversible reaction and this accounts for the stability of the Δ^4 -3-keto steroids which gives rise to the overall irreversibility of the two step oxidation. It is also the linking of the 3 β HSD with the isomerase which causes the specificity of this enzyme to its substrate, as compared to other dehydrogenases which are much less substrate-specific. (Marcus and Talalay, 1955).

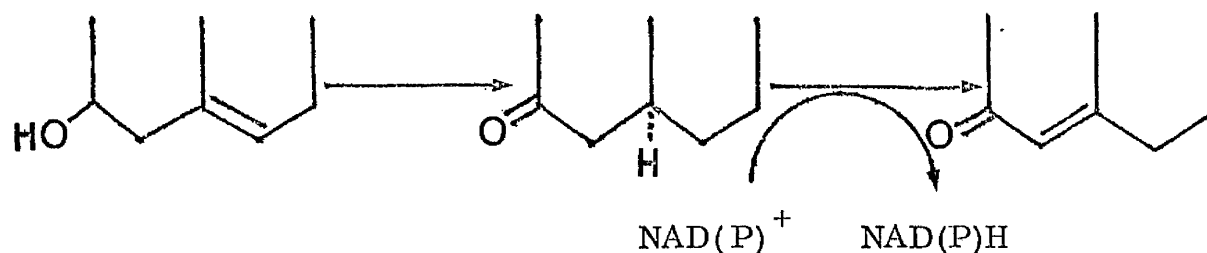
Kinetic studies carried out on α and β hydroxysteroid dehydrogenases to determine the substrate specificity factors influencing reaction equilibria and the velocity of oxidation as a function of substrate structure and concentration, have shown the Michaelis constants to be among the lowest for any enzyme in substrate interaction and the affinities for specific steroids to be very high. Thus/

Figure 5 Enzymes involved in the histochemical method described



Thus the strength of interaction between steroids and the corresponding dehydrogenases is very sensitive to small changes in steroid structure (Talalay, 1957).

It appeared in the early investigations of HSD reactions that NAD is involved. When NAD was added to HSD reactions the rate of reaction was markedly increased. The addition of nicotinamide as an inhibitor of the nucleotidase produced the same effect. It was therefore ascertained that NAD is involved in the reaction and it is now known that it is an essential co-enzyme which is involved in the oxidation as H acceptor (Samuels *et al.*, 1951).



The H atoms are transferred from the oxidation reaction by the respiratory co-enzyme NAD, in a stepwise process by a series of oxidative reductions with oxygen acting as the terminal acceptor in vivo. Many of the enzymes such as HSD which are involved in biological oxidations are mitochondrial. Steroid dehydrogenases are linked with NAD in the oxidative pathways, though some require the phosphorylated nucleotide NADP. 3 β HSD is thought to be NAD-dependant in most cases.

The/

The studies elucidating the nature and kinetics of the enzyme are of a biochemical nature. Other considerations involved in the elucidation of the metabolic and biological significance of an enzyme can be approached by other means of observations and among them histochemical techniques. The recognition of the presence and significance of 3β HSD in the skin is a good example of the way in which several paths of investigations lead to a working hypothesis.

Various approaches to histochemical investigations are possible. There are the classical methods of histological techniques based on colour reactions, and staining methods. These microscopic techniques employing chemical methods depend on the direct observation of an insoluble product of a micro-chemical reaction between the substance whose distribution is being investigated and a suitable reagent. The reagent used must be specific and the reaction between it and the substance being investigated must result in a stable product which can be visualised (Glick, 1949).

These techniques also require the preparation of sections which can be studied under the microscope and which must be thin and allow as little alteration of the constituent investigated as is possible. The important considerations which arise in these methods are therefore the preparation of suitable experimental material, the choice of fixative and of reagent used.

Holt and O'Sullivan described in 1958 the principles of cytochemical staining methods and at the same time an analysis of frozen section techniques was presented by Thornbury (1957) in the context of enzymic histology.

The/

33

The development of histochemical procedure is reflected in the change from fixed sections to fresh frozen sections which has made possible from the earlier detection of a substance present in a tissue, to the more sophisticated studies demonstrating the presence of an enzyme. The development of the cryostat from a microtome by Linderstrom-Lang in the late thirties led to the considerations of temperature effect of tissue preparations by Scott in the early forties (Scott, 1943). The technique of sudden cooling to low temperatures by using solid carbon dioxide or liquid nitrogen, overcame the formation of crystalline ice which might occur causing damage to cellular structure. In the development of the best method for preparing sections to be used in enzymic studies by histochemical techniques, the important criteria were necessarily the maximum preservation of intact cell structures and the minimum chemical change in the tissue. With the development of modern cryostat equipment, these aims are satisfactorily achieved.

Whereas classical methods of histochemistry based on staining procedures allowed the localization of various substrates in the cell (such as fats by differential staining with the Sudan dye) the modern techniques of tissue section preparations led on to enzymatic work and so allowed biochemical studies to be undertaken by histochemical methods. These methods include histochemical investigations in tissue sections on microscope slides (Glick, 1949) or enzymatic determinations on tissue sections followed by elution in view of determining or measuring one of the participant products on the reaction. It can also be extended to the use of modern isotopic techniques and to autoradiography.

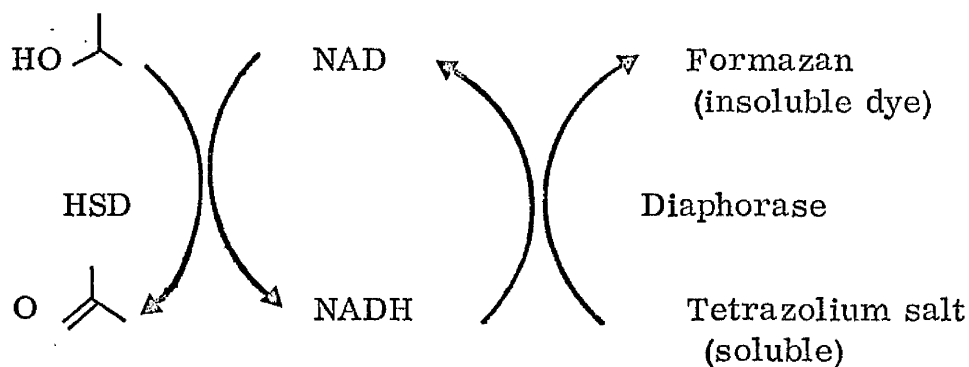
The/

The tremendous progress achieved in histochemical methods over the recent years has made possible the vast developments as applied to cell biology. To mention but a few of the techniques developed within the last two decades, one may consider spectrophotometry, electron microscopy, fluorescence microscopy, manometric methods in measurement of cell respiration (Chayen and Denby, 1968). Lowry (1954, 1957) described general analytical procedures and tools for quantitative histochemical studies on the enzyme measurements of the brain. The methods he developed are fluorimetric measurements of pyridine nucleotides and these will be considered more fully under the special introductory subsection.

Burstone (1960) used fluorimetric techniques for the demonstration of enzymes and this histochemical method has also been applied to the study of sebaceous glands.

Within recent years there has been an increased application of the techniques of biochemistry and biophysics to histochemical allocation of enzymes and reactive groups within the intracellular framework. In the attempts to localize enzymically active sites in tissue sections, the coupling of the enzymic reaction to a visible indicator system has been adopted. Since Wattenberg in 1958 used a hydrogen acceptor to follow the course of hydroxysteroid dehydrogenations, a great deal of histochemical work has been done in this field. Histochemical techniques which allow the localization of the site to enzymic reaction in a tissue section depend on the formation of a visible i.e. coloured, insoluble product in the course of the enzymic incubation of a tissue section. If/

If the section is incubated under suitable conditions (of pH, temperature) in the presence of the substrate specific to the enzyme under investigation, with the addition of the necessary co-factors, (Nicotinamide Adenine Dinucleotide) the enzymic reaction can be so coupled to an indicator-system that the presence of the particular enzyme in the section entails the deposition of the indicator dye at the site of the reaction. In this way Wattenberg (1958) coupled the oxidation of the 3β hydroxy group on the steroid molecule to the reduction of a tetrazolium salt, thus making the localization of the reaction possible in tissue sections.



The value of tetrazolium salts as agents for demonstrating dehydrogenase activity has been fully established (Black, 1953) and its implications will be fully described under the special introduction subsection. Among this group of tetrazoles, nitro blue tetrazolium (Nitro BT) was found to be an ideal reagent for histochemical purposes (Nachlas, 1957).

The/

The requirements for a suitable histochemical indicator include the rapid formation of good pigment quality with low solubility in aqueous solutions and these requirements are met by Nitro BT.

The reduced form of Nitro BT has marked substantivity for protein (Dawson et al., 1969). It is deposited in distinct dark blue granules, easily identified on microscopic examination. Nitro BT is widely used for the cytochemical localization of dehydrogenase systems (Nachlas et al., 1958). In principal its function in the histochemical reaction is demonstrated in Figure 5. Most dehydrogenase systems are NAD-dependant and the reoxidation of the NADH resulting from the dehydrogenase reaction in the presence of the NADH diaphorase, is coupled to the reduction of Nitro BT.

The measurement of the 3β HSD activity of a tissue section could theoretically be approached from two angles -

1. Direct measurement of enzymic reaction by determining the amount of substrate used, product formed, or co-enzyme reduced e.g. fluorimetric measurements of pyridine nucleotides (Lowry, 1954).
2. Coupling of the enzymic reaction through a diaphorase system and determining the amount of formazan produced. This could be done by elution techniques followed by spectrophotometric studies. It could alternatively be attempted by counting procedures of the granular deposit of formazan in the sections by such methods as micro densitometry (Stuart and Bitensky, 1969).

Both these methods will be considered more fully under the appropriate sub-sections.

It/

It is therefore possible to divide the methods of approach to enzymic studies on the sebaceous glands and the chemical processes which occur in sebum formation, into two main categories -

(a) Study of surface lipid and sebum such as the gravimetric measurements of Strauss et al., (1961) or the quantitative determinations of surface lipid constituents (Rothman 1964) as well as enzymatic determinations of surface lipids (Cook and Lorincz, 1963).

(b) Study of sebum within the pilosebaceous structure and within the cells of the sebaceous gland. This approach would utilise histochemical techniques to localize and identify different substances and enzymes.

Both these methods could also be considered from the biochemical angle and with the use of active isotopes and modern chromatographic techniques, the identification of compounds within the gland and on the surface of the skin could be achieved.

In reality all these methods of approach are necessary to elucidate the problem of steroid transformations in the skin, and it must be remembered that in developing a histochemical method for the detection of 3β HSD in the sebaceous glands of the skin one is not solving, but at least approaching the more important consideration of steroid metabolism in one of the target tissues.

Such studies in man are limited, on ethical grounds, to very general inquiries. The search for an experimental animal is important as it would allow more advanced experimental trials on topical and systemic effects of steroids on the metabolic pattern in a target organ. In/

In accordance with the need for such an experimental subject, investigations into this possibility are detailed in the appropriate section.

In all cases histochemical investigations can at most indicate an approach to more fundamental studies of biochemical nature, involving isotopic tracers to elucidate the exact nature of the products of the enzymic reactions sited in a given tissue. Histochemical investigations do however allow rapid screening and provide a ready method for siting and estimating an enzymatic reaction. They also allow surveying on a large scale, the distribution of such a reaction in different tissues or different individuals, as well as forming a preliminary inquiry into abnormal situations such as occur under certain metabolic disorders. They provide also a suitable screening method for studying in vitro substrates which are suspected of participating in or on the contrary inhibiting the enzymic reaction, as for example in the investigations of DHA-SO₄ described at the end of these experimental studies, or antiandrogens mentioned at the beginning. Such investigations as the screening of antiandrogens by histochemical methods, are of course strictly limited to the possibilities of in vitro experiments as the only certain criterion of anti-androgenicity, is a bioassay.

PURPOSE OF RESEARCH

The aim of the work described in this thesis was at the outset:

1. To improve and quantitate the histochemical technique used in determining HSD activity in the sebaceous glands of skin, and to reduce the quantities of substances used in the incubating medium in such a way as to allow for a micro-histochemical technique which it was hoped would lead to greater precision, to loss of waste and to reduction of amounts of expensive steroid substrates often used.
2. To find a method of estimating the results of the histochemical reaction and thus to allow quantitative comparisons of HSD activity in different skin samples.
3. To collect enough data on HSD activity in the sebaceous glands of skin taken from various sites in individuals of both sexes and all age groups, to enable a survey of HSD distribution to be established.
4. To find a suitable experimental animal showing HSD activity in the sebaceous glands of skin or special organs which would allow further histochemical and biochemical studies involving the use of steroids and isotopes that are impossible to carry out in human subjects for ethical and medical reasons.

INTRODUCTION TO THE EXPERIMENTAL WORK

Histochemical Methods


Histochemical methods were first used to establish the presence of 3 β HSD in mammalian tissues by Sammuels et al., (1951) and Wattenberg (1958). This same method which consists of coupling the oxidation reaction to the reduction of a tetrazolium salt resulting in the formation of a coloured insoluble formazan which can be localised in a histological section, was applied by Baillie et al., (1965) to sections of human skin in which the presence of 3 β HSD was shown to be localized in the sebaceous glands.

In the course of the work described in this thesis the purpose was to establish the optimum conditions and minimum quantities in the standardisation of the histochemical technique, as well as to introduce some method of quantitation of the enzyme activity reaction.

Preincubation Techniques

Unfixed frozen sections were used for enzyme histochemistry because they were highly active and readily prepared. The cryostat shown in Figure 6 consists of a microtome enclosed in a refrigerated chamber. The cryostat was devised by Linderstrom-Lang, K., and Morgensen, K.R., (1938). An/

Figure 6 The cryostat, showing knife, slide and a
sample of skin mounted on chuck



An analysis of frozen section techniques was made by Thornburg, W., and Mengers, P.E., (1957) who ascertained optimum conditions for cutting thin sections from unfixed frozen tissues.

In past work on steroid dehydrogenase localisation it was noted by Fuhrmann (1961) that hydroxysteroid dehydrogenases are sensitive to many of the widely used laboratory fixatives such as mercuric chloride and osmium tetroxide. Therefore Baillie et al., (1965, 1966) used unfixed frozen tissues and various methods of achieving rapid freezing were investigated. The one which was adopted was freezing of small skin blocks in solid carbon dioxide (dry ice). This method overcomes the risk of ice crystal artefact.

In general, unfixed frozen sections maintained on slides are favoured for the demonstration of enzymes of the dehydrogenase system. The freezing and thawing encountered in the preparation of frozen sections may however disrupt the morphological integrity of the specimens particularly when studied at the cytological level, but this problem is overcome by using thin tissue sections and exposing them to rapid freezing procedure at low temperatures in liquid nitrogen or on solid carbon dioxide (solid CO₂) known as 'dry ice'.

Incubation Techniques

The histochemical reaction depends on the hydrogen ion exchange illustrated in Figure 5. NAD acts as the intermediate hydrogen carrier and it is an essential co-factor (Beyer and Samuels, 1956). In the presence of the steroid base, if the corresponding steroid dehydrogenase is present in the tissue section, the/

the hydrogen is transferred from the hydroxy group on the steroid molecule to the NAD molecule causing the reduction of the latter to reduced nicotinamide adenine dinucleotide (NADH). In some cases NADP is thought to be the intermediate hydrogen carrier in the oxidation-reduction chain which is set up rather than NAD. Some HSD enzymes are NAD dependant, e.g. 3β HSD and 20β HSD. Other HSD enzymes are NADP dependant such as 20α HSD. There are also some hydroxysteroid dehydrogenases which use either NAD or NADP, for example 3α or 17β HSD (Hurlock and Talalay, 1959, Jarabak *et al.*, 1962, Balogh, 1964).

Biological oxidation reduction reactions constitute the mechanism by which hydrogen atoms or electrons are transferred from one molecule to another in a living cell. Reactions of this type which are catalysed by enzymes are related to synthetic and degradative processes. Most enzymatically catalysed oxidation reactions are dehydrogenations or transfers of electrons from the substrate to the electron acceptor. The hydrogen atoms or electrons are transferred by means of intermediate compounds such as flavine adenine dinucleotide (FAD) and NAD (and NADP) (Mehler, 1957).

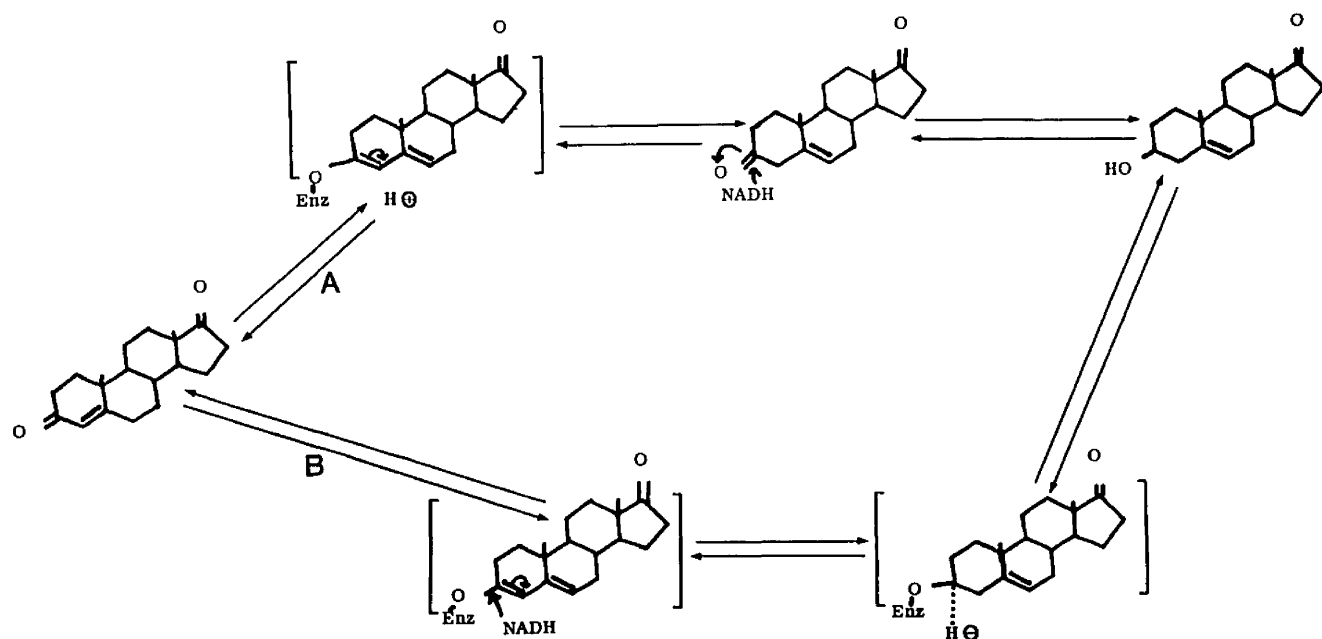
Steroid dehydrogenases are NAD-linked dehydrogenases. The enzyme catalyses the direct transfer from substrate to the first hydrogen acceptor which is NAD.

The mechanism of action of this enzyme was first studied by Talalay, P., and Wang, V.S., (1955).

Two pathways were proposed (one by Slaunwhite and Samuels, 1956 and the other by Neher and Wettstein, 1960) and are illustrated in Figure 7.

Two/

Figure 7 The two pathways proposed for the conversion
of Δ^4 -3 keto-steroids to Δ^5 -3 β alcohols



Two enzymes are involved: a dehydrogenase (3β -dehydrogenase) and an isomerase, catalysing the isomerisation of $\Delta^{5(6)}$ keto steroid to the corresponding α , β - unsaturated ketone. Wattenberg, L.W., (1958) described a histochemical technique for the demonstration of steroid 3β -ol dehydrogenase which employs NAD in conjunction with either nitro-tetrazolium or nitro blue tetrazolium (Nitro BT). Subsequently the technique was modified by Allen, (1960) who used a substrate solution containing the following:-

0.01 M DHA
 10 mg. NAD
 0.1 M Phosphate buffer pH 7.5, 8.0 ml.
 0.3 M KCN pH 7.5, 5.0 ml.
 3.5 mg. Nitro BT

and water to make a total volume of 30 ml.

Blue tetrazolium and neotetrazolium were used by various workers (Nachlas, 1957, 1958, Baillie, 1965, 1966) in the histochemical demonstration of steroid dehydrogenases but nitro BT was finally adopted by this group (Baillie *et al.*, 1966) as being most suitable.

The fact that tetrazolium salts have a low redox potential (-0.08 volts) makes them sensitive indicators of reducing enzyme systems in tissues. Essentially the histochemical application of tetrazolium salts depends on the fact that in the unreduced form, the dye is soluble and when reduced it is insoluble and coloured (Figure 5). The reduced dye is deposited at the site of the enzymic reaction and makes localisation of the enzyme possible.

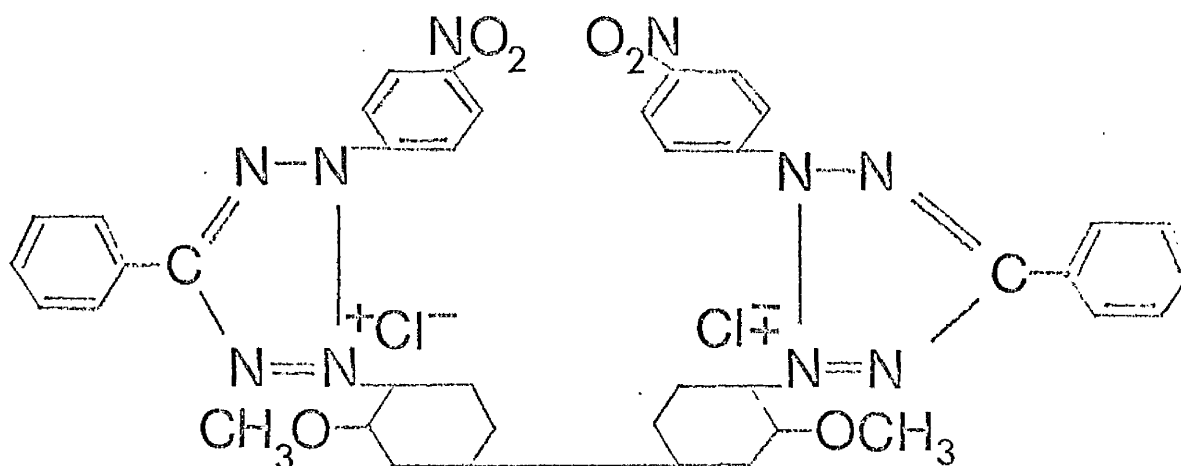
An/

An ideal tetrazole histochemical substrate should possess the following characteristics:-

1. Ready reduction to the formazan and resistance to oxidation by molecular oxygen back to the tetrazole.
2. Strong attraction for hydrogen or electrons liberated from the substrate so that atmospheric oxygen does not act as a significant competitor.
3. Production of a formazan of good pigment quality and low solubility.

Nitro BT possesses the above qualities to a great extent and is thus of great value in enzyme histochemistry.

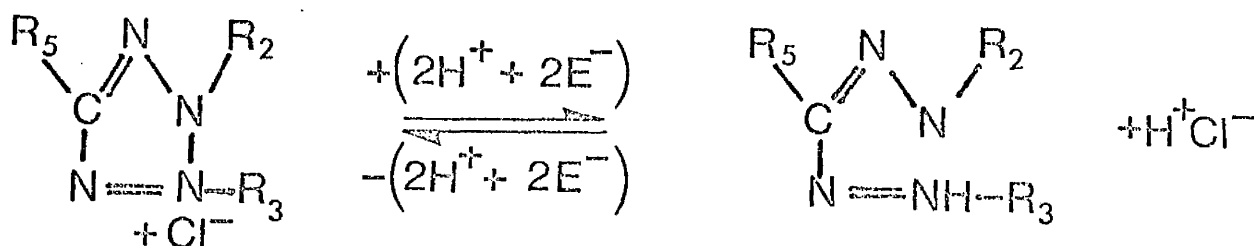
Nachlas (1958) noted the superiority of nitro BT over other tetrazolium salts, previously used, in that it allowed the cytochemical visualisation of sites on enzymatic activity in the tissue sections after a relatively short incubation period. Nitro BT: 2, 2' di-p-nitro phenyl-5, 5'-diphenyl-3, 3' -ditetrazolium chloride.



This/

This ditetrazole was synthesised in 1956 by Tsou (Tsou et al., 1956).

The transformation of the tetrazole to its corresponding formazan occurs through a ring opening.



This application of tetrazolium salts as biochemical reagents and more detailed consideration of the various aspects of the enzymatic reduction of tetrazolium salts, were studied by Black et al., (1953). Kivy-Rosenberg et al., (1955) reported on the application of tetrazolium salts as indicators of changes in tissue metabolism during functional activity.

The reactions occurring during a histochemical incubation in which an enzymatically active tissue section is exposed to the incubating medium containing steroid substrate, NAD co-enzyme and nitro BT can be subdivided into two parts (See Figure 5):-

1./

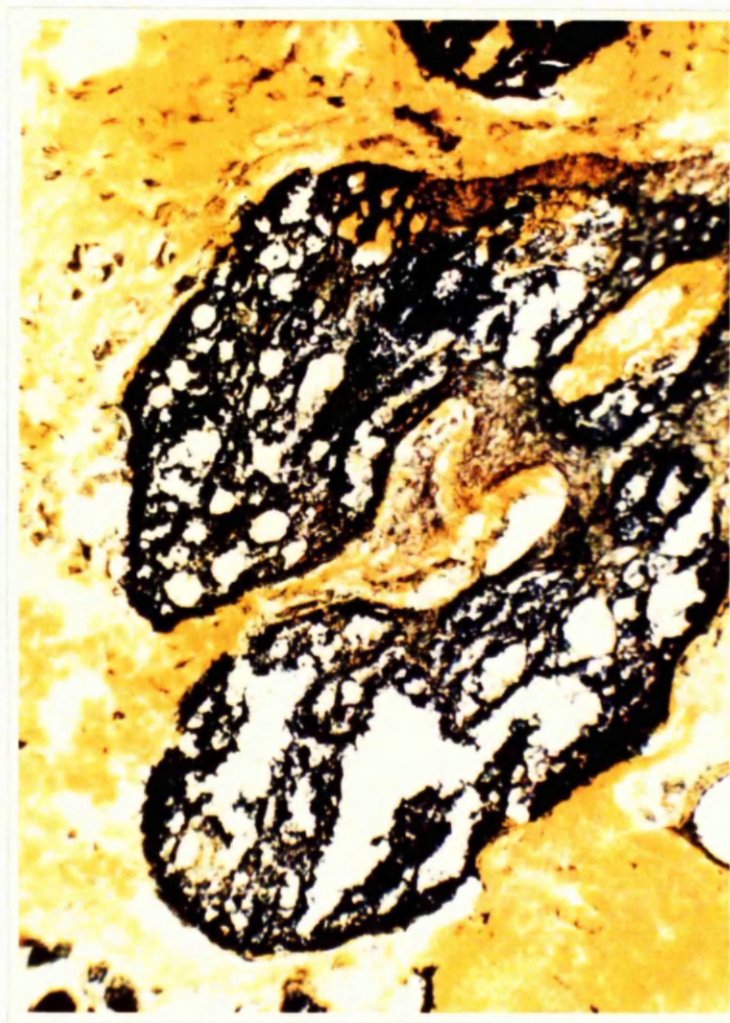
1. Hydrogen transfer from the hydroxyl group of the steroid to NAD mediated by 3 β HSD and resulting in the production of a keto group on the steroid molecule and the formation of NADH.

2. A further H transfer from the NADH to nitro BT resulting in the a) reoxidation of NADH to NAD and b) the deposition of blue diformazan granules.

This reaction, the reduction of the tetrazolium salt to its insoluble coloured product, with the oxidation of NADH back to NAD is catalysed by a diaphorase (See Figure 5). The diaphorase is a widely distributed enzyme in all tissues.

Allen (1959, 1960) studied the histochemical localisation of NAD diaphorase and also 3 β HSD activity in the adrenal cortex of the mouse. The demonstration of the presence of the diaphorase in skin sections in the presence of NADH and Nitro BT is used as a general control in the histochemical work. Its presence is an indication that the latter part of the histochemical demonstration illustrated in Figure 5 is possible. NAD diaphorase is found in the sebaceous gland as well as in the surrounding connective tissue in the skin. Its distribution in a skin section is illustrated in Figure 8 which shows the result of an incubation of a section in the presence of NADH and nitro BT, by the histochemical method described in the experimental section. This/

Figure 8 Skin section showing diaphorase activity after
incubation with NADH



(x 240)

50.

This widely distributed enzyme allows the histochemical demonstration of other NAD linked enzymes in tissues as well as the steroid dehydrogenases in the sebaceous glands of skin. The use of the NADH control is therefore a check on the NADH-Nitro BT hydrogen transfer reaction (Nachlas, 1958). If a test incubation in the presence of a steroid substrate, NAD co-enzyme and nitro BT as electron acceptor, gives a negative result i.e. no reduction of nitro BT, has occurred and yet the diaphorase control with nitro BT and NADH is positive, one can be sure that the negative result in the test incubation is not due to the absence of the diaphorase but to the absence of the HSD in the tissue section (see Figure 5).

The important point is that there is little possibility that the activity of NAD-diaphorase is a limiting factor in the study of 3β HSD in the skin.

Quantitation

The problems encountered in attempting to quantitate the histochemical method of estimating hydroxysteroid dehydrogenase are mainly:-

1. Different size of diformazan granules deposited in the sebaceous glands.
2. Different focal levels at which the granules are deposited.
3. The uneven distribution of the granules in the sebaceous glands.

The/

The different size of granules is probably due to their superimposition at one spot, or to intracellular conditions affecting crystal growth.

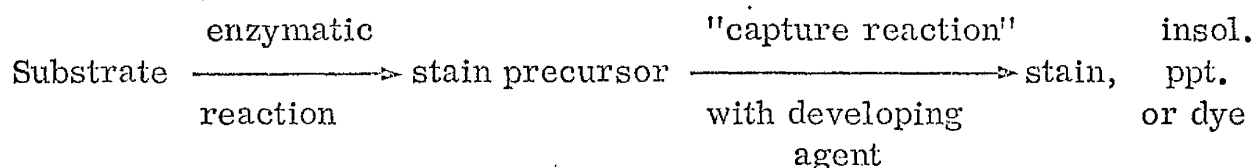
Three types of dye stuffs are known to result from histochemical reactions:-

1. Dyes amorphous in appearance such as nitro BT.
2. Dyes which are initially amorphous but subsequently crystallise.
3. Dyes which are crystalline in pattern such as the simple formazan dyes.

The formation of a precipitate occurs by the inception of submicroscopic particles of the reaction product and the growth of grains by aggregation of these particles.

The dyes are held within the tissue section by chemical combination with tissue proteins by physical forces, such as hydrogen - bondings or by mechanical means whereby the insoluble pigment particles are held in the section.

According to Holt and O'Sullivan, an enzyme histochemical staining reaction may be indicated as follows -



The/

The skin sections are as thin as it is possible to cut them without breaking them up (about 8μ) and granule deposition occurs mainly on the surface of the section in contact with the incubating medium, but some granules are deposited deeper within the section, this becoming apparent when one focuses on the sebaceous gland with the high power of the microscope. It makes granule counting difficult and constitutes serious disadvantage in quantitating methods.

In 1967 when this section of the work was being carried out in our laboratory in an effort to establish a method of quantitating the histochemical reaction evolved for HSD estimations, the microdensitometer apparatus available was inadequate for the reasons stated previously. Since then however, a scanning and integrating microscope has been built specially with such an aim in view by the group comprising of Dr. Chayen et al., (1969) who have used it to determine the amount of the insoluble colour reaction produced by lysosomal and by mitochondrial enzymes. The level of detection which they have achieved by the method of microdensitometry for the detection of the insoluble colour reaction produced by lysosomal and by mitochondrial enzymes, is of the order of 10×10^{-12} g. or less. This new equipment overcomes the shortcomings which led us to abandon this method two years earlier on the older type of equipment, and mainly the problem of inhomogeneous dispersion. With this improved scanning and integrating microscope, it would be possible to envisage quick and accurate estimations of granule deposition in the sebaceous glands of skin and comparisons of such estimations between different skin samples. The/

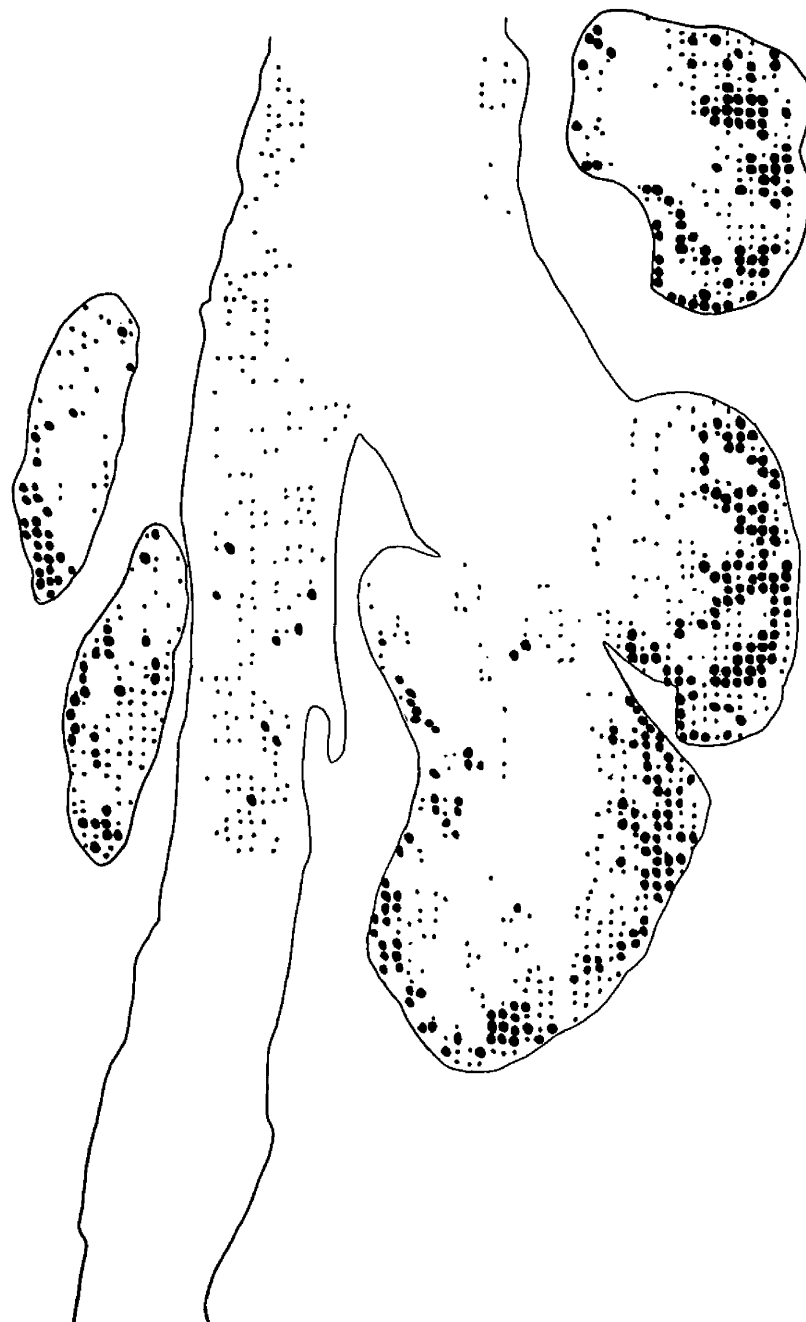
The method appears reliable and its great advantage is independence from the individual observer's estimation.

Chayen's group show good correlation between relative absorption and section thickness data which when plotted give them a linear increase of relative absorption with section thickness while relative absorption plotted against time of incubation levels off towards a maximum value of absorption.

Granule deposition in the sebaceous gland is uneven as shown in Figure 9. Sebaceous glands show greater activity around the periphery than in the centre and hence depending on the level at which the gland is sectioned, the relative density of the granules differs. In the glandular acini, the cells show a centripetal enlargement, those in the centre being large and often misshapen and moribund, while the cells on the outer periphery are undifferentiated and resemble those of the epidermis in appearance. These cells are the most active in the sebaceous gland. Sebaceous differentiation denotes the accumulation of lipid droplets in cells. At the completion of differentiation, the cells at the centre of the sebaceous gland become fragmented and form the sebum. As it is the cells on the periphery of the sebaceous gland which are most active, the histochemical method for demonstrating enzymatic activity results in greatest granule deposition in the area of these cells. To compare the activity of two different skin samples, one would either require to take sections at exactly the same level of the sebaceous gland in both skin samples, which is impractical, or one would need to make counts in a large number of sections of sebaceous glands in the areas considered and to subject these to statistical tests.

The/

Figure 9 Diagrammatic representation of 3β HSD distribution in
the sebaceous gland
(traced with the aid of Wild M20 microscope)



01.

The method (Wild M20 microscope) used in semiquantitating the histochemical reaction is therefore limited to comparisons between counts of consecutive sections in studies of the effect of co-factors (such as Mg) or inhibitors (such as antiandrogens, cyproterone and cyproterone acetate) on the enzymic reaction.

In this limited capacity the method is useful, rapid and simple. It provides a functional system for screening large amounts of material as well as constituting an excellent preliminary investigation into more detailed biochemical and physical estimations and measurements of the final products of the enzyme reactions involved.

Fluorimetric Studies

In the 3β HSD dependant enzymic reaction in which NAD is an essential co-factor, the amount of NADH produced (Figure 5) is proportional to the amount of enzymic change. In measuring the amount of NADH formed one may therefore determine the enzymic activity of the tissue sample (Lowry, 1954). These experiments consist in measuring the amount of NADH produced during a two hour incubation of skin sections in the presence of a steroid base and NAD. Of course other enzymes besides steroid dehydrogenases will be expected to be present in the tissue, many of which are NAD dependant also and would therefore also lead to the formation of NADH. It can be expected that a certain amount of NADH will be produced from NAD normally present in the tissue and competitively used by other NAD dependant enzymes. These/

02.

These factors however can be accounted for by the use of double controls (a) no steroid (b) no NAD in the incubation medium, besides the basic control of normal incubation containing no skin sections.

This method of estimation of enzyme activity in tissue sections is by no means foolproof. It is in effect an indirect estimation, measuring only one of the products of the reaction and moreover a product which is not confined to this reaction alone. NAD and NADH interchanges occur widely in metabolic processes and not only other enzymes but also back-reactions in the steroid processes can account for either production or disappearance of the NADH formed. The method can only be said to be roughly indicative of the amount of steroid dehydrogenase activity per certain weight of skin, if one discounts the value of the controls. And even then it would require a much greater involvement into tissue fractionation and enzyme purification to establish this method as a quantitative tool in HSD studies than can possibly be undertaken in the limited conditions of equipment, materials and time in this project.

It is thought that more elaborate studies in this field within the future would give good quantitative results and so justify the digression from the otherwise histochemical nature of these studies. A separate project involving tissue fractionation, enzyme separation and purification by dialysis and other methods, possibly preceded by dissection of sebaceous glands leading to such work would appear to be worthwhile.

Survey/

Survey of Distribution

A survey of the distribution of steroid dehydrogenases in sebaceous glands of human skin was carried out with respect to 3β , 16β and 17β HSD, the findings of this survey being reported in the enclosed publication (Ref: Calman, Muir, Milne and Young, In press (1970)). In particular the distribution of 3β HSD activity was considered in the context of this thesis.

Prewashing Technique

In the course of the survey of 3β HSD in the skin, some skin samples gave rise to positive controls. It was thought that this may arise due to the presence of endogenous steroids in high enough concentrations to give rise to an enzymatic reaction in the sebaceous gland cells of the sections. In skin samples in which this occurred, the incubation was repeated (both test and control) on fresh sections which were briefly rinsed in phosphate buffer prior to being covered with the incubation medium. This method was found to be successful in giving rise to clear negative controls while the test sections (incubated in the presence of steroid base in the incubating medium) still gave positive results.

Introduction/

Introduction to Animal Experiments

In studies linking the effects of androgenic substances with sebaceous gland activity, the availability of a suitable experimental animal would be of great advantage. It is for this reason that interest has been growing recently in the skin of rat (Ebling, 1957) hamster (Takayasu, 1969) and gerbil (Thiessen, 1968) and other small laboratory animals. The investigations which are described involving a series of small animals (mouse, rat, guinea pig, gerbil and hamster) were undertaken with the purpose of finding suitable material for histochemical studies on the effect of androgenic and anti-androgenic substances in sebaceous glands. Besides the normal skin of these animals, special sebaceous structures were considered whenever possible. These included the preputial gland of the rat, the territorial marking of the gerbil and the costovertebral organ of the Syrian hamster. Basic histochemical techniques previously described for human skin were applied. Where these failed to give good results, experiments were designed to modify the basic technique in varying the conditions of incubation in an effort to demonstrate the presence of HSD in the simple sebaceous glands associated with body hairs of the animal skins as well as in special sebaceous structures such as the territorial marking in the gerbil, the preputial gland in the rat and the costovertebral organ in the hamster.

Special Animal Studies

Gerbil/

Gerbil

The Mongolian Gerbil (Meriones unguiculatus) is a small rodent weighing about 70 - 90 g. and showing a midventral, orange, fusiform pad constituting the territorial marking (Figure 10). This pad consists of skin very rich in sebaceous gland. In a shaved animal it is clearly distinguishable from the surrounding area (see Figure 10) in the different colour and texture of hair from that covering the rest of the animal's body. The sebaceous gland pad is about 0.2 cm. thick and 3 cm. long in an adult male, and about half that size in the female.

Thiessen (1968) et al., have investigated the effects of testosterone on the sebaceous gland pad of the gerbil while Glenn and Gray (1965) had studied the development of the sebaceous gland pad after stimulation with several steroid hormones. Mitchell (1965) described the effects of castration on the territorial gland pad of the gerbil. All these investigations are however mainly concerned with morphological effects and the biological significance of the sebaceous gland pad in the gerbil.

In this project I set out to combine the physiological and morphological observations with histochemical studies into the nature of the sebaceous gland pad and the effect on it of androgens. The morphological changes brought about by treatment of adult male gerbils with biologically active androgens is considered in their effect on the size and appearance on the sebaceous gland patch. Also the appearance and size of the individual sebaceous glands in relation to their position in the dermis is considered as well as the histochemical activity and the presence of various steroid dehydrogenases.

The/

Figure 10

The Mongolian gerbil (Meriones unguiculatus) with shaved abdomen showing centrally situated glandular pad



The gerbil is a small animal and very suitable as an experimental subject. In the eventuality of the sebaceous gland pad showing skin rich in sebaceous glands and if in histochemical work this skin proves suitable, one can envisage a series of interesting experiments with the view of elucidating the interaction between steroid metabolism and sebaceous gland activity.

If, as is supposed, there is a direct correlation between the development of acne and the presence of greater amounts of active androgens at the onset of puberty, (in the human) then it would be of interest to observe the effect on the sebaceous glands of an excess of active androgens. In the event of a state resembling acne being induced it would be of interest to apply possible countermeasures. These studies would also allow the comparison of the effect of testosterone and oestradiol on the sebaceous gland activity.

It is thought that the development of the glandular pad in the gerbil is related to the sexual maturity of the animal. This is borne out by the fact that the sebaceous gland pad attains its greatest size in the adult male. In studies on the gerbils actual size or weight increase in the gland pad is considered as measurement of functional activity. It is reported (Myles, Glenn and Grey, 1965) that response to testosterone is dose related, and not altered by simultaneous administration of other steroid hormones. Hydrocortisone and ACTH administration shows no effect while testosterone, oestradiol and progesterone stimulate the development of the sebaceous gland pad.

In/

88.

In the experiments carried out on the gerbils, it was therefore envisaged initially to study the physiological and histochemical effects of the administration of two steroid hormones: testosterone and oestradiol, independently and simultaneously.

The effect of androgenic steroids on the Syrian hamster sebaceous glands

The costovertebral glands of the Syrian hamster provide suitable material for investigations of the metabolism of a model sebaceous gland. Both males and females of the species possess a pair of symmetrical dorsally situated glands darker in colour and easily differentiated from the surrounding skin. The animals are shaved to provide better exposure in the area of these glands and in topical application of a substance, one of the glands can be used as test while the other is kept untreated as control. Hamilton and Montagna (1950) and Takayasu and Adachi (1969) have studied hormonal control of the metabolism of hamster sebaceous gland but, as in gerbil studies by other investigators, these reports concern mainly the size and sebum secretion of the glands. In the work undertaken in this project, I was concerned more with the effect of various androgenic steroids on the enzyme activity in the sebaceous glands and in particular 3β HSD and the implications of these effects.

Iodoacetate/

Iodoacetate Trials

Hairs show an intense blue formazan stain in the bulbs of hairs extending up to the hair shaft (Figure 11). In attempting to quantitate the histochemical reaction by means of the microdensitometer or the use of spectrophotometric techniques, one comes up against the problem of the strong colour development in the hair shaft of the pilosebaceous unit. This colour development which occurs during the histochemical incubation described earlier is not associated with the enzymic reaction studied. Reduction of nitro BT to formazan is caused by two separate reactions:

- (1) Specific enzyme reduction of nitro BT mediated by HSD and NADH diaphorase
- (2) Nonenzymatic reduction of nitro BT directly by sulfhydryl - rich hair roots can be shown to occur in control solutions, containing only nitro BT and buffer. This non-enzymatic reduction of nitro BT can be blocked by pretreatment of hairs in 0.1 M. N-ethyl maleimide and 0.01 M. iodoacetate. (Muller and Winkelmann, 1969).

It would be advantageous for the purposes of histochemical investigations on the skin, for reasons described above, if the non-enzymic staining of the hair shaft could be removed without inhibiting the HSD enzyme in the sebaceous gland cells. For this purpose a series of pre-incubations of skin sections in iodoacetate at different time intervals was set up in an attempt to block the non-enzymatic reaction of the hair shaft without inhibition of the HSD reaction. Skin sections were given a brief rinse after preincubation and they were then subjected to the usual histochemical procedure for detecting 3β HSD activity.

Abnormal/

Abnormal Skins

So far all the histochemical investigations undertaken in this project were on normal skin obtained from patients in the course of operative incisions or biopsies. It was thought of interest to compare the results thus obtained with histochemical investigations of abnormal skins. Ideally one would envisage a survey done on a number of cases in which through metabolic disorders such as acne or through medical treatment such as steroid therapy, the steroid metabolism of the sebaceous gland might be thought to be altered. On ethical grounds however this is very difficult to carry out. In patients suffering from skin disorders such as acne, the removal of a skin biopsy may easily give rise to complications. As the people most severely suffering from acne are young people, the problem of scarring is one to be seriously considered. Even more so in attempting to follow the effect of treatment where therefore two biopsies (one before and one following the treatment) would have to be taken, do ethical considerations come into account. The skins for this project must be obtained from patients only upon voluntary agreement and in spite of the months of duration of this project, only a few skin specimens were examined before and after various treatments for acne in the Dermatology Department of the Western Infirmary.

Other Experiments

a) /

- a) Enzyme activity estimations between different sebaceous glands to establish whether activity is a cyclic phenomenon.

Sebaceous glands in a skin section are found in different stages of development. There are budding small sebaceous glands with densely packed cells showing strong 3β HSD activity, there are large mature sebaceous glands with cells densely distributed only on the periphery of the gland and very loosely distributed large, disintegrating cells in the lumen of the gland, showing less intense 3β HSD activity as observed in the histochemical studies. This situation may be due to the level of sectioning the sebaceous gland, some being cut at the edge of the gland while others may be cut through the middle. In studying the 3β HSD activity of a sebaceous gland in one section, one cannot ascertain whether what appears as a small active gland is in fact a budding developing sebaceous gland or the edge of a mature gland. However if one considers a skin sample rich in sebaceous glands such as a biopsy of the scalp in which a few sebaceous glands can be examined side by side and if one examines not one but a hundred consecutive sections of this biopsy all subjected similarly and simultaneously to the usual histochemical investigation, one can then ascertain whether in the human skin there are in fact sebaceous glands showing differing degrees of enzymic activity which would indicate a cyclic phenomenon associated perhaps with the hair growth cycle. On the other hand it may also be envisaged that the seeming variation in enzymic activity between two sebaceous glands in a skin section are due to the different levels of the sebaceous gland at which the section was taken. It was with a view of establishing the possible existence of a cyclic activity in the sebaceous glands that this experimental section was undertaken.

- b) /

b) Warm stage experiment

The formation of pink monoformazan and of blue diformazan through the reduction of nitro BT in the course of histochemical investigations into HSD activity in tissue sections as reported by Baillie et al., (1966) may be due as envisaged by these investigators to the different degrees of activity exhibited by different tissue sections. It may however be thought to be the result of two different enzymic reactions which becomes apparent in different tissues or in the same tissue under different conditions of incubation. With the standard incubation techniques evolved in this project and described earlier, sections showed a distinct positive or negative result so that either the deposition of blue diformazan granules was clearly distinguishable or in negative results the section was quite free of all formazan development. In order to elucidate the problem of monoformazan formation and also with the view of observing the manner of blue diformazan formation, the warm stage experiment was undertaken in which the section could be observed continuously on a microscope stage throughout the period of incubation under the usual conditions of histochemical studies of 3β HSD activity in skin sections. The method of incubation used for this experiment was the hanging drop technique, described in the section of 'Methods of Incubation'.

c) Experiment to determine whether NADP can replace NAD as the
co-enzyme of the steroid dehydrogenases

Nicotinamide/

Nicotinamide adenine dinucleotides are essential co-factors in most dehydrogenase reactions (Samuels et al., 1951). Some dehydrogenase systems are NAD dependent, while others are NADP dependent (Beyer and Samuels, 1965, Hubener et al., 1956, Hurlock and Talalay, 1959, Mahesh and Ulrich, 1959).

3β HSD is NAD dependent (Beyer and Samuels, 1956) but Baillie et al., (1966) reported that in some tissues a reaction will develop with NADP.

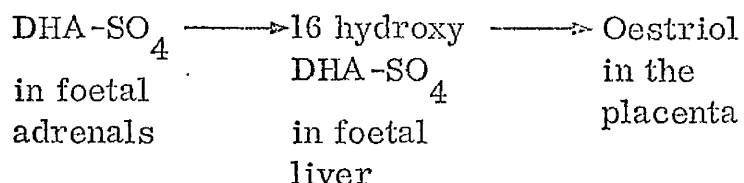
In the experimental section dealing with animal skins, difficulty was encountered in obtaining a good histochemical reaction with some sections e.g. gerbil glandular pad and it was thought worthwhile to run a trial experiment with NADP replacing NAD as co-factor in the incubation medium. This was therefore attempted on both human and animal skins in 3β HSD studies.

d) DHA-SO_4 as steroid substrate for HSD activity determinations
in human skin

DHA in the plasma is found in three forms:

1. DHA-SO_4 which accounts for most of the circulating DHA.
This is cleared slowly and is almost certainly an intermediate or a source of DHA. No known role can be attributed to it in non-pregnant individuals. Although/

Although the most abundant steroid in the body, it is androgenically inactive. In pregnancy it forms a source of placental oestrogens.



2. DHA glucuronide, which is cleared rapidly and can almost certainly be regarded as a metabolic end product.
3. Free DHA represents the smallest proportion of circulating DHA in the body. It is extensively bound to albumin

Total DHA in plasma disappears at about 4 weeks after birth and reappears again at puberty (Migeon, 1957)

Very little is known about the function of DHA in steroid metabolism and as DHA-SO₄ constitutes the greater part of circulating DHA it is of interest to consider its role in the body and it was thought worth investigating the possibility of its being a substrate in the 3β HSD reaction, in the adult but even more as a possibility in the foetus where it is thought to play an important function in placental interchanges of steroids.

e)/

e) Histochemical investigations on some other steroids

In the course of this work, the enzyme under special investigation was Δ^5 -3 β -hydroxy-steroid dehydrogenase and the steroid substrate particularly used in the histochemical investigations was DHA. .

Other steroids however were also tried and assays involving 16 β and 17 β enzymes have been described in the course of this thesis.

Besides the enzymes already mentioned, interest was also aroused by the possibility of histochemical investigations supporting currently obtained biochemical data into the steroid metabolism of the skin (Hodgins and Hay, unpublished data). In these biochemical investigations, incubations of skin with labelled steroid substrates are found to give rise to several labelled derivatives, and the general pattern which emerges implicates DHA and testosterone in multiple transformations of anabolic and kerabolic nature in the skin. Among the steroid products identified so far are - androstenediol, androstenedione, androsterone, epiandrosterone and etiocholanolone. Each of these was used in histochemical incubations on several skin samples.

Moreover in repeating some of the work previously done by Baillie et al., (1965, 1966) with the improved histochemical procedure, the presence of Δ^5 -3 β HSD in areas of the body (see Survey of Distribution) or animal material (see 'rat preputial gland' in Animal Experiments) was confirmed in spite of earlier negative results and so it was considered worthwhile to repeat some of the histochemical investigations using various steroid substrates already tried by the previously mentioned authors. In this category were:

- 3 β hydroxy-steroid : pregnenolone
- 6 β hydroxy-steroid : 6 β -hydroxy-4-pregnen-3, 20-dione
- 20 β hydroxy-steroid : 20 β -hydroxy-4-pregnen-3-one

METHODS

I Histochemical Methods

- (a) Aim
- (b) Materials
- (c) Preincubation techniques
- (d) Incubation medium
- (e) Incubation techniques
- (f) Post incubation techniques
- (g) Counterstaining procedure

II Semiquantitation

A. (Methods of granule counting)

- (a) Projection onto a screen
- (b) Scanning and integrating microdensitometer
- (c) Wild M20 microscope

B. (Other methods of quantitation of the enzymic reaction)

- (a) Spectrophotometric trials
- (b) Spectrophotofluorimetric experiments

III Survey of Distribution

IV/

IV Experimental Animal Studies

- (a) General
- (b) Gerbil experiments
- (c) Hamster experiments

V Iodoacetate Trials

VI Abnormal Skins

VII Other Experiments

- (a) Enzyme activity estimations between different sebaceous glands to establish whether activity is a cyclic phenomenon.
- (b) Warm stage experiment
- (c) Experiment to determine whether NADP can replace NAD as the co-enzyme of the steroid dehydrogenase.
 - (i) in human skin
 - (ii) in animal skins
- (d) DHA-SO₄ as steroid substrate for HSD activity determinations in human skin.
 - (i) adult
 - (ii) perineal
 - (iii) foetal
- (e) Histochemical assays on several other steroid substrates

I Histochemical Methods

Most of the work described in this thesis deals with a histochemical method, the development of which constituted the first part of the project and the details of which have been published in two papers enclosed herewith.

A more detailed report of this method is as follows:-

(a) Aim

Further investigations of the histochemical reaction used to determine the presence of hydroxysteroid dehydrogenases (Baillie et al., 1965 and 1966) with the purposes of a) reducing it to a micro-technique b) introducing some form of quantitation and to use this in an attempt to characterise the enzymes more fully.

(b) Materials - List of main compounds used for histochemical incubations -

Steroids (Steraloids) - DHA(Dehydroepiandrosterone)

Pregnenolone

Epiandrosterone

Etiocholanolone

Androsterone

Testosterone

Oestradiol

5-Androsten-3 β -16 β -diol-

3 Methyl ether

Anti-androgens from Schering

Laboratories

Androgenic/

Androgenic compounds used in
animal experiments provided
by Organon Laboratories.

NAD	Nicotinamide adenine dinucleotide. Co-enzyme I (D5755 Sigma)
NADH	Reduced nicotinamide adenine dinucleotide (D7380 Sigma)
DMF	Dimethylformamide - BDH
Nitro BT	Nitro blue tetrazolium (N 6876 Sigma)
Buffer	Buffer pH 7.4 phosphate buffer (Hopkin & Williams) 0.1M

(c) Preincubation techniques

Full thickness skin biopsy specimens about 5 mm in size were obtained from diverse sites of male and female subjects of different age groups. These skin specimens were frozen on solid carbon dioxide within 2 mins. after interruption of their blood supply and sectioned at 8 - 10 μ on a cryostat maintained at -20°C. The sections were attached on No. 1 glass coverslips 20 mm. in diameter, by momentary thawing. The sections were stored in sealed plastic containers at -20°C for up to 2 weeks until required.

(d) Incubation medium

The standard incubation medium was made up in 10 ml. and contained:-

1 mg. nitro BT (Sigma)
2 mg. NAD (Sigma)
0.3 mg. steroid dissolved in 0.3 ml.
DMF Made up to 10 ml. with
Phosphate Buffer pH 7.4

Control/

Control incubations were set up simultaneously and were the same as the standard incubation except that they did not contain either a) steroid or b) NAD. With each series of incubations an NADH trial was also simultaneously performed. This incubation medium was made up with NADH, nitro BT, and buffer only. The quantities were based on those previously described (Baillie et al., 1966a). The amount of medium used for each incubation was 0.7 ml. Incubations were carried out at 37°C (except in the optimum temperature trials) and they were run for 2 hours (except in the time curve experiments).

Other substances were used in trials designed to test their action as co-enzymes or inhibitors. These were as follows:-

Magnesium sulphate (M & B) Nicotinamide (Sigma)
 Vitamin K menadione (BDH) as possible co-enzymes
 and Quinestradol (Vister, Vismara Therapeutics,
 Como) Cyproterone (Schering, A.G., Berlin)
 Cyproterone acetate (Schering, A.G., Berlin)

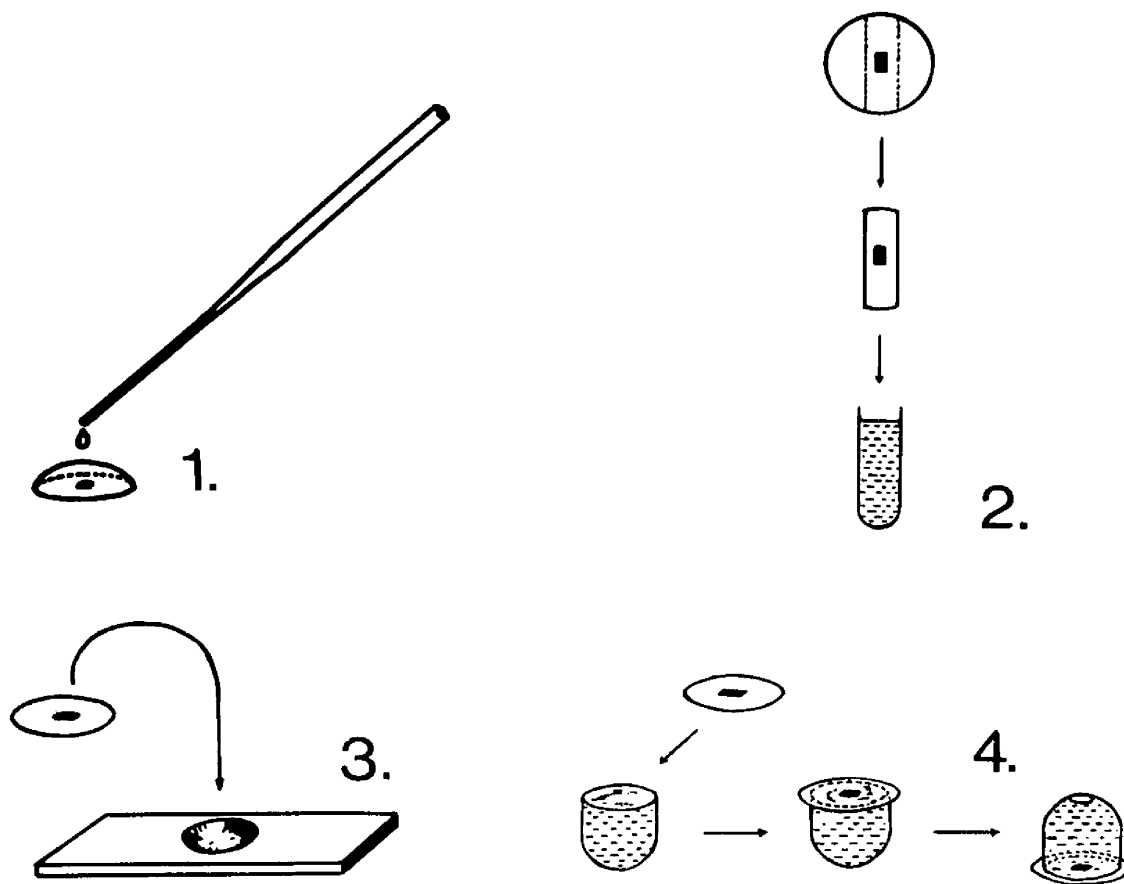
These substances were added to the standard incubation medium in various concentrations (Haslinmoto et al., 1964, Kochakian et al., 1957).

(e) Incubation Techniques

Various incubation techniques were tried. They are shown diagrammatically in Figure 12.


(i)/

Figure 12 Incubation techniques 1 - 4



- (i) Coverslip with the attached section was covered with the incubation medium by means of a Pasteur pipette with an attached rubber teat by means of which one normally controls the rate of flow, drop by drop. About 0.7 ml. of medium were needed to cover the section and avoid evaporation to dryness in 2 hours.
- (ii) A small strip of coverslip cut out with a glass diamond, so as to hold the skin section, was placed in a small test tube (5 x 50 mm.) filled with incubating medium. About 0.4 ml. of the medium were required for this method of incubation.
- (iii) The coverslip with the attached skin section was inverted over a hanging drop slide which contained the incubation medium (about 0.2 ml.) or inverted over a watch glass, enclosing 0.5 ml. of medium.
- (iv) Small glass domes, made by cutting and grinding down the closed end of an ordinary glass test tube (1.5 x 15 cm.) The dome was filled with incubation medium (0.8 ml.) closed by the coverslip and inverted for incubation on a small wooden base. This is known as the bell - jar method.
- (v) The perspex chamber - A modification of method (i) was devised in our laboratory with the help of the chief technician Mr. H. Young, who designed the trays shown in Figure 13. The/

Figure 13 Incubation technique No. 5 perspex chamber



The perspex tray 12 in. sq. is fitted with an air-tight lid to form a box 1 inch in height thus constituting a moist chamber. The tray is made in such a way that a shallow $\frac{1}{4}$ inch wide trough runs round at 1 inch distance from the edge. This trough can be filled with water or wet swabs of cotton wool placed in the corners of the tray before the lid is fitted on for incubation to sustain the humidity level in the chamber and reduce evaporation of the incubating fluid.

The coverslips are placed on a double layer of filter paper which causes rapid absorption over a small area of any incubating medium which might inadvertently spill from one of the coverslips.

Without such rapid absorption the overspill of one coverslip meniscus would easily lead to a spread of overspilling in the adjacent coverslips. As the meniscus of incubating medium is held on the coverslip by surface tension it would be easy to provoke overspill spreading throughout the tray. The filter paper also serves as a good background to the coverslips for easier visibility in the incubator when the incubating solution is dropped onto the coverslips with a Pasteur pipette by means of a rubber teat.

To follow the progress of the reaction with time, two methods were used:-

(a)/

- (a) Sections were incubated on a projection microscope within an incubating oven at 37°C . The reaction was started when all the reactants and equipment had reached the required temperature. The reaction was followed throughout the incubation by projecting onto a screen in the incubating cabinet and it was then possible to count the number of granules within a single high power field at set intervals of time.
- (b) The incubation was carried out on the warm stage of the microscope (at 37°C) where it could be examined continuously.

To study the effect of temperature on enzyme activity, skin sections were heated in a dry oven at 60°C , 80°C , 100°C and 160°C for various intervals of time up to half an hour. Normal incubations were then carried out on these preheated sections.

To determine whether the enzymes were soluble in the buffer or not, two consecutive sections were assayed for 3β HSD. The first control was subjected to the normal routine incubation, while the other was preincubated in buffer alone for 10 mins. and then subjected to normal incubation. The experiment was repeated with oestradiol, testosterone and 5-androstene- 3β - 16β -diol-3-methyl ether as substrates.

(f) /

(f) Post Incubation Techniques

After 2 hours of incubation the reaction was terminated by dehydration with alcohol.

A method of counterstaining was evolved to facilitate the observation of the granule deposition in the skin sections.

Various stains were tried for cytoplasmic and nuclear counterstaining of these.

Cytoplasmic

- a) Tartrazine in cellosolve (ethoxyethanol - BDH) - yellow
- b) Saturated aqueous picric acid - yellow
- c) Dilute acid carbol fuchsin - pink
- d) 0.5% aqueous eosin - red

Nuclear

- a) 1% aqueous neutral red - red
- b) G. T. Gurr's haematoxylin - red

The effect of these stains on bringing out of the details of the section after incubation as well as on making this appearance lasting was studied.

Sections were mounted in DePeX.

Steroids were dissolved in Dimethylformamide (DMF) in concentrations: 1 mg. steroid/1 ml. DMF. These solutions were made up 10 ml. quantities and stored at 4°C for up to 8 weeks.

Incubating solutions were made up freshly on the day of incubation.

Incubation/

Incubation solution

0.3 mg. steroid (in 0.3 ml. DMF)
2 mg. NAD (dissolved in 1 ml. buffer)
1 mg. nitro BT (dissolved in 1 ml. buffer)
M/10 Phosphate buffer pH 7.4 added to
total volume = 10 ml.
(Final concentration of steroid = 0.1μ
mole/ml.)

Control solution

0.3 ml. DMF (no steroid)
2 mg. NAD (in 1 ml. buffer)
1 mg. nitro BT (in 1 ml. buffer)
Buffer added to total volume = 10 ml.

NADH solution (Diaphorase control)

2 mg. NADH (in 1 ml. buffer)
1 mg. nitro BT (in 1 ml. buffer)
Buffer added to total volume = 10 ml.

(g) /

(g) Counterstaining Procedure

Materials

Xylene, pure and sulphur free
 Absolute alcohol, 74 OP
 Methylated spirits, 66 OP
 Mayer's haematoxylin
 Distilled water
 Tartrazine
 Cellosolve
 DePeX (Gurr) or Harleco synthetic resin (HSR) (Kodak)

Method

After incubation the coverslips were placed in staining racks and the following staining procedure was adopted:

Brief rinse in distilled water
 Haematoxylin blue - 2 minutes
 Brief rinse in distilled water
 Methylated spirits - 1 minute
 Tartrazine - 2 minutes
 Methylated spirits - 2 minutes
 Absolute alcohol I - 2 minutes
 Absolute alcohol II - 2 minutes
 Xylol I - 2 minutes
 Xylol II - 2 minutes

The coverslips were then mounted onto microscope slides (3" x 1", 0.8 - 1.0 mm. thickness, prewashed) with DePeX or HSR.

II Semiquantitations

A. Methods of granule counting

(a) Projection onto a screen. Granules were counted on a projection screen at varying time intervals during the course of the reaction. The section was incubated by the hanging drop method ((iii) in Figure 12) on a warm stage (at 37°C) of a projection microscope. All reagents and equipment were at 37°C at the start of incubation. At intervals of 10, 15, or 30 mins., the microscope lamp was switched on and the sebaceous gland image was projected onto a screen. The area of the sebaceous gland was measured and the granules counted.

(b) Scanning and integrating microdensitometer. An attempt was made to estimate the number of formazan granules deposited in the sebaceous glands of skin by use of a Barr & Stroud scanning and integrating microdensitometer (by courtesy of Dr. Duguid of the Royal Infirmary of Glasgow).

Skin sections are submitted to the normal histochemical procedure and then examined under this special microscope which scans the field under examination, recording the number of times the light beam hits an optically dense particle.

The shortcomings of this method (which proved unsatisfactory) are further discussed in Results but to overcome some of its disadvantages, a different type of scanning and integrating microdensitometer was assayed by courtesy of the Mining Department of Strathclyde University. This/

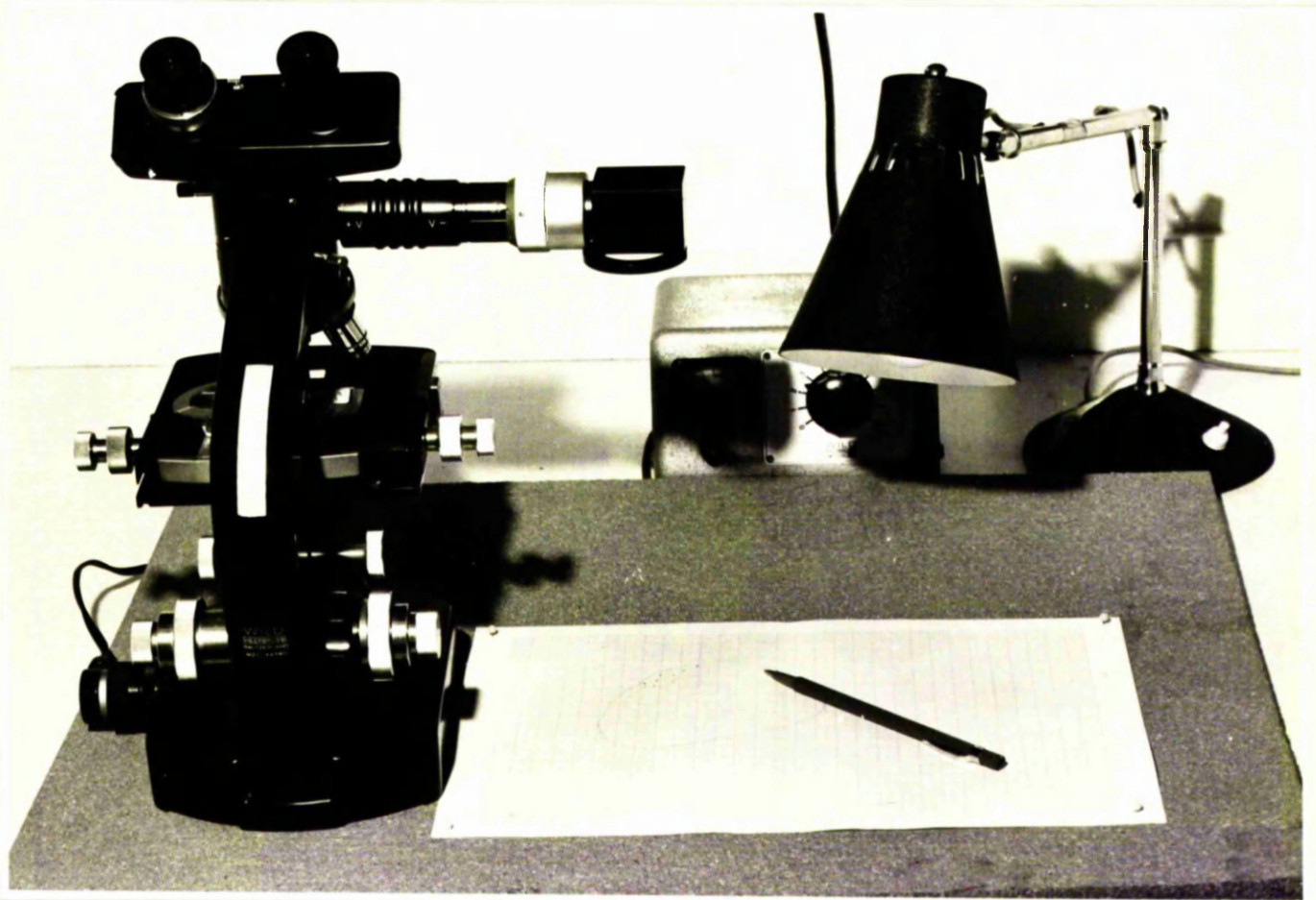
This apparatus also scans the field under examination and records the number of particles in the path of the light beam, but also the equipment can be set to record different particle size, so that it is in principle possible to count small, medium and large granules and to add this up to a grand total of granules in a field. The settings however are very time consuming. This method also was found to be unsatisfactory and was discarded. The method finally adopted was:

(c) A Wild M20 Microscope with a drawing tube attachment (Figure 14) was used to examine the counterstained and mounted sections and to project the image of the sebaceous gland at a suitable magnification onto a sheet of mm. type graph paper. The principle is that of camera obscura. The sebaceous gland being viewed at a high magnification (x 400) the image is superimposed on the graph paper where it can be quite easily traced out with a pencil and the granules marked in it. The measurement of the sebaceous gland area and the counting of the granules can then be done at a later time. Two methods were used in an attempt to find a rapid method of granule deposition estimations:

1. Granules lying exactly on the intersections of 5 mm. sequences of the graph paper were drawn and counted.
2. The number of granules within each 5 mm. square were counted and scored as -

0 /

52.
Figure 14 Wild M20 microscope with drawing tube attachment



- 0 - if there were none
- 1 - if there were 1 - 5 granules
- 2 - if there were more than 5 granules
per 5 mm. square

The latter method was finally adopted.

The figures were added up to give a total estimate of granules and the results expressed as granules estimated/square μ .

The Wild M20 microscope was calibrated in all cases with a slide micrometer and the area of sebaceous gland when counted, expressed in square microns.

Statistical tests were applied to all the methods described.

B. Other methods of quantitation of the enzymic reaction

(a) Spectrophotometric trials

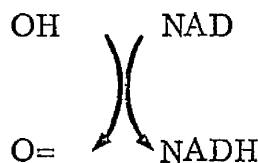
1. Elution method - Assays using method (ii) of incubation technique with a strip of coverslip holding the skin section being incubated, in a small test-tube (see Figure 12). The contents of the test-tube was then transferred into a spectrophotometer cell and the reading compared with a control sample in which the incubation proceeds without a steroid base.

2./

2. Colorimetric technique - Skin sections were incubated by method (iv) on a coverslip (see Figure 12). After incubation the coverslip containing the skin section is rinsed and mounted on another coverslip. The strip containing the skin sections is then cut out with a glass diamond and placed in a spectrophotometric cell in such a way that the light can pass through the section. Readings are taken of test incubated and control incubated skin sections.

(b) Fluorimetric method for quantitative estimations of 3β -steroid dehydrogenase activity in human skin

This method consists of measuring the conversion of NAD to its reduced form NADH this being part of the reaction which leads to the oxidation of the hydroxy to keto grouping on the steroid molecule according to the reaction.



Nicotinamide nucleotide is an essential co-enzyme of the steroid dehydrogenase and this assay is based on the method used by Lowry, Roberts and Kaplan (1957).

Method/

Method of fluorimetric estimation of steroid dehydrogenase activity in human skin - Aminco Bowman Spectrophotofluoremeter was used (by courtesy of the Biochemistry Department of the University of Glasgow).

This apparatus (Figure 15) consists of -

Optical Unit - including an electrical panel, Xenon lamp with housing and blower, two mono-fluometers, cell shutter, cell compartment, photomultiplier, shutter and photomultiplier tube housing. The unit operates on 115 volt. a.c., 60 cycles, single phase power.

Photomultiplier microphotometer

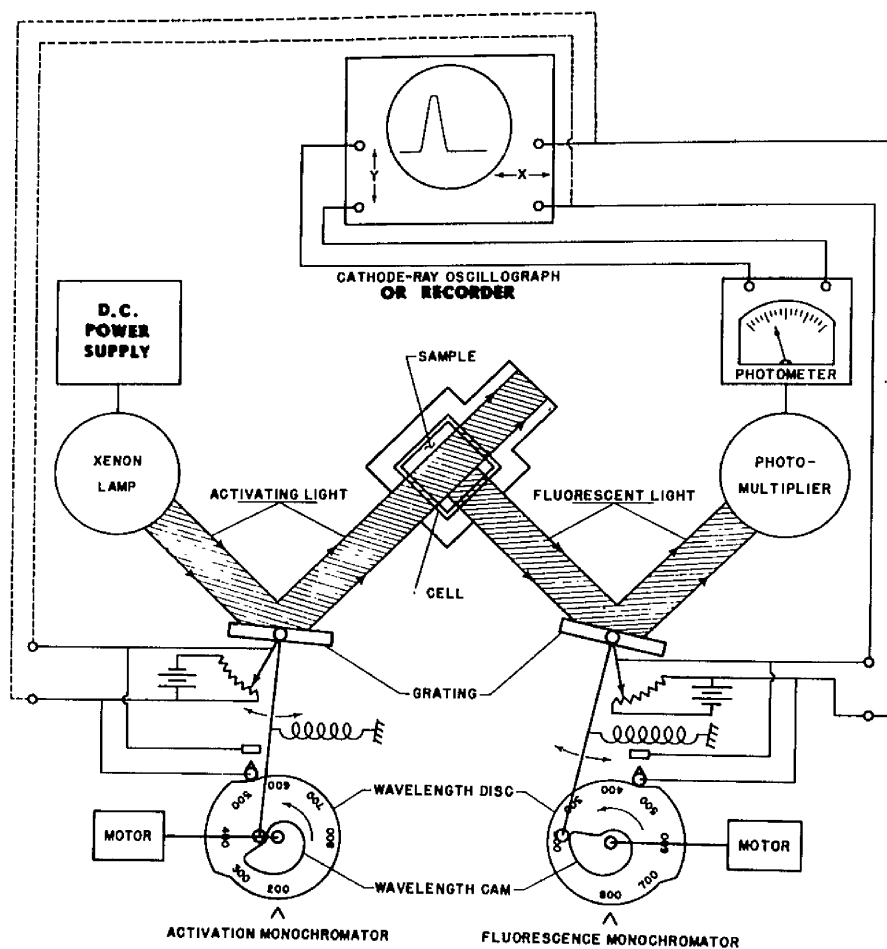
D.C. Power supply for an Xenon lamp and accessories.

Experimental conditions and settings -

1. Photomultiplier tube type and serial number: 1P28.
2. Slit arrangement (sensitivity varies with slit arrangement) number 4 used.
3. Activation and fluorescent wavelengths.
4. Type of activation lamp.
5. Meter multiplier setting.
6. Sensitivity setting.
7. Meter reading

Method/

Figure 15 Diagrammatic representation of the spectrophotofluoremeter
(by courtesy of Aminco-Bowman)



Schematic of Aminco-Bowman Spectrophotofluorometer.

Method -

Skin samples were frozen on carbon dioxide ice in the usual way. They were mounted on chucks and cut in the cryostat but instead of mounting individual sections on coverslips (as for histochemical incubation techniques) the cut sections were collected down a slide (Figure 6) into small glass jars, 30 sections of 8 microns in thickness, being collected in each jar. Approximate weight of thirty such sections, varying with the cross-section of the skin sample = 20 mg.

Three jars containing 30 sections each were prepared from each skin sample.

As larger skin samples were needed for this experiment than is available in normal skin biopsies, the skin samples used for these assays were obtained from the thoracic unit operating theatre at the Western Infirmary of Glasgow.

The three jars were labelled A, B, and C and they were incubated as follows:-

A. Steroid base (DHA)	0.3 mg.
dissolved in DMF	0.3 ml.
NAD	2 mg.
Phosphate buffer to make up	10 ml.
B. Steroid base (DHA)	0.3 mg.
dissolved in DMF	0.3 ml.
Phosphate buffer to make up ad	10 ml.
C./	

C. NAD	2 mg.
Phosphate buffer to make up	10 ml.

3 ml. amounts of these incubating media were added to the corresponding glass jars with the skin sections and these were incubated at 37°C for two hours.

The contents of the jars were then centrifuged. Small M.S.E. centrifuges at 2500 r.p.m. for 3 minutes and the supernatant solution read on the Aminco Bowman Spectrophotofluometer against standards of -

1. NAD solution
2. NADH solution

against a buffer blank.

III Survey of Distribution

Using the histochemical technique described and assessing the results by the semiquantitative method by means of the Wild M20 microscope, one hundred and eighty skin biopsies taken from different sites of individuals of all ages and both sexes, were tested for 3 β HSD activity and the results published in the paper enclosed. (Survey of Steroid Dehydrogenase Distribution in Human Skin)

Part/

Part of this survey was carried out in the Biochemistry Department of the All India Institute of Medical Sciences (A.I.I.M.S.) in New Delhi, India under the supervision of Professor G.P. Talwar. Skin biopsies were obtained from the operating theatres of A.I.I.M.S., and equipment of the Biophysics Department and of the Physiology Department was used by courtesy of the heads of the departments of A.I.I.M.S.

The survey involved a series of one hundred and eighty biopsy specimens from different regions of the body surface. These biopsies were obtained from different operating theatres in the Western Infirmary, Glasgow and the A.I.I.M.S., New Delhi, by the courtesy of the surgeons. The specimens were taken from patients of both sexes in all age groups. The skin samples were frozen on Co_2 ice within seconds of incision. The skin samples were cut in a cryostat into 10μ sections which were mounted on coverslips and stored at -20°C when storage was necessary. Incubations were carried out by the usual histochemical procedure described in the previous section.

The skin samples were obtained over a period of three years from various operating theatres in the Glasgow Western Infirmary and the A.I.I.M.S. unit in New Delhi.

The project was done in conjunction with Dr. Calman of the Department of Surgery at the Western Infirmary, Glasgow.

The/

The results of the survey were analysed according to sex, age and site of distribution and statistical tests were applied.

As the skin specimens were obtained slowly over a long period of time, it was not found possible to store them for testing in groups and the histochemical assay was carried out whenever skin samples were available. It was therefore not found practical to compare the intensity of the reaction in different skin specimens by the semiquantitative method described previously and in this section of the work only the positive or negative results of the histochemical reaction was reported and considered.

IV Experimental Animal Studies

(a) General

In an attempt to find a suitable experimental animal for studies on steroid dehydrogenases, the following animals were considered:

1. mouse - skin
2. rat - skin from body - skin from preputial gland
3. mongolian gerbil - skin from body - skin from territorial marking
4. guinea pig - skin from body - skin from lip
5. Syrian hamster - skin from body - skin from costovertebral organs.

The/

The animals were killed either by cervical dislocation (mouse, rat) or by nembutal (gerbil, guinea pig, hamster) and the required tissue removed after shaving immediately following death, and frozen on solid CO₂. The techniques for preparation of sections were the same as those described earlier for human skin. In this section of the work other steroid bases besides DHA were used in an effort to establish the presence of various HSD enzymes in the samples studied. The steroids used were:-

1. Dehydroepiandrosterone (DHA) for the demonstration of 3 β HSD activity.
2. 5-androstene-3 β -16 β -diol-3 methyl ether for the demonstration of 16 β HSD activity.
3. Testosterone
4. Oestradiol for the demonstration of 17 β HSD activity

Controls were set up with no steroid base. Diaphorase activity was checked using an incubating medium which consists of -

NADH	2 mg. (Sigma)
Nitro blue tetrazolium	1 mg.
Phosphate buffer ad	10 ml.

In view of the fact that the basic medium consisting of -

Steroid	0.3 mg./0.3 ml. DMF
NAD	2 mg.
Nitro blue tetrazolium	1 mg.
Phosphate buffer ad	10 ml.

in/

in some cases did not show good results, a series of experiments were carried out -

1. Varying the above concentrations which had been established to be successful for human skin.
2. Varying the time and temperature of incubation.
3. Using NADP as co-factor instead of NAD.
4. Due to the fact that in certain experiments positive results were obtained and even in the same experiment certain sections would show positive results while others did not and linking these discrepancies with previous reports which failed to establish the presence of HSD enzymes in the same material (Baillie, Ferguson, Hart, 1966) it was considered possible that the enzymes although present in the sebaceous material (as indicated by some of the sections being slightly positive) was of a more diffusable nature than that in human sebaceous glands.

During the course of the incubation, the enzyme may diffuse out into the surrounding medium so that it is washed away in the course of the brief rinse to which the sections are subjected prior to counterstaining and mounting. To overcome this effect on enzyme diffusion it was then thought advisable to add to the incubating medium, polyvinylpyrrolidone, (PVP) an inactive high-molecular substance which is water soluble (Pearse, 1968, Burstone, 1969) and which would provide a stabilising factor during the histochemical incubation. This/

This was tried adding 0.3 gm. PVP/10 ml. incubation medium. As will be described in the Results section, the addition of PVP gave good results. In some experimental runs, it was found however that the addition of PVP while giving good positive results in the test sections, also gave rise to a new problem namely positive controls. These had also sometimes been observed in straight runs on some human skin samples and as with those cases, the problem was overcome by resorting to prewashing. This simple technique consists of subjecting all test and control sections in a given series to a brief rinse in phosphate buffer prior to incubation.

The animal skin at various sites was shaved and skin samples taken as for biopsies, and frozen immediately on solid carbon dioxide.

Sections were cut on a cryostat as for human skin (see preincubation techniques) and incubated by the normal histochemical procedure.

The difficulty encountered in animal skin being the presence of many hair follicles which give a very strong colour reaction (see Results and Discussion) a genetically hairless mouse was obtained by the courtesy of Mill Hill Research Laboratories. This skin however has no adequate sebaceous glands. Very small keratinized sebaceous glands were found and these were not suitable for the histochemical assay.

The Mongolian gerbil (Meriones unguiculatus) has a sebaceous gland patch on its lower ventral abdomen. This patch is clearly distinguishable from the surrounding fur as it varies from it in colour and direction of hair growth (Figure 10). The/

The patch is larger in male than in female gerbils and it attains its full size only at maturity. For most of the experiments on the gerbils mature male animals were used. The skin of the glandular pad is shaved and taken for sectioning on the cryostat as described in the histochemical technique. Skin sections of the glandular pad, show an abundance of sebaceous glands and a sparse distribution of hair follicles which do not therefore mask the histochemical results of the assay. Owing to the inconstancy of the results in consecutive sections, incubation conditions were altered in an effort to find the optimum conditions for the histochemical technique in this animal. It was thought that either the temperature at which the incubation is carried out or the concentrations of one or more of the constituents of the incubating medium might if suitably altered improve the results and give a more consistent picture. These efforts failed. In consequence of the positive results received in some skin sections in some of the incubations and in view of these results being inconstant, it was thought that some other technical factor must be responsible for the frequent failure of the histochemical method in this particular animal skin (Chayen et al., 1965, The meaning of a good histochemical reaction). The doubt was therefore raised regarding the greater solubility of the steroid dehydrogenases in the gerbil as compared to human skin. If this suspicion was justified then by using PVP to raise the viscosity of the incubating medium one should diminish the loss of enzyme activity by diminishing diffusion during incubation. Polyvinylpyrrolidone (PVP) (Sigma) 0.3 gms. were used per 10 ml. incubating medium. The use of PVP was tried also on the other animal skins and on human skin.

As/

As in the animal skins the main disadvantage is the side effect of colour development in the hair shafts, areas of skin in which this would not apply were tried and among them guinea pig lip which proved to be satisfactory material.

(b) Gerbil experiments - Effect of androgens and antiandrogens on the sebaceous glands of the glandular pad in the gerbil.

Gerbils were subjected to a series of experiments designed to show the effect of androgens and antiandrogens on steroid dehydrogenases of the sebaceous glands in the sebaceous gland patch of skin.

Gerbils(Meriones unguiculatus) as has been stated (Figure 10) show a well marked sebaceous gland patch about 1 cm. long and 3 - 4 mm. wide on the lower ventral side.

Two series of a dozen animals were used. Each series was divided into four groups of three animals. In these experiments systemic treatment was considered throughout.

Experiment I

Group I	Testosterone (T. Propionate, Organon Laboratories, in arachis oil with 10% benzyl alcohol) 5 mg./day.] for two weeks
Group II	Oestradiol (O. Benzoate, Organon Laboratories) 1 mg./day	
Group III	DHA (Steroids dry powder product, dissolved in arachis oil with 10% benzyl alcohol) 1.25 mg./day	
Group IV	Controls	

After/

After one week one animal was sacrificed from each group and a sample of body skin and the skins of the sebaceous gland patch subjected to histological and histochemical examinations. After two weeks one of the Group I animals was changed from testosterone to oestradiol treatment.

The forementioned groups were continued as before.

After three weeks one animal from each group was sacrificed and a sample of body skin and the skin of the sebaceous gland patch, subjected to histochemical tests.

The remaining animals i. e. one of each of the groups:

Group I	(testosterone treatment)
Group II	(oestradiol treatment)
Group III	(DHA treatment)
Group IV	(control)

were put onto tetracycline (5 mg./day)

Experiment II

The series was divided into four groups of 3 gerbils each.

Group I	Testosterone	<u>Testosterone</u>
	Testosterone and tetracycline	
	Testosterone and antiandrogen	
Group II	Oestradiol	<u>Oestradiol</u>
	Oestradiol and tetracycline	
	Oestradiol and antiandrogen	
	DHA/	

	DHA	
Group III	DHA and tetracycline	<u>DHA</u>
	DHA and antiandrogen	
Group IV	Tetracycline	<u>Control</u>
	Antiandrogen	

Testosterone	1 mg./day
Oestradiol	1 mg./day
DHA	1 mg./day
Tetracycline	(dissolved in water) 5 mg./day
Antiandrogen	1 mg./day. It was dissolved in arachis oil with 10% benzyl alcohol.

The antiandrogens were provided by Schering Laboratories.

They were - 6 chlor-substituted pregnenolones which have biological antiandrogenicity and show histochemical blocking.

This experiment was continued for 1 week before the animals were sacrificed and examined as described previously.

All the substances used in these experiments were injected subcutaneously. Intramuscular incubations were first tried but the animals developed sores on the injection site and subcutaneous injections proved more satisfactory. The animals were momentarily left in a glass jar in an ether atmosphere and injected while in a semi-comatose condition. When sacrificed the animals were injected with 1 ml. of nembutal.

(c)/

- (c) Syrian hamster experiments - Topical and systemic action of steroid compounds on the costovertebral organs of the Syrian hamster.

Syrian hamsters have two circular dark patches about 5 mm. in diameter in the mid dorsal position, one on each side and about 2 cm. distant from the vertebral column. These are known as the costovertebral organs (C. V. O.)

Unmedicated lotion base of Efcortelan EPZ (c) 10/11 specially provided by Glaxo Laboratories Ltd., Greenford, Middlesex was used.

Steroid compounds tested were provided by Organon Laboratories.

1. 17β -hydroxy- 5α -androstan-3-one (5α -dihydrotestosterone)
2. $3\alpha, 17\beta$ -dihydroxy- 5α -androstan
3. 5α -androstan-3, 17-dione
4. $3\beta, 17\beta$ -dihydroxy- 5α -androstan
5. 3β -hydroxy- 5α -androstan-17-one (Epiandrosterone)
6. 3α -hydroxy- 5α -androstan-17-one (Androsterone)

For the effects of topical application of the steroid compounds, 20 μ g. amounts dissolved in ethanol were incorporated in the lotion base and rubbed daily onto the shaved right C. V. O. of the animal, while the left side of the animal was observed as control. Both sides of the animal were shaved prior to the experiment.

For/

For the effects of systemic application, daily intramuscular injections of $10\text{ }\mu\text{g/day}$ of the steroid compound dissolved in a trace of ethanol and taken up in arachis oil, were given to the hamsters. Ethanol was evaporated before injection.

Treatment was continued for 10 days.

Topical application ($20\text{ }\mu\text{g/day}$) in lotion

<u>Animals</u>	<u>Steroids applied</u>
1.	17β -hydroxy- 5α -androstan-3-one (5α -dihydrotestosterone)
2.	3α , 17β -dihydroxy- 5α -androstan
3.	5α -androstan-3, 17-dione
4.	3β , 17β -dihydroxy- 5α -androstan
5.	3β -hydroxy- 5α -androstan-17-one
6.	3α -hydroxy- 5α -androstan-17-one
7.	base lotion only - control

Systemic application ($10\text{ }\mu\text{g/day}$) in arachis oil

8.	17β -hydroxy- 5α -androstan-3-one
9.	3α , 17β -dihydroxy- 5α -androstan
10.	3β , 17β -dihydroxy- 5α -androstan
11.	arachis oil alone - control
12.	no treatment - control

V Iodoacetate Trials

Post mortem skins from the scalp region were used in this experiment. The experiment was repeated four times. Skin from the scalp was used because of the abundance of hairs in that region. Post mortem skin was readily available and this was taken usually within 24 hours after death although skin removed even later shows unaltered histochemical reaction.

Skin sections were cut and prepared in the usual way and pre-incubated at room temperature with

A) iodoacetate (0.01M) - ethyl
maleimide (0.1M) solution.

B) phosphate buffer

for periods of 3, 5, 7, 9, 12, 15 and 20 minutes. The coverslips with the sections are then briefly rinsed in buffer and set up for normal DHA and control incubations.

As controls, sections which have undergone no preincubation were also set up.

The DHA incubations were run on one of each time interval pre-incubated sections in the A) and B) series. And the controls likewise.

After two hours of incubation at 37°C the sections were counterstained in the usual manner and examined for formazan deposition and for hair-shaft coloration.

VI/

VI Abnormal Skins

Most of the work so far described has been carried out on normal skins, that is to say that the skin biopsies taken for technical studies and for the Survey of Steroid Dehydrogenase Distribution in Human Skins was taken from healthy skin areas from individuals not undergoing treatment for any special skin condition.

It was thought of interest to test for steroid dehydrogenase activity in skin of patients suffering from skin conditions which might be thought to be associated with steroid metabolism notably acne, as well as patients undergoing some treatment (topical or parenteral) which might be reflected in an altered enzymatic state of the sebaceous gland, notably steroid treatment. Sulfur treatment and tetracycline treatment in view of their importance in acne are of course of great interest in such considerations.

Only a few skin samples are reported. These were collected over a long period of time and unfortunately not more than this half a dozen can be reported for reasons dealt with more fully under Discussion. Briefly however - it is difficult for ethical reasons to demand two skin biopsies from a patient and yet two biopsies are required to observe the effect of treatment.

Skins examined/

Skins Examined

<u>Patient</u>	<u>Age</u>	<u>Site</u>	<u>Condition</u>	<u>Treatment</u>	<u>Duration of Treatment</u>
Case 1 Male	24	Back,	Acne	Pentovis (Quinestradiol) Oestradiol	10 days
Case 2 Male	22	Back, Scapular region	Acne	Sulphur - (topical) Tetracycline - (oral)	1 week
Case 3 Female	18	Back, Scapular region	Acne	Quinoderm - (topical) 5% Sulphur - (topical)	8 days
Case 4 Female	16	Back, Scapular region	Acne	Synalar Fluocinolone acetone ointment - (topical)	10 days
Case 5 Male	25	Back Scapular region	Acne	Sulphur - (topical) Tetracycline - (oral)	1 week

Two skin biopsies were taken : pre and post - treatment, and these were taken as near as possible from the same site.

VII Other Experiments

(a) Enzyme activity estimations between different sebaceous glands to establish whether activity is a cyclic phenomenon

Sixty consecutive sections of skin containing a few sebaceous glands were examined after a normal histochemical assay for 3β - HSD activity determinations. Enzyme activity was estimated by means of granule counting (Wild M20 microscope; semiquantitative method described previously).

(b) Warm stage experiment

A skin section fixed on a coverslip was set on a microscope slide (hanging drop method) and placed on the warm stage of a microscope. The temperature of the warm stage was maintained at $33 - 34^{\circ}\text{C}$ during two hours and the deposition of blue formazan colour was observed through the microscope under a suitable power to allow viewing of a sebaceous gland and the surrounding area of the skin section.

(c) Experiment to determine whether NADP can replace NAD as the co-enzyme of the steroid dehydrogenase reaction

- (i) Three different adult human skin biopsies
- (ii) Skin of rat, gerbil and hamster. Preputial gland of rat, territorial marking of gerbil and costovertebral organ of hamster.

Two/

Two sections of each tissue sample were incubated with each incubating medium.

The media were made up as follows:-

- | | | |
|---------------|---|-----------------------------------------|
| Control | < | 1. NAD, nitro BT, buffer |
| | | 2. NADP, nitro BT, buffer |
| DHA | < | 3. NAD, DHA, nitro BT, buffer |
| | | 4. NADP, DHA, nitro BT, buffer |
| 16 β | < | 5. NAD, 16 β , nitro BT, buffer |
| | | 6. NADP, 16 β , nitro BT, buffer |
| Testosterone | < | 7. NAD, testosterone, nitro BT, buffer |
| (17 β) | | 8. NADP, testosterone, nitro BT, buffer |
| Oestradiol | < | 9. NAD, oestradiol, nitro BT, buffer |
| (17 β) | | 10. NADP, oestradiol, nitro BT, buffer |

(d) DHA-Sulfate as steroid substrate for HSD activity determinations in human skin

Incubation media were made up as for normal 3 β HSD histochemical trials.

The solutions used were:

1. Control (no steroid substrate)
2. DHA as steroid substrate
3. DHA-SO₄ as steroid substrate
4. Diaphorase control (NADH)

The/

The skins tested were:-

- (i) three skin biopsies of adult human skin
- (ii) two skin biopsies of perineal skin
- (iii) two skin biopsies of foetal skin (20 and 26 weeks old respectively)

(e) Histochemical assays on several other steroid substrates

In investigations of other steroid bases, the histochemical methods used were in all respects similar to those already described.

The steroid bases used :-

- 1. Pregnenolone
- 2. Epiandrosterone
- 3. Androstenediol
- 4. Androsterone
- 5. Androstenedione
- 6. Etiocholanolone
- 7. 6β -hydroxyprogesterone
- 8. 20β -hydroxyprogesterone
- 9. Dihydrotestosterone
- 10. $3\beta, 17\beta$ -Dihydroxy- 5α -androstan
- 11. $3\alpha, 17\beta$ -Dihydroxy- 5α -androstan
- 12. 5α Androstan-3, 17-dione

The skin samples used in these incubations were as follows:-

Sample/

Sample

1. Female, 36 years, ant. chest
2. Male, 49 years, upper abdomen
3. Male, 38 years, scalp
4. Male, 63 years, post chest
5. Female, 32 years, post chest
6. Male, 69 years, lower abdomen
7. Female, 60 years, breast
8. Male, 59 years, chest
9. Female, 26 years, scapular
10. Female, 36 years, post. chest
11. Female, 53 years, ant. chest
12. Male, 18 years, lower abdomen
13. Male, 65 years, lower abdomen
14. Female, 54 years, ant. chest
15. Female, 26 years, ant. chest
16. Female, 30 years, post. chest
17. Male, 47 years, post. chest
18. Female, 30 years, lower abdomen

All the skins used in this experiment were ones previously ascertained to be active for 3β HSD with DHA as steroid substrate.

RESULTS

I Histochemical Methods

The results are shown graphically in Figures 16 - 22 and in Tables 1 and 2.

Figure

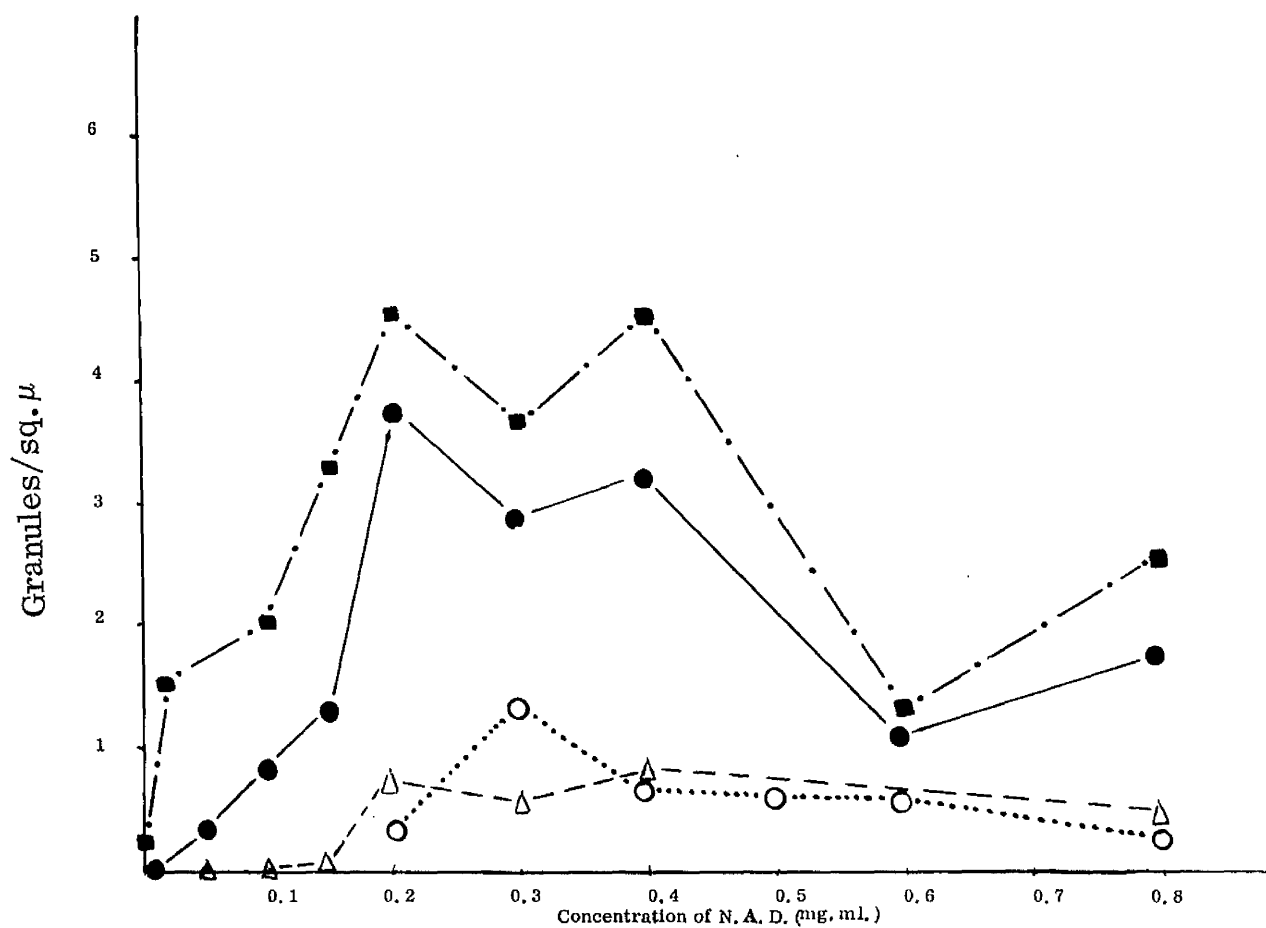
16. Effect of NAD concentration on HSD activity
17. Effect of DHA concentration on HSD activity
18. Effect of Mg on HSD activity
19. Effect of nicotinamide on HSD activity
20. Effect of Vitamin K on HSD activity
21. Time course of HSD activity
22. Longer time course of HSD activity

- (i) Concentration curves carried out on several skin samples were set up to establish the optimum concentration of NAD and DHA in the incubation medium for histochemical studies on 3β HSD (Figures 12 and 14).

The granules were counted by means of the Wild M20 microscope in the method described and the results plotted against concentration of the one varying constituent in the otherwise constant incubation medium.

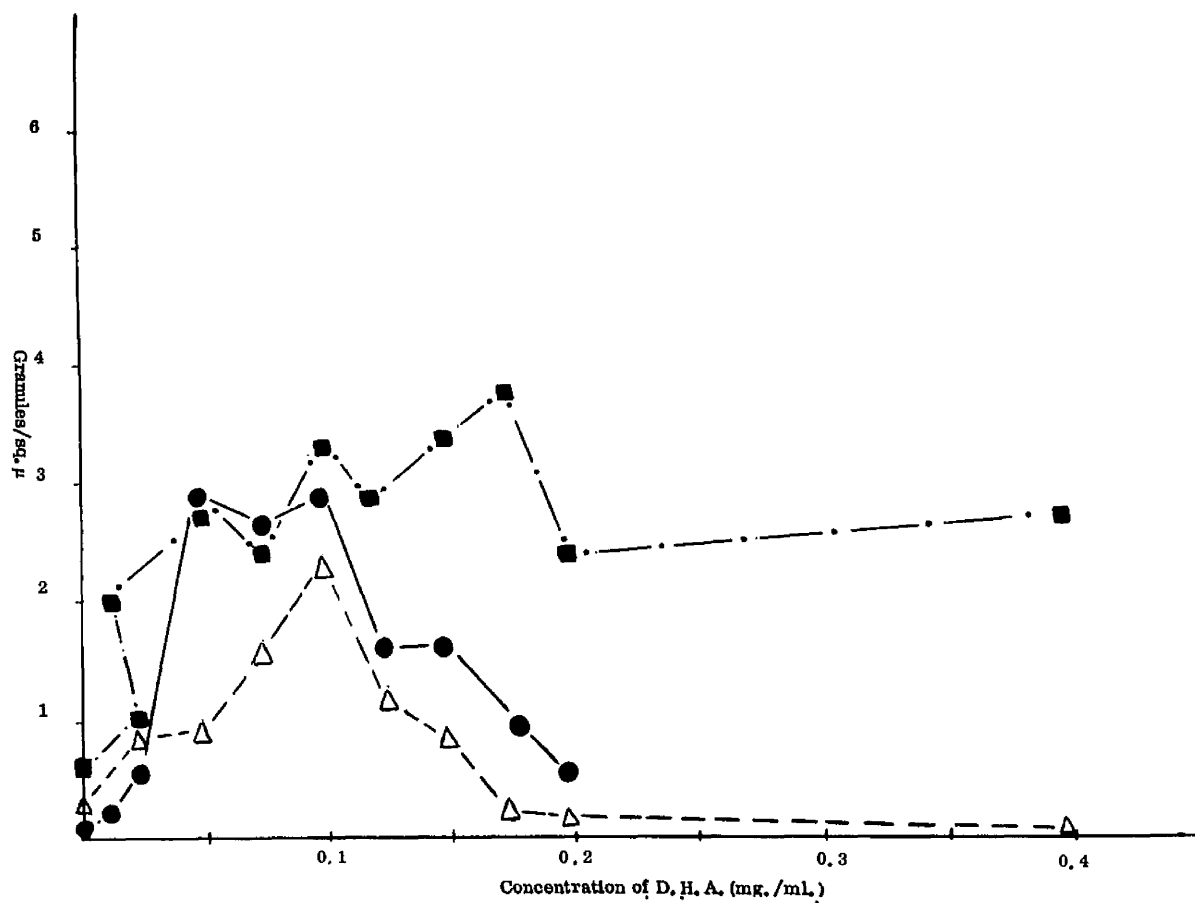
(ii/

Figure 16 NAD concentration curve



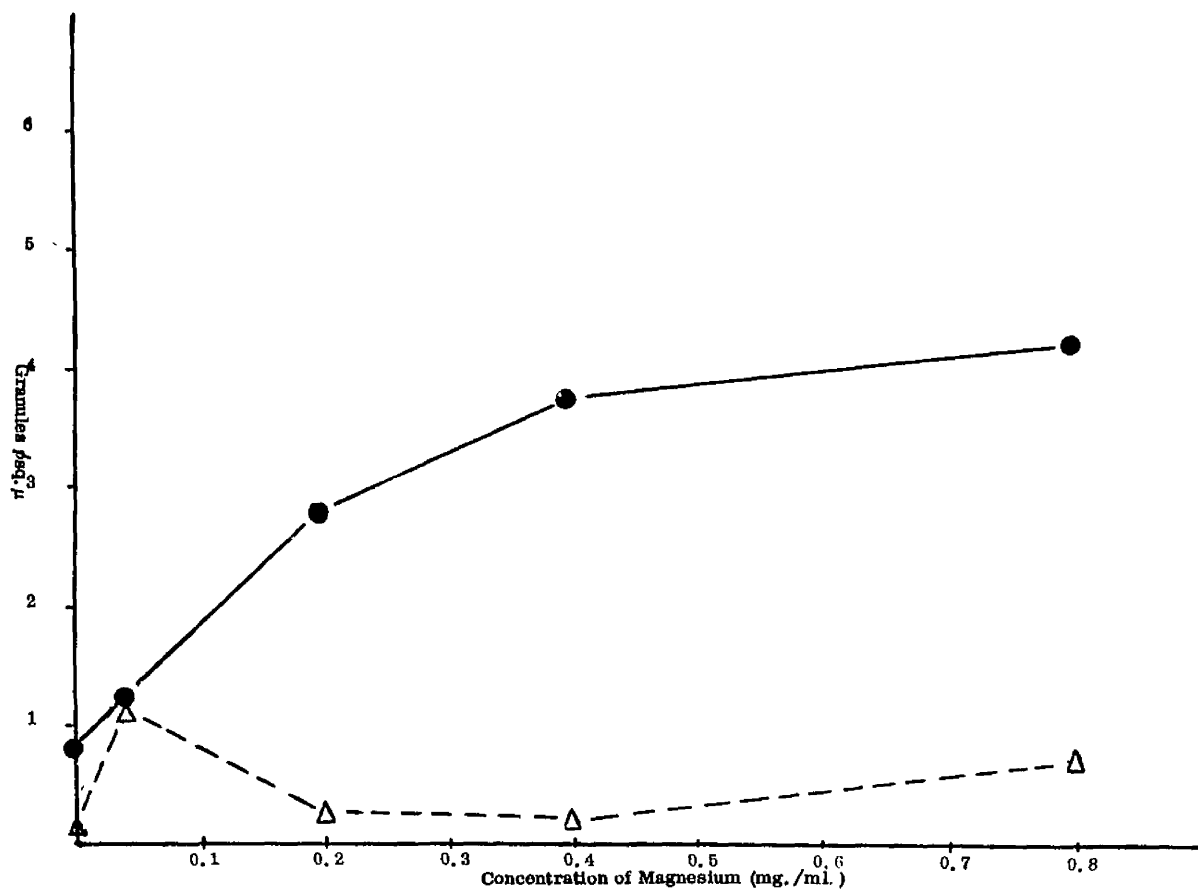
The symbols on the figure represent different runs of the experiment

Figure 17 DHA concentration curve



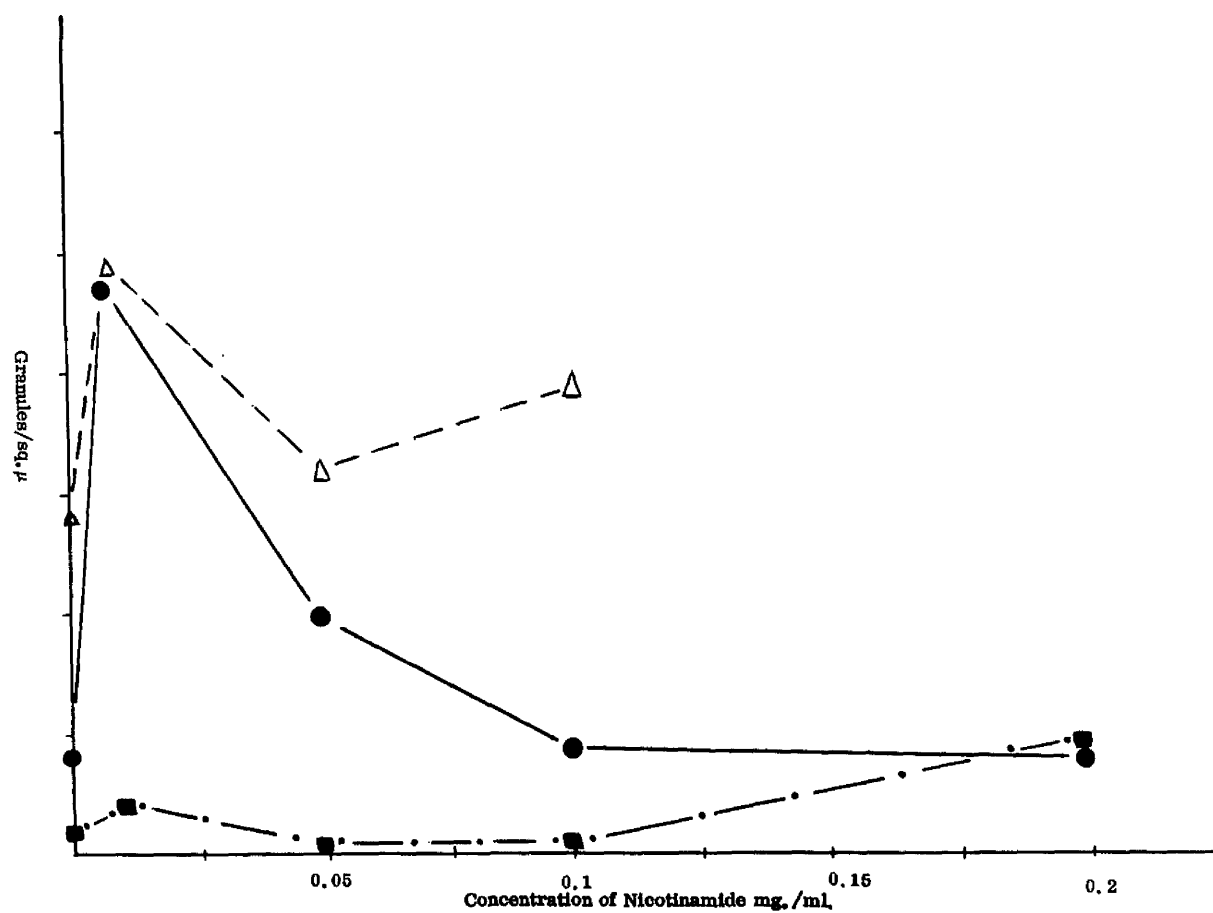
The symbols on the figure represent different runs of the experiment

Figure 18 Effect of magnesium



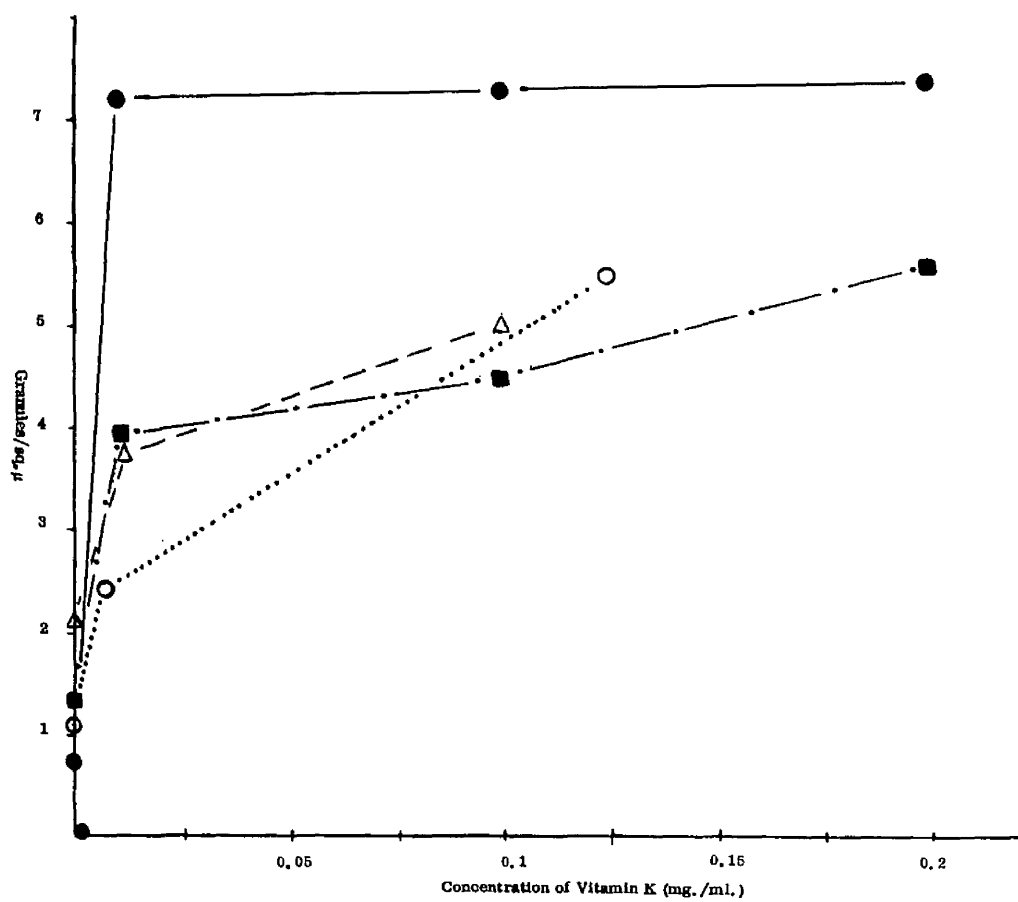
The symbols on the figure represent different runs of the experiment

Figure 19 Effect of Nicotinamide



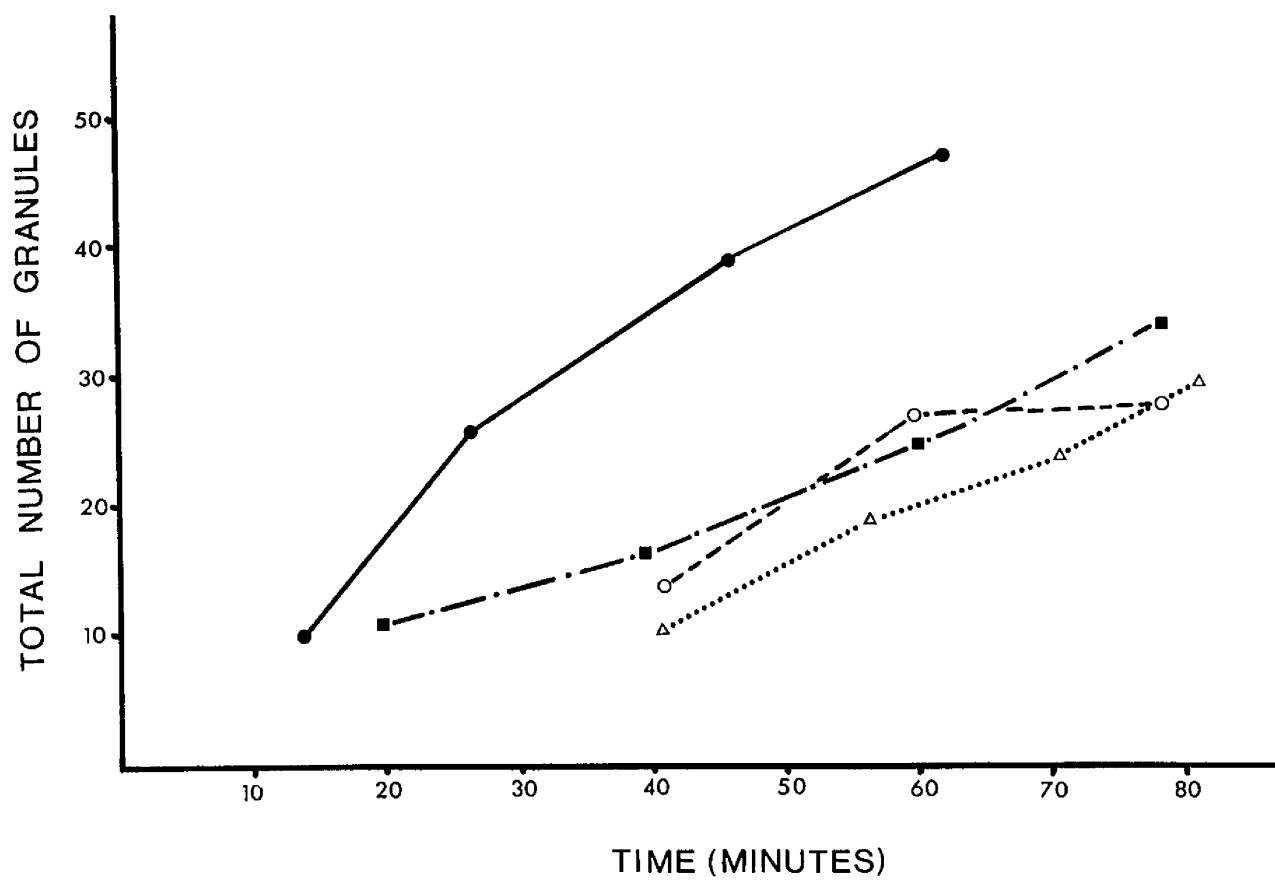
The symbols on the figure represent different runs of the experiment

Figure 20 Effect of Vitamin K



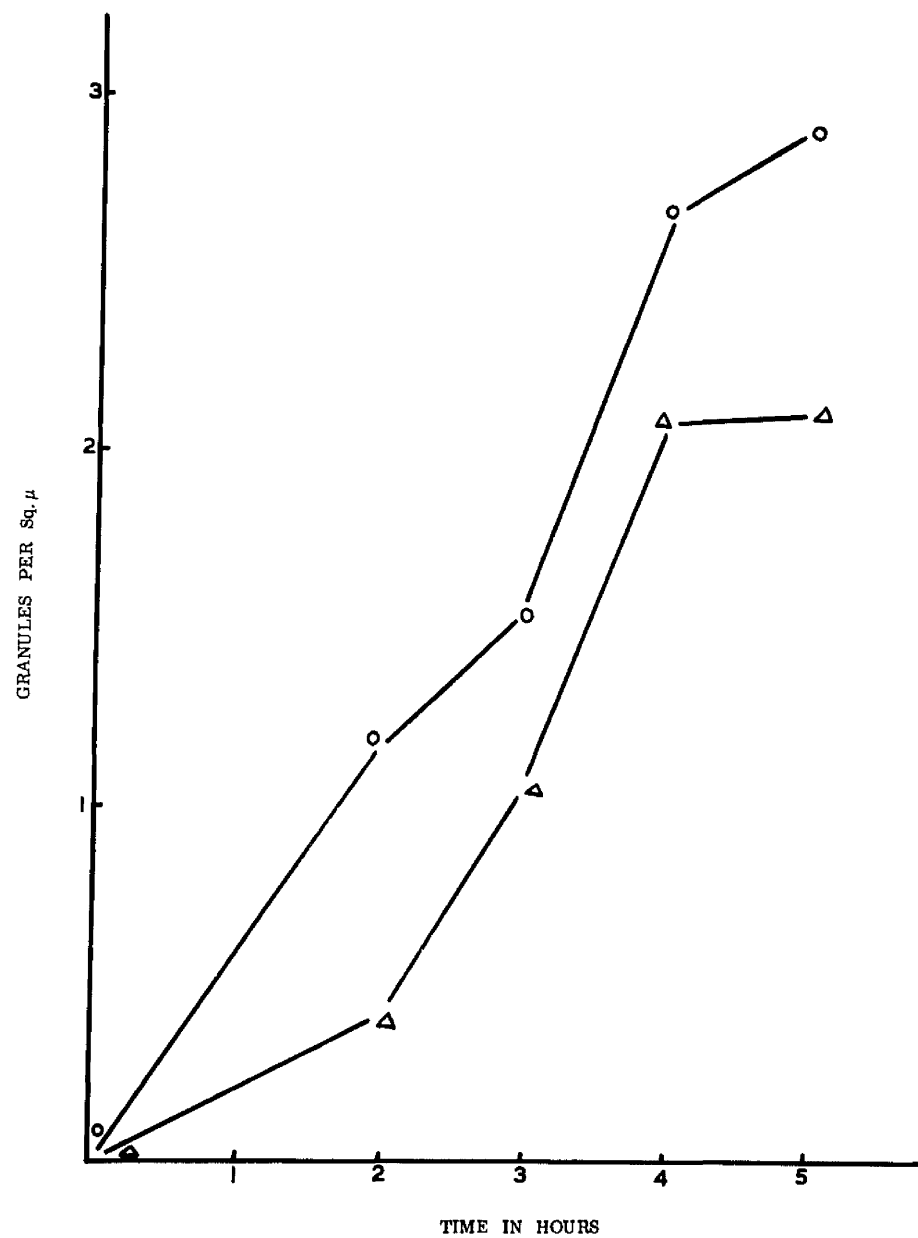
The symbols on the figure represent different runs of the experiment

Figure 21 Time course of reaction (a)



The symbols on the figure represent different runs of the experiment

Figure 22 Time course of reaction (b)



The symbols on the figure represent different runs of the experiment

- (ii) The effect of substances thought to be possible co-factors in the steroid dehydrogenase reaction is shown in Figure 18 (Magnesium) Figure 19 (Nicotinamide) and Figure 20 (Vitamin K). These results were obtained also by the method employing the Wild M20 microscope.
- (iii) The time course of the incubation reaction is shown in the graphs a) and b) depicting
$$\frac{\text{Total number of granules}}{\text{Time of incubation (in mins.)}}$$
 (Figures 21 and 22)

To investigate the progress of the reaction with time, sections were incubated on a projection microscope within an incubating oven at 37°C and the number of granules within a high power field were counted at set intervals of time.

This method was found to be practical for a limited time of incubation - until after approximately 45 minutes of incubation it becomes difficult due to the blotting out effect of the granules (Figure 21). Longer terms of incubation were carried out in another series of experiments by the routine method, the reaction being stopped at set intervals of time and the intensity of reaction estimated by the Wild M20 method. The times of incubation were 30, 60, 120, 150, and 180 minutes. The effect is shown in Figure 22. The reaction levels off at 2 hours.

(iv/

(iv) The effect of temperature was studied by -

- (a) carrying out the incubations simultaneously on consecutive sections on skin in four different ovens (20°C , 30°C , 37°C , 50°C)
- (b) the effect of temperature on the 3β HSD enzyme was also studied by preheating consecutive skin sections for 15, 20 or 30 minutes in ovens set at 60°C , 80°C , 100°C and 160°C followed by routine incubation for 3β HSD.

The results indicate that -

1. the course of the enzyme reaction is very little affected by the temperature of incubation, the activity being approximately the same at the various temperatures of incubation in the case of three skin samples studied.
2. the enzyme is very heat - stable. After preheating for 30 minutes at 160°C the histochemical reaction is still positive. This heat - resistance, in dry heat, was noted for 3β , 16β and 17β steroid dehydrogenase which were studied in different skin samples.

(v/

- (v) The effects of some substances thought to be possible inhibitors are shown in Table 1.

Quinestradol appears to have no inhibitory effect on the steroid dehydrogenases except in some of the skins studied when it does inhibit 3β HSD.

The antiandrogens, cyproterone and cyproterone acetate which are among the most potent of the antiandrogens so far produced, show a strong inhibitory effect on 3β and 16β HSD enzymes in all the skin samples tested, but not in all cases on the 17β HSD.

- (vi) Effect of preincubation in buffer on several hydroxysteroid dehydrogenases is summed up in Table 2.

To determine the extent to which the HSD enzymes are extracted out of the tissue section into a buffer solution, two consecutive sections were assayed for 3β HSD. The first control was subject to the routine incubation of 3β HSD but the second was preincubated in the buffer for ten minutes. The experiment was repeated with oestradiol, testosterone and androsten - 3β - 16β diol-3 methyl ether as substrates.

The results (shown in Table 2) indicate that all the steroid dehydrogenases studied with the exception of 16β -dehydrogenase, readily diffuse out from tissue sections.

Table 1 Histochemical assays using inhibitors in the
incubation medium

	<u>Control</u>	<u>Quinestradiol</u>	<u>Cyproterone</u>	<u>Cyproterone Acetate</u>
Testosterone	+	+	+	+
16 β	+	+	-	-
Oestradiol	+	+	-	+
DHA	+	+	-	-
Control	-	-	-	-

(+) granules present

(-) granules absent

Table 2 Effect of preincubation in Buffer on several HSDs

	<u>Control (no steroid)</u>	<u>DHA</u>	<u>Oestradiol</u>	<u>Testosterone</u>	<u>16β</u>
No preincubation	-	+	+	+	+
Preincubation	-	-	-	-	+

(+) granules present

(-) granules absent

Methods of incubation

The four methods of incubation described are illustrated diagrammatically in Figure 12.

The advantages and disadvantages of these various techniques are listed in Table 3.

The method finally adopted, method 5 (see Figure 13) consisted of an adaptation of method (i). The coverslips with attached tissue sections were placed on a double layer of filter paper on a perspex tray fitted with an air tight lid. The coverslips are covered with a meniscus of incubating solution and the lid of the box replaced gently. Wet swabs of cotton wool are placed in the box. The evaporation of the incubating medium is thus reduced to a minimum.

The method is easy to use, quick to set up and allows for clear labelling of a large number of sections incubated - with pencil on the filter-paper, as illustrated in Figure 13.

Counterstaining

Different methods of staining were assessed for quality of tissue definition and for the effect on the diformazan granules. The staining method finally adopted is shown in Figure 23.

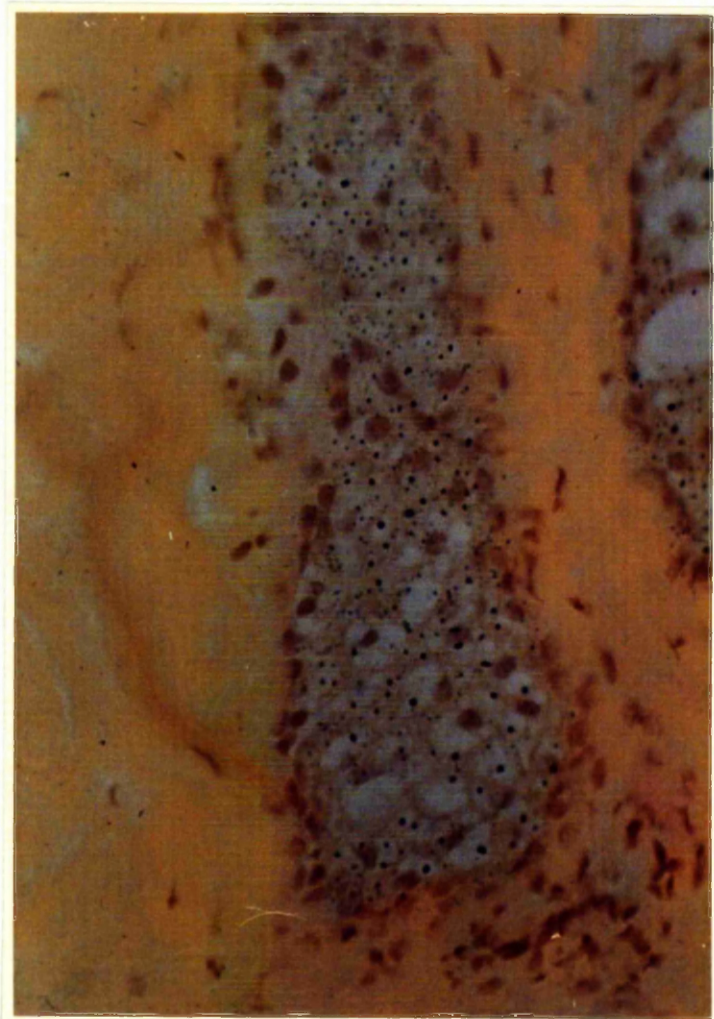
Using the semiquantitative method for granule estimation, the effect of fading or removal of diformazan particles was examined.

Consecutive/

Table 3 Advantages and disadvantages associated
with various methods of incubation

<u>Method</u>	<u>Advantages</u>	<u>Disadvantages</u>
1	Easiest to use	Inaccurate because of loss by evaporation of solvent
2	Small amount of incubation medium used	Difficulty in cutting cover- slips
3	Ease of use, small amount of reaction mixture	Difficulty in recovering reaction medium
4	Reaction conditions stabilised. Easy to recover reaction medium	Initial preparation of test- tube ends
5	Easy to use, over- comes problem of evaporation	

Figure 23 Skin section counterstained following incubation
showing the deposition of diformazan granules
in the sebaceous gland



(x275)

Consecutive skin sections which were -

- (a) unstained
- (b) stained by the method described and examined immediately
- (c) stained and examined after a few days

were subjected to the semiquantitative estimation (using the Wild M20 microscope) to compare the granule deposition. Statistical analysis of the results in Table 4 shows that the staining did not cause any extraction of the granules, and the counterstaining technique enhances the ease with which the granules can be observed and counted.

II Semiquantitation

Two main types of methods of estimating enzyme activity of skin samples were considered -

- A. Histochemical method of granule counting
- B. Fluorimetric method of estimation of reaction product (by measuring NADH formed)

A. Granule Counting

The preparation of skin sections by histochemical methods involving the deposition of diformazan granules in the sebaceous glands has been described. Methods of estimating the enzymic activity by this procedure involve granule - counting. Four methods of granule counting were attempted and these attempts were described in the methods section.

(a)/

Table 4 Comparison of numbers of granules/sq. μ in
 stained and unstained sections

	<u>Unstained section</u>	<u>Stained section</u>
1.	1.18	1.33
2.	1.70	2.20
3.	0.84	1.02
4.	3.39	3.48
5.	3.1	5.6
6.	4.96	5.06
7.	2.13	3.18
8.	1.70	1.73
9.	2.50	2.67
10.	0.96	1.8

(a) The counting of granules on a projection screen was found to be unsuccessful because -

1. only a few consecutive sections can be considered
2. the method is complicated and laborious
3. the projected picture is not clear, granules and particles of dirt are indistinguishable
4. granule deposition after more than 30 mins. of incubation appears blotted, granule superimposition making the reading of results unreliable. Thus granule estimation at the optimum time of incubation when the granule deposition curve/time begins to level off, is impossible to achieve by this method. This method was therefore abandoned.

(b) Scanning microdensitometer - This method does not:

- a) distinguish between granules of different sizes
- b) record in depth but only in the microscopic field set in focus.
- c) distinguish between formazan granules, dirt particles or the dense nuclei of cells, cell partitions etc.

In/

In the case of the more sophisticated scanning and integrating microdensitometer which was tried in these investigations, the first of the above problems a), is overcome, mainly the apparatus can be set to read granules of different sizes. At the time these assays were done (1966-1967) there was no other apparatus of this sort which could get over the other two shortcomings of the method (b) and c)). This method was therefore found to be unsatisfactory and was abandoned. (further developments in this field are described in Discussion).

(c) The Wild M20 microscope method gave good results. The following experiments were carried out to ensure that the method is statistically valid.

(i) To establish validity of one observer counting, one microscopic field, ten different microscopic fields, (a - j) were counted anything from seven to ten times. These counts were not carried out successively at the one time, but were done at random at various times. Thus on one day fields a, c, f, g and h might be counted, on the next day b, d, e, i and j, the following day b, c, e and f being counted for the second time and so on until sufficient data could be carried out to draw up Table 5 in which the values represent granules/sq. μ .

Using the Bartlett test of **homogeneity** of variance, there is evidence for significant **heterogeneity** at the 5% level of significance. This/

Table 5 Table of variation of one field counted by one
observer ten times

(a)	(b)	(c)	(d)	(e)	(f)	(g)	(h)	(i)	(j)
2.05	1.96	1.75	3.10	2.7	1.2	6.9	4.9	6.6	6.3
2.08	1.73	1.72	3.60	2.62	1.42	6.9	4.2	6.68	6.54
2.02	1.87	1.84	3.75	2.80	1.42	6.5	4.7	6.88	6.6
2.05	2.05	1.10	3.84	2.97	1.48	6.3	4.3	6.0	6.5
1.98	2.02	1.60	3.85	2.89	1.37	6.9	4.6	6.8	6.15
1.97	2.06	1.38	3.75	3.00	1.38	6.6	4.5	6.45	6.7
1.85	1.89	1.67	3.95	3.10	1.42	6.2	4.57	6.56	6.18
2.14	1.82	1.50	-	3.07	1.44	6.5	4.25	6.25	6.45
2.19	1.88	1.76	-	-	1.24	6.5	4.67	6.64	6.37
2.28	1.50	1.74	-	-	1.46	6.8	4.48	6.4	6.5

This evidence of variability of determinations from field to field means that some care must be taken in specifying the differences in determinations which might be regarded as representing a significant difference in activity. It is statistically acceptable to use the highest sample variance (0.07985) instead of the pooled variances of the samples (0.04162). On this basis a difference of 0.80 in two determinations would be regarded as evidence of significant difference in the two activities. (The corresponding difference based on the pooled variance is 0.58)

(ii) Variation between two observers counting one field - Two observers X and Y were involved. Five different fields (A - E) were considered, each one being counted three times by each observer. The results are shown in Table 6.

By a standard analysis of variance there is evidence of significant observer - field interaction at the 5% level. This indicates that with the present technique it is certainly inadvisable to allow comparisons of fields made by different observers.

(iii) Variation between serial sections of the same gland - Analysis/

Table 6 Table of variation between two observers (X and Y)

	<u>X</u>	<u>Y</u>
<u>A</u>	1.98	2.68
	1.87	2.66
	1.86	2.68
<u>B</u>	1.22	1.65
	1.40	1.57
	1.20	1.68
<u>C</u>	1.16	1.14
	1.11	1.23
	1.21	1.14
<u>D</u>	1.27	1.57
	1.35	1.65
	1.46	1.45
<u>E</u>	0.98	0.79
	0.90	0.93
	0.99	0.75

Analysis of variance on 5 series of readings of 10 consecutive sections of sebaceous gland shows no significant difference.

The evidence for this analysis was extracted from the 3 skins considered in the Table "Variation in counting one microscope field by one observer" (Table 5)

From all these statistical analysis in the data accumulated by means of the Wild M20 microscope estimation technique, it can be concluded that the method is satisfactory only -

- (1) as practiced by a single observer in a set of readings
- (2) if great care is taken by the person who carries out these estimations.

The method relies very much on the individual using it. This is in fact its greatest drawback. Eye-strain on the part of the observer, tiredness or hurry can give unreliable results.

Distribution of diformazan granules in the sebaceous gland can be traced from the projection in the Wild microscope technique and such a diagrammatic representation is shown in Figure 9. This granule deposition reflects enzyme distribution in the sebaceous gland as previously explained in the Introduction.

The/

The distribution of granules shown in Figure 9 is characteristic of 3β HSD distribution in a sebaceous gland. It was found that the distribution of 3β HSD and 16β HSD enzymes in the gland varies from the distribution of 17β HSD in the sebaceous gland and this is illustrated in Figure 24 and Figure 25. Two photographs are shown. These represent consecutive sections incubated by the usual histochemical method with a) DHA to show the distribution of 3β HSD (Figure 24) and b) Testosterone to show the distribution of 17β HSD (Figure 25) in the sebaceous gland of human skin. As will be seen 3β and 16β HSD appear to be distributed throughout the sebaceous gland more intensely around the periphery. 17β HSD shows small pockets of activity within the sebaceous gland.

B. Other methods of quantitation of the enzymic reaction

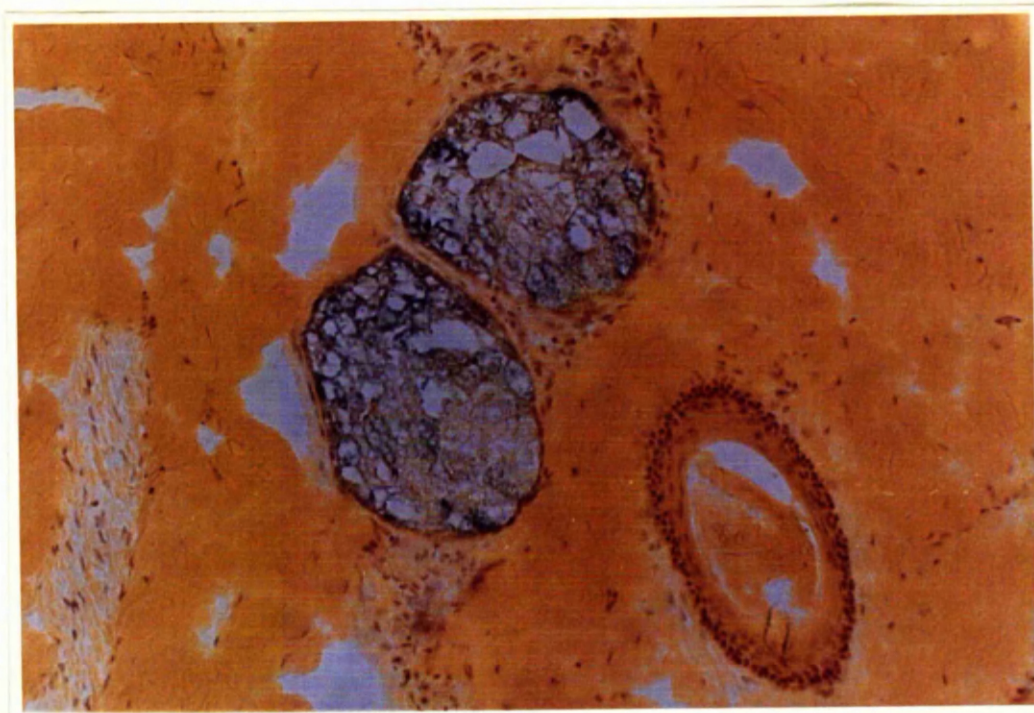
(a) Spectrophotometric trials - Spectrophotometric methods were assayed with the purpose of quantitating dehydrogenase activity in skin sections. Two methods of approach were considered:

- (i) elutions
- (ii) spectrophotometric reading (colorimetric estimation) of colour development in skin sections incubated by the usual method and placed directly in the light beam of a spectrophotometer.

In both these assays there was no measurable difference in colour intensity between test and control.

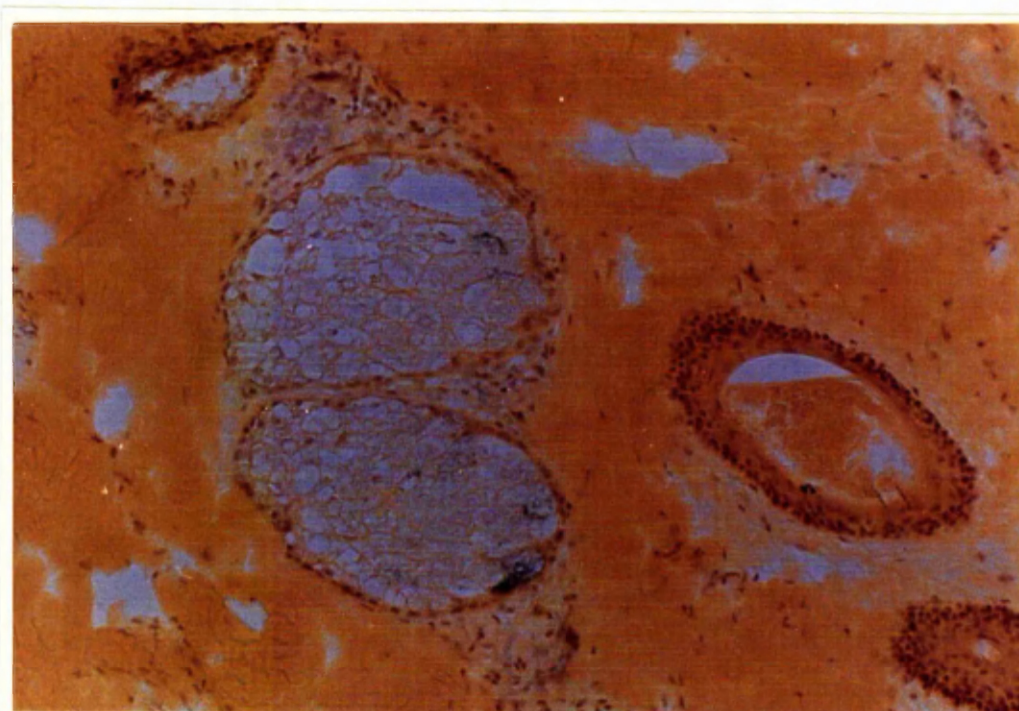
As/

Figure 24 Distribution of 3β HSD in the sebaceous
gland of human skin



(x 240)

Figure 25 Distribution of 17β HSD in the sebaceous
gland of human skin



(x 240)

As a positive control lactic dehydrogenase in liver sections gave readings of sufficient value to be significant.

Spectrophotometric assays of this nature measure in principle the intensity of colour formed. Histochemical studies on skin sections reveal however two distinct and different colour reactions. The one we are interested in measuring is the deposition of blue diformazan particles in the sebaceous gland of skin in the presence of intrinsic steroid dehydrogenase and added steroid. This colour reaction is masked in spectrophotometric measurements by the stronger non-enzymic reduction of nitro BT in the hair-shaft of the skin sections. This interference of the hair-shaft reaction makes spectrophotometric estimations on whole sections of skin impossible. To overcome this effect, one would need to be rid of the staining of the hair-shaft or dissect out the sebaceous gland from the skin section prior to incubation.

Further experimental work was undertaken (see Iodoacetate Assays) in an effort to overcome this problem.

(b) Fluorimetric estimations - Three different skin samples were assayed by means of the Aminco Bowman spectrophotofluoremeter (shown in Figure 16). The results are shown on Table 7.

In each of the three experiments the results give at least 100% higher readings in the test than in either of the controls.

(Test/

Table 7 Fluorimetric estimations of NADH

	Fluorimetric readings		
	Skin		
	<u>Sample I</u>	<u>II</u>	<u>III</u>
1. Normal 3β HSD + skin incubation	0.085	0.089	0.21
2. Control A (no steroid) + skin	0.045	0.040	0.05
3. Control B (no NAD) + skin	0.045	0.045	0.07
4. Normal incubation medium <u>no skin</u>	0.015	0.02	0.018
5. NAD solution (5 mg./10 ml. buffer)	0.015	0.02	0.01
6. NADH solution (0.5 mg./10 ml. buffer)	0.65	0.64	0.62
7. NADH solution (0.05 mg./10 ml. buffer)	0.095	0.09	0.092
8. NADH solution (0.005 mg./10 ml. buffer)	0.02	0.02	0.02
9. NADH solution (0.0005 mg./10 ml. buffer)	0.005	0.005	0.005
10. NADH solution (0.00005 mg./10 ml. buffer)	0.005	0.005	0.005

(Test: skin sections + normal 3β HSD incubating medium - Control A: skin sections + incubating medium lacking steroid base - Control B: skin sections + incubating medium lacking NAD)

An additional control in which normal 3β HSD incubating medium is incubated without skin and read on the fluorimeter gives even lower results than the previously described controls A and B.

NAD solution alone (in buffer) gives equally low readings. NADH solution alone (in buffer) gives readings higher than the skin test incubation for high concentration of NADH (0.5 mg./10 ml. buffer), and approximately the same readings for concentration of 0.05 mg. NADH/10 ml. buffer.

III Survey of Distribution

The results of the survey are summarised in Tables 8 - 12.

Table 8 shows the distribution of the skin samples among male and female subjects and age grouping. In all 136 patients are listed. The survey as mentioned involved 180 skin samples. The discrepancy in the numbers is due to the fact that in some cases two skin biopsies were taken from the one patient, as for example during thoracic surgery when skin samples from the anterior thoracic and from the upper abdominal regions were obtained.
Only/

Table 8 Age and sex distribution of specimens

Total number of specimens 136 - Males 81, Females 55

<u>Age</u>	<u>Male</u>	<u>Female</u>	<u>Total</u>
0-10 years	7	1	8
11-20 "	6	6	12
21-30 "	14	9	23
31-40 "	16	19	35
41-50 "	13	6	19
51-60 "	14	10	24
61 + "	11	4	15

Table 9 Distribution of sebaceous glands in different
regions of the body

Total number of specimens 180

	<u>Sebaceous glands present</u>	<u>Sebaceous glands absent</u>	<u>Total</u>	<u>%</u>
Face and neck	17	1	18	95
Scalp	13	1	14	93
Anterior chest	25	12	37	68
Posterior chest	23	10	33	70
Upper abdomen	10	9	19	53
Lower abdomen	10	6	16	63
Leg	13	13	26	50
Arm	12	5	17	71

X^2 statistical analysis shows a significant difference at the
1% level in the distribution of sebaceous glands.

Table 10 Age distribution of 3β HSD activity

	<u>3β+</u>	<u>Total number of skins</u>	<u>%</u>
0-10 years	5	8	63
11-20 "	9	12	75
21-30 "	23	23	100
31-40 "	26	35	74
41-50 "	26	35	74
51-60 "	17	19	90
61 + "	11	15	73

Table 11 Sex distribution

	<u>Number of active skins</u>	<u>Total number of skins tested</u>	<u>%</u>
Male	64	81	79
Female	42	55	77

X^2 test shows no significant difference

Table 12 Enzyme activity associated with body area of skin

	<u>Number of active skins</u>	<u>Total number of skins tested</u>	<u>%</u>
Face and neck	16	17	94
Scalp	12	13	83
Anterior chest	19	25	76
Posterior chest	16	23	70
Upper abdomen	9	10	90
Lower abdomen	8	10	80
Leg	10	12	84
Arm	7	12	58

Only one patient is listed in the female cases of 0-10 years age group, but in the other groups, numbers sufficient to constitute the basis of statistical enquiries were assembled over a period of two years.

Table 9 sets out the distribution of sebaceous glands in different regions of the body. Each skin sample was histologically examined for the presence of sebaceous glands. When these were not found on initial examination the skin sample was cut further in, if necessary right through the sample and every 10th section examined after a brief haematoxylin - eosin staining to facilitate microscopic examination of the skin sections. X^2 statistical analysis shows a significant difference at the 1% level in the distribution of sebaceous glands. It appears from this Table that sebaceous glands are most densely distributed in the face and neck region (were over 95% of skin samples show the presence of sebaceous glands) as well as in the scalp region. It is in fact in the skin of the head that the large follicular acini of sebaceous glands are known to be found. Only two skin samples from this region showed a total absence of sebaceous glands and in those two cases the biopsies available were very small, being of the order of a few square mm. Next in the order of sebaceous gland distribution is the skin of the chest (anterior and posterior) and that of the arm. The lowest figures (in the region of 50-60%) were obtained for the skin of the abdominal region (upper and lower) and the skin covering the legs.

Table 10 sets out enzyme activity related to age and the results are represented/

represented as a percentage of the number of active skins over the total number of skins tested. It is noted that all the skins in the 21 - 30 year age group are positive for 3β HSD activity with lower figures in the other age groups.

Table 11 compares the number of active skins per total number of skins tested in males and females. There is no significant difference in 3β HSD activity in males and females as tested statistically by the X^2 test from these results.

Finally in Table 12 are represented the figures for enzyme activity in the sebaceous glands of skin from different areas of the body, these being given as percentages of the number of active skins per total number of skins tested.

From this Table it appears that the area of highest 3β HSD activity (giving the number of active skins over the total number of skins tested as 94%) is the face and neck region.

IV Experimental Animal Studies

(1.) Mouse skin did not give very good results. The sebaceous glands do not show a strong HSD reaction for any of the four steroid bases used, the glands are small and the dark staining of the hair shafts masks the weak reaction of the glands.

Genetically/

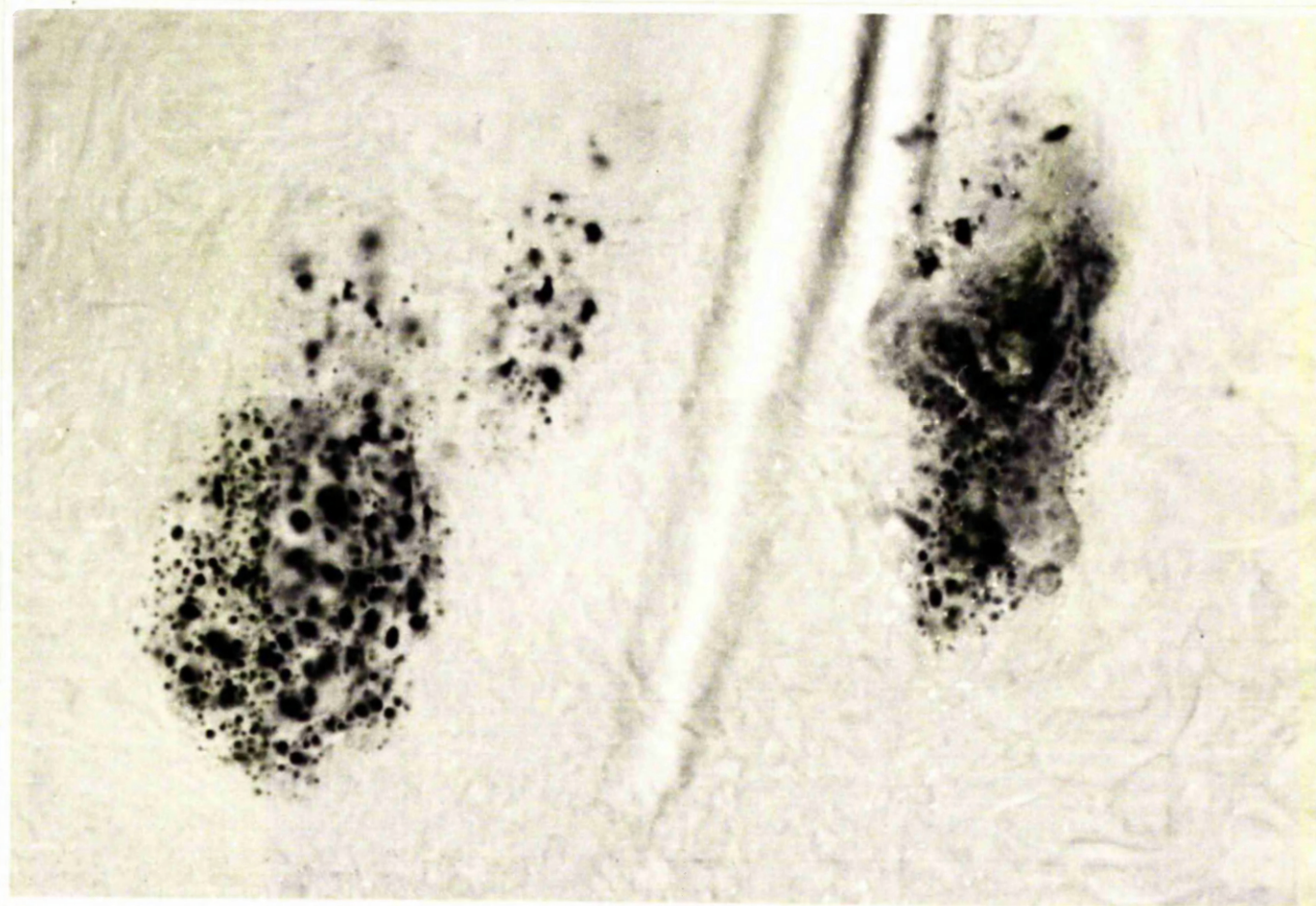
Genetically hairless mice were used in an attempt to overcome the problem of the hair-shaft reaction. It was found however that in the skin of the hairless mouse the sebaceous glands are strongly keratinized and quite insignificant for histochemical investigations.

(2.) Rat skin shows small but distinct sebaceous glands (Figure 26) which give good positive reaction for 3β and 16β HSD. 17β HSD can be shown when Oestradiol is used as the steroid base but very weak reaction appears when Testosterone is used. The presence of HSD in the rat was first made obvious in the presence of PVP in the incubating medium. After repeated experimentation on animal skin material which it was found needs much more careful handling than human skin, it was possible to get consistently good results even in the absence of PVP.

Rat preputial gland showed very good positive results for 3β and 16β HSD (Figure 27). Only some samples showed 17β HSD activity. Again as with rat skin these results were first obtained in the presence of PVP and later, almost as strongly, in the absence of PVP.

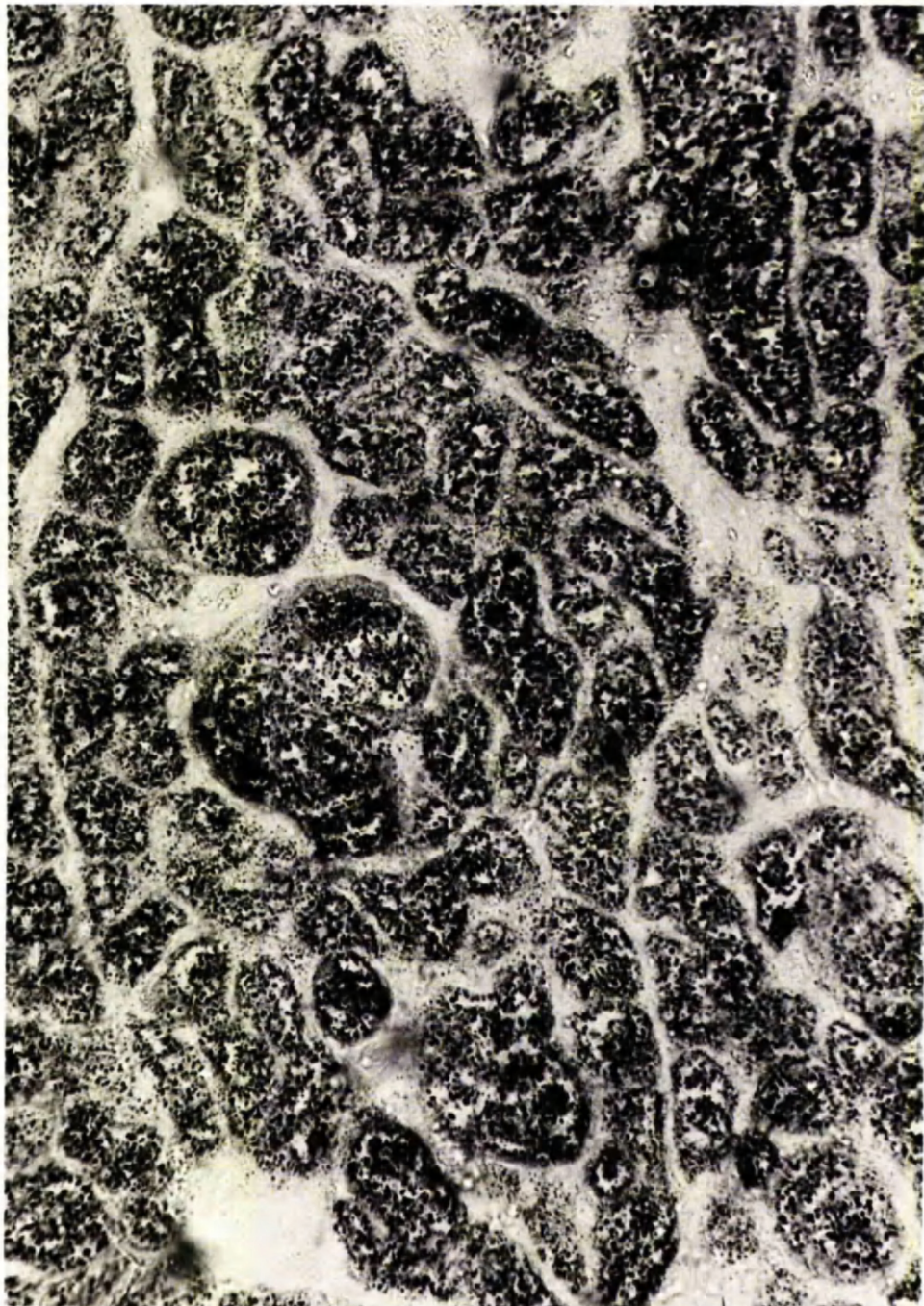
(3.) Gerbil skin does not provide good histological material for sebaceous gland studies. The sebaceous glands are small, and the presence of hair causes a problem as described previously. No reaction was observed. Gerbil territorial marking provides very good material with large well-defined and numerous sebaceous glands. However, it was found that only one out of 6 - 8 sebaceous glands showed a positive HSD reaction, stronger for 3β and 16β than for 17β HSD. A/

Figure 26 Rat skin showing 3β HSD activity in
sebacaceous glands



(x 240)

Figure 27 Rat preputial gland showing 3β HSD activity



($\times 175$)

150.

A series of experiments were designed to overcome this disappointing picture. It was felt that gerbil territorial marking would constitute excellent working material in androgen assays related to sebaceous gland activity. The territorial marking is so well defined and large, especially in the male. The gerbil is one of the more agreeable laboratory animals and many weeks were spent in attempting to overcome the inexplicable failure to achieve a clear cut result. But neither the variation of time or temperature of incubation, nor the variation of the concentration of different constituents of medium, nor yet the addition of PVP changed in any degree, the basic observation that only one of 6 - 8 sebaceous glands are positive, and even that not consistently so in all animals examined. However, even these results were at the time considered of value and a series of experiments were carried out using the territorial marking of gerbil in an attempt to follow the effect of different androgenic steroids on sebaceous glands HSD activity (see Gerbil Experiments section)

(4.) Guinea pig skin does not show very good results. The sebaceous glands are small and only very weak activity was noted within.

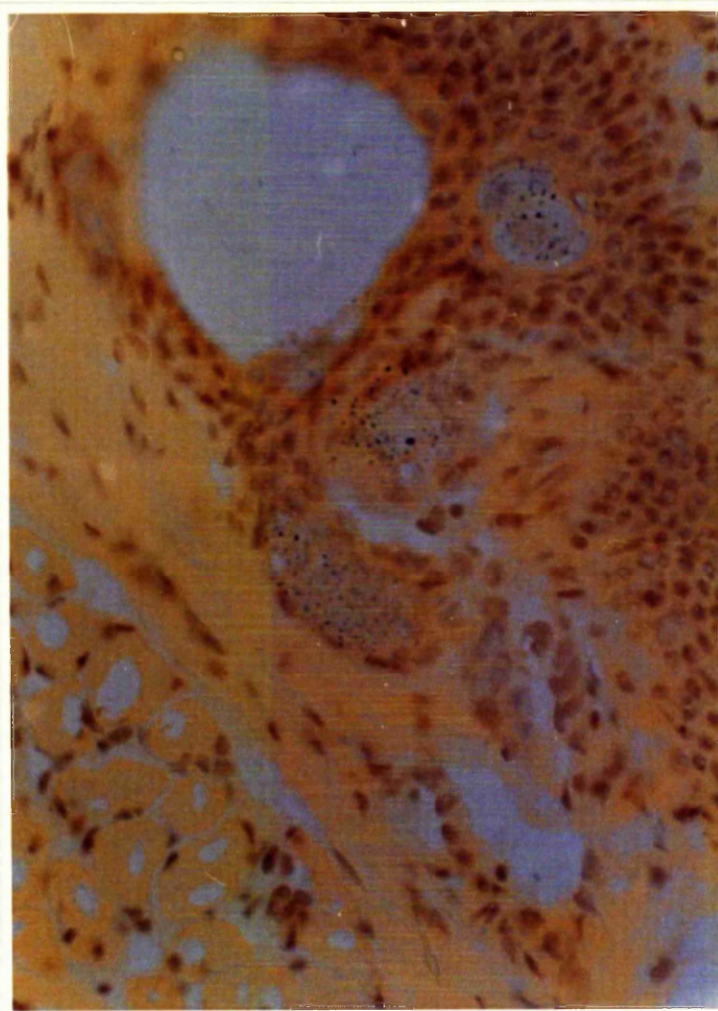
Guinea pig lip was found to provide very suitable histological material showing well differentiated sebaceous glands and good activity for all the steroids tested (Figure 28).

(5.) Syrian hamster skin sections show small sebaceous glands of indifferent HSD activity and similarly to the skins of mouse, guinea pig and gerbil described above were not thought to constitute suitable material for further histochemical investigations.

Syrian/

Figure 28

Guinea pig lip skin section showing 3β HSD
activity in the sebaceous glands



($\times 175$)

137.

Syrian hamster costovertebral organs are rich in large well defined sebaceous glands, which show granule deposition with PVP. It was observed however that in incubations with PVP, controls came up positive as well. In PVP prewashed runs, the controls are negative but the test granule deposition is very weak, so as to be almost insignificant. This problem is further considered in the special section on Syrian hamster as the costovertebral organ was adopted as experimental material in a series of further experiments.

A series of experiments carried out with the aim of improving the histochemical demonstration of HSD activity in animal tissues, gave the following results -

1. Variations of concentrations of steroid substrate or NAD co-factors did not alter the results.
2. Varying the time and temperature of incubation did not improve the results.
3. Using NADP instead of NAD ad co-factors did not alter the results. (Table 16)
4. The use of PVP in the incubating medium gave rise to the first positive histochemical results in animal tissues (rat skin) and thereafter with careful attention to detail the technique was successful even in the absence of PVP.

Gerbil experiments were undertaken before the finding of more suitable experimental animals (rat and hamster) came to light.

The/

The only results which can be unhesitatingly given from these two series of experiments are:-

1. The size of the glandular pad increases in the animals which have undergone treatment with androgens.
2. The relative size of the sebaceous glands in the glandular pad increases greatly in animals which have undergone treatment with androgens. (Figures 29 and 30)

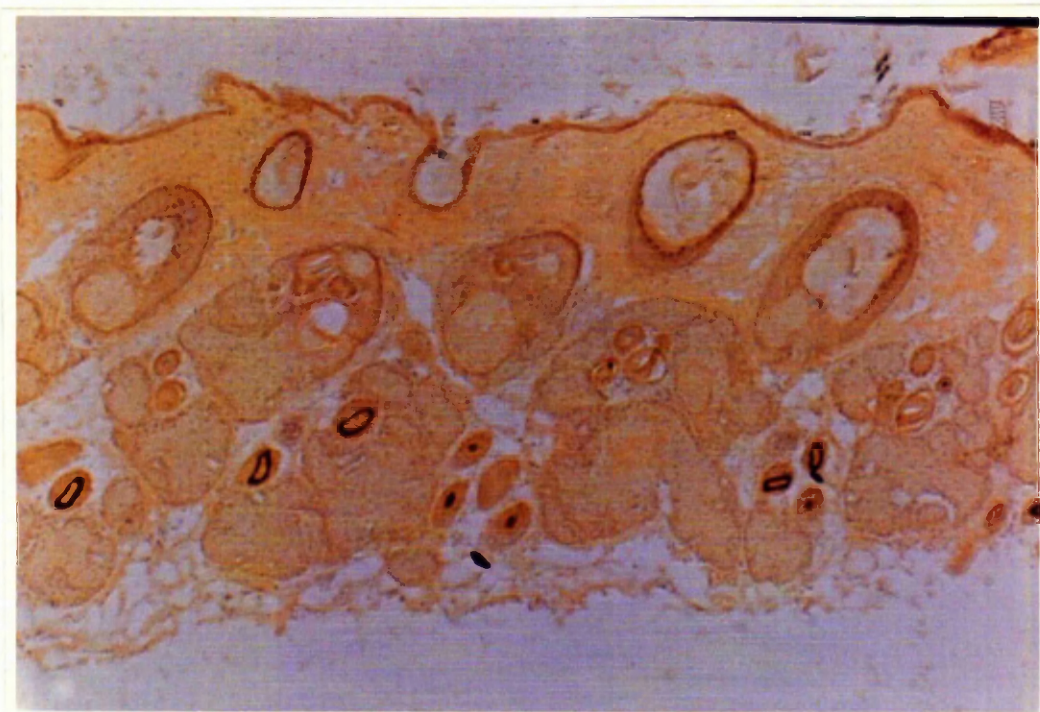There appears to be strong HSD activity in histochemical assays on androgen-treated animals but as this activity continues to show the pattern described earlier, namely that only one in 6 - 8 sebaceous glands shows activity and as after treatment the appearance of the glandular pad sections is so altered that comparative quantitation is difficult, this series of experiments is unfortunately inconclusive.

Results of Syrian hamster experiments are shown in Table 13. These results show:-

1. The effect on C.V.O. size
2. The effect on individual sebaceous gland size in the C.V.O.
3. The effect on HSD activity

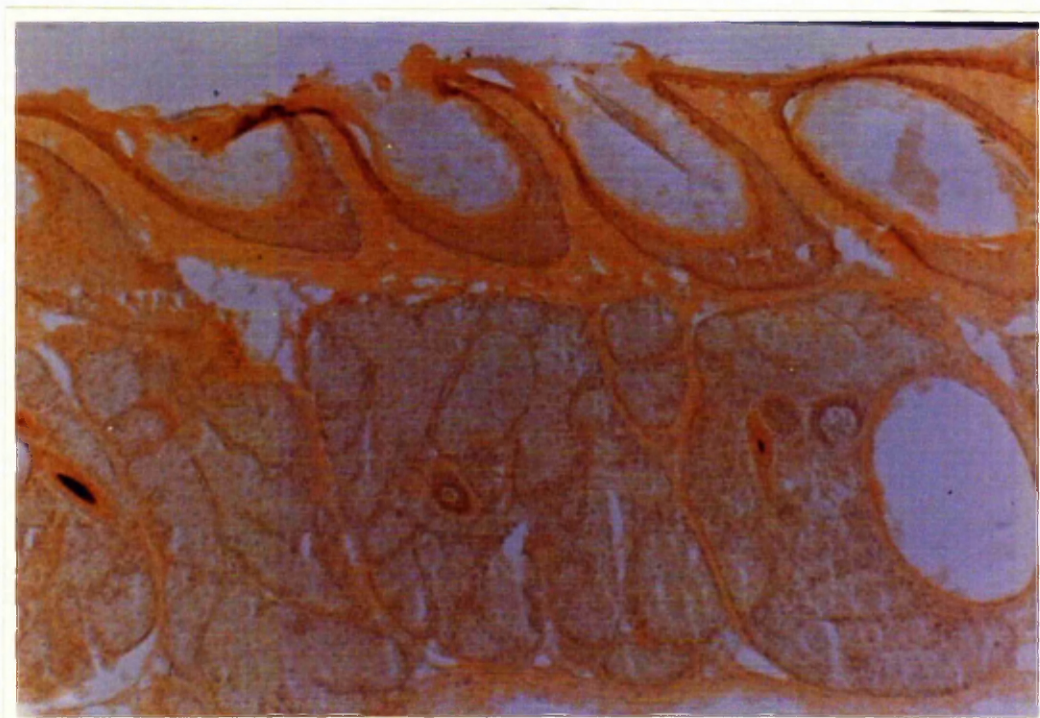(1.) /

Figure 29 Gerbil glandular pad section before



(x110)

Figure 30 and after treatment of animal with testosterone



(x110)

Table 13 Syrian hamster experiments

	<u>Treatment</u>	<u>C.V.O. Size</u>	<u>Sebaceous gland size</u>	<u>3β (with DHA) and 17β (with Testosterone) HSD Activity</u>
Topical treatment in lotion base	1. 17 β -hydroxy-5 α -androstane-3-one (Dihydrotestosterone)	Increased	Increased	+ve (for both right and left C.V.O. skin sections)
	2. 3 α -17 β -dihydroxy-5 α -androstane	Increased	Increased	X
	3. 5 α -androstane-3, 17-dione	-	-	X
	4. 3 β , 17 β -dihydroxy-5 α -androstane	-	-	X
	5. 3 β -hydroxy-5 α -androstane-17-one (Epiandrosterone)	-	X	X
	6. 3 α hydroxy 5 α androstane-17-one (Androsterone)	-	X	X
	7. Base lotion only - Control	-	-	X
Systemic treatment	8. As 1, injected in arachis oil	Increased	Increased	+ve
	9. As 2, injected in arachis oil	Increased	X	X
	10. As 4, injected in arachis oil	-	Increased	+ve
	11. Arachis oil only - Control	-	-	-
	12. No treatment - Control	-	-	-

X - C.V.O. skin lost in faulty section cutting

(1.) Topical treatment was applied on only the right side of the animals but where increase in size of the C.V.O. was observed (animals 1, 2, 5 and 6 on Table 13) such an increase in size occurred in both C.V.O. Increase in the size of C.V.O. was caused by treatment of the animals with :

- a) 17β -hydroxy- 5α -androstan-3-one
(considerable effect)
- b) 3α - 17β -dihydroxy- 5α -androstan
(slight effect)

both in topical and systemic application.

(2.) Increase in the size of the individual sebaceous glands within the dermal layer in skin sections of the C.V.O. was observed (Figures 31 and 32) in animals treated with 17β -hydroxy- 5α -androstan-3-one. Unfortunately in these early experiments the technique of cutting the soft wrinkled wart-like skin of the C.V.O. was as yet in the experimental stages and a lot of the animals in the other groups are not listed in the Table as these C.V.O. skins were faultily cut and cannot be considered.

The only negative results which are left to report in this subsection are animals 3, 4 and 6 and all the controls (which were done last, by which time the preincubation technique was improved).

(3.) The same observations apply to this subsection. Of the C.V.O. skins available for HSD studies those of group 1 (17β -hydroxy- 5α -androstan-3-one treated) gave positive results while those in groups 3, 4, 6 and the controls gave negative results.

Results/

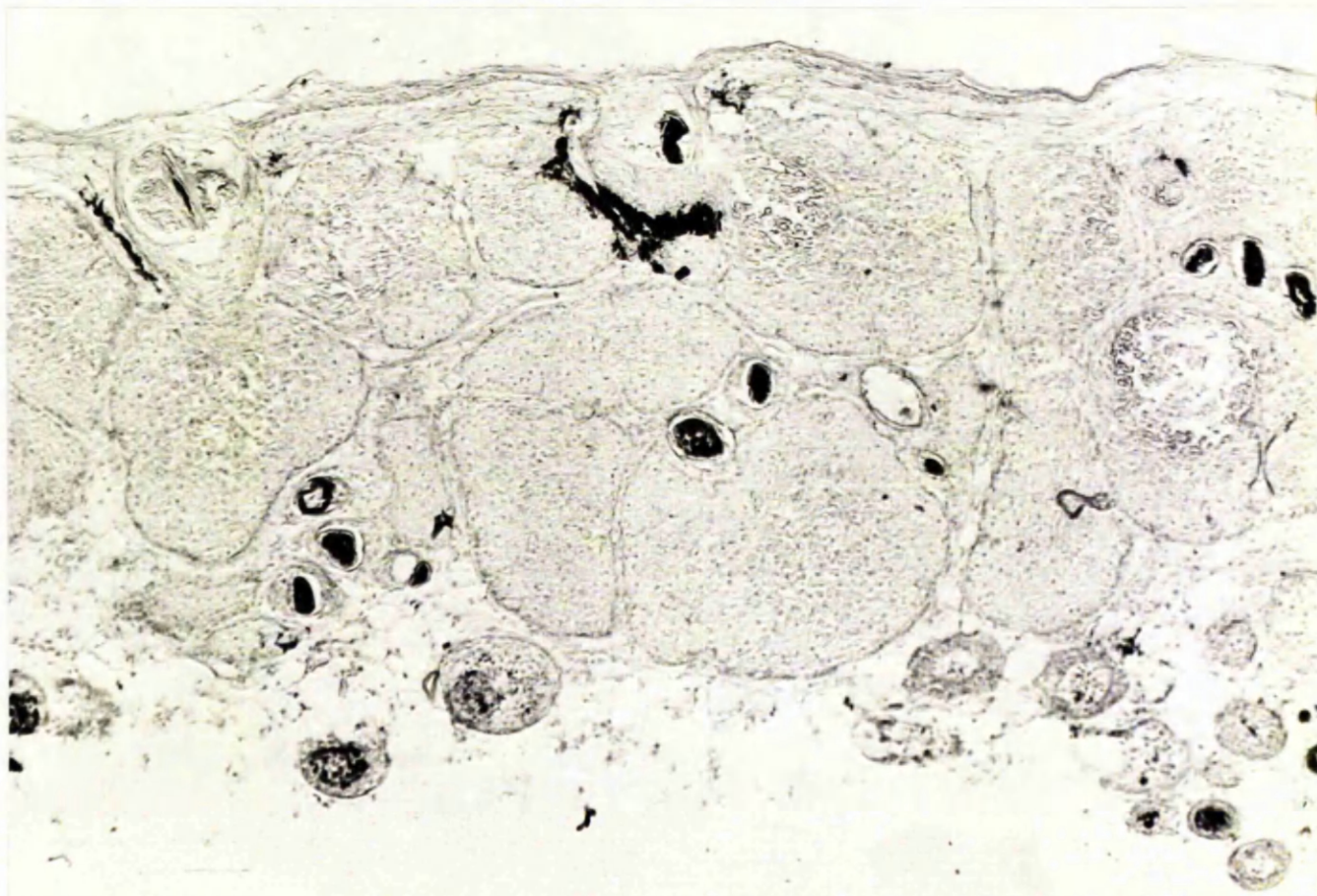
Figure 31 Hamster costovertebral organ section before

(x110)



Figure 32 and after treatment of animal with androgens

(x110)



Results were considered positive in estimating HSD activity when the test showed much stronger formazan deposition than the control incubated section. The problem of positive controls is further considered in the Discussion. HSD activity was tested for 3β HSD enzyme. In animals of group 1 HSD activity after treatment was found to be much greater than in control, untreated animals.

V Iodoacetate Trials

The assay was repeated on 5 different skin samples. All the skin samples were human, scalp, post-mortem skin samples taken within 24 hours after death.

All the skin samples gave the results set out in Table 14.

Preincubation with phosphate buffer of up to 15 minutes removes neither enzyme activity nor staining of the hair-shaft.

Preincubation with iodoacetate - ethyl maleimide solution for more than 3 minutes followed by normal routine incubation for 3β HSD activity shows -

- (a) enzyme inactivation
- (b) gradual removal of staining in the hair-shaft which becomes stain-free after 15 minutes of preincubation.

Preincubation/

Table 14 Iodoacetate trials

Preincubation with buffer <u>(in minutes)</u>	<u>3β HSD</u> <u>Incubation results</u>		Preincubation with solution of iodoacetate - maleimide <u>(in minutes)</u>	<u>3β HSD</u> <u>Incubation results</u>	
	<u>Control</u>	<u>Test</u>		<u>Control</u>	<u>Test</u>
0	-	+	0	-	+
3	-	+	3	-	+
5	-	+	5	-	-
7	-	+	7	-	-
9	-	+	9	-	-
12	-	+	12	-	-
15	-	+	15	-	-

Preincubation in iodoacetate-ethyl maleimide solution for periods of up to 3 minutes in some cases does not cause complete deactivation of the dehydrogenase enzyme and granules may be found to be deposited in the course of the routine test run for 3β HSD which follows the preincubation. The staining of the hair-shaft however is also still in evidence after such short preincubation runs.

It is therefore impossible by this method to get rid of the non-enzymic hair-shaft staining effect without inactivating the steroid dehydrogenase enzymes in skin.

V Abnormal Skins

The results of histochemical investigations on 5 acne skins before and after treatment by various clinically used therapeutic drugs are shown in Table 15. It was noted that skin biopsies from acne patients show strong histochemical activity for 3β HSD, 16β HSD and 17β HSD (both with testosterone and oestradiol as steroid substrate)

Biopsies taken after treatment with Pentovis, Quinoderm and Synalar showed no marked decrease in HSD activity in histochemical trials, compared to HSD activity results from histochemical assays done on the first pretreatment biopsies.

Topical/

Table 15 Abnormal skins HSD activity

<u>Patient</u>	<u>Treatment</u>	<u>Duration of Treatment</u>	<u>C</u>	<u>DHA</u>	<u>Test.</u>	<u>Oest.</u>	<u>16β</u>	<u>NADH</u>
<u>Case 1</u>								
Male 24 years	Pentovis (Topical)	10 days	a) - b) -	+	+	+	+	+
<u>Case 2</u>								
Male 22 years	Sulphur (Topical) and Tetracycline (Oral)	1 week	a) - b) -	+	+	+	+	+
<u>Case 3</u>								
Female 18 years	Quinoderm (Local) and Sulphur 5% (Local)	8 days	a) - b) -	+	+	+	+	+
<u>Case 4</u>								
Female 16 years	Synalar (Local)	10 days	a) - b) -	+	+	+	+	+
<u>Case 5</u>								
Male 25 years	Sulphur (Local) and Tetracycline (Oral)	1 week	a) - b) -	+	+	+	+	+

Biopsies taken: a) before and b) after treatment as near as possible from the same site

Topical Sulphur and oral Tetracycline treatment resulted in some decrease in HSD activity in both subjects investigated. In one case 3β and 16β HSD activity persisted after 10 days of treatment while 17β HSD disappeared. In the second case the first skin biopsy which was taken before treatment was began, showed strong activity for all HSD's tested, while the second biopsy taken 10 days after treatment was began, was active only when testosterone was used as steroid substrate (i.e. only partial 17β HSD activity was retained).

Clinically it was reported that the patients on Tetracycline - Sulphur treatment showed marked improvement in the acne condition while the patients on Quinoderm and on Synalar treatment did not show a comparable improvement.

VII Other Experiments

- (a) Enzyme activity estimations between different sebaceous glands to
establish whether activity is a cyclic phenomenon

In human skin there appears to be no cyclic pattern in sebaceous gland activity.

The/

The examination of a hundred consecutive sections of a skin sample from the scalp, rich in sebaceous glands and showing strong 3β HSD activity and the consideration of each sebaceous gland in this section throughout the series of sections examined reflects the following distribution of activity:-

1. The periphery of the sebaceous gland consists of small, densely packed cells showing strong 3β HSD activity. Sebaceous glands sectioned at the periphery give the appearance of strong diformazan deposition and are therefore considered to be very active in respect of 3β HSD enzyme investigated.

2. The lumen of the sebaceous gland consists of large loosely packed, disintegrating cells which do not show strong 3β HSD activity, in fact sometimes show the absence of any 3β HSD activity. Sebaceous glands cut at or near the middle tend therefore to show little or no diformazan deposition in histochemical investigations and may easily be thought as lacking 3β HSD activity unless one happens to have examined such a sebaceous gland throughout a series of sections and to have observed the increase of 3β HSD activity towards the periphery of the gland.

This distribution is seen in 3β and also in 16β HSD in sebaceous glands of human skin (Figure 24).

17β HSD however shows another pattern of distribution in the sebaceous gland. Histochemical incubations using 17β hydroxy steroids such as testosterone or oestradiol result in diformazan distribution in small pockets throughout the gland (Figure 25).

The/

The series of consecutive sections examined to establish whether activity is a cyclic phenomenon between different sebaceous glands was assayed by the usual histochemical method for 3β HSD activity. Although in examining any one section which contains a number of sebaceous glands it appears as though some of these sebaceous glands are more active than others, in serial studies of each sebaceous gland, it becomes obvious that the apparent activity of a sebaceous gland depends on the level at which it has been cut.

In animal skins on the other hand such a pattern exists. In gerbil skin only one among a few adjacent sebaceous glands in the skin from the sebaceous gland patch of the body shows activity. The possibility exists therefore in animal skin of sebaceous glands being in an active or resting phase, this being perhaps associated with hair growth cycles.

(b) Warm stage experiment

In the course of a routine test incubation for 3β HSD carried out on a warm stage of a microscope a microscope field containing a sebaceous gland with surrounding cells was observed at high power. Initially the sebaceous gland appears briefly to be pink. Within 15 minutes from the start of incubation blue colouration is noted in the sebaceous gland. After 45 minutes from the start of incubation this general blue stain which is diffused over the surface of the sebaceous gland, results in agglomerations of more intense colour, resulting in a darker granular appearance which consists at first of very small particles. These/

These particles grow, presumably, by superimposition of a number of small particles into larger, better defined granules. The diffuse blue colouration of the sebaceous gland clears and after an hour from the start of incubation the picture is that of a clear sebaceous gland with well defined dark blue granules. Throughout the course of the incubation, no colour development was noted in any cells outside the sebaceous gland.

(c) NAD and NADP in histochemical investigations of human skin HSD activity

The results are shown in Tables 16 and 17.

(i) The results are noted in terms of intensity of reaction. Very heavy granules deposition is indicated as (+++), while weak reaction is denoted by (+). In cases where some of the sebaceous glands show no granule deposition, the result is noted as (+-). In the case of the enzymes considered on the three skin samples which were tried, it appears that the HSD is far more active in the presence of NAD than in the presence of NADP.

NADH and NADPH were used in diaphorase control incubations for experiments in which NAD and NADP respectively were co-factors.

(ii)/

Table 16 NAD and NADP in histochemical incubations of human
skin sections

		<u>Skin Sample</u>		
		<u>I</u>	<u>II</u>	<u>III</u>
	1. NAD, nitro BT, buffer	-	-	-
	2. NADP, nitro BT, buffer	-	-	-
3β	{ 3. NAD, DHA, nitro BT, buffer	++	++	++
	{ 4. NADP, DHA, nitro BT, buffer	+	+	+
16β	{ 5. NAD, 16β steroid base, nitro BT, buffer	+++	+++	+++
	{ 6. NADP, 16β steroid base, nitro BT, buffer	++	++	++
17β	{ 7. NAD, testosterone + nitro BT + buffer	++	++	++
	{ 8. NADP, testosterone + nitro BT + buffer	+-	+-	+
17β	{ 9. NAD, oestradiol + nitro BT + buffer	++	++	++
	{ 10. NADP, oestradiol + nitro BT + buffer	+-	-	+
	11. NADH + nitro BT + buffer	+	+	+
	12. NADPH + nitro BT	+	+	+

Table 17 NAD and NADP in histochemical incubations of animal
skin sections

		<u>Rat Skin</u>	<u>Gerbil Territorial Pad Skin</u>	<u>Hamster Costovertebral Organ Skin</u>
3β	1. NAD, nitro BT, buffer	-	-	-
	2. NADH, nitro BT, buffer	-	-	-
	3. NAD, DHA, nitro BT, buffer	+	-	-
	4. NADH, DHA, nitro BT, buffer	+	-	-
16β	5. NAD, 16β steroid, nitro BT, buffer base	+	-	-
	6. NADH, 16β steroid, nitro BT, buffer base	+	-	-
17β	7. NAD, testosterone, nitro BT, buffer	+-	-	-
	8. NADH, testosterone, nitro BT, buffer	+-	-	-
	9. NAD, oestradiol, nitro BT, buffer	+	-	-
	10. NADH, oestradiol, nitro BT, buffer	+	-	-
	11. NADH, nitro BT, buffer	+	+	+
	12. NADPH, nitro BT, buffer	+	+	+

(ii) Similarly it was found that in animal skins those samples that give good positive results with NAD as co-factor (such as rat skin) give good results with NADP while those which give poor results with NAD (such as gerbil glandular pad or hamster C.V.O.) give poor results when NADP is used as co-factor (Table 17). It is thought therefore that NADP does not constitute a more suitable co-factor than NAD in the HSD reactions studied (3β , 16β and 17β) in either the human skins nor the animal skins which were investigated.

(d) Three different skin samples from adult subjects, two perineal skin samples and two foetal skin samples all showing positive 3β HSD reactions using DHA as steroid substrate in histochemical incubations were used in this experiment. Simultaneous incubations were run on consecutive sections of all seven skin samples.

1. Control (no steroid substrate)
2. DHA as steroid substrate
3. DHA- SO_4 steroid substrate
4. NADH (diaphorase control)

Results are shown in Table 18. Neither adult skin (surface or perineal) nor foetal skin was found able to utilise DHA- SO_4 as steroid substrate although 3β HSD and diaphorase enzymes were found to be present.

(e)/

Table 18 DHA-SO₄ as steroid substrate in histochemical tests
of 3 β HSD activity in human skin

<u>Skin</u>	<u>Age</u>		<u>Control</u>	<u>DHA</u>	<u>DHA-SO₄</u>	NADH Diaphorase <u>Control</u>
Adult	35 years	Chest	-	+	-	+
Adult	42 years	Back	-	+	-	+
Adult	43 years	Scalp	-	+	-	+
Perineal	34 years		-	+	-	+
Perineal	23 years		-	+	-	+
Foetal	20 weeks		-	+	-	+
Foetal	26 weeks		-	+	-	+

173

(e) The results of histochemical assays for HSD activity in human skin using several steroid substrates in the incubation medium are reported in Table 19.

Pregnenolone gave strongly positive results in all skin samples used, indicating the suitability of this compound as a base for 3β HSD activity. This result is in agreement with the findings reported by Baillie et al., (1965).

Epiandrosterone likewise gave good positive results in all skin samples examined. The implications of this observation are further considered in the Discussion.

Androstenediol gave positive results which is to be expected with the two hydroxyl groups in the molecule in 3β and 17β position.

Androsterone and etiocholanolone both gave negative results in all human skin samples examined. Likewise 20β -hydroxyprogesterone which was reported by Baillie et al., (1965) as giving a trace reaction was found in this series of experiments to be negative.

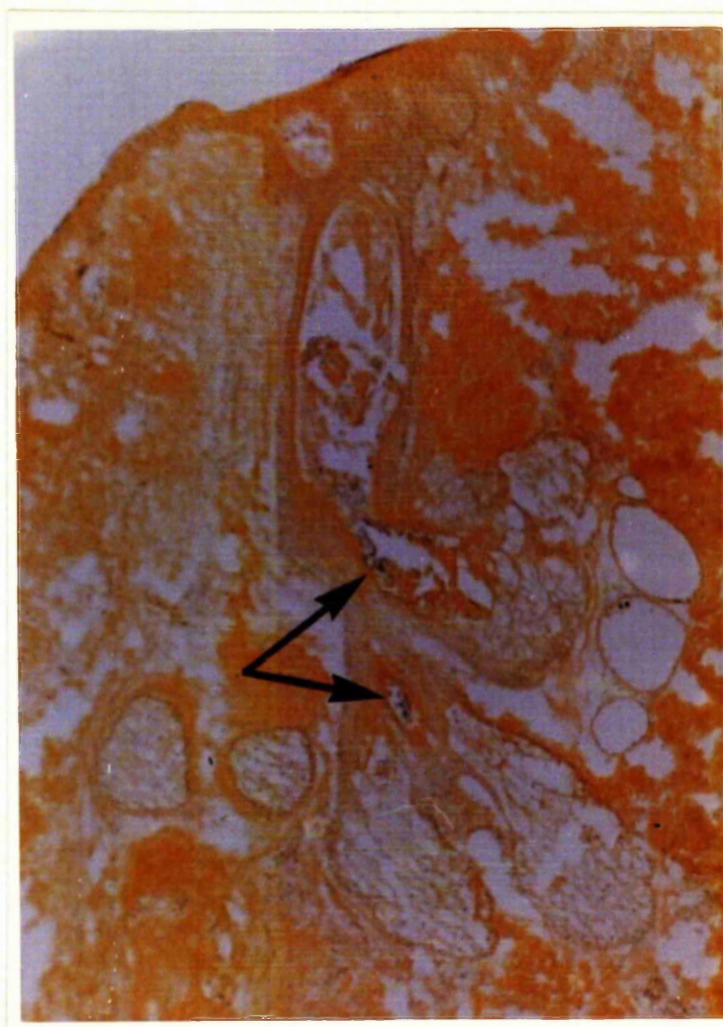
6β hydroxyprogesterone also previously examined by Baillie et al., (1965) and reported as showing a trace reaction, was found to give rise to an unusual reaction. This reaction (Figure 33) consists of diformazan deposition in the sebaceous gland duct while sebaceous gland cells remain perfectly clear, showing no granular deposit. Of the twenty or so skin samples examined for 6β HSD activity, only two (sample 3 and sample 6, see Methods) sections showed the presence of sebaceous ducts and in both of these the same unusual reaction occurred. The/

Table 19 Histochemical assays using various steroid substrates
in human and in rat skin sections

	<u>Human Skin</u>	<u>Rat Skin</u>
1. Pregnenolone	+	+
2. Epiandrosterone	+	+
3. Androstendiol	+	+
4. Androsterone	-	+
5. Androstenedione	-	-
6. Etiocholanolone	-	-
7. 6β -Hydroxyprogesterone	*(particular form of granule deposition)	-
8. 20β -Hydroxyprogesterone	-	-
9. Dihydrotestosterone	+	-
10. Androstadiol (3β , 17β)	+ (very strong 3β type of enzyme distribution in sebaceous gland)	+
11. Androstadiol (3α , 17β)	+ (17β type of enzyme distribution in sebaceous gland)	+
12. Androstandione	-	-
13. DHA	+	+
14. Testosterone	+	-+
15. Control	-	-
16. NADH	+	+

* 6β -Hydroxyprogesterone gives rise to granular deposition in sebaceous ducts only

Figure 33 Section of human scalp skin showing 6β HSD
activity only in the sebaceous gland duct



(x175)

The possible significance of this finding is examined in the Discussion.

Unlike human skin, rat skin histochemical assays on -

- a) androsterone, give very strong positive reaction
- b) dihydrotestosterone, shows no activity.

Other steroids assayed show similar results to those found in human skin.

DISCUSSION

Histochemical Techniques

Using the semiquantitative method (described previously) of estimation of enzymic activity in skin samples, it was found possible to establish optimum conditions of enzymic incubations which varied a little from those previously used (by Baillie, Calman and Milne, 1966) in this work. The optimum concentrations of NAD and DHA were found to be higher than those previously used, being 0.3 mg. NAD/ml. for cofactor and 0.1 mg. DHA/ml. for steroid base.

In the experiments determining the effect of substances as co-factors or inhibitors of the enzymic reaction, the following results emerged:-

No definite effect was noted with the addition of magnesium. Vitamin K if added in very small quantities enhances granule deposition, but with increased concentration of Vitamin K the effect levels off. This effect has been noted previously in histochemical work by Hashimoto et al., (1964). Nicotinamide, which acts as an inhibitor of diphosphopyridine nucleotidase produces, when added in very small concentrations, an increase in granule deposition, stressing once more the involvement of NAD in the reaction. In higher concentrations the effect of nicotinamide on the reaction falls off.

Of/

Of the substances investigated as inhibitors, the antiandrogens studied showed an inhibitory effect (see Table 1) and the method affords a simple technique for screening rapidly, substances suspected of having such activity. Such preliminary screening of antiandrogenic activity by histochemical methods must of course be considered only within the limits of the significance of the histochemical reaction. Bioassays of the kind described in the rat sebaceous gland by Shuster (1969) provide the criteria necessary in establishing either androgenic or antiandrogenic properties of a steroid substance. Quinestradiol showed no effect in our investigations nor did Ubiquinone (Coenzyme Q_{10}) although Ogawa and Hashimoto (1961) describe the effect of Coenzyme Q_{10} and its substitutes in the electron transfer system of succinic dehydrogenase and diaphorases by observations on the staining reactions of frozen sections in conjunction with nitro BT as a substrate.

The time course of the enzymatic reaction shows a linear correlation between the granule deposition and time, this effect levelling off after 2 - 3 hours. In some skin samples there is an initial period of about 30 mins. before granules can be demonstrated. In the observations carried out on the warm stage of a microscope it was apparent that granules may be deposited after a varying period of time during which a diffuse pink stain (monoformazan) is found throughout the sebaceous gland area, eventually changing in colour to light blue and depositing out in minute dark blue granules (of diformazan) which increase in size and intensity over the next hour or so. These/

The variation between different skin samples in the time course of the histochemical reaction is not surprising when one considers the complexity of the multienzyme system involved in these kinetic studies.

The physiochemical properties of the enzymes which have been considered have given us information about heat stability and solubility. The steroid dehydrogenases seem to be very stable at least in dry heat, resisting temperatures of up to 160°C . The enzymes studied, with the exception of 16β HSD, diffuse out of tissue sections.

The fact that 16β HSD activity is still found in skin sections after preincubation in buffer may be due to the presence of this enzyme in greater amounts in the human skin as compared to the other HSD enzymes.

Human/

Human skin sections repeatedly show stronger 16β HSD activity than either 3β or 17β HSD activity in the sebaceous glands, but the significance of 16β HSD in the skin and possibly in steroid metabolism is unknown.

The effect of high enzyme solubility was especially marked in animal skin samples and for this reason the series of experiments was designed in which an inactive high molecular weight substance, polyvinyl pyrrolidine was included in the reaction medium in an attempt to reduce enzyme diffusion.

Post Incubation Techniques

Counterstaining allows for a clear differentiation of the blue diformazan granules from the background of the sebaceous gland cells and nuclei which are counterstained (see Figure 23). The method allows for a good definition of the sebaceous gland and its measurement as well as facilitating the counting of the granules in a given area. As seen from the Results (Table 4) the staining procedure does not result in any loss of granules but seems on the contrary to make the granules more easily seen and therefore counted. The method of counterstaining was therefore adopted in combination with granule counting for estimating the activity of 3β HSD.

Quantitation Techniques

The/

The method adopted for granule counting was an extension of the stereologic techniques used in measurements of tissue section constituents described among others by Freese and Weibel (1967).

In adopting this method an assessment of the number of granules per unit area replaces a test system of points, lines or areas. An automatic scanning counting device for the mechanical estimation of the number of granules formed in a skin section would of course give greater reproducibility of technique.

The use of a semiquantitative counting technique limits the accuracy of histochemical investigations of enzyme activity for reasons shown in the Results.

The use of a scanning and integrating microdensitometer would overcome the observer difference in scoring as well as effects of fatigue etc., but with the Barr and Stroud model which was tried, three obstacles were encountered:-

1. problem of granules deposition at different focal levels
2. inhomogeneous granule distribution in different areas of the sebaceous gland.
3. varying size granules

All/

All these difficulties have however been overcome by the group of Chayen and Bitensky (1969) who using the new type GN2 of Barr and Stroud microdensitometer have successfully assessed the amount of formazan present and have established reproducible activity - time curves.

Quantitation

The problems encountered in attempting to quantitate the histochemical method of estimating hydroxysteroid dehydrogenase are mainly:-

1. different size of diformazan granules deposited in the sebaceous glands.
2. different focal levels at which the granules are deposited.
3. the uneven distribution of the granules in the sebaceous glands.

The different size of granules is probably due to their superimposition at one spot, or to intracellular conditions affecting crystal growth.

Three types of dye stuffs are known to result from histochemical reactions:-

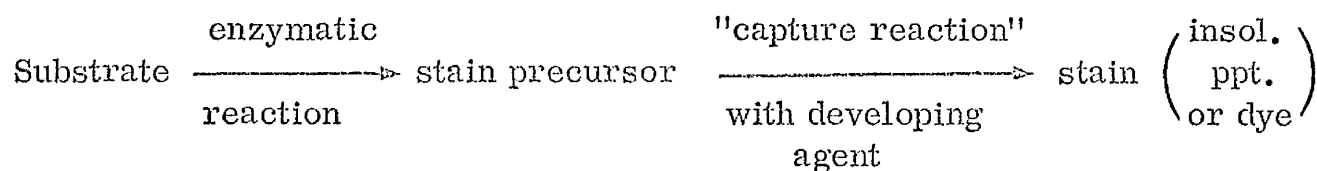
1. Dyes amorphous in appearance such as nitro BT.
2. Dyes which are initially amorphous but subsequently crystallise.
3. Dyes which are crystalline in pattern such as the simple formazan dyes.

The/

The formation of a precipitate occurs by the inception of submicroscopic particles of the reaction product and the growth of grains by aggregation of these particles.

The dyes are held within the tissue section by chemical combination with tissue proteins, by physical forces such as hydrogen - bondings or by mechanical means whereby the insoluble pigment particles are held in the section.

According to Holt and O'Sullivan (1958) an enzyme histochemical staining reaction may be indicated as follows:-



The skin sections are as thin as it is possible to cut them without breaking them up (about 8μ) and granule deposition occurs mainly on the surface of the section in contact with the incubating medium, but some granules are deposited deeper within the section, this becoming apparent when one focuses on the sebaceous gland with the high power of the microscope. It makes granule counting difficult and constitutes serious disadvantage in methods such as the microdensitometer.

In/

In 1967 when this section of the work was being carried out in an effort to establish a method of quantitating the histochemical reaction evolved for HSD estimations, the microdensitometer apparatus available was inadequate for reasons set out in the Results section. Since then however, a scanning and integrating microscope has been built specially with such an aim in view by the group comprising of Dr. J. Chayen et al., (1969) who have used it to determine the amount of the insoluble colour reaction produced by lysosomal and by mitochondrial enzymes. The level of detection which they have achieved by the method of microdensitometry is of the order of 10×10^{-12} g. or less. This very superior piece of new equipment, which is the first of its kind to be used, overcomes the shortcomings which led us to abandon this method two years earlier on the older type of equipment, and mainly the problem of inhomogeneous dispersion. With this improved, and so far unique scanning and integrating microscope it would be possible to envisage quick and accurate estimations of granule deposition in the sebaceous glands of skin and comparisons of such estimations between different skin samples. The method appears reliable and its great advantage is independance from the individual observer's estimation.

The Chayen group show very good correlation between relative absorption and section thickness.

Granule/

Granule deposition in the sebaceous gland is uneven as shown in Figure 9. Sebaceous glands show greater 3β HSD activity around the periphery than in the centre and hence depending on the level at which the gland is sectioned the relative density of the granules differs. In the glandular acini the cells show a centripetal enlargement, those in the centre being large and often misshapen and moribund, while the cells on the outer periphery are undifferentiated and resemble those of the epidermis in appearance. These cells are the most active in the sebaceous gland. Sebaceous differentiation denotes the accumulation of lipid droplets in cells. At the completion of differentiation the cells at the centre of the sebaceous gland become fragmented and form the sebum. As it is the cells on the periphery of the sebaceous gland which are most active, the histochemical method for demonstrating enzymic activity results in greatest granule deposition in the area of these cells. Therefore to compare the activity of two different skin samples, one would either require to take sections at exactly the same level of the sebaceous gland in both skin samples, which is impractical or one would need to make counts in a large number of sections of sebaceous glands in the areas considered and to subject these to statistical tests.

The method (Wild M20 microscope) used in semiquantitating the histochemical reaction is therefore limited to comparisons between counts of consecutive sections in studies of the effect on the enzymic reaction of co-factors (such as Mg) or inhibitors (such as antiandrogens).

In/

In this limited capacity the method is useful, rapid and simple. It makes a good tool for screening large amounts of material as well as constituting an excellent preliminary investigation into more detailed biochemical and physical estimations and measurements of the final products of the enzymic reactions involved.

Survey of Distribution

The significant results to appear from the survey concerns the distribution of sebaceous glands in different areas of the human skin and the varying amount of 3β HSD activity in these different areas as well as in different age groups.

For the purpose of the survey the body was considered sub-divided into different areas (as in Table 9) and skin samples from all these areas were studied. It was found that in the face, neck and scalp there is a great abundance of sebaceous glands and these are large and well defined, with many acini. Even within a single section of skin, numerous glands can be seen. In contrast to this the sebaceous glands of other body areas are smaller and fewer, so that often in a small skin biopsy no sebaceous glands can be found. These results confirm previous findings (Montagna 1963) and they are of importance in the interpretation of the histochemical findings.

The survey indicates that there is a significant difference in 3β HSD activity between different age groups (as shown in Table 10) as well as in different sites of the body (Table 12) but there appears to be no significant difference between male and females in 3β HSD activity (Table 11).

It/

It would seem that 3β HSD is present more readily in the sebaceous glands of the head region and the upper abdomen than at other sites of the body. The regions where HSD activity is most readily found corresponds to those regions of the skin where the sebaceous glands are large and well defined structures of obvious physiological importance. The 3β HSD activity of the sebaceous glands in the chest region is however lower than in the upper abdomen although the sebaceous glands in the chest region are important both in size and number. However also in regions where the sebaceous glands are smaller and less significant in size and number such as arm and leg, one does find from the survey (Table 12) that there is considerable 3β HSD activity, a fact which can be easily overlooked in preliminary investigations where one might overlook the greater number of sections having no sebaceous glands as being negative. In this survey only skin sections showing well developed and yet clearly inactive sebaceous glands were considered negative.

It appears from Table 10 that 3β HSD activity can be found in any age group as positive results were obtained with the youngest (4 years old) case as well as the oldest (81 years old). Highest activity however was found in the 20 - 30 age group a fact which may be thought to be associated with the functional activity of the sebaceous glands at this age. It is interesting to note that the sebum secretion rate when related to age, mirrors very closely the results described above. Cunliffe and Shuster (1969) have measured the sebaceous secretion rate in subjects with and without previous evidence of acne vulgaris. They/

They found that in patients with acne, the highest secretion rate was in the 20 - 30 age group, the rate falling off after this but remaining steady at about 50% of the maximum. This pattern is similar to that found in this survey although no attempt has been made to separate subjects with or without acne vulgaris.

Experimental Animal Studies

In this section of the work which aimed at finding a suitable experimental animal for histochemical investigations involving steroid dehydrogenases, several interesting findings were observed. Animal sebaceous material, both in skin and in specialised structures provides more difficult tissue for histochemical work than human skin. The negative results previously reported in rat skin or preputial gland (Baillie et al., 1966) is thought to be due to this difficulty. The techniques applied to animal skin studies must be very careful and precise. The use of PVP in first confirming the presence of HSD in animal sebaceous glands led to more intensified studies in the section and, as will be observed from the Results several suitable experimental systems were eventually established. Whereas so far 3β HSD activity (with pregnenolone as steroid substrate) and 17β HSD (with testosterone as steroid substrate) were demonstrated in histochemical studies on avian preen gland by Baillie et al., (1966), one now has as an outcome of the present investigation (Muir et al., 1970) rat skin, rat preputial gland, guinea pig lip skin, and to some extent Syrian hamster costovertebral organ all showing histochemical activity of 3β HSD, 16β HSD, and with oestradiol as steroid substrate 17β HSD. A new problem which arises from/

from the results of the studies on rat skin and rat preputial gland tissue, is the poor utilisation of testosterone as 17β hydroxy steroid substrate. The metabolism of testosterone by target organs is at present of great interest since it was found that testosterone is converted to 5α -dihydro-testosterone in the rat prostate (Anderson and Liao, 1968) and by skin slices (Wilson and Walker, 1969) and that dihydrotestosterone is a more powerful androgen in certain bioassay studies (Dorfman and Dorfman, 1962). This conversion is accomplished by the action of a 5α -reductase and it is thought to occur in the cell nuclei. It may be considered possible that HSD activity in the skin is closely associated with the action of androgens and oestrogens on sebaceous gland activity. Dubovyi (1967) showed that some steroids are excreted in sebum through the skin and it is possible that HSD enzymes are involved in such active excretion process. An experimental animal, especially one as small as a rat or hamster would be very suitable for further studies in this direction and now that positive histochemical results can be demonstrated in using these laboratory animals one can envisage a new development in these investigations.

Two series of experiments currently began have, as far as they have given results up to date, been reported in the special animal studies.

The gerbil was used before good results were obtained from histochemical work on other animal skins and it was thought that the gerbil though showing poor histochemical results, was the only laboratory animal giving any results at all. Work on these animals continues however and it is hoped that the technical difficulties which have arisen will be overcome.

The/

The same remarks apply to the experimental section on the Syrian hamster. The presence of two C.V.O. in this animal was considered very suitable in topical assays where it was thought one C.V.O. would act as test and the other as control in the same animal. This however proved not to be so. Topical application of steroid substances which show androgenic properties in this bioassay system in that they cause a considerable growth in size of the C.V.O., affect both the test and the control C.V.O. of the animal. It seems therefore that these androgenic substances exhibit at least a certain amount of solubility in vivo.

The suitability of the hamster as an experimental animal in histochemical investigations is also limited by positive controls. The amount of formazan deposited in these positive control sections varies, and it is thought to reflect enzymatic reaction occurring with endogenous substrate within the cell. Chayen and Bitensky (1969) described the similarity of the initial velocity of the activity time curves in the presence and absence of added exogenous substrate within the first 20-30 minutes before incubation, i.e. before the exogenous substrate can replace endogenous substrate in the reaction.

Although for the purposes of the histochemical technique, attempts were made to remove this endogenous activity in order to achieve negative controls by prewashing of sections in buffer before incubation, (Muir et al., 1970) in fact an assessment of the resting or endogenous cell enzymic activity may be as important as the maximal exogenous activity achieved when the excess of substrate is present in the cell (as described in the hamster C.V.O.)

The/

The first preliminary experiment of which the results are shown in Table 13 is incomplete because of difficulties experienced in cutting sections of the very soft wrinkled tissue which makes up the C. V. O. Unfortunately some of these sections were so bad that the results could not be interpreted, which accounts for the incomplete Table.

The interesting observation, which is illustrated in Figures 31 and 32 applies to this experiment, is the fact of greatly enhanced HSD activity in the sebaceous glands of the C. V. O. of those animals treated with steroid compounds which may be said to possess androgenic properties such as dihydrotestosterone. Such increased post-treatment activity parallels an increase in the size of the C. V. O. and also of the individual sebaceous gland as observed in the sections under the microscope. Such threefold effect of androgenic steroids causing:

1. increase in the special sebaceous organ size
2. increase in individual sebaceous gland size
 within this special structure.
3. increase in HSD activity in the sebaceous gland

has been noted in the C. V. O. of the hamster (animal 1 in Table 13) as well as in the previous experiments reported in the gerbil.

Both these series of experiments constitute preliminary studies. Work is now in progress on both these groups of animals in an effort to overcome the technical difficulties and to further the investigations on effect of treatment (topical and parenteral) of steroid compounds (androgens and antiandrogens).

Iodoacetate/

Iodoacetate Trials

It was hoped in this section of the work to get rid of the non-enzymic reaction which occurs in the hair-shaft during the histochemical method of HSD studies. This aim was not achieved. The method of destroying the non-enzymic reduction of nitro BT in the hair-shaft requires a long period of action by iodoacetate and this constitutes a preincubation was long enough to cause a loss of the HSD enzymic reaction in the sebaceous gland cells. No intermediate was found between retaining the HSD enzymic reaction in the sebaceous glands + the non-enzymic reaction in the hair-shaft and the disappearance of the HSD activity + the disappearance of the hair-shaft reaction.

The diformazan deposition which causes very strong coloration of the hair-shaft in the skin sections does not interfere in the counting method described using the Wild M20 microscope which is used in the semiquantitation of the HSD activity of the tissue. It does however interfere in spectrophotometric studies which were undertaken in connection with the histochemical method.

Abnormal Skins

This section of the work which was planned in conjunction with the survey of distribution of HSD activity in skins to constitute a large part of the considerations in this thesis has, as will be appreciated from the results (Table 15) been limited by the lack of skin biopsy specimens. It/

It was hoped to have many more cases of skin disorders, including mainly, but not necessarily only, acne and to study HSD activity before and after treatment, both topical and systemic, by various clinical drugs. In this form it was supposed to constitute a sector of comparison with HSD activity in normal skins, which it was hoped would impart some information on the subject of investigative dermatology.

When it was realised that most of the patients suffering from acne severe enough to be subject to special supervised treatment or hospitalization, were very young people and that removing biopsies in their condition was risking scars and blemishes for life, it was considered unethical to take such biopsies even when these were voluntarily offered for the purpose of a research project which subsequently may not prove worthy enough of such measures. It is hoped that experiments on laboratory animals will soon yield answers to many of the questions now arising in the field of clinical dermatology and steroid biochemistry.

Other Experiments

a) HSD activity in the sebaceous gland of human skin does not appear to be cyclic phenomenon. The observation that in one skin section several sebaceous glands of seemingly differing degree of activity are found, is thought to be associated with the different levels at which these glands are cut in sectioning of the tissue. If/

If the sebaceous gland is considered as an irregular sphere, the areas around the periphery of this sphere consists of active growing cells, showing strong HSD activity, while the lumen of the sphere contains disintegrating sebaceous cells and sebum and shows less intense diformazan deposition i.e. less HSD activity (See Figure 24). This is true at least for 3β HSD which is shown in the Figure 24 mentioned, and applies also to 16β HSD. 17β HSD however shows a different pattern of enzyme distribution (illustrated in Figure 25) in pockets of activity throughout the gland. 3β HSD was considered in this experimental section and in studying this enzyme activity at different levels of the sebaceous gland, it is evident that in sections cut at or near the middle of the sebaceous gland, the activity will be lesser than in those sections of the same sebaceous gland, which have been cut nearer the edge. The appearance of varying activity in a number of sebaceous glands within one skin section and possibly even the presence of a sebaceous gland showing no HSD activity among other quite active sebaceous glands in the section, is not a reflection of any cyclic phenomenon of enzyme activity in the sebaceous glands of human skin.

Animal skins on the other hand do appear to show a cyclic pattern of HSD enzymic activity. This is perhaps associated with the hair cycle which would be understandable considering the close association of the pilo-sebaceous unit. It may be considered to be responsible for the observation recorded in a previous section of this thesis, that only one in six sebaceous glands in sections of the glandular pad of the gerbil shows HSD activity.

b)/

b) The histochemical incubation procedure for HSD activity followed and examined throughout on the warm stage of the microscope, shows a diffuse appearance of pink monoformazan which gradually strengthens, darkens and contracts into distinct deposition of blue diformazan granules in the sebaceous glands of skin. The trace and monoformazan reactions reported by earlier workers (Baillie et al., 1965) are thought therefore to be due to an incomplete reaction, occurring either due to incomplete time of incubation or due to the lack of the necessary amounts of constituents in the incubation medium. In the controlled quantitative method established and applied in this work, the problem of intermediate reaction results has been overcome. A positive reaction implies a deposition of distinct dark blue diformazan granules after two hours of incubation under conditions described previously in this thesis. The course of the histochemical reaction involved in these observations has been more fully described in the earlier section of the Discussion dealing with 'histochemical techniques'.

c) The use of NAD and NADP in histochemical incubations of human skin sections (Table 16) shows that in the skin samples studied NAD is an essential co-factor for 3β , 16β and 17β HSD enzymes and that this essential co-factor function cannot be served by NADP. 3β and 16β HSD enzymes are accepted by various authors as being indeed NAD dependant although 3β HSD is reported to be active also in the presence of NADP in some tissues (Baillie et al., 1966). 17β /

17 β HSD however is reported by the previously mentioned group to utilise well both NAD and NADP, a fact which is not borne out in the experiments carried out within the context of this thesis.

It was found that animal skins which show HSD activity with NAD will show almost as good activity with NADP (Table 17) for 3 β , 16 β and 17 β HSD which were investigated. Thus rat skin which shows good HSD activity with NAD, especially in the case of 3 β and 16 β HSD, shows also good activity with NADP. There seems accordingly to be a difference in the co-enzyme requirements in skins of human and of animal origin and the significance of this difference is not clear. A correlation between histochemical work and biochemical methods in the elucidation of this problem would be of interest.

d) DHA-SO₄ as steroid substrate in histochemical tests of 3 β HSD activity in human skin, gave negative results for all three types of skin specimens assayed: adult skin (from back and chest), perineal skin (non-pregnant) and foetal skin (23 and 26 weeks old, sample taken from scalp skin). All the samples assayed showed strong 3 β HSD activity in the sebaceous glands when DHA was used as the steroid substrate. The absence of enzymic activity found when DHA-SO₄ is used as steroid substrate in the same tissue, may indicate the absence of the specific enzyme for that substrate or the absence of a sulphatase which may in vivo cause a release of free DHA from DHA-SO₄ with subsequent activity of the normal 3 β HSD on the free DHA. Such/

Such sulphatase is known to be present in some tissues, for instance in the liver and if the large amounts of DHA-SO₄ in the adult are to be considered involved in steroid metabolism in a regulatory capacity the existence of a) the specific sulphatase and b) the 3 β HSD in different tissues of the body, may account for the mechanism of such a regulation. DHA-SO₄ is generally thought to play an important role in pregnancy and for this reason it was thought of interest to subject perineal and foetal skin samples to the histochemical assay but as seen in Table 18, these also gave negative results.

These results suggest that a) if a specific 3 β HSD for DHA-SO₄ exists in the body, the preliminary histochemical tests based on the usual techniques used in these investigations, does not constitute conditions favourable for the demonstration of such an enzyme. In such a case, the conditions of incubation, the incubating medium, the co-factor used could all be varied in a further attempt to demonstrate this new enzyme activity in the sebaceous glands of skin, and at the same time biochemical tests in which DHA-SO₄ is used as steroid base in tracer study experimental incubations

or, b) if DHA-SO₄ is first hydrolysed and then DHA is oxidised by the usual 3 β HSD shown to be present in the sebaceous glands of skin, then the sulphatase responsible for this release of free DHA is not found in the skin or is inactive under the conditions of incubation described. In which case further investigations could be envisaged as suggested above, both by histochemical and by biochemical methods.

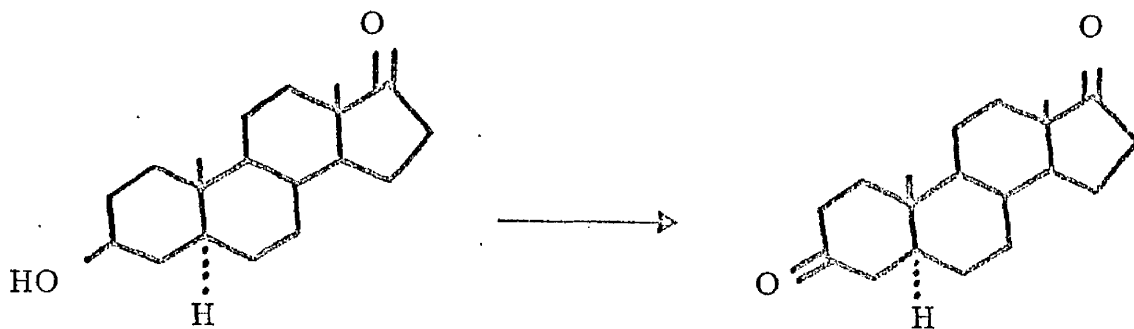
e)/

e) Baillie (1965) reported a series of experiments on investigations of sebaceous gland activity with different steroids. He subdivided his reactivity reaction into three categories:

1. Tr - Trace deposition for formazan
2. M - Monoformazan deposition
3. MD - Mono and diformazan deposition

He considered both epiandrosterone and etiocholanolone, both of which he classifies in the M series of results. With the histochemical techniques developed in the course of this work, the necessity for classifying of enzyme activity of the skin into these categories has been overcome. We need no longer consider Trace reactions or Monoformazan deposition. In a positive reaction strong deposition of blue diformazan granules is obtained, and where this is not found there is no deposition at all and clean negatives are obtained. In repeating these assays on several skin samples using epiandrosterone and etiocholanolone, it was found repeatedly and distinctly that epiandrosterone gives positive results and etiocholanolone gives negative results (in about 30 skin samples assayed).

It might be assumed that epiandrosterone undergoes conversion to 5α -androstandione in the skin



and/

and that the 3β HSD enzyme required for this conversion is present in the sebaceous glands which would account for the diformazan deposition in the histochemical reaction.

It must be stressed that this enzyme is a single enzyme, not associated as in the case of the Δ^5 3β HSD considered in the bulk of this thesis, with an isomerase. Epiandrosterone unlike DHA does not have a double bond in the molecule and the problem of $\Delta^5 - \Delta^4$ conversion in the course of the oxidation process, does not arise. Whereas the Δ^5 3β HSD is a double enzyme system and consequently very substrate - specific, the 3β HSD envisaged in the conversion of epiandrosterone is a totally different enzyme, a single-enzyme-system, and not to be confused with the former. The metabolic transformations of epiandrosterone have not so far received very much attention in biochemical studies. Epiandrosterone is thought to be found in the skin as a product of steroid breakdown metabolism from 5α -androstandione. If the 3β HSD capable of converting it back to 5α androstandione, as the histochemical result indicates is in fact present in the skin, this reaction is a reversible interconversion. So far the reaction has not been thought to be reversible as products like epiandrosterone, etiocholanolone (formed from 5β -androstandione) androsterone (Figure 1) were considered to be end products of androgen metabolism in the skin. The reversibility of the reaction -

$5\alpha/$

5 α androstandione \rightleftharpoons epiandrosterone may throw new light on the problem of androgen metabolism, control and retention in the sebaceous gland.

The other 3 β hydroxy steroid substrate used was pregnenolone which as previously reported by Baillie (1965) gives rise to strong diformazan deposition.

Androstenediol also, as reported by Baillie in the same paper, gives rise to a good histochemical reaction, which is not surprising.

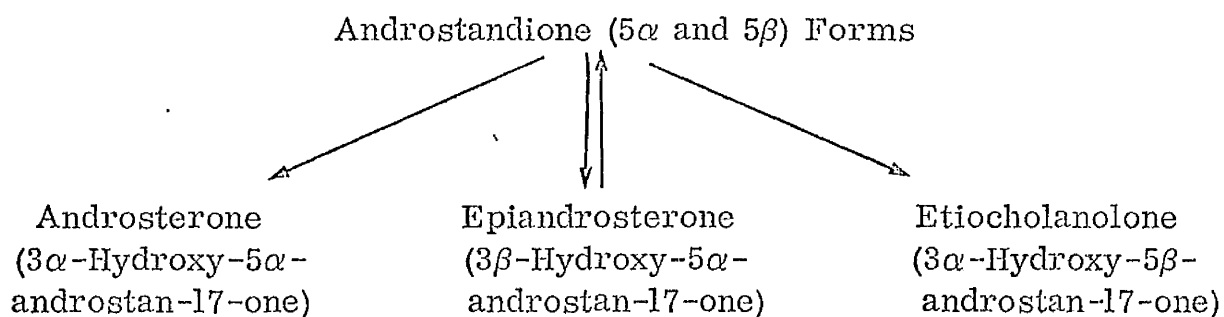
6 β hydroxy steroid however (Baillie used 6 β -hydroxyprogesterone and the same was used in these assays) was reported as showing a Trace reaction. In the present series of experiments it was found that 6 β hydroxyprogesterone used as steroid base in histochemical incubations with different skin samples gave either no reaction at all, or in a few of the skins examined gave rise to a most unusual dye deposition in the section. The diformazan was not deposited in the sebaceous cells as is normally the case in positive results but there occurred a distinct deposition in the sebaceous duct. This would suggest that the 6 β HSD if present is not found in the sebaceous gland cells as the HSD enzymes described so far but in the sebum. Is it possible that the 6 β HSD activity shown in Figure 33 is the property of a micro-organism present in the sebum? If this were so, and further studies are in progress to investigate this possibility, it might explain the unusual site of 6 β HSD activity in the skin and its presence in only some of the skin samples examined in which perhaps bacterial contamination of the skin surface by a particular micro-organism has occurred.

Androstenedione/

Androstenedione and androsterone gave negative results in histochemical assays on the skins so far examined.

According to these preliminary histochemical findings and subject of course to further biochemical studies which will be undertaken in this laboratory as a result of these findings, a portion of Table 1 which represents (in the left hand corner of the Table) the accepted views on the breakdown of androgenic steroids, might be altered with respect to some reaction equilibria.

It would appear from the positive results of HSD activity obtained with epiandrosterone as steroid substrate in the histochemical assay, and the negative results obtained with etiocholanolone and androsterone respectively, that the Table should read:-



SUMMARY

The purpose of research outlined in the course of this thesis was at the outset:-

1. To establish a precise microtechnique suitable for histochemical investigations of hydroxysteroid dehydrogenase (HSD) in the sebaceous gland of skin.
2. To attempt to develop a method of quantitation which could be applied to the results obtained from such a study.
3. To collect enough data to enable a survey of the distribution of HSD activity in the sebaceous glands of human skin.
4. To find a suitable laboratory animal in which HSD activity can be demonstrated by the histochemical techniques in the sebaceous glands of skin and special sebaceous structures of skin which would enable further investigations to be carried out into the problems of steroid metabolism in target organs.

In/

In the course of the work for reasons stated in the Introduction, it was decided to concentrate on one particular enzyme, the 3β -hydroxy- Δ^5 - steroid dehydrogenase and with dehydroepiandrosterone (DHA) as steroid substrate, the histochemical method was improved, quantitated and a microtechnique established in the demonstration of 3β HSD activity.

In trying to estimate the degree of enzymic activity in the sebaceous glands of a skin specimen, various methods were applied. The result was a semiquantitative method which consists of counting the diformazan granules deposited in the sebaceous gland of skin showing HSD activity, by means of the Wild M20 microscope. This is described and discussed.

The search for an experimental animal suitable in histochemical investigations resulted in establishing the presence of HSD activity in the sebaceous glands of skin and in specialised sebaceous organs including the sebaceous glands in the skin of rat, the preputial gland of the rat, the sebaceous glands in the lip of the guinea pig and the costovertebral organ of the Syrian hamster.

In the course of the work described many new problems were revealed, some of which were investigated and are described in this thesis. Others are still in the course of investigation.

The close connection between the problem investigated and the biochemistry of steroid metabolism and its relationship to the problem of acne vulgaris have been taken into account and the implications of their interaction has been considered.

BIBLIOGRAPHY

Allen, J.M., (1960), A Histochemical Study of 3β -Steroid Dehydrogenase in the Adrenal Cortex of the Developing Mouse.
Anat. Rec. 137, 57.

Anderson, K.M., and Liao, S., (1968), Selective Retention of Dihydrotestosterone by Prostatic Nuclei.
Nature 219, 277.

Baillie, A.H., and Griffiths, K., (1964), 3β -Hydroxysteroid Dehydrogenase Activity in the Mouse Leydig Cell.
J. Endocr., 29, 9

Baillie, A.H., Calman, K.C., and Milne, J.A., (1965), Histochemical Distribution of Hydroxysteroid Dehydrogenases in Human Skin.
Brit. J. Derm., 77, 610.

Baillie, A.H., Calman, K.C., Ferguson, M.M., and D. McK Hart,
, (1965), Histochemical Demonstration of 20β HSD
J. Endocr., 32, 337

Baillie, A.H., Ferguson, M.M., Calman, K.C., and D. McK Hart,
, (1965), Histochemical Demonstration of 11β HSD
J. Endocr., 33, 119

Baillie, A.H., Thomson, J., and Milne, J.A., (1966), The Distribution of Hydroxysteroid Dehydrogenase in Human Sebaceous Glands
Brit. J. Derm., 78, 451.

Baillie/

- Baillie, A.H., Ferguson, M.M., and Hart, D.McK., (1966),
Developments in Steroid Histochemistry.
Acad. Press (London & N.Y.)
- Balogh, K., (1964), A Histochemical Method for the Demonstration
of 20α -Hydroxysteroid Dehydrogenase Activity in Rat Ovaries.
J. Histochem. Cytochem., 12, 670.
- Bardin, C.W., and Lipsett, M.B., (1967), Testosterone and
Androstenedione Blood Production Rates in Normal Women
and Women with Idiopathic Hirsutism or Polycystic Ovaries.
J. clin. Invest., 46, 891.
- Bardin, C.W., Hembree, W.C., and Lipsett, M.B., (1968), Suppre-
ssion of Testosterone and Androstenedione Production Rates
with Dexamethesone in Women with Idiopathic Hirsutism and
Polycystic Ovaries.
J. clin. Endocr., 28, 1300.
- Benfenati, A., and Brillanti, F., (1939), Sulla Distribuzione Delle
Ghiandole Sebacee Nella Cute Del Corpo Umano.
Arch. Ital. dermatol. sifilog. et venerol, 15, 33.
- Berliner, D.L., Pasqualini, J.R., and Gallegos, A.J., (1968), The
Formation of Water Soluble Steroids by Human Skin.
J. invest. Derm., 50, 220.
- Beyer/

Beyer, K.F., and Samuels, L.T., (1956), Distribution of Steroid
-3 β -ol Dehydrogenase in Cellular Structures of the Adrenal Gland.
J. biol. Chem., 219, 69.

Black, M.M., Iwelfach, B.W., and Speer, F.D.,
_____ (1953), Tetrazolium Salts.
Amer. J. clin. Path., 23, 332.

Boch, K., (1959), Biogenesis and Transformations of Squalene
Biosynthesis of Terpenes and Sterols.
Little, Brown and Co., Boston, p. 4.

Bruchovsky, N., and Wilson, J.D., (1968), Evidence that Dihydro-
testosterone is the Active Form of Testosterone.
Clin. Res. 14, 74.

Bruchovsky, N., and Wilson, J.D., (1968), The Conversion of Testo-
sterone to 5 α -Androsten-17 β -ol-3-one by Rat Prostate in vivo
and in vitro
J. biol. Chem., 243, 2012

Bullough, W.S., and Laurence, E.B., (1960), Experimental Sebaceous
Gland Suppression in the Adult Male Mouse.
J. invest. Derm., 35, 37.

Burstone, M.S., (1960), Post Coupling, Noncoupling and Fluorescence
Techniques for the Demonstration of Alkaline Phosphatase.
J. Natl. Cancer Inst., 24, 1199.

Burstone/

Burstone, M.S., (1962), Enzyme Histochemistry.

Acad. Press.

Calman, K.C., Muir, A.V., Milne, J.A., and Young, H., (1970),

Survey of the Distribution of Steroid Dehydrogenases in the
Sebaceous Glands of Human Skin.

Brit. J. Derm. **82**, 567

Cameron, E.H.D., Bahne, A.H., Grant, J.K., Milne, J.A., and

Thomson, J., (1966), Transformation in vitro of (7α - ^3H)-
Dehydroepiandrosterone to H^3 - testosterone.

J. Endocrin, 35, XIX, (Abstr.)

Cavallero, C., and Ofner, P., (1967), Relative Effectiveness of Various
Steroids in an Androgen Assay Using the Exorbital Lacrymal
Gland of the Castrated Rat, II C19 - Steroids of the 5α -Androstene
Series.

Acta Endocr. (Kbh) 55, 131.

Chayen, J., and Derby, E.F., (1968), Biophysical Techniques as Applied
to Cell Biology.

Methuen Monogr., London.

Chayen, J., Bitensky, L., Butcher, R.G., Poulter, L.W., and

Ubhi, G.S., (1969), Methods for the Direct Measurement of Anti-
Inflammatory Action on Human Tissue Maintained in vitro.

Syntex Symposium, Cambridge.

Cook/

- Cook, T.J., and Lorincz, A.L., (1963), Enzymatic Determination of Hydroxysteroids in Human Skin Surface Lipids.
J. invest. Derm., 41, 265.
- Cruickshank, C.N.D., (1965), Metabolic Processes in Skin.
Brit. J. Derm., 77, 603.
- Cunliffe, W.J., Shuster, S., and Cassels Smith A.J.,**
(1969), The Effect of Topical Cyproterone Acetate on Sebum Secretion in Patients with Acne.
Brit. J. Derm., 81, 200,
- Cunliffe, W.J., and Shuster, S., (1969), Pathogenesis of Acne.
Lancet (i), 685.
- Dawson, R.M.C., Elliott, D.C., Elliott, W.H., and Jones, K.M.,**
D. al., (1969), Data for Biochemical Research p. 441
2nd edition,
Oxford Press
- Deeley, E.M., (1955), An Integrating Microdensitometer for Biological Cells.
J. Sci. Instrum. 32, 263.
- Dietschy, J.M., and Wilson, J.D., (1968), Cholesterol Synthesis in the Squirrel Monkey: Relative Rates of Synthesis in Various Tissues and Mechanisms of Control.
J. clin. Invest., 47, 12a.
- Dorfman, R.I., and Ungar, L., (1953), Metabolism of Steroid Hormones.
Burgess Publish. Co., Minneapolis.
- Dorfman/

Dorfman, R.I., and Shipley, R.A., (1956), Androgens Biochemistry,
Physiology and Clinical Significance.
Wiley, N.Y.

Dorfman, R.I., (1961), Mechanism of Action of Steroid Hormones:
Androgens in "Mechanism of Action of Steroid Hormones"
(C.A. Villee and L.L. Engle eds.)
Pergamon Press, N.Y.

Dorfman, R.I., and Dorfman, A.S., (1962), Assay of Subcutaneously
Administered Androgens on the Chicks Comb.
Acta Endocr., 41, 101.

Dubovyi, M.I., (1967), Androgenic Steroids in Sebum.
Vestn. Derm. Vener., 41, 14.

Dulmanis, A., Coghlan, J.P., Wintour, M., and Hudson, B.
D. 1, (1964), The Estimations of Testosterone in Biological
Fluids II Testosterone in Urine.
Aust. J. Exp., Biol. Med. Sci., 42, 385.

Ebling, F.J., (1948), Sebaceous Glands I, The Effect of Sex Hormones
on the Sebaceous Glands of the Female Albino Rat.
J. Endocr., 5, 297.

Ebling, F.J., (1957), The Action of Testosterone and Oestradiol on the
Sebaceous Glands and Epidermis of the Rat.
J. Embryol, exp. Morph., 5, 74,

Ebling/

Ebling, F.J., (1957), The Action of Testosterone on the Sebaceous Glands and Epidermis in Castrated and Hypophysectomized Male Rats.

J. Endocr. 15, 297.

Ebling, F.J., (1964), Androgens of the Skin.

J. Endocr., 29, Proc. VIII.

Ebling, F.J., (1967), The Action of an Anti-Androgenic Steroid 17α -Me-B Nortestosterone on Sebum Secretion in Rats Treated with Testosterone.

J. Endocr., 38, 181.

Ebling, F.J., and Skinner, J., (1967), The Measurement of Sebum Production in Rats Treated with Testosterone and Oestradiol.

Br. J. Derm., 79, 386.

English, R.S., and Withowski, J.A., (1964), Etiological Factors in Acne.

W. Virg. Med. J., 60 (7), 178.

Evans, C.J., Smith, W.M., Johnston, E.A., and Gibbett, E.R.,
E (1950), Bacterial Flora of the Normal Human Skin.

J. invest. Derm., 15, 305.

Faradin, I., Webb, J.L., and Julesz, M., (1967), The in vitro Metabolism of 4 - 14 C-Dehydroepiandrosterone by Human Pubic Skin.

Europ. J. Steroids, 2, 223.

Faradin, I., Webb, J.L., and Julesz, M., (1967), The in vitro Metabolism of DHA in Human Skin.

Acta med. Acad. Sci. hung., 23, 169.

Faradin/

- Faradin, J., Fazekas, A.G., Toth, I., Kokai, K., and Julesz, M.,
(1969). Transformation in vitro of 4 - ^{14}C - Dehydro-
epiandrosterone into 7-Oxygenated Derivatives by Normal
Human Male and Female Skin Tissue.
J. invest. Derm., 52, 357.
- Fentenstein, G.N., and Morton, R.A., (1955), Provitamin D in
Animal Tissues.
Bioch. J., 60, 22.
- Flesch, P., (1948), Physiology and Biochemistry of the Skin.
S. Rothman ed. Univ. Chicago Press, Chap., XVI, pp.601.
- Freere, R.H., and Weibel, E.R., (1967), Stereologic Techniques
in Microscopy.
J. Roy. micr. Soc., 87, 25.
- French, F.S., Baggett, B., Van Wyk, J.J., Talbert, L.M.,
Hubbard, W.R., Johnston, F.R., Weaver, R.P., Forchielli, E.,
Rao, G.S., and Sarda, I.R., (1965), Testicular Feminization:
Clinical, Morphological and Biochemical Studies.
J. clin. Endocr., 25, 661.
- French, F.S., Van Wyk, J.J., Baggett, B., Easterling, W.E.,
Talbert, L.M., Johnston, F.R., Forchielli, E., and Dey, A.C.,
(1966), Further Evidence of a Target Organ Defect in the
Syndrome of Testicular Feminisation.
J. clin. Endocr., 26, 493.
- Futterweit, W., McNiven, N.L., Guerra-Garcia, R., Gibree, N.,
Drosdovsky, M., Siegel, G.L., Soffer, L.J., Rosenthal, I.M.,
and Dorfman, R., (1964), Testosterone in Human Urine.
Steroids, 4, 137.
- Gallegos, A.J., and Berliner, D.L., (1967), Transformation and
Conjugation of DHA by Human Skin.
J. clin. Endocr., 27, 1214.

- Gaylor, J.L., and Sault, F.M., (1964), Localisation and Biosynthesis of 7-Dehydrocholesterol in Rat Skin.
J. Lipid Res., 5, 422.
- Glen, E. Myles, and Gray, J., (1965), Effect of Various Hormones on the Growth and Histology of the Gerbil (Meriones unguiculatus) Abdominal Sebaceous Gland Patch.
Endocrinology, 76, 1115.
- Glick, D., (1949), Techniques of Histo - and Cytochemistry
Interscience Publishers Inc., N.Y.,
- Goldzieher, J.S., and Acelrod, L.R., (1962), The Polycystic Ovary. II Urinary Steroid Excretion.
J. clin. Endocr., 22, 425.
- Gomez, E.C., and Hsia, S.L., (1968), In vitro Metabolism of Testosterone 4 - ^{14}C and 4 - Androstene-3, 17-Dione-4- ^{14}C in Human Skin.
Biochemistry, 7, 24.
- De Graaf, H. J., (1943), De Invloed Van Geslachtshor Monen Op De Smeerklieren.
Ned. Tijdschr. Geneeskunde, 87, 1450.
- Griffith, S.K., Grant, J.K., and Whyte, W.G., (1963), Steroid Biosynthesis in vitro by Cryptorchid Testes from a Case of Testicular Feminization.
J. clin. Endocr. 23, 1044.
- Gwinup, G., Wieland, R.G., Besch, P.K., Hamwi, G.J., (1966), Studies on the Mechanism of the Production of the Testicular Feminization Syndrome.
Amer. J. Med. 41, 448.
- Hamilton/

Hamilton, J.B., (1941), Male Hormone Substance: A Prime Factor in Acne.
J. clin. Endocr., 1, 570.

Hamilton, J.B., (1947), Growth Changes Induced by Androgens in the
Connective Tissues, Sebaceous Glands, Hairs, Muscle and
Melanoblasts in the Skin.
Anat. Rec., 97, 340 (a).

Hamilton, J.B., and Montagna, W., (1950), The Sebaceous Gland of the
Hamster. I Morphological Effects of Androgens on Integumentary
Structures.
Amer. J. Anat. 86, 191.

Haskin, D., Lasher, N., and Rothman, S., (1953), Some Effects of
ACTH, Cortisone, Progesterone and Testosterone on Sebaceous
Glands in the White Rat.
J. invest. Derm., 20, 207.

Heinrichs, W.L., Karsznia, R., Wyss, R., and Herrmann, W.L.,
(1969), Testicular Feminization: An Apparent
Enzyme Defect.
Clin. Res. 17, 143.

Hellman, L., Nakada, F., Zumoff, B., Fukushima, D.K., Bradlow, H.L.,
and Gallagher, T.F., (1968), 11β HSD Studied in vivo in Man with Cortisol-
4-¹⁴C-11-³H.

Advances in the Biosciences p.17, Schering Workshop on Steroid
Metabolism "In vivo versus in vitro"
Berlin, Pergamon Press.

Holt/

- Holt, S.J., and O'Sullivan, D.G., (1958), Studies in Enzyme
Cytochemistry, I Principles of Cytochemical Staining Methods.
Proc. Roy. Soc., B148, 465.
- Hooker, C.W., and Pfeiffer, C.A., (1943), Effects of Sex Hormones
Upon Body Growth, Skin, Hair and Sebaceous Glands in the Rat.
Endocr. 32, 69.
- Horton, R., and Tait, J.F., (1966), Androstenedione Production and
Interconversion Rates Measured in Peripheral Blood and Studies
on the Possible Site of its Conversion to Testosterone.
J. clin. Invest., 45, 301.
- Hubener, H.J., Fukushima, D., and Gallagher, T.F., (1956), Substrate
Specificity of Enzymes Reducing the 11 - and 20 - Keto Groups
of Steroids.
J. Biol. Chem., 220, 499.
- Hudson, B., Coghlan, J., Dulmanis, A., Wintour, M., and Ekkel, I**
(1963), The Estimation of Testosterone in Biological
Fluids I. Testosterone in Plasma.
Anst. J. Exp. Biol. Med. Sci., 41, 235.
- Hurlock, B., and Talalay, P., (1959), Microsomal 3α and 11β -Hydroxy-
steroid Dehydrogenases.
Arch. Biochem. Biophys., 80, 468.
- Imamura, S., Pochi, P.E., Strauss, J.S., and McCabe, W.R.,**
(1969), The Localization and Distribution of
Corynebacterium acnes and its Antigens in Normal Skin and in
Lesions of Acne Vulgaris.
J. invest. Derm., 53, (2), 143.

Ismail/

Ismail, A.A.A., and Loraine, J.A., (1969), Hirsutism: A Disorder
Frequently Associated with Menstrual Abnormalities.
Clin. Obstetr. and Gynecol., 12, (3), 800.

IUPAC Commission on the Nomenclature of Organic Chemistry and
IUPAC -IUB Commission on Biochemical Nomenclature
Revised Tentative Rules for Nomenclature of Steroids.
Bioch. J., 113, (1), 5.

Jarabak, J., Adams, J.A., and Talalay, P., (1962), Purification of a
17 β -Hydroxysteroid Dehydrogenase of Human Placenta.
J. Biol. Chem., 237, 345.

Jarrett, A., (1959), Effects of Progesterone and Testosterone on Surface
Sebum and Acne Vulgaris.
Br. J. Derm., 71, 102.

Jeffcoate, S.L., Brooks, R.V., London, D.R., Prunty, F.T.G.,
(1968), Secretion of C₁₉ - steroids and Oestrogens
and Rhodes, P.,
in the Polycystic Ovary Syndrome: Ovarian Studies in vivo and in vitro
(Including Studies in vitro on a Coincidental Granulosa Cell Tumour)
J. Endocr., 42, 229.

Julesz, M., Faradin, I., and Toth, I., (1966), Steroids in Human Skin and
Hairs I. Zimmermann Chromogens in the Skin of Normal and of
Hirsute Women.
Acta Med. Acad. Sci. Hung., 22, 25.

Julesz/

Julesz, M., (1968), New Advances in the Field of Androgenic Steroidogenesis of the Human Skin.

Acta med. Acad. Sci. Hung., 25, 273.

Kahnt, F.W., Neher, R., Schmid, K., and Wettstein, A., ⁵
(1961), Bildung von 17α -Hydroxy- Δ -Pregnenolon
und 3β -Hydroxy- 17 -Keto Δ -Androsten (DHA) in Nebennieren - und
Testes-Gewebe.

Experimentia (Basel) 17, 19.

Kalz, F., (1958), Hormonal Influences on Sebaceous Gland Activity
and on Acne Vulgaris.

Can. Med. Assoc., 79, 852.

Kandutsh, A.A., and Russell, A.E., (1960), Intermediates in a Pathway
from Lanosterol to Cholesterol.

Federatn. Proc., 19, 237.

Kandutsh, A.A., and Russell, A.E., (1960), Preputial Gland Tumour Sterols
III. A Metabolic Pathway from Lanosterol to Cholesterol.

J. Biol. Chem., 235, 2256.

Kase, N., and Kowal, J., (1962), In vitro Production of Testosterone in a
Human Adrenal Homogenate.

J. clin. Endocr., 22, 925.

Kivy-Rosenberg, E., Cascarano, J., and Zweifach, B.W., (1955),
Tetrazolium Salts as Indicators of Changes in Tissue Metabolism
During Functional Activity.

Trans. N.Y. Acad. Sci., 17, 402.

Kligman/

Kligman, A.M., and Shelley, W.B., (1958), An Investigation of the
Biology of the Human Sebaceous Gland.

J. invest. Derm., 30, 99.

Kovenman, S.G., and Lipsett, M.B., (1965), Peripheral Conversion
of DHA to Testosterone Glucuronoside.

Steroids 5, 509.

Krant, M.J., Brandrup, C.S., Greene, R.S., Pochl, P.E.

and Strauss, J.S., 1968), Sebaceous Gland Activity in Breast Cancer.

Nature 217, 463.

Lamb, E.J., Dignam, W.J., Pton, R.J., Simmer, H.H.,

, (1964), Plasma Androgens in Women: I Normal

and Non-Hirsute Females, Oophorectomized and Adrenalectomized
Patients.

Acta Endocr., 45, 243.

Lapiere, C., (1953), Modifications Des Glandes Sebacees Par Des
Hormones Sexuelles Appliquees Localement Sur La Peau De Souris
C.R. Soc. biol., 147, 1302.

Lasher, N., Lorincz, A.L., and Rothman, S., (1954), Hormonal Effects
on Sebaceous Glands in the White Rat II. The Effect of the Pituitary
Adrenal Axis.

J. invest. Derm., 22, 25.

Lederer, E., Mercier, D., (1948), Sur Les Constituants De La Graisse
De La Laine. La Peau De Moutons Comme Organe De La
Biosynthese Des Alcools Triterpeniques.

Biochim. et Biophys. Acta 2, 91

Lieberman/

- Lieberman, S., and Teich, S., (1953), Recent Trends in the Biochemistry of the Steroid Hormones.
Pharmacol. Revs. 5, 285.
- Linderstom-Long, K., and Morgensen, K.R., (1963), Enzymic Histology XXXI Histological Control of Histochemical Investigations.
Compt. rend. trav. lab. Carlsbergser, Chim, 23, 27.
- Lison, H., (1936), Histochemie Animale Methodes Et Problemes
Paris Gauthier - Villars.
- Lowry, O.H., Roberts, N.R., Leiner, K.Y., Wu, M.L., and Farr, A.L., (1954), The Quantitative Histochemistry of Brain. I Chemical Methods.
J. biol. Chem., 207, 1.
- Lowry, O.H., Roberts, N.R., Wu, M.L., Hixon, W.S., and Crawford, E.J., (1954), The Quantitative Histochemistry of Brain. II Enzyme Measurements.
J. biol. Chem., 207, 19.
- Lowry, O.H., Roberts, N.R., and Kappahn, J.I., (1957), The Fluorimetric Measurement of Pyridine Nucleotides.
J. biol. Chem., 224, 1047.
- Mahesh, V.B., and Ulrich, F., (1959), Distribution of Enzyme Systems Responsible for Steroid Metabolism in Different Tissues and Subcellular Fractions.
Nature 184, 1147.

Mahesh/

- Mahesh, V.P., and Greenblatt, R.B., (1964), Steroid Secretions of the Normal and Polycystic Ovary.
Recent Progr. Hormone Res., 20, 341.
- Marcus, P.I., and Talalay, P., (1955), On the Molecular Specificity of Steroid - Enzyme Combinations. The Kinetics of β -Hydroxysteroid Dehydrogenase.
Proc. Roy. Soc., London S.B., 144, 116.
- Marcus, P.I., and Talalay, P., (1956), Induction and Purification of α - and β -Hydroxysteroid dehydrogenases.
J. biol. Chem., 218, 661.
- Martan, J., and Price, D., (1967), Comparative Responsiveness of Supracadudal and other Sebaceous Glands in Male and Female Guinea Pigs to Hormones.
J. Morph., 121, 209.
- Mauvais-Jarvis, P., Bercovici, J.P., and Gauthier, F., (1969),
In vivo Studies on Testosterone Metabolism by Skin of Normal Males and Patients with the Syndrome of Testicular Feminization.
J. Clin. Endocr., 29, 417.
- Mehler, A.H., (1957), Introduction to Enzymology.
N.Y. Acad. Press.
- Migeon, C.J., Gardner, L.I., Crigler, J.F., Jr., Wilkins, L., (1952),
Effect of cortisone treatment for 28 days on radio-iodine metabolism in normal rats and adrenalectomized rats maintained with desoxycorticosterone. Endocrinology 51, 117.

Milne/

- Milne, J.A., (1969), The Metabolism of Androgens by Sebaceous Glands
Brit. J. Derm., 81 (2), 23.
- Mitchell, O.G., (1965), Effect of Castration and Transplantation on the
Ventral Gland of the Gerbil.
Proc. Soc. Exp., Biol. Med. (N.Y.) 119, 953.
- Mitchell, O.G., and Butcher, E.O., (1966), Growth of Hair in the
Ventral Glands of Castrate Gerbils Following Testosterone
Administration.
Anat. Rec. 156, 11.
- Montagna, W., and Noback, C.R., (1946), The Histology of the Preputial
Gland of the Rat.
Anat. Rec. 96, 41.
- Montagna, W., and Noback, C.R., (1946), The Histochemistry of the
Preputial Gland of the Rat.
Anat. Rec. 96, 111.
- Montagna, W., and Hamilton, J.B., (1947), Histochemical Analysis of the
Sebaceous Glands of the Hamster.
Federation Proc. 6, 166.
- Montagna, W., (1947), Histochemistry of the Sebaceous Gland of the Rat.
Anat. Rec. 97, 356.
- Montagna, W., and Noback, C.R., (1947), Histochemical Observations
on the Sebaceous Glands of the Rat.
Am. J. Anat. 81, 39.
- Montagna/

- Montagna, W., and Kenyon, P., (1949). Growth Potentials and Mitotic Division in the Sebaceous Glands of the Rabbit. Anat. Rec., 103, 365.
- Montagna, W., Ellis, R.A., and Silver, A.F., (1963), Advances in Biology of Skin Vol. IV The Sebaceous Gland Pergamon Press.
- Montagna, W., (1963), Advances in Biology of the Skin Vol. 4. Ed. Montagna, Ellis and Silver
- Morris, J.M., and Mahesh, V.B., (1963), Further Observations on the Syndrome "Testicular Feminization". Amer. J. Obstet. Gynec., 87, 731.
- Muir, A.V., Calman, K.C., Thomson, J., MacSween, M.P., Milne, J.A., Chakraborty, J., and Grant, J.K., (1968). Hydroxysteroid Dehydrogenase Activity in Human Skin I Histochemical Techniques and a Method for Quantitation. Brit. J. Derm., 80, 594.
- Muir, A.V., Calman, K.C., Thomson, J., MacSween, M.P., Milne, J.A., Chakraborty, J., and Grant, J.K., (1968). Hydroxysteroid Dehydrogenase Activity in Human Skin II Factors Influencing HSD Activity in Sebaceous Glands of Human Skin. Brit. J. Derm., 80, 652
- Muir, A.V., Hodgins, M.B., Milne, J.A., and Young, H., (1970) The Presence of HSD Activity in Mammalian Sebaceous Structures. Brit. J. Derm., 83, 291

Muller/

- Muller, M.D., and Winkelmann, R.K., (1969), Oxidative Enzymes in Plucked Human Scalp Hairs.
J. invest. Derm., 52, 400.
- Myles Glenn, E., and Gray, J., (1965), Effect of Various Hormones on the Growth and Histology of the Gerbil (Meriones unguiculatus) Abdominal Sebaceous Gland Pad.
Endocr. 76, 1115.
- Nachlas, M.M., Tsou, K.C., de Souza, E., Cheng, C.S., and Seligman, A.M.,** (1957), Cytochemical Demonstration of Succinic Dehydrogenase by the Use of a New p - Nitrophenyl Substituted Ditetrazole.
J. Histochem. Cytochem., 5, 420.
- Nachlas, M.M., Walker, D.G., and Seligman, A.M., (1958), A Histochemical Method for the Demonstration of Diphosphopyridine Nucleotide Diaphorase.
J. biophys. biochem. Cytol. 4, 29.
- Neher, R., and Wettstein, A., (1960), Occurrence of ⁵-3 β -hydroxysteroid Dehydrogenases in Adrenal and Testicular Tissue.
Acta Endocr. 35, 1.
- Nicoloides, N., and Rothman, S., (1955), The Site of Sterol and Squalene Synthesis in the Human Skin.
J. invest. Derm., 24, 125.
- Nicoloides, N., Reiss, O.K., and Langdon, R.G., (1955), Studies of the In vitro Lipid Metabolism of the Human Skin. I Biosynthesis in Scalp Skin.
J. Am. Chem. Soc., 71, 1535.
- Nicoloides/

- Nicoloides, N., and Wells, G.C., (1957), On the Biogenesis of the
Free Fatty Acids in Human Skin Surface Fat.
J. invest. Derm., 29, 423.
- Nikkari, T., and Valavaara, M., (1969), The Production of Sebum in
Young Rats. Effects of Age, Sex, Hypophysectomy and Treatment
with Somatotrophic Hormone and Sex Hormones.
J. Endocr., 43, 113.
- Northcutt, R.C., Island, D.P., and Liddle, G.W., (1969), An Explanation
for the Target Organ Unresponsiveness to Testosterone in the
Testicular Feminization Syndrome.
J. clin. Endocr., 29, 422.
- Ogawa, K., and Hashimoto, K., (1961), Co-enzymes Q7 and its Substitutes
in the Electron Transport System of the Succinic Dehydrogenase
System and Diphosphopyridine Nucleotide Diaphorase
J. histochem. Cytochem., 9, 635.
- Owens, D.W., and Knox, J.M., (1967), The Effect of Hormones on the
Sebaceous Gland
Acta dermat., Venereol., (Stockholm) 47, 363.
- Pearse, A.G.E., (1968), Histochemistry,
Churchill Ltd., Ed., 3rd ed.
- Pearson, B., and Grose, F., (1959)(a), Histochemical Study of Some
DPNH and DPN Dependent Dehydrogenases.
Federation Proc. 18, 499.
- Pearson/

Pearson, B., and Grose, F., (1959) (b), Histochemical Demonstration of 17β -Hydroxysteroid Dehydrogenase by Use of a Tetrazolium Salt. Proc. Exptl. Biol. Med., 100, 636.

Plewig, G., and Kligman, A.M., (1969), Establishment of Acne in the Mouse by Topical Corticosteroids. J. invest. Derm., 52, 4, 392.

Pochi, P.E., Strauss, J.A., and Mescon, H., (1963), The Role of Adrenocortical Steroids in the Control of Human Sebaceous Gland Activity. J. invest. Derm., 41, 391.

Pochi, P.E., and Strauss, J.A., (1963), Sebaceous Gland Function Before and After Bilateral Orchiectomy.

Arch. Dermat. (Chicago) 88, 729.

Pochi, P.E., Strauss, J.S., Rao, G.S., Sarda, I.R., Forchielli, E., and Dorfman, R.L. (1965), Plasma Testosterone and Oestrogen Levels, Urine Testosterone Excretion and Sebum Production in Males with Acne Vulgaris. J. clin. Endocr., 25, 1660.

Pochi, P.E., and Strauss, J.S., (1969), Sebaceous Gland Response in Man to the Administration of Testosterone, Δ^4 -Androstenedione and Dehydroepiandrosterone.

J. invest. Derm., 52, 32.

Rauschkolb, E.W., Davis, H.W., Fenimore, D.C., Black, H.S., and Fabre, L.F. (1969), Identification of Vitamin D₃ in Human Skin. J. invest. Derm., 53 (4), 289.

Roberts/

- Roberts, S., and Szregó, C.M., (1955), The Importance of DPN-Linked Dehydrogenases in the Interconversions of Steroids in the Body. *Ann. Rev. Bioch.* 24, 543.
- Rongone, E.L., (1966), Testosterone Metabolism by Human Male Mammary Skin. *Steroids* 7, 489.
- Rongone, E.L., Hill, M., and Burns, R., (1967), Testosterone Metabolism by Chicken Uropygial Gland. *Steroids* 10, 425.
- Rony, H.R., and Zakon, S.J., (1943), Effects of Androgen on the Sebaceous Glands of Human Skin. *Arch. Dermatol. & Syph.*, 33, 9.
- Samuels, L.T., and Gordon, E.S., (1950), A Symposium on Steroid Hormones. *Madison*, 241.
- Samuels, L.T., Helmreich, M.L., Lasater, M.B., and Reich, H.,** (1951), An Enzyme in Endocrine Tissues which Oxidizes Δ^3 -Hydroxysteroids to α , β Unsaturated Ketones. *Science* 113, 490.
- Samuels, L.T., Helmreich, M.L., and Lasater, M.D., (1951), Abstracts 12th International, Congr. Pure and Appl. Chem., 108, N.Y.
- Saunders, H.L., and Ebling, F.J., (1969), The Antiandrogenic and Sebaceous Gland Inhibitory Activity of 6α , 6β -Ethylene 17α -Me- β -Nortestosterone. *J. invest. Derm.*, 52, (2), 163.

Savard/

Savard, K., Marsh, J.M., and Price, B.F., (1965), Gonadotropins and Ovarian Steroidogenesis.

Recent Prog. Hormone Res. 21, 285.

Schroepfer, G.J., and Frantz, I.D., (1961), Conversion of Δ^7 -Cholestenol -4-¹⁴C and 7-Dehydrocholesterol -4-¹⁴C to Cholesterol.

J. biol. Chem., 236, 3137

Shuster, S., (1969), Bioassay of Androgens and Anti-Androgens in the Rat Sebaceous Gland.

In Assay Methods in Invest. Derm., Syntex Symposium.

Sih, C.J., and Whitlock, H.W., (1968), Biochemistry of Steroids.

Ann. Rev. Bioch., 37, 661.

Slaunwhite, W.R., and Samuels, L.T., (1956), Progesterone as a Precursor of Testicular Androgens

J. biol. Chem., 220, 341.

Smith, M.A., and Waterworth, P.M., (1961), Bacteriology of Acne Vulgaris in Relation to its Treatment with Antibiotics.

Brit. J. Derm., 73, 152.

Sobel, H., (1949), Squalene in Sebum and Sebum-Like Materials.

J. invest. Derm., 13, 333.

Southern, A.L., Tochimoto, S., Carmody, N.C., and Isuruki, K.,
(1965), Plasma Production Rates of Testosterone in Normal Adult Men and Women and in Patients with the Syndrome of Testicular Feminization.

J. clin. Endocr., 25, 1441.

Strauss/

Strauss, J.S., and Kligman, A.M., (1960), The Pathological Dynamics of Acne Vulgaris.

Arch. Derm., Chicago 82, 779.

Strauss, J.S., and Kligman, A.M. (1961), The Effect of Progesterone and Progesterone-Like Compounds of Human Sebaceous Glands. J. invest. Derm., 36, 309.

Strauss, J.S., and Pochi, P.E., (1961), The Quantitative Gravimetric Determination of Sebum Production. J. invest. Derm., 36, 293.

Strauss, J.S., Kligman, A.M., and Pochi, P.E., (1962), The Effect of Androgens and Oestrogens on Human Sebaceous Glands. J. invest. derm., 39, 139.

Strauss, J.S., and Pochi, P.E., (1963), The Human Sebaceous Gland: Its Regulation by Steroidal Hormones and its Use as an End Organ for Assaying Androgenicity in vivo. Rec. Prog. Horm. Res. 19, 385.

Strauss, J.S., and Pochi, P.E., (1964), Effect of Cyclic Progestin Oestrogen Therapy on Sebum and Acne in Women. J.A.M.A., 190, 815.

Strauss, J.S., Pochi, P.E., Sarda, I.R., and Wotiz, H.H.,
(1969), Effect of Oral and Topical 17- α -Me- β -Nortestosterone on Sebum Production and Plasma Testosterone. J. invest. Derm., 52, 95.

Strauss/

- 220
- Strauss, J.S., and Pochi, P.E., (1969), Recent Advances in Androgen Metabolism and Their Relation to the Skin. (Review article)
Arch. Derm., 100, 621.
- Stuart, J., Bitensky, L., and Chayen, J., (1969), Quantitative Enzyme Cytochemistry of Leukemic Cells.
J. clin. Path., 22, 563.
- Susskind, R.R., (1951), The Chemistry of the Human Sebaceous Gland
J. invest. Derm., 17, 37.
- Takayasu, S., and Adachi, K., (1969), Hormonal Control of the Metabolism of Hamster Sebaceous Gland.
J. invest. Derm., 52, 371.
- Talalay, P., and Dobson, M.M., (1953), Purification and Properties of a β -Hydroxysteroid Dehydrogenase
J. biol. Chem., 205, 823.
- Talalay, P., and Wang, V.S., (1955), Enzymic Isomerisation of Δ^5 -3-Keto Steroids.
Biochem. Biophys. Acta 18, 300.
- Talalay, P., and Marcus, P.I., (1956), Specificity, Kinetics and Inhibition of α and β -Hydroxysteroid Dehydrogenases.
J. biol. Chem., 218, 675.
- Talalay, P., (1957), Enzymic Mechanisms in Steroid Metabolism.
Physiol. Revs. 37, 362.
- Talalay/

- 230
- Talalay, P., (1960), Enzymic Analysis of Steroid Hormones in Methods of Biochemical Analysis 8, 119.
- Thiessen, D.D., Friend, H.C., and Lindzey, G., (1968), Androgen Control of Teritorial Marking in the Mongolian Gerbil Science 160, (3826), 432.
- Thornburg, W., and Mengers, P.E., (1957), An Analysis of Frozen Section Techniques I Sectioning of Fresh Frozen Tissue. J. histochem. Cytochem. 5, 47.
- Tsou, K.C., Cheng, C.S., Nachlas, M.M., and Seligman, A.M**
(1956), Syntheses of Some p-Nitrophenyl Substituted Tetrazolium Salts as Electron Acceptors for the Demonstration of Dehydrogenases. J. Am. Chem. Soc. 78, 6139.
- Turfitt, G.E., (1946), The microbiological Degradation of Steroids 3. Oxidation of Hydroxysteroids to Keto-Derivatives by Proactinomyces spp. Bioch. J. 40, 79.
- Vadasz, E., and Debreczeni, M., (1966), Beitrage Zum Hormonalen Hintergrund Der Akne. Ztschft. f. Haut u. Geschl, 40, (2), 34.
- Warren, J.C., and French, A.P., (1967), Distribution of Steroid Sulfatase in Human Skin. J. clin. Endocr. 25, 278.
- Wattenberg/

Wattenberg, L.W., (1958), Microscopic Histochemical Demonstration
of Steroid - 3β -O α -Dehydrogenase in Tissue Sections
J. histochem. Cytochem. 6, 225.

Wheatley, V.R., The Chemical Composition of Sebum. Jubilaiae
1901 - 1951 De La Soc. Belge De Dermat.
Syphil. pp. 90-102.

Wheatley, V.R., (1953), Some Aspects of the Nature and Function of Sebum
St. Bartholemew's Hosp., J., 57, 5.

Wilde, P.F., and Ebling, F.J., (1969), Preliminary Observations on the
Composition of Skin Surface Fat from Rats Treated with Testosterone
and Oestradiol.
J. invest. Derm., 52, 362,

Wilson, J.D., and Walker, J.D., (1969), The Conversion of Testosterone
to 5α -Androstan- 17β -O α -3-One (Dihydrotestosterone) by Skin Slices
of Man.
J. clin. Invest., 48, 371.

Zackheim, H.S., (1968), Effect of Prolonged Administration of Testosterone
on the Epidermis of Female Rats.
J. invest. Derm., 50, 401.