



University
of Glasgow

<https://theses.gla.ac.uk/>

Theses Digitisation:

<https://www.gla.ac.uk/myglasgow/research/enlighten/theses/digitisation/>

This is a digitised version of the original print thesis.

Copyright and moral rights for this work are retained by the author

A copy can be downloaded for personal non-commercial research or study, without prior permission or charge

This work cannot be reproduced or quoted extensively from without first obtaining permission in writing from the author

The content must not be changed in any way or sold commercially in any format or medium without the formal permission of the author

When referring to this work, full bibliographic details including the author, title, awarding institution and date of the thesis must be given

Enlighten: Theses

<https://theses.gla.ac.uk/>
research-enlighten@glasgow.ac.uk

DERMATITIS HERPETIFORMIS : SMALL-INTESTINAL
AND IMMUNOLOGICAL STUDIES

N.G. FRASER

M.B., Ch.B., M.R.C.P.E., D.Obst.R.C.O.G.

Thesis submitted for the degree of Doctor of Medicine of the
University of Glasgow.

May, 1972

ProQuest Number: 10647763

All rights reserved

INFORMATION TO ALL USERS

The quality of this reproduction is dependent upon the quality of the copy submitted.

In the unlikely event that the author did not send a complete manuscript and there are missing pages, these will be noted. Also, if material had to be removed, a note will indicate the deletion.



ProQuest 10647763

Published by ProQuest LLC (2017). Copyright of the Dissertation is held by the Author.

All rights reserved.

This work is protected against unauthorized copying under Title 17, United States Code
Microform Edition © ProQuest LLC.

ProQuest LLC.
789 East Eisenhower Parkway
P.O. Box 1346
Ann Arbor, MI 48106 – 1346

CONTENTS

	Page
INTRODUCTION	1
DIAGNOSIS OF DERMATITIS HERPETIFORMIS	5
PART I STRUCTURE AND FUNCTION OF THE SMALL-INTESTINE	
Introduction	15
Patients and methods	16
Results	20
Discussion	27
Summary	43
PART II SERUM IMMUNOGLOBULINS	
Introduction	50
Patients and methods	51
Results	55
Discussion	58
Summary	68
PART III SERUM AUTOANTIBODIES	
Introduction	74
Patients and methods	75
Results	76
Discussion	78
Summary	85

	Page
GENERAL DISCUSSION	89
CONCLUSIONS	95
ACKNOWLEDGEMENTS	97
REFERENCES	100
APPENDIX	125

INTRODUCTION

Dermatitis herpetiformis is a comparatively uncommon skin disease characterised by chronic relapsing lesions affecting predominantly the elbows, knees, shoulders, buttocks area and scalp. As indicated by the name, the hall mark of the disease is the appearance of grouped vesicles on an erythematous base, as occurs in herpes simplex or herpes zoster; but commonly various other primary and secondary lesions occur, and these may make the diagnosis less obvious. The eruption is normally accompanied by severe itching, but fortunately a good response is usually obtained with the empirical use of the drugs dapsone or sulphapyridine. The dose of dapsone, the drug most commonly used, necessary to control dermatitis herpetiformis is very variable, and it was this fact which prompted the initiation of this investigation: the hypothesis being tested was that dapsone induced a malabsorption state with consequent variable absorption of the drug. Several months after the study began, Marks, Shuster and Watson (1966) reported, in a preliminary communication, the finding of small-intestinal abnormalities in dermatitis herpetiformis; and these changes were present in some patients who had never received specific drug therapy for their disease. The initial findings in the present study were similar to those of Marks and her colleagues (Fraser et al., 1967), and so, the investigation was/

was continued over a five year period to delineate further the enteropathy of dermatitis herpetiformis. Also, the report by Fry et al. (1967), on study of a small group of patients with dermatitis herpetiformis, of the occurrence of an incidence of serum IgM deficiency similar to that of coeliac disease, prompted the study of serum immunoglobulin levels in a larger group of dermatitis herpetiformis patients to try to determine whether a relationship existed between these levels and the presence of disease in the skin or the small-intestine. In addition to the findings of Fry et al. (1967) on serum immunoglobulins, the reports of immunoglobulins in the skin (Cormane, 1967; Van der Meer, 1969; Cormane et al., 1970) and the demonstration of gluten sensitivity in the small-intestine (Shuster et al., 1968) suggested that the occasional occurrence of putative autoimmune disease in patients with dermatitis herpetiformis might not be coincidental but part of the spectrum of immunological abnormalities present in this disease: the incidence of serum autoantibodies was determined to investigate this possibility.

The study, therefore, was carried out in three parts. In the first, the structure and function of the small-intestine in dermatitis herpetiformis was determined with particular reference to the use of the small-intestinal biopsy capsule. In addition to histological assessment of the mucosa, disaccharidase enzyme concentrations were assayed in some specimens, and the effect of the/

the mucosal abnormalities on the patient was investigated.

Serum immunoglobulins were assayed in the second part of the study, and evidence to substantiate a specific relationship between immunoglobulin levels and the skin eruption was sought by measuring serum immunoglobulin and complement (C'3) levels at different phases of disease activity. Patterns of serum immunoglobulin levels in various skin diseases, not associated with definite small-intestinal abnormalities, were also ascertained, to exclude a non-specific effect of skin disease on serum immunoglobulins.

In the third part of the study, the incidence of anti-thyroid, anti-gastric and anti-nuclear antibodies was determined in a group of patients with dermatitis herpetiformis, and in a control group matched for age and sex. Further interpretation of the results obtained was sought by relating serum autoantibodies to the small-intestinal biopsy grading (determined in Part I) and serum immunoglobulin levels (determined in Part II).

The results obtained in this study were of some immediate interest and significance during the period when the investigation was being carried out, and so part of the material forming the thesis has already been published.

The papers containing this material are as follows:-

Fraser, N.G. (1970) Autoantibodies in Dermatitis Herpetiformis. Br. J. Derm., 83, 609.

Fraser, /

Fraser, N.G., Beck, J.S. & Albert-Recht, F. (1971) Serum Complement (C'3) and Immunoglobulin Levels in Dermatitis Herpetiformis. *Br. J. Derm.*, 85, 314.

Fraser, N.G., Dick, Heather M. & Crichton, W.B. (1969) Immunoglobulins in Dermatitis Herpetiformis and Various Other Skin Diseases. *Br. J. Derm.*, 81, 89.

Fraser, N.G., Ferguson, Anne & Murray, D. (1968) Dermatitis Herpetiformis in Two Patients with Idiopathic Steatorrhoea (Adult Coeliac Disease). *Br. med. J.*, 4, 30.

Fraser, N.G., Murray, D. & Alexander, J.O'D. (1967) Structure and Function of the Small Intestine in Dermatitis Herpetiformis. *Br. J. Derm.*, 79, 509.

McNeish, A.S., Fraser, N.G. & Morley, W.N. (1970) Dermatitis Herpetiformis in a Treated Coeliac Child. *Archs Dis. Childh.*, 45, 279.

Finally, as the concept of dermatitis herpetiformis has been modified since the first description by Duhring in 1884, it was necessary first, before presenting the three parts of the investigation, to discuss the modern concept of this disease and the criteria used in diagnosis.

DIAGNOSIS OF DERMATITIS HERPETIFORMIS

Historical Concept

In 1884, Duhring described a number of different clinical manifestations affecting the skin which he believed were due to the same basic morbid process. The different clinical types were categorized according to the predominant primary lesion - erythematous, papular, vesicular, bullous, pustular; the title multiform was given to the type in which no particular lesion predominated. The belief that all these forms represented the same disease process was based on the observation that changes from one type to another could occur at different times in the same patient. The disease was designated dermatitis herpetiformis: the term herpetiformis being used because of the tendency of the primary lesions to occur in groups, a feature noted by Duhring in all his cases. Other characteristics emphasized by Duhring were that the disease was usually chronic, with a "disposition to appear in repeated successive outbreaks"; was marked by severe itching; and was "exceedingly rebellious to treatment". Four years later, Brocq, in agreeing with the above concept, emphasized the polymorphous nature of the eruption and the outstanding symptomatic feature, intense itching or pain, in the title "dermatitis polymorphe douloureuse". However, although the concept of dermatitis herpetiformis is normally attributed to Duhring and Brocq, /

Brocq, Tilbury Fox had clearly described this entity in 1880 in the paper "A Clinical Study on Hydroa" published posthumously by his brother Colcott Fox.

The original concept of dermatitis herpetiformis, however, was wide, including such diseases as impetigo herpetiformis (Hebra, 1872) and herpes gestationis (Bulkley, 1873), and diseases more recently delineated - pemphigoid (Lever, 1953), subcorneal pustular dermatosis (Sneddon and Wilkinson, 1956) and juvenile pemphigoid (Kim and Winkelmann, 1961). These diseases are now regarded at least for purposes of definition, as separate diseases, although exact classification awaits further information. The historical concept, therefore, having been modified, it seems likely that dermatitis herpetiformis, as it is now understood, is a single disease entity, a conclusion accepted by Tolman et al. (1959) in their discursive paper on this subject.

Criteria for Diagnosis

Nowadays, several criteria are used in the diagnosis of dermatitis herpetiformis and these will be considered in turn.

Clinical features - The disease may start as a localised eruption, e.g. on the elbows, which after a period of months or years becomes widespread, or, it may be generalised from the beginning. In relation to the primary lesions, reference may still be made to the careful description of Duhring. The vesicular/

vesicular variety is the most common, the vesicles being of different sizes varying from a pin-head to a pea. These are firm, tensely distended, arising usually from normal coloured skin when single but with a marked tendency to aggregate in small clusters upon a slightly raised erythematous base (thus the resemblance to herpetic infections) (Fig. 1, 2). Less common is the erythematous variety in which erythematous patches occur which if oedematous resemble urticaria and if confluent show marginate outlines (Fig. 3). Maculo-papules and vesico-papules may also be seen in this form making the true diagnosis more obvious. Duhring's pustular form of dermatitis herpetiformis is less clearly defined than the previous two forms as the pustules are commonly intermingled with vesicles and bullae. A pustular form may, however, precede or appear at intervals during the course of the more common vesicular variety. The papular variety is probably less uncommon than Duhring suggested (Bolger and Chastanet, 1963) and is characterised by groups of small or large pea-sized papules generally excoriated from scratching. Bullae (i.e. blistering lesions >1 cm diameter) are rare in dermatitis herpetiformis although they may be seen in the exacerbation following withdrawal of suppressive therapy (Rook et al., 1968). In some patients different primary lesions may occur without the predominance of any (the multiform variety of Duhring). Lesions of the oral mucosa are rare and transient/

transient (Rook et al., 1968), and involvement of other mucous membranes has not been reported. Secondary lesions, particularly excoriated primary lesions, are common, and occasionally crusting and eczematization may be seen. Healing of the lesions of dermatitis herpetiformis is often followed by pigmentation and scarring.

The distribution of dermatitis herpetiformis is highly characteristic there being a marked predilection for the extensor surfaces of the elbows and knees, shoulders, buttocks area and natal cleft and the scalp. Any part of the integument may, however, be affected.

Slight constitutional symptoms may precede or accompany an exacerbation of the disease, but the marked symptomatic feature of dermatitis herpetiformis is severe itching or burning. Rupture of vesicles by scratching commonly produces relief of itching.

As already stated, the course of the disease is chronic and variable with periods of spontaneous remission which may be complete and last for years. More commonly, however, the eruption does not completely disappear during these periods, and the disease persists for many years or indefinitely.

The age and sex of the patient are of little help when considering the clinical diagnosis of dermatitis herpetiformis, although the disease is uncommon below the age of 5 years (Kim and Winkelmann, 1961) and over the age of 60 years/

years (Smith, 1966): males are affected about twice as often as females (Eyster and Kierland, 1951).

Skin biopsy - Aggregation of neutrophils and eosinophils in the dermal papillae with associated oedema and later vesicle formation was first suggested to be pathognomonic for dermatitis herpetiformis by Allen (1954). These papillary microabscesses can be seen in early lesions and lead to the formation of multilocular bullae (Fig. 4). In later lesions they can often be seen at the periphery of unilocular blisters. These views were endorsed by the studies of Pierard and Whimster (1961) and MacVicar et al. (1963). Other authors, however, doubted the specificity of the papillary microabscesses and indicated that these could also form at the periphery of bullae in pemphigoid (Bolger and Chastanet, 1963; Jablonska and Chorzelski, 1963; Lever, 1965). Nevertheless, more recently Lever (1967) has stated that "the presence of an early multilocular vesicle with microabscesses at the tip of each papilla can be regarded as diagnostic for dermatitis herpetiformis", these features being best seen in "an erythematous area without clinically visible vesicles". The biopsy, therefore, of an early lesion in dermatitis herpetiformis will confirm the diagnosis; but unfortunately these lesions are often quickly excoriated thus destroying the distinctive histological features. This difficulty can be overcome, however, by making use of the ability of iodides/

iodides to induce an exacerbation of the skin eruption. This aid to diagnosis will now be considered.

Potassium iodide provocation test - The sensitivity of patients with dermatitis herpetiformis to iodides, whether applied locally as a patch test or taken orally, has long been recognised (Goldsmith, 1936). Felsher (1947a) studied the nature of the adherence of the epidermis to the dermis to help elucidate this iodide effect. He concluded that the property of the iodide anion to swell collagen and thus decrease the adhesion between the epidermis and the dermis could be responsible for the induction of blistering in dermatitis herpetiformis by iodides. In a later paper Felsher (1947b) by applying 20% potassium iodide in petrolatum locally produced epidermal-dermal separation in patients with dermatitis herpetiformis: unfortunately, he does not record a histological assessment of the one positive reaction obtained in 30 normal control subjects. Alcon (1947), however, questioned the specificity of this test by demonstrating that positive patch test reactions occurred in about one third of patients with various dermatoses. Again, the possibility of these reactions being due to a primary irritant or sensitivity reaction to the iodide was not excluded histologically. Little information is available on the use of an oral dose of potassium iodide to induce an exacerbation of dermatitis herpetiformis/

herpetiformis but Eyster and Kierland (1951) reported the test positive in 78% of the group of dermatitis herpetiformis patients studied. In the same series the potassium iodide patch test was positive in only 50% of patients. It would appear, therefore, that the oral test, as would be expected in view of the poor penetration of iodides through intact skin (Rothman, 1954), is more helpful in the diagnosis of dermatitis herpetiformis and does not present the same problems of local irritation or sensitivity. The test should probably be used, however, to obtain a lesion suitable for skin biopsy, thus avoiding the possibility of false positive reactions (Andrews, 1946; Urbach and Le Winn, 1946).

Potassium iodide, administered orally in a dose of 1.5-2 g to adult patients suspected clinically of suffering from dermatitis herpetiformis, was used on a number of occasions when patients presented during a quiescent phase of the disease (Fig. 5), so that a lesion suitable for biopsy could be obtained (Fig. 6). The ability of oral KI to induce an exacerbation of the rash of dermatitis herpetiformis was also utilised during the study of immunoglobulin and complement levels at different phases of disease activity (Part II).

Therapeutic test with dapsone - Experience in the treatment of dermatitis herpetiformis with dapsone, following the initial usage by Esteves and Brandao (1950) and Cornbleet (1951), caused some authors to suggest that the drug could/

could be used as a therapeutic test for the disease (Laptev and Smelov, 1958; Van Ketel, 1960; March and Sawicky, 1962). Smith (1966), in his paper "The Diagnosis of Dermatitis Herpetiformis", sought to evaluate the position of dapsone as a therapeutic test for diagnosis of this disease. From his studies of patients with dermatitis herpetiformis attending St. John's Hospital for Diseases of the Skin over a 10 year period, he suggested that many of the patients diagnosed clinically as dermatitis herpetiformis and not responding to dapsone therapy were examples of other diseases. However, he admitted that some patients unresponsive to dapsone clearly did conform to the clinical picture of this disease. Conversely, some of the skin biopsies performed from the group of patients said to respond to dapsone therapy showed the histological features of other diseases. Although Smith concluded that this test was valuable as an aid to diagnosis, the fallacies which he noted limit its reliability, and so it was not used in the present study.

Differential Diagnosis

Undoubtedly, to the experienced observer the occurrence of herpetiform skin lesions in the classical distribution of dermatitis herpetiformis makes the diagnosis reasonably secure. No difficulty should be experienced in differentiating dermatitis herpetiformis from the blistering eruption of pregnancy, herpes gestationis, and only rarely will pemphigoid, occurring as/

as it does in the elderly and associated with large tense bullae which excite only mild itching, cause difficulty in differential diagnosis. Occasionally, however, the non-specific eruption which commonly precedes the full-blown clinical picture of pemphigoid may be confused with dermatitis herpetiformis (Sneddon and Church, 1955), and the true diagnosis only becomes clear in retrospect. In juvenile pemphigoid the bullous nature of the eruption, the distribution and the relative absence of pruritus distinguish it from dermatitis herpetiformis occurring in children (Kim and Winkelmann, 1961; Ganpule, 1967; Grant, 1968). Also, although the above mentioned diseases are all characterised by subepidermal blister formation, as indicated previously, the histological changes in the skin in dermatitis herpetiformis are distinctive provided that an early lesion is biopsied. Pemphigus and subcorneal pustular dermatosis, the other chronic blistering diseases normally considered in this context, should not provide serious difficulty in differential diagnosis as, in addition to the clinical appearances, the histological features are quite different from those in dermatitis herpetiformis.

Unfortunately, however, in some patients with dermatitis herpetiformis frank blistering only occurs sporadically largely due to the excoriation of early lesions by the patient. In these non-blistering phases of the disease diagnosis on clinical grounds alone is indeed hazardous. Confusion with scabies, /

scabies, generalised pruritus (from any cause) with excoriation, neurodermatitis, papular "ide" eruptions (e.g. from stasis dermatitis), chronic folliculitis or pityriasis lichenoides may occur. Less commonly there may be confusion with urticaria in the erythematous variety of dermatitis herpetiformis, and when secondary eczematization is prominent a diagnosis of one of the clinical varieties of dermatitis may be mistakenly made. It is in the non-blistering phases of dermatitis herpetiformis that the potassium iodide provocation test is particularly useful in establishing the diagnosis.

Summary

The diagnosis of dermatitis herpetiformis may be regarded as established when, in a patient suspected clinically of suffering from this disease, skin biopsy of an early lesion shows the features of multilocular vesicles with papillary microabscesses; the lesion erupting spontaneously or being induced by oral potassium iodide.

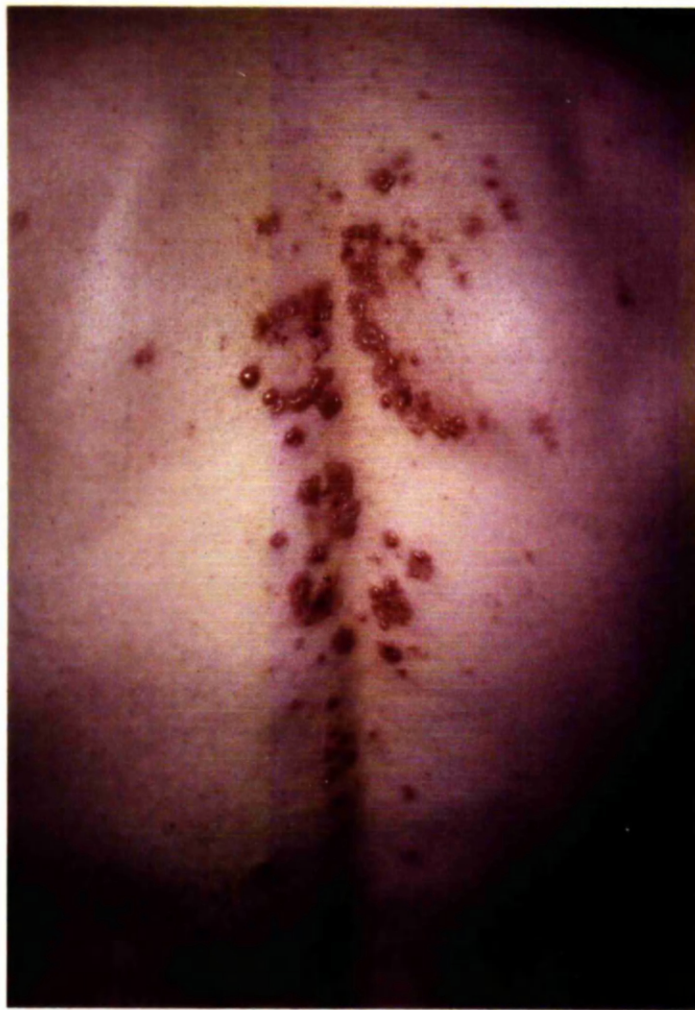

Fig. 1. - Grouping of vesicular lesions on the back of a patient with dermatitis herpetiformis.

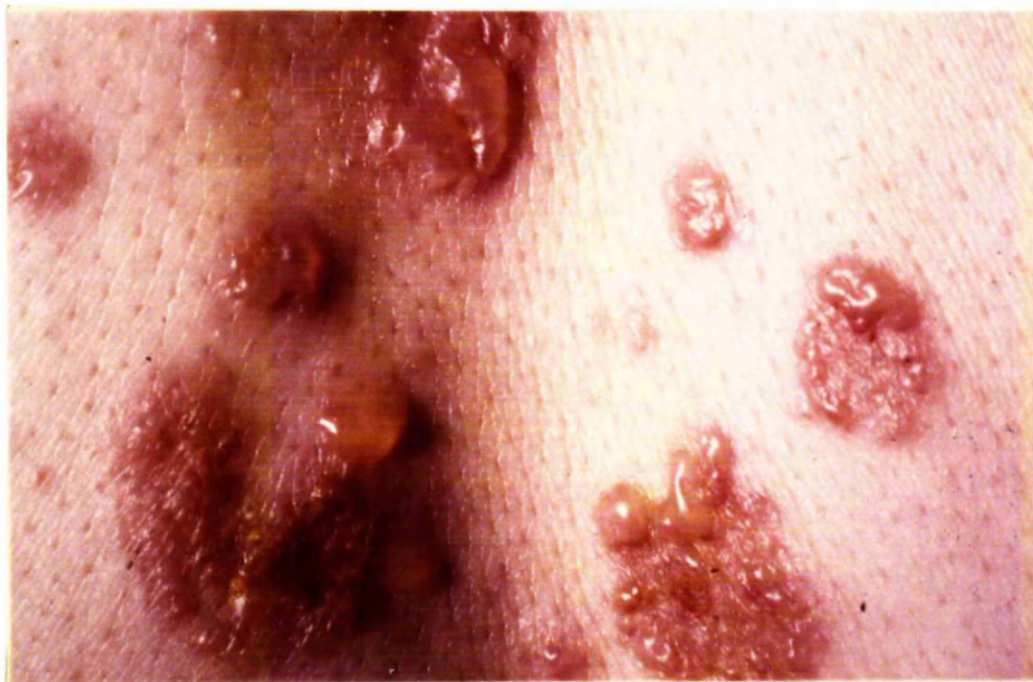

Fig. 2. - Detail of Fig. 1.

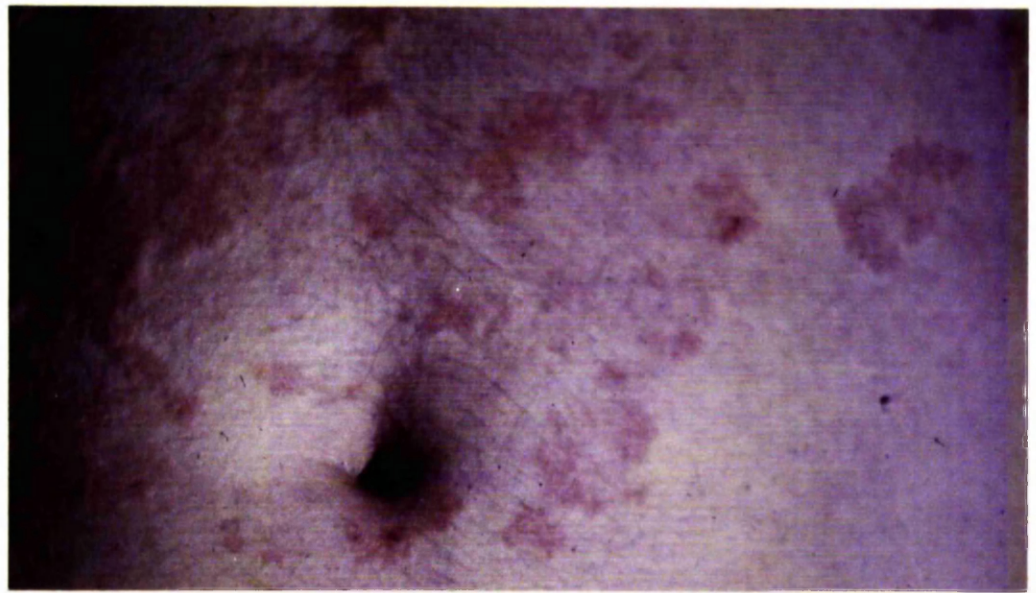

Fig. 3. - Erythematous variety of dermatitis herpetiformis with eruption resembling urticaria.

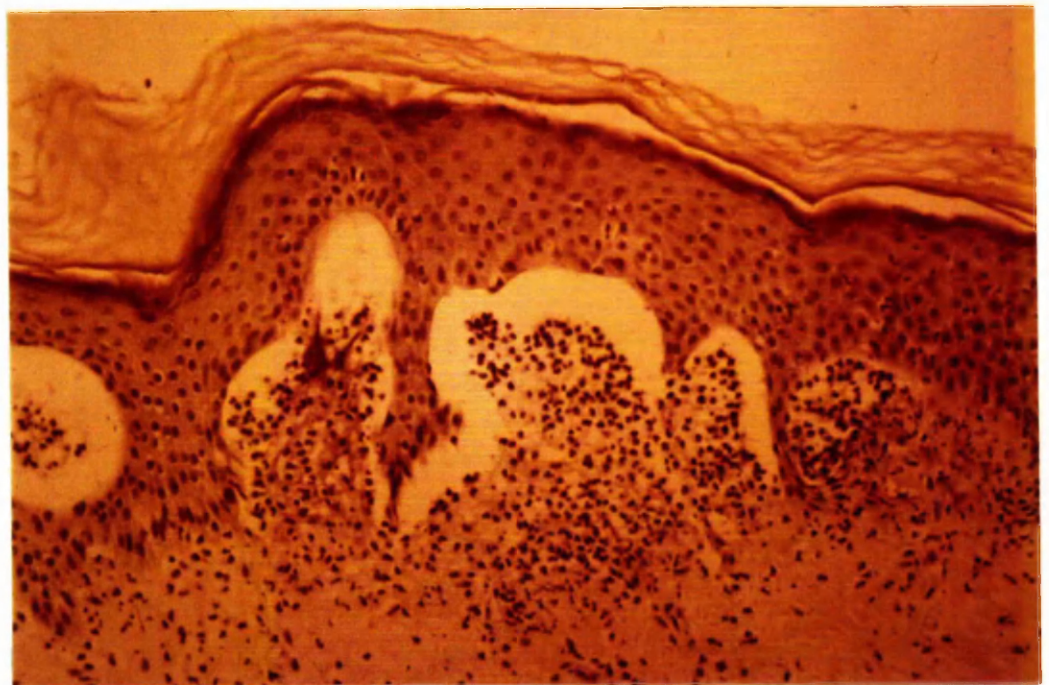


Fig. 4. - Skin histology in dermatitis herpetiformis showing typical papillary microabscesses with early subepidermal blister formation. H. and E. x 100.

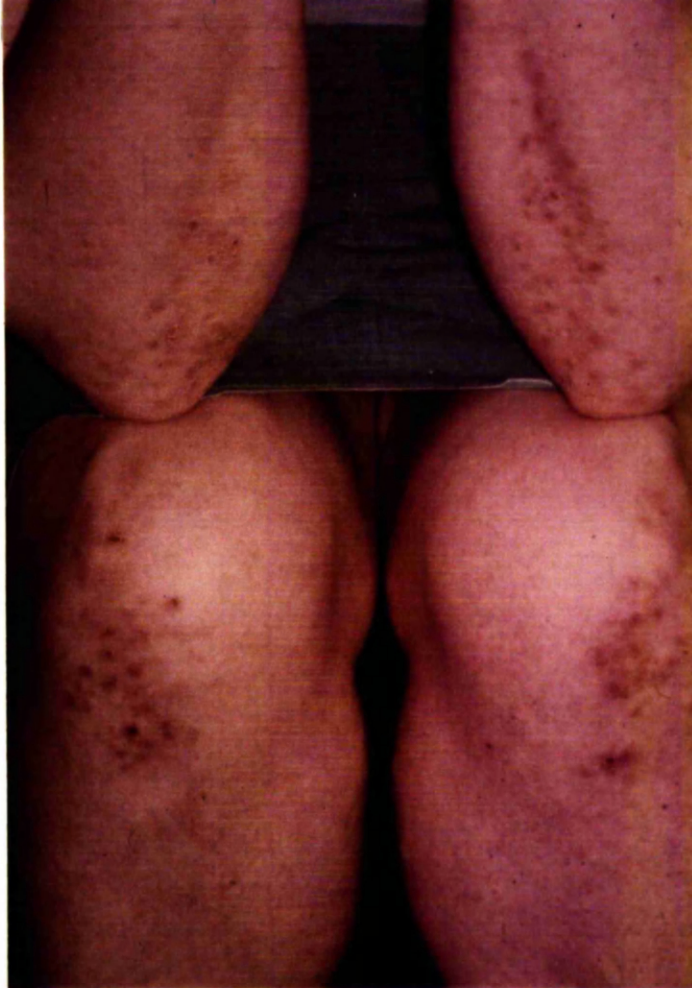

Fig. 5. - Excoriated papular lesions on elbows and knees during a relatively quiescent phase of the disease process.

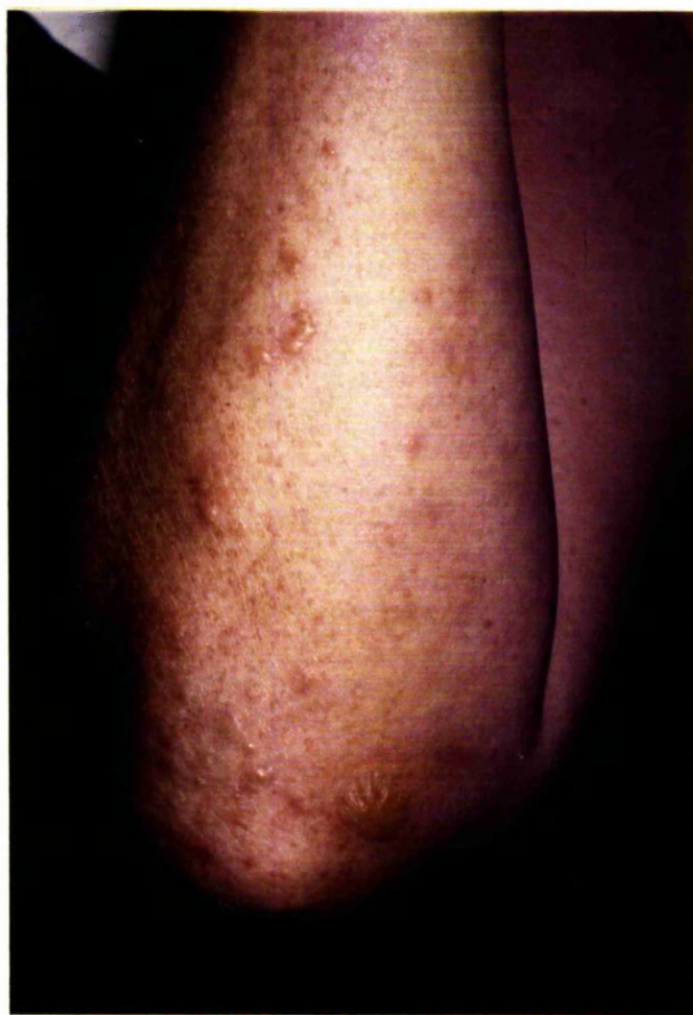

Fig. 6. - Blistering induced by oral medication.

PART I

STRUCTURE AND FUNCTION OF THE SMALL-INTESTINE

INTRODUCTION

Following the introduction of sulphone drugs in the treatment of dermatitis herpetiformis by Esteves and Brandao (1950) and Cornbleet (1951), it soon became apparent that the dose of the drug required to control the eruption varied widely from patient to patient (Kruizinga and Hamminga, 1953; Calnan, 1954; Alexander, 1955). At the time the work of this thesis began it had recently been noted that the drugs triparanol and neomycin could induce a malabsorption state (Jacobson et al., 1960; Hvidt and Kjeldsen, 1963; McPherson and Summerskill, 1963) and so a pilot study of the structure and function of the small-intestine in dermatitis herpetiformis was undertaken to evaluate the possibility of dapsone, the sulphone normally used in treatment, inducing malabsorption with consequent variability of absorption of the drug. Little evidence to suggest malabsorption was present in the literature although, even before the advent of dapsone therapy, patients with dermatitis herpetiformis were noted to be often poorly nourished and debilitated (Becker and Obermayer, 1944). Smith (1966), however, in his review of dermatitis herpetiformis, had described two patients on dapsone therapy who had an associated malabsorption syndrome.

After the investigation began, it quickly became evident that while abnormalities of the structure and function of the small-intestine were indeed present, /

present, dapsone therapy alone could not be held responsible, as these abnormalities were noted in some patients before treatment. These initial findings were in agreement with the preliminary communication of Marks, Shuster and Watson (1966) on this subject. Consequently, the first part of this study was concerned with delineating the incidence, nature and effect of the enteropathy in patients with dermatitis herpetiformis.

PATIENTS AND METHODS

60 patients (males, 37; females, 23) with dermatitis herpetiformis were studied. All were adults apart from 2 boys of 8 years. The clinical diagnosis was confirmed by skin biopsy in 55 patients: the other 5 patients were seen during a quiescent phase of the disease and before the use of the potassium iodide provocation test. These latter patients were not excluded from the study as the clinical features were otherwise typical of dermatitis herpetiformis.

42 patients were from the geographical area of the Western Regional Hospital Board and 18 from the area of the North-Eastern Regional Hospital Board. All patients were investigated as in-patients in Glasgow and Aberdeen respectively.

27 of the 60 patients in the series were not on any specific drug therapy at the time of small-intestinal investigation, 5 were on sulphapyridine and the remainder, 28, on dapsone.

A clinical history with particular reference to gastro-intestinal symptoms was/

was obtained. A family history of skin or intestinal disease was sought.

The heights and weights of patients were recorded.

Gastrointestinal Investigations

Small-intestinal biopsy - Peroral biopsy of the small-intestine was carried out with the Watson capsule (Fig. 7) (Crosby and Kugler, 1957). The patient swallowed the capsule in the evening and the following morning, provided the position was satisfactory on radiological examination (Fig. 8), the capsule mechanism was fired by firm suction on the free end of the tubing with a 10 ml glass syringe, and the tube withdrawn. In some instances, further time was required for the progress of the capsule, and then the patient was positioned on the right side if the duodenum had not been reached, and on the left side if the capsule was already beyond the first part of the duodenum. Not all specimens, however, were obtained from the first 20 cm of the jejunum, the area aimed for, 6 being taken from the distal duodenum because of slow progress of the capsule. In a few patients the test had to be repeated due to premature firing or non-firing of the capsule or separation of the cap from the body of the capsule. Small-intestinal biopsy was repeated in 3 patients, 2, 8 and 12 months respectively after starting dapsone therapy. No serious complications of this investigation occurred during the survey. Two patients, however, were excluded from this part of the study because of failure to swallow the/

the capsule in one, and failure of the capsule to enter the duodenum in the other. In 2 patients (no. 25 and 35) this investigation was performed in medical units before the development of dermatitis herpetiformis and, in view of the institution of a gluten-free diet, these results rather than those of subsequent biopsies are used for purposes of classification. Complete clinical history and findings in these 2 patients are recorded in the Appendix.

The specimens obtained were immediately placed in 10% formalin solution for later examination under the dissecting and conventional microscopes except in those patients in whom disaccharidase enzyme activity was to be measured. In those patients, the specimens obtained were divided into two parts, one part being placed in the formalin solution and other part immediately weighed on a microtorsion balance and then homogenized in at least 1 ml of ice cold distilled water. If the piece of tissue weighed more than 10 mg the volume was adjusted to give a tissue concentration of 10 mg/ml. Disaccharidase activity (maltase, lactase and sucrase) was assayed immediately thereafter (Dahlqvist, 1964).

Xylose-tolerance test - The test was performed in 50 patients; a 25 g dose was given to 18 patients and a 5 g dose to 32. Patients over 60 years were not tested as deterioration in renal function with age reduces xylose excretion (Kendall, 1970). The patients fasted overnight and after the oral dose of xylose the/

the amount of the sugar excreted in the urine in the next five hours was measured (Roe and Rice, 1948). The lower limit of normal for urinary xylose excretion in five hours was taken as 4.1 for a 25 g dose and 1.2 for a 5 g dose.

Faecal-fat excretion - Stools were collected over a five day period on 27 occasions, and over a three day period on 8 occasions, with patients on a normal ward diet. Faecal-fat content was estimated by the method of Van de Kamer et al. (1949). An excretion of more than 5 g per day was considered abnormal.

Small-bowel barium meal - This investigation was performed in 12 patients.

Lactose tolerance test - An oral dose of 50 g lactose was given to 8 patients after an overnight fast and total reducing substances were measured in blood samples obtained immediately before the lactose was given and at half-hourly intervals thereafter for 2 hours (McMichael et al., 1965). In one patient the dose of lactose administered was 100 g. Normally, the concentration of reducing substances in the blood rises by more than 25 mg per 100 ml,

Haematological Investigations

Peripheral-blood examination - This consisted of haemoglobin concentration, packed cell volume, mean corpuscular haemoglobin concentration, white blood count and film. A reticulocyte count was performed on patients who were/

were on dapsone therapy.

Bone-marrow examination - This was only performed in some patients with non-dapsone induced anaemia.

<u>Serum iron</u> (normal range — 70 - 160 ug/100 ml))	
<u>Serum vitamin B₁₂</u> (normal range — 160 - 800 uug/ml))	These assays
<u>Serum folate</u> (normal range — 4 - 18 mug/ml))	

were undertaken in only a few patients in whom anaemia was present.

Clearance of ⁵¹Cr-labelled heat-damaged red cells (Marsh et al., 1966) -

This test of splenic function was performed in 1 patient in whom the presence of Howell-Jolly bodies in the red cells suggested the existence of splenic atrophy.

Biochemical Investigations

Serum-calcium, serum alkaline phosphatase and serum proteins were estimated by standard procedures.

RESULTS

Clinical Findings

A history of chronic diarrhoea which could not be related to causative factors other than the small-intestine was obtained in 10 out of 56 patients. In 3 of the 10 patients with diarrhoea the small-intestinal mucosa was normal.

One/

One patient (no. 35) had been diagnosed as coeliac disease of infancy 6 years before the rash appeared, and another (no. 25) as adult coeliac disease 2 years before the rash appeared. The onset of diarrhoea preceded the rash in another 5 patients. In only the 2 patients previously diagnosed as coeliac disease was the diarrhoea sufficiently troublesome to necessitate treatment with a gluten-free diet.

Five of the 60 patients in the series presented initially in departments other than the Skin Department with features secondary to their enteropathy (Table 1).

In no instance was a family history of dermatitis herpetiformis obtained, but a brother of one patient (no. 32) appears to have had childhood coeliac disease, and a brother of another patient (no. 58) had recently been diagnosed as having adult coeliac disease.

Weight and Height - The weight and height of each patient was recorded and deviation from average weight was obtained by reference to standard tables (Society of Actuaries, 1959). Patients with associated diseases liable to affect weight were excluded. Comparison was made between the results obtained in those patients with a normal or mildly abnormal small-intestinal biopsy and those with a definitely abnormal biopsy (Fig. 9). The patients with a normal or near normal intestinal mucosa were on average 2 lb heavier than/

than the expected average weight, and the patients with an abnormal mucosa were on average 7 lb lighter than the expected average weight. The difference between the two groups, however, was not significant ($t = 1.289$; $P > 0.10$).

Gastro-intestinal Findings

Small-intestinal biopsy - These were assigned to one of four grades.

Dissecting microscope appearances are quoted first, followed by the conventional microscope appearances.

Grade 1:- Finger shaped villi with varying proportions of tongue or leaf shaped forms (Fig. 10). In 5 patients short ridges were also seen, and in another patient the surface was convoluted. Histology normal (Fig. 11). This grade was regarded as representing normal jejunal appearances.

Grade 2:- Predominantly leaf-shaped villi with short villous ridges, some of which were U-shaped (Fig. 12). Histologically, epithelium was for the most part normal but in several areas, although tall columnar, was lacking a distinct brush border and was infiltrated by numerous round cells. Villi were often slightly blunted and misshapen. Lamina propria had an increased round-cell content (Fig. 13).

Grade 3:- Convolutions, or convolutions and ridges, were seen in most but in 2 cases convolutions, ridges and leaves occurred and in 2 other cases only ridges/

ridges and leaves were present (Fig. 14). Histologically, the features were those of partial villous atrophy with short, broadened "villi", degenerated surface epithelium, elongated crypts of Lieberkuhn and increased round-cell content of lamina propria (Fig. 15).

Grade 4:- No villi were seen. Surface was mainly flat with a few broad convoluted ridges or with a mosaic pattern (Fig. 16). Histologically, the appearances were those of sub-total villous atrophy with absent or rudimentary "villi", degenerate surface epithelium, elongated crypts and increased cellularity of lamina propria (Fig. 17).

In view of the minor nature of the abnormalities comprising grade 2, the patients falling into this grading are combined with grade 1 patients and designated normal when comparison is being made with those patients whose small-intestinal mucosa was indisputably abnormal (grades 3 and 4).

The number of patients falling into each grade is recorded in Table II. In the total series the percentage of patients with a normal or mildly abnormal mucosa (grades 1 and 2) was 47 and the percentage of patients with definite mucosal abnormalities (grades 3 and 4) was 53. Analysis of results from the 2 geographic areas reveals that the percentage of patients with definite mucosal abnormalities was 57% in the Western region and 44% in the North-Eastern region. Also of the 27 patients not on specific therapy at the time of/

of small-intestinal biopsy investigation, 14 (52%) had definite mucosal abnormalities. In the 3 patients who had repeat intestinal biopsies after dapsone therapy no change was noted in one patient with a grade 3 mucosa, in a second patient the mucosal grading changed from 4 to 3 and in a third from 3 to 2.

Disaccharidase estimations - The results of these estimations are recorded in Table III and expressed as units (micromoles of substrate hydrolysed per minute) per gramme wet weight of mucosa. The limits of normality used are those determined by Paton et al. (1966) in the same laboratory, the lower limits for maltase, lactase and sucrase being 13.4 units, 1.4 units and 3.5 units respectively.

In the 4 patients with a grade 1 mucosa the disaccharidase concentrations were also normal and in the 4 patients with a grade 2 mucosa the only abnormality noted was alactasia in 1 patient.

Conversely, only 1 of the 9 patients with grades 3 and 4 mucosa had normal enzyme concentrations, diminished levels of all three enzymes being obtained in the remainder. Four of the 9 patients had alactasia.

Lactose-tolerance test - The blood sugar rise was less than 25 mg/100 ml, in 7 patients (Table IV). Apart from one patient with a blood sugar rise of 24 mg/100 ml and a normal lactase concentration the abnormal results were associated/

associated with diminished lactase activity. In only 1 of the 4 patients with diarrhoea and diminished lactase activity was symptoms, flatulence and abdominal distension, induced by the oral dose of lactose. This latter patient, however, was given 100 g lactose so that strict comparison cannot be made with those patients who received the smaller dose (50 g).

Xylose-tolerance test - Diminished excretion was noted in 12 of the 50 patients studied. Excretion was normal in 16 of the 25 patients with mucosal abnormality; and in 3 patients with diminished excretion the small-intestinal mucosa was normal (Table V).

Faecal-fat excretion - 11 of the 35 patients in whom this was measured were found to have an increased excretion. Excretion was normal in 12 of the 19 patients with mucosal abnormality; and in 4 patients with increased excretion the small-intestinal mucosa was normal (Table V).

Small-bowel barium meal - Abnormalities were noted in 5 of the 12 patients examined and these consisted of dilatation of the jejunal loops in 2 and flocculation of barium in 3. In all 5 patients with an abnormal test the small-intestinal mucosa showed the features of partial or subtotal villous atrophy, but in the other 5 patients with an abnormal mucosa, as well as in 2 patients with a normal mucosa, the test was unremarkable.

Haematological Findings

The haemoglobin concentration, estimated in all patients, fell below the accepted/

accepted lower limits of normality in the laboratory (males 12.5 g/100 ml; females 11.5 g/100 ml) in 11 patients. In 2 patients the haematological findings indicated a haemolytic anaemia the patients being on 200 and 150 mg of dapsone per day respectively, and in another patient a previous partial gastrectomy for duodenal ulceration may have contributed to the anaemia. In 8 patients, however, the most likely cause of anaemia was malabsorption: 6 had not received dapsone therapy and in 2 the dose taken was low. Details of these patients are recorded in Table VI. Anaemia was diagnosed in 5 patients prior to attending the Skin Department; in 4 of these patients before dermatitis herpetiformis had developed. A satisfactory response to oral iron therapy was obtained in 6 patients and in the remaining 2, intramuscular vitamin B₁₂ and oral folic acid were given in addition. In all 8 patients the jejunal mucosa was abnormal.

Howell-Jolly bodies were noted in the red cells in 3 patients in the series. The clearance of ⁵¹Cr-labelled autologous heat-damaged red cells was investigated in one of these patients and was found to be reduced, the half clearance time being 34 min (normal 10 - 16 min), and the blood radioactivity at 180 min was 24 per cent.

Biochemical Findings

The serum albumin level was low (<3.3 g/100 ml) in 4 of the 54 patients in/

in whom it was measured. In 3 patients the jejunal biopsy was normal, and in only 1 patient (patient no. 25), who had partial villous atrophy and severe clinical malabsorption, could the low level (3.1 g/100 ml) be related to the presence of an enteropathy (Appendix).

The serum calcium level was determined in 47 patients and found to be low (<4.5 mEq/l) in 2. In one of these the alkaline phosphatase level and jejunal mucosa were normal and the slight fall in serum calcium level (4.4 mEq/l) was probably due to a low serum albumin level (3.0 g/100 ml); the other was patient no. 25, already referred to in paragraph one, in whom the serum calcium was 2.5 mEq/l.

Serum alkaline phosphatase levels were ascertained in 50 adult patients: an abnormal level (>14 K. - A. units) was obtained in 3 - patients no. 20 and 26 in whom serum calcium levels were normal and patient no. 25 in whom the serum calcium level was low.

The serum globulin level was >3.0 g per 100 ml in 26 of the 54 patients examined but exceeded 4.0 g per 100 ml in only one, a patient who also suffered from pulmonary sarcoidosis. Conversely, the serum globulin level was <2 g per 100 ml in 2 patients (1.7 g per 100 ml).

DISCUSSION

The occurrence of skin changes, particularly eczema and pigmentation, is/

is well recognised as a feature of malabsorption (Manson-Bahr and Willoughby, 1930; Bennet et al., 1932; Kaufman and Smith, 1943; Cooke et al., 1953; Badenoch, 1960; Wells, 1962) and treatment of the intestinal disease usually results in marked improvement in the skin changes (Wells, 1962; Friedman and Hare, 1965; Fry et al., 1966). Wells (1962) emphasized that these patients may first present to the dermatologist, and it is likely that this observation, together with the increasing use by gastro-enterologists of the small-intestinal biopsy capsule devised by Crosby and Kugler (1957), stimulated a reappraisal of the small-intestine in skin diseases. Subsequently, abnormalities of the jejunal mucosa were described in rosacea (Watson et al., 1965), exfoliative dermatitis (Shuster and Marks, 1965; Shuster, 1967), psoriasis (Shuster et al., 1967), subcorneal pustular dermatosis (Van de Staak et al., 1970) and dermatitis herpetiformis (Marks et al., 1966; Fraser et al., 1967; Fry et al., 1967; Van Tongeren et al., 1967; Bendl and Williams, 1968; Marks et al., 1968; Shuster et al., 1968; Berg et al., 1970; Van de Staak et al., 1970; Brow et al., 1971). The small-intestine in pemphigoid, formerly known as senile dermatitis herpetiformis, was normal (Marks and Shuster, 1969); and in other skin diseases only minor abnormalities were noted (Fry et al., 1966). More recently, however, the validity of some of these findings has been questioned in view of further study of the characteristics of normal jejunal mucosa./

mucosa. This can conveniently be considered together with the mucosal classification used in the present study,

Holmes, Hourihane and Booth (1961a, 1961b) described the normal jejunal mucosal appearance under the dissecting microscope as consisting of finger-like villi or leaf-shaped villi with frequently a mingling of both types in the same specimen. In addition, on occasions the leaf-shaped villi appeared to coalesce to form distinct ridges, a manifestation more common in the duodenum. Conventional histological examination alone, on the other hand, did not reflect these differences in macroscopic structure, merely showing a thin glandular layer and long slender villi the 3-dimensional representation of the leaf-shaped villus and villous ridge being absent. Thus, both macroscopic and microscopic appearances were incorporated in the classification of jejunal mucosal appearances. This concept of normality was similar to that of other workers in the field (Scott et al., 1964; Rubin and Dobbins, 1965; Salem and Truelove, 1965; Stewart et al., 1967), while others did not find villous ridges in the jejunum in control subjects (Girdwood et al., 1966; Burhol and Myren, 1968). A more radical disagreement with the concept of Holmes et al., however, was the work in Newcastle by Marks and Shuster (1970a) on post-mortem control subjects, in which they described a predominantly convoluted mucosa in 8% of jejunal biopsies. This had not previously/

previously been noted in this country although a convoluted mucosa is a not uncommon finding in control subjects in several countries abroad, including Southern India (Baker et al., 1962), East Africa (Banwell et al., 1964) and Israel (Parkins et al., 1966). Marks and Shuster suggested that the different mucosal appearances noted in control patients by the various workers in this country might simply reflect regional variation. In the same study these authors found that the incidence of a convoluted mucosa in dermatitis and psoriasis was not significantly different from their control group and so they withdrew their previous claims of a structural jejunal abnormality in dermatogenic enteropathy (Shuster and Marks, 1965; Shuster, 1967) and psoriasis (Shuster et al., 1967). Also, they suggested that the discrepancy in the jejunal biopsy findings in rosacea between the Glasgow series (Watson et al., 1965), reported as abnormal, and the London series (Marks et al., 1967), reported as normal, might be false due to inadequate knowledge of normal jejunal mucosal appearances in the Glasgow area. In view of the above, therefore, the one patient in the present study with a convoluted mucosa and normal histology was not regarded as abnormal but placed in the grade representing a normal jejunal mucosa, grade 1.

The classification of the abnormal jejunal mucosal appearance by Holmes et al. (1961a, 1961b) fell into two groups. In the first, a flat mucosal surface devoid/

devoid of villi was seen to be associated with the histological appearances of subtotal villous atrophy, and in the second, the histological appearances of partial villous atrophy were represented under the dissecting microscope by a series of ridges, convolutions and whorls for which the descriptive title convoluted was suggested. These two categories of abnormality were noted in idiopathic steatorrhoea (adult coeliac disease). They are represented by grades 4 and 3 respectively in the present study.

A number of patients in the present work had a jejunal biopsy appearance which was classified as grade 2: villous ridges were present on macroscopic examination and minor villous and epithelial cell abnormalities on microscopic examination. A similar grade is present in the classification of several other workers studying dermatitis herpetiformis (Fry et al., 1967; Marks et al., 1968; Shuster et al., 1968). These changes have also been noted in the relatives of coeliac disease patients by MacDonald et al. (1965), but these authors classified the appearance as "non-specific abnormality" as no relationship to gluten could be demonstrated. A similar "abnormality" has been described in pernicious anaemia (Foroozan and Trier, 1967) and rosacea (Watson et al., 1965), and the possibility that local factors are important in its production is suggested by the work of Townley et al. (1964) on experimental instillation of hydrochloric acid into the jejunum. Accordingly, in the present study, grade/

grade 2 mucosae were grouped with grade 1 when comparative assessments were being made with the definitely abnormal grades 3 and 4.

Excluding that part of the present work previously published (Fraser et al., 1967) the changes of partial or subtotal villous atrophy of the jejunal mucosa were noted in 46 of the 81 patients studied in the first 6 papers published on the subject of dermatitis herpetiformis and the small-intestine (Marks et al., 1966; Fry et al., 1967; Van Tongeren et al., 1967; Bendl and Williams, 1968; Marks et al., 1968; Shuster et al., 1968). This incidence of abnormality (57%) is very similar to the incidence of 53% obtained in the present work, and further evidence against any marked regional variation in the prevalence of small-intestinal abnormalities in dermatitis herpetiformis was provided by the similar incidence of abnormality found in patients in the North-East of Scotland (8 of 18) and the West of Scotland (24 of 42). Such small variations as do exist between one area and another may simply relate to the small numbers of patients normally comprising a series. Another factor, suggested by the variation in mucosal appearance in the 3 patients who had repeat biopsies from the same area of jejunum, is that the mucosal abnormality may be patchy. Indeed, Berg et al. (1970) reported marked variation between two biopsies taken from the same area of jejunum in one patient with dermatitis herpetiformis, and in another patient marked variation was noted in adjacent areas/

areas of the same biopsy. More recently, Brow et al. (1971), by taking multiple biopsies of the proximal small-bowel in 22 patients with dermatitis herpetiformis, demonstrated that the mucosal involvement was patchy in 5. A similar patchy mucosal involvement has been recorded in adult coeliac disease (Roy-Choudhury et al., 1967).

Disaccharidase enzyme activity correlated well with the histological assessment of the jejunal mucosa in the patients studied (Table III): only 1 of the 9 patients with severe mucosal changes had normal enzyme activity, and in only 1 of the 8 patients with a normal mucosa was the enzyme activity reduced (isolated lactase deficiency). These findings are in agreement with the published work in this field (Fraser et al., 1967, 1968; Shuster et al., 1968; Berg et al., 1970), and it is likely, as further suggested by the beneficial effect of a gluten-free diet in patient no. 25, that, in most cases, reduction of enzyme activity is secondary to mucosal abnormality. A similar situation obtains in coeliac disease where reduced disaccharidase enzyme activity is restored to normal on treatment with a gluten-free diet (Plotkin and Isselbacher, 1964; Lifshitz et al., 1965). Despite low lactase levels in dermatitis herpetiformis patients, however, lactose intolerance was demonstrated on only one occasion (Table IV). This accords with the studies of Hammerli et al. (1965) in which asymptomatic lactase deficiency was described. In relation to reduced disaccharidase enzyme/

enzyme concentrations and the skin eruption, it is of interest that Pock-Steen and Niordson (1970) have reported that a milk-free diet may benefit some patients with dermatitis herpetiformis. This effect, however, appeared to be related to the protein rather than the lactose content of the milk.

In general, the effect of the small-intestinal abnormalities on patients with dermatitis herpetiformis was slight. Five patients did, however, present with symptoms or signs related to malabsorption prior to attending the Skin Department (Table I). In only 2 of these, however, was the malabsorption severe; an incidence of 4% which compares with the 8% incidence in the initial series referred to above. Again, the incidence of diarrhoea in the present study was 19%, with 7 of the 10 patients affected having an abnormal jejunal mucosa; and this compares with a 17% incidence of diarrhoea in the initial series, 10 of the 12 patients affected having an abnormal mucosa. Clearly, although most patients in whom mucosal abnormalities exist do not have diarrhoea there is a good correlation between the presence of diarrhoea and an abnormal small-intestinal mucosa. That the small-intestinal abnormalities commonly precede the eruption of dermatitis herpetiformis is suggested by the fact that the symptom of diarrhoea preceded the eruption in 7 of the 10 patients with this symptom, and indeed in 2 instances (patients no. 25 and 35) the presence of jejunal mucosal abnormalities was established by intestinal biopsy before the rash/

rash appeared.

As stated previously, in the introduction to this part of the study, patients with dermatitis herpetiformis were regarded as often poorly nourished. No significant difference, however, was present in the variation from average weight between patients with jejunal mucosal grades 1 and 2 and patients with mucosal grades 3 and 4 (Fig. 9), although clearly, in a relatively small number of patients, an effect of small-intestinal abnormality on body weight might be difficult to demonstrate, in view of the variability of this measurement even in the normal population. Fry et al. (1967) also concluded that, in general, dermatitis herpetiformis patients were not underweight; although some patients with mucosal abnormality did gain weight when treated with a gluten-free diet (Fry et al., 1968, 1969). It is likely, therefore, that weight loss due to dermatitis herpetiformis enteropathy is infrequent and normally slight.

Abnormalities of the two main tests of intestinal absorption, the xylose-tolerance test and the faecal-fat excretion, were present in only a small proportion of patients with small-intestinal mucosal changes; and in some patients with abnormal absorption tests the small-intestinal mucosa was normal (Table V): the findings are similar to those of the initial published series (Fry et al., 1967; Marks et al., 1968; Shuster et al., 1968). However, although/

although in coeliac disease the percentage of abnormal tests is high, the degree of abnormality cannot be correlated with the severity of jejunal mucosal changes, and appears to depend on the extent of small-intestinal involvement rather than its severity at any one point (MacDonald et al., 1964; Stewart et al., 1967). Brow et al. (1971) reached a similar conclusion in dermatitis herpetiformis by correlating faecal-fat excretion with the extent of small-intestinal involvement, and their finding of patchy mucosal involvement in some patients with this disease may explain the occasional presence of abnormal absorption tests in patients with a normal jejunal mucosa (Table V). For similar reasons, abnormalities detected by small-bowel barium meal examination were infrequent, as were abnormalities in the serum biochemistry.

The incidence of anaemia, likely to be secondary to small-intestinal abnormality, was also low in the present series; only 8 of the 60 patients being affected (Table VI). In most cases oral iron therapy produced a satisfactory response, and this has been the experience of other investigators (Fry et al., 1967; Shuster et al., 1968; Berg et al., 1970). Indeed, Fry et al. (1967) reported that low serum iron levels and absence of bone marrow iron are common in dermatitis herpetiformis. In some patients low serum folate levels occurred with mild macrocytosis of the peripheral blood film (Table/

(Table VI). These latter changes have been described by many authors (Fry et al., 1967; Marks et al., 1968; Berg et al., 1970; Brow et al., 1971) and may be due to malabsorption of food folate (Hoffbrand et al., 1970), although the chronic haemolysis produced by dapsone therapy may, by increasing folate utilization, also contribute to the finding of low serum folate levels (Fry et al., 1967). Severe megaloblastic anaemia, however, as in patient no. 25, is usually associated with a frank malabsorption state (Marks et al., 1966; Van Tongeren et al., 1967; Shuster et al., 1968): low serum B₁₂ levels as well as low serum folate levels may be present. In general, however, as would be expected from a predominantly proximal small-intestinal involvement (Brow et al., 1971), serum B₁₂ levels and the Schilling test for vitamin B₁₂ absorption are recorded as normal in dermatitis herpetiformis (Fry et al., 1967; Shuster et al., 1968; Berg et al., 1970; Brow et al., 1971); although in the series of Marks et al. (1968) and Cream and Scott (1970), low levels were noted. Certainly, small-intestinal function may not be the only factor affecting serum B₁₂ levels, as Andersson et al. (1971a) have reported decreased gastric secretion of intrinsic factor in dermatitis herpetiformis: indeed, an association with pernicious anaemia has occasionally been recorded (Ilyas, 1968; Wyburn-Mason, 1968; Cream and Scott, 1970). Nevertheless, despite the possible deficiency of these various haematonic factors/

factors, severe anaemia ($Hb < 10 \text{ g}/100 \text{ ml}$) is uncommon, the incidence in the present series being 5%, and in a group of published series involving a total of 67 patients, the incidence was 4% (Fraser et al., 1967; Fry et al., 1967; Marks, 1968; Berg et al., 1970). Finally, in regard to haematological findings, this study confirmed that Howell-Jolly bodies may be found in the red cells of a small percentage of patients with dermatitis herpetiformis, and that this abnormality indicates the presence of splenic atrophy (Fry et al., 1967).

The nature of the enteropathy in dermatitis herpetiformis and particularly its relationship with coeliac disease has been the subject of much investigation. The significance of mild histological abnormalities in the jejunal mucosa is uncertain and has been considered already, but the more severe changes of partial or subtotal villous atrophy are identical with those occurring in gluten-induced enteropathy; otherwise called idiopathic steatorrhoea or coeliac disease. The possible relationship to gluten ingestion was first suggested by Fry et al. (1967), and the clinical benefit and histological improvement in the jejunal mucosa following the use of a gluten-free diet is now well documented (Fry et al., 1968, 1969; Shuster et al., 1968; Marks et al., 1969; Berg et al., 1970; Marks and Shuster, 1970; Van de Staak et al., 1970; Weinstein et al., 1971). Also, the role of a dietary factor in the pathogenesis of the enteropathy is consistent with the observation that the mucosal damage/

damage is more severe in the proximal than in the distal small-intestine (Shuster et al., 1968; Brow et al., 1971). The relationship to gluten has been further confirmed by demonstrating the deleterious effect of gluten administration on a normal area of small-intestinal mucosa (Shuster et al., 1968; Weinstein et al., 1971); an effect previously demonstrated in coeliac disease by Rubin et al. (1962).

Another aspect of the relationship between the enteropathy in the two diseases is seen in family studies: the presence of jejunal abnormalities in the relatives of patients with coeliac disease is well known (MacDonald et al., 1965; McCrae, 1969), and Marks et al. (1970) investigating 19 relatives of patients with dermatitis herpetiformis found jejunal abnormalities in 7. Indeed, patients with dermatitis herpetiformis may give a history of having relatives with coeliac disease (Marks et al., 1968; Marks et al., 1970), a feature noted in 2 patients in the present study. A number of other points of similarity between dermatitis herpetiformis and coeliac disease have been recorded: the lowering of serum IgM levels reported in coeliac disease by Hobbs and Hepner (1966, 1968) and Blecher et al. (1969) is also found in dermatitis herpetiformis (Fry et al., 1967; Marks, 1968; Fraser et al., 1969); splenic atrophy described in coeliac disease by McCarthy et al. (1966) has been recorded by Fry et al. (1967) in dermatitis herpetiformis, and was demonstrated/

demonstrated in one patient in the present study; a high incidence of agglutinating factor to Lactobacillus casei in the sera of patients with coeliac disease (Cowan et al., 1966) has been described in dermatitis herpetiformis by Fry et al. (1967); and the occurrence of intra-abdominal lymphomas, previously noted in patients with coeliac disease (Upshaw and Pollard, 1957; Scudamore, 1961; Gough, 1962), has recently been described in patients with dermatitis herpetiformis (Gjone and Nordoy, 1970; Andersson et al., 1971b).

The close relationship between the gut findings in dermatitis herpetiformis and coeliac disease is further emphasized by the fact that patients have been diagnosed as typical examples of adult or childhood coeliac disease before the rash of dermatitis herpetiformis had appeared (Smith, 1966; Bendl and Williams, 1968; Dyer and Verbov, 1968; Fraser et al., 1968; Mayon-White, 1969; McNeish et al., 1970; Brow et al., 1971 -- these reports include 3 patients in the present study) and by the discovery of the occasional patient suffering from dermatitis herpetiformis in reviews of patients with coeliac disease attending gastro-enterology clinics (Marks and Shuster, 1971; Weinstein et al., 1971; Young and Pringle, 1971).

From the weight of supporting evidence, therefore, it would appear that the enteropathy of dermatitis herpetiformis differs only in degree of severity from/

from the condition designated childhood or adult coeliac disease, and this difference may be artificial merely reflecting the fact that patients with overt coeliac disease form only a small proportion of the individuals with the small-intestinal abnormalities of this disease (MacDonald et al., 1965).

However, the problem of the relationship existing between the skin and the small-intestine in dermatitis herpetiformis is less clear. A number of different factors have been suggested over the years as forming a possible direct link between the skin and the gut in this disease. Thus, it was postulated by Fry et al. (1967) that the changes in the small-intestine and the skin might be an expression of a defect in folate metabolism, possibly aggravated by dapsone therapy, but these authors later reported that the serum folate levels could be restored to normal on treatment with a gluten-free diet (Fry et al., 1968, 1969) suggesting that the low levels were secondary to the enteropathy rather than having a primary causative role. Also, as noted in the present study, jejunal abnormalities were just as common in patients who had never received dapsone therapy as in those who had, and in the 3 patients who had repeat jejunal biopsies after dapsone therapy, no marked difference in appearance was noted. There is no evidence, therefore, that treatment of the skin eruption with dapsone either exacerbates or improves the bowel abnormality, and a similar negative effect has been reported with sulphapyridine/

sulphapyridine (Brow et al., 1971). The only serious contention now, in this regard, is that gluten may be responsible for the skin disease as well as the gut abnormality. A number of authors have described improvement in the skin eruption in some patients on a gluten-free diet (Van Tongeren et al., 1967; Fry et al., 1968, 1969; Marks et al., 1969; Van de Staak et al., 1970; Weinstein et al., 1971) but others have failed to note any effect (Verbov and Barkhan, 1967; Bendl and Williams, 1968; Dyer and Verbov, 1968; Fraser et al., 1968; Shuster et al., 1968; Mayon-White, 1969; Berg et al., 1970; Marks and Shuster, 1970b; McNeish et al., 1970). Indeed, several authors have described patients, including 2 from the present study (Fraser et al., 1968; McNeish et al., 1970), who first developed dermatitis herpetiformis while on a gluten-free diet (Bendl and Williams, 1968; Mayon-White, 1969). Shuster et al. (1968) believe that the apparent beneficial effect of a gluten-free diet in some patients can be explained by the fact that spontaneous fluctuations of the severity of the disease process in the skin occur from time to time. And so, Shuster et al. suggest that the relationship between the rash and the enteropathy in dermatitis herpetiformis is indirect and probably genetic in nature.

Dermatitis herpetiformis, however, has only occasionally been recorded in more than one member of a family (Little, 1914; Smith, 1928; Bock, 1954; Kinmont, /

Kinmont, 1955; Deeken and Bamshad, 1970; Marks et al., 1971) and it may be that the eruption is produced by external factors in the genetically predisposed.

SUMMARY

The status of the small-intestinal mucosa in 60 patients with dermatitis herpetiformis is described: partial or subtotal villous atrophy was present in over 50% of patients. The incidence of a frank malabsorption state was only 4%, and, although some other patients did exhibit symptoms and signs related to malabsorption, in general the gut changes were asymptomatic and investigations for the presence of malabsorption often negative. Reduction of disaccharidase concentrations appeared to be secondary to the mucosal abnormalities and although lactase concentrations were often low, only one patient had symptoms of lactose intolerance. The enteropathy of dermatitis herpetiformis could not be related to dapsone therapy and is probably identical to gluten-induced enteropathy (adult or childhood coeliac disease). The relationship between the small-intestinal abnormalities and the skin disease is uncertain.

TABLE 1 - Five Patients in whom Rash was not Presenting Feature

Patient no.	Sex and age	Intestinal mucosa (biopsy grade)	Presenting feature	Time of appearance of rash
15	M 7	3	Anaemia	8 months before+
16	F 52	3	Anaemia*	8 years after
25	F 57	3	Weight loss, diarrhoea*	3 years after
35	M 2	4	Diarrhoea*	5 years after
54	M 53	4	Anaemia	5 years after

* coeliac disease diagnosed at the time of presenting feature.

+ rash mild and not diagnosed until 2 years later.

**TABLE II - Grading of Small-Intestinal Mucosa in 60 Patients with
Dermatitis Herpetiformis**

Intestinal mucosa (biopsy grade)	No. of patients studied		Total	%
	Western region	N-Eastern region		
1	9	9	18	30
2	9	1	10	17
3	19	3	22	36
4	5	5	10	17
TOTAL	42	18	60	100

TABLE III - Disaccharidase Studies

<u>Patient no.</u>	<u>Sex and age</u>	<u>Intestinal mucosa (biopsy grade)</u>	<u>Maltase*</u>	<u>Lactase*</u>	<u>Sucrase*</u>
1	F 53	3	2.4	0.0	0.6
2	F 53	1	21.7	1.5	5.8
3	M 33	3	4.3	0.0	0.7
4	F 58	1	17.8	3.7	4.9
5	M 67	3	10.0	1.1	2.1
6	M 49	2	15.6	2.1	4.4
7	M 69	4	3.2	1.1	0.8
8	M 33	4	4.5	0.0	1.2
9	F 20	4	1.8	0.1	0.4
10	F 16	1	21.4	3.6	5.7
11	M 14	2	15.4	0.0	4.0
12	M 38	3	32.1	6.6	9.2
13	F 15	1	17.9	4.9	3.9
14	M 24	2	14.9	1.7	4.9
15	M 8	3	10.4	0.0	2.4
17	M 47	2	18.9	4.1	5.3
25	F 60	3	6.1	0.2	1.7
		3+	18.5	0.3	5.4

* Units of activity (umol substrate hydrolysed per minute)
per gramme of tissue wet weight (lower limits of normal -
maltase 13.4 units, lactase 1.4 units, sucrase 3.5 units).

+ Repeat intestinal biopsy 3 years after first with patient on
a gluten-free diet.

TABLE IV - Blood-Sugar Rise after Lactose Tolerance Test in 8 Patients

Patient no.	Sex and age	Intestinal mucosa (biopsy grade)	Lactase+	Blood-sugar rise (mg/100 ml)	Symptoms during test
1*	F 53	3	0.0	7	none
8*	M 33	4	0.0	16	none
9	F 20	4	0.1	22	none
10	F 16	1	3.6	85	none
11	M 14	2	0.0	20	none
12*	M 38	3	6.6	32	none
15*	M 8	3	0.0	6	none
17*	M 47	2	4.1	24	none
25*	F 60	3	0.3	14†	flatulence, abdominal distension

* history of diarrhoea.

+ units of activity (umol substrate hydrolysed per minute) per gramme of tissue wet weight.

‡ 100 g lactose given.

TABLE V - Incidence of Abnormal Absorption Tests in Relation to Small-Intestinal Mucosal Grading.

Intestinal mucosa	Xylose-tolerance tests (proportion abnormal)		Faecal-fat excretion (proportion abnormal)	
	Present series	Published* series	Present series	Published* series
Grades 1 and 2	3/25 (12%)	6/19 (32%)	4/16 (25%)	3/19 (16%)
Grades 3 and 4	9/25 (36%)	15/30 (50%)	7/19 (37%)	15/33 (45%)

* Fry et al., 1967; Marks et al., 1968; Shuster et al., 1968.

TABLE VI - Details of 8 Patients with Anaemia

Patient no.	Sex and age	Jejunal biopsy grading	Hemo-globin (g per 100 ml)	Peripheral - film	Bone-marrow examination	Serum B ₁₂ (μg per ml)	Serum folate (μg per ml)	Serum iron (μg per 100 ml)	Treatment of anaemia
15*	M 7	3	4.8	microcytic	-	-	-	30	I.M. and oral iron.
16*	F 52	3	11.5	aniso-cytosis, occas. macrocyte	normo-blastic	50	-	-	G.F.D.,) no effect. I.M.B. ₁₂) Oral folic acid) good Oral iron) response.
25*	F 57	3	9	aniso-cytosis, macro-cytosis	megalo-blastic	10	-	40	G.F.D., I.M.B. ₁₂) oral folic acid) and iron,)
26	M 50	3	10.2	normal	-	250	2.7	-	Oral folic acid - no effect. Oral iron - good response.
30	M 37	3	10.7	aniso-cytosis, occas. macrocyte	normo-blastic, no stainable iron	160	1.1	15	Oral iron.
35*	M 2	4	9.6	hypochromic	-	-	-	15	G.F.D.,) Oral iron.)
36	F 39	3	10.7	hypochromic	-	-	2.6	-	Oral iron.
54*	M 53	4	10.1	microcytic, hypochromic	-	-	-	-	Oral iron.

* Anaemia detected before attending Skin Department.

G.F.D. = gluten-free diet.




Fig. 7. - The Watson intestinal biopsy capsule.

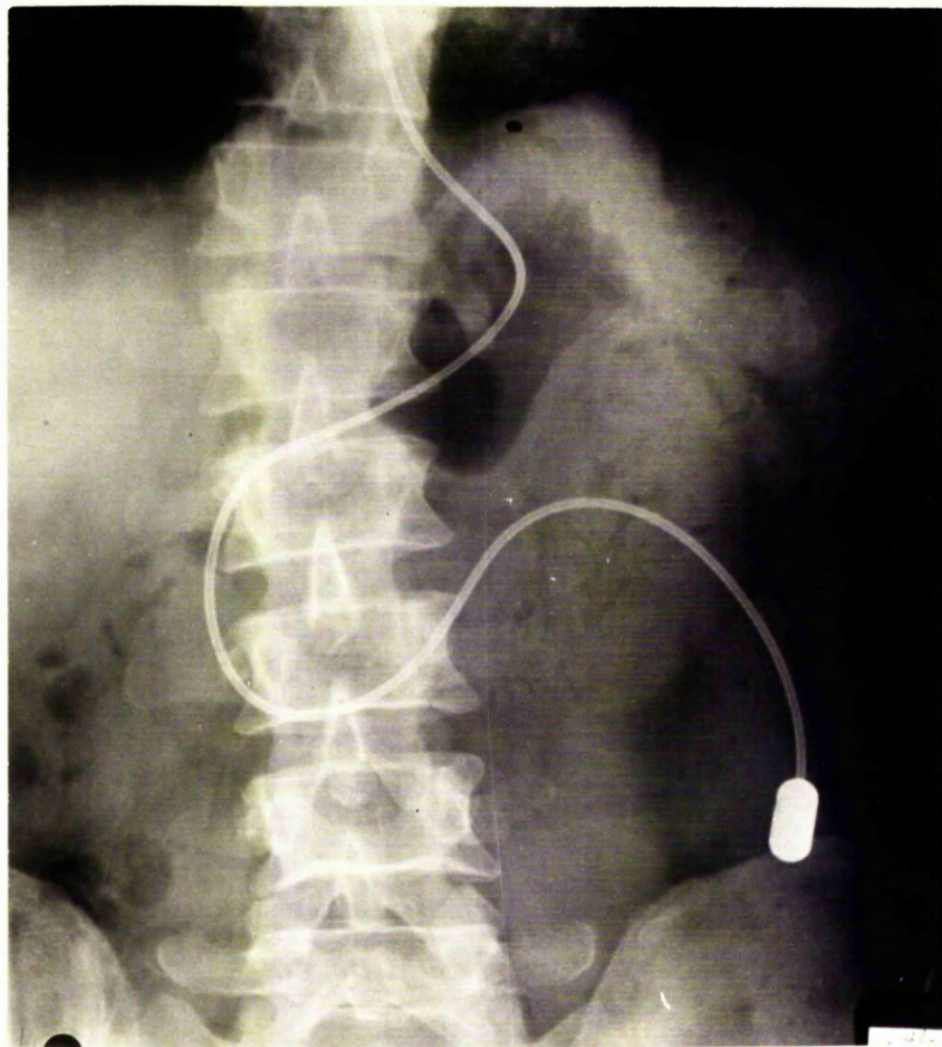


Fig. 8. - The Watson capsule positioned in the proximal jejunum.

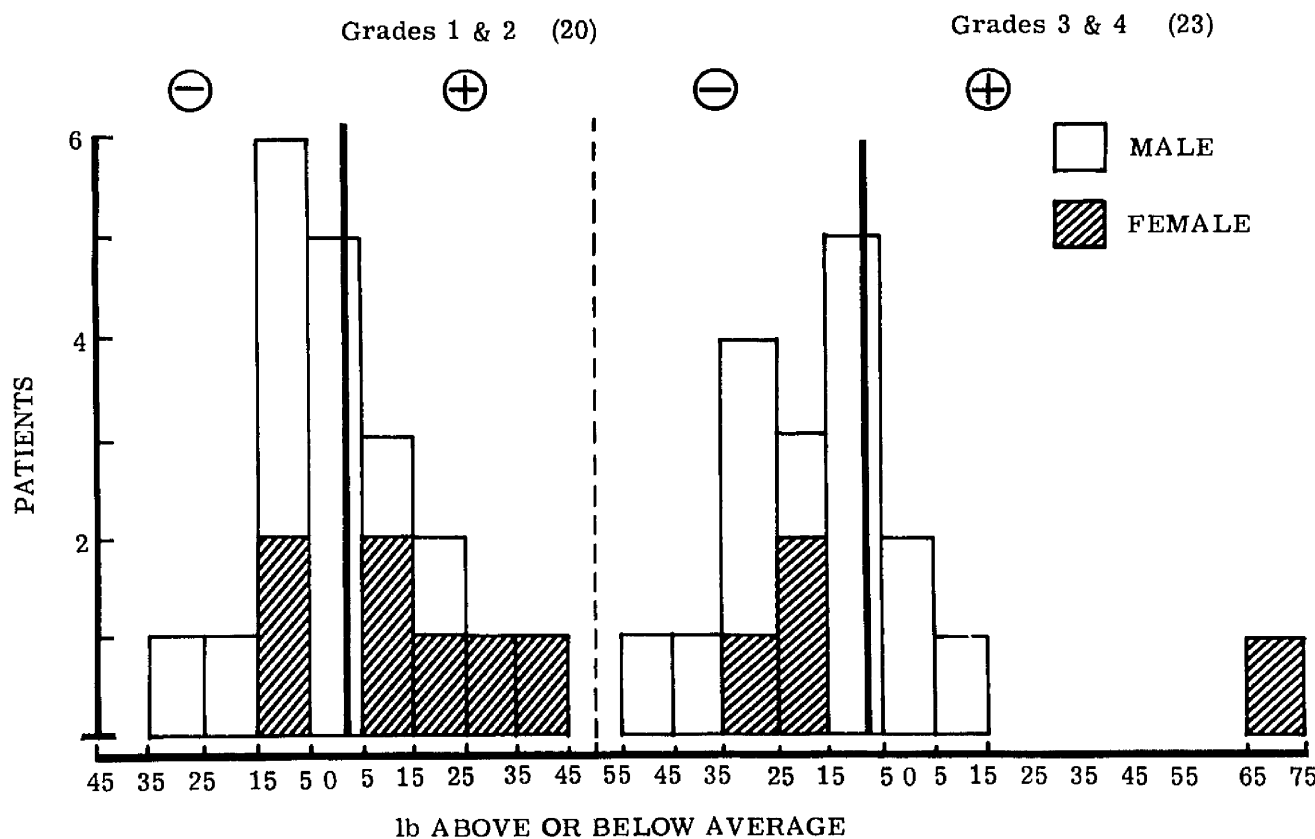


Fig. 9. - Deviation of weights of patients with grades 1 and 2 small-intestinal mucosa and grades 3 and 4 small-intestinal mucosa from normal. Differences are those between an individual and the average weight for all individuals of the same age, sex and height. The mean deviation for both groups of patients is indicated.

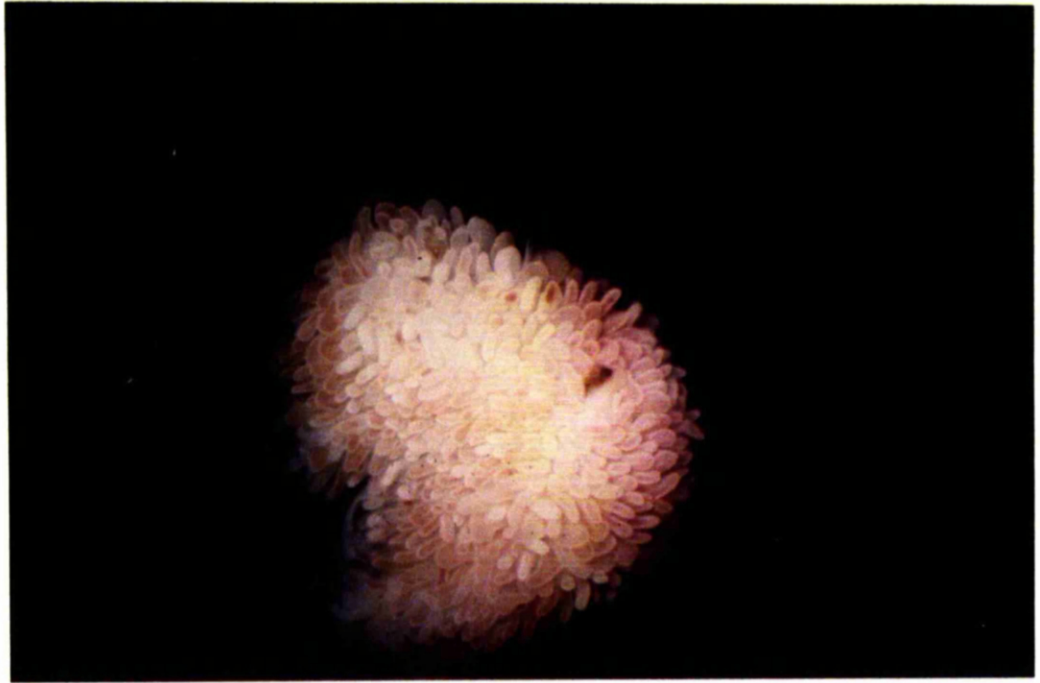

Fig. 10. - Dissecting microscope appearance of grade 1 mucosa showing finger and leaf shaped villi. x 10.

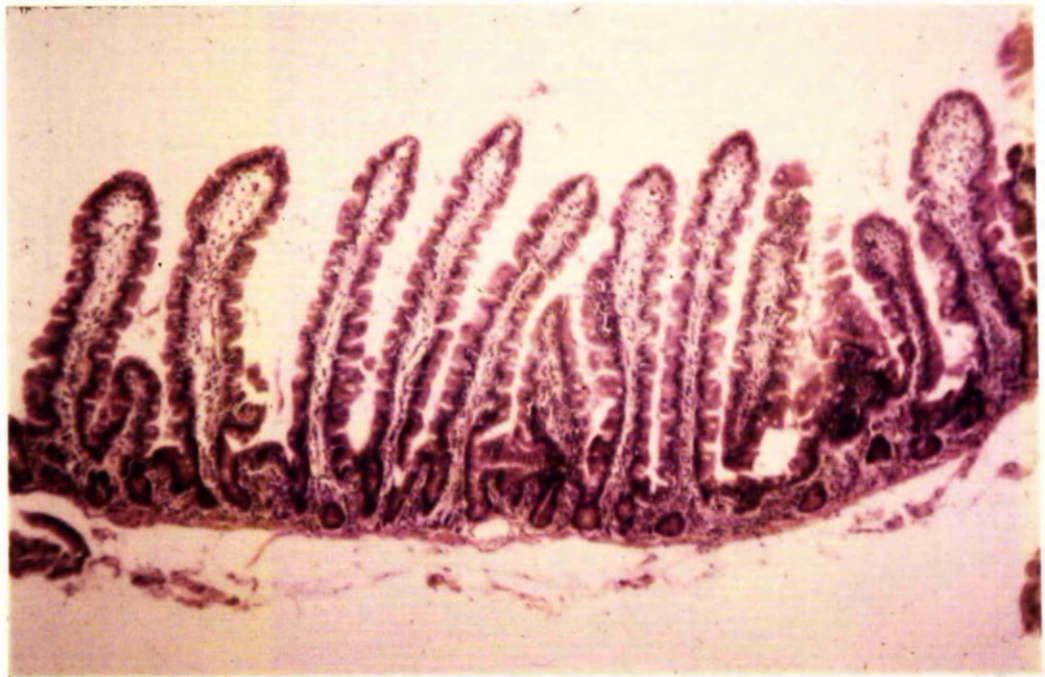


Fig. 11. - Histological appearance of grade 1 mucosa. H. and E. x 100.

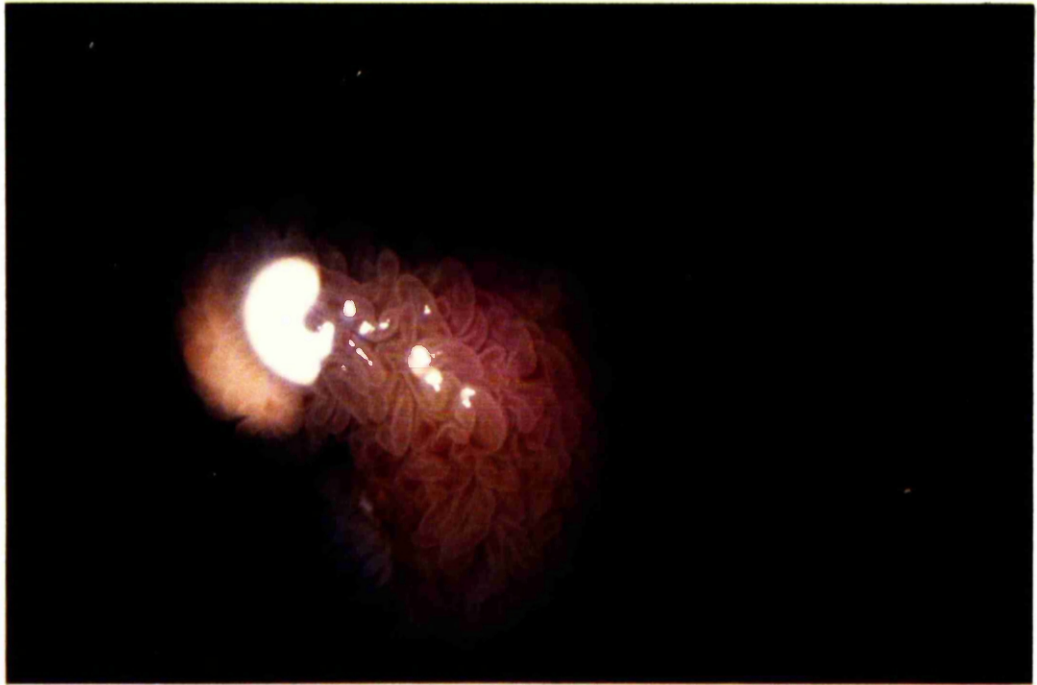


Fig. 12. - Dissecting microscope appearance of grade 2 mucosa showing mainly leaf shaped villi with some short villous ridges. x 10.

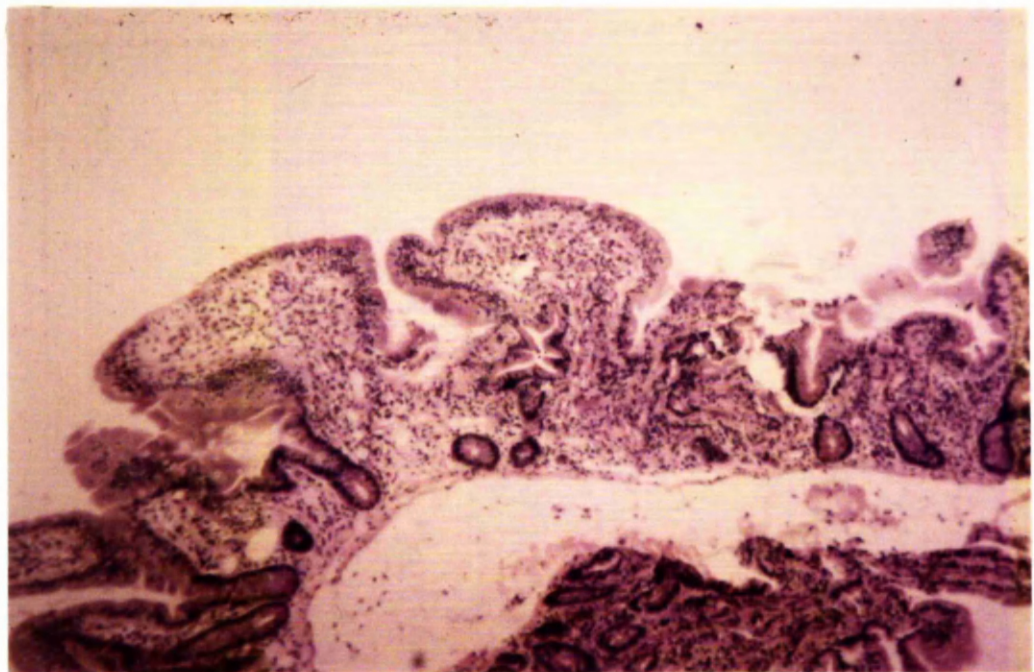


Fig. 13. - Histological appearance of grade 2 mucosa. H. and E. x 100.

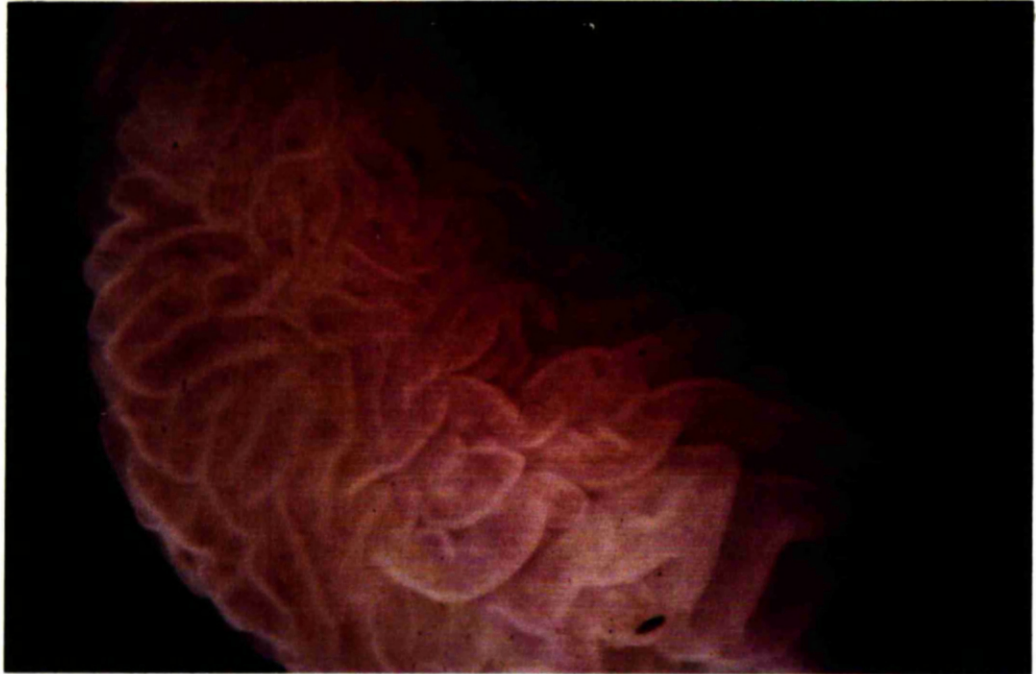

Fig. 14. - Dissecting microscope appearance of grade 3 mucosa showing a convoluted pattern. x 50.

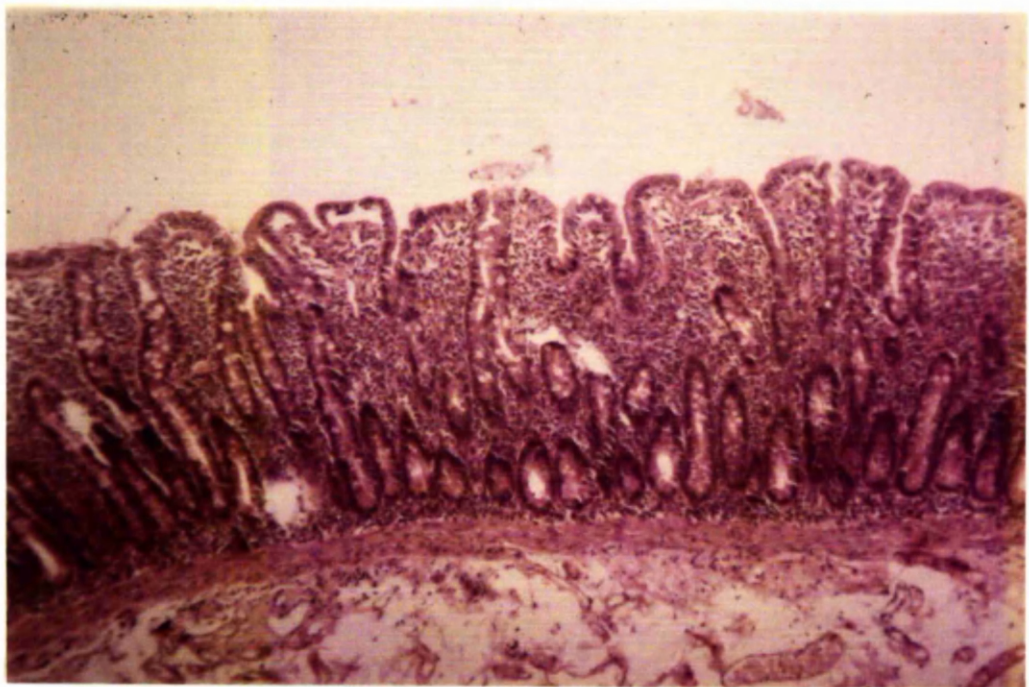


Fig. 15. - Histological appearance of grade 3 mucosa. H. and E. x 100.

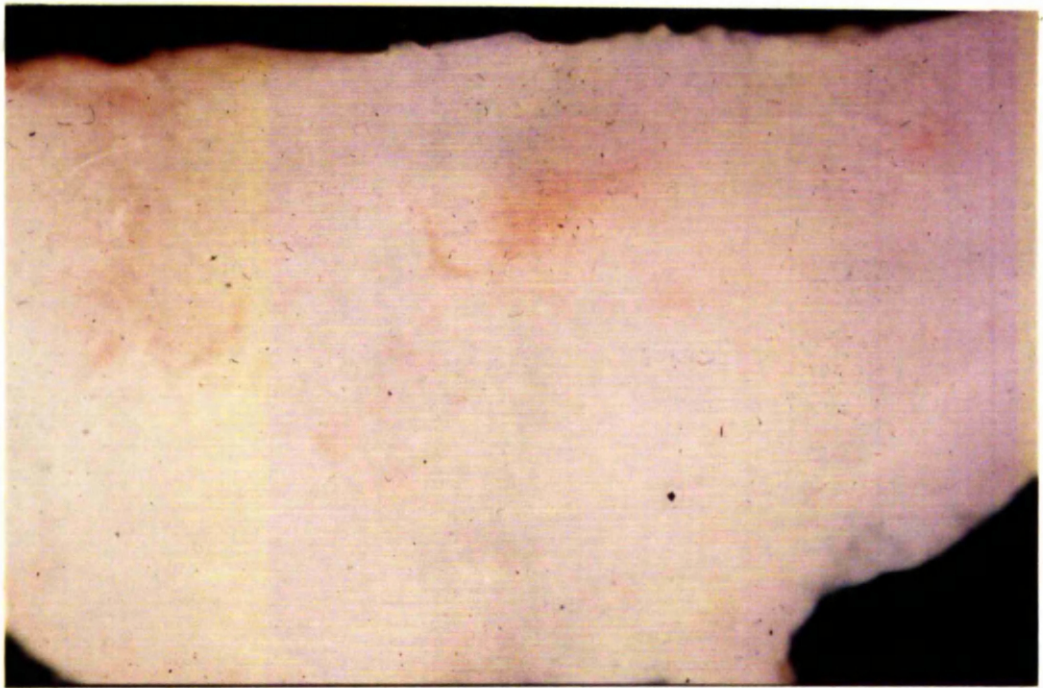

Fig. 16. - Dissecting microscope appearance of grade 4 mucosa showing a completely flat surface. x 50.

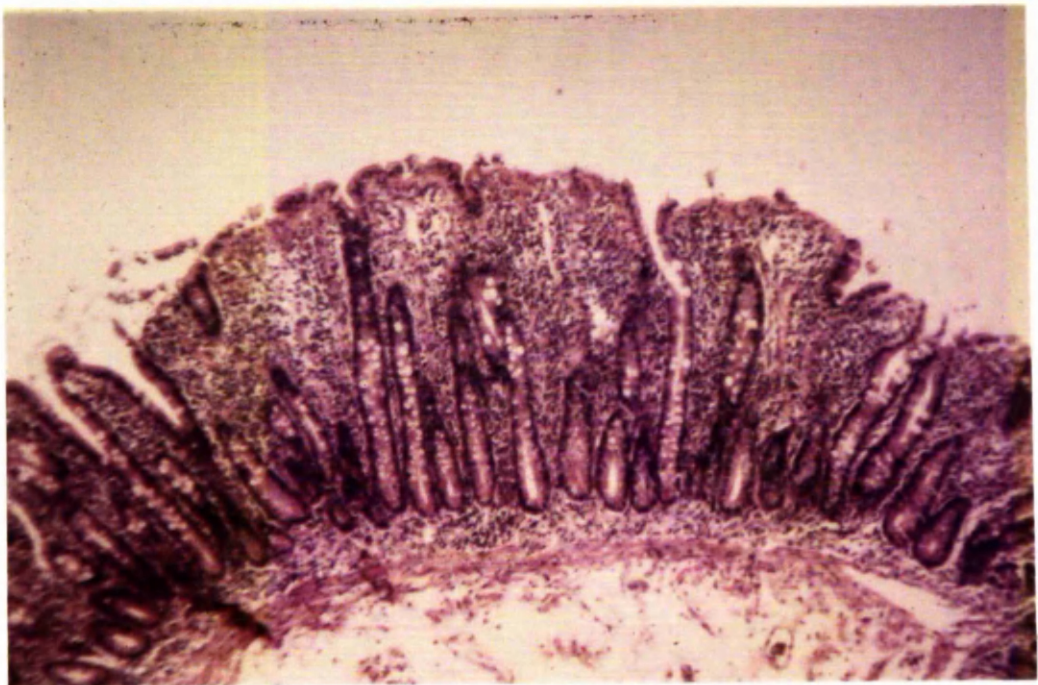


Fig. 17. - Histological appearance of grade 4 mucosa. H. and E. x 100.

PART II

SERUM IMMUNOGLOBULINS

INTRODUCTION

After the initial report of Marks, Shuster and Watson (1966) on the small-intestinal abnormalities in dermatitis herpetiformis, Fry et al. (1967) in confirming the histological similarity of these changes to those occurring in adult coeliac disease sought further evidence of a relationship between the small-intestinal abnormalities in the two diseases. And so, the serum immunoglobulin levels were determined, and although the numbers studied were small, a lowering of IgM occurred in one-third of patients. This accorded with the lowering of serum IgM levels noted previously in about one-third of patients with adult coeliac disease (Hobbs and Hepner, 1966).

A more detailed study of the immunoglobulin status of patients with dermatitis herpetiformis was undertaken and an attempt made to relate serum immunoglobulin levels with the presence of disease in the small-intestine or the skin. That serum immunoglobulin levels might be related to the skin eruption had been suggested by the finding of immunoglobulins and complement (C'3) in the dermis of patients with dermatitis herpetiformis (Cormane, 1967; Van der Meer, 1969; Cormane et al., 1970) and so, to examine this possibility, and, indeed, to seek further evidence of an immune reaction in the skin in this disease, serum immunoglobulin and complement (C'3) levels were determined at different phases of disease activity. Also, serum immunoglobulin/

globulin levels were analysed in 7 other skin diseases, not associated with definite small-intestinal abnormalities, for comparison with the results obtained in dermatitis herpetiformis.

PATIENTS AND METHODS

The investigation was carried out in 248 adults. The only child was a boy of 8 years with dermatitis herpetiformis.

The study consisted of 2 parts:-

Part 1. Subjects investigated in Glasgow.

(a) 33 patients with dermatitis herpetiformis. All these patients were also included in Part I of the thesis.

Two patients under treatment with a gluten-free diet were excluded from this part of the study.

(b) 154 patients with various other skin diseases: psoriasis 27 cases, acne vulgaris 18, atopic eczema 15, other eczemas 29, rosacea 32, erythema multiforme 18, discoid lupus erythematosus 15.

(c) 47 control subjects. These were healthy adults without skin disease: 27 medical and technical staff, 10 women attending a gynaecological out-patient department and 10 healthy blood donors.

A total of 124 blood samples for immunoglobulin estimation were obtained from/

from the 33 patients with dermatitis herpetiformis. This comprised a single blood sample in 8 patients and between 2 and 7 samples taken over a 2-12 month period in 25. The patients with other skin diseases and the control subjects had a single blood sample analysed. The sera were stored at -20°C and thawed immediately before being used.

Serum immunoglobulin estimation - Quantitative determination of the serum immunoglobulins IgG, IgA and IgM was performed by a radial immunodiffusion technique (Mancini et al., 1964). Commercially available radial immunodiffusion plates were used (Hyland Immunoplates, Baxter Laboratories Ltd., Norfolk, England). Specific antiserum to one immunoglobulin is incorporated in a uniform layer of agar on a perspex slide. The test serum is placed in a small antigen well in the agar and allowed to diffuse. A ring of antigen-antibody precipitate forms in the agar around the well and the diameter of this precipitin ring reflects the concentration of immunoglobulin in the serum (Fahey and McKelvey, 1965). Three reference standard sera of known immunoglobulin concentration were used to construct the graph of diameter of precipitin ring against immunoglobulin concentration on which the immunoglobulin concentrations of the test sera were calculated.

Part 2. Subjects investigated in Aberdeen.

(a) 19 patients with dermatitis herpetiformis. 17 of these patients/

patients were included in Part I of the thesis, and in the other 2 patients the diagnosis of dermatitis herpetiformis was confirmed on skin biopsy. A patient with active Sjogren's syndrome was excluded from this part of the study.

(b) 8 normal control subjects (medical staff).

Immunoglobulin estimations were carried out on a single blood sample in 6 patients and on two blood samples, taken at an interval of at least 1 month, from each of the other 13 patients. Also, in 7 patients 3 blood samples were taken, 1 before and 2 after oral potassium iodide (KI) administration so that immunoglobulin levels could be estimated at different phases of disease activity: dapsone therapy was stopped 2 - 6 days before the test in the 3 patients on this treatment.

Single blood samples from 10 dermatitis herpetiformis patients on dapsone therapy were obtained to estimate serum complement (C'3) levels. The blood samples obtained during the KI test were also analysed for serum complement levels.

In the 8 control subjects single blood samples were taken from 4. In the other 4 a further sample was taken at 24 hours: these 4 control subjects then swallowed 1.5 g KI and 24 hours later a third blood sample was removed. Complement estimations were performed on all sera from the control subjects.

Serum/

Serum from all blood samples being used for complement analysis was separated immediately and stored at -20°C until tested.

Serum immunoglobulin estimation - Quantitative determination of the serum immunoglobulins, IgG, IgA and IgM in this part of the study was also carried out by the radial immunodiffusion technique, using locally produced rabbit antisera. The normal range in the laboratory is IgG 700 - 1800 mg/100 ml, IgA 90 - 450 mg/100 ml, and IgM 50 - 280 mg/100 ml.

Serum complement (C'3) estimation - Quantitative estimation of complement (C'3) levels was performed with commercially available radial immunodiffusion plates (Hyland Immuno-plates, Baxter Laboratories Ltd., Norfolk, England). The normal range is 100 - 190 mg/100 ml.

Potassium iodide provocation test - An exacerbation of the disease activity was induced by orally administered potassium iodide (KI) in the 7 patients with dermatitis herpetiformis mentioned above. A small test dose (60 mg) was given 1 day before the full dose: this varied between 1.2 and 2 g, depending mainly on clinical activity at the time of the test. Each patient was started on dapsone therapy 24 hours after the main dose of KI. Disease activity was graded in the following manner: 4+, active with bullae; 3+, active with vesiculation; 2+, moderately active with or without minimal vesiculation; 1+, minimally active with few lesions; 0, no active lesions present.

RESULTS/

RESULTS

Part 1. Details of the 33 patients with dermatitis herpetiformis together with the serum immunoglobulin levels are given in Table VII. Where immunoglobulins were estimated on more than one occasion the mean values are recorded and used for subsequent analysis. The intestinal biopsy grading results determined in Part I of the thesis are also included in the table. Comparison was made between the levels of IgG, IgA and IgM in the dermatitis herpetiformis group and those of the control subject group. To obtain a more normal distribution the IgM values were converted to logarithms. The mean IgG level of the dermatitis herpetiformis patients at 1158 mg/100 ml was similar to the control group value of 1121 mg/100 ml ($t = 0.379$; $P > 0.35$); the mean IgA value at 254 mg/100 ml was significantly greater than the control group mean of 188 mg/100 ml ($t = 2.764$; $P < 0.005$); and the mean IgM value 73 mg/100 ml was significantly lower than the control group mean of 132 mg/100 ml ($t = 2.534$; $P < 0.01$).

The IgA and IgM values in patients with intestinal mucosal grades 1 and 2 were compared with the same values in patients with intestinal mucosal grades 3 and 4. There was no significant difference between the two groups in IgA values ($t = 0.995$; $P > 0.15$) or IgM values ($t = 0.701$; $P > 0.20$).

In 10 patients with dermatitis herpetiformis the initial IgA and IgM values were/

were compared with the second values obtained at least 1 month after starting dapsone therapy (Table VIII). No dapsone effect on these immunoglobulins was noted; nor did any significant changes in IgG levels occur. Also, immunoglobulin levels could not be related to the duration of the skin disease (Table VII).

The results of the immunoglobulin determinations in the group of other skin diseases are shown as the means (\pm standard error) for the 3 classes of immunoglobulin determined (Fig. 18, 19 and 20). The dermatitis herpetiformis group results were included for comparison in these figures. For each skin disease statistical comparison was made with the control group. In the discoid lupus erythematosus group serum IgA and IgM levels showed marked variation making analysis of results in a small number of patients somewhat unsatisfactory. Significant depression of the mean IgG level occurred in erythema multiforme; the mean IgA levels were significantly raised in eczema, psoriasis, rosacea and discoid lupus erythematosus; the mean IgM levels were significantly depressed in psoriasis ($P < 0.0005$).

Part 2. Immunoglobulin studies - The immunoglobulin values of the 19 patients with dermatitis herpetiformis in this part of the study are recorded in Table IX. The IgG level was high (> 1800 mg/100 ml) in 2 patients. The IgA level was low (< 90 mg/100 ml) in 1 patient. IgM values were low (< 50 mg/100 ml)/

(<50 mg/100 ml) in 5 of the 19 patients.

The results of the estimation of immunoglobulin values in dermatitis herpetiformis at different phases of disease activity are recorded in Table X. The test dose of KI had no appreciable effect on the skin eruption in any patient, but the main dose produced an exacerbation of the disease within 2 hours in 5 patients and at about 10 hours in 2. The eruption exacerbated in sites normally affected by the disease, lesions already present flaring up and new ones, papular and urticarial at first and later becoming vesicular or bullous, appearing. Mouth lesions, however, urticarial or vesicular in type and later becoming haemorrhagic, appeared in all subjects, and in 4, erythematous macules which later became haemorrhagic appeared on the palms or soles. Side effects of the iodide administration occurred only after the full dose. These were noted in 6 of the 7 patients and consisted of excessive lachrimation and salivation and pain in the throat and ears; pain in the region of the salivary glands was also noted in some patients. These are the symptoms of iodism and they settled without treatment in about 24 hours.

Serum complement (C'3) studies - In the 10 patients on dapsone therapy the serum complement levels ranged from 64 - 150 mg/100 ml with a mean value of 122 mg/100 ml. This compares with a range of 92 - 180 mg/100 ml in the 8 control subjects and a mean value of 152 mg/100 ml. Two patients in the/

the dermatitis herpetiformis group had slight lowering of complement levels at 76 and 64 mg/100 ml respectively, but there was no significant difference between the dermatitis herpetiformis and control group values ($t = 1.09$; $P = 0.15$).

The serum complement values obtained at different phases of disease activity in dermatitis herpetiformis are recorded in Table X. Only small differences of values were noted and did not differ significantly from the daily variation of 8 - 15 mg/100 ml or the variation of 0 - 10 mg/100 ml after administration of KI noted in the 4 control subjects.

DISCUSSION

Serum immunoglobulins have been widely studied in coeliac disease with some divergence of the results obtained. The most consistent finding has been in IgM levels where low values have been recorded in 20 - 40% of patients (Hobbs and Hepner, 1966; Asquith et al., 1969; Blecher et al., 1969). A later paper of Hobbs and Hepner (1968) recorded an even higher incidence of IgM deficiency, 61%, in a group of patients with untreated coeliac disease, and they found that treatment with a gluten-free diet frequently produced a return to normal serum levels. Søltøft and Weeke (1969) also noted that a low mean IgM level in a group of untreated coeliac patients increased significantly during treatment with a gluten-free diet, but Asquith et al. (1969)/

(1969) demonstrated a significant rise in IgM in only 2 of 10 patients with coeliac disease treated with this diet. Paradoxically, the local production of IgM in the jejunal mucosa of patients with untreated coeliac disease appears to be actually increased as evidenced by the increased number of IgM-containing plasma cells (Spiltoft and Weeke, 1969; Douglas et al., 1970) and the increase of IgM levels in the jejunal juice (Douglas et al., 1970). Consequently, as the lowering of IgM values has been demonstrated to be due to a defect in synthesis of this immunoglobulin (Brown et al., 1969), a defect which, incidentally, may be reversed in some patients on treatment with a gluten-free diet, the reduced production must occur in tissues other than the jejunal mucosa. Indeed, Douglas et al. (1970) have described a decreased number of IgM-containing plasma cells in the bone marrow in coeliac disease. And so, Hobbs et al. (1969) suggest that the IgM deficiency of coeliac disease is part of the depression of lymphoreticular dysfunction in this disease (McCarthy et al., 1966) and is secondary to the as yet unidentified primary lesion.

Serum IgM findings in dermatitis herpetiformis are remarkably similar to those determined in coeliac disease. The mean IgM value in the present study was significantly less than the control mean value, and IgM levels below 50 mg/100 ml were noted in 13 of 33 (39%) patients in the Glasgow series/

series and 5 of 19 (26%) patients in the Aberdeen series. Fry et al., (1967) and Marks (1968) also recorded that about one-third of dermatitis herpetiformis patients had IgM deficiency. This similarity in the incidence of IgM deficiency in dermatitis herpetiformis and coeliac disease occurs despite the fact that the enteropathy of the former disease is generally mild (Part I of the thesis) and, indeed, in the present work low IgM values were just as common in those whose jejunal biopsy showed a normal or mildly abnormal mucosa as in those with definite mucosal abnormalities. In the series of Fry et al., (1967) also, 2 of the 4 patients with IgM deficiency had a normal or near normal jejunal biopsy. Brow et al., (1971), however, have demonstrated, by taking multiple jejunal biopsies, that the gut lesion in dermatitis herpetiformis may be patchy and so gluten sensitivity of the intestinal mucosa cannot be excluded on a single biopsy: it may be that the presence of gluten sensitivity rather than the degree is the important factor in determining IgM deficiency. Certainly, in coeliac disease Hobbs and Hepner (1968) were unable to correlate IgM deficiency with any parameter of malabsorption or with any specific histological appearance in the small-bowel. On the other hand, only a percentage of patients with coeliac disease have low IgM levels and in those who have, the effect of a gluten-free diet on these levels is, as noted above, variable. And so, factors other than gluten sensitivity may be involved in the observed depression of IgM levels. Clearly, /

Clearly, therefore, the inability to relate IgM levels to the small-intestinal abnormalities in dermatitis herpetiformis does not necessarily indicate that the nature of the IgM changes in dermatitis herpetiformis is different from that in coeliac disease, and the suggestion that in coeliac disease IgM deficiency is part of a general lymphoreticular dysfunction (Hobbs et al., 1969) may also apply in dermatitis herpetiformis where evidence of such dysfunction, in the form of splenic atrophy, has been noted in some patients (Fry et al., 1967; Thesis, Part I).

The possibility of IgM deficiency in dermatitis herpetiformis being related to the skin eruption must also be considered. No consistent changes in levels, however, were noted on control of the disease process with dapsone (Table VIII) nor after the production of an exacerbation of the disease with oral potassium iodide (Table X). On the other hand, low serum levels of this immunoglobulin have been noted in pemphigoid (Lim and Fusaro, 1962), a blistering disease without an associated enteropathy (Marks and Shuster, 1969), and also in pemphigus (Waldorf and Rogentine, 1966; Grob and Inderbitzen, 1967), but the deficiency appears to be less marked, as in the series of Waldorf et al., only 2 of 21 patients with pemphigus had an IgM value below 50 mg/100 ml, and in the series of Grob and Inderbitzen only 3 of 15 patients with pemphigus had a mean level below 50 mg/100 ml: in neither/

neither series did the level of serum IgM fall below 40 mg/100 ml. Certainly, of the various skin diseases other than dermatitis herpetiformis studied in the present work, low levels of IgM were only noted in psoriasis (Fig. 20), a finding previously recorded by Krebs et al. (1963). A recent study by Varelzidis and Theodoridis (1971), however, has described normal IgM values in psoriasis. At all events, unlike the frequent increase in serum IgA levels, marked diminution of serum IgM levels appears to be uncommon in skin diseases. No clear evidence exists, therefore, to suggest that the IgM deficiency in dermatitis herpetiformis is related to the skin eruption.

In contrast to the substantial agreement on IgM levels in coeliac disease differing results on measurement of IgA levels have been obtained. Thus, Eidelman et al. (1966) and Asquith et al. (1969) noted significant increases in mean IgA levels in groups of patients with coeliac disease whereas others recorded that, in general, IgA levels were normal (Hobbs and Hepner, 1968; Blecher, 1969; Sjøtoft and Weeke, 1969). Nevertheless, Hobbs and Hepner (1968) did find high values in some patients; values which returned to normal on treatment with a gluten-free diet in 3 of 6 patients studied. Thus, gluten sensitivity which appears to induce low IgM values may also induce high IgA values. Eidelman et al. (1966) suggested that high serum IgA levels in coeliac disease were related to an increase in IgA-containing plasma cells in/

in the small-intestinal mucosa, but more recent studies have failed to show a significant increase in the numbers of these cells (Sjøltoft and Weeke, 1969; Douglas et al., 1970). An increase of these cells might have been expected to occur where serum IgA levels are high as the plasma cells of the intestinal mucosa contribute significantly to the pool of circulating IgA (Vaerman and Heremans, 1970). The situation in coeliac disease is further complicated by the association in some patients of the intestinal lesion of coeliac disease with severe isolated IgA deficiency (Crabbe and Heremans, 1967). Indeed, study of two large series of patients with coeliac disease has indicated that IgA deficiency has an incidence of about 1 in 50 (Asquith et al., 1969; Beale et al., 1971). These low levels of IgA are associated with a marked diminution in the numbers of IgA-containing plasma cells in the jejunal mucosa (Crabbe and Heremans, 1966), a situation which also obtains in IgA deficiency unassociated with gluten enteropathy (Eidelman et al., 1966; Eidelman and Davis, 1968; Douglas et al., 1970). It would appear, therefore, that IgA levels in patients with coeliac disease may be increased, normal or decreased and so, in view of the wide scatter of results, comparison with the findings in dermatitis herpetiformis is difficult.

In dermatitis herpetiformis the mean IgA level was significantly increased compared with the mean of the control group (Fig. 19) although only 1 of 52 patients/

patients had an IgA level above 450 mg/100 ml. Marks (1968), however, found the mean IgA level normal, and Fry et al. (1967), in his series of 12 patients, noted only 1 patient with a high IgA level (450 mg/100 ml). In relation to low IgA levels, 2 of the 52 patients had a clearly significant IgA deficiency (63 and 42 mg/100 ml) an incidence of isolated IgA deficiency similar to that recorded by Hobbs and Hepner (1968) in their study of 75 patients with coeliac disease, and very much higher than the 1 in 500 incidence reported for the normal population (Bachmann, 1965; Hobbs, 1968). IgA levels in dermatitis herpetiformis could not be correlated with the intestinal mucosal histology but in coeliac disease too serum IgA levels could not be related to the IgA-containing plasma cell population of the jejunal mucosa (Sjøltoft and Weeke, 1969; Douglas et al., 1970). Recently, it has been demonstrated that despite normal or high serum levels of IgA in coeliac disease a qualitative defect in this immunoglobulin occurs (Beale et al., 1971). The finding of a similar qualitative defect in dermatitis herpetiformis would further increase the likelihood of the IgA changes in this disease being related to the enteropathy rather than the skin eruption. Such an investigation, however, has not as yet been reported.

Previous work has noted the presence of high IgA levels in several skin diseases (Lim and Fusaro, 1962; Varelzidis et al., 1966; Grob and Inderbitzen, /

Inderbitzen, 1967) and the frequent occurrence of this abnormality is confirmed in the present study where high mean IgA levels were present in 4 of the 7 other skin diseases studied (Fig. 19). In psoriasis, clearing of the skin eruption produced a return to normal of high IgA values (Varelzidis and Theodoridis, 1971) but no such alteration was noted, in the present work, on control of the skin eruption of dermatitis herpetiformis with dapsone (Table VIII). Also, the serum IgA levels did not alter significantly during an exacerbation of the disease process produced by KI (Table X). However, in view of the frequency of high IgA levels in skin diseases it may well be that the presence of the skin eruption in dermatitis herpetiformis does contribute, to some extent, to the high IgA levels.

The results obtained on investigation of serum IgG levels in coeliac disease are even more variable than for the other immunoglobulins. Thus, Hobbs and Hepner (1968) and Sjøtoft and Weeke (1969) stated that in general IgG levels were normal, Blecher et al. (1969) found that a considerable proportion of patients had raised IgG levels and Asquith et al. (1969) reported the mean IgG level in a group of coeliac patients was significantly lower than the mean level in a control group. Sjøtoft and Weeke (1969) while noting an increase in IgG-containing plasma cells in the jejunal mucosa of patients with coeliac disease could not correlate serum levels with this increase. At all events, no/

no significant difference was noted between the mean IgG level in the dermatitis herpetiformis patients and the controls (Fig. 18). Abnormal results within the series were few: the IgG was over 1800 mg/100 ml in 5 patients and the IgG was less than 700 mg/100 ml in 2 patients. Similar findings have been reported by Fry et al. (1967) and Marks (1968). Alterations in serum IgG levels do not appear to be a common feature in diseases of the skin as they were noted in only 1, erythema multiforme, of the 7 other skin diseases studied (Fig. 18).

The possibility of an immunological reaction occurring in the skin in dermatitis herpetiformis has been suggested by the finding of immunoglobulins and complement in the dermal papillae in this disease (Van der Meer, 1969; Cormane et al., 1970; Chorzelski et al., 1971; Cormane and Giannetti, 1971; Holubar et al., 1971). Immunoglobulin-complement complexes occur in the skin (Kalsbeek and Cormane, 1964; Ten Have-Opbroek, 1966) and renal glomeruli (Lachmann et al., 1962; Paronetto and Koffler, 1965; Koffler et al., 1967) in systemic lupus erythematosus, and in the dermal blood vessels of patients with allergic vasculitis (Stringa et al., 1966; Copeman, 1970), and a fall of serum complement levels during exacerbations of these diseases provides evidence of an active immunological reaction (Elliott and Mathieson, 1953; Wedgewood and Janeway, 1953; Morse et al., 1962; /

1962; Townes et al., 1963; Schur and Sandson, 1968; McDuffie, 1970).

Consequently, particularly as allergic vasculitis affects the skin to approximately the same extent as active dermatitis herpetiformis, a fall in serum complement levels could have been expected in dermatitis herpetiformis if a similar immunological reaction occurred. No significant alterations in the serum levels of complement were obtained at different phases of skin disease activity (Table X). However, the main immunoglobulin detected in the skin in dermatitis herpetiformis is IgA and as this is only complement-binding when attached to secretory piece (Adinolfi et al., 1966) the complement present in the skin may not be involved in the main immunological reaction. It may be, indeed, that the quantity of complement present in the skin is insufficient to affect serum levels, a situation which presumably obtains in pemphigoid where normal serum complement levels are reported (Katz, Inderbitzen and Halprin, 1970) despite the presence of immunoglobulin-complement complexes in the skin (Chorzelski and Corman, 1968) and basement-membrane zone antibodies in the serum (Beutner et al., 1965; Chorzelski et al., 1966; Jordan et al., 1967; Chorzelski et al., 1968). Serum immunoglobulin levels, like the complement levels, did not change significantly during the KI investigation (Table X) and although this does not exclude an antibody response in dermatitis herpetiformis (the antibody response would require to be massive to be detectable/

detectable on estimation of gross immunoglobulin levels) these findings do not provide any further evidence in favour of an immune reaction in the skin in this disease.

Thus, the immunoglobulin changes in dermatitis herpetiformis seem more likely to be associated with the enteropathy than related to the skin lesions, but the cause of these abnormalities is still uncertain.

SUMMARY

Serum immunoglobulins, IgG, IgA and IgM were determined in 52 patients with dermatitis herpetiformis: 33 patients comprised the Glasgow series, and 19 the Aberdeen series. Mean immunoglobulin levels of patients in the Glasgow series were compared with mean levels obtained in a control series: the mean IgG level was not significantly different from the control mean; the mean IgA level was significantly raised; and the mean IgM level significantly lowered. Results for individual patients revealed an abnormally high IgA level in only 1 patient, and an abnormally low level in 1 patient from each series. Similarly, the results for each series were comparable in IgM levels, low levels occurring in 39% of patients in the Glasgow series, and 26% of patients in the Aberdeen series. These immunoglobulin changes are similar to those occurring in coeliac disease. Immunoglobulin values, however, could not be correlated with the histological appearances of the small-intestinal mucosa. Also, immunoglobulin levels/

levels were unaffected by dapsone therapy and could not be related to the duration or activity of the skin disease. Estimation of serum immunoglobulin and complement (C'3) levels at different phases of disease activity did not provide any further evidence for an immunological basis to the skin eruption. Serum immunoglobulin determinations, in the 7 other skin diseases studied, revealed that an increase in the mean IgA level occurred commonly whereas a definite lowering of mean IgM level was noted only in psoriasis. It was concluded that the serum immunoglobulin abnormalities in dermatitis herpetiformis cannot be clearly related to the presence of disease in the small-intestine or the skin and may be part of a general lymphoreticular dysfunction in this disease.

TABLE VII - Serum Immunoglobulin Levels and Other Details in 33 Patients with Dermatitis Herpetiformis (Glasgow Series)

Patient no.	Sex and age	Duration of skin disease (years)	Intestinal mucosa (biopsy grade)	Serum immunoglobulins* (mg/100 ml)		
				IgG	IgA	IgM
1	F 53	3	1	1032	83	36
2	F 58	20	1	1416	267	81
3	F 16	1	1	1204	212	57
4	F 15	12	1	918	63	179
5	F 58	3	1	880	348	61
6	M 62	2½	1	525	158	17
7	M 54	4	1	1995	300	125
8	M 14	2	2	896	111	42
9	M 24	¾	2	939	331	47
10	M 47	2	2	816	274	76
11	M 24	7	2	780	420	60
12	M 26	½	2	850	180	20
13	F 72	8	2	1004	207	33
14	M 20	5	2	1006	230	107
15	M 60	1	2	1148	300	53
16	F 53	1	3	920	134	48
17	M 33	4½	3	1420	278	35
18	M 67	12	3	1201	334	107
19	M 38	¼	3	1995	380	66
20	M 8	2½	3	1122	102	38
21	F 63	3	3	1027	229	37
22	M 29	Yrs	3	646	180	30
23	M 54	17	3	1882	411	22
24	M 50	15	3	1494	259	71
25	M 56	3	3	1737	341	156
26	M 37	½	3	1552	403	59
27	M 29	1½	3	1000	166	110
28	F 58	42	3	928	82	147
29	F 39	15	3	769	95	107
30	F 26	2½	3	1585	295	186
31	M 69	15	4	1476	540	119
32	M 33	1½	4	924	370	23
33	F 20	2½	4	1128	287	62

* Normal range: IgG 700 - 1800 mg/100 ml; IgA 90 - 450 mg/100 ml; IgM 50 - 280 mg/100 ml.

TABLE VIII - Serum IgA and IgM Levels in 10 Patients with Dermatitis Herpetiformis Before and After Dapsone Therapy (Glasgow Series)

Patient no.	Sex and age	Serum IgA* (mg/100 ml)		Serum IgM* (mg/100 ml)	
		B	A	B	A
3	F 16	196	182	13	53
4	F 15	89	56	208	240
5	F 58	345	398	56	70
9	M 24	446	402	53	50
11	M 24	420	360	60	50
13	F 72	180	200	35	19
21	F 63	360	300	38	36
23	M 54	360	398	20	17
28	F 58	70	85	100	224
33	F 20	195	360	14	60

* Normal range: IgA 90 - 450 mg/100 ml; IgM 50 - 280 mg/100 ml.

B = before dapsone therapy

A = after dapsone therapy

TABLE IX - Serum Immunoglobulins and Other Details in Patients with Dermatitis Herpetiformis (Aberdeen Series)

Patient no.	Sex and age	Duration of skin disease (years)	Intestinal mucosa (biopsy grade)	Serum immunoglobulins* (mg/100 ml)		
				IgG	IgA	IgM
1	F 49	9	1	1440	156	116
2	M 62	4	1	1420	174	16
3	F 42	11	1	1068	292	76
4	F 57	2	1	1340	172	144
5	M 59	12	1	1590	426	22
6	M 54	$\frac{1}{2}$	1	1670	220	98
7	F 42	$4\frac{1}{2}$	1	1600	128	76
8	M 37	$\frac{3}{4}$	1	1000	125	82
9	M 62	1	2	1000	100	136
10	M 45	3	3	1200	156	44
11	F 48	5	3	1960	124	188
12	F 34	$\frac{1}{2}$	3	1636	138	64
13	M 20	1	4	800	42	92
14	M 59	1	4	1710	156	35
15	F 14	2	4	1838	190	121
16	M 20	$\frac{1}{4}$	4	950	106	36
17	M 33	$\frac{1}{2}$	4	1600	228	58
18	F 62	4	-	950	180	130
19	M 69	7	-	1268	96	60

* Normal range: IgG 700 - 1800 mg/100 ml; IgA 90 - 450 mg/100 ml; IgM 50 - 280 mg/100 ml.

TABLE X - Serum Immunoglobulins and Complement (C'3) Levels at Different Phases of Disease Activity in Patients with Dermatitis Herpetiformis (Aberdeen Series)

Patient no.	Serum* samples	Severity of disease	Treatment	Serum immunoglobulins† (mg/100 ml)			C'3 (mg/100 ml)
				IgG	IgA	IgM	
10	a	3+	none	1120	128	34	80
	b ₁	4+	none	1360	208	45	86
	c	2+	dapsone	1200	156	44	86
5	a	3+	none	1300	434	16	110
	b ₂	4+	none	1250	452	20	115
	c ²	2+	dapsone	1340	492	24	105
3	a	0	none	1000	368	92	83
	b	3+	none	940	368	92	80
	d	2+	dapsone	908	360	88	86
14	a	2+	none	1420	184	41	130
	b	3+	none	1280	180	39	150
	d	2+	dapsone	1180	176	36	150
4	a	2+	none	1240	160	168	120
	b	3+	none	1040	120	128	130
	d	2+	dapsone	1280	156	160	120
6	a	2+	none	1660	296	128	130
	b	3+	none	1660	320	140	145
	e	0	dapsone	1520	328	120	145
15	a	1+	none	1660	236	146	105
	b	3+	none	1580	232	136	105
	e	0	dapsone	1380	208	132	115

* Timing of samples: a - before potassium iodide (KI); b - 24 hours after KI; c¹ - 7 days before KI; c² - 14 days before KI; d - 3 days after KI; e - 7 days after KI.

† Normal range: IgG 700 - 1800 mg/100 ml; IgA 90 - 450 mg/100 ml; IgM 50 - 280 mg/100 ml.

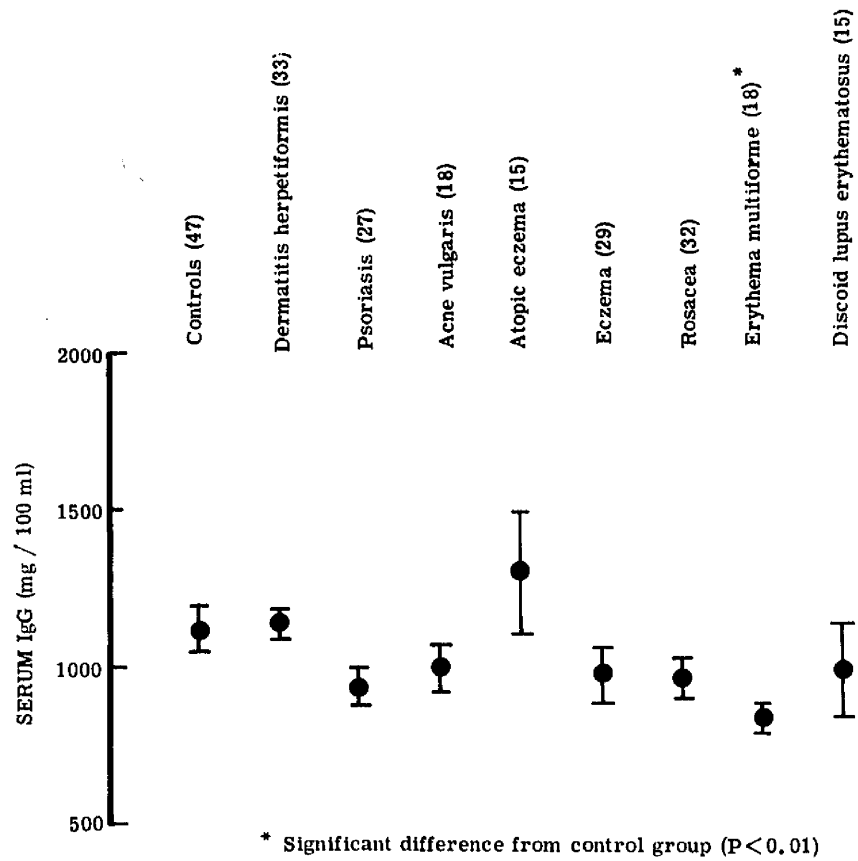


Fig. 18. - Levels of IgG (mg/100 ml) in control subjects and patients with various skin diseases. Results expressed as mean - standard error. () - numbers in brackets represent numbers of patients.

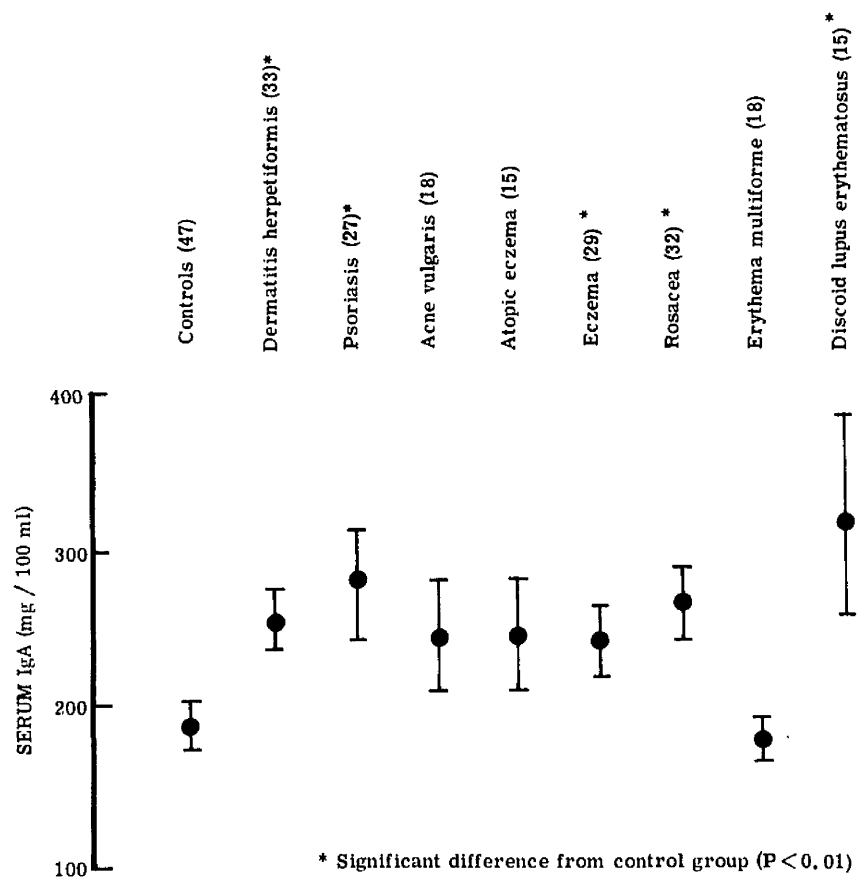


Fig. 19. - Levels of IgA (mg/100 ml) in control subjects and patients with various skin diseases. Results expressed as mean \pm standard error. () - numbers in brackets represent numbers of patients.

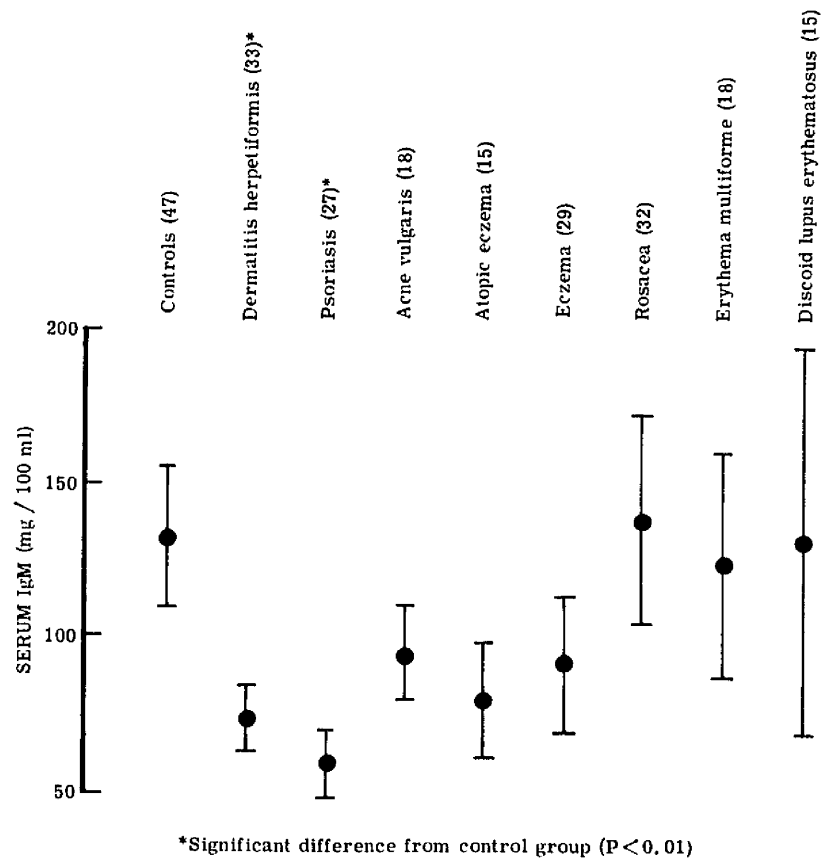


Fig. 20. - Levels of IgM (mg/100 ml) in control subjects and patients with various skin diseases. Results expressed as mean \pm standard error. () - numbers in brackets represent numbers of patients.

PART III

SERUM AUTOANTIBODIES

INTRODUCTION

Although dermatitis herpetiformis had been described by Duhring in 1884 no serious suggestion of an association with small-intestinal disease had been put forward before the recent work using the small-intestinal biopsy capsule (Marks et al., 1966; Fraser et al., 1967; Fry et al., 1967; Van Tongeren et al., 1967; Bendl and Williams, 1968; Marks et al., 1968); the failure to recognise the association was due to the infrequent occurrence of clinical malabsorption even when relatively large numbers of patients were studied (Smith, 1966). During the previous parts of this study (Parts I and II) several patients with dermatitis herpetiformis were noted to have concomitant autoimmune disease, particularly thyroid disease. Review of the literature also revealed the occasional association of dermatitis herpetiformis with thyrotoxicosis (Du Castel, 1912; Werther, 1925; Hansen, 1937; Ratner et al., 1950; Smith, 1966) and, more recently, pernicious anaemia (Ilyas, 1968; Wyburn-Mason, 1968).

And so, to ascertain the possibility of a significant association between dermatitis herpetiformis and autoimmune disorders a study was undertaken to determine the incidence of serum antibodies of organ specific and non-organ specific types and, further, to seek to relate any abnormalities found with the presence of disease in the small-intestine (Part I) or the previously noted changes/

changes in the immunoglobulin levels (Part II).

PATIENTS AND METHODS

The investigation for the presence of thyroid and gastric autoantibodies was undertaken in 42 adult patients (males, 22; females, 20) and a boy of 8 years. These comprised 33 patients included in Part I of the thesis, and 10 patients not previously involved in the work. The diagnosis of dermatitis herpetiformis in these latter patients had been determined on histological grounds in 9 and on clinical grounds alone in 1. 28 of the patients were from the Glasgow area and 15 from the Aberdeen area. The control series, matched for age and sex, consisted of 41 patients with skin diseases and 2 normal persons. Overt putative autoimmune diseases, including thyroid disease and pernicious anaemia, were excluded from both series: the patients excluded from the test series were 4 patients with a history of thyroid disease (thyrotoxicosis, 3; Hashimoto's disease, 1) and 1 patient with Sjogren's syndrome.

Serum samples were obtained from patients and controls and stored at -20°C until used. All samples were tested at the same time to avoid inaccuracies caused by variation in the sensitivity of the test procedures which may occur at different times. The method of Fulthorpe et al. (1961), involving the agglutination of tanned red cells coated with human thyroglobulin, was used to/

to test for thyroglobulin antibodies: the fluorescent antibody technique of Coons and Kaplan (1950) was used to look for thyroid microsomal and gastric parietal cell antibody. In those patients with gastric parietal cell antibody examination for the presence of intrinsic factor antibody was undertaken by the method of Ardeman and Chanarin (1963) in which the ability of this antibody to block the uptake of ^{60}Co -vitamin B_{12} by serum in the presence of normal gastric juice is utilized.

Investigation for the presence of antinuclear factor was undertaken in 51 adult patients (males, 29; females, 22) - 45 patients who had been studied in Part I of the thesis, and 6 other patients with dermatitis herpetiformis from the Aberdeen area; the diagnosis having been made on clinical and histological grounds. Patients with putative autoimmune diseases were excluded as before. Examination for the presence of antinuclear factor in the serum was performed using the immunofluorescent technique (Beck, 1961). Investigation of a control series was not carried out.

The results of small-intestinal biopsy and serum immunoglobulin assays carried out in Parts I and II of the thesis respectively were used for analysis of results in this part of the study.

RESULTS

Thyroid autoantibodies (Table XI) - Thyroid microsomal antibody was present in 9 patients (males, 5; females, 4) with dermatitis herpetiformis and in 1 control/

control subject; $\chi^2 = 5.5$, d.f.1, $P < 0.02$. Thyroglobulin antibody in titres ranging from $\frac{1}{64}$ to $\frac{1}{256}$ occurred in 6 patients (all female) and did not occur in the control subjects. As 2 patients with the latter antibody did not have thyroid microsomal antibody the overall incidence of thyroid antibody was 11 in the dermatitis herpetiformis group and 1 in the control subject group; $\chi^2 = 7.8$, d.f.1, $P = 0.005$.

Gastric autoantibodies (Table XI) - Gastric parietal cell antibody was present in 10 patients (males, 7; females, 3) with dermatitis herpetiformis and in 4 control subjects (females, 3; male, 1). This difference is not significant. Intrinsic factor antibody was not present in any of the 10 patients with gastric parietal cell antibody. Five of the 10 patients with gastric parietal cell antibody also had thyroid microsomal antibody.

Antinuclear factor - 3 of the 51 patients with dermatitis herpetiformis had antinuclear factor in the serum.

Relationship of thyroid and gastric autoantibodies to the small-intestinal mucosa and serum immunoglobulin levels - 5 of 13 patients with autoantibody in whom intestinal biopsy had been performed, showed severe mucosal abnormalities; an incidence of abnormality similar to that obtained in the whole series (Part I).

Immunoglobulin levels were available (Part II) for 9 patients with serum autoantibody/

autoantibody and 11 patients without serum autoantibody. In 2 patients (1 from each group) serum IgA levels were < 90 mg/100 ml, and as IgA deficiency is known to be associated with an increased incidence of autoimmune disease (Hobbs, 1968; Cassidy et al., 1969; Ammann and Hong, 1970), these patients were excluded from the statistical analysis. The patients in both groups formed part of the Glasgow series of immunoglobulin estimations thus allowing valid comparison. No significant difference was present between IgA levels in the 2 groups ($t = 0.601$; $P > 0.25$), but a significant difference was present between the serum IgM levels in the 2 groups (Fig. 21): the mean IgM value in 8 patients with autoantibody in the serum was 44 mg/100 ml, and the mean IgM value in 10 patients without autoantibody in the serum was 98 mg/100 ml ($t = 3.467$; $P < 0.0025$).

DISCUSSION

Little attention has been paid in the past to disease processes occurring in association with dermatitis herpetiformis, and the references made to concomitant thyrotoxicosis mainly sought to indicate that thyroid hyperfunction could aggravate the skin eruption. Thus, Hansen (1937) in discussing the previously noted association of the two diseases (Du Castel, 1912; Werther, 1925) and reporting a patient of his own with dermatitis herpetiformis and thyrotoxicosis, stated that the giving of thyroid extract to another dermatitis herpetiformis/

herpetiformis patient with normal thyroid function caused the skin eruption to exacerbate. Similarly, Ratiner et al. (1950) stressed the deleterious effect of thyroid overactivity when recording that oral potassium iodide, given preoperatively to a patient with dermatitis herpetiformis and thyrotoxicosis, paradoxically produced an immediate improvement in the skin eruption. Smith (1966), however, on noting that in 2 of 3 patients with both diseases the skin eruption settled after subtotal thyroidectomy, suggested that the eruption in these cases was a cutaneous manifestation of thyroid overactivity, analogous or even related to the generalised pruritus which may occur in thyrotoxicosis, rather than true dermatitis herpetiformis. On the other hand, treatment of the thyrotoxicosis present in the 3 patients excluded from this part of the study did not produce clearing of the skin eruption, and this was also true of the patient recorded by Andersson et al. (1971a). It is more likely, therefore, that the improvement noted in some patients on treatment of the thyroid disorder is non-specific, and not indicative of a basic difference in the skin disease process.

In seeking further to determine the status of thyrotoxicosis in patients with dermatitis herpetiformis advantage was taken of the fact that thyrotoxicosis is regarded as one of the autoimmune thyroid disorders, the histological changes of autoimmune thyroiditis (lymphocyte infiltration and Askanazy/

Askanazy cell change) being found in most thyrotoxic glands (Gell and Coombs, 1968). These glandular changes correlate well with the presence of thyroid microsomal antibody in the serum (Goudie et al., 1959) and, indeed, this antibody was found in the sera of 65% of thyrotoxic patients in one series (Anderson et al., 1964). And so, the finding of an increased incidence of this antibody in dermatitis herpetiformis patients with normal thyroid function (Table XI) would suggest that there is an increased incidence of subclinical thyroiditis in these patients, and that study of a large series of patients might reveal a significant association with clinical autoimmune thyroid disease. The occurrence of dermatitis herpetiformis and thyrotoxicosis in the same patient, therefore, may have more significance than previously thought.

Pernicious anaemia, another member of the autoimmune group of diseases, has also been reported in association with dermatitis herpetiformis - although on only a few occasions (Ilyas, 1968; Wyburn-Mason, 1968; Cream and Scott, 1970). Atrophic changes in the gastric mucosa constitute the pathological abnormality of pernicious anaemia and gastric parietal cell antibody is present in the serum of about 90% of patients with this disease (Taylor et al., 1962). Conversely, the presence of this antibody in the serum correlates well with the occurrence in the stomach of varying degrees of gastritis (Adams et al., 1964). And so, the increased incidence of gastric parietal/

parietal cell antibody in the serum of patients with dermatitis herpetiformis (Table XI) would suggest an increased incidence of gastritis in these patients. Intrinsic factor antibody studies were negative and, therefore, did not provide evidence for the presence of latent pernicious anaemia in those patients with gastric parietal cell antibody; but as the former antibody is found in the serum of only about 60% of patients with the overt disease (Ardeman and Chanarin, 1963), these negative findings are not conclusive. Indeed, a low secretion of acid and intrinsic factor has been reported in dermatitis herpetiformis (Andersson et al., 1971a), a finding consistent with the presence of gastritis inferred from the present autoantibody study, and low serum B₁₂ levels have been noted by some authors (Marks et al., 1968; Cream and Scott, 1970). And so, although the common lowering of serum folate levels in dermatitis herpetiformis, and the demonstrated malabsorption of food folate (Hoffbrand et al., 1970), would indicate that folic acid deficiency is the main factor in producing megaloblastic anaemia in this disease, the findings discussed above would suggest that a significant association may also exist with pernicious anaemia.

The finding of an increased incidence of organ-specific autoantibodies in dermatitis herpetiformis again raises the question, previously discussed in Part II, of the skin disease process itself being of an immunological nature. Certainly, /

Certainly, there is little to suggest that dermatitis herpetiformis is an autoimmune disease: the histological reaction in the skin consists of an acute inflammatory cell infiltrate rather than the lymphocytic infiltrate of organ-specific autoimmune disease; the male sex preponderance (Wyatt et al., 1971) contrasts with the female preponderance of organ-specific autoimmune disease; the rare familial occurrence of dermatitis herpetiformis (Marks et al., 1971) contrasts with the well known familial incidence of organ-specific autoimmune disease; and, whereas serum autoantibodies against the affected organ are usually present in patients with organ-specific autoimmune disease, circulating skin antibodies are not present in dermatitis herpetiformis (Chorzelski et al., 1967; Jordan et al., 1967). However, patients with autoimmune disease appear to have an increased liability to react to various antigens. Thus, in thyroid disease Blizzard et al. (1959) have reported an increased incidence of allergic reactions, particularly against penicillin, and in the relatives of patients with pernicious anaemia, Whittingham and Ungar (1969) have described an increased prevalence of allergic diseases. Conversely, Serafini et al. (1965) noted that patients with type I hypersensitivity diseases (asthma and allergic rhinopathy) had an increased incidence of thyroid and gastric autoantibodies in the serum. And so, the results of this part of the investigation could be regarded as further/

further evidence to suggest that the immunoglobulins and complement found in the skin in dermatitis herpetiformis (Van der Meer, 1969; Cormane et al., 1970; Chorzelski et al., 1971; Cormane and Giannetti, 1971; Holubar et al., 1971) are involved in an immunological reaction.

The possible relationship of organ-specific autoantibodies to the disease process in the small-intestine must also be considered, since Seah et al. (1971) reported that these autoantibodies were increased not only in dermatitis herpetiformis but also in adult coeliac disease. However, no correlation could be established between serum autoantibody and jejunal abnormality in dermatitis herpetiformis patients: the proportion of patients with mucosal change in the group with autoantibody was similar to the incidence of mucosal abnormality in the series as a whole.

The possibility of serum autoantibodies in dermatitis herpetiformis being related to immunoglobulin abnormalities was suggested by the reported observations of an increased incidence of autoimmune disease in serum IgA deficiency (Hobbs, 1968; Cassidy et al., 1969; Ammann and Hong, 1970) and by the report of Lancaster-Smith and Strickland (1971) in which they correlated the presence of serum autoantibodies in a group of patients with adult coeliac disease with serum IgM deficiency. Consequently, a correlation was sought between the presence of serum autoantibodies in dermatitis/

dermatitis herpetiformis and the immunoglobulin abnormalities noted in this disease (Part II). Only 1 patient with serum autoantibody had a low serum IgA level, but serum IgM levels were significantly lower in the group of patients with autoantibody than in the group of patients without autoantibody in the serum. The increased activity of cellular immune mechanisms in IgA deficiency which are thought to produce the increased incidence of autoimmune phenomena (Hobbs, 1968) may also be operative where IgM deficiency occurs, particularly if a qualitative defect of IgA, as has been reported in coeliac disease (Beale et al., 1971), is also present in dermatitis herpetiformis.

The non-organ-specific autoimmune diseases have not been reported in association with dermatitis herpetiformis, but Seah et al. (1971) suggested that a more general immunological disturbance than occurs in organ-specific autoimmune disease may be present in this condition in view of their finding of an increased incidence of antinuclear factor and the presence of anti-reticulin antibody. Surprisingly, although Seah and his colleagues found an even higher incidence of anti-reticulin antibody in adult coeliac disease than in dermatitis herpetiformis, no increase in the incidence of antinuclear factor was noted in the former disease. Similarly, Lancaster-Smith and Strickland (1971) did not discover antinuclear factor in any of their 23 patients/

patients with adult coeliac disease. The incidence of antinuclear factor in dermatitis herpetiformis in the present work (6%) was very much smaller than the 35% incidence noted by Seah et al. and was, in fact, similar to the 4% incidence which they noted in their control group.

The description of antibodies reacting against the basement membrane zone of the jejunal mucosa in some patients with dermatitis herpetiformis (Dick et al., 1969) also raises the possibility of an immunological upset involving a number of different tissues being present in this disease, but, while a similar antibody has been described in a group of patients with coeliac disease and IgA deficiency (Ammann and Hong, 1971), Holubar et al. (1971) were unable to confirm the findings of Dick and her colleagues in dermatitis herpetiformis.

In conclusion, therefore, the occasional reports of the occurrence of organ-specific autoimmune disease in patients with dermatitis herpetiformis, together with the increased incidence of thyroid and gastric autoantibodies, may indicate the presence of a defect of immune tolerance in this disease: the reports suggesting that this defect is of a general nature are, however, largely unconfirmed.

SUMMARY

The incidence of thyroid and gastric autoantibodies in the sera of 43 patients/

patients with dermatitis herpetiformis was determined and compared with a control group matched for age and sex. Eleven patients with dermatitis herpetiformis had thyroid autoantibody in the serum (thyroid microsomal antibody, 9; thyroglobulin antibody, 6) compared with 1 control subject with thyroid microsomal antibody. This difference is statistically significant. Ten patients with dermatitis herpetiformis had gastric parietal cell antibody in the serum compared with 4 control subjects. This difference does not reach statistical significance. Intrinsic factor antibody was not present in any of the 10 patients with gastric antibody. The presence of thyroid or gastric autoantibody could not be related to small-intestinal biopsy findings, but a significant relationship was noted with low serum IgM levels. The incidence of antinuclear factor was determined in 51 patients with dermatitis herpetiformis and was found in the serum of only 3 patients. It was concluded that while these findings suggest that a relationship between dermatitis herpetiformis and organ-specific autoimmune disease may indeed exist, they do not support the suggestion of a more general upset in immune tolerance in this disease.

Addendum:

The diagnosis of dermatitis herpetiformis was subsequently found to be erroneous in 2 patients included in this part of the study: the boy of 8 years who/

who was accepted into the investigation on clinical grounds alone (he had previously attended the Skin Department as a case of dermatitis herpetiformis over a period of 5 years) was later found to be non-reactive to oral potassium iodide, and biopsy of an early lesion showed a folliculitis reaction histologically; and a woman of 59 years diagnosed on clinical and histological grounds later developed pemphigoid. Autoantibody was not present in the serum of either of these patients and so their exclusion from the series would, if anything, increase the significance of the results.

TABLE XI - Incidence of Thyroid and Gastric Autoantibodies in Patients with Dermatitis Herpetiformis and in Control Subjects.

Number of patients with	Diagnosis (and number) of patients	
	Dermatitis herpetiformis (43)	Controls (43)
Thyroid microsomal antibody	9	1
Thyroglobulin antibody	6	0
Either type of thyroid antibody	11	1
Gastric parietal cell antibody	10	4

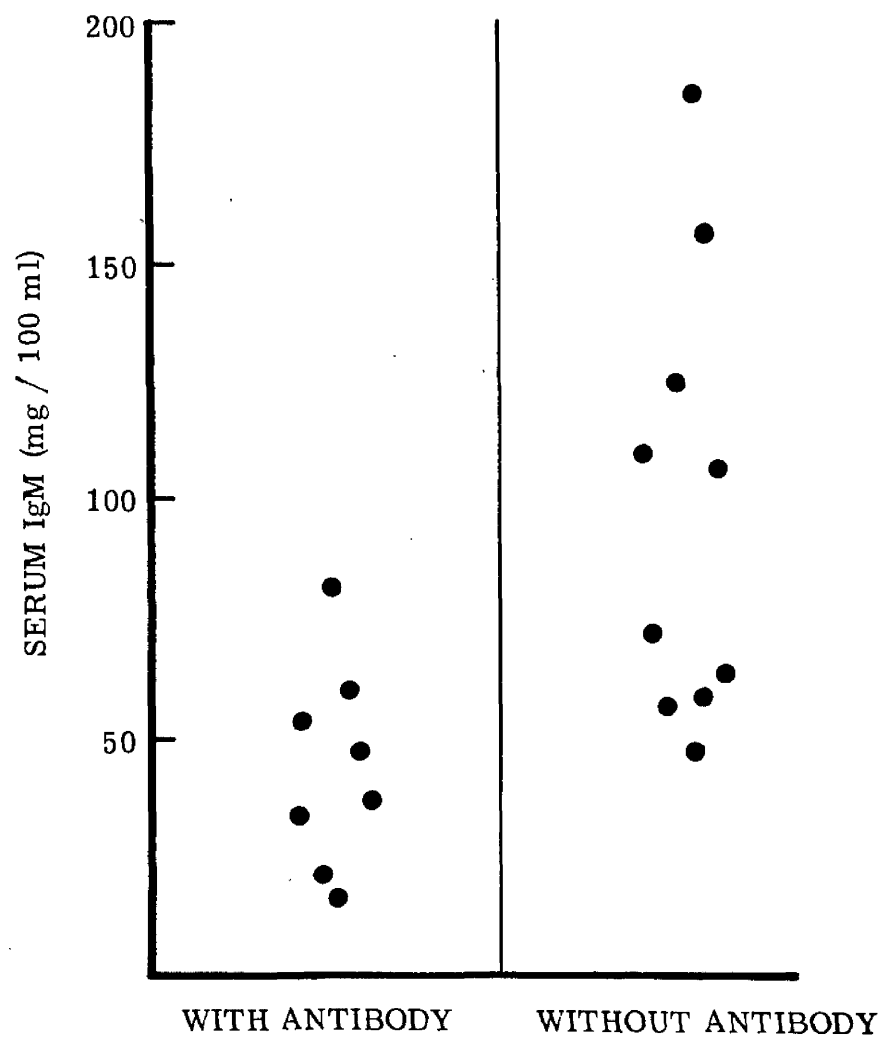


Fig. 21. - Serum IgM levels in patients with and without antithyroid or anti-gastric antibodies in the serum.

GENERAL DISCUSSION

The existence of an association between dermatitis herpetiformis and small-intestinal disease was not suspected from the literature on this disease: the investigation of Marks et al. (1966) was part of a survey of the structure and function of the small-intestine in various skin diseases; and the present investigation was begun to test the hypothesis that the variation in the dose of dapsone necessary to control the rash was due to a drug-induced enteropathy with consequent malabsorption of the drug. The survey has demonstrated, however, that the incidence of small-intestinal abnormality in dermatitis herpetiformis is similar whether treatment with dapsone has been given or not; and it is unlikely that absorption of the drug is significantly altered by the presence of small-bowel abnormality (Alexander et al., 1970).

The failure to recognise the association of small-intestinal disease with dermatitis herpetiformis before the use of the small-intestinal biopsy capsule is not surprising, however, in view of the infrequency of a severe malabsorption state (an incidence of 4% in Part I). The relative absence of symptoms and signs of malabsorption, and the frequency with which malabsorption tests were normal even in patients with severe mucosal changes, has been the experience of all investigators in this field. Marked depression of disaccharidase enzyme concentrations was associated with these mucosal changes but, although lactase concentrations/

concentrations were often low, lactose intolerance was noted in only one patient. The disparity between the severity of the histological abnormalities and the mildness and infrequency of symptomatology is likely to be due to these abnormalities affecting only a limited extent of the small-intestine.

The enteropathy of dermatitis herpetiformis is generally accepted to be gluten-induced and, although this aspect was not specifically studied, patients no. 25 and 35 (Appendix) were diagnosed in medical units as cases of adult and childhood coeliac disease respectively, and treated successfully with a gluten-free diet, before they developed the skin eruption of dermatitis herpetiformis. Other evidence indicative of the similarity between the enteropathy of dermatitis herpetiformis and gluten-induced enteropathy or coeliac disease was also obtained: in Part I splenic atrophy was demonstrated in one patient; a similar serum immunoglobulin pattern to that occurring in coeliac disease was described in Part II; and, in Part III, an increased incidence of serum autoantibodies was noted, a feature which has been recorded in coeliac disease by Seah et al. (1971) and Lancaster-Smith and Strickland (1971).

In view of the experience of having two patients who developed dermatitis herpetiformis while under treatment with a gluten-free diet, this study did not examine the possibility that the skin eruption as well as the small-intestinal abnormality could be due to gluten sensitivity, a possibility which has now been/

been rejected by most authors. Instead, serum immunoglobulin levels were determined and an attempt made to relate the abnormalities found to the presence of disease in the small-intestine or the skin.

The immunoglobulin abnormalities noted in dermatitis herpetiformis were similar to those which have been reported in coeliac disease: the mean IgA level was increased and the mean IgM level decreased. No direct relationship was evident, however, between high IgA or low IgM levels and the presence of small-intestinal abnormality. This does not necessarily mean that the dysgammaglobulinaemia of dermatitis herpetiformis is basically different from that of coeliac disease, as a single intestinal biopsy in dermatitis herpetiformis does not exclude patchy mucosal involvement and, also, although gluten sensitivity does appear to influence immunoglobulin levels in coeliac disease, a more basic defect than gluten sensitivity is likely to exist in the latter disease in view of the variable effect of gluten withdrawal on these levels. Further comparison, therefore, of the lymphoreticular dysfunction of dermatitis herpetiformis and coeliac disease must await a clearer understanding of the nature of the disturbance in both diseases.

The reports describing immunoglobulins, mainly IgA, and complement in the dermal papillae of patients with dermatitis herpetiformis (Van der Meer, 1969; Cormane et al., 1970; Chorzelski et al., 1971; Cormane and Giannetti, 1971; /

1971; Holubar et al., 1971) have suggested that the skin eruption may be due to an immunological reaction. The finding of an increased incidence of thyroid and gastric autoantibodies (Part III) would lend some support to this suggestion, since patients with autoimmune disease appear more likely to suffer from other types of immunological reaction (Blizzard et al., 1959). However, immunoglobulin levels could not be related to the duration or activity of the skin eruption and serum complement levels did not alter significantly during different phases of skin disease activity (Part II). These latter findings do not, of course, exclude the occurrence of an immune reaction in the skin in dermatitis herpetiformis but do further emphasize the possibility that if such a reaction does occur it is of a minor nature.

The specificity of the immunoglobulin changes in dermatitis herpetiformis was investigated by determining immunoglobulin levels in a variety of other skin diseases. The frequency with which IgA levels were raised indicated that high IgA levels in skin diseases must be interpreted with caution, but as lowering of IgM levels to the extent seen in dermatitis herpetiformis only occurred in psoriasis, the pattern of immunoglobulin change in dermatitis herpetiformis is likely to represent a specific dysgammaglobulinaemia.

The significance of these immunoglobulin changes was further emphasized in Part III when an increased incidence of thyroid and gastric autoantibodies was/

was found in dermatitis herpetiformis; these autoantibodies being related not to the presence of small-intestinal disease but to low serum IgM levels.

Thus, if a significant association does exist between dermatitis herpetiformis and organ specific autoimmune disease, and it was to test this hypothesis that Part III of the study was undertaken, then the defect of immune tolerance would appear to be related, not to the skin eruption or the small-intestinal abnormality, but to the lymphoreticular dysfunction responsible for the low IgM values. The absence of an increased incidence of antinuclear factor, on the other hand, would weigh against the defect in immune tolerance in dermatitis herpetiformis being of a general nature, although evidence in favour of such a defect has been reported by Seah et al. (1971).

This investigation, therefore, has indicated that in dermatitis herpetiformis there is, in addition to a skin eruption, the frequent presence of small-intestinal abnormalities, and evidence of an immunological upset both in relation to serum immunoglobulin levels and immune tolerance. The relationship between these three aspects of the disease - dermatological, intestinal and immunological - is at present unknown, and the benefit to the patient with dermatitis herpetiformis of the accumulated knowledge is relatively small. Nevertheless, dermatitis herpetiformis is now far removed from being simply an eruption/

eruption on the skin, and it should prove possible in the foreseeable future to correlate the three aspects of the disease to the further benefit of the patient and the speciality.

CONCLUSIONS

1. The changes of partial or subtotal villous atrophy of the small-intestine were present in over 50% of patients with dermatitis herpetiformis.
2. Symptoms and signs suggesting malabsorption were usually mild or absent and laboratory investigations for malabsorption were frequently negative.
3. The incidence of severe clinical malabsorption was 4%.
4. Deficiency of disaccharidase enzyme concentrations, particularly lactase, occurred in association with the small-intestinal mucosal abnormalities, but lactose intolerance was noted in only one patient.
5. Serum immunoglobulin studies showed an increase in the mean IgA level and a decrease in the mean IgM level in dermatitis herpetiformis. These abnormalities could not be related to small-intestinal disease or the duration or activity of the skin disease.
6. No further evidence in support of an immune reaction in the skin being responsible for the rash of dermatitis herpetiformis was obtained: immunoglobulin and complement levels did not alter significantly during different phases of skin disease activity.
7. Estimation of serum immunoglobulin levels in 7 other skin diseases, not associated with small-intestinal abnormality, revealed that whereas serum IgA levels were frequently raised, lowering of serum IgM levels to the extent seen/

seen in dermatitis herpetiformis occurred only in psoriasis. These results indicated that the immunoglobulin abnormalities obtained in dermatitis herpetiformis were unlikely to be a non-specific effect of the skin eruption.

8. An increased incidence of thyroid and gastric autoantibodies in dermatitis herpetiformis supported the proposition that an association exists between this disease and organ-specific autoimmune disease.
9. The presence of autoantibody did not correlate with small-intestinal abnormalities but a significant correlation was present with low serum IgM levels. This suggested that a defect in immune tolerance secondary to dysgammaglobulinaemia was present in dermatitis herpetiformis.
10. The incidence of antinuclear factor in the serum of patients with dermatitis herpetiformis was low, and there was, therefore, no evidence of a general upset in immune tolerance.
11. The evidence from all three parts of the study supported the contention that the enteropathy of dermatitis herpetiformis is identical to that of coeliac disease; but no direct relationship was noted between the small-intestinal and immunological abnormalities, and the disease process in the skin.

ACKNOWLEDGEMENTS

The study was carried out with the collaboration of many doctors and technicians and in acknowledging the part they played I would also express my appreciation for the willingness of their co-operation.

Professor R.B. Goudie and Mrs M. Hughes performed the thyroid and gastric autoantibody tests and the majority of the antinuclear factor tests, at the Regional Immunopathology Laboratory, Baird Street, Glasgow.

Professor J.S. Beck and Mr A. Willox carried out the serum complement estimations, the intrinsic factor antibody tests and some of the antinuclear factor tests, at the Immunopathology Department, University of Aberdeen.

Dr Heather M. Dick and Mr W.B. Crichton of the Department of Bacteriology, Glasgow Royal Infirmary, and Dr F. Albert-Recht, Department of Chemical Pathology, University of Aberdeen, assayed the serum immunoglobulin levels.

Classification of the small-intestinal mucosa specimens was carried out under the supervision of Dr D. Murray, Glasgow Royal Infirmary, who also proposed the system of mucosal grading employed.

Disaccharidase enzyme estimations on specimens of small-intestinal mucosa were performed by Dr Anne Ferguson and Mr I. McCabe of the Department of Medicine, /

Medicine, Glasgow Royal Infirmary.

The radio-active (^{51}Cr) test of splenic function was carried out by Dr G.A. McDonald, Department of Haematology, Glasgow Royal Infirmary.

Malabsorption studies on patients no. 25 and 35 (described in the Appendix) were undertaken by Dr Anne Ferguson, Department of Medicine, Glasgow Royal Infirmary, and Dr A.S. McNeish, Royal Hospital for Sick Children, Glasgow, respectively.

The various routine haematological, biochemical and radiological examinations performed in this study were undertaken in the relevant departments at the Royal and Western Infirmaries, Glasgow, and at Aberdeen Royal Infirmary.

Photography of patients and specimens recorded in this investigation was made possible by the co-operation of a number of people: Fig. 1 and 2 - Dr A. Lyell, Department of Dermatology, Glasgow Royal Infirmary; Fig. 3 - Mr I. McKie, Photography Unit, Anderson College, University of Glasgow; Fig. 4, 14 and 16 - Dr T. McFadyen, Department of Dermatology, Glasgow Royal Infirmary; Fig. 10 and 12 - Dr Rona M. MacKie, Department of Dermatology, Western Infirmary, Glasgow; Fig. 11, 13, 15 and 17 - Dr D. Murray, Department of Pathology, Glasgow Royal Infirmary. The remaining photographs and presentation of figures were carried out by the Department of/

of Medical Illustration, University of Aberdeen.

The statistical analysis involved in the study was carried out under the guidance of Professor D.F. Kerridge, Department of Statistics, University of Aberdeen, and Dr J.A. Boyle, Department of Medicine, Glasgow Royal Infirmary.

I am greatly indebted to my dermatological colleagues in the Glasgow and Aberdeen area who allowed me to study patients under their care, and particularly to Dr J.O'D. Alexander, Glasgow Royal Infirmary, for his help and encouragement during the initial period of the study.

Finally, I would like to record my thanks to the patients involved in the different parts of the study for their willingness to co-operate and for their cheerfulness and interest throughout.

REFERENCES

- ADAMS, J.F., GLEN, A.I.M., KENNEDY, E.H., MACKENZIE, I.L., MORROW, J.M., ANDERSON, J.R., GRAY, K.G. & MIDDLETON, D.G. (1964) The Histological and Secretory Changes in the Stomach in Patients with Autoimmunity to Gastric Parietal Cells. *Lancet*, i, 401.
- ADINOLFI, M., GLYNN, A.A., LINDSAY, MARGARET & MILNE, CELIA M. (1966) Serological Properties of γ A Antibodies to Escherichia coli Present in Human Colostrum. *Immunology*, 10, 517.
- ALCON, D.N. (1947) Sensitivity to Iodides and Bromides in Dermatoses other than Dermatitis Herpetiformis. *J. invest. Derm.*, 8, 287.
- ALEXANDER, J.O'D. (1955) Dapsone in the Treatment of Dermatitis Herpetiformis. *Lancet*, i, 1201.
- ALEXANDER, J.O'D., YOUNG, E., McFADYEN, T., FRASER, N.G., DUGUID, W.P. & MEREDITH, E.M. (1970) Absorption and Excretion of ^{35}S Dapsone in Dermatitis Herpetiformis. *Br. J. Derm.*, 83, 620.
- ALLEN, A.C. (1954) The Skin. St. Louis: Mosby. p. 256.
- AMMANN, A.J. & HONG, R. (1970) Selective IgA Deficiency and Autoimmunity. *Clin. exp. Immunol.*, 7, 833.
- AMMANN, A.J. & HONG, R. (1971) Unique Antibody to Basement Membrane in Patients with Selective IgA Deficiency and Coeliac Disease. *Lancet*, i, 1264.
- ANDERSON/

- ANDERSON, J.R., GRAY, KATHLEEN, G., MIDDLETON, D.G. & YOUNG, J.A. (1964) Autoimmunity and Thyrotoxicosis. *Br. med. J.*, ii, 1630.
- ANDERSSON, H., DOTEVALL, G. & MOBACKEN, H. (1971a) Gastric Secretion of Acid and Intrinsic Factor in Dermatitis Herpetiformis. *Scand. J. Gastroent.*, 6, 411.
- ANDERSSON, H., DOTEVALL, G. & MOBACKEN, H. (1971b) Malignant Mesenteric Lymphoma in a Patient with Dermatitis Herpetiformis, Hypochlorhydria, and Small-Bowel Abnormalities. *Scand. J. Gastroent.*, 6, 397.
- ANDREWS, G.C. (1946) Diseases of the Skin. Philadelphia: W.B. Saunders Co. p. 566.
- ARDEMAN, S. & CHANARIN, I. (1963) A Method for the Assay of Human Gastric Intrinsic Factor and for the Detection and Titration of Antibodies against Intrinsic Factor. *Lancet*, ii, 1350.
- ASQUITH, P., THOMPSON, R.A. & COOKE, W.T. (1969) Serum - Immunoglobulins in Adult Coeliac Disease. *Lancet*, ii, 129.
- BACHMANN, R. (1965) Studies on the Serum Gamma-A-Globulin Level. 3. The Frequency of A-Gamma-A-Globulinaemia. *Scand. J. clin. Lab. Invest.*, 17, 316.
- BADENOCH, J. (1960) Steatorrhoea in the Adult. *Br. med. J.*, ii, 879.
- BAKER/

- BAKER, S.J., IGNATIUS, M., MATHAN, V.I., VAISH, S.K. & CHACKO, C.C. (1962) Intestinal Biopsy in Tropical Sprue. in Intestinal Biopsy (Ciba Foundation Study Group No. 14). London: Churchill. p. 84.
- BANWELL, J.G., HUTT, M.S. & TUNNICLIFFE, R. (1964) Observations on Jejunal Biopsy in Ugandan Africans. *E. Afr. med. J.*, 41, 46.
- BEALE, A.J., PARISH, W.E., DOUGLAS, A.P. & HOBBS, J.R. (1971) Impaired IgA Responses in Coeliac Disease. *Lancet*, i, 1198.
- BECK, J.S. (1961) Variations in the Morphological Patterns of "Autoimmune" Nuclear Fluorescence. *Lancet*, i, 1203.
- BECKER, S.W. & OBERMAYER, M.E. (1944) *Modern Dermatology and Syphilology*. Philadelphia: Lipincott. p. 119.
- BENDL, B.J. & WILLIAMS, PENELOPE B. (1968) Histopathological Changes in the Jejunal Mucosa in Dermatitis Herpetiformis. *Canad. med. Ass. J.*, 98, 575.
- BENNETT, T.I., HUNTER, D. & VAUGHAN, J.M. (1932) Idiopathic Steatorrhoea (Gee's disease); Nutritional Disturbance Associated with Tetany, Osteomalacia, and Anaemia. *Q. Jl Med.*, 1, 603.
- BERG, N.O., DAHLQVIST, A., LINDBERG, T., MANSSON, A., NORDEN, A. & RORSMAN, H. (1970) Gastrointestinal Dysfunction in Dermatitis Herpetiformis. *Acta derm.-vener.*, Stockh., 50, 42.
- BEUTNER/

- BEUTNER, E.H., LEVER, W.F., WITEBSKY, E., JORDAN, R. & CHERTOCK, B. (1965) Autoantibodies in Pemphigus Vulgaris. *J. Am. med. Ass.*, 192, 682.
- BLECHER, T.E., BRZECHWA-AJDUKIEWICZ, A., McCARTHY, C.F. & READ, A.E. (1969) Serum Immunoglobulins and Lymphocyte Transformation Studies in Coeliac Disease. *Gut*, 10, 57.
- BLIZZARD, R.M., HAMWI, G.J., SKILLMAN, T.G. & WHEELER, W.E. (1959) Thyroglobulin Antibodies in Multiple Thyroid Diseases. *New Engl. J. Med.*, 260, 112.
- BOCK, H.D. (1954) Gleichzeitiges Auftreten von Dermatitis Herpetiformis Duhring bei Vater und Sohn. *Hautarzt*, 5, 41.
- BOLGERT, M. & CHASTANET, B. (1963) A Propos d'une Statistique de 43 Cas de Maladie de Duhring-Brocq. *Annls Derm. Syph.*, 90, 259.
- BROCQ, L. (1888) De la Dermatite Herpetiforme du Duhring. *Annls Derm. Syph.*, IX, 1.
- BROW, J.R., PARKER, F., WEINSTEIN, W.M. & RUBIN, C.E. (1971) The Small Intestinal Mucosa in Dermatitis Herpetiformis. *Gastroenterology*, 60, 355.
- BROWN, D.L., COOPER, A.G. & HEPNER, G.W. (1969) IgM Metabolism in Coeliac Disease. *Lancet*, i, 858.
- BULKLEY/

- BULKLEY, L.D. (1873) On Herpes Gestationis, a Rare Affection of the Skin, Peculiar to Pregnancy. *Am. J. Obstet. Dis. Wom.*, 6, 580.
- BURHOL, P.G. & MYREN, J. (1968) Jejunal Biopsy Findings in Healthy Young Men. *Scand. J. Gastroent.*, 3, 346.
- CALNAN, C.D. (1954) A Note on Sulphone Treatment of Dermatitis Herpetiformis. *Trans. a. Rep. St John's Hosp. dermat. Soc.*, 33, 54.
- CASSIDY, J.T., BURT, ANN, PETTY, R. & SULLIVAN, DONITA (1969) Selective IgA Deficiency in Connective-Tissue Diseases. *New Eng. J. Med.*, 280, 275.
- CHORZELSKI, T.P., BEUTNER, E.H., JABLONSKA, S., BLASZCZYK, M. & TRIFTSHAUSER, C. (1971) Immunofluorescence Studies in the Diagnosis of Dermatitis Herpetiformis and its Differentiation from Bullous Pemphigoid. *J. invest. Derm.*, 56, 373.
- CHORZELSKI, T.P. & CORMANE, R.H. (1968) The Presence of Complement "Bound" in vivo in the Skin of Patients with Pemphigoid. *Dermatologica*, 137, 134.
- CHORZELSKI, T. & JABLONSKA, S. (1967) Immunopathologische Untersuchungen bei der Duhringschen Krankheit und Pemphigoid. *Derm. Wschr.*, 153, 558.
- CHORZELSKI, T., JABLONSKA, S. & BLASZCZYK, M. (1966) Immunopathologische Untersuchungen bei der Subcornealen Pustulösen Dermatose Sneddon/

- Sneddon-Wilkinson. *G. ital. Derm.*, 107, 809.
- CHORZELSKI, T., JABLONSKA, S., BLASZCZYK, M. & JARZABEK, M.
(1968) Autoantibodies in Pemphigoid. *Dermatologica*, 136, 325.
- COOKE, W.T., PEENEY, A.L.P. & HAWKINS, C.F. (1953) Symptoms,
Signs and Diagnostic Features of Idiopathic Steatorrhea. *Q. Jl Med.*,
22, 59.
- COONS, A.H. & KAPLAN, M.H. (1950) Localization of Antigen in Tissue
Cells; Improvements in a Method for the Detection of Antigen by Means
of Fluorescent Antibody. *J. exp. Med.*, 91, 1.
- COPEMAN, P.W.M. (1970) Investigations into the Pathogenesis of Acute
Cutaneous Angiitis. *Br. J. Derm.*, 82, Suppl. 5, 51.
- CORMANE, R.H. (1967) Immunofluorescent Studies of the Skin in Lupus
Erythematosus and Other Diseases. *Path. europ.*, 2, 170.
- CORMANE, R.H. & GIANNETTI, A. (1971) IgD in Various Dermatoses;
Immunofluorescence Studies. *Br. J. Derm.*, 84, 523.
- CORMANE, R.H., SZABO, E. & HAUGE, L.S. (1970) Immunofluorescence
of the Skin: the Interpretation of the Staining of Blood Vessels and
Connective Tissue Aided by New Techniques. *Br. J. Derm.*, 82, Suppl.
5, 26.
- CORNBLEET, T. (1951) Sulfoxone (Diasone) Sodium for Dermatitis Herpetiformis.
Archs Derm. Syph., 64, 684.

COWAN/

- COWAN, JEAN D., HOFFBRAND, A.V. & MOLLIN, D.L. (1966) Effect of Serum-Factors other than Folate on the Lactobacillus casei Assay. *Lancet*, i, 11.
- CRABBE, P.A. & HEREMANS, J.F. (1966) Lack of Gamma A-Immunoglobulin in Serum of Patients with Steatorrhoea. *Gut*, 7, 119.
- CRABBE, P.A. & HEREMANS, J.F. (1967) Selective IgA Deficiency with Steatorrhoea. A New Syndrome. *Am. J. Med.*, 42, 319.
- CREAM, J.J. & SCOTT, G.L. (1970) Anaemia in Dermatitis Herpetiformis. *Br. J. Derm.*, 82, 333.
- CROSBY, W.H. & KUGLER, H.W. (1957) Intraluminal Biopsy of the Small Intestine; the Intestinal Biopsy Capsule. *Am. J. dig. Dis.*, 2, 236.
- DAHLQVIST, A. (1964) in Disorders Due to Intestinal Defective Carbohydrate Digestion. Ed. P. Durand. Rome: Grune. p. 44.
- DEEKEN, M.D. & BAMSHAD, J. (1970) Dermatitis Herpetiformis in Siblings. *Cutis*, 6, 73.
- DICK, HEATHER M., FRASER, N.G. & MURRAY, D. (1969) Immunofluorescent Antibody Studies in Dermatitis Herpetiformis. *Br. J. Derm.*, 81, 692.
- DOUGLAS, A.P., CRABBE, P.A. & HOBBS, J.R. (1970) Immunochemical Studies of the Serum, Intestinal Secretions and Intestinal Mucosa in Patients with Adult Celiac Disease and Other Forms of the Celiac Syndrome. *Gastroenterology*/

Gastroenterology, 59, 414.

DU CASTEL, M.J. (1912) Sur un Cas de Dermatite Polymorphe Dououreuse

et de Basedowisme Associés. Bull. Soc. fr. Derm. Syph., 23, 173.

DUHRING, L.A. (1884) Dermatitis Herpetiformis. J. Am. med. Ass., 3, 225.

DYER, N.H. & VERBOV, J.L. (1968) Malabsorption and the Skin. Br. med.

J., 4, 455.

EIDELMAN, S. & DAVIS, S.D. (1968) Immunoglobulin Content of Intestinal

Mucosal Plasma-Cells in Ataxia Telangiectasia. Lancet, i, 884.

EIDELMAN, S., DAVIS, S.D., LAGUNOFF, D. & RUBIN, C.E. (1966) The

Relationship between Intestinal Plasma Cells and Serum Immunoglobulin A

(IgA) in Man. J. clin. Invest., 45, 1003.

ELLIOT, J.A. & MATHIESON, D.R. (1953) Complement in Disseminated

(Systemic) Lupus Erythematosus. Archs Derm., 68, 119.

ESTEVEZ, J. & BRANDAO, F.N. (1950) Acerca de Accao das Sulfamidas e das

Sulfonas na Doenca de Duhring. Trabhs Soc. port. Derm. Vener., 8, 209.

EYSTER, W.H. & KIERLAND, R.R. (1951) Prognosis of Dermatitis Herpetiformis,

Treated and Untreated. Archs Derm. Syph., 64, 1.

FAHEY, J.L. & McKELVEY, E.M. (1965) Quantitative Detemination of Serum

Immunoglobulins in Antibody - Agar Plates. J. Immun., 94, 84.

FELSHER, Z. (1947a) Studies on the Adherence of the Epidermis to the Corium.

J. invest. Derm., 8, 35.

FELSHER/

FELSHER, Z. (1947b) The Nature of Halogen Sensitivity in Dermatitis

Herpetiformis and Pemphigus. *J. invest. Derm.*, 8, 55.

FOROOZAN, P. & TRIER, J.S. (1967) Mucosa of the Small Intestine in

Pernicious Anaemia. *New Engl. J. Med.*, 277, 553.

FOX, T. (1880) A Clinical Study of Hydroa. *Archs Derm. Syph.*, 6, 16.

FRASER, N.G., DICK, HEATHER M. & CRICHTON, W.B. (1969) Immuno-

globulins in Dermatitis Herpetiformis and Various Other Skin Diseases.

Br. J. Derm., 81, 89.

FRASER, N.G., FERGUSON, ANNE & MURRAY, D. (1968) Dermatitis

Herpetiformis in Two Patients with Idiopathic Steatorrhoea (Adult Coeliac

Disease). *Br. med. J.*, 4, 30.

FRASER, N.G., MURRAY, D. & ALEXANDER, J.O'D. (1967) Structure and

Function of the Small Intestine in Dermatitis Herpetiformis. *Br. J. Derm.*,

79, 509.

FRIEDMAN, M. & HARE, P.J. (1965) Gluten-Sensitive Enteropathy and Eczema.

Lancet, i, 521.

FRY, L., KEIR, P., McMINN, R.M.H., COWAN, JEAN D. & HOFFBRAND,

A.V. (1967) Small-Intestinal Structure and Function and Haematological

Changes in Dermatitis Herpetiformis. *Lancet*, ii, 729.

FRY, L., McMINN, R.M.H., COWAN, JEAN D. & HOFFBRAND, A.V.

(1968)/

(1968) Effect of Gluten-Free Diet on Dermatological, Intestinal, and Haematological Manifestations of Dermatitis Herpetiformis. *Lancet*, 1, 557.

FRY, L., McMINN, R.M.H., COWAN, JEAN D. & HOFFBRAND, A.V.

(1969) Gluten-Free Diet and Reintroduction of Gluten in Dermatitis Herpetiformis. *Archs Derm.*, 100, 129.

FRY, L., McMINN, R.M.H. & SHUSTER, S. (1966) The Small Intestine in Skin Diseases. *Archs Derm.*, 93, 647.

FULTHORPE, A.J., ROITT, I.M., DONIACH, D. & COUCHMAN, K.

(1961) A Stable Sheep Cell Preparation for Detecting Thyroglobulin Auto-Antibodies and its Clinical Applications. *J. clin. Path.*, 14, 654.

GANPULE, M. (1967) Juvenile Dermatitis Herpetiformis. *Br. J. Derm.*, 79, 221.

GELL, P.G.H. & COOMBS, R.R.A. (1968) Clinical Aspects of Immunology. Oxford and Edinburgh: Blackwell Scientific Publications. p. 948.

GIRDWOOD, R.H., WILLIAMS, A.W., McMANUS, J.P.A., DELLIPANI, A.W., DELAMORE, I.W. & KERSHAW, P.W. (1966) Jejunal Biopsy in Patients with Malabsorptive Disease. *Scott. med. J.*, 11, 343.

GJONE, E. & NORDOY, A. (1970) Dermatitis Herpetiformis, Steatorrhoea, and Malignancy. *Br. med. J.*, 1, 610.

GOLDSMITH/

- GOLDSMITH, W.N. (1936) Recent Advances in Dermatology. Philadelphia: Blackiston Co. p. 490.
- GOUDIE, R.B., ANDERSON, J.R. & GRAY, K.G. (1959) Complement-Fixing Antithyroid Antibodies in Hospital Patients with Asymptomatic Thyroid Lesions. *J. Path. Bact.*, 77, 389.
- GOUGH, K.R., READ, A.E. & NAISH, J.M. (1962) Intestinal Reticulosis as a Complication of Idiopathic Steatorrhoea. *Gut*, 3, 232.
- GRANT, P.W. (1968) Juvenile Dermatitis Herpetiformis. *Trans. a. Rep. St John's Hosp. dermat. Soc.*, 54, 128.
- GROB, P.J. & INDERBITZEN, T.M. (1967) Serum Immunoglobulins in Pemphigus. *J. invest. Derm.*, 49, 282.
- HAMMERLI, U.P., KISTLER, H., AMMANN, R., MARTHALER, T., SEMENZA, G., AURICCHIO, S. & PRADER, A. (1965) Acquired Milk Intolerance in the Adult Caused by Lactose Malabsorption Due to a Selective Deficiency of Intestinal Lactase Activity. *Am. J. Med.*, 38, 7.
- HANSEN, P. (1937) Über die Prognose bei Dermatitis Herpetiformis. *Acta dermat.-vener., Stockh.*, 18, 452.
- HEBRA, F. (1872) Über Einzelne Während vor Schwangerschaft in Wochenbette und bei Uterinalkrankheiten der Frauen zu bei Aubachtinde Hautkrankheiten. *Wien. med. Wschr.*, 22, 1197.
- HOBBS/

- HOBBS, J.R. (1968) Immune Imbalance in Dysgammaglobulinaemia Type IV. *Lancet*, i, 110.
- HOBBS, J.R. & HEPNER, G.W. (1966) Deficiency of δ -Macroglobulin in Coeliac Disease. *Gut*, 7, 711.
- HOBBS, J.R. & HEPNER, G.W. (1968) Deficiency of δ M-Globulin in Coeliac Disease. *Lancet*, i, 217.
- HOBBS, J.R., HEPNER, G.W., DOUGLAS, A.P., CRABBE, P.A. & JOHANSSON, S.G.O. (1969) Immunological Mystery of Coeliac Disease. *Lancet*, ii, 649.
- HOFFBRAND, A.V., DOUGLAS, A.P., FRY, L. & STEWART, J.S. (1970) Malabsorption of Dietary Folate (Pteroylpolyglutamates) in Adult Coeliac Disease and Dermatitis Herpetiformis. *Br. med. J.*, 4, 85.
- HOLMES, R., HOURIHANE, D.O'B. & BOOTH, C.C. (1961a) Dissecting-Microscope Appearances of Jejunal Biopsy Specimens from Patients with "Idiopathic Steatorrhoea". *Lancet*, i, 81.
- HOLMES, R., HOURIHANE, D.O'B. & BOOTH, C.C. (1961b) The Mucosa of the Small Intestine. *Post-grad. med. J.*, 37, 717.
- HOLUBAR, K., DORALT, MAJA & EGGERTH, G. (1971) Immunofluorescence Patterns in Dermatitis Herpetiformis. *Br. J. Derm.*, 85, 505.
- HVIDT, S. & KJELDEN, K. (1963) Malabsorption Induced by Small Doses of Neomycin/

- Neomycin Sulfate. *Acta med. scand.*, 173, 699.
- ILYAS, M. (1968) Malabsorption with Dermatitis Herpetiformis. *Lancet*, i, 248.
- JABLONSKA, S. & CHORZELSKI, T. (1963) Kann das Histologische Bild die Grundlage zur Differenzierung des Morbus Duhring mit dem Pemphigoid und Erythema Multiforme Darstellen? *Derm. Wschr.*, 146, 590.
- JACOBSON, E.D., CHODOS, R.B. & FALLOON, W.W. (1960) An Experimental Malabsorption Syndrome Induced by Neomycin. *Am. J. Med.*, 28, 524.
- JORDAN, R.E., BEUTNER, E.H., WITEBSKY, E., BLUMENTAL, G., HALE, W.L. & LEVER, W.F. (1967) Basement Zone Antibodies in Bullous Pemphigoid. *J. Am. med. Ass.*, 200, 751.
- KALSBECK, G.L. & CORMANE, R.H. (1964) "Bound" Complement in the Skin of Patients with Chronic Discoid Lupus Erythematosus and Systemic Lupus Erythematosus. *Lancet*, ii, 178.
- KATZ, S.I., INDERBITZEN, T.M. & HALPRIN, K.M. (1970) Serum Complement (C'3) Levels in Patients with Autoimmune Bullous Skin Diseases. *Archs Derm.*, 102, 368.
- KAUFMAN, W.H. & SMITH, D.C. (1943) Cutaneous Changes in Sprue Syndrome. *J. Am. med. Ass.*, 121, 168.
- KENDALL, M.J. (1970) The Influence of Age on the Xylose Absorption Test. *Gut*, 11, 498.

KIM/

- KIM, R. & WINKELMANN, R.K. (1961) Dermatitis Herpetiformis in Children. *Archs Derm.*, 83, 895.
- KINMONT, P.D.C. (1955) Familial Dermatitis Herpetiformis. *Br. J. Derm.*, 67, 410.
- KOFFLER, D., SCHUR, P.H. & KUNKEL, H.G. (1967) Immunological Studies Concerning the Nephritis of Systemic Lupus Erythematosus. *J. exp. Med.*, 126, 607.
- KREBS, A., HESS, M. & BUETLER, R. (1963) Vergleichende Immunoelktrophoretische Untersuchungen bei Psoriasis Arthropathica, Psoriasis Vulgaris und Primar-Chronischer Polyarthrit. *Schweiz. med. Wschr.*, 93, 492.
- KRUIZINGA, E.E. & HAMMINGA, H. (1953) Treatment of Dermatitis Herpetiformis with Diamino-Diphenyl-Sulphone (D.D.S.) *Dermatologica*, 106, 387.
- LACHMANN, P.J., MULLER-EBERHARD, H.J., KUNKEL, H.G. & PARONETTO, F. (1962) The Localization of in vivo Bound Complement in Tissue Sections. *J. exp. Med.*, 115, 63.
- LANCASTER-SMITH, M.J. & STRICKLAND, I.D. (1971) Autoantibodies in Adult Coeliac Disease. *Lancet*, i, 1244.
- LAPTEV, V.A. & SMELOV, N.S. (1958) Diaminodiphenylsulfone Therapy of Patients with Duhring's Disease. *Vest. Derm. Vener.*, 32, 7.
- LEVER/

LEVER, W.F. (1953) Pemphigus. *Medicine*, 32, 1.

LEVER, W.F. (1965) Pemphigus and Pemphigoid. Springfield: Charles C. Thomas.
pp. 88, 94.

LEVER, W.F. (1967) Histopathology of the Skin. 4th ed. London: Pitman
Medical Publishing Co. p. 129.

LIFTSHITZ, F., KLOTZ, A.P. & HOLMAN, G.H. (1965) Intestinal Disaccharidase
Deficiencies in Gluten-Sensitive Enteropathy. *Am. J. dig. Dis.*, 10, 47.

LIM, S.D. & FUSARO, R.M. (1962) Pemphigus Vulgaris. I Analysis of β_2A and
 β_2M Serum Proteins by Immunoelectrophoresis. *J. Invest. Derm.*, 39, 303.

LITTLE, E.G. (1914) Dermatitis Herpetiformis. *Br. J. Derm.*, 26, 165.

McCARTHY, C.F., FRASER, I.D., EVANS, K.T. & READ, A.E. (1966)
Lymphoreticular Dysfunction in Idiopathic Steatorrhoea. *Gut*, 7, 140.

McCRAE, W.M. (1969) Inheritance of Coeliac Disease. *J. med. Genet.*,
6, 129.

MacDONALD, W.C., BRANDBORG, L.L., FLICK, A.L., TRIER, J.S. &
RUBIN, C.E. (1964) Studies of Celiac Sprue. IV. The Response of the
Whole Length of the Small Bowel to a Gluten-Free Diet. *Gastroenterology*,
47, 573.

MacDONALD, W.C., DOBBINS, W.O. & RUBIN, C.E. (1965) Studies of the
Familial/

Familial Nature of Celiac Sprue Using Biopsy of the Small Intestine.

New Engl. J. Med., 272, 448.

McDUFFIE, F.C.. (1970) Serum Complement Levels in Cutaneous Diseases.

Br. J. Derm., 82, Suppl., 5, 20.

McMICHAEL, H.B., WEBB, JOAN & DAWSON, A.M. (1965) Lactase

Deficiency in Adults. A Cause of "Functional" Diarrhoea. Lancet, i, 717.

McNEISH, A.S., FRASER, N.G. & MORLEY, W.N. (1970) Dermatitis

Herpetiformis in a Treated Coeliac Child. Archs Dis. Childh., 45, 279.

McPHERSON, J.R. & SUMMERSKILL, W.H.J. (1963) An Acute Malabsorption

Syndrome with Reversible Mucosal Atrophy. Gastroenterology, 44, 900.

MacVICAR, D.N., GRAHAM, J.H. & BURGOON, C.F. (1963) Dermatitis

Herpetiformis, Erythema Multiforme and Bullous Pemphigoid: a Comparative

Histopathological and Histochemical Study. J. invest. Derm., 41, 289.

MANCINI, G., VAERMAN, J.-P., CARBONARA, A.O. & HEREMANS,

J.F. (1964) A Single-Radial-Diffusion Method for the Immunological

Quantitation of Proteins. Protides biol. Fluids, 11, 370.

MANSON-BAHR, P. & WILLOUGHBY, H. (1930) Studies on Sprue with Special

Reference to Treatment. Q. Jl. Med., 23, 411.

MARCH, C. & SAWICKY, H.H. (1962) Diaminodiphenyl Sulfone in Dermatitis

Herpetiformis. Archs Derm., 85, 751.

MARKS/

- MARKS, JANET, BIRKETT, D., SHUSTER, S. & ROBERTS, D.F. (1970)
Small Intestinal Mucosal Abnormalities in Relatives of Patients with
Dermatitis Herpetiformis. *Gut*, 11, 493.
- MARKS, JANET, MAY, S.B. & ROBERTS, D.F. (1971) Dermatitis Herpetiformis
Occurring in Monozygous Twins. *Br. J. Derm.*, 84, 417.
- MARKS, JANET & SHUSTER, S. (1969) Small-Intestinal Mucosa in Pemphigoid
and Subcorneal Pustular Dermatoses. *Archs Derm.*, 100, 136.
- MARKS, JANET & SHUSTER, S. (1970a) Small-Intestinal Mucosal Abnormalities
in Various Skin Diseases - Fact or Fancy? *Gut*, 11, 281.
- MARKS, JANET & SHUSTER, S. (1970b) Dermatitis Herpetiformis. The Role of
Gluten. *Archs Derm.*, 101, 452.
- MARKS, JANET & SHUSTER, S. (1971) Skin Disease and the Gut. *Br. med. J.*,
i, 110.
- MARKS, JANET, SHUSTER, S. & WATSON, A.J. (1966) Small-Bowel Changes
in Dermatitis Herpetiformis. *Lancet*, ii, 1280.
- MARKS, R. (1968) Dermatitis Herpetiformis and the Gastro-Intestinal Tract.
Trans. a. Rep. St John's Hosp. derm. Soc., 54, 141.
- MARKS, R., BEARD, R.J., CLARK, M.L., KWOK, M. & ROBERTSON, W.B.
(1967) Gastrointestinal Observations in Rosacea. *Lancet*, i, 739.
- MARKS, R. & WHITTLE, M.W. (1969) Results of Treatment of Dermatitis
Herpetiformis/

- Herpetiformis with a Gluten-Free Diet after One Year. Br. med. J., 4, 772.
- MARKS, R., WHITTLE, M.W., BEARD, R.J., ROBERTSON, W.B. & GOLD, S.C. (1968) Small-Bowel Abnormalities in Dermatitis Herpetiformis. Br. med. J., 1, 552.
- MARSH, G.W., LEWIS, S.M. & SZUR, L. (1966) The Use of ^{51}Cr -Labelled Heat-Damaged Red Cells to Study Splenic Function. Br. J. Haemat., 12, 161.
- MAYON-WHITE, R.T. (1969) Dermatitis Herpetiformis Occurring in a Case of Controlled Coeliac Disease. Br. J. Derm., 81, 635.
- MORSE, J.H., MULLER-EBERHARD, H.J. & KUNKEL, H.G. (1962) Antinuclear Factors and Serum Complement in Systemic Lupus Erythematosus. Bull. N.Y. Acad. Med., 38, 641.
- PARKINS, R.A., EIDELMAN, S., PERRIN, E.B. & RUBIN, C.E. (1966) A Preliminary Study of Factors Affecting Blood Lipid Levels in Three Groups of Yemenite Jews. Am. J. clin. Nutr., 18, 134.
- PARONETTO, F. & KOFFLER, D. (1965) Immunofluorescent Localization of Immunoglobulins, Complement, and Fibrinogen in Human Diseases. I Systemic Lupus Erythematosus. J. clin. Invest., 44, 1657.
- PATON, E., MURRAY, E. & WATSON, W.C. (1966) Intestinal Disaccharidase Activity in Rosacea. Br. med. J., i, 459.
- PIÉRARD, J. & WHIMSTER, I. (1961) The Histological Diagnosis of Dermatitis Herpetiformis/

- Herpetiformis, Bullous Pemphigoid and Erythema Multiforme. Br. J. Derm., 73, 253.
- PLOTKIN, G.R. & ISSELBACHER, K.J. (1964) Secondary Disaccharidase Deficiency in Adult Celiac Disease (Non Tropical Sprue) and other Malabsorption States. New Engl. J. Med., 271, 1033.
- POCK-STEEN, O.Ch. & NIORDSON, A.-M. (1970) Milk Sensitivity in Dermatitis Herpetiformis. Br. J. Derm., 83, 614.
- RATTNER, H., RODIN, H. & BARSKY, S. (1950) Residual Lesions of Dermatitis Herpetiformis and Thyrotoxicosis in a Woman Aged 24. Archs Derm., 61, 704.
- ROE, J.H. & RICE, E.W. (1948) Photometric Method for Determination of Free Pentoses in Animal Tissues. J. biol. Chem., 173, 507.
- ROOK, A., WILKINSON, D.S. & EBLING, F.J.G. (1968) Textbook of Dermatology. Oxford and Edinburgh: Blackwell Scientific Publications. p. 1186.
- ROTHMAN, S. (1954) Physiology and Biochemistry of the Skin. Chicago: University of Chicago Press. p. 36.
- ROY-CHOUDHURY, D.C., COOKE, W.T., BANWELL, J.G. & SMITS, B.J. (1967) Multiple Jejunal Biopsies in Adult Celiac Disease. Am. J. dig. Dis., 12, 657.
- RUBIN, C.E., BRANDBORG, L.L., FLICK, A.L., PHELPS, P., PARMENTIER, C./

- C. & VAN NIEL, S. (1962) Studies of Celiac Sprue. III The Effect of Repeated Wheat Instillation into the Proximal Ileum of Patients on a Gluten-Free Diet. *Gastroenterology*, 43, 621.
- RUBIN, C.E. & DOBBINS, W.O. (1965) Peroral Biopsy of the Small Intestine. *Gastroenterology*, 49, 676.
- SALEM, S.N. & TRUELOVE, S.C. (1965) Small-Intestinal and Gastric Abnormalities in Ulcerative Colitis. *Br. med. J.*, i, 827.
- SCHUR, P.H. & SANDSON, J. (1968) Immunologic Factors and Clinical Activity in Systemic Lupus Erythematosus. *New Engl. J. Med.*, 278, 583.
- SCOTT, G.B., WILLIAMS, M.J. & CLARK, C.G. (1964) Comparison of Jejunal Mucosa in Post-Gastrectomy States, Idiopathic Steatorrhea, and Controls Using the Dissecting Microscope and Conventional Histological Methods. *Gut*, 5, 553.
- SCUDAMORE, H.H. (1961) Observations on Secondary Malabsorption Syndrome of Intestinal Origin. *Ann. intern. Med.*, 55, 433.
- SEAH, P.P., FRY, L., HOFFBRAND, A.V. & HOLBOROW, E.J. (1971) Tissue Antibodies in Dermatitis Herpetiformis and Coeliac Disease. *Lancet*, i, 834.
- SERAFINI, U., TORRIGIANI, G. & MASALA, C. (1965) Organ-Specific Autoantibodies in Reagin-Containing Sera from Allergic Patients. *Lancet*, ii, 821.
- SHUSTER/

SHUSTER, S. (1967) Systemic Effects of Skin Disease. *Lancet*, i, 907.

SHUSTER, S. & MARKS, JANET (1965) Dermatogenic Enteropathy. *Lancet*, i, 1367.

SHUSTER, S., WATSON, A.J. & MARKS, JANET (1967) Small Intestine In Psoriasis. *Br. med. J.*, 3, 458.

SHUSTER, S., WATSON, A.J. & MARKS, JANET (1968) Coeliac Syndrome in Dermatitis Herpetiformis. *Lancet*, i, 1101.

SMITH, E.L. (1966) The Diagnosis of Dermatitis Herpetiformis. *Trans. a. Rep. St John's Hosp. derm. Soc.*, 52, 176.

SMITH, J.F. (1928) Dermatitis Herpetiformis in Brother and Sister. *Br. J. Derm.*, 40, 19.

SNEDDON, I.B. & CHURCH, R. (1955) Diagnosis and Treatment of Pemphigoid. *Br. med. J.*, ii, 1360.

SNEDDON, I.B. & WILKINSON, D.S. (1956) Subcorneal Pustular Dermatoses. *Br. J. Derm.*, 68, 385.

SOCIETY OF ACTUARIES (1959) Build and Blood Pressure Study. Chicago. p. 16.

STEWART, J.S., POLLOCK, D.J., HOFFBRAND, A.V., MOLLIN, D.L. & BOOTH, C.C. (1967) A Study of Proximal and Distal Intestinal Structure and Absorptive Function In Idiopathic Steatorrhoea. *Q. Jl. Med.*, 36, 425.

STRINGA, S.G., BIANCHI, C. & ZINGALE, S.B. (1966) Nodular Vasculitis: Immunofluorescent Study. 7S Gamma-Globulin and Complement (β_{1C} - Globulin)/

- Globulin) in Lesions of Nodular Vasculitis. *J. invest. Derm.*, 46, 1.
- SØLTOFT, J. & WEEKE, B. (1969) Immunoglobulins in Serum and Jejunal Biopsies in Non-Tropical Sprue. *Acta med. scand.*, 186, 459.
- TAYLOR, K.G., ROITT, I.M., DONIACH, D., COUCHMAN, K.G. & SHAPLAND, C. (1962) Autoimmune Phenomena in Pernicious Anaemia: Gastric Antibodies. *Br. med. J.*, ii, 1347.
- TEN HAVE-OPBROEK, A.A.W. (1966) Demonstration of Immunoglobulin and Complement in the Skin of Patients with Lupus Erythematosus. *Acta dermat. vener.*, Stockh., 46, 68.
- TOLMAN, M.M., MOSCHELLA, S.L. & SCHNEIDERMAN, R.N. (1959) Dermatitis Herpetiformis - Specific Entity of Clinical Complex? *J. invest. Derm.*, 32, 557.
- TOWNES, A.S., STEWART, C.R., JR & OSLER, A.G. (1963) Immunologic Studies of Systemic Lupus Erythematosus. II. Variations of Nucleoprotein-Reactive Gamma Globulin and Haemolytic Serum Complement Levels with Disease Activity. *Bull. Johns Hopkins Hosp.*, 112, 202.
- TOWNLEY, R.R.W., CASS, M.H. & ANDERSON, CHARLOTTE M. (1964) Small Intestinal Mucosal Patterns of Coeliac Disease and Idiopathic Steatorrhoea Seen in other Situations. *Gut*, 5, 51.
- UPSHAW, C.B., JR & POLLARD, H.M. (1957) The Sprue Syndrome Associated with/

- with Intra-Abdominal Lymphoblastoma. *Gastroenterology*, 33, 104.
- URBACH, E. & LE WINN, E.B. (1946) *Skin Diseases, Nutrition and Metabolism*. New York. Grune and Stratton. p. 24.
- VAERMAN, J.-P. & HEREMANS, J.F. (1970) Origin and Molecular Size of Immunoglobulin - A in the Mesenteric Lymph of the Dog. *Immunology*, 18, 27.
- VAN DE KAMER, J.H., TEN BOKKEL HUININK, H. & WEYERS, H.A. (1949) Rapid Method for the Determination of Fat in Faeces. *J. biol. Chem.*, 177, 347.
- VAN DER MEER, J.B. (1969) Granular Deposits of Immunoglobulins in the Skin of Patients with Dermatitis Herpetiformis. An Immunofluorescent Study. *Br. J. Derm.*, 81, 493.
- VAN DE STAAK, W.J.B.M., VAN TONGEREN, J.H.M., SCHILLINGS, P.H.M. & DOOMERNIK, L. (1970) Dermatitis Herpetiformis and Pathological Changes of the Mucous Membrane of the Small Intestine. *Dermatologica*, 140, 231.
- VAN KETEL, W.G. (1960) Langdurende Behandeling van Dermatitis Herpetiformis (Ziekte Van Duhring) met Diamino - Difenylsulfon (DDS). *Ned. Tijdschr. Geneesk.*, 104, 1986.
- VAN TONGEREN, J.H.M., VAN DER STAAK, W.J.B.M. & SCHILLINGS, P.H.M. (1967) Small-Bowel Changes in Dermatitis Herpetiformis. *Lancet*, i, 218.
- VARELZIDIS/

- VARELZIDIS, A. & THEODORIDIS, A. (1971) Serum Immunoglobulins and Psoriasis Before and After Ultra Violet Light Therapy. *Br. J. Derm.*, 85, 14.
- VARELZIDIS, A., WILSON, ANNE B., MEARA, R.H. & TURK, J.L. (1966) Immunoglobulin Levels in Atopic Eczema. *Br. med. J.*, ii, 925.
- VERBOV, J.L. & BARKHAN, P. (1967) Dermatitis Herpetiformis. *Lancet*, ii, 1085.
- WALDORF, D.S. & ROGENTINE, G.N. (1966) Serum Immunoglobulins in Pemphigus Vulgaris. *J. invest. Derm.*, 47, 227.
- WATSON, W.C., PATON, ESTHER & MURRAY, D. (1965) Small-Bowel Disease in Rosacea. *Lancet*, ii, 47.
- WEDGEWOOD, R.J.P. & JANEWAY, C.A. (1953) Serum Complement in Children with "Collagen Diseases". *Pediatrics*, 11, 569.
- WEINSTEIN, W.M., BROW, J.R., PARKER, F. & RUBIN, C.E. (1971) The Small Intestinal Mucosa in Dermatitis Herpetiformis. *Gastroenterology*, 60, 362.
- WELLS, G.C. (1962) Skin Disorders in Relation to Malabsorption. *Br. med. J.*, ii, 937.
- WERTHER, J. (1925) Pemphigus Vulgaris Benignus Chronicus bei 53 Jahriger Frau. *Zenbl. Haut-u. GeschlKrankh*, 17, 414.
- WHITTINGHAM, SENG, UNGAR, BERTHA, MACKAY, I.R. & MATHEWS, J.D. (1969) The Genetic Factor in Pernicious Anaemia. A Family Study in Patients with Gastritis. *Lancet*, i, 951.
- WYATT/

WYATT, E., SHUSTER, S. & MARKS, JANET (1971) A Postal Survey of Patients with Dermatitis Herpetiformis. Br. J. Derm., 85, 511.

WYBURN-MASON, R. (1968) Coeliac Syndrome in Dermatitis Herpetiformis. Lancet, i, 1250.

YOUNG, WINIFRED F. & PRINGLE, ELIZABETH M. (1971) 110 Children with Coeliac Disease, 1950-1969. Archs Dis. Childh., 46, 421.

APPENDIX

Patient No. 25

Clinical history and findings - This patient aged 57 years, was admitted to the medical wards in October 1965 with a 16 month history of weight loss and a 7 month history of flatulence and diarrhoea. On examination she had a low grade pyrexia, evidence of weight loss, a red smooth tongue, angular stomatitis and marked palmar erythema. Blood pressure was $\frac{100}{70}$ mm Hg. Abdomen was rather full.

Investigations - Haemoglobin 9 g/100 ml; P.C.V. 29%; M.C.H.C. 31%; E.S.R. (Westergren) 60 mm in 1 h; film-anisocytosis, target cells, macrocytosis, hypersegmented polymorphs. Marrow examination - megaloblastic change, stainable iron present. Serum vitamin B₁₂ <10 uug/ml. Schilling test - 0.5% dose excreted in urine in 24 hours. Figlu test positive. Serum iron 40 ug/100 ml, total iron-binding capacity 204 ug/100 ml, saturation 20%. Serum sodium 140 mEq/l; potassium 3.3 mEq/l; chloride 99 mEq/l; blood urea 23 mg/100 ml. Albumin 3.1 g/100 ml; globulin 2.8 g/100 ml. Bilirubin 0.9 mg/100 ml; thymol turbidity 1.4 Maclagan units; calcium 2.5 mEq/l; inorganic phosphate 2.3 mg/100 ml; alkaline phosphatase 19 King-Armstrong units/100 ml. Tubular reabsorption of phosphate - 97%. X-ray of spine - osteoporosis. Urine xylose excretion after 5 g dose - 0.77 g in 5 hours./

hours. Small-bowel x-ray - flocculation of barium in the small intestine. Jejunal biopsy - ridged and convoluted mucosa under dissecting microscope; low broad irregular villi, long crypts, degenerate epithelial cells and plasma cell infiltrate in the lamina propria under light microscope. Results of disaccharidase assay are in Table XII. The diagnosis of adult coeliac disease was made and she was treated initially with vitamin B₁₂, folic acid, intramuscular iron, Parentrovite, vitamin D and calcium and gluten-free diet.

One year later her weight had increased by 42 lb and treatment was continued with a gluten-free diet, folic acid 10 mg b.d., ferrous sulphate 0.2 g t.i.d, and vitamin B₁₂ 1,000 ug monthly.

In February, 1968, the patient noticed an itching, blistering eruption affecting mainly the scalp, extensor surfaces of the elbows, abdomen and back of the knees. In April, 1968, skin biopsy of an erythematous papule showed the typical papillary microabscesses of dermatitis herpetiformis. The patient's only other complaint at this time was of occasional flatulence and abdominal distension after meals. Clinical examination was negative.

Investigations - Haemoglobin 14.1 g/100 ml; P.C.V. 42%; M.C.H.C. 34%; E.S.R. (Westergren) 15 mm in 1 h; film normal. Albumin 4.3 g/100 ml; globulin 2.5 g/100 ml. Thymol turbidity 2.2 MacLagan units; bilirubin 0.7 mg/100 ml. Calcium 4.7 mEq/l; inorganic phosphate 2.7 mg/100 ml; alkaline/

alkaline phosphatase 12 King-Armstrong units/100 ml. Lactose tolerance test - maximum blood sugar rise after 100 g lactose was 14 mg/100 ml. Abdominal pain and flatulence occurred during the test. Jejunal biopsy again showed partial villous atrophy. The infiltrate of inflammatory cells in the lamina propria was more marked than in the previous biopsy. Disaccharidase results are shown in Table XII. The patient's flatulence was thought to be due to lactose intolerance and she was advised to adopt a gluten-free, lactose-free diet. The skin eruption showed a good response to dapsone therapy.

Treatment with a gluten-free diet in this patient resulted in relief of diarrhoea and a gain in weight of 42 lb. There was, however, no significant change in the structural jejunal mucosal abnormality and although maltase and sucrase activity reverted to normal, lactase activity remained low and was responsible for the lactose intolerance.

Patient No. 35

Clinical history and findings - This patient was admitted to the paediatric medical ward in July 1962 at the age of 2 years with a history of having bouts of loose pale stools since the age of 6 months: mixed feeding had begun at the age of 2 months. At the time of investigation his height was on the 25th centile and his weight on the 20th centile.

Investigations - Haemoglobin 9.6 g/100 ml; film - hypochromic. Serum iron 16 ug/100 ml./

16 ug/100 ml. Fat balance test with a 40 g fat intake - 86% absorption.

Small-bowel x-ray examination - malabsorption pattern. Jejunal biopsy - subtotal villous atrophy. X-ray examination of spine - osteoporosis.

A diagnosis of coeliac disease was made and treatment with a gluten-free diet instituted. This produced resolution of symptoms and growth acceleration until both height and weight reached the 75th centile. For a period of 6 months in 1965 a normal diet was resumed against medical advice, and this resulted in a weight loss of 1 kg. A gluten-free diet was restarted, weight gain resulted, and thereafter the diet was strictly maintained.

In January 1968, over 5 years after starting treatment with a gluten-free diet, he developed an itching eruption on extensor surfaces of elbows and knees, buttocks, shoulders and face. The lesions were erythematous and urticarial in appearance but failed to respond to oral antihistamines. He was then admitted to the ward for investigation.

Investigations - KI test - oral ingestion of 350 mg KI induced a marked exacerbation of the rash, and skin biopsy showed the histological features of dermatitis herpetiformis. Haemoglobin and full blood count normal. Serum proteins and immunoglobulins normal. Xylose excretion - 42% in 5 hours. Faecal fat excretion (ward diet) - 3.8 g/day. Jejunal biopsy - normal.

The/

The coeliac disease was in clinical, biochemical and histological remission on a gluten-free diet when the eruption of dermatitis herpetiformis first appeared. Dapsone therapy was given, and the eruption settled.

TABLE XII - Effect of Gluten-Free Diet on Weight and Intestinal Mucosa in Patient No. 25.

	Before gluten-free diet	After gluten-free diet
Weight	105 lb (47.6 kg)	147 (66.7 kg)
Intestinal mucosa	partial villous atrophy	partial villous atrophy
Maltase*	6.1	18.5
Lactase*	0.2	0.3
Sucrase*	1.7	5.4

* Units of activity (umol substrate hydrolysed per minute)
per gramme of tissue wet weight.