

**CANINE SPLENIC DISEASE: A CLINICO-PATHOLOGICAL AND
ULTRASONOGRAPHICAL STUDY.**

by

CAREEN HANKANGA.

Thesis submitted for the degree of Master of Veterinary Medicine in the
Faculty of Veterinary Medicine, University of Glasgow.

Departments of Veterinary Anatomy and Clinical Studies.
University of Glasgow.

October, 1995.

ProQuest Number: 11007861

All rights reserved

INFORMATION TO ALL USERS

The quality of this reproduction is dependent upon the quality of the copy submitted.

In the unlikely event that the author did not send a complete manuscript and there are missing pages, these will be noted. Also, if material had to be removed, a note will indicate the deletion.



ProQuest 11007861

Published by ProQuest LLC (2018). Copyright of the Dissertation is held by the Author.

All rights reserved.

This work is protected against unauthorized copying under Title 17, United States Code
Microform Edition © ProQuest LLC.

ProQuest LLC.
789 East Eisenhower Parkway
P.O. Box 1346
Ann Arbor, MI 48106 – 1346

Thesis
10273
Copy 1



Abstract

During the last two decades, two-dimensional ultrasonography has been introduced in the evaluation of abdominal disease. It provides a rapid non-invasive means of supplementing information obtained by physical examination and radiography. Ultrasonography accurately depicts changes in size, shape and spatial relationships of abdominal organs; however, limitations include the non-specific nature of many observed abnormalities, which prevents a definite diagnosis. The aim of this study was to assess the accuracy of ultrasonography in detecting disease affecting the canine spleen by comparison with clinicopathological findings.

Scanning was performed on the ventral abdominal wall using a 3.75 MHz curvilinear probe.

Fourteen cases were studied, 13 dogs and one cat. Non-specific clinical signs were seen in the cases studied and variable sonographic appearances. One case of haemangioma was presented, the ultrasonographic lesion was of mixed echogenicity. Two cases of haemangiosarcoma also showed a mixed echogenicity with acoustic enhancement. The sonographic appearance of splenic nodular hyperplasia varied between hyperechoic, heteroechoic, and hypoechoic. Cystic structures seen in this study include a splenic abscess, haematoma and anechoic masses on the liver; all appeared hypoechoic to anechoic with acoustic enhancement and edge shadowing. Splenic lymphosarcoma showed multifocal hypoechoic lesions. Metastatic adenocarcinoma was seen in two cases as multifocal hypoechoic lesions; both cases had hepatic involvement. Splenic infarcts were seen as hypoechoic areas causing distortion of the splenic capsule. Malignant fibrous histiocytoma was seen sonographically as a heteroechoic lesion with some areas casting distal acoustic enhancement. One case had nodular lesions which were not confirmed by the histopathological examination, however, extramedullary haematopoiesis was a main feature in this and another case which sonographically showed multifocal linear hypoechoic areas which were deduced to be dilated splenic vessels.

The conclusion of this study is that ultrasonography is an important modality for studying the canine spleen.

List of Contents

	Page
Title	i
Abstract	ii
List of Contents	iii
List of Figures	v
List of Tables	viii
List of Appendices	ix
Acknowledgement	x
Author's declaration	xi
Dedication	xii
Chapter 1	1
Section A. Ultrasonography	1
1. Principles of ultrasonography	1
1.1. Production of the image	2
1.1.1. The pulse echo principle	2
1.1.2. Interaction of the sound waves with tissue	3
1.1.3. Common imaging artifacts	7
1.1.3.1. Acoustic enhancement	7
1.1.3.2. Acoustic shadowing	7
1.1.3.3. Reverberation artifacts	8
1.1.3.4. Mirror image artifact	9
1.1.3.5. Comet-tail artifact	9
1.1.3.6. Other artifacts	9
1.2. The transducer	10
1.2.1. Types of transducers	11
1.2.1.1. Linear array transducers	11
1.2.1.2. Sector transducers	11
1.2.1.3. Annular arrays	12
1.3. The scanner	13
1.3.1. Display systems	13
1.3.1.1. Bistable systems	13
1.3.1.2. Gray-scale systems	13
1.3.2. Display format	13
1.3.2.1. A - mode	13
1.3.2.2. B - mode	13
1.3.2.3. M - mode	14
1.4. Image recording systems	14
1.4.1. Polaroid camera	14

1.4.2. Video printers	14
1.4.3. Multiformat camera	14
1.5. Biological effects of ultrasound	15
1.6. Principles of ultrasound interpretation	15
Section B. Radiography	21
2. Principles of radiography	21
2.1. Production of X-rays	21
2.2. Image formation and differential diagnosis	21
Chapter 2.	23
Section A.	23
3. The normal spleen	23
3.1. Anatomy	23
3.2. Histology	24
3.3. Functions	24
Section B.	30
4. Splenic disease	30
4.1. Splenic masses	
4.1.1. Non-neoplastic splenic masses	30
4.1.1.1. Splenic haematoma	30
4.1.1.2. Splenic nodular hyperplasia	31
4.1.1.3. Splenic abscess	31
4.1.2. Neoplastic splenic masses	32
4.1.2.1. Splenic haemangiosarcoma	32
4.1.2.2. Splenic haemangioma	34
4.1.2.3. Other tumours of the spleen	34
4.2. Generalised splenomegaly	35
4.2.1. Inflammatory splenomegaly	35
4.2.2. Hyperplastic splenomegaly	36
4.2.3. Congestive splenomegaly	36
4.2.4. Infiltrative splenomegaly	37
Section C.	38
5. Sonography of the spleen	38
5.1. Sonography of the normal spleen	38
5.2. Sonographic appearance of splenic disease	38
5.2.1. Focal splenic lesions	38
5.2.2. Diffuse splenic lesions	41

Section D.	42
6. Radiographic interpretation of splenic disease	42
6.1. Radiography of the normal spleen	42
6.2. Radiographic interpretation of splenomegaly	42
Chapter 3. Materials and Methods	46
Chapter 4. Case summaries	49
Chapter 5. Results	99
Chapter 6. Discussion and Conclusions	107
Appendices	124
List of references	128

List of figures

	Page
Figure 1.1. Acoustic enhancement from gall bladder	17
Figure 1.2. Acoustic shadow due to stomach gas	17
Figure 1.3. Reverberation artifact due to intestinal gas	18
Figure 1.4. Mirror image artifact at the diaphragmatic-lung interface	18
Figure 1.5. Comet-tail artifact at the diaphragmatic-lung interface	19
Figure 1.6. Slice thickness artifact in the bladder	19
Figure 1.7. Bladder acting as an acoustic window	20
Figure 2.1. Visceral surface of normal dog spleen	28
Figure 2.2. Transverse section of a dog showing organ relationships	28
Figure 2.3. Sagittal section of a dog showing organ relationships	29
Figure 2.4. Ultrasound image of normal dog spleen	39
Figure 2.5. Ultrasound image showing splenic, kidney and hepatic echogenicity	39
Figure 2.6. Lateral abdominal radiograph of normal canine abdomen	43
Figure 2.7. Dorsoventral abdominal radiograph of normal canine abdomen	44
Figure 4.1. Sagittal ultrasound image of splenic haemangioma from case no. 1.	50
Figure 4.2A. Enlarged spleen with mass from case no. 1.	51
Figure 4.2B. Sagittal section of the haemangioma	51
Figure 4.3. Lateral abdominal radiograph of case no. 2 showing a soft tissue mass	54
Figure 4.4. Transverse ultrasound image of splenic	55

	haemangiosarcoma from case no. 2	
Figure 4.5A.	Enlarged spleen with mass at the cranial aspect from case no. 2	56
Figure 4.5B.	Section of splenic haemangiosarcoma	56
Figure 4.6A.	Ultrasound image of splenic abscess from case no. 3	59
Figure 4.6B.	Ultrasound image of splenic abscess 13 days later	59
Figure 4.7.	Parasagittal section through splenic abscess	60
Figure 4.8.	Lateral abdominal radiograph of case no. 4 with no organ displacement	62
Figure 4.9A.	Ultrasound image of spleen from case no. 4 infiltrated with adenocarcinoma	63
Figure 4.9B.	Ultrasound image of the liver infiltrated with adenocarcinoma	63
Figure 4.10.	Longitudinal section of spleen showing adenocarcinoma infiltration	64
Figure 4.11A.	Ultrasound image of large splenic hyperplastic nodule from case no. 5	66
Figure 4.11B.	Ultrasound image of case no. 5 showing liver metastases	66
Figure 4.12.	Section through large hyperplastic splenic nodule	67
Figure 4.13.	Lateral abdominal radiograph of case no 6 showing a soft tissue mass	70
Figure 4.14A.	Ultrasonogram of case no. 6 showing spleen with adenocarcinoma metastases	71
Figure 4.14B.	Ultrasound image showing liver metastases	71
Figure 4.15A.	Enlarged spleen with irregular surface from case no. 6	72
Figure 4.15B.	Transverse section through nodular spleen	72
Figure 4.16.	Transverse ultrasound image of case no. 7 showing splenic haemangiosarcoma	75
Figure 4.17A.	Enlarged spleen from case no.7 with mass at caudal end	76
Figure 4.17B.	Longitudinal section through spleen	76

Figure 4.18.	Lateral abdominal radiograph of case no. 8 showing hepato-splenomegaly	78
Figure 4.19.	Ultrasound image of case no. 8 showing splenic lymphosarcoma	79
Figure 4.20.	Lateral abdominal radiograph of case no. 9 showing a soft tissue mass	82
Figure 4.21.	Ultrasound image of case no. 9 of a splenic haematoma	83
Figure 4.22A.	Spleen from case no. 9 with omental adhesions	84
Figure 4.22B.	Section through spleen to show dilated blood vessels	84
Figure 4.23.	Ultrasound image of case no. 10 showing splenic MFH	86
Figure 4.24.	Ultrasound image of case no. 11 showing multifocal hypoechoic masses	88
Figure 4.25A.	Enlarged nodular spleen from case no. 11	89
Figure 4.25B.	Parasagittal section showing nodular lesions	89
Figure 4.26.	Lateral abdominal radiograph of case no. 12 showing enlarged spleen	92
Figure 4.27.	Ultrasound image of case no. 12 showing splenic hypoechoic lesions	93
Figure 4.28.	Grossly enlarged and congested spleen from case no. 12	94
Figure 4.29.	Ultrasound image of case no. 13 showing splenic nodular hyperplasia	96
Figure 4.30.	Ultrasound image of case no. 14 showing cystic masses overlying the spleen	98

List of Tables

	Page
Table 5.1. Age, weight, breed and sex distribution of the 14 cases presented	100
Table 5.2. Ultrasound characteristics of the splenic lesions seen in the 13 dogs	101
Table 5.3. Distribution and echogenicity of splenic and hepatic lesions in the 14 cases studied	103
Table 5.4. Primary and secondary tumour sites of suspected splenic disease	104
Table 5.5. Clinical, radiographical, ultrasonographic and histopathological diagnosis	105
Table 5.6. Breed, sex, age and splenic echogenity of the control group	106

List of Appendices

	Page
Appendix 4.1. Clinical signs for the 13 dogs with splenic disease	124
Appendix 4.2. Haematology results for the 11 dogs whose results were available	125
Appendix 4.3. Biochemistry results for the 13 dogs with splenic disease	126
Appendix 4.4. Normal laboratory values	127

Acknowledgements

I would like to express my sincere gratitude to some people and organisations without whose assistance this work would not have been possible.

I would like than thank my sponsors, British Council for awarding me the scholarship to study at Glasgow University.

I am forever indebted to my supervisors, Professors Nash A.S. and Boyd J.S. for their guidance and support throughout the course of my study.

My special thanks to "the girls", Susan Spence and Andrea Cauvin, for performing most of the scans with me. I am especially grateful for their support, encouragement and friendship.

I would like to thank Calum Paterson for his technical advice and assistance.

I would also like to thank Alan May, for his assistance and patience during the photographic sessions.

My thanks to the following people in the Clinical Studies department: the Clinical Scholars and nursing staff for their assistance in the course of the study.

I would also like to thank Alan Reid, Sheena McMath, Susan Cain and David Newham, in the department of Anatomy, for their technical assistance.

I would like to thank the pathologists and technicians in the Pathology department, for their assistance with the histopathological specimens and haematological samples.


I would like to thank the PDSA, Shamrock Street, staff for supplying cases for ultrasonographical studies.

Special thanks to my son Chama, my father and the rest of the family for their encouragement and patience during the course of my study.

Thank you to my flat mate and friend Lina Audicana for her kindness and support.

Declaration.

I hereby declare that the work presented in this thesis was done by me in the Clinical Studies and Anatomy departments.



Careen Hankanga.

Dedication.

In loving memory of my mother, Kathleen Gertrude Hankanga, whose love and guidance I will forever miss.

May her soul rest in eternal peace.

Chapter 1.

Introduction.

Section A

Ultrasonography

Not only do bats use high frequency sound waves for navigation, but they also use them to hunt their prey by night. Man has since learnt to “see” into the body using the same technique.

In the early 1870's, the Curie brothers discovered a means by which to produce and detect these high frequency sound waves. Forty years later, following the Titanic disaster in 1912 and with the threat of war looming, a way had to be found to detect unseen under water obstructions and submarines. Langevin applied the ultrasound techniques developed by the Curies for these tasks. In 1920, Sokolov suggested that the technique could be used to detect hidden flaws in metals (Shirley and others 1978). During the second world war, Langevin's crude detection system evolved into sound navigation and ranging (SONAR) and the radio detecting and ranging (RADAR) systems, these use pulse-echo principles. A machine called a reflectoscope was also devised to detect hidden flaws in metals. In 1937, the Dussink brothers in Austria were the first to describe the use of ultrasound for imaging: they used a transmission technique similar to X-radiography to produce “hyperphonograms” of the head. The technique was found to be of no clinical value and was later abandoned.

In 1949, Ludwig and Strothers applied the wartime use of ultrasound to detect metals, gallstones and foreign bodies in tissues using a 2.5 MHz pulsed echo commercial A-mode fault finding piece of equipment (Shirley and others 1978). Despite having observed multiple echoes from other tissues they dismissed these saying “tumour detection by the echo method is not a likely possibility, although it is conceivable that further improvements in instrumental design and refinements in technique may render it possible” (Wild 1978). In 1952, Reid and Wild performed the first two-dimensional scan to detect tumours in tissues using an improved machine (Shirley and others 1978). At about the same time a group led by Howry developed a machine that could display echoes from tissue boundaries.

In 1953, Hertz and Edler described the principles of echocardiography. In the same year, a Swedish neurosurgeon Leksell demonstrated by ultrasound a shift in the midline of a young boy's brain (Shirley and others 1978). He later operated and removed a blood clot saving the boy's life.

In the mid 1950's, Professor Ian Donald at the University of Glasgow, introduced the use of ultrasound to distinguish cystic and solid gynaecological lesions. This initiated the use of direct contact scanning with the full urinary bladder taking the place of the water bath into which a patient was immersed to

achieve adequate contact. Later, together with an engineer, he produced the world's first contact scanner in 1958.

By the late 1950's, diagnostic ultrasound was of proven clinical value and was used in the investigation of the eye, abdomen, heart, brain and pelvis. It was not until 1969 that Wild's original idea was utilised by Wells who was interested in the smaller echoes from the liver parenchyma. In 1972, Mountfold showed changes in the echo pattern received from a cirrhotic liver. In 1972, Kossoff, showed how tissue characterisation could be achieved using the gray scale technique, which made it possible to image the strong echoes from the organ boundaries and the weaker ones from tissue infrastructure (Shirley and others 1978).

One more hurdle had to be crossed and that was scanning of moving structures which was difficult and patterns of movement could not be scanned. In the early seventies, Somer and Bom pioneered the design of a real time system that produced rapidly updated moving images of a moving structure.

The use of ultrasound began much later in veterinary medicine although A-mode ultrasonography has been used for the evaluation of fat and lean proportions of meat animals since 1956 (Stouffer and Westervelt 1977). The reproductive use of ultrasound began as early as 1966 with A-mode being used for pregnancy diagnosis (Rantanen and Ewing 1981). Later B-mode gray-scale ultrasonography was used to evaluate other systems such as the abdomen, urinary tract and heart.

1.Principles Of Ultrasound

1.1. Production of the image

1.1.1. The pulse-echo principle

The transducer contains one or more crystals with piezo-electric properties. "Piezo" is derived from Greek meaning pressure. When these crystals are deformed by pressure, they produce electricity. Conversely, when an electric current is passed through them, they undergo mechanical deformation. Quartz was the original material used by the Curie brothers but was later found to be unsuitable, after which it was replaced by synthetic ceramics made of lead zirconate and barium titanate. Any given ceramic has a resonant frequency at which it will produce ultrasound most efficiently and this depends on the thickness of the ceramic. When a rapidly alternating electric signal is applied across these ceramics, an ultrasound beam is produced with maximum efficiency for the conversion of electric energy to acoustic energy (Taylor and others 1979). The highest frequency man can hear is 20,000 Hz (20-20,000 Hz). Frequencies commonly used in diagnostic ultrasound range from 1 to 10 MHz.

In continuous wave (cw) ultrasound, a single pure frequency is emitted. When a range of short pulse is used, wide frequency ranges are employed, the latter range is called the band width. The band width of an ultrasound signal refers to its frequency spectrum. Although in pulse-echo a nominal frequency is spoken of, because attenuation increases with frequency, the ultrasound band width actually changes as it passes through the tissues since the higher frequencies are attenuated. The ultrasound is released through the "pulse-echo principle", a term best explained using the example of a man in a canyon who shouts "hello!". This is the "pulse" which travels through air at the speed of sound until it hits the opposite wall and is then reflected, upon which it becomes an "echo" (Bartrum and Crow 1977).

A sound wave can be compared to a longitudinal wave having a wavelength, frequency and velocity. The wavelength (L) is the distance between two similar points on a given wave. The frequency is the number of cycles or wavelengths occurring per second. The velocity is described by the following formula:

$$\text{velocity} = \text{frequency} \times \text{wavelength}$$

If the speed of sound in a particular medium is known and the time taken for a pulse of sound to be emitted and returned to its source can be measured, the distance the sound travelled can be calculated. As the sound travels through the patient, it sends back echoes at reflecting surfaces. Instead of reporting the actual distance the sound travelled to the transducer from the reflecting surface, the ultrasound scanner converts this information into dots of light on a cathode ray tube (CRT) screen. The amplitude of the echoes received is reported in terms of brightness and the position of the dot of light on the screen is proportional to the actual distance travelled. An image of the tissues and organs traversed by the sound beam is constructed and their relative sizes and position in relationship to the transducer measured.

1.1.2. Interaction of the sound waves with tissue

When an ultrasound pulse is sent into the soft tissues of the body, it undergoes continuous modification, the most significant being attenuation, which occurs mainly through reflection, absorption and scattering of the sound beam. Of the three modes of attenuation, reflection is the most important in the production of the image. This is the portion of the sound beam which is returned to the transducer upon striking a reflective surface and thus forms the basis of ultrasound imaging.

The body is made up of different tissues which have a diverse cellular make-up giving the tissues a characteristic acoustic impedance. Acoustic impedance is the ability of a sound beam to compress and stretch the tissue that it is travelling through. The ability of a tissue to stretch or be compressed (bulk modulus) depends in turn on its molecular density. Acoustic impedance (Z) is

therefore a product of the tissue density (ρ) and the velocity (V) of sound in that tissue. Thus,

$$Z = \rho V.$$

The amplitude of the returning echo is determined by the absolute difference in acoustic impedance of one tissue compared to another. This is illustrated in the following examples:

Sound travels at a speed of approximately 1540 m/s through soft tissue, the only variable which contributes to the acoustic impedance at a soft tissue interface is the difference in densities between one tissue and another. When tissues of different densities are in contact an acoustic interface is created. At a fatty tissue/soft tissue interface; since the density of fat is much lower than that of soft tissue, an increase in echogenicity is seen with fatty infiltration of an organ as a result. The difference in acoustic impedance at this interface is small so that most of the sound is transmitted on into the deeper tissues to send back further information.

In the case of a soft tissue/air interface, not only is the passage of sound slower through air (331 m/s), but air also has a negligible density. This creates a large mismatch in acoustic impedance and a strong echo is seen at this interface. This echo is so strong that air acts as an effective barrier to the sound beam, contributing to artifacts such as acoustic shadowing and reverberation which are due to the high reflectivity of the interface.

Bone is considerably denser than soft tissue and allows the passage of sound at a velocity of 3,100 m/s. The considerable difference in the tissue densities creates a great mismatch in acoustic impedance at a soft tissue/bone interface. This interface, like a soft tissue/air interface, also effectively blocks the sound beam through reflection and also absorption by the bone mass.

The difference between the acoustic impedance of soft tissue is rather small, and the echogenicity is accounted for by the bulk modulus of the tissues. Structures which serve as support for soft tissues are more rigid than the surrounding tissue. Examples are collagen, elastin and other support tissues of the fibrous skeleton (Taylor 1978).

Interfaces give rise to two types of reflections, specular and non-specular echoes. Specular reflections occur when an interface is larger than the sound beam. The angle of incidence of the beam is equal to the angle of reflection and so echoes from this interface do not return to the transducer unless they strike the specular reflector head on. Thus the echoes have an angle-dependence. Examples of these reflectors are the various supporting tissues such as organ capsules, collagen fibres, large blood vessels and diaphragm. The strength of an echo therefore does not only depend on the difference in acoustic impedance but also the angle at which the beam strikes the interface. Non-specular (back scattered) reflections occur when the interface is smaller

than the sound beam. Therefore as the small non-reflector interface is always surrounded by the beam, the amplitude of the non-specular echo is independent of the beam angle. The beam is scattered in many directions so that only a small portion (known as back scatter) of this is returned to the transducer. These non-specular echoes are of low amplitude and they give organs their characteristic "echo-texture". Tissue features known to influence back scatter include fat, water content, vascularity, collagenous tissue and calcification. Because of their size these reflectors generate weaker echoes compared to the larger specular reflectors. When high amplitude echoes originate within soft tissues these are considered to be due to change in the tissue consistency and not random orientation of the transducer (Taylor 1978). Echo-texture changes in tissue therefore reflect changes in tissue elements that do not include specific histological manifestation such as inflammation and neoplasia. The size of the scatterer is an important factor in influencing back scatter. For example fat produces relatively strong back scatter because of the large size of adipocytes compared to other cells (one cell may reach up to 0.1 mm in diameter). Hence accumulation of fat in the liver causes an increase in tissue echogenicity whereas focal reduction in fat content (e.g by a tumour mass) will produce a hypoechoic lesion. Since these echoes are weak, they are amplified to be viewed properly by selectively increasing the gain on the machine, which is further discussed under time gain control.

Attenuation is the sum of acoustic energy losses resulting from absorption, scattering and reflection (Taylor and others 1980). The sound beam is attenuated at the rate of 1 db/cm/MHz. However it is important to remember that the sound beam actually travels twice the distance that is, from the transducer to the reflecting surface and then back. Therefore a 5 MHz sound beam is attenuated 40 decibels at 4 cm. Attenuation, like all forms of energy, is an exponential phenomenon, that is, it increases with the square of the distance travelled (Taylor and others 1980). Therefore when the distance travelled is doubled, the attenuation increases by a factor of 4. Attenuation of ultrasound increases linearly with the frequency of the beam (Taylor and others 1980). Due to attenuation of the ultrasound beam, echoes originating from deeply placed tissues are weaker than those from the more superficial ones. Selective amplification of the weaker echoes is required to get even sized echoes throughout a homogeneous tissue (Taylor and others 1980).

The time gain compensation (TGC) control is the electronic compensation for tissue attenuation (Taylor 1978). Time refers to the fact that the amplifier increases the gain as a function of time. Since time is the same as distance, this may be called distance gain compensation. Since attenuation is exponential, the TGC is also exponential, that is, an echo coming from twice the distance has four times the amplification so that a similar echo amplification

emanates from reflectors independent of the distance from the transducer and effects of attenuation (Taylor and others 1980). Take, for example, a homogeneous organ with three interfaces at different depths of 3 cm, 6 cm, and 9 cm. Since they are at different depths, they will give echoes of different amplitudes. If a 2 MHz transducer would yield echoes of 50 dB, the 3 cm interface will yield $2 \text{ MHz} \times 1 \text{ dB/cm/MHz} = 2 \text{ dB/cm}$ which is the rate of attenuation. Since the echo actually travelled a distance of 6 cm, it will have attenuated $6 \text{ cm} \times 2 \text{ dB/cm} = 12 \text{ dB}$; the 6 cm interface 24 dB and the 9 cm interface 36 dB. Thus the echoes received from these interfaces would be $(50 - 12) = 38 \text{ dB}$, 26 dB and 14 dB respectively. Since these echoes should have been 50 dB, they need to be corrected using an amplifier. Echoes that come from a greater distance are amplified more. Therefore, the echoes from the 3 cm interface are amplified by 12 dB, the 6 cm by 24 dB and the 9 cm one by 36 dB. Improper gain setting can produce an abnormal parenchymal pattern or even simulate an image of a tumour or abscess. On an ultrasound machine the TGC control is varied over a wide range depending on the tissue being scanned and the transducer used (Bartrum and Crow 1977).

Resolution is the ability to visualise separately two closely spaced interfaces (Bartrum and Crow 1977) and is expressed as distance (mm). Resolution is dependent on the wavelength. As already seen, wavelength is inversely proportional to frequency, therefore increasing the frequency causes a decrease in the wavelength and increases the resolution. However, as the frequency increases, so does attenuation of the sound beam. Low frequency transducers are used to image deeper structures with a compromise of resolution whereas higher frequency transducers can image the more superficial structures and obtain high resolution (Herring and Bjornton 1989).

Axial resolution refers to resolution along the path of the sound beam and is therefore the ability to distinguish two points along a vertical line (Bartrum & Crow 1977, Herring and Bjornton 1989). This is determined by the pulse-length of the sound beam. The pulse-length is a product of the speed of sound in the medium and the duration of the pulse (Bartrum and Crow 1977). For example, to calculate the optimal resolution in soft tissue; since the speed of sound in soft tissue is 1540 m/s, and a typical pulse lasts for 2 microseconds, the pulse length is approximately 2 mm. As physical principles state that the resolution should be no more than half the pulse length (Bartrum and Crow 1977), the optimal resolution in this case is therefore 1 mm. The smaller the axial resolution, the better the image (Herring and Bjornton 1989).

Resolution perpendicular to the sound beam is known as lateral resolution. This refers to the ability to distinguish between two echo-forming surfaces lying side by side in relation to the sound beam (Herring and Bjornton 1989). The lateral resolution is determined by the size and width of the sound beam (the

narrower the beam the better the resolution), the distance of the echo-forming surfaces from the transducer face and the size of the transducer itself (Herring and Bjornton 1989, Bartrum and Crow 1977). If the two interfaces are closer together than the beam width, they will give rise to two echoes which will be received as a single echo by the transducer.

1.1.3. Common Imaging artifacts

An artifact on a B-mode, gray-scale ultrasound image has been defined as any dot appearing in the ultrasound image that does not correspond to a real echo in the patient (Park and others 1981). To prevent errors in interpretation of the images, thorough understanding of artifacts and their production is essential. Artifacts are caused by sound beam properties, transducer qualities (side lobes), instrument adjustments and scan techniques. Some artifacts such as acoustic shadowing and enhancement can be helpful in making an accurate diagnosis whereas others, such as reverberation and mirror image artifacts, are not.

1.1.3.1. Acoustic enhancement (distant or through transmission)

When a sound beam passes through a relatively homogeneous medium such as a fluid-filled structure, there is less reflection and attenuation. Therefore when the sound strikes the far wall of this cystic structure and the deeper structures, the echoes appear to be brighter than the surrounding structures at the same depth (Figure 1.1). This is confirmation of a fluid-filled structure which may appear anechoic or may even be echogenic as in the case of an abscess. A solid mass may also demonstrate prominent acoustic enhancement (Bree and Silver 1979). Some homogeneous non-fluid filled masses (such as freshly clotted blood) may appear anechoic but enhancement of the deeper tissues will not be seen (Rantanen and Ewing 1981). Acoustic enhancement is possible only when there is an anatomical area into which the sound can travel (Bree and Silver 1979).

1.1.3.2. Acoustic shadowing

This artifact is caused by diminished transmission of sound due to attenuation and/or reflection of the sound beam at an acoustic interface. The zone deep to the reflecting or attenuating structure is anechoic (Figure 1.2). The zone may be completely anechoic (clean shadowing) or light reverberations may appear in the shadowed area (dirty shadowing). Acoustic shadows of clinical significance are caused by calculi and gas. If the shadowing object is in the wider part of the beam, then sufficient energy may pass around it and illuminate the distal tissues; thus no shadow will be seen. The object must therefore be within the transducer's focal zone, where the beam is narrowest,

in order to produce a shadow and the operator must know the focal zone of the transducer being used (Taylor 1985, Kremkau and Taylor 1986). An earlier attempt to predict the origin of a shadow by its appearance, has more recently been shown to be unreliable, as the highly reflective structures produce both clean and dirty shadows (Rubin and others 1991). A shadow may not be cast if the shadowing object is smaller than the beam width or the wavelength (Taylor and others 1979).

Shadowing may also be produced by refraction of the sound beam at the edge of a rounded structure, when it travels from a medium velocity area to a lower one (Figure 1.1). The beam is reflected at this interface and then, after travelling through the cystic contents, it is again refracted at the tissue/cyst interface, so that the beam emerges parallel to the incident beam (Taylor and others 1980). This is seen in abdominal scanning at the gall bladder and urinary bladder. It is important to remember that:

(a) The object causing the shadow must be within the focal zone of the transducer to be fully appreciated. If it is not, the shadow may fill in, with echoes coming from surrounding tissues as the beam diverges (Jaffe and Taylor 1979).

(b) Using a properly focused transducer and viewing areas of interest from more than one angle (Jaffe and Taylor 1979).

In the final analysis, ultrasonographic interpretation of acoustic shadows is difficult and may lead to erroneous conclusions. A reverberation pattern is almost always due to gas, clean shadows and those with diffuse echoes lack specificity. (Laing 1983).

1.1.3.3. Reverberation artifacts

Reverberation artifacts occur when returning echoes are reflected at the transducer face and re-enter the patient, causing a second echo to be displayed twice as far from the original acoustic interface and possibly repeated many times. This artifact is mainly seen at a soft tissue/fluid-gas interface, therefore it is mainly seen at the diaphragm-lung interface. It appears as hyperechoic parallel lines recurring at regular intervals (Figure 1.3). This artifact is not seen at soft tissue - bone interface because most of the sound is absorbed. Situations in which reverberations are severe:

(i) The stronger echo has enough amplitude to make a return journey and be reflected many times; soft tissue interfaces do not produce reverberation unless they are large specular reflectors located at right angles to the sound beam.

(ii) Reverberations are more likely to be produced at high gain than low. Increasing the gain gives the echoes more amplitude thus less attenuation (Skolnick and others 1975).

(iii) The nearer an interface is to the transducer face, the more likely it is to

produce reverberation artifacts due to lesser attenuation.

1.1.3.4. Mirror-image artifact

This artifact also occurs at a highly reflective interface, but here, multiple internal reverberations occur between the interface and other body tissues. These echoes are thus delayed in returning to the transducer and are displayed as originating beyond the original interface. Any curved surface with highly reflective walls can be a source of multipath reflections (Laing 1983). This artifact is most dramatic when it recreates a mass and is usually seen at the diaphragmatic-lung interface (sound beams are reflected by this interface, then by the gall-bladder and then back to the transducer, so that the liver is seen beyond the diaphragm). The mirror-image artifact is also seen at the pericardium-lung interface (Figure 1.4).

The mirror-image artifact should therefore be suspected when a “lesion” occurs immediately behind a strongly reflective and absorptive interface (Laing 1983).

1.1.3.5. Comet-tail artifact (meteorisation)

This is a reverberation artifact and is the least common. It occurs when there is marked difference in the acoustic impedances between an object and its surroundings. The diaphragm-lung or the bowel wall-gas-filled lumen interfaces may produce this artifact. Typically the artifact tapers as the apparent distance from the transducer increases; the brightness of the displayed echoes also decrease (Figure 1.5).

This artifact has to a certain extent some clinical significance in that it may assist in increasing the degree of confidence of a diagnosis, an example of which is seen in the thorax. The absence of comet-tails in the lungs or their displacement is an indication of a pleural effusion or an extrapleural mass (Thickman and others 1983)

1.1.3.6. Other artifacts

Two other artifacts are “slice or beam thickness” and side lobe artifacts. The effect of these in a fluid collection is that they create echoes which mimic dependent particulate matter (e.g. in the bladder and gall bladder, they mimic sludge), (Figure 1.6). The slice thickness artifact occurs when part of the ultrasound beam interacts with a fluid-filled structure and the rest with an echo reflector. This may be avoided by focusing a narrow beam at the level of the cystic structure.

Side lobe artifacts are due to the presence of transducer side lobes that are multiple lower intensity sound beams located outside the main beam (Laing 1983). The echoes produced may be diffuse or specular in appearance and occur when sufficiently intense side lobes interact with highly reflective

acoustic surfaces. This specular side lobe artifact is seen in the area of a curved highly reflective surface such as diaphragm, urinary bladder or gall bladder (Laing 1983). Positioning the transducer away from the reflective structure should reduce or eliminate these echoes. These artifacts are both dependent on the beam angulation.

1.2. The Transducer

The transducer has been described as the 'heart' of the ultrasound machine. It houses the crystals with the piezo-electric properties. The frequency of the transducer is determined by how many times the crystals expand and contract per second (Bartrum and Crow 1977). This is controlled by application of a cycling voltage at the required frequency and use of the property of resonance of the crystals. Because of this property, some frequencies (resonant frequencies) are enhanced while others are suppressed.

A transducer may either be focused or unfocused. When placed in contact with a patient, the sound beam flares out in a fan-shape. This area is made up of two areas of interest, the "near field" (Fresnel zone) and the "far field" (Fraunhofer zone) (Bartrum and Crow 1977). The near field, which is closest to the transducer face is relatively constant and is about the same width as the transducer crystal. The beam later becomes divergent in the far field. The location of the transition between the two zones depends on the diameter of the transducer in relation to the frequency (wavelength). The relationship is represented by

$$d = r^2/L$$

where d is the length of the near field, r is the transducer radius and L is the ultrasonic wavelength.

The wide field of the transducer limits the lateral resolution. Using the above equation it can be seen that when the transducer size is decreased, the boundary between the near and far fields will be closer to the transducer. In the Fraunhofer zone, as a result of beam divergence, there is increased attenuation and loss of lateral resolution (Bartrum and Crow 1977). The depth of the Fresnel zone is directly related to the size of the transducer face and inversely related to the wavelength. This zone can therefore be lengthened by using a transducer with a larger face or lower frequency or both (Bartrum and Crow 1977). Non-focused transducers are suitable for many ultrasound applications e.g. echoencephalography and bi-stable abdominal scanning. However, gray-scale abdominal scanning requires a focused transducer for best resolution and echo amplitude sensitivity.

Focusing a transducer changes the shape of the sound beam and produces a narrow section of the beam, referred to as the focal zone, the mid point of which is the focal point. Focusing is done by using a lens or mirror (externally focused) or more recently by producing crystals with a curved surface

(internally focused). Since axial resolution is a function of the pulse width, the smaller the pulse width the better the axial resolution (Rantanen and Ewing 1981). Higher frequency transducers have a narrower beam width than a lower frequency one of the same diameter; the higher the frequency of the transducer, the better it can be focused. For transducers of the same frequency, the degree of focusing is related to the size of the transducer face; the larger the face the better (Bartrum and Crow 1977).

1.2.1. Types of Transducers

1.2.1.1. Linear array transducers

i. Mechanical linear array transducers

A single transducer is moved backwards and forwards at high speed. Despite some mechanical disadvantages in such a system, the use of a single transducer element produces good beam profile so that the imaging qualities are quite variable (Taylor and others 1980).

ii. Electronic linear arrays

This type of transducer consists of 64-120 transducers arranged like piano keys (Taylor and others 1980). They are electronically fired in a given sequence which is so rapid that no evidence of image replacement is noticed on the screen. The resulting image is rectangular. The number of transducer elements determines the amount of information on the screen. Electronic focusing allows the image quality to approach that of electronic sector scanners (Herring and Bjornton 1989). These scanners allow a large field of view, even close to the scanning surface, which facilitates recognition of structures and their anatomical relationships with other organs. They are cheaper in price than the sector scanners.

Their main disadvantage is that they are bulky and so require a relatively large contact with the body surface. Smaller transducers have recently become available for the veterinary market. Due to their flat surface, there is poor contact because of the curved contours of the body wall; early linear arrays had poor lateral resolution but this has been overcome by electronic focusing (Taylor and others 1980, Herring and Bjornton 1989, Barr 1990).

1.2.1.2. Sector transducers

i. Mechanical sector transducers (rockers, rotating transducers)

A single transducer is rocked mechanically or crystals mounted on a rotating wheel are rocked to and fro in an arc producing a triangular or fan-shaped image. The sector can be varied from 15-60 degrees at a frame rate of 60 per second. The mechanical scan heads have to stop at the end of each arc and they must avoid any lateral movements although the latest mechanical

transducers have overcome this problem. A compromise has to be made between the number of pulses per second (pulse repetition frequency - prf) and the depth of penetration. Most scanners may produce a maximum prf of 3000 per second and up to a depth of 25 cm. If a higher prf is used, this results in the echoes from one pulse being superimposed on those from the next one (Taylor and others 1980). Sector scanners have a smaller area of view compared to linear ones making it more difficult to identify and relate structures. Resolution is compromised when imaging a fast moving organ with a high frame-rate but this is overcome by narrowing down the beam at the expense of a larger field of view.

The scan heads are small and so only a small contact area is required and a small window can be used, avoiding artifacts caused by structures such as the ribs and air-filled lung. In addition to abdominal scanning, sector scanners are mainly used for echocardiography

II. Electronic sector transducers (phased arrays)

These transducers consist of a fixed array of crystals which are electronically triggered to sweep the ultrasound beam through a fan-shaped field like that produced by the mechanical sector. Variable focusing by the crystals is achieved. They basically have the same advantages and disadvantages as the mechanical scanners but are more superior in quality as they do not have moving parts which wear out. The sequential firing by the crystals is controlled by a microcomputer, this makes these transducers very expensive, and as a result their use is limited in veterinary medicine (Herring and Bjornton 1981, Barr 1990).

1.2.1.3. Annular arrays

This is a nest of transducers designed to improve the beam profile over that produced by a single transducer element (Taylor and others 1980). The transducers are concentrically arranged and each transducer focuses at a different distance, so that by the use of all the transducers, a thin beam profile should be obtained (Taylor and others 1980). Because of the number of transducers involved, the transducer head tends to be large and skin contact becomes more difficult. The clinical trials carried out show that the improvement in resolution is marginal. Cost effectiveness over a single focused element is unproven and the future of annular arrays remains uncertain (Taylor and others 1980).

1.3. The Scanner

1.3.1. Display systems

1.3.1.1. Bi-stable systems

The bi-stable system was employed before the advent of gray-scale systems in 1974. In this system either an echo had sufficient amplitude to be recorded or it was below the given threshold and was not recorded on the cathode ray tube (CRT). The system thus discarded an enormous amount of information on echo amplitude and echoes of different sizes above the critical threshold were displayed at uniform intensity. It failed to register many small echoes from within the soft tissue parenchyma, therefore essentially only large specular echoes were displayed and cystic lesions could be diagnosed at increased gain whereas subtle soft tissue textural differences were entirely lost.

1.3.1.2. Gray-scale systems

The term gray-scale refers to a selective amplification of low level echoes which originate from within soft tissues and display these at the expense of larger echoes. The larger echoes which are specular in origin are increasingly compressed. As the amplitude of these reflectors depends on the beam angle to the particular reflector, the absolute amplitude of the reflectors is random (Bartrum and Crow 1977). It is because of the nature of these reflectors that the compression of this type of data leads to little loss of clinically important information.

1.3.2. Display format

There are three basic display formats:

1.3.2.1. A- mode (Amplitude modulation)

As a short pulse of ultrasound traverses biological tissue, multiple small interfaces are encountered. At each of these interfaces a small fraction of energy is returned along the path of the incident ultrasound beam towards the transducer where each of these fractions produce a potential difference by the reverse piezo-electric effect. The image produced consists of vertical peaks along a horizontal axis. The horizontal axis represents distance and the vertical axis the strength of the returning echo. This form of ultrasonography was used in encephalography but has now been replaced by computed tomography (CT) scanning.

1.3.2.2. B-mode (Brightness modulation)

Most veterinary ultrasound currently performed is B-mode real-time imaging. This mode provides a two dimensional anatomic reconstruction of cross-sectional soft tissue slices made by the sound beam. Returning echoes are displayed on a cathode-ray tube (CRT) as dots of light on a black background.

The amplitude of the echo determines the brightness of the dot. B-mode displays can be two dimensional with X-axis representing distance and the Y-axis time. There was some debate about the better background format for ultrasound: black on white or white on black. The former is preferred but some machines offer both formats. The two basic types of B-mode scanners are static and real-time scanners.

Static scanners require a skilled operator to create the ultrasound image on the display screen by manually moving the transducer crystal over the structures being examined. The image may be held on a display screen once it is completed.

“Real-time” is a phrase borrowed from computer jargon. It refers to the dynamic presentation of sequential images, at frame rates of up to sixty per second. This results in a moving replication of structures as they change position with time. Real-time imaging has two important applications: the ability to image the movements of fast moving structures such as heart valves and as the system is automated imaging, it is independent of manual skill of the sonographer.

1.3.2.3. M-mode (Motion modulation)

This is an adaptation of real-time scanning. A cursor allows selection of one line on the B-mode scan. In isolation this would be shown as a single line composed of dots of varying brightness representing the interfaces crossed. This vertical line is continuously updated and the image moved along a horizontal axis, thus showing movement of the structures along that line. This form of display is used exclusively in echocardiology.

1.4. Image recording systems

1.4.1. Polaroid camera

This is a simple and initially cheap system. The camera is swung in front of the screen to photograph the frozen image. The major disadvantages of instant film are that images produced have poor contrast, each print is expensive to produce and is temperature sensitive.

1.4.2. Video printers

These are more expensive than the polaroid camera, but they produce rapid reproduction of the frozen image on paper at very low cost. The prints are of excellent quality but turn yellow-brown with time. Newer versions have a longer life and approach photographic quality.

1.4.3. Multi-format camera

These cameras are either manual or automatic but both types are expensive. Images are produced on x-ray film which is processed routinely to produce a

permanent image of excellent quality. The cost of producing each image is low as four to six images maybe recorded on each piece of film. This camera is therefore the method of choice for recording the frozen image.

Real-time equipment requires the use of a recording device. Video cassette recording systems are available which allow review through the ultrasound monitor. Adaptations can also be made between the video tape equipment and the ultrasound monitor to allow for still frame photography. The moving image may also be replayed for revaluation of the whole scan.

1.5. Biological effects of ultrasound

During the development of ultrasound for echo-sounding in naval warfare, it was observed that small fish were killed by the action of the sound beam. This led in the 1930s to a considerable interest in the possibilities for using ultrasound for tissue modification or destruction of a wide range of disorders including cancer. It has been long known that high frequency, continuous wave ultrasound can cause chromosomal aberrations in a number of plant species. Reports by Macintosh and Davey (1970, 1972) of chromosomal aberrations in human lymphocytes after prolonged insonation with ultrasound caused a great stir, mainly because the ultrasound generator used was a foetal heart detector. However, other attempts (Coakley and others 1972) to replicate these results failed and it was concluded that the changes seen by Macintosh and Davey were the result of experimental technique and independent of insonation. An elaborate study on the possible harmful effects of ultrasound by Thacker (1973) did not reveal any incriminating evidence.

Portions of the ultrasound beam can be absorbed by the body as heat, and it is these which could be responsible for the potential biological damage to the tissues insonated. However, the intensity of the sound beam is too low ($3-10$ milliwatts/cm²) and the amount absorbed as heat is negligible due to dissipation in the fluids of the body (Rantanen and Ewing 1981). Also the ultrasound transducer only emits bursts of ultrasound 1/1000 of the time it is operating; 999/1000, it is in receiving mode. This therefore means that if an ultrasound transducer were placed in over an area for one hour, only three seconds ultrasound would be emitted. In most examinations the time taken to perform a scan is far less than an hour and the transducer is placed at various sites on the body.

Therapeutic ultrasound employs higher intensities ($0.5-3$ watts/cm²) but if used properly, no deleterious effects are seen (Rantanen and Ewing 1981).

1.6. Principles of ultrasound interpretation

Different tissues or matter can in part be recognised ultrasonographically by echo patterns. Bone and gas are highly reflective tissues and so effective

imaging cannot be performed through them. Fat is more echoic than water-dense tissues and can thus be recognised when surrounded by such tissues. Soft tissue organs are identified on gray-scale ultrasound scans by their specular and non-specular echo patterns. These give organs characteristic echo patterns and organ boundaries which are based on their cellular and stromal composition. Infiltrative processes such as oedema may reduce an organ's echogenicity or may increase it in the case of fibrous, fatty or some neoplastic cellular infiltration. Such diffuse changes in organ echogenicity may also be the result of technical machine settings and thus such variations should be checked against the echoic pattern of another parenchymal organ. Locating a scan plane that avoids bowel gas, lung and bony structures is called finding an acoustic window (Herring and Bjornton 1989), (Figure 1.7).

Ultrasound terminology

Echogenicity is a term used to describe the tissue appearance that results from the composite of returning echoes detected by the transducer. Relative echogenicity is the relative intensity (brightness) of various areas or organs within the region of interest. Echogenicity is relative and subjective and the descriptive terms have been introduced.

Anechoic (transonic, echolucent, sonolucent): no echoes are detected in the cavity containing the fluid, so there is increased sound intensity (acoustic enhancement) in the deeper areas. A solid mass may also be anechoic but no far enhancement is seen unless the mass is completely homogeneous.

Hypoechoic (echopoor): this may either be solid or complex fluid (abscess, haematoma and neoplasm). These soft tissue lesions usually have irregular ill-defined borders; acoustic enhancement of the deeper areas is not readily observed.

Isoechoic (usually solid): the echoes detected in the mass have essentially the same intensity as those in the surrounding area; there is usually no far enhancement or shadowing.

Hyperchoic (echogenic): the echoes detected in the mass are brighter than those in the area surrounding it. These may or may not have shadows beyond them.

Complex lesions appear as a mixture of echoic and hypoechoic areas and are seen with neoplasia or other tissues containing necrotic or cystic areas.

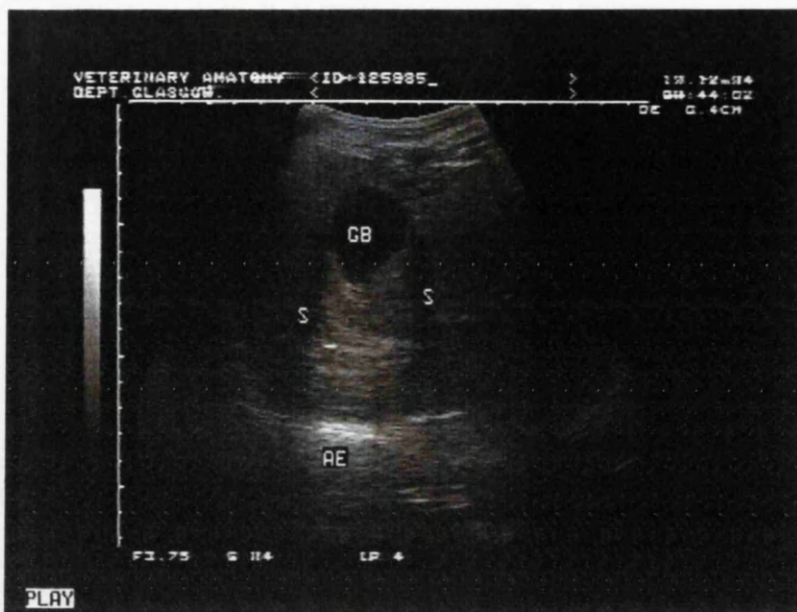

Figure 1.1.
Area of acoustic enhancement (AE) from the gall bladder. Edge shadowing (S) also shown.¹

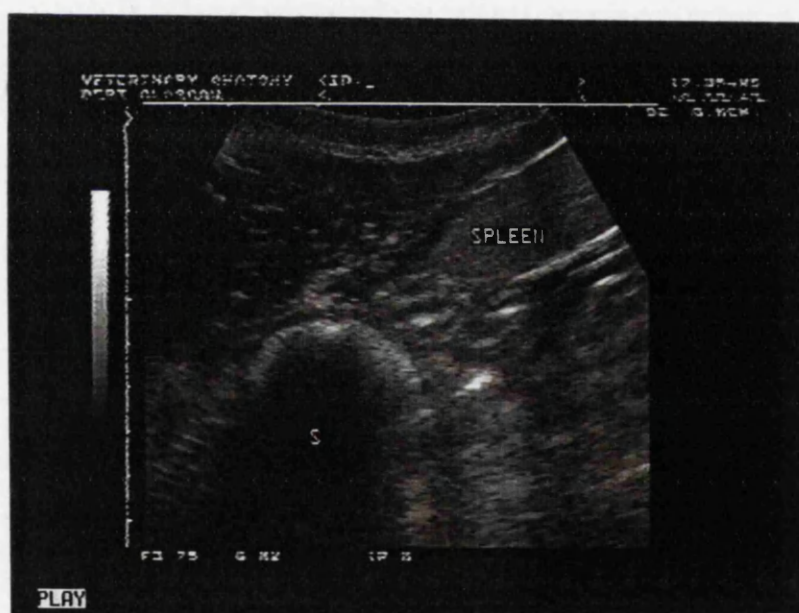

Figure 1.2.
Acoustic shadow (S) in the underlying tissues due to stomach gas.

¹All ultrasonograms are shown with the ventral abdominal wall at the top of the image.

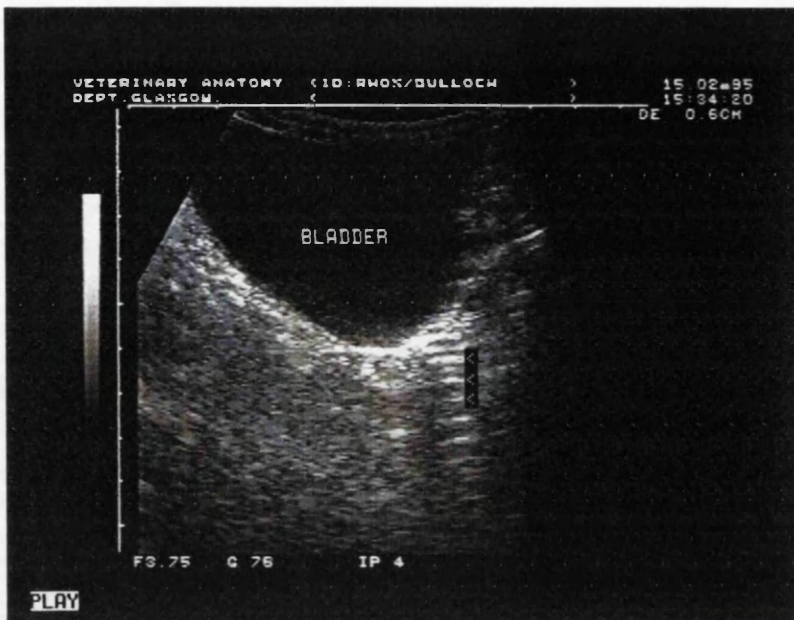


Figure 1.3.
 Reverberation artifact (arrows) due to intestinal gas seen as equidistant echogenic lines.

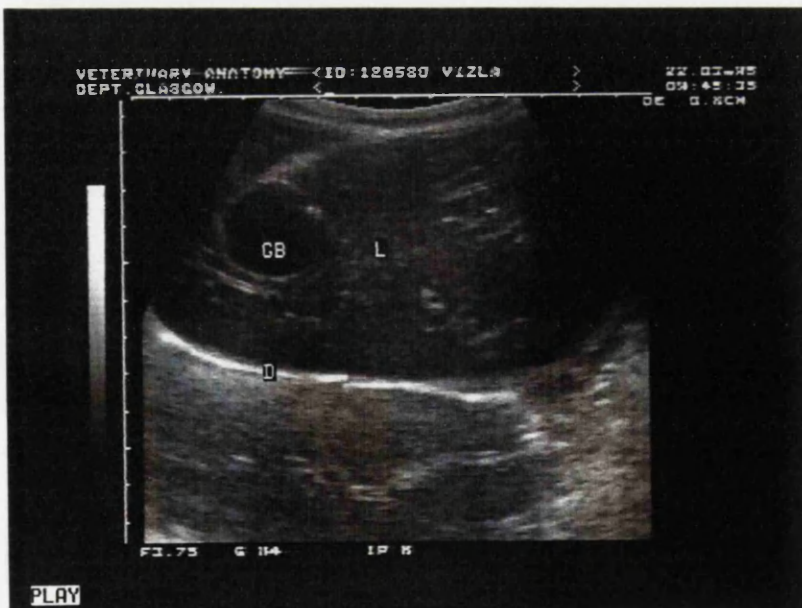

Figure 1.4.
 Mirror image artifact at the diaphragmatic-lung interface. An image of the liver (L) can be seen beyond the diaphragm.

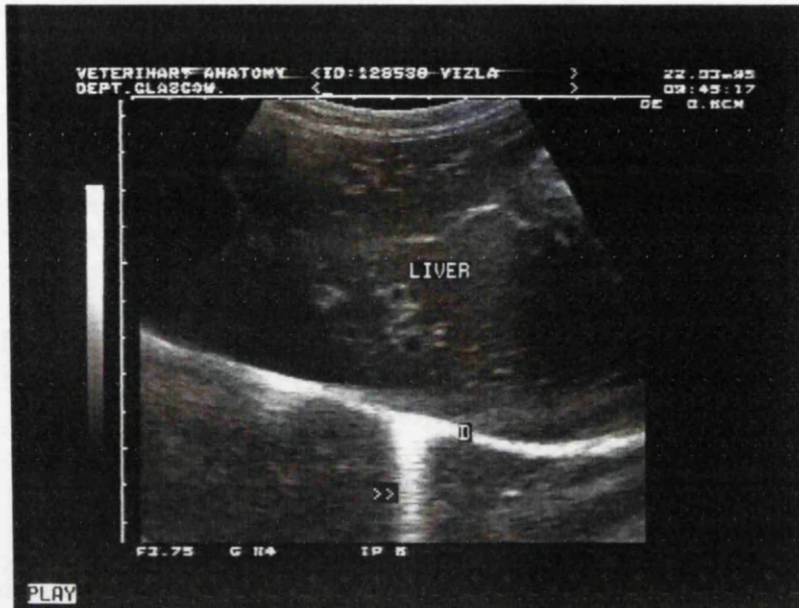

Figure 1.5.
 Comet-tail artifact (>>) at the diaphragmatic-lung interface.

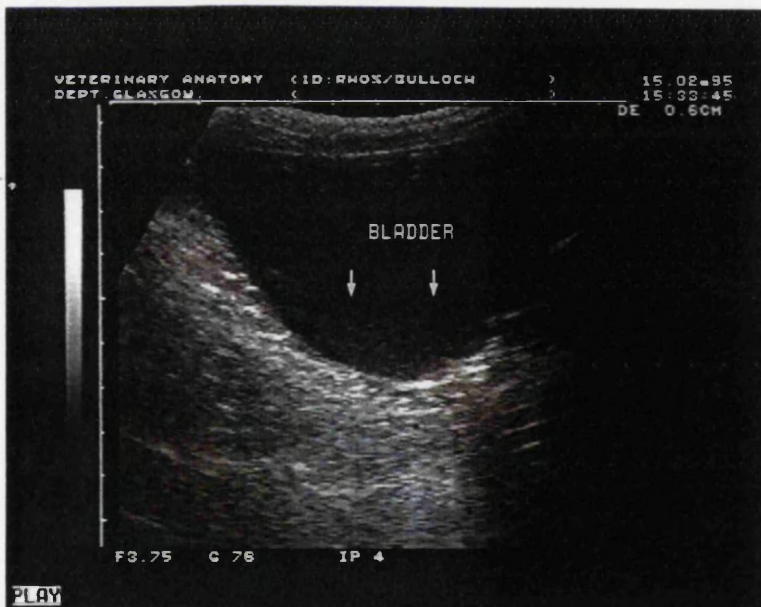


Figure 1.6
 Slice thickness artifact (arrows) in urinary bladder mimicking sludge.

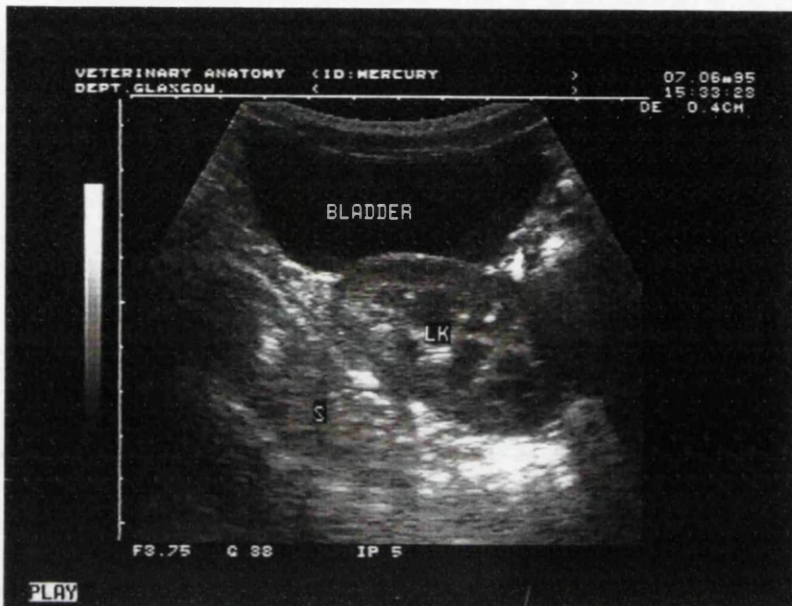

Figure 1.7.
Bladder acting as an acoustic window. Left kidney (LK) is shown with shadow (S) due to refraction of the sound beam.

Section B.

Radiography

2. Principles of radiography

X-rays form a part of the electromagnetic radiation which also include radio waves, microwaves (radar and heating) infrared visible light, ultraviolet light and gamma rays. These are all transmitted by combined electric and magnetic fields, travelling at a velocity of $3 \times 10^8 \text{ m/s}$ in a vacuum. They travel in straight lines and when they interact with matter can be absorbed or scattered.

2.1. Production of x-rays

X-rays are produced when charged particles are slowed down or stopped. The output of X-radiation is inversely proportional to the square of the mass of the incident particles.

In the X-ray tube, the cathode is the electron source and the negative electrode for the high voltage placed across the tube. The electrons are produced by heating a filament via an electric current from the low tension circuit of the X-ray machine. This process is known as thermionic emission. As the metal is heated, the movement and velocity of the outer or free electrons increases until they have enough velocity to pass through the surface of the metal and form an electron cloud around the metal. The number of electrons available to the electron cloud is directly proportional to the temperature of the filament. The number of electrons which pass from the cathode to the anode during the exposure represents the tube current and is measured in milliamperes (mA).

The anode consists of the target material embedded in a cylinder or disc, depending on whether it is a fixed or rotating anode X-ray tube. The electrons produced are accelerated toward the anode and strike the target which is made of tungsten or tungsten-rhenium alloy. The kinetic energy of the electrons when they reach the target is proportional to the high voltage which has accelerated them across the tube. The potential difference between the anode and the cathode is measured in kilovolts (kV). The higher the kV, the faster the electrons are accelerated and the greater the energy of the X-rays produced when the electrons strike the target. Less than one percent of the energy is converted to X-ray energy, the rest of the energy is converted into heat. Thus the anode is constructed so as to remove heat from the target.

2.2. Image formation and differential absorption

Some X-rays are absorbed by the patient or object and some pass through unchanged producing film blackening. X-rays are not absorbed homogeneously by the body, some tissues are more efficient at this than others. This phenomenon is called differential absorption. X-ray absorption by

a substance is affected by the effective atomic number of its elements and the physical density of the substance. For example, air has a physical density of 0.001 g/cm³ and atomic number 7.8; whereas fat is 0.9 g/cm³ and 6.5, respectively. Despite the higher effective atomic number, air is more radiolucent because of the lower physical density, that is, there are fewer molecules per unit area to absorb X-rays. If the physical densities and effective atomic numbers of water (1.00 and 7.5) and muscle (1.04 and 7.6) respectively are taken, muscle should be more radiopaque. However as the difference in their parameters is so small, the radiographic imaging system is not sensitive enough to allow detection of the differences in the radiopacities with substances with such small differences in physical density and effective atomic number. Thus the radiopacity of most fluids (blood, urine, transudates, exudates, bile and cerebro-spinal fluid) and non-mineralised, non-adipose tissues, including cartilage, muscle, fascia, tendons, ligaments and parenchymal organs, is essentially the same. The radiopacity of these fluids and tissue is referred to as soft-tissue radiopacity.

Chapter 2.

Section A.

3. The Normal spleen

3.1. Anatomy

The spleen is an elongated roughly dumb-bell shaped organ which is covered by a fibromuscular capsule. It is made up of a head, which is the dorsum of the organ, a body and a tail, which is the ventral extremity. The head of the spleen is rounded and wedge-shaped with the organ tapering towards the tail. The visceral aspect of the spleen is divided by a longitudinal ridge (the hilus), through which the splenic arteries and sympathetic nerves enter, and the veins and efferent lymphatics leave the organ (Figure 2.1). The area cranial to the hilus is related to the greater curvature of the stomach and that caudal to the hilus is related to the left kidney proximally (Figure 2.2). The central portion of the spleen is related to the colon and the distal portion to the intestinal mass (Figure-2.3). The parietal surface is convex and lies mostly against the left flank.

The organ is located dorsoventrally in the cranial left quadrant of the abdomen. The dorsal end is relatively fixed near the midline - caudal to the last rib. The rest of the organ is freely movable, hence the variations in position, which varies according to the animal's configuration, i.e. deep versus flat-chested and the degree of fullness of the stomach. These two factors influence how easily accessible the organ is for palpation.

The dorsal extremity lies ventral to the left crus of the diaphragm between the fundus of the stomach and the cranial pole of the left kidney. Because of the relatively fixed position, this part of the organ is least variable. The parietal surface faces the diaphragm and the left abdominal wall; it extends from the vertebral end of the last two ribs ventrolaterally and continues tangentially across the medial surface of the costal arch.

The blood vessels of the spleen are the splenic and gastrosplenic arteries arising from the coeliac artery and the splenic vein which drains into the gastrosplenic vein eventually reaching the portal vein. Blood enters the organ by way of numerous splenic branches which once within the capsule, course in the trabeculae branching repeatedly before entering the lymphoid tissue. At a calibre of 40-50 μm they leave the lymphatics and enter the red pulp to further branch into small straight vessels called penniculi (Bloom and Fawcett 1968)

Three types of spleen have been described in different species, and are referred to as, defensive, intermediate and storage spleens (Banks 1993). The first type has fewer trabeculae and muscle fibres but abundant lymphatic tissue (man and lagomorphs). The storage type has many smooth muscle fibres and trabeculae are relatively large and have less white pulp than the other form

(horse, dog and cat). Intermediate forms are typical of ruminants and swine (Banks 1993).

3.2. Histology

Histologically the spleen is made up of four main compartments: the capsule and trabeculae, the red pulp, white pulp and the marginal zone.

The fibromuscular capsule contains a large amount of smooth muscle fibres. These relax with the administration of barbiturates and some tranquillisers therefore causing a transient splenomegaly. The fibres contract in response to exogenous and endogenous catecholamines resulting in the release of red blood cells stored in the organ. Splenic contraction also occurs due to a massive bleeding episode. The capsule branches to form the trabeculae.

The marginal zone separates the red and white pulp. In cats and dogs it is poorly developed but in other species, it is populated with macrophages and is involved in blood filtration and phagocytosis (Weiss 1988).

The white pulp consists primarily of lymphocytes and reticuloendothelial cells distributed along the course of arterial vessels; these are cylindrical structures that surround the arteries after they leave the trabeculae and are referred to as the periaarterial lymphatic sheath (PALS).

The red pulp consists primarily of arterial capillaries, small venous vessels, a reticulum filled with macrophages and blood (Weiss 1988). The central arteries of the white pulp terminate in arterial capillaries in the red pulp. When these enter the red pulp they lose their PALS and become surrounded by a dense sheath of reticulum and macrophages, the periaarteriolar macrophage sheath (PAMS). This is well developed in cats and dogs and is the main area for clearance of blood-borne parasites.

The structure of the venous vessels is the main difference between the canine and feline spleen. In the dog these vessels form an anastomosing system of venous sinuses composed of long rod-shaped endothelial cells that lie parallel to one another. These structures are incompletely surrounded by basement membrane and reticular cells. The sinuses are closed and blunt at their origins and form major veins which drain into trabecular veins. In order to leave the spleen, blood cells need to squeeze between adjacent endothelial cells and enter the sinus lumen. The canine spleen is thus known as the sinusal spleen. In the cat, contiguous endothelial cells are pulled apart at various intervals forming apertures through which RBCs can escape into the lumen without changing shape. Cat spleens are termed as non-sinusal spleens.

3.3. Functions

Galen, the Greek physician, called the spleen the “organ plenum mysterii”. He considered it to be the source of black bile and melancholy (McNee 1931). To

Pliny, it was a source of merriment, but others regarded it as an impediment to athletes hence the reason for most splenectomies carried out in ancient Greece (McNee 1931). Despite later studies carried out on splenic function and disease, there still remain some unanswered questions.

In 1841, Bardeleben noted a reduction in red cell count, an increase in white count and hyperplasia of the bone marrow following splenectomy, thus elucidating the role of the spleen in erythropoiesis in human beings. Haematopoiesis is an important prenatal function of the spleen but this ceases after birth except in the mouse (Crosby 1977). However the organ retains its ability to begin producing red cells in bone marrow hypoplasia through pluripotent cells which differentiate into erythroid, myeloid and megakaryocytic precursors. Extramedullary haematopoiesis (EMH) appears to be more common in dogs than cats (Couto 1990). A variety of reasons such as RBC destruction, severe splenic or extrasplenic inflammation, neoplastic infiltration of the spleen, bone marrow hypoplasia and congestion may result in the spleen resuming its foetal haematopoietic function and producing RBC, WBC and platelets. Factors that normally inhibit release of abnormally immature cells into the blood stream do not exert their control at extramedullary sites.

In the dog the spleen plays an important role in erythropoiesis, as seen with the reticulocyte response following splenectomy giving a reticulocytosis of 67% and an increase in maturation time of 0.4-0.9 day when compared to control animals. However, there was a decrease in red cell production despite a 125% increase in the intravascular life span of the reticulocytes in the peripheral blood circulation. The haematocrit decreased (15-22%) compared with control dogs for a period of 6 months post-splenectomy with a decrease in the circulating blood volume, but there was no change in the RBC life span (Waldmann and others 1959). The changes were probably due to :

- (i). early release of reticulocytes from the bone marrow at an earlier stage of development (Lorber 1958);
- (ii). slower maturation of erythrocytes in the peripheral circulation (Jacobsen and Plum 1942); and
- (iii). lack of the organ that "pits" nuclear inclusions and normally sequesters reticulocytes (Waldmann and others 1959, Berendes 1959).

The question as to whether the spleen plays a role in bone marrow regulation still remains unanswered (Krumbhaar 1932, Singer and Weisz 1945).

The spleen is also responsible for iron turnover. According to Waldmann and others (1959), the plasma and red cell iron turn over was 32-36% below control determinations. Despite this decrease, which is due to the lack of the splenic recycling of this iron, the serum iron concentration tends to be low for a considerable period of time.

Dog and cat spleens have been described as "storage spleens" because of

their expansile qualities. Using kinetic analyses of RBC washout from perfused isolated spleens, it was determined that the blood flow in the canine and feline spleen is composed of three functional compartments: a fast compartment receiving 90% of total blood flow through which the RBC circulate in 30 seconds, comparable to the transit of RBCs through conventional capillaries in skeletal muscle; an intermediate compartment receiving 9% of the blood flow but containing 56% of the RBCs in the spleen because of a longer transit time of 8 minutes; and a slow compartment receiving approximately 1% of the splenic blood flow and containing reticulocytes, with a transit time of one hour. During sleep or narcosis the canine spleen stores as much as 35% of the blood volume causing a decrease in the haematocrit (Crosby 1977). During exercise, anoxia, haemorrhage, (pregnancy and heat?) and emotional distress, the spleen contracts resulting in a 6-15% rise in the blood volume (Barcroft 1930). There is no granulocytic pool in the spleen. However, there is a large lymphocyte population which is continuously interchanging with those of the thoracic duct, lymphatics, and blood (Jandl and Aster 1967).

In much the same way as a woman plucks a cherry stone without damaging the rest of the fruit, the spleen "pits" cytoplasmic inclusions (Heinz bodies, haemoparasites, Howell-jolly bodies) from red blood cells (Crosby 1959). Passage of the RBCs is facilitated by their pliancy and deformability, therefore the non-pliable portion of the cell containing the inclusion is severed, retained and phagocytosed in the red pulp. This filtration property of the spleen includes removal of abnormal blood cells such as acanthocytes, spherocytes, IgG-coated cells and senescent blood cells which are retained by the red pulp and later phagocytosed. These are removed by adsorption to the pulp cells through electro-physical processes (Robinson 1928). In hyposplenism both abnormal cells and cells containing cytoplasmic inclusions are found in the blood (Crosby 1959 and 1963). This process of filtration is greatly increased in splenomegaly.

The spleen accelerates reticulocyte maturation by removing their excessive membrane, thus it is called the "training camp of reticulocytes" (Crosby 1977). The spleen reduces the reticulocyte surface area by one third converting them from target cell to biconcave discs. In the process it also removes a high molecular weight surface protein complex (Eichener 1979).

Approximately 30% of the total platelet pool resides in the spleen and may be expressed into the circulation by a slow infusion of adrenaline. This is not seen in splenectomised animals (Waldmann and others 1959, Aster 1966). In humans with splenomegaly, up to 70% of the platelet pool may be sequestered in the spleen (Hill-Zobel and others 1986). Removal of the spleen thus results in thrombocytosis (Waldmann and others 1959), which is persistent if there is a continuing haemolytic anaemia with concomitant active bone marrow (Hirsh

and Dacie 1966) or if there is an underlying myeloproliferative disease. The result in these situations is severe thrombocytosis leading to increased risk of haemorrhage and thrombo-embolism.

The spleen is a critical line of defence when the host is invaded by blood-borne bacteria. It is the main site for clearance of such organisms and is the initial site for synthesis of immunoglobulin M (IgM) antibody (Eichener 1979). The spleen is a major site for synthesis of tuftsin and properdin, two proteins which serve as opsonins. Tuftsin is a polypeptide that coats polymorphonuclear leukocytes and macrophages to promote phagocytosis; properdin is a vital component of the alternate pathway of complement activation (Spirer and others 1977). In splenectomised or hyposplenic patients, an overwhelming post-splenectomy infection (OPSI) occurs in children and adults who undergo elective surgery (Erakis and others 1967, Constantopoulos and others 1973). Patients splenectomised due to splenic rupture, have almost normal levels of the opsonins, due to splenosis and are less susceptible to infection (Spirer and others 1977). In humans 50% of the infections are caused by pneumococci bacteria (Spirer and others 1977 and Likhite 1976.). There are few cases of septicaemia in dogs in the literature, one case of fulminant sepsis in splenic lymphosarcoma and secondary bacterial sepsis is recorded in the literature (Couto 1989) and another of a 10 year old Pomeranian which died of streptococcal septicaemia post-splenectomy following a dental extraction operation (Withrow 1979). Of a total of 131 splenectomies in the dog and cat, only four dogs were reported to have died from fulminant sepsis. These were splenectomised for immune-mediated anaemia and were on immunosuppressive therapy (Frey and Betts 1977, Hosgood 1987). Dogs are apparently not susceptible to OPSI, as they are resistant to pneumococcal infections (Hosgood 1987).

Other functions of the spleen include:

- (i). storage and activation of factor VIII coagulant activity and factor VIII related antigen (Von Willebrand's factor).
- (ii). regulation of the formation and liberation or degradation of angiotensin-converting enzyme.
- (iii). modulation of plasma norepinephrine levels and/or renal PGE2 activity (splenectomy protects from epinephrine-induced acute tubular nephrosis and myocardial infarction), (Couto 1989).

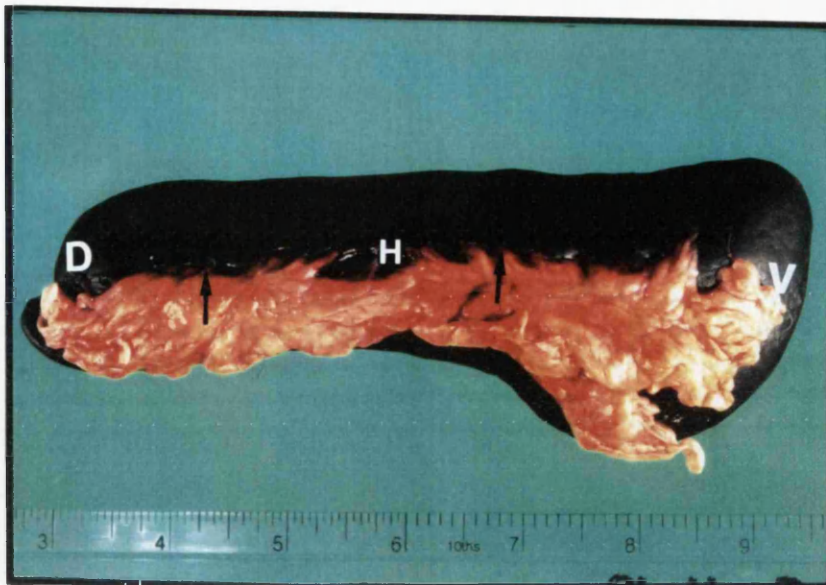


Figure 2.1.

Visceral surface of the normal dog spleen showing the hilar ridge (H) with splenic vessels (arrows). The dorsal (head) extremity (D) and Ventral extremity (tail) (V) can be seen.

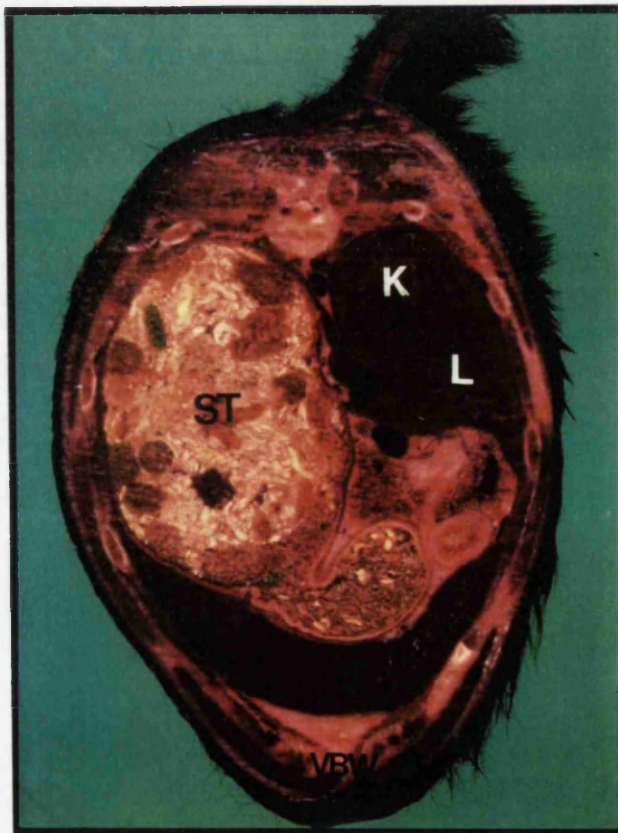


Figure 2.2.

Transverse section of a dog, at L1, showing parietal and visceral surface relationship of the spleen to other organs. K = kidney, ST = stomach, L = liver, S = spleen, VBW = ventral body wall.

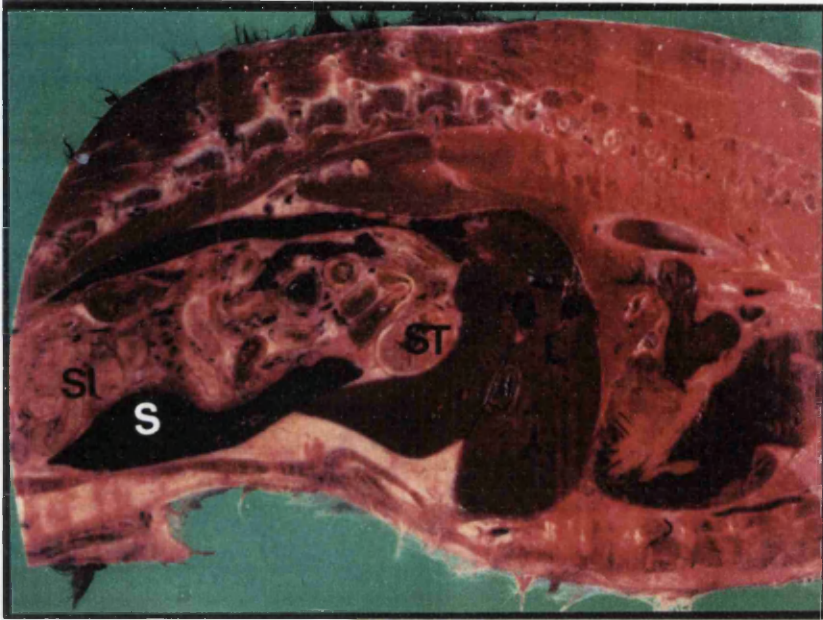


Figure 2.3.

Sagittal section of a dog showing normal organ relationships of the head, body and tail of the spleen. S = spleen, ST = stomach, SI = small intestines, L = liver.

Section B.

4. Splenic disease

Enlargement of the spleen is known as splenomegaly. This may either be generalised or localised. Localised splenomegaly refers to focal palpable enlargement of the spleen (splenic mass). Abdominal palpation and abdominal radiography are important diagnostic tools for detection of splenic pathology (Hosgood 1987, Johnson and others 1989, Frey and Betts 1977). Splenic masses are more common than generalised disease in the dog and the reverse is true for cats (Hosgood 1987).

4.1. Splenic masses

Splenic masses are classified as either neoplastic or non-neoplastic depending on their histological features. Although malignant neoplastic masses are very common (Hosgood 1987), non-neoplastic splenic masses such as haematoma were found to be the most common type of splenic mass (Couto 1990, Spangler and Culbertson 1992). Neoplastic splenic masses may be vascular (angiogenic) or non vascular (non-angiogenic) in origin. The two main vascular tumours are splenic haemangiosarcoma (SHS) which is malignant, and haemangioma (HGA), which is benign. Non-vascular tumours of the spleen include fibrosarcomas, leiomyosarcomas, leiomyomas, myelolipomas and occasional lymphosarcomas. Non-neoplastic masses of the spleen, need to be differentiated from the neoplastic ones, these are haematomata, abscesses, siderofibrosis and nodular hyperplasia which has assumed an important position in ultrasonographic studies of the spleen.

4.1.1. Non-neoplastic splenic masses

4.1.1.1. Splenic haematoma (SHA)

The terminology used to describe splenic trauma in dogs and humans includes laceration, transection, fracture, rupture, contusion, subcapsular haematoma and haematoma. Laceration, transection and fracture of the spleen describe increasing severe disruption of the splenic capsule in association with abdominal effusion. Splenic rupture is not clearly defined and splenic contusion describes "small collections of blood interspersed with disrupted splenic pulp" (Lupien and Sauerbrei 1984).

The pathogenesis of the formation of SHA is not well known and still under study. Trauma has been implicated as a cause but most dogs presented do not have a recent known history of trauma. In a study by Wrigley and others (1989), only one out of 10 dogs had a known history of trauma. In dogs, the spleen does not appear to be often involved in injury in accidents as in human beings. This is illustrated in a study carried out by Kolata and others (1975); out of 600

dogs involved in road accidents, only 3 had subcapsular splenic haemorrhage. In humans, the spleen is the organ most commonly injured during blunt abdominal trauma (Hanson and Penninck 1994). Previous trauma has been implicated in humans with formation of delayed splenic haematomata, this phenomenon has also been seen in one dog (Wrigley and others 1989). Recently an association has been found between splenic haematomata and splenic nodular hyperplasia (Spangler and Culbertson 1992). Distortion of the marginal zone where there is an intricate circulation of blood, in this case by nodular hyperplasia, results in failure of zonal circulation and blood accumulates around and within the nodule, eventually leading to haematoma formation, hypoxia and necrosis. SHA may also occur secondary to other diseases such as lymphosarcoma and haemangiosarcoma. Although SHA is a benign disease, the median survival time was significantly lower than that of control animals, 327 days compared with 617, respectively, in a study by Prymak and others (1988). No sex predilection is seen in SHA. The Standard Poodle was found to be at higher risk of suffering from SHA than the other pure breeds (Prymak and others 1988).

4.1.1.2. Splenic nodular hyperplasia (lymphoid follicular hyperplasia)

Splenic nodular lymphoid hyperplasia comprises areas of proliferation of the lymphocytes and reticular cells. Other areas may also show fibroblast, collagen deposition and even calcification (Ishmael and Howell 1968). These areas form solitary or multiple nodules of varying size which protrude from the splenic surface and may have necrotic centres; the nodules themselves are not encapsulated. SNH may be difficult to differentiate from early nodular lymphosarcoma and in dogs lymph node biopsies may be helpful in differentiation (Moulton 1978) The nodules become of clinical significance if they enlarge greatly, thus impinging on other organs, or when they rupture and cause fatal exsanguination (King 1993). Nodular hyperplasia occurs more frequently in dogs over 8 years old and rarely in dogs under 2 years (Moulton 1978). There is no sex or breed predilection (Moulton 1978). The nodules are usually firmer than the normal spleen and are either dark red or greyish white (Ishmael and Howell 1968, Moulton 1978). The cause of splenic nodular hyperplasia is unknown but spontaneous occurrence is said to result from senile functional degradation of the parenchyma and may be induced artificially by feeding high fat-low protein diets (Thomson 1978). Splenic nodular hyperplasia has also been encountered in cattle and sheep.

4.1.1.3. Splenic abscesses

Splenic abscesses are rare in the dog and are thought to be caused by

penetrating abdominal wounds, migrating foreign bodies (e.g. plant awns), haematogenous dissemination of bacterial infection (e.g. bacterial endocarditis, septicaemia with pyogenic organisms), bacterial infections secondary to splenic torsion, protozoal and mycobacterial infections (Couto 1990). In humans splenic abscesses are usually secondary to septic emboli, trauma or infarction and so solitary abscesses of the spleen are relatively uncommon (Dubbins 1980, Pawar and others 1982). Due to high mortality seen in these cases, in man, early diagnosis is vital for proper management (Chulay and others 1976). In man, clinical signs seen include left upper quadrant pain, fever, vomiting and in some cases a pleural effusion may be present (Pawar and others 1982).

4.1.2. Neoplastic splenic masses

4.1.2.1. Splenic haemangiosarcoma (malignant haemangioendothelioma, angiosarcoma)

Splenic haemangiosarcoma (SHS) is a tumour of immature endothelial cells that generally form vascular spaces, often as small clefts but sometimes as cavernous channels. These contain a variable amount of blood and sometimes exhibit thrombi. The vessels formed by this neoplasm are fragile and frequently rupture with resultant haemorrhage. The neoplastic cells are usually elongated but may vary in size.

Haemangiosarcoma occurs most frequently in dogs but is also encountered in other domestic species including the cow, horse, and cat (Pulley and Stannard 1978). Haemangiosarcoma is more prevalent in dogs than it is in man, the development of these tumours in the latter being related to exposure to chemicals such as thorium dioxide, arsenicals, and vinyl chloride (Ishmael and Howell 1968). Splenic haemangiosarcoma accounts for two thirds of all neoplastic splenic masses in dogs. It arises mainly from the liver, spleen, subcutaneous tissue and the right atrium but as it is a tumour of the endothelial origin it can arise in any tissue (Waller and Rubarth 1967, Waters and others 1988). The primary tumour site is difficult to determine in cases with widely disseminated disease, but when involved, the right atrium is considered the primary lesion due to infrequent metastasis to this area (Waters and others 1988). Unusual sites of haemangiosarcoma include bone (Bingel and others 1974), bladder, aorta, prostate and tongue. The simultaneous evolution of haemangiosarcoma in more than one organ (the concept of multicentric disease) is a possibility that cannot be dismissed (or proved) in certain individuals (Pulley and Stannard 1978).

A study by Prymak and others (1988) shows that dogs between the age of 8-13 years are more susceptible to SHS with an average age of 9 to 10 years old agreed by most authors (Frey and Betts 1977, Hosgood 1987, Pulley and

Stannard 1978). The German Shepherd dog (GSD) has been found to be the most susceptible breed to SHS (Waller and Rubarth 1967, Pearson and Head 1976, Pulley and Stannard 1978, Brown and others 1985, Prymak and others 1988). Sex predilection has also been reported in the literature; male dogs are more prone to SHS (Waller and Rubarth 1967, Frey and Betts 1977, Brown and others 1985). Hosgood (1987), however, found equal representation in the sex of animals that underwent splenectomies. Neutered females were also more frequently represented than intact ones (Prymak & others 1988).

The metastatic potential of haemangiosarcoma is extremely high. In a study by Bingel and others (1974), only 4 out of 22 dogs lacked metastases. Metastatic lesions are found in the lungs, liver, kidneys, adrenals, heart, omentum, peritoneum, skeletal muscle, mesentery, lymph nodes and diaphragm (Bingel and others 1974). Intraperitoneal spread occurs in SHS and the liver is the most important site of metastasis (Frey and Betts 1977). In a study by Waters and others (1988), 72% of dogs with SHS had disease confined to the peritoneal cavity. Multicentric haemangiosarcoma has been reported in one case in man. The use of tumour size in designating of the primary site in haemangiosarcoma is complicated by this tumour's propensity to extensive haemorrhage (Waters and others 1988, Bingel and others 1974).

The clinical signs of haemangiosarcoma are vague, depending on the site of the primary or metastatic lesions. In the case of SHS, commonly occurring signs include depression, weakness, anaemia, splenic enlargement, increased pulse and respiration, haemoperitoneum and weight loss (Pulley and Stannard 1978, Pearson and Head 1978, Couto 1989, Brown and others 1985). Gastrointestinal signs are due to mechanical displacement of viscera by a large splenic tumour, while extensive liver metastasis may lead to cachexia, gastrointestinal disorders, nodular hepatomegaly, ascites, icterus and alterations in clotting (Brodey 1964).

The laboratory findings are characterised by mild to severe anaemia with a decrease in haemoglobin, haematocrit and erythrocytic values. Increased number of reticulocytes, nucleated RBCs, polychromasia, poikilocytosis and anisocytosis in some cases indicate a compensatory erythroid hyperplasia (Brodey 1964). Mild to moderate neutrophilic leucocytosis is usually apparent because any stimulus to the erythropoietic marrow affects myeloid elements. Blood in the peritoneal cavity or degenerative changes in the tumour may exert a leukocyte-stimulating effect (Brodey 1964).

Dogs with haemangiosarcoma have a very poor prognosis regardless of the location of the tumour. In a study by Brown and others (1985), 100 of the 104 dogs studied died. Dogs with only primary splenic lesions had a survival period of 151 days, ruptured primary tumours, 107 days and those with metastasis 73 days (Brown and others 1985). The median survival time was found to be 3-4

months (Brown and others 1985, Johnson and others 1989).

4.1.2.2. Splenic haemangioma (SHG)

Haemangioma is also a tumour of endothelial origin. It is usually classified as either cavernous or capillary depending on the size of the vascular spaces (Pulley and Stannard 1978). Either haemangioma type may show thrombosis which is usually followed by fibrosis and scarring thus giving rise to the term sclerosing haemangioma (Nielsen 1983). These tumours, like SHS, are more common in dogs than any other domestic animals but are also found in the cat, horse, cow, sheep and pig. They are usually solitary but they may be multiple and may arise from any tissue of the body. In dogs they usually occur in the dermis, subcutis of leg, flank, neck, face and eyelid (Pulley and Stannard 1978).

The average age of dogs affected is 9 years although the tumour may also develop in younger dogs and congenital haemangiomas have been reported in the foal and calf (Pulley and Stannard 1978).

The clinical signs of SHG are similar to those of SHS including the propensity for haemorrhage. Histological differentiation of the tumours is difficult. Jubb and Kennedy (1970) suggest that the tumour be regarded as benign (SHG) if confined to the spleen and malignant (SHS) if there is evidence of metastasis.

4.1.2.3. Other tumours of the spleen

Leiomyosarcomas and fibrosarcomas are the only non-angiogenic primary sarcomas of the spleen and have a very low incidence (Frey and Betts 1977).

Extraskelatal osteosarcoma has been infrequently reported in humans (Bardet and others 1983). Most of these arise from the connective tissue of the limbs. In dogs extraskelatal osteosarcomas are most often found in mammary and thyroid neoplasia and in oesophageal infection with *Spirocerca lupi* (Jabara and McLeod 1988). Others have been reported in the lungs, liver, jejunum, perianal area and retroperitoneum (Bardet and others 1982). A survival time 3.3 months has been reported by Jabara and McLeod (1988). Smolowitz and Carpenter (1988), found that in a study of 14 dogs with splenic osteosarcoma, the mean age was 12 years, mostly small sized dogs were affected and no sex predilection was seen.

Malignant fibrous histiocytoma (MFH) is an expansile tumour usually involving the extremities and the retroperitoneum. The term MFH was originally used to refer to a group of soft tissue tumours characterised by a storiform or cartwheel-like growth pattern but this tumour is now known to manifest a broad range of histological appearances (Rogers and others 1994). Different theories have been put forward as to the precise cellular origin of the tumour including histiocytes, fibroblasts or primitive mesenchymal cells. Recent *in vitro* work

suggests that MFH is not a tumour of true histiocytes, but of facultative histiocytes showing mesenchymal differentiation (Rogers and others 1994). It may also derive from perivascular mesenchymal cells that retain multipotentiality to differentiate into various cell types. This may explain the great variety of histologic variants of MFH human subtypes; storiform/pleomorphic, myxoid giant cells, inflammatory and angiomatoid (Weinstein and others 1989). No breed, age or sex predilection has been reported in MFH (Weinstein and others 1989) although all the dogs reported in a study by Hendrick and others (1992) were between 9 and 14 years.

With the exception of splenic leiomyosarcoma, the other splenic neoplasms behave like haemangiosarcoma and thus have a short mean survival time irrespective of the tumour stage (Johnson and others 1989, Weinstein and others 1989).

4.2. Generalised splenomegaly

There are four main major categories of diffuse splenomegaly in dogs and cats based on their associated pathogenesis. Splenic enlargement can result from inflammatory changes, lymphoreticular hyperplasia, congestion, or infiltration with normal or abnormal cells (Couto 1990).

4.2.1. Inflammatory splenomegaly

Inflammatory changes in the spleen usually result in localised or diffuse enlargement of the organ. Most disorders associated with splenitis are infectious or granulomatous in nature. Splenitis may be acute, subacute or chronic based on the course of the disease. It can also be classified according to the predominant cells or exudate.

Suppurative splenitis may be either acute, subacute or chronic. When discrete cavitated pus-filled lesions occur, they are referred to as splenic abscesses, as discussed earlier .

Due to splenic torsion and neoplasia, necrotising splenitis may occur. One report is of complete necrosis of the spleen in a Great Dane with splenic torsion and gastric dilation and volvulus (GDV). A pneumoperitoneum was also present due to gas forming bacteria of the *Clostridium* species; *E. coli* *Streptococcus* species also being present (Wong 1981). Coagulation necrosis may be seen in inflammation, e.g. infectious canine hepatitis and with salmonellosis. The presence of intrasplenic gas bubbles on radiographs usually suggests necrosis and emphysema (Hurley and Stone 1994).

Eosinophilic splenitis is mainly observed in conjunction with hypereosinophilic syndrome in cats and eosinophilic gastroenteritis in dogs (Couto 1990).

Lymphoplasmacytic splenitis commonly occurs with subacute or chronic infectious disorders such as infectious canine hepatitis, pyometra, brucellosis,

erlichiosis, babesiosis and haemobartonellosis (Couto 1990).

Granulomatous splenitis occurs in systemic mycoses such as histoplasmosis and some mycobacterium species.

4.2.2. Hyperplastic splenomegaly

The spleen reacts to haematogenous antigens and to RBC destruction with hyperplasia of the reticuloendothelial and lymphoid components. This has been referred to as “work hypertrophy” since it usually results in varying degrees of enlargement (Eichener 1979). Hyperplastic splenomegaly is common in dogs with subacute bacterial endocarditis, systemic lupus erythematosus and chronic bacterial disease.

In humans phagocytosis by the splenic reticuloendothelial cells leads to hyperplasia of this cell population resulting in splenomegaly (Eichener 1979). The same seems to occur in dogs and cats with certain haemolytic disorders including immune-mediated haemolytic anaemia, drug-induced and Heinz body haemolysis, pyruvate kinase deficiency anaemia, familial non-spherocytic haemolysis in Poodles and Beagles (Couto 1990).

4.2.3. Congestive splenomegaly

Feline and canine spleens have a large capacity to store blood and under normal circumstances they store 10-20% of the total blood volume. Tranquillisers and barbiturates increase blood volume by relaxation of the splenic capsule. Pooling of blood in an enlarged spleen may account for up to 30% of the total blood volume (Barton 1981). Anaesthetics such as halothane produce a 10-20% decrease in the haematocrit and plasma protein concentration as a result of splenic pooling (Couto 1990).

Portal hypertension can also lead to congestive splenomegaly. This is however more common in humans than in dogs and cats (Couto 1990). Portal hypertension may be due to congestive heart failure, obstruction of the caudal vena cava by neoplasia or heartworms and intrahepatic obstruction.

Splenic torsion is another common cause of splenomegaly. The condition is frequently seen in large breed, deep-chested dogs, such as Great Dane, German Shepherd dog and Saint Bernard (Hurley and Stone 1994). There is no apparent sex predilection although dogs between the age of 1 and 8 years are frequently affected. Splenic torsion, although usually associated with GDV, may occur independently. The pathogenesis of isolated splenic torsion is unknown although the following possible explanations have been given; repeated episodes of GDV or spontaneous resolution, and partial GDV stretching the gastrosplenic, phrenicosplenic and splenocolic ligaments which loosely suspend the organ, thus predisposing it to torsion (Hurley and Stone 1994). Exercise, rolling or retching further accentuates displacement of the

spleen. The two clinical presentations of splenic torsion are **(a)** acute, usually with abdominal pain and circulatory collapse and **(b)** chronic (or intermittent) with intermittent anorexia, vomiting, abdominal distension, polyuria, weight loss and haemoglobinuria. Physical examination reveals pale mucous membranes, abdominal pain and variably palpable splenomegaly (Stevenson and others 1981). Disseminated intravascular coagulation (DIC) is a common complication of splenic torsion because of the reduced function of the RES in removing the possible initiators of the DIC process from the circulation. An important sequel of torsion is thrombosis, leading to splenic infarction and necrosis. Wong (1981), reported a case of severe splenic necrosis and pneumoperitoneum following torsion in a dog.

4.2.4. Infiltrative splenomegaly

Infiltration of the spleen with neoplastic cells is one of the most common causes of splenomegaly in small animals. The prevalence of lymphosarcoma has been reported to be as high as 24/100,000 dogs (Teske and others 1994). Lymphosarcoma (malignant lymphoma or lymphoma) is a lymphoid neoplasm that originates in solid haematopoietic organs such as lymph nodes, liver or spleen (Couto 1989). According to the anatomical distribution, lymphosarcoma may be classified as, multicentric, alimentary, mediastinal and extranodal in order of decreasing importance in dogs. Eighty percent of cases exhibit the multicentric form (Theilen and Madewell 1987). In the canine patient, older dogs are more frequently affected whereas in cats, there is a bimodal distribution (Hardy 1981). In the dog there is also a breed predisposition, Boxers, Basset hounds, Saint Bernards and Scottish terriers being at increased risk (Couto 1989). The clinical signs and physical findings of lymphosarcoma are variable and are directly related to tumour volume and location (Couto 1989). Other conditions such as systemic mastocytosis invade the haematopoietic system, with splenomegaly being a characteristic feature in dogs and cats (Liska and others 1979).

Section C.

5. Sonography of the spleen

5.1. Sonography of the normal spleen

In dogs, the spleen is easily imaged because it is in a superficial position and lies ventral to the alimentary tract; ultrasound artifacts are therefore infrequently produced. The spleen should be ultrasonographically evaluated for location, size and parenchymal appearance. The head of the spleen may be located lateral to the gastric gas in the left cranial abdomen and traced caudally (Nyland and others 1989). Due to variability of splenic position, scanning may be performed across the midline or along the left ventral abdominal wall in longitudinal and transverse planes (Nyland and others 1989). The splenic contour should be smooth and the size evaluated subjectively. When incident to the ultrasound beam, the splenic capsule is seen as a fine echogenic line that defines the boundaries of the organ (Wood and others 1990). The capsule aids in both the identification of the organ and determination of whether a mass is continuous or merely in contact with the spleen (Lamb 1990).

The splenic substance has a uniformly mottled echogenicity apart from the anechoic lumina of the venous rami which are seen at the hilus but not within the splenic substance (Wood and others 1990), (Figure 2.4). The splenic parenchyma is uniform in appearance with a finer, slightly more dense stromal pattern than the liver. The echogenicity of the spleen is compared to that of the liver and the left kidney thus:

renal cortex echogenicity \leq liver echogenicity \leq splenic echogenicity (Figure 2.5).

5.2. Sonographic appearance of splenic disease

5.2.1. Focal splenic lesions

Focal abnormalities of the spleen are most frequently due to primary and secondary neoplasia. Haematomata, abscesses, infarcts and hyperplastic nodules are identified less frequently due to the inability to differentiate them, sonographically from the neoplastic ones.

Splenic haemangiosarcoma may present as an hypoechoic or complex lesion (Wrigley and others 1988b, Lamb 1990). The sonographic appearance may show many well-defined anechoic areas without encapsulation but acoustic enhancement of the underlying tissues may be evident (Wrigley and others 1988b).

Splenic lymphosarcoma shows predominantly hypoechoic lesions which are poorly margined, or anechoic to hypoechoic lesions with no acoustic enhancement (Wrigley and others 1988a). In most of these cases the splenic parenchyma is hypoechoic compared to the liver parenchyma.

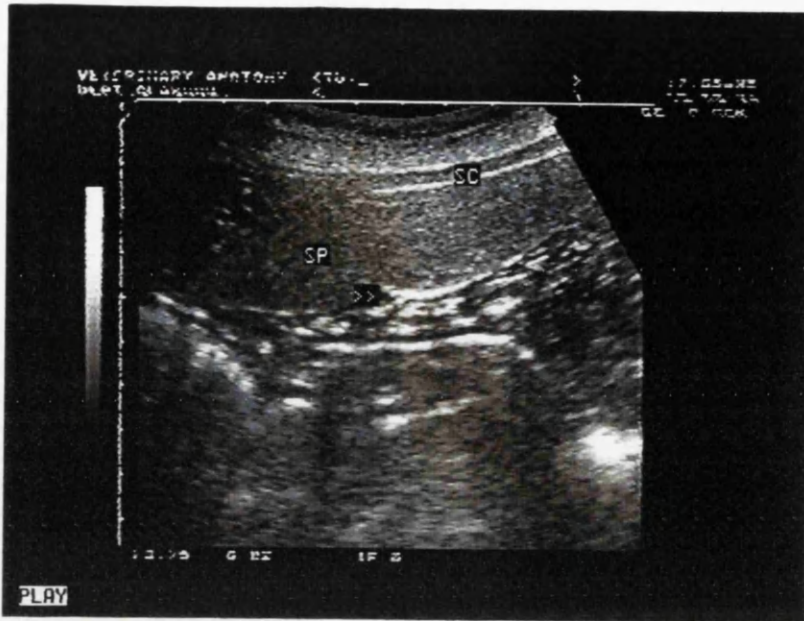


Figure 2.4.
 Ultrasound image of normal spleen (SP) showing the splenic capsule (SC) and vessels (>>).

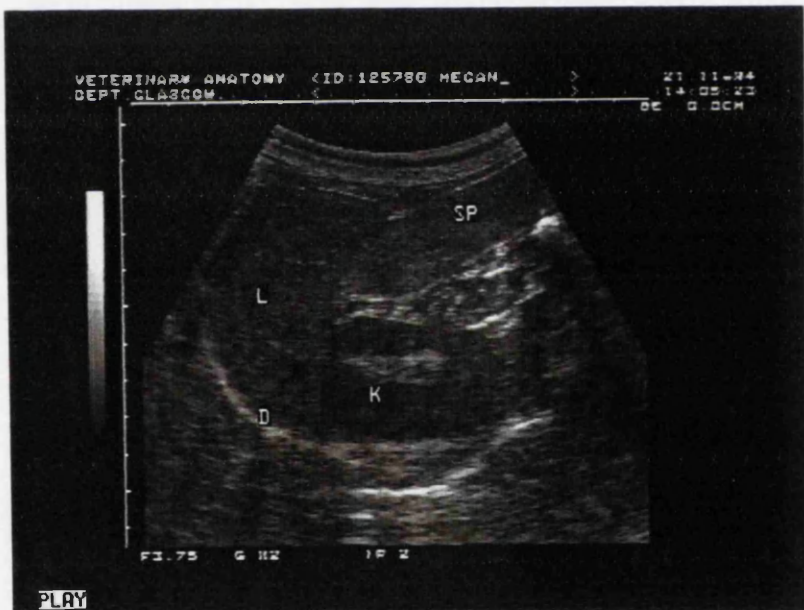

Figure 2.5.
 Ultrasound image showing the difference in echogenicity between liver (L), kidney (K) and spleen (SP). Diaphragm (D) is also shown.

Well circumscribed masses with mixed echo pattern and a distorted splenic capsule have also been documented, Wrigley and others (1988a). Splenic lymphosarcoma has been reported to appear hyperechoic in humans but this has not been reported in the dog (Solbiati and others 1983).

Splenic haematomata show a diverse range of sonographic appearances. They may be seen as well-defined, irregular hypoechoic masses with an anechoic component and a distortion of the splenic contour (Hanson and Penninck 1994). In a report of 10 dogs with haematomata by Wrigley and others (1989), hypoechoic to mixed lesions were found with some showing septation. These haematomata may also show encapsulation, which was also seen in a horse with haematoma where the haematoma showed septation with low echogenicity fluid which appeared to be homogeneous (Spiers and others 1986). In humans, an anechoic area ("double contour" sign) may be seen indicating sub-capsular fluid accumulation (Solbiati and others 1983).

Splenic abscesses present as generally anechoic lesions with good through transmission demonstrated in the underlying tissue. Depending on the maturity of the lesion, irregular walls and internal echoes due to debris may be seen (Solbiati and others 1983, Pawar and others 1982). Abscesses are hyperechoic initially and with time tend to become anechoic, hypoechoic or mixed (Nyland and others 1989). They are usually recognised at the hypoechoic stage with few internal echoes of higher echogenicity.

Splenic infarcts are described ultrasonographically as focal hypoechoic lesions that correlate in appearance to those seen in the acute phase in man (Nyland and Hager 1985). Schelling and others (1988) described the lesions as focal hypoechoic or isoechoic areas, with deformation of the splenic capsule, suggesting nodular masses. In man, the sonographic appearance ranges from hypoechoic, poorly defined areas to well demarcated (echogenic line seen after a few days) wedge-shaped infarct (Yeh and others 1981). Weingarten and others (1984) evaluated patients following splenic artery embolisation for portal hypertension and found the wedge-shaped infarct in two-thirds of the patients with acute disease. Later Maresca and others (1986) showed that an acute infarct may also be manifested as an echo-free area with well defined borders; more rounded infarcts as opposed to wedge-shaped ones, were also found.

The ultrasonographic appearance of splenic nodular hyperplasia is poorly described in the veterinary literature. In one case with splenic and hepatic nodular hyperplasia (Stowater and others 1990), the splenic lesion was described as having a complex echotexture comprising numerous ill-defined hypoechoic foci intermixed with isoechoic to hyperechoic areas. Another clinical report (Hashimoto and others 1991) described a splenic nodule as a well-defined mass with a fine speckled echotexture.

5.2.2. Diffuse splenic lesions

Diffuse abnormalities of the spleen tend to decrease the echogenicity of the organ. This is observed in infiltrative diseases such as lymphosarcoma (Lamb 1990). Most relatively benign conditions, including splenomegaly secondary to passive congestion, anaesthesia or right heart failure and myelofibrosis, may be hypoechoic, while erythropoiesis, reticuloendothelial hyperactivity or congestion appear isoechoic compared to the liver (Mittelstaedt and Partain 1980, Konde and others 1989, Lamb 1990). Diffuse hyperechoic splenomegaly may be seen with brucellosis, tuberculosis, lymphosarcoma and myeloproliferative disorders (Taylor and Milan 1976).

Vascular compromises such as torsion and thrombosis of the splenic veins, and necrosis may cause a decrease in splenic echogenicity. Splenic torsion also causes an overall decrease in echogenicity, with some short linear hypoechoic densities which are thought to represent dilated vessels separating larger anechoic areas (Konde and others 1989, Thomas and others 1991, Hurley and Stone 1994). The splenic hilar vessels are also usually dilated. In splenic torsion, the sonographic appearance is more specific and reliable than the clinical signs (Hurley and Stone 1994).

Normal or decreased echogenicity has been identified in most of the above conditions, but chronic inflammatory or congestive diseases of the spleen in humans may produce an increase in echogenicity (Taylor and Milan 1976, Mittelstaedt and Partain 1980).

Section D.

6. Radiographic interpretation of splenic disease

Radiographic diagnosis of disease of the spleen depends on recognition of alterations in size, shape, contour, margination, location and radiopacity of the organ. Although these abnormalities are not pathognomonic of a single disease, the character of the splenic abnormality can be useful to the clinician. Radiographically, the density of abdominal organs varies with their physical density and thickness. The difference in density (contrast) allows individual viscera to be identified. Gas in the stomach and intestines provides contrast to those organs whereas solid viscera are contrasted by surrounding fat (Kleine 1984).

6.1. Radiography of the normal spleen

The spleen is normally well visualised on abdominal radiographs but there is a wide range of normal variation in appearance. The entire spleen is rarely seen in any projection. Only a cross-sectional silhouette is commonly seen (Root 1974). With the right side dependent, the spleen appears at the caudoventral aspect of the body of the stomach. With left side dependent, the spleen is rarely seen as it is hidden by the intestinal mass. This is because it is attached only by its head and only to the left side of the greater curvature of the stomach (Root 1974).

In the ventrodorsal or dorsoventral projection, the spleen is found in the lateral aspect of the space between the cranial pole of the left kidney and the caudo-lateral aspect of the wall of the greater curvature of the stomach. The length of the gastrosplenic ligament affects the portion of the spleen that is identified (Ackerman and Silverman 1978). If it is short, the stomach and the spleen are in close apposition and the visualised portion is the head of the spleen (dorsal extremity). If it is longer, then the body of the spleen is visualised. The spatial relationship between the stomach, spleen and left kidney is also affected by the degree of gastric distension.

6.2. Radiographic interpretation of splenomegaly

Abdominal abnormalities are often subtle because viscera have inherently low radiographic contrast and some diseases further diminish contrast (Kleine 1984). Margins of the spleen may become obscured or obliterated by fluid accumulation in the abdomen or around the spleen. This loss of visualisation is particularly true in traumatic splenic rupture, with haemorrhage initially accumulating around the spleen; streaky, hazy areas of increased opacity obscure the normally sharp, clearly defined splenic margins (Pechman 1994).

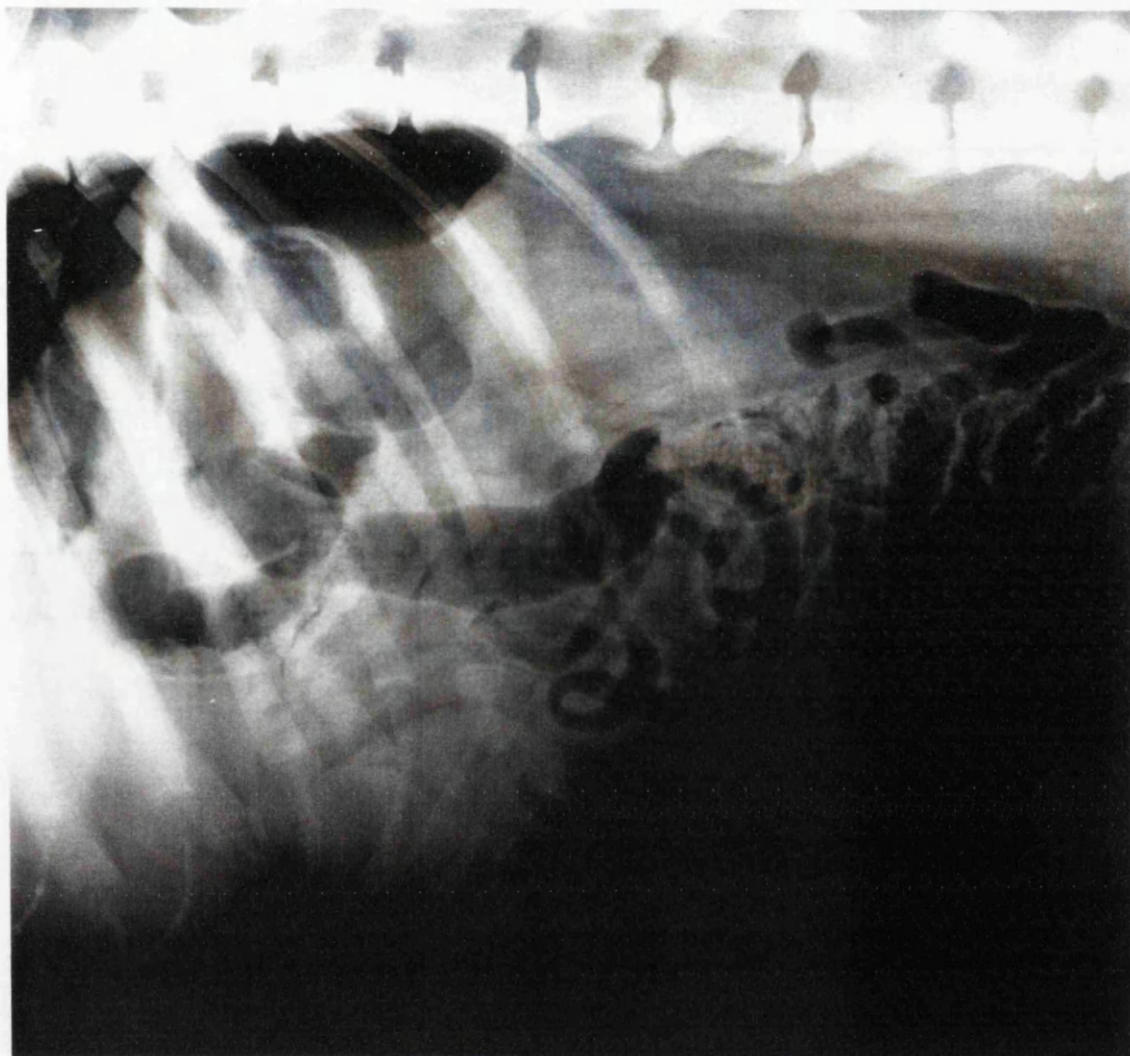


Figure 2.6.
Lateral abdominal radiograph of normal canine abdomen showing the spleen.

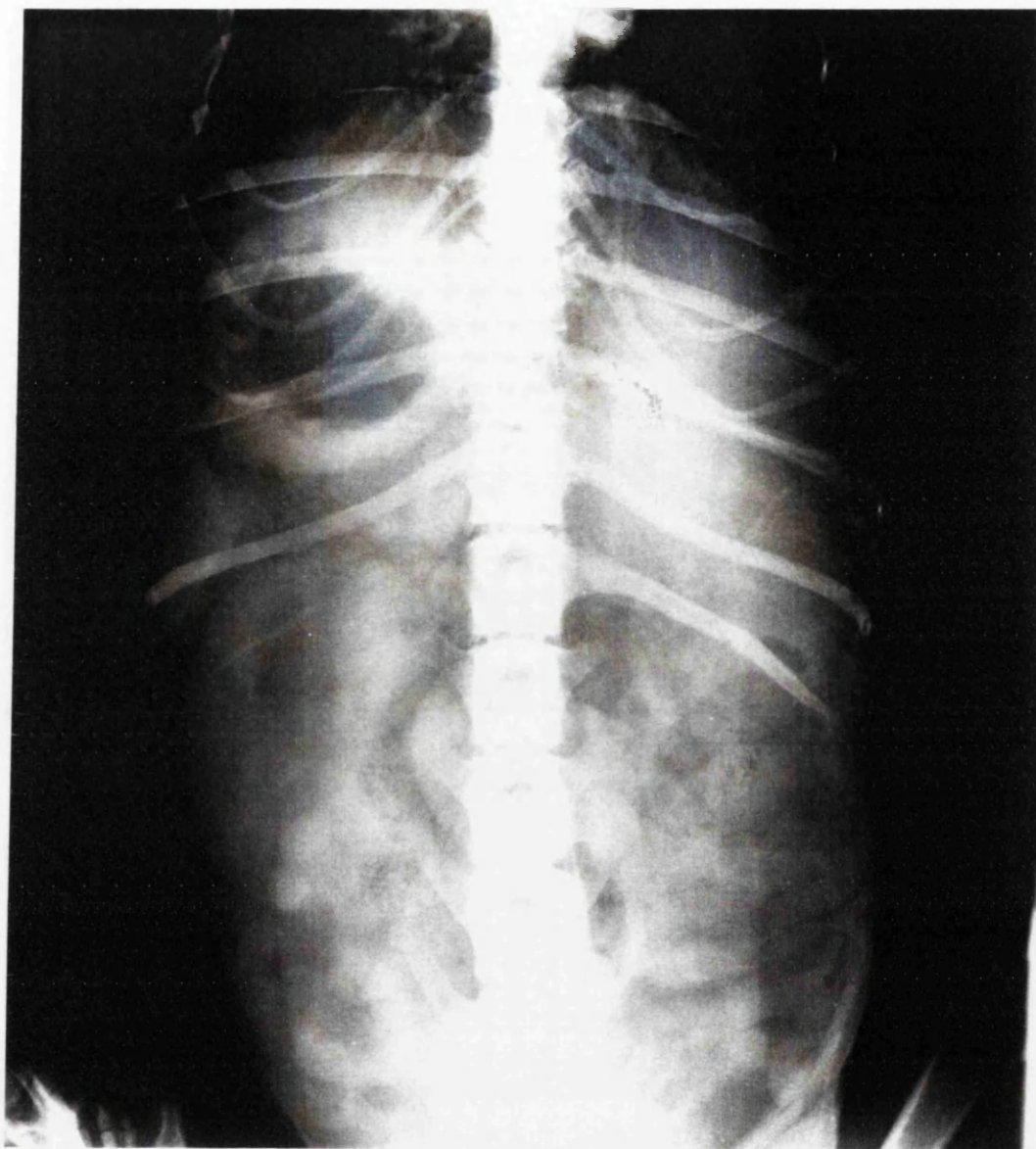


Figure 2.7.
Dorsoventral abdominal radiograph of the normal canine abdomen.

In patients with recent splenic torsion, the caudal displacement of the gastric fundus and the spleen may be diffusely enlarged and C-shaped as a result of rotation about its own pedicle. If the spleen is located between the body wall and the right lateral aspect of the enteric viscera, medial displacement of the descending duodenum and ascending colon is seen (Root 1994). Changes in the radiopacity of the spleen are rare (Suter 1982). Gas accumulation (radiolucent areas) may be associated with splenic torsion and subsequent proliferation of gas-forming organisms.

Focal splenomegaly may be difficult to appreciate radiographically due to the mobility of the body and tail of the spleen. If the head is involved in the disease process, the left kidney may be displaced caudally and medially and the left side of the greater curvature of the stomach may be displaced cranially and medially. In the case of body and tail involvement, the small bowel is often displaced dorsally, cranially, caudally and to the right. The direction of displacement of other organs depends on the degree of enlargement of the spleen or whether or not the entire organ is involved (Kealy 1979).

Diffuse splenomegaly is recognised radiographically by the rounding of the borders of the splenic shadow. Because the spleen is variable in size and position and since its apparent size is greatly influenced by its position, definite limits with respect to size in comparison to other structures cannot be established.

The spleen may be difficult to visualise when the liver is enlarged and its caudal limit is not discernible. However, other signs such as caudal gastric displacement are seen. A mass located caudoventral to the ventral aspect of the stomach, while usually splenic, may be hepatic (Root 1974).

Chapter 3.

Materials and Methods

Eleven of the patients in this study were referred to the small animal hospital of Glasgow University Veterinary School (GUVS) after detection of a palpable abdominal mass or of a soft tissue density on abdominal radiographs, for further investigation, in some cases only for abdominal ultrasonography. The remaining three cases (nos. 10, 13 & 14) were examined at the People's Dispensary for Sick Animals (PDSA), Shamrock Street, Glasgow, to which the ultrasound equipment was taken once a week in order to scan selected cases. Case nos. 1 to 13 were all dogs; case no. 14 was the only feline in the study (Table 5.1).

Ten clinically normal dogs which were scanned following abdominal palpation, served as the control group (Table 5.6).

Scanning technique

Hair was clipped from the ventral midline of the abdomen and a coupling gel (Henleys Medical, Herts, U.K.) applied to facilitate adequate contact between the transducer and the skin. The patients were scanned in a standing position with the transducer held against the ventral abdominal wall. Transverse, sagittal and parasagittal scans were then done in order to visualise the whole length of the spleen. The liver was also scanned to compare its echogenicity with that of the spleen and to check for metastases in cases in which neoplasia was a possibility. No sedation was used for these procedures.

A CAPASEE Linear Scanner (Toshiba Medical Systems Limited, Crawley, U.K.), equipped with a 3.75 MHz curvilinear probe was used to perform the scans. One hepatic scan (case no. 5), was performed with an INTERSPEC-APOGEE Sector Scanner (Advanced Technology Laboratories (ATL), U.K. Limited), using a 3.5 MHz sector probe.

The procedures were performed in a darkened room to allow for easy reading of the images obtained on the screen. The scans were all recorded on video tapes (Fuji, super VHS). Representative photographic prints were made using a colour video printer (Sony) and a video monitor (Panasonic) linked to the INTERSPEC-APOGEE Sector Scanner, in order to be able to adjust the image so as to obtain good quality print.

Radiography

In this study radiography was used as a complementary procedure to ultrasonography. Either dorsoventral, lateral abdominal or both radiographic views were obtained of the cases presented at GUVS. The dogs were sedated for this procedure using a combination of acetylpromazine and buprenorphine.

Blood samples

After each scan, blood samples were collected for routine laboratory tests. Blood for haematology was collected in tubes containing ethylenediamine tetra-acetic acid (EDTA) and that for biochemistry in heparinised tubes.

Pathological samples

In cases where splenectomy or post mortem examination was carried out, a representative sample was taken and placed in buffered neutral formalin prior to processing for histopathological examination. The organ was then photographed prior to freezing. The frozen spleen was later sliced transversely or longitudinally through the lesions and the cut surface wetted to form a smooth ice glaze prior to further photography. In some of the cases, the photographed spleens may appear darker than they were when removed from the animals because of time lapse between removal and examination, post mortem changes and necessary handling prior to initial photography.

In one case (no. 10), a fine needle aspirate was obtained using a 22 gauge needle and a 20 ml hypodermic syringe. The spleen was immobilised with one hand and the needle inserted into the mass, the handle was then pulled back to apply suction, during which time the needle and syringe were moved in several directions. The negative pressure on the plunger was released just before the needle was withdrawn from the organ, in order to prevent suction of the material into the syringe. The needle was detached from the syringe which was then filled with air, this was re-attached to the needle and the contents of the needle were blown gently onto a clean glass microscope slide. The slides were air dried and submitted for cytological examination.

Chapter 4

Case Summaries

Abbreviations

ALT	alanine aminotransferase.
AST	aspartate aminotransferase.
CDRM	chronic degenerative radiculomyelopathy.
EDTA	ethylenediamine tetra-acetic acid.
Hb	haemoglobin.
Hct	haematocrit.
MCH	mean corpuscular haemoglobin.
MCHC	mean corpuscular haemoglobin concentration.
RBC	total red blood cells.
AP	plasma alkaline phosphatase.
WBC	total white blood cells.

Case number 1

Subject. Labrador, 7 years old, neutered female. Weight 30 kg.

History and clinical signs

Abdominal enlargement, palpable cranial abdominal mass, pain on palpation and tachypnoea. The dog had an earlier history of long-standing lameness which was not investigated further.

Laboratory test results¹

Haematology. Reduced platelets ($94 \times 10^9/L$). In addition, the following white cell parameters were reduced: WBC ($4 \times 10^9/L$), lymphocytes ($0.540 \times 10^9/L$) and monocytes ($0.140 \times 10^9/L$).

Biochemistry. The biochemistry results showed very mild reductions in magnesium (0.61 mmol/L), phosphate (0.77 mmol/L) and very slight elevations in albumin (37 g/L) and globulin (36 g/L) but these could not be fully interpreted in relation to the diagnosis.

Tentative clinical diagnosis: cranial abdominal mass, leukopenia and possible thrombocytopenia.

Radiography was not done in this case².

Ultrasonography

A circular mass showing a heteroechogenic (mixed echogenicity) echotexture was seen at the tail of the spleen. The mass was composed of hypoechoic, isoechoic and hyperechoic areas. It measured 10 cm across and was surrounded by a hyperechoic splenic capsule. Normal splenic echotexture was found on the ventral aspect of the mass (Figure 4.1).

The liver was scanned for changes in the echotexture but none were apparent.

Ultrasound diagnosis: splenic neoplasia.

Further examinations/treatment.

A splenectomy was performed and the spleen submitted for histopathological examination.

Pathological examination.

The enlarged spleen had a mass on the caudal aspect, with omental adhesions (Figure 4.2)

Histopathological diagnosis: splenic haemangioma.

Outcome.

The dog made an uneventful recovery.

¹ See Appendices for Haematology and Biochemistry reference ("normal") values.

² Radiography was only done for GUVS cases, PDSA cases and those referred for ultrasonography were not done due to economic reasons.

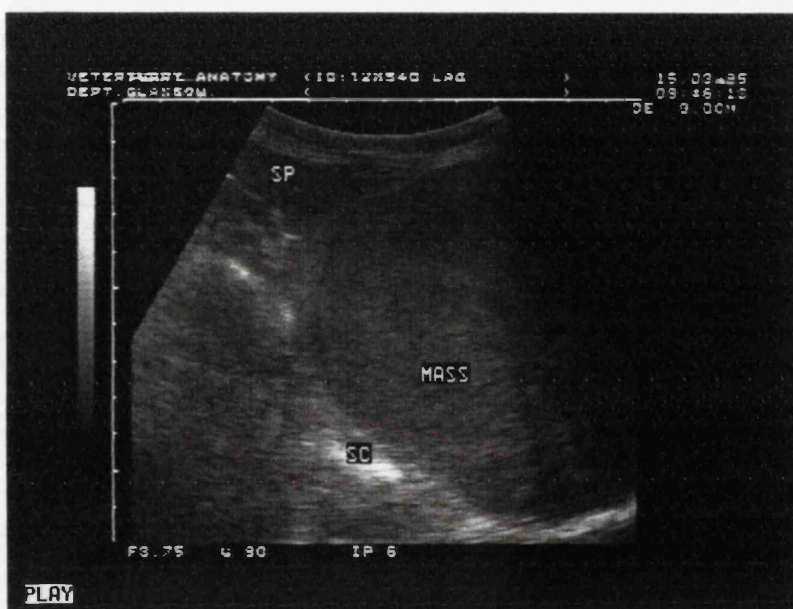

Figure 4.1.

Sagittal splenic ultrasonogram of case no. 1 showing a large mass of mixed echogenicity. Intact splenic capsule (SC) and normal splenic echotexture (SP) can be seen caudal to the mass.

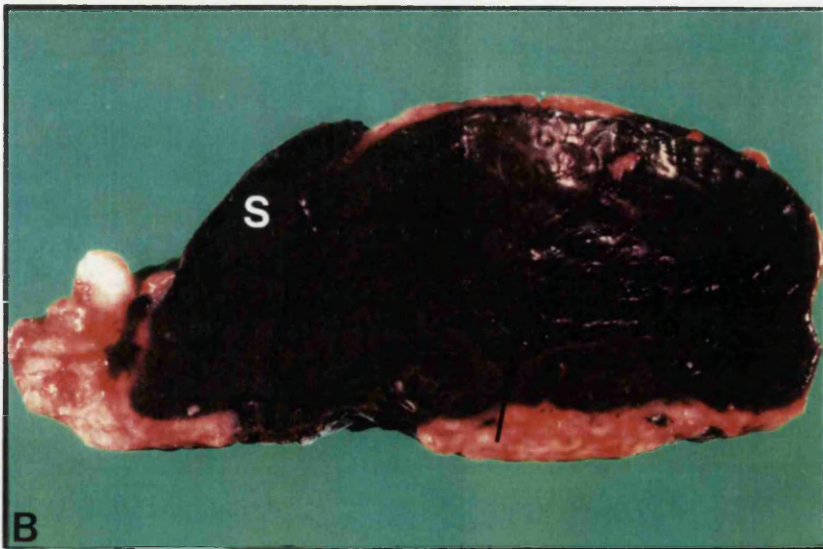
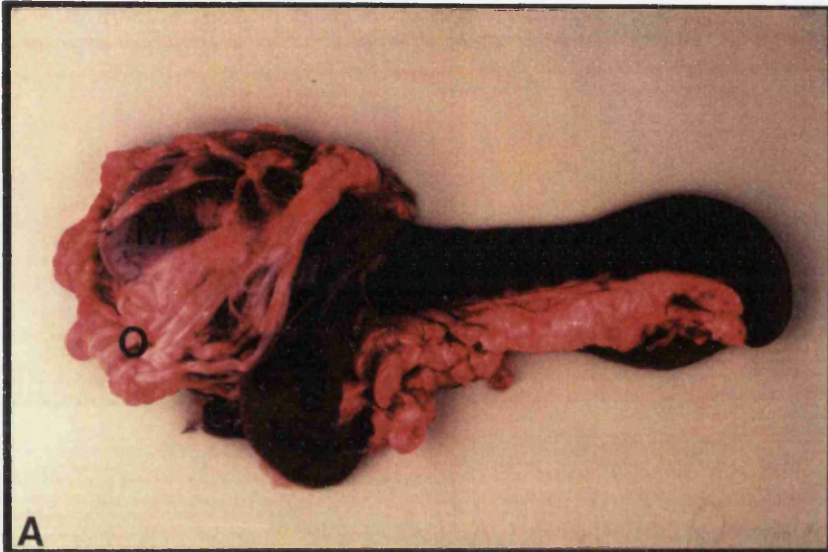


Figure 4.2.

A. Large mass (M) (case no. 1) at the caudal extremity of the spleen with omental (O) adhesions attached to it. **B.** Sagittal section through the splenic mass showing the heterogeneous nature of the mass. Note the dilated blood vessel (arrow). S = normal spleen.

Case number 2

Subject. German Shepherd dog, 6 years old, neutered male. Weight 53 kg.

History and clinical signs

Polydipsia for 2 months, partial anorexia and abdominal enlargement during the last 3 weeks. The dog was tachypnoeic and had a palpable abdominal mass.

Laboratory test results

Haematology. The following red cell parameters were reduced: RBC ($4.04 \times 10^{12}/L$), Hb (8.3 g/dl), Hct (25.4 %) and platelets ($160 \times 10^9/L$). In addition, there was a mild leukocytosis ($19.5 \times 10^9/L$) and mature neutrophilia ($18.135 \times 10^9/L$). The blood picture was regenerative with many schistocytes present.

Abdominocentesis was performed and a bloody peritoneal effusion found. On cytological examination, it contained blood parameters of almost the same values as the blood sample, except for reduced numbers of lymphocytes ($0.784 \times 10^9/L$).

Biochemistry. Only the following parameters were slightly elevated: urea (10.8 mmol/L), glucose (5.7 mmol/L) and AST (62 U/L) but these changes could not be fully interpreted in relation to the diagnosis.

Tentative clinical diagnosis: ruptured haemangiosarcoma with moderate haemorrhagic anaemia.

Radiography

Lateral view: dorsal displacement of the intestinal mass by a soft tissue structure with loss of serosal detail (Figure 4.3).

Radiological diagnosis: cranial abdominal mass with peritoneal effusion.

Ultrasonography

A 9.3 cm circular mass was present at the head of the spleen. It had a mixed echotexture composed of hyperechoic, hypoechoic and anechoic areas. The anechoic areas were well-defined but not encapsulated and showed acoustic enhancement in the distal tissues. The mass was incompletely covered by the splenic capsule. A peritoneal effusion was also present; the fluid was generally anechoic but had some echoes in it (Figure 4.4).

There was no evidence of disruption of the liver echotexture.

Ultrasound diagnosis: haemorrhaging splenic tumour.

Further examination and treatment

An exploratory laparotomy was carried out. Disseminated spread of the tumour to the peritoneum, mesentery and omentum was evident. A haemoperitoneum was also present.

The dog was euthanased on the operating table and submitted for a full post mortem examination.

Pathological examination

A large mass measuring 9.3 cm across, was found at the head of the spleen (Figure 4.5). Dark red masses, 1-2 cm in size, were found on the omentum, mesentery and peritoneum with the haemoperitoneum. No other gross abdominal involvement was found. In the thorax, a 1 cm diameter dark red mass was found, on the right auricle.

Histologically the masses were composed of blood cells with a branching network of cellular septa dividing the masses into vascular spaces. The cells lining the cavities were plump spindle-shaped with hyperchromatic round/oval nuclei.

Histopathological diagnosis: disseminated haemangiosarcoma.

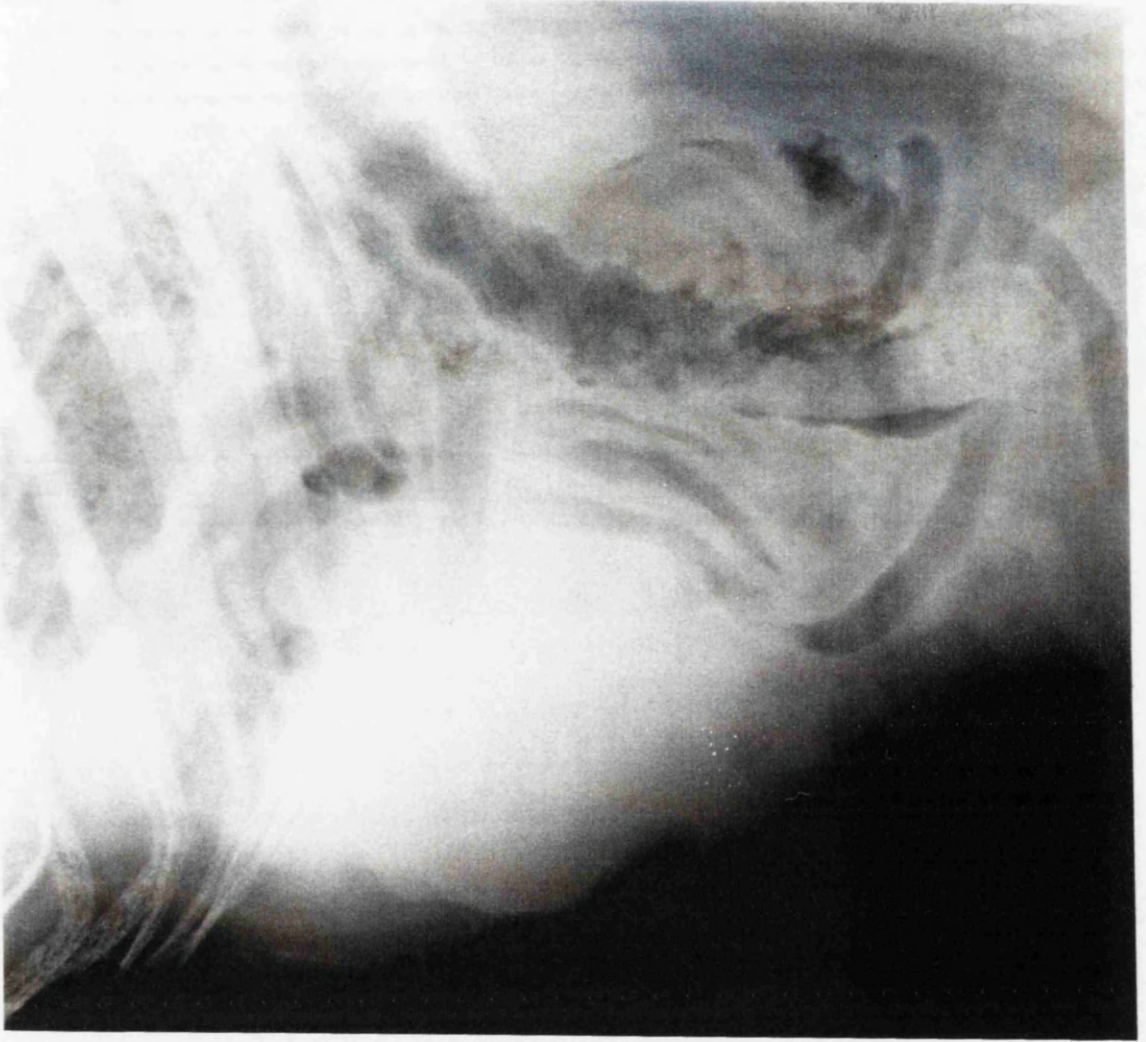


Figure 4.3.

Lateral abdominal radiograph of case no. 2 showing dorsal displacement of intestines by a soft tissue structure. Note the loss of serosal detail.

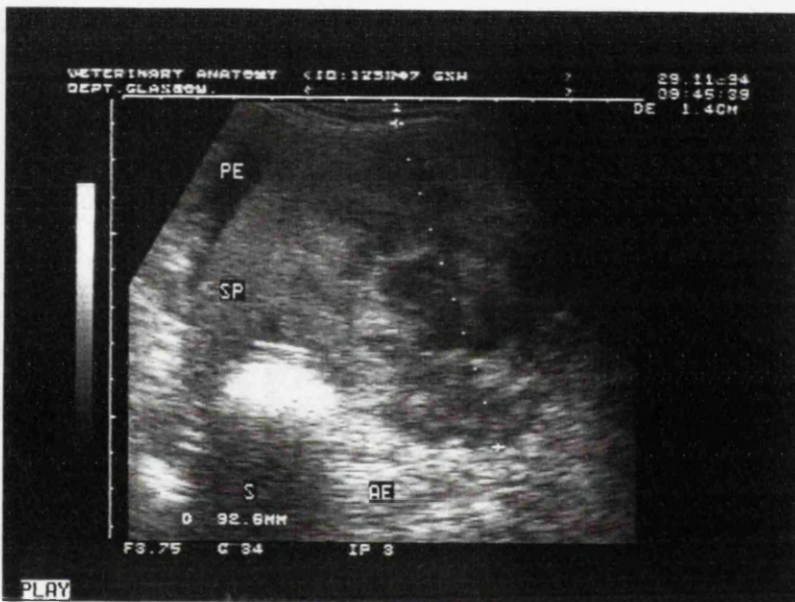

Figure 4.4.

Transverse ultrasonogram of the spleen of case no. 2 showing mass of mixed echogenicity. Anechoic areas seen casting acoustic enhancement (AE) in the deeper tissues. Peritoneal effusion (PE) present and normal splenic echotexture evident (SP).

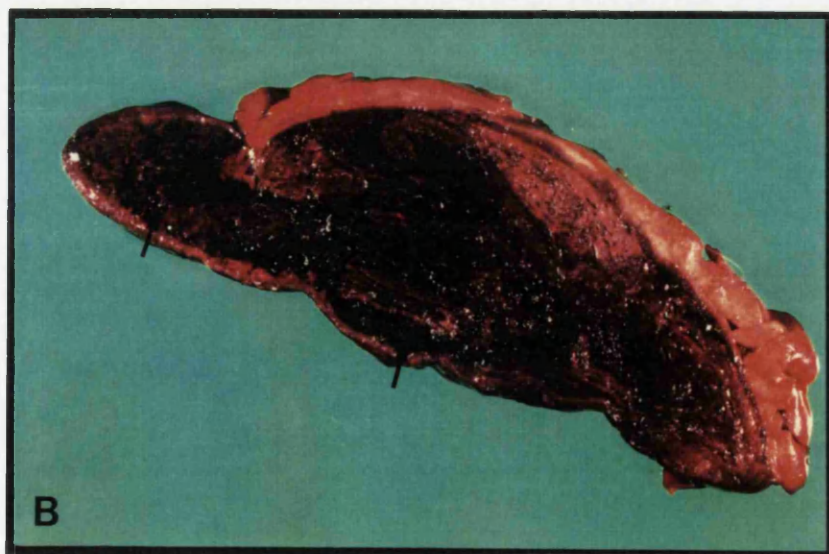
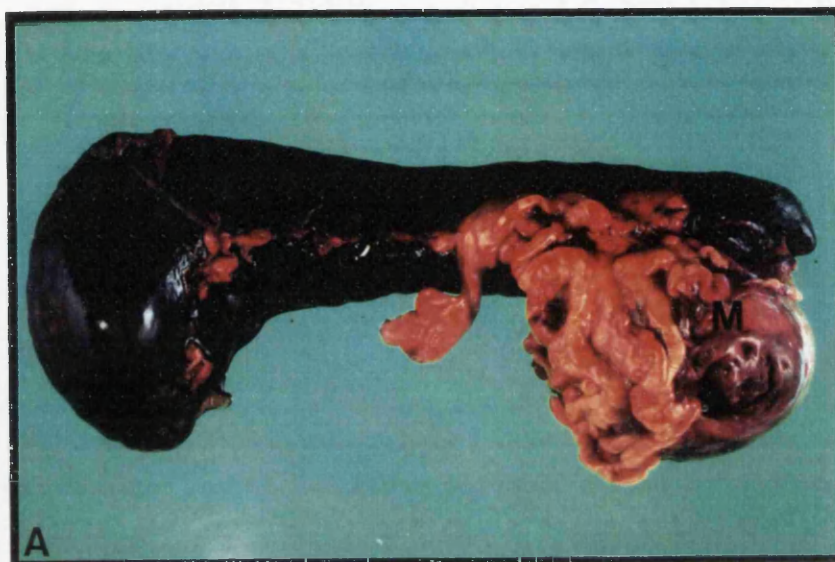


Figure 4.5.

A. Enlarged spleen from case no. 2 with mass (M) at the cranial aspect, omental adhesions and discontinuity of the splenic capsule. **B.** Section of the mass. Blood-filled cavities (arrows) shown interspersed between tissue. Omental adhesions also present.

Case number 3

Subject. Hungarian Vizsla, 7 years old, entire female. Weight 20.5 kg.

History and clinical signs

Short duration coughing and weight loss. The animal was dull and her mucous membranes were dry and congested. The dog showed pain on palpation of the cranial abdomen and a mass could be felt.

Laboratory test results

Haematology. The following red blood cell parameters were reduced: MCHC (31.7 g/dl) and platelets ($168 \times 10^9/L$). In addition, there was elevation of the WBC ($24.4 \times 10^9/L$) and mature neutrophilia ($20.130 \times 10^9/L$). Normoblasts ($0.366 \times 10^9/L$) were also present. A follow-up haematology sample taken 18 days later was very similar with a slight improvement in the platelet count ($187 \times 10^9/L$) and reductions in the WBC ($17.4 \times 10^9/L$) and neutrophils ($14.44 \times 10^9/L$).

Biochemistry. There was a marginal increase in the cholesterol (7.3 mmol/L) and significantly high globulin (47 g/L). A follow up biochemistry profile 13 days later, yielded very similar values.

Tentative clinical diagnosis: palpable abdominal mass, leukocytosis, neutrophilia and hyperglobulinaemia.

Radiography

Radiographs were not taken.

Ultrasonography

A circular mass, 5.3 cm, was visualised at the tail of the spleen. Its contents were echogenic, with strong acoustic enhancement with edge shadowing. The capsule of the mass was hyperechoic with roughening of the dorsal wall and a hyperechoic area was present on the dorso-lateral aspect of the mass (Figure 4.6A). The mass was adjacent to a fluid-filled pylorus.

When re-scanned 13 days later, the mass still showed strong acoustic enhancement with an echogenic wall, and slight roughening of the dorsal wall. The mass was more hypoechoic and had acoustic shadows at its edge. The contents were less echogenic than when previously scanned and the mass had increased in size (6.6 cm). The hyperechoic area was still present on the dorsolateral aspect of the mass (Figure 4.6B).

Ultrasound diagnosis: heterogeneous cystic splenic mass.

Further examination and treatment

The dog was treated with baquiloprim and sulphadimethoxine prior to the exploratory laparotomy. A splenectomy was performed and the spleen submitted for histopathology. The mass contained thick creamy-brown malodorous purulent material. A sample of this was sent for bacteriological examination. *Enterobacter agglomerans* and *Pseudomonas aureofaciens* were isolated from the lesion. Both were sensitive to trimethoprim sulphonamide and

oxytetracycline.

Pathological examination

The spleen was enlarged with omental attachments on either side of the mass showing localised inflammation. Figure 4.7 shows a sagittal section through the splenic mass.

Histopathologically, there was a mixture of fibrous connective tissue, with central areas of necrosis in the white and red pulp. The latter were surrounded by macrophages and few polymorphonuclear cells.

Final diagnosis: splenic abscess adjacent to focus of nodular hyperplasia with a necrotic centre.

Outcome

The dog made an uneventful recovery.

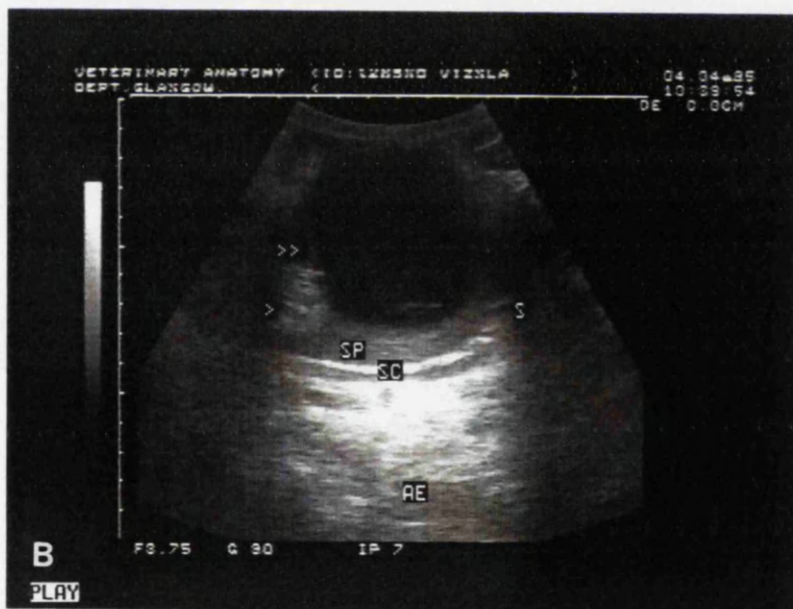
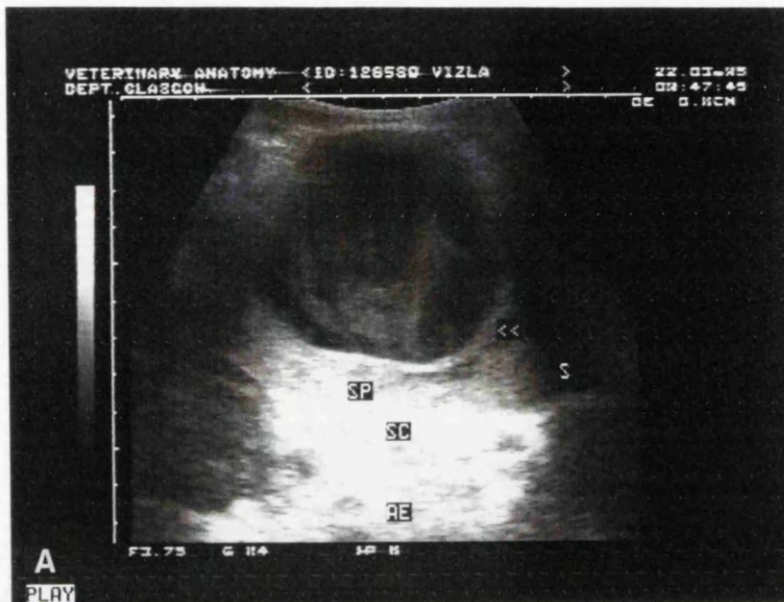
Figure 4.6.

A. Sagittal ultrasound image of the spleen of case no. 3 showing an encapsulated (<<) circular mass with echogenic material on dorsal aspect. Acoustic enhancement (AE) and shadowing (S) also seen. Normal splenic echotexture (SP) also evident in the dorsal aspect of the mass.

B. Thirteen days later, a follow-up ultrasonogram of the mass which appears hypoechogenic with less echogenic contents. Hyperechoic lesion (>) shown on the dorsolateral aspect of mass. Capsule (>>) of the mass and splenic capsule (SC) also shown.

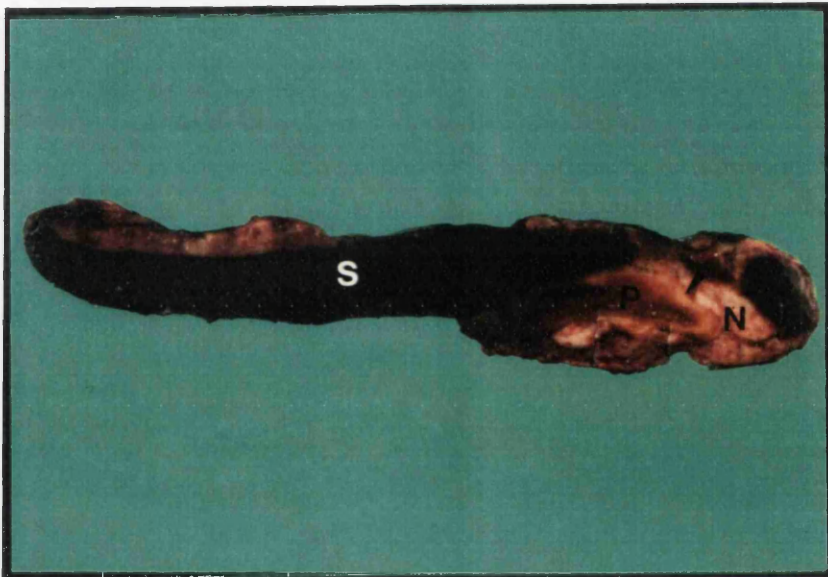


Figure 4.7.

Parasagittal section of spleen (S) from case no. 3. Capsule (arrow head) of the mass shown with purulent contents (P). Area of nodular hyperplasia (N) also visible.

Case number 4

Subject. Cocker Spaniel, 8 years old, entire male. Weight 14.6 kg

History and clinical signs

Recurrent vomiting associated with chronic pancreatitis. The dog was presented with dullness, cranial abdominal pain and was in a collapsed state. The patient was given first aid treatment with intravenous cotrimoxazole and normal saline at twice the maintenance dose. Buprenorphine was also given to relieve pain.

Laboratory test results

Haematology. The platelets were aggregated but apparently adequate in numbers.

Biochemistry. Remarkably high SAP (2229 IU/L), AST (973 IU/L), ALT (349 IU/L), lipase (>13750 IU/L) and amylase (1911 IU/L) and moderately low globulin (24 g/L) were reported.

Tentative clinical diagnosis: chronic pancreatitis.

Radiography

There was no apparent displacement of the organs. A smooth ovoid soft tissue mass situated cranially was recognised as a fluid-filled pylorus (Figure 4.8). Two rounded caudal borders suggestive of liver lobes were seen in the cranioventral abdomen. Mineralisation was present in the intervertebral disc of L1.

Radiographic diagnosis: hepatomegaly, calcified intervertebral discs.

Ultrasonography

Poorly defined small hypoechoic areas were present throughout the splenic parenchyma. Larger hypoechoic masses (approx. 1.5 cm) were also present, resulting in distortion of the splenic capsule. The spleen showed a general decrease in echogenicity and was isoechoic with the liver (Figure 4.9A). The liver showed complete disruption of echotexture with multifocal poorly-defined hypoechoic and hyperechoic areas with distortion of liver margins (Figure 4.9B).

Ultrasound diagnosis: splenic neoplasia with hepatic involvement.

Further examination and treatment

The dog was euthanased on humane grounds and a full post mortem carried out.

Pathological examination.

The spleen showed multiple white masses of up to 2 cm, some of which were umbilicated (Figure 4.10). There was heavy cellular infiltration, with necrosis and congestion. Masses were also evident in the liver and pancreas.

Histopathological diagnosis: pancreatic adenocarcinoma with splenic and hepatic metastasis.

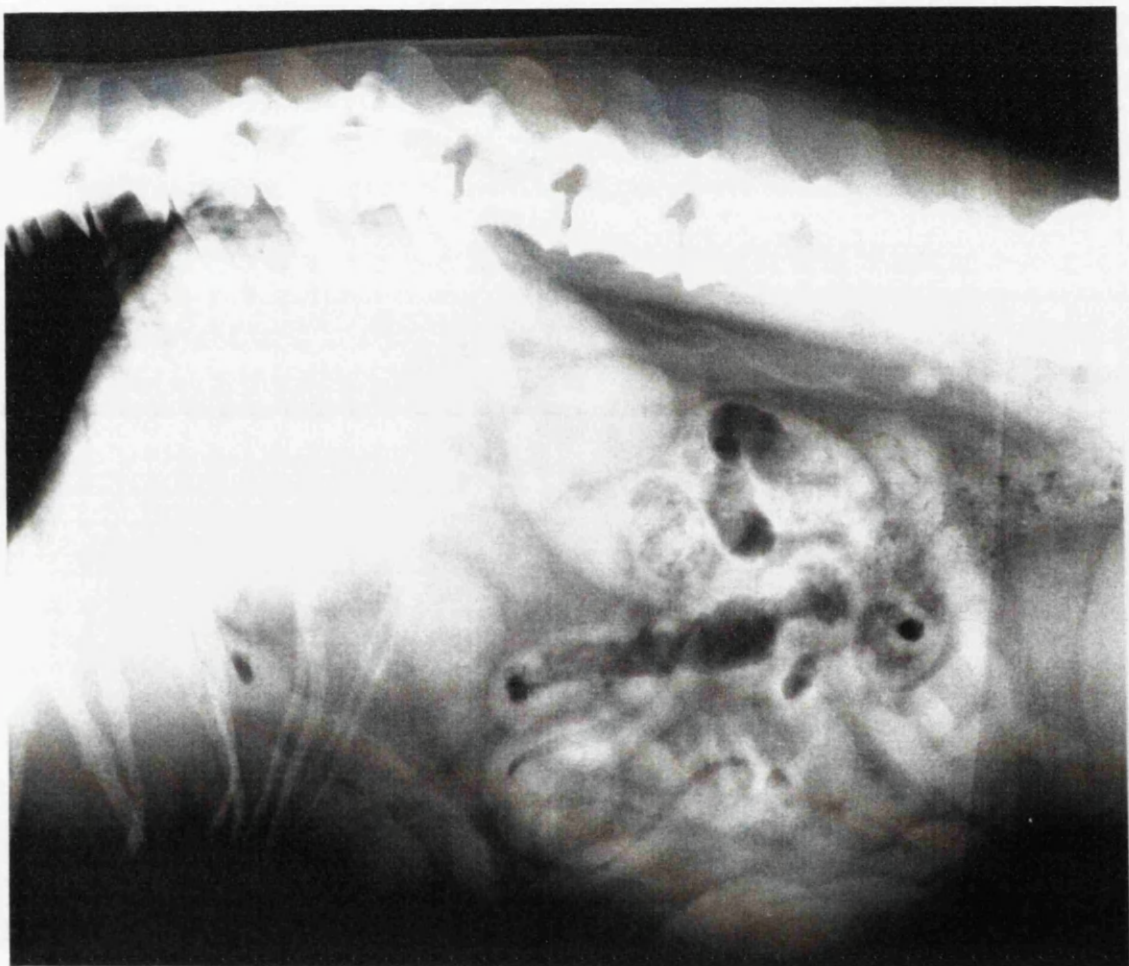


Figure 4.8.

Lateral abdominal radiograph of case no. 4 showing no apparent organ displacement and fluid-filled pylorus.

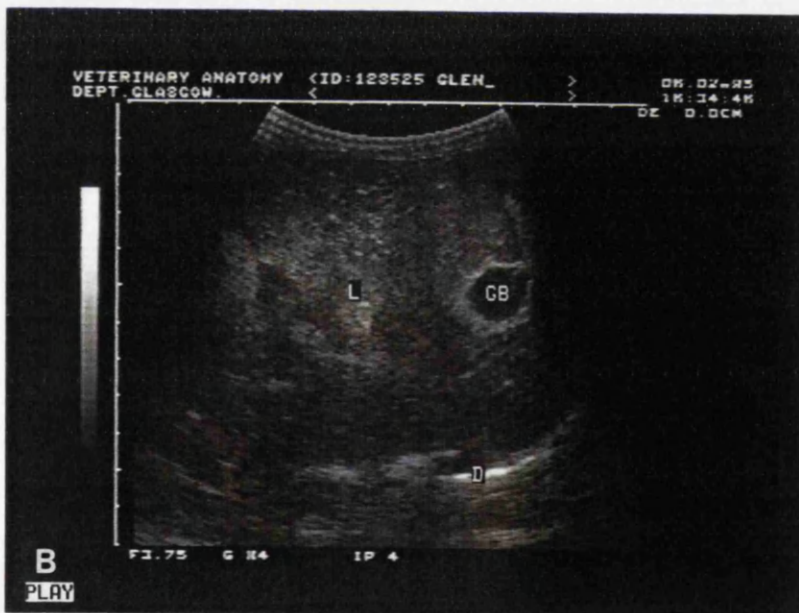
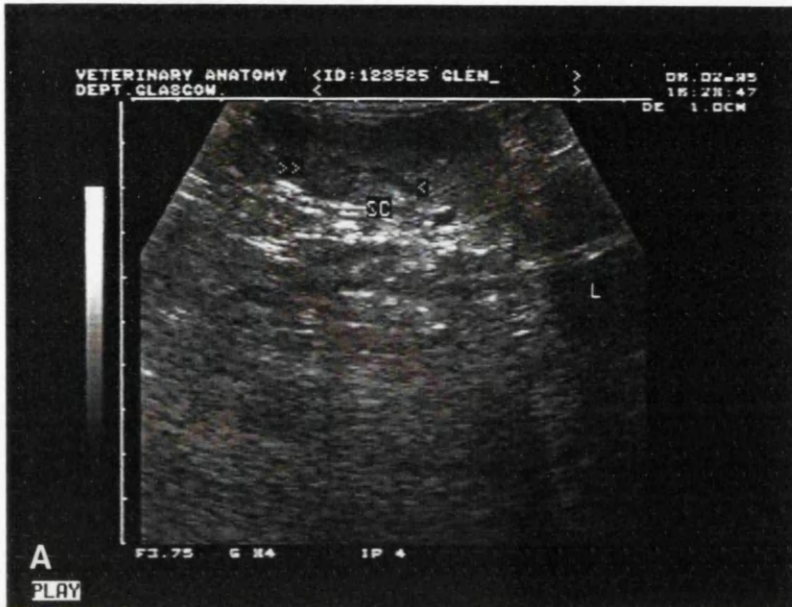
Figure 4.9.

A. Sagittal ultrasound image of spleen of case no. 4 showing multiple hypoechoic areas (>>) and splenic capsule (SC) distortion. A splenic vessel (<) is also shown. Note the similar echogenic appearance of the spleen and the liver (L).

B. Transverse ultrasound image of the liver (L) showing mixed echogenicity with complete loss of normal hepatic architecture and a distorted diaphragm (D). Gall bladder (GB) also shown.

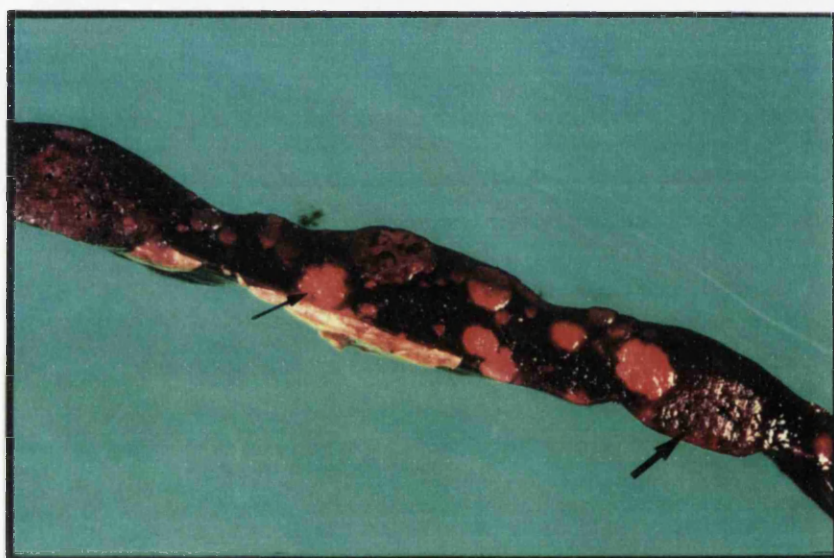

Figure 4.10.

Longitudinal section of the spleen of case no. 4 showing nodules (thin arrow) with larger ones (thick arrow) showing necrosis.

Case number 5

Subject. Crossbred terrier, 10 years old, entire male. Weight 14 kg.

History and clinical signs

Recurrent syncopal episodes for over 4 months. The oral and ocular mucous membranes were pale. Abdominal distension was very marked and the dog resented abdominal palpation. A large abdominal mass was palpated.

Laboratory test results

Haematology. The blood sample showed auto-agglutination on the walls of the EDTA tube, and the blood later clotted.

Biochemistry. Marked increases in total protein (113 g/L) and globulin (89 g/L).

Tentative clinical diagnosis: large abdominal mass, probably neoplasia with hyperproteinaemia and hyperglobulinaemia.

Radiography

Radiographs were not done.

Ultrasonography

A large mass measuring 11 cm was found and there was an absence of normal splenic echotexture. The mass was made up of a mixed echo-pattern: some areas well-defined and hypoechoic. However, most of the mass was largely isoechoic with few hyperechoic areas (Figure 4.11A).

The liver showed hyperechoic areas (Figure 4.11B).

Ultrasound diagnosis: splenic and liver neoplasia.

Further examination and treatment

An exploratory laparotomy was performed by the referring veterinary surgeon. The liver appeared normal on gross examination while the spleen was removed and submitted for histopathological examination.

Pathological examination

A large solid mass occupied most of the splenic substance. The omentum was adherent to the mass and extremely dilated splenic vessels were present (Figure 4.12).

Histologically, the red and white pulp were very congested and disorganised, consistent with hyperplastic nodular hyperplasia. The white pulp was composed of sheets of lymphocytes with few mitotic figures.

Histopathological diagnosis: splenic nodular hyperplasia.

Outcome

The dog died a few hours after the operation. Apart for some free blood in the abdominal cavity, there were no other significant findings. A full post mortem was not carried out.

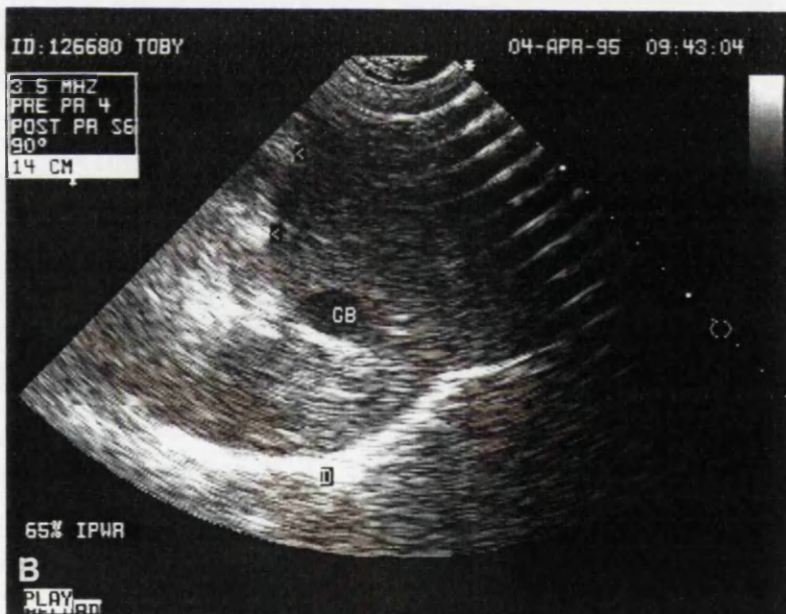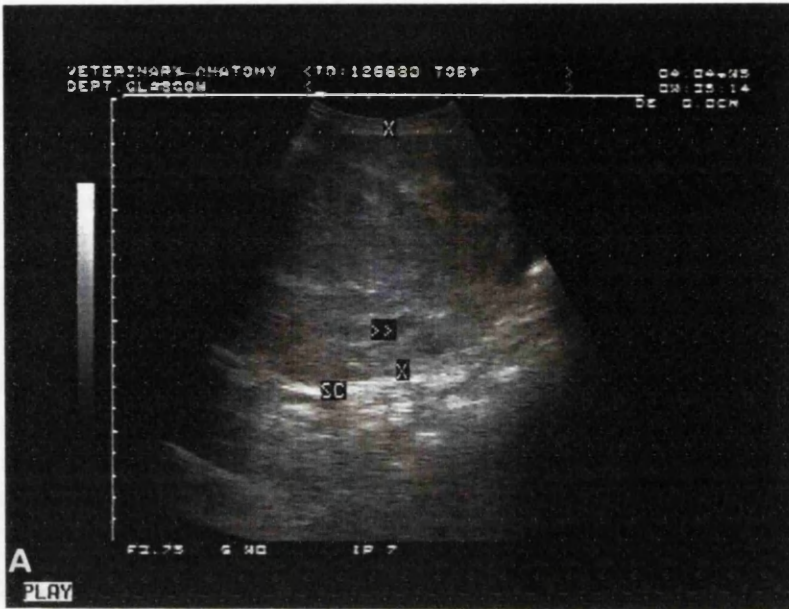


Figure 4.11.

A. Ultrasonogram of spleen of case no. 5 showing large mass (dorsoventral borders marked by "X") with mixed echogenicity. Mass surrounded by echogenic splenic capsule (SC) and dilated blood vessels (>>) also visible. Poor contact due to massive abdominal enlargement produced peripheral shadows.

B. Transverse ultrasonogram of the liver of case no. 5 showing hyperechoic poorly-defined masses (<). The gall bladder (GB) and the diaphragm (D) are also shown.

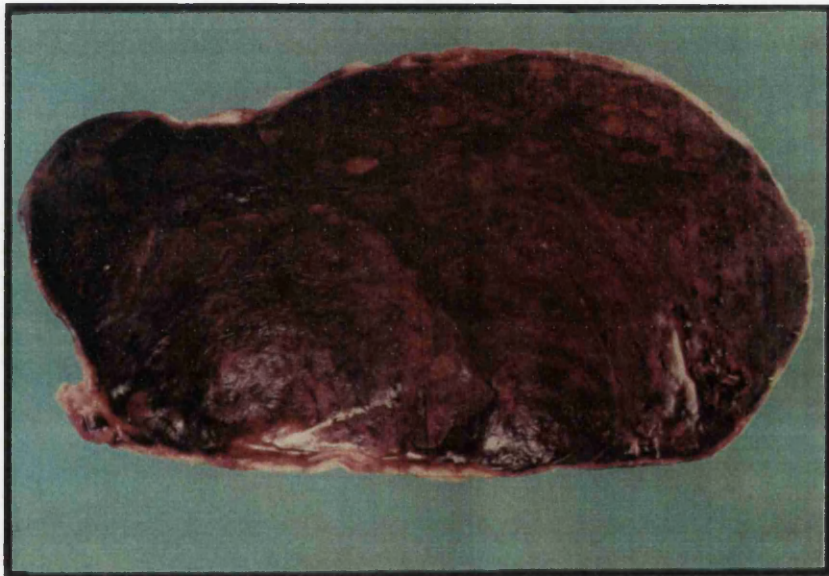


Figure 4.12.

Transverse section of the splenic mass of case no. 5 showing its heterogeneous nature.

Case number 6

Subject. Crossbred German Shepherd dog, 10 years old, neutered male. Weight 36 kg.

History and clinical signs

Chronic vomiting, weight loss, urinary incontinence, partial anorexia, polydipsia and polyuria of 3 weeks duration. On examination, he was dull, hyperpnoeic and resented abdominal palpation. Prolapse of the rectum was also present.

Laboratory test results

Haematology. Slight leukocytosis ($17.2 \times 10^9/L$) and neutrophilia ($14.964 \times 10^9/L$) were present with slightly reduced lymphocytes ($0.602 \times 10^9/l$). Platelets were aggregated but there were apparently adequate numbers.

Biochemistry. Calcium levels were significantly raised (4.64 mmol/L).

Tentative clinical diagnosis: neoplasia with paraneoplastic hypercalcaemia.

Radiography

The lateral thoracic radiograph showed numerous bony lesions and multiple punctate lucencies which were present in the spinous process of T5. The middle third of the third rib had a mottled density with new bone around the right shoulder joint, consistent with degenerative joint disease.

A large soft tissue mass was seen in the cranial abdomen and mineralised material was observed on the ventral aspect of the liver (Figure 4.13).

Radiographic diagnosis: soft tissue mass with gall bladder mineralisation and spondylosis. Multiple myeloma suspected due to the bone changes.

Ultrasonography

The spleen was enlarged and had poorly-defined hypoechoic areas throughout its substance. Two irregularly shaped areas were present at both poles of the spleen; these were hypoechoic, 2 cm wide and extended across the organ. Splenic margins were distorted (Figure 4.14A).

The liver echotexture was completely disrupted. The gall bladder appeared distended and contained echogenic material. A hyperechoic structure in the gall bladder had an acoustic shadow. The liver had a mixed echotexture, some isoechoic lesions had an echolucent ring around them. Normal hepatic vasculature was not recognisable (Figure 4.14B).

Ultrasound diagnosis: splenic and hepatic neoplasia with evidence suggestive of gall bladder calculi.

Further examination and treatment

The dog was euthanased due to poor prognosis and a full post mortem carried out.

Pathological examination

Tumour deposits were widespread throughout the body. Multiple firm, white, umbilicated nodules of up to 2 cm were found in all the liver lobes. The spleen

showed many smaller (2 mm) nodules and infarcts were also present (Figure 4.15A & B). In the kidneys similar tiny foci were found together with infarcts. Vegetative endocarditis was present in the aortic valve cusps. Masses were present in the long bones, with damage to the vertebrae especially the lumbar spine. A small white plaque-like mass was found on the left anal sac.

Histologically, the primary tumour was found to originate from the anal sac where, in addition to normal apocrine sweat glands, large pleomorphic cells with hyperchromatic nuclei and aberrant mitosis were found.

Histopathological diagnosis: Apocrine adenocarcinoma of the anal sac.

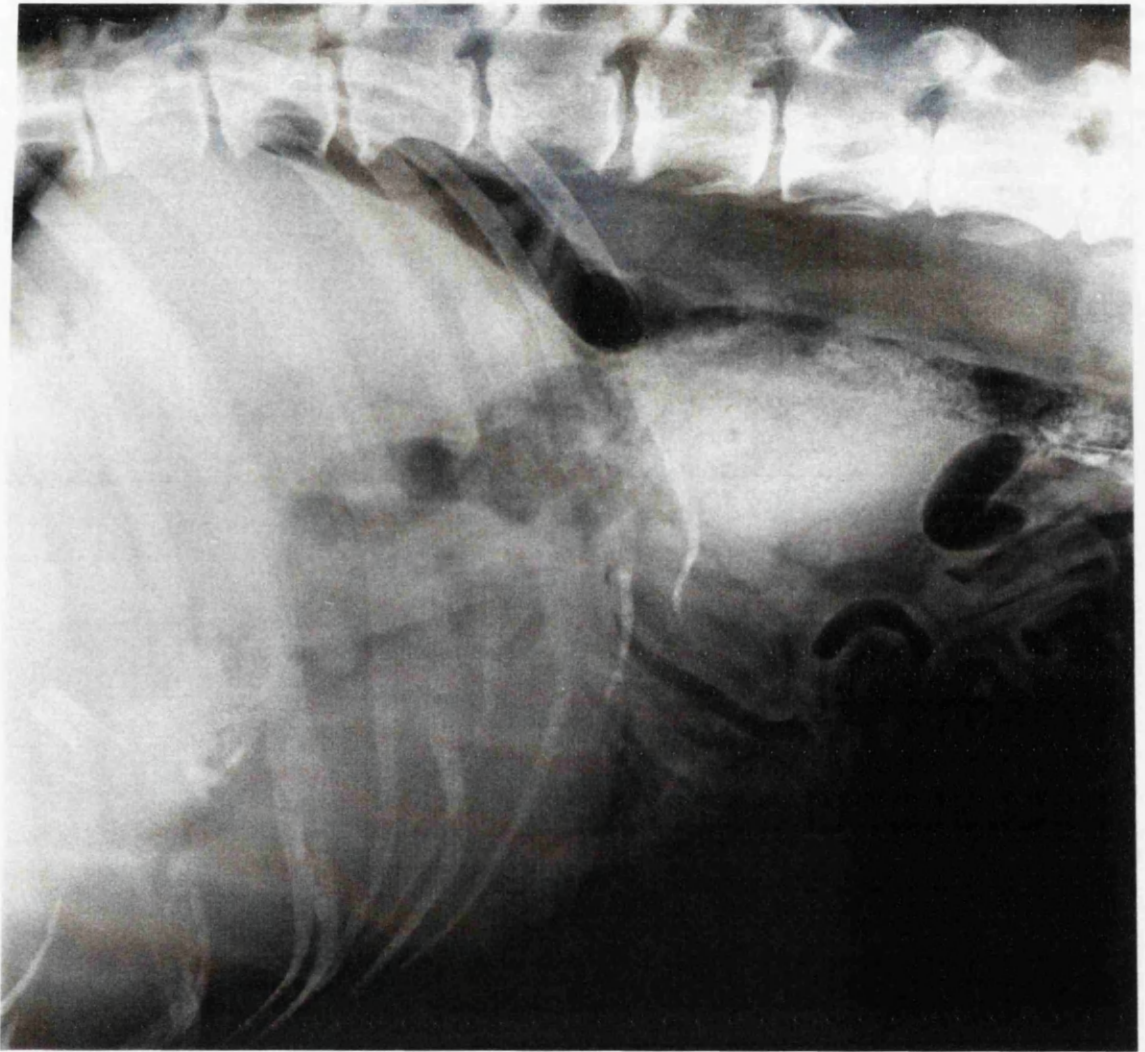


Figure 4.13.

Lateral abdominal radiograph of case no. 6 showing a large soft tissue mass in the cranial abdomen.

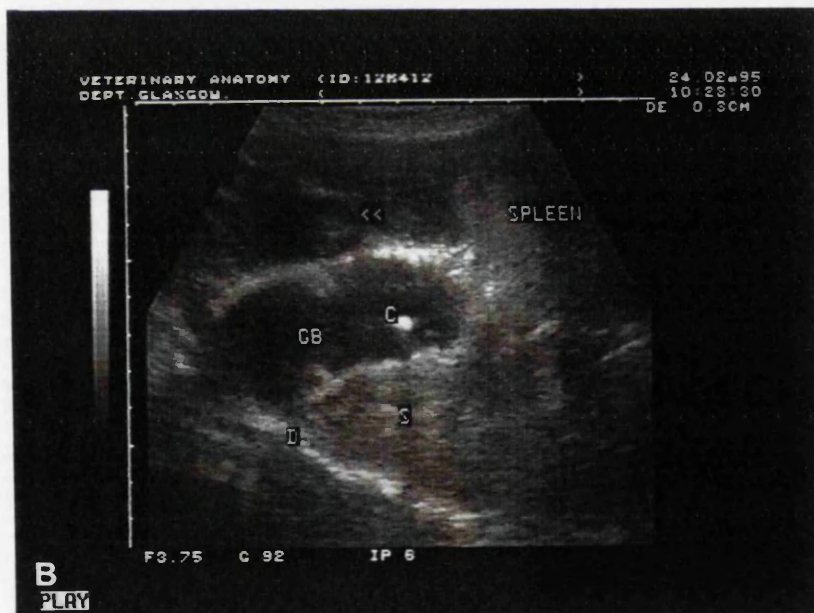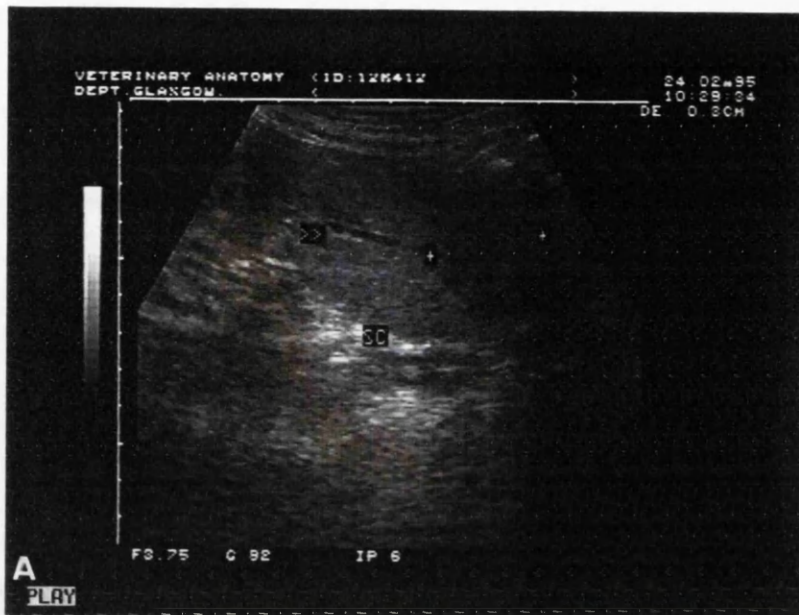


Figure 4.14.

A. Parasagittal ultrasound image of the spleen of case no. 6 showing hypoechoic masses of various sizes. Larger mass (width marked with "+" sign) traversing the width of the spleen. Splenic capsule (SC) and a dilated blood vessel (>>) also shown.

B. Sagittal ultrasound image of the liver showing complete distortion of the echotexture. Note the hypoechoic lesion with an anechoic rim (<<). Hyperechoic calculi (C) with a shadow distal to it can be seen in an irregular gall bladder (GB). An irregular diaphragm (D) is also shown.

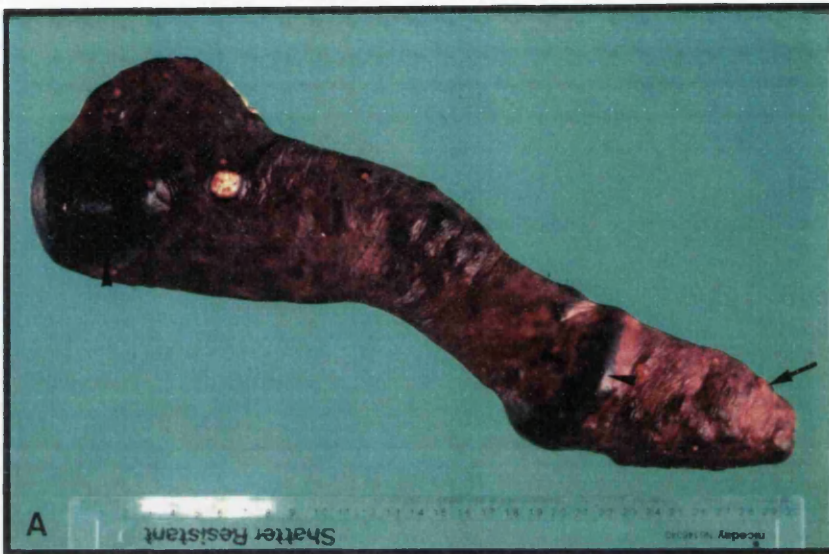


Figure 4.15.

A. Enlarged spleen from case no. 6 with irregular surface shown. Note the large infarcts (arrow heads) and smaller white tumour nodules (arrows). **B.** Transverse section of the spleen showing the infarcted areas (thick arrow) and nodules (long arrow). Dilated blood vessel (white arrow) also shown.

Case number 7

Subject. German Shepherd dog, 11 years, neutered female. Weight 38 kg.

History and clinical signs

Initially referred with CDRM. This was treated with prednisolone and some improvement was seen. However the dog developed a chronic colitis for which a course of metronidazole at 200 mg/kg twice daily was prescribed. Several months later, the dog showed increased reluctance to rise, weight loss, anorexia, dullness and lethargy. She had pale membranes with a bounding pulse. On abdominal palpation, there was cranial abdominal tenderness and a fluid wave was felt on ballotment.

Laboratory test results

Haematology. The following red cell parameters were reduced: RBC ($4.18 \times 10^{12}/L$), Hb (8.8 g/dl), Hct (28.7%), MCHC (30.6 g/dl), and platelets ($98 \times 10^9/L$). In addition, there was a mild leukocytosis ($20.1 \times 10^9/L$) and neutrophilia ($17.487 \times 10^9/L$). A regenerative blood picture was seen with normoblasts and schistocytes present.

Biochemistry. A slightly increased level of ALT (70 U/L) and mildly reduced globulin (26 g/L) were present but no conclusions could be drawn as to their significance.

Tentative clinical diagnosis: possible neoplasia with peritoneal effusion, regenerative anaemia and thrombocytopenia.

Radiography

Despite movement blurs on both the lateral and dorsoventral views, a soft-tissue density mass was seen in the left cranial abdomen with lateral and caudal displacement of the intestinal mass on the dorsoventral view. On the lateral view, there was poor contrast due to the lack of body fat but despite this, there was evidence of caudal displacement of the intestines in the mid cranial region. Radiograph not reproduced due to poor quality.

Radiographic diagnosis: cranial abdominal mass.

Ultrasonography

A well-defined mass measuring 6 cm was present at the tail of the spleen. It had a mixed echogenicity made up of isoechoic, anechoic, hypoechoic and some hyperechoic areas. The mass cast strong acoustic enhancement in the distal tissues. The margins of the mass were irregular and there was no discernible capsule. A peritoneal effusion with few echoes was present (Figure 4.16). The liver was difficult to assess because of the presence of gas within the stomach.

Ultrasound diagnosis: haemorrhaging splenic tumour.

Further examination and treatment

A guarded prognosis was given and the owner requested euthanasia. A full post mortem examination was carried out.

Pathological examination

A large amount of free blood was found in the abdominal cavity. On the tail of the spleen, there was a dark red irregularly shaped mass approximately 6 cm in diameter (Figure 4.17 A & B). The liver also contained some small dark masses.

Histopathological diagnosis: splenic haemangiosarcoma.

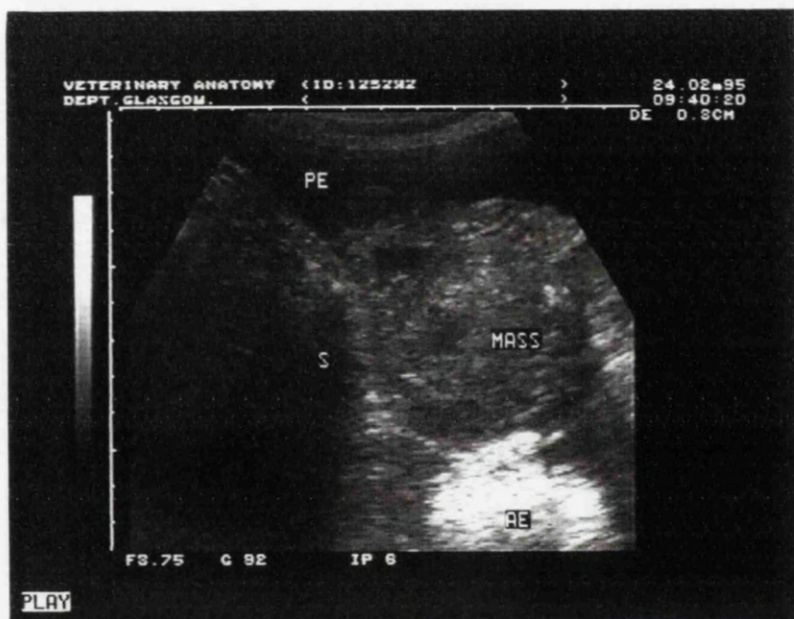

Figure 4.16.

Transverse ultrasonogram of the splenic mass in case no. 7 with mixed echogenicity. Acoustic enhancement (AE) and peritoneal effusion (PE) also shown. Note shadow (S) from intestinal gas.

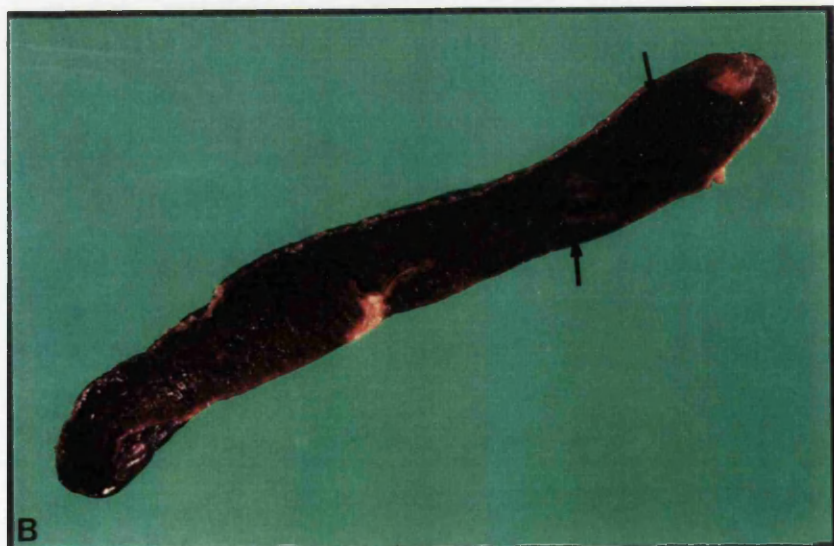
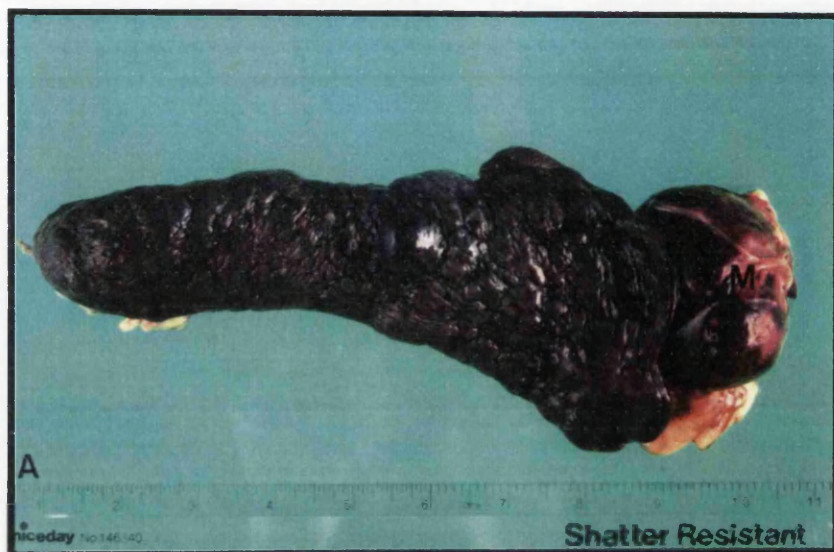

Figure 4.17.

A. Enlarged spleen from case no. 7 with mass (M) at caudal pole. Mass shows irregular surface and omental adhesions. **B.** Longitudinal section of the spleen showing a blood filled mass (arrows) at the caudal pole.

Case number 8

Subject. German Shepherd dog, 7.5 years old, female neuter. Weight 22 kg.

History and clinical signs

Weight loss, generalised lymphadenopathy, polyphagia and vomiting. On clinical examination, the dog was pyrexia (40°C), tachypnoeic, slightly cyanotic and had palpable organomegaly in the cranial abdomen.

Laboratory test results

Haematology. Reduced WBC ($5.5 \times 10^9/\text{L}$) with mild leukopenia and severe neutropenia ($0.88 \times 10^9/\text{L}$) were reported. Although the platelets were aggregated, their numbers appeared normal.

Biochemistry. Slightly increased levels of urea (9.6 mmol/L), glucose (5.3 mmol/L) and chloride (115 mmol/L) were present. These could not be fully interpreted in relation to the diagnosis.

Tentative clinical diagnosis: possible lymphoid neoplasia with severe neutropenia.

Radlography

A lateral view, revealed a soft tissue mass in the cranial abdomen with caudal displacement of the intestinal mass. A gas-filled stomach and mineral densities throughout the gastrointestinal tract were also seen (Figure 4.18).

Radiological diagnosis: cranial abdominal mass.

Ultrasonography

There was an overall decrease in echogenicity of the spleen when compared to that of the liver, with multi-focal well-defined hypoechoic (almost anechoic) areas, giving the organ a "punched out" or Swiss cheese appearance, with distortion of the splenic margins. The size of the lesions was variable but most were less than 1 cm. There was no acoustic enhancement in the underlying structures (Figure 4.19). The liver echotexture appeared normal.

Ultrasound diagnosis: diffuse splenic neoplasia.

Further examination and treatment

A submandibular lymph node was biopsied using fine needle aspiration and the sample submitted for histopathological examination. A combination chemotherapeutic regime using cyclophosphamide, vincristine and prednisolone was instituted. The dog was on the treatment for approximately 3 months after which time the owner became non-compliant.

Pathological examination

Sheets of large lymphoblasts with prominent nucleoli and basophilic cytoplasm were seen on the smear.

Cytological diagnosis: multicentric lymphosarcoma.

Outcome

The dog's health deteriorated 4 weeks after discharge from GUVS but thereafter the owner could not be contacted.

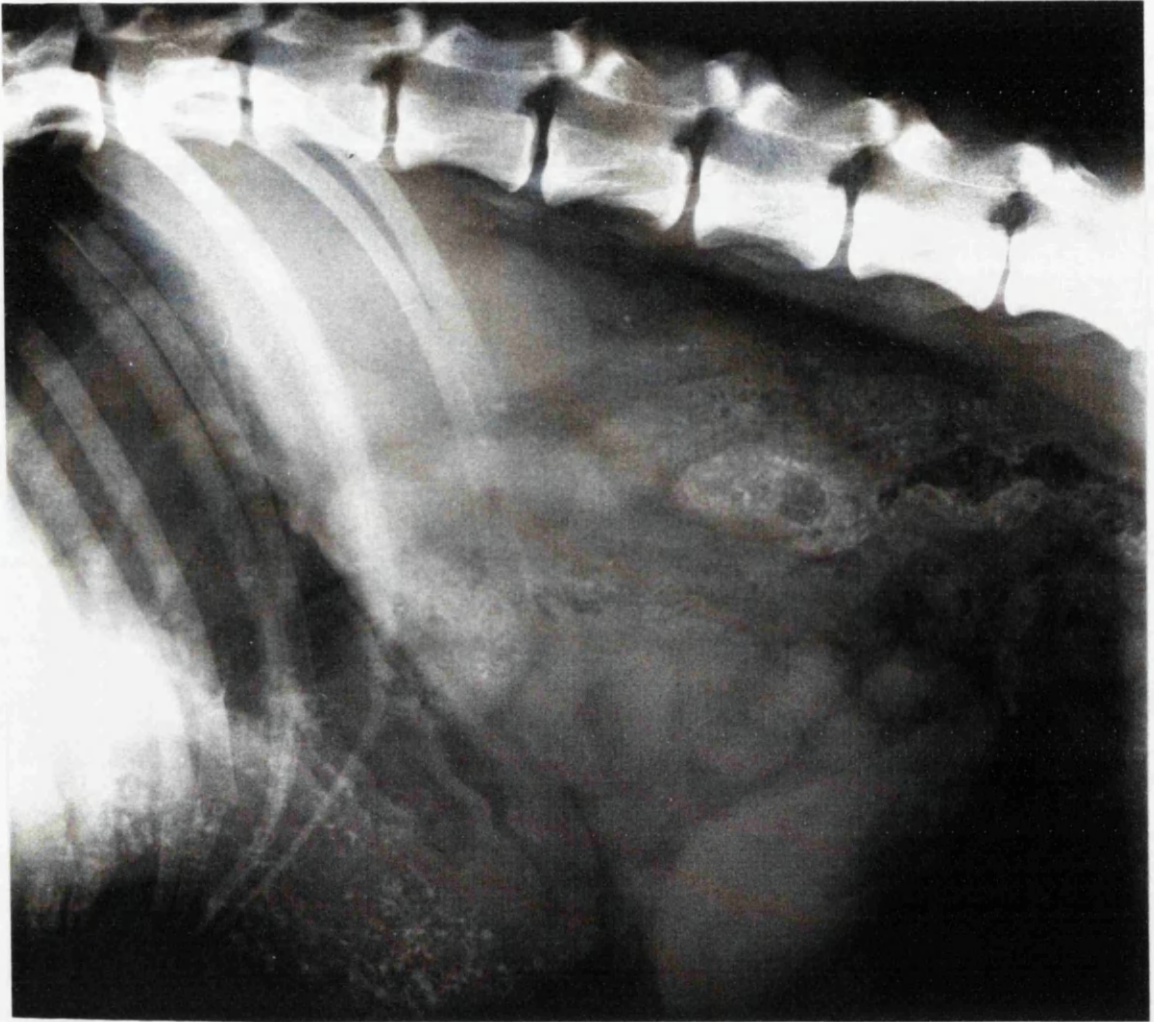


Figure 4.18.

Lateral abdominal radiograph of the abdomen of case no. 8 showing enlarged spleen and liver shadow.

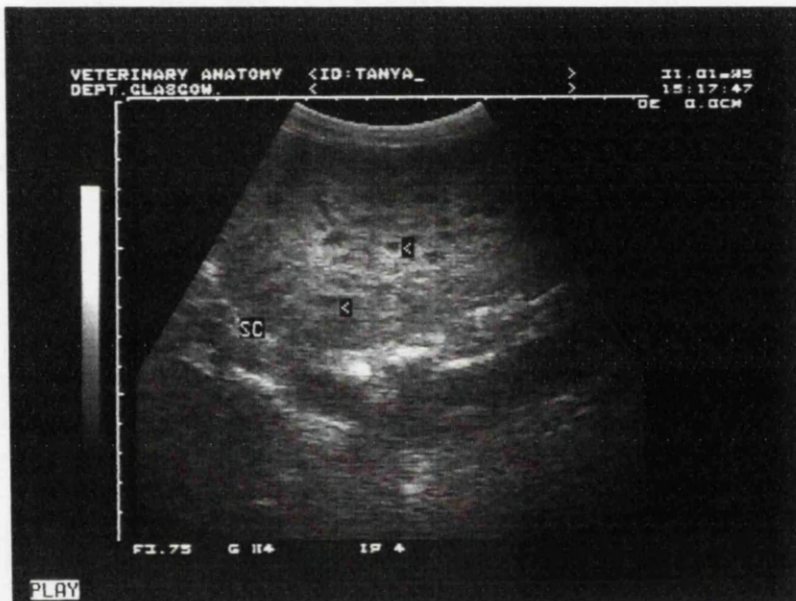


Figure 4.19. Parasagittal ultrasonogram of spleen of case no. 8 with multiple hypoechoic areas (<). Note the distorted splenic capsule (SC).

Case number 9

Subject. Boxer, 8.5 years old, neutered male. Weight 34 kg.

History and clinical signs

Weight loss, collapse, anaemia, lethargy and dullness for six weeks. The dog was also polydipsic, polyuric, partially anorexic and knuckled his hindlimb digits. The owner had also noticed an eye twitch and possible nystagmus. On clinical examination the dog was pale, had muffled heart sounds and coughed. The left hindlimb showed reduced placing reflex.

Laboratory test results.

Haematology. The following red cell parameters were reduced: RBCs ($3.17 \times 10^{12}/L$), Hb (8.2 g/dl), Hct (24.1%), platelets ($189 \times 10^9/L$), monocytes ($0.144 \times 10^9/L$), MCH (25.8 pg) was slightly raised. The blood picture was regenerative (normoblasts $1.248 \times 10^9/L$) with many target cells and some schistocytes.

Biochemistry. The following parameters were marginally elevated: glucose (6.3 mmol/L) and AST (38 U/L). In addition, chloride (112 mmol/L) was mildly elevated and albumin (25 g/L) slightly reduced. These values could not be fully interpreted in relation to the diagnosis.

Tentative clinical diagnosis: brain lesion - possibly a pituitary tumour; severe anaemia.

Radiography

A lateral abdominal view showed an oval shaped soft tissue mass in the cranial mid-ventral abdomen with displacement of the small intestinal mass dorsally. Abdominal contrast and definition were poor, possibly indicating a small amount of free fluid in the abdomen (Figure 4.20). There was also evidence of thoracic and lumbosacral spondylosis, and mineralised stomach contents. The lateral thoracic radiograph showed a narrowing of cardiac shadow, pulmonary vessels and caudal vena cava. The lung fields were hyperlucent even though this was an expiratory radiograph.

Radiographical diagnosis: abdominal mass (splenic), thoracic and lumbosacral spondylosis and a hypovolaemic picture in the thorax.

Ultrasonography

A large (approx. 12 cm) well-defined circular mass was present on the spleen. The mass showed strong acoustic enhancement and acoustic shadows at the lateral edges of the mass. It was hypoechoic but had an anechoic component and few linear echogenic areas. Focal anechoic to hypoechoic areas were interspersed with the normal splenic parenchyma. A splenic capsule was present covering the mass (Figure 4.21). There was no evidence of peritoneal effusion.

Ultrasound diagnosis: cystic splenic mass.

Further examinations and treatment

The dog died unexpectedly some hours following examination and was sent for a full post mortem examination.

Pathological examination

The post mortem examination revealed good body condition with marked carcass pallor. The abdomen was distended with frank blood, the site of abdominal haemorrhage being a flattened spherical mass located in the cranial pole of the spleen. The mass had a soft fluid consistency with extensive omental adhesions (Figure 4.22).

Histopathology revealed an outer rim of compressed collagenous tissue with the mass itself consisting of a large blood clot. Occasional ingrowing fibrocytes at the margin were seen but no structured vascular spaces or channels. The adjacent splenic tissue showed marked extramedullary haematopoiesis.

The liver and kidneys showed advancing autolysis. The spinal cord also showed signs of autolysis with slight increase in laciness of the white matter especially on the ventral aspect which was consistent with CDRM.

Histopathological diagnosis: splenic haematoma.

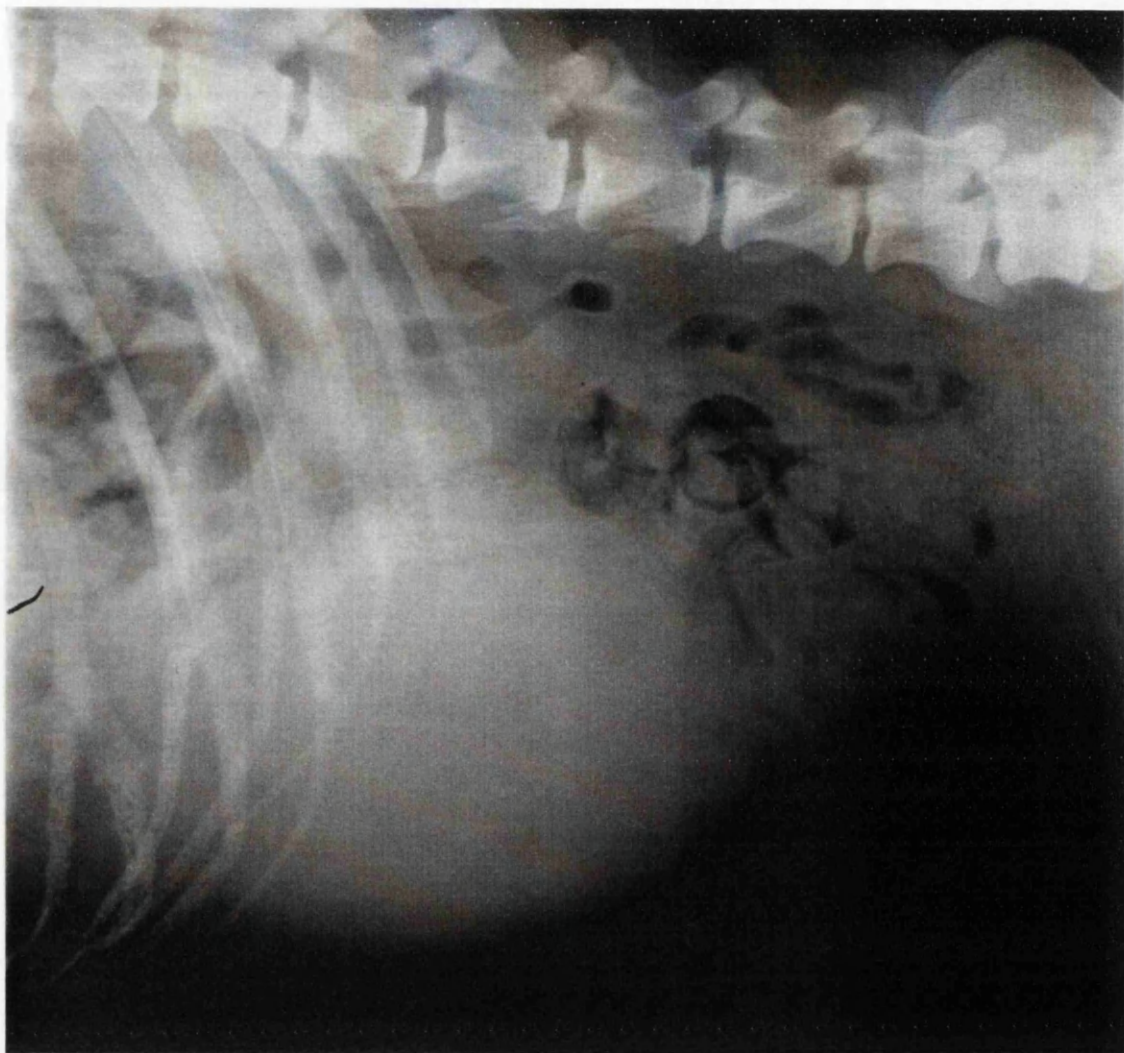


Figure 4.20.

Lateral abdominal radiograph of case no. 9 showing an oval shaped soft tissue mass with caudal displacement of the intestinal mass.

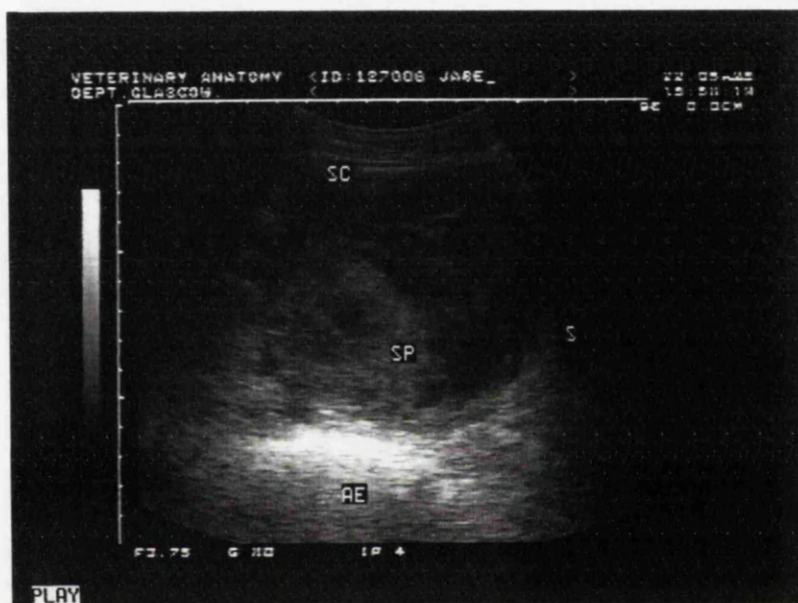


Figure 4.21.

Transverse ultrasonogram of the spleen of case no. 9 showing a large hypoechoic mass with echogenic linear lesions. Note the presence of acoustic enhancement (AE) and edge shadowing (S). Normal splenic echotexture (SP) and splenic capsule (SC) present.

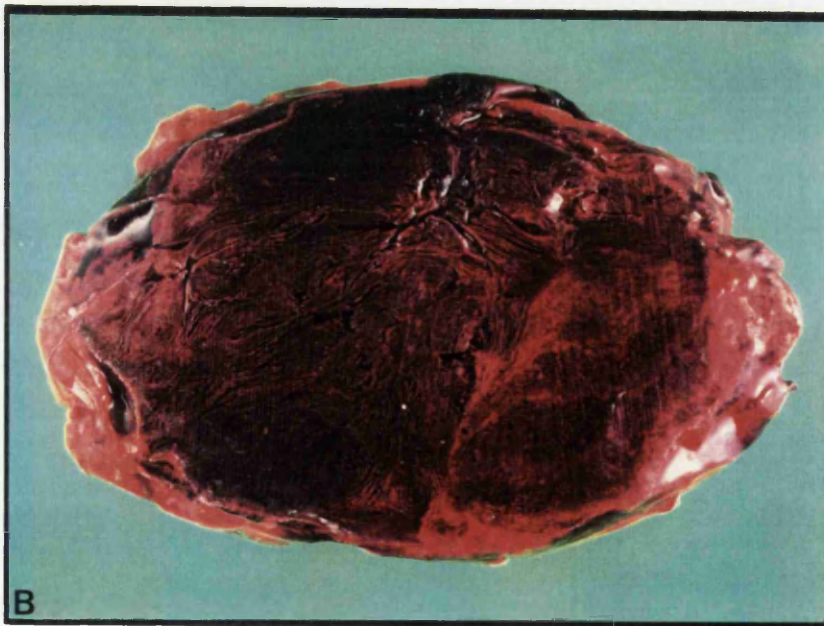
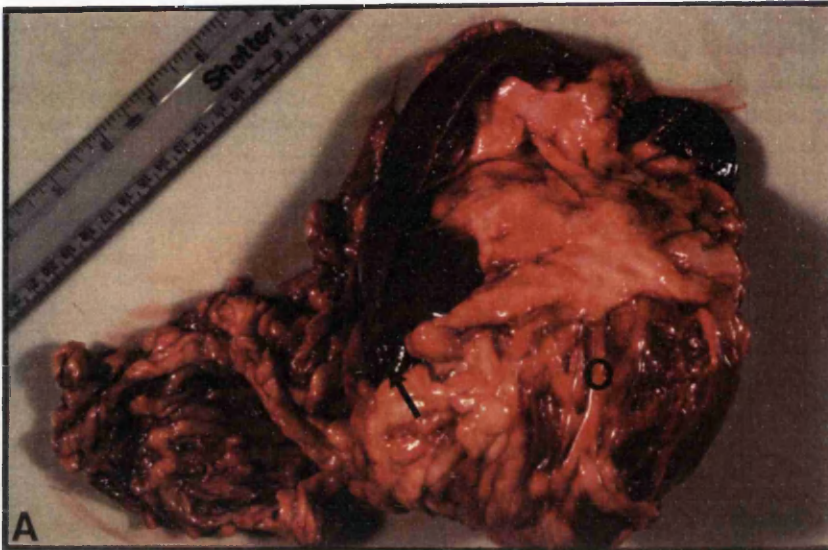


Figure 4.22.

A. Large mass from case no. 9 shown with omental adhesions (O). Point of splenic rupture (arrow) also shown. **B.** Transverse section of the spleen showing dilated blood vessel (arrow) and blood-filled areas (arrow heads).

Case number 10

Subject. Crossbred terrier, 12 years old, entire female. Weight 13 kg

History and clinical signs

Skin disease with pruritis, alopecia and lichenification for 3 years during which time corticosteroid treatment was instituted. Abdominal distension had been present for one year. The dog was dull, anorexic, lethargic, polydipsic, had pale mucous membranes and a palpable abdominal mass.

Laboratory test results

Haematology. There was evidence of auto-agglutination of the blood sample on the EDTA tube and the blood later clotted.

Biochemistry. The following parameters were moderately elevated: urea (13.4 mmol/L), AST (207 U/L) and globulin (41g/L).

Tentative clinical diagnosis: iatrogenic Cushing's disease which was not confirmed biochemically.

Radiography

Radiographs were not done.

Ultrasonography

A well-defined circular mass measuring 10 cm was seen in the area of the spleen. The mass was of mixed echogenicity with some anechoic, hypoechoic, isoechoic and hyperechoic areas present (Figure 4.23). Some of the anechoic areas had acoustic enhancement in the areas deep to them. The mass was covered by an obvious splenic capsule. There was no acoustic enhancement in tissues distal to the mass.

Ultrasound diagnosis: splenic neoplasia.

Further examination

A splenic sample was obtained by fine-needle aspiration.

Pathological examination

Cytological examination of the fine needle aspirate of the mass revealed numerous large cells with foamy cytoplasm and prominent, eccentric round nuclei. There were cellular and nuclear pleomorphisms, hyperchromasia and many giant bi-nucleated cells, indicating a histiocytic neoplasia.

Cytological diagnosis: malignant fibrous histiocytosis of the spleen.

Outcome

The owner opted for euthanasia because of the poor prognosis. A post mortem examination was not permitted.

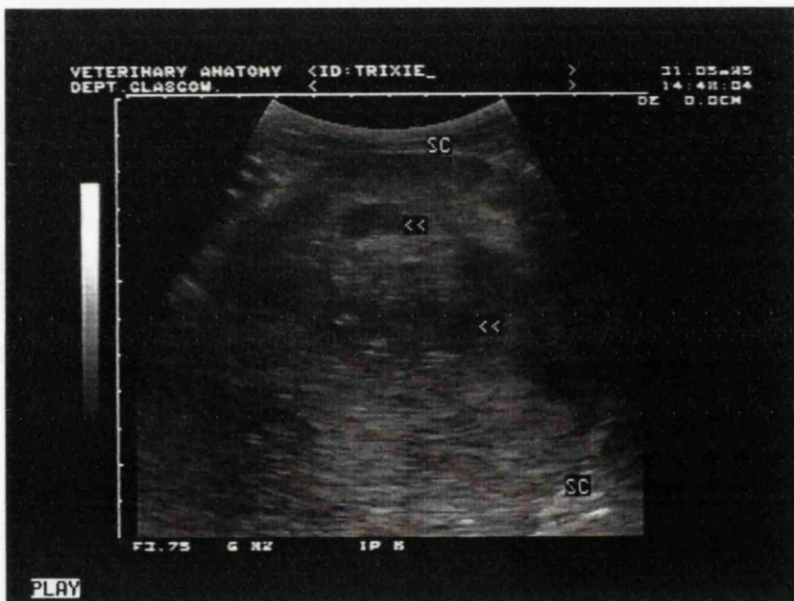


Figure 4.23.

Ultrasonogram of splenic mass from case no. 10 showing a complex echotexture. A splenic capsule (SC) is shown surrounding the mass. Note acoustic enhancement from the hypoechoic areas (<<) in the mass.

Case number 11

Subject. Crossbred Labrador, 11 years old, entire male. Weight 27 kg.

History and clinical signs

The owner had discovered an abdominal mass one month previously prior to the development of clinical signs. Four weeks later, the dog became lethargic and dull, with signs of abdominal discomfort.

Laboratory test results

Haematology. At first presentation, unremarkable apart from a slightly raised MCHC (36.4g/dl), reduced WBC ($5.8 \times 10^9/L$) and lymphocytopenia ($0.870 \times 10^9/L$). One month later, evidence of deterioration with reduced platelets ($100 \times 10^9/L$), WBC ($3.5 \times 10^9/L$), neutropenia ($2.52 \times 10^9/L$) and lymphocytopenia ($0.525 \times 10^9/L$).

Follow-up haematology 3 months later revealed normal values.

Biochemistry. Unremarkable apart from a slightly raised ALT (49 U/L) which could not be fully interpreted in relation to the diagnosis.

Tentative clinical diagnosis: Abdominal mass; leukopenia and thrombocytopenia.

Radiography was not done.

Ultrasonography

The splenic echotexture was disrupted by multifocal poorly-defined hypoechoic areas (Figure 4.24). Some of these were almost anechoic with no enhancement. The splenic capsule appeared slightly irregular but there was little change in the contour of the organ.

Ultrasound diagnosis: splenic neoplasia.

Further examination and treatment

The dog underwent an exploratory laparotomy, the spleen was excised and submitted for histopathological examination.

Pathological examination

The spleen was enlarged with nodular masses protruding through the splenic capsule (Figure 4.25).

All the normal splenic elements were present in their correct proportions. The most striking feature was congestion of the red pulp. Inactive haematopoietic precursors were also present. Some aggregations of granular haemosiderin were found in many phagocytes but the amount was considered normal for the dog's age.

Histopathological diagnosis: extramedullary haematopoiesis.

Outcome

The dog made an uneventful recovery.

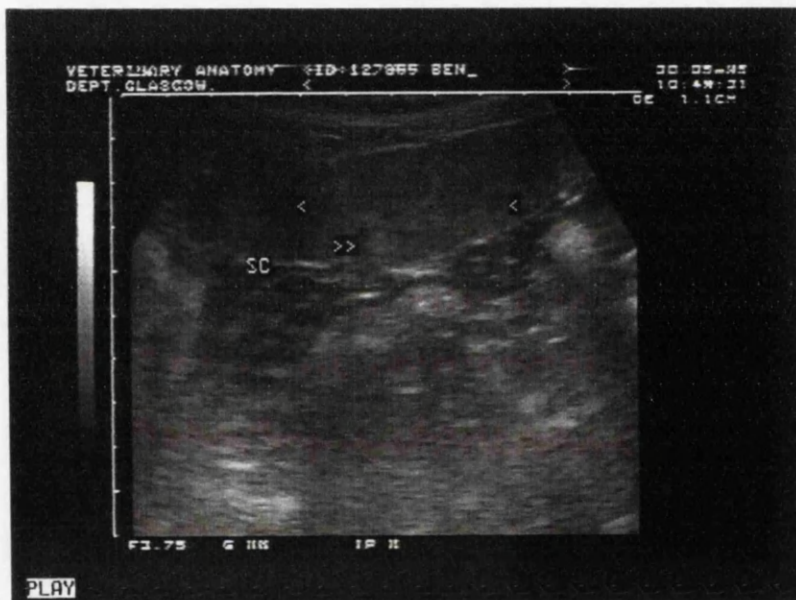

Figure 4.24.
Parasagittal ultrasonogram of spleen of case no. 11 showing multiple hypoechoic areas (<). Note the echogenic splenic capsule (SC) and veins (>>).

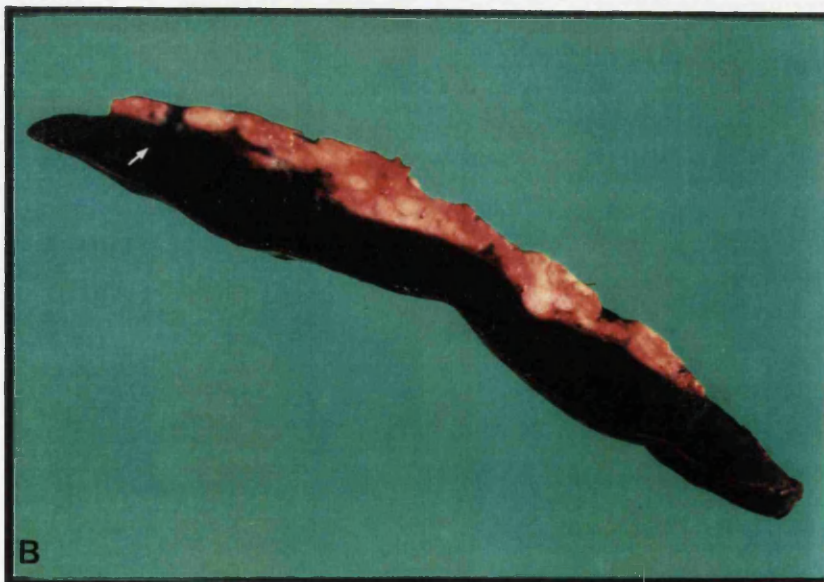
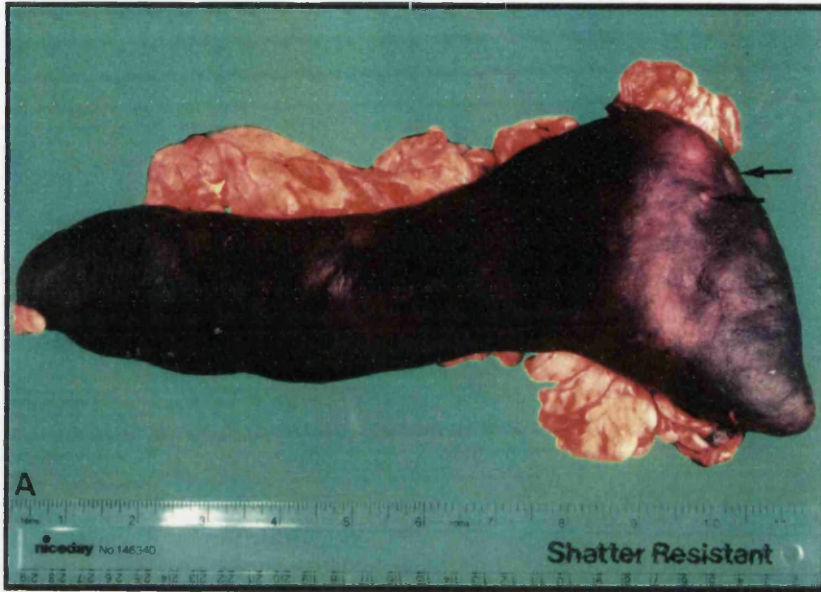

Figure 4.25.
A. Enlarged spleen from case no. 11 with nodular (arrows) surface.
B. Parasagittal section of the spleen showing small mass (arrow).

Case number 12

Subject. Golden Retriever, 5 year old, entire male. Weight 32.5 kg.

History and clinical signs

A mass measuring 2.5 cm had developed on the left flank of the abdomen. It was later resected, sent for histopathological examination and found to be a subcutaneous haemangiosarcoma.

Laboratory test results

Initial tests were unremarkable.

Haematology (post-splenectomy). The following red cell parameters were marginally reduced: RBC ($5.18 \times 10^{12}/L$), Hct (36.2%) and MCHC (36.4 g/dl). In addition, elevated WBC ($17.5 \times 10^9/L$) and mature neutrophils ($14.437 \times 10^9/L$) present.

Biochemistry remained unremarkable.

Tentative clinical diagnosis: splenomegaly due to haemangiosarcoma with leukocytosis due to neutrophilia.

Radiography

A lateral abdominal view, showed the spleen as an elongated soft tissue mass occupying the entire ventral abdominal floor (Figure 4.26). An initial lateral thoracic radiograph was unremarkable but 6 weeks later, a further thoracic radiograph showed increased radiopacity of the lung parenchyma with some areas of patchy increase in radiopacity indicating pulmonary metastasis.

Final radiological diagnosis: massive splenomegaly; probable malignant neoplasm with thoracic metastasis.

Ultrasonography

An enlarged, echoic spleen was visible. The splenic parenchyma showed diffuse multiple poorly-defined hypoechoic linear areas of variable sizes (<0.5 cm) and the splenic blood vessels were dilated (Figure 4.27).

Ultrasound diagnosis: diffuse splenic neoplasia.

Further examination and treatment

A splenectomy was performed and the spleen submitted for histopathological examination. Following splenectomy the dog was prescribed palliative treatment consisting of corticosteroids; methylprednisolone and carprofen and an anabolic steroid, nandrolone. However it became more lethargic, anorexic and weak with scuffing of its hindlimbs and a further thoracic radiograph was taken.

Pathological examination

The spleen was uniformly swollen and congested with no discrete gross lesions (Figure 4.28). Microscopy revealed severe congestion, sparse white pulp, evidence of focal extramedullary haematopoiesis and scattered haemosiderin-laden macrophages.

Histopathological diagnosis: extramedullary haematopoiesis and congestion.

Outcome

The dog became more lethargic, anorexic and showed exercise intolerance. This deterioration continued and the dog was euthanased. A post mortem examination was refused.

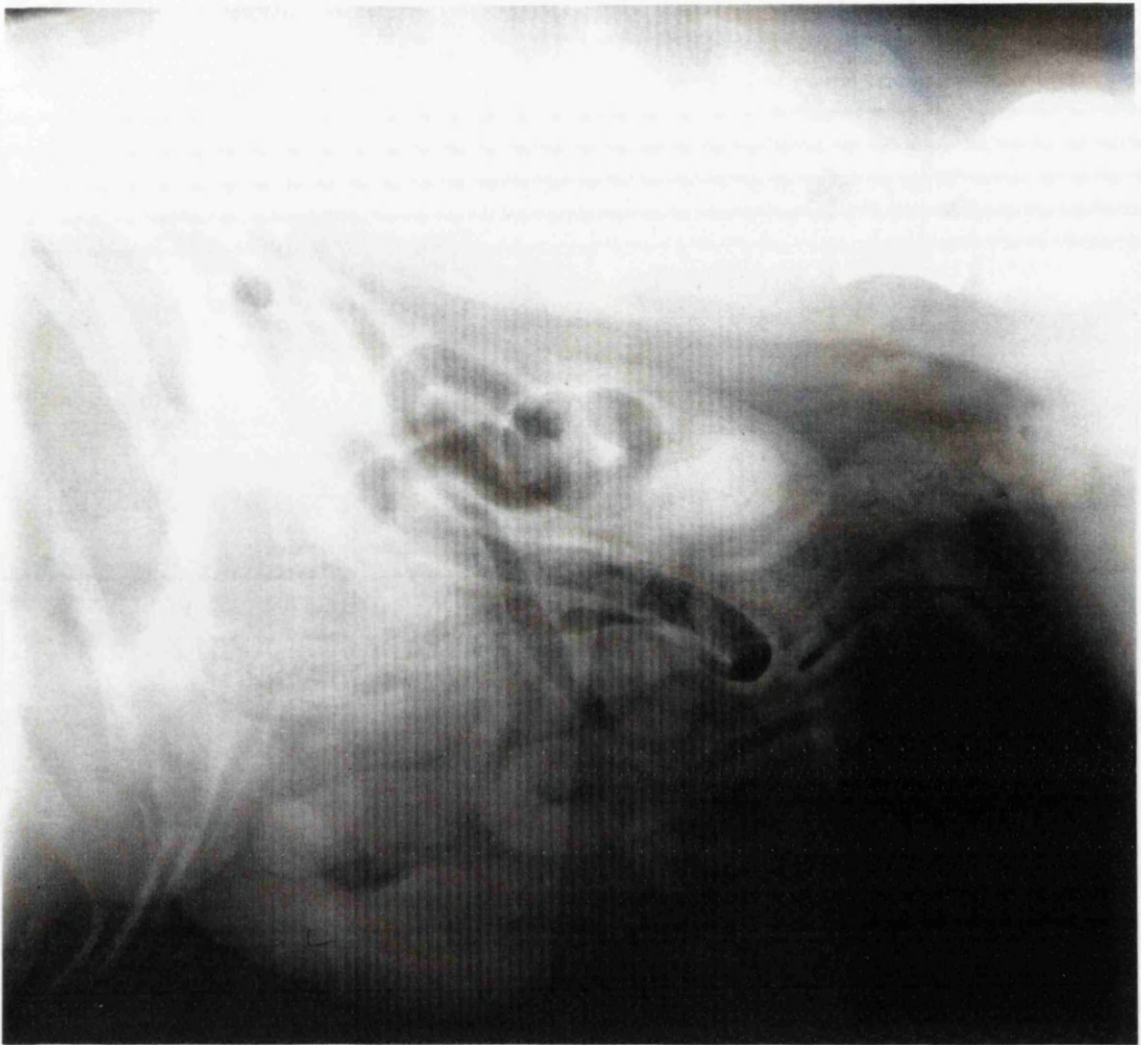

Figure 4.26.
Lateral abdominal radiograph of case no. 12 showing an enlarged spleen.

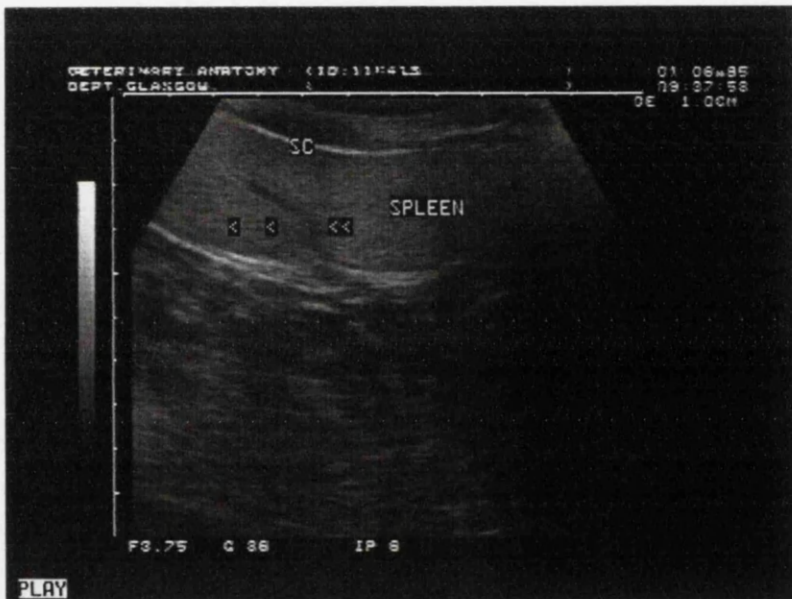

Figure 4.27.

Ultrasound image of grossly enlarged spleen in case no. 12. Note the dilated splenic vessels (<<) and the hypoechoic lesions (<).

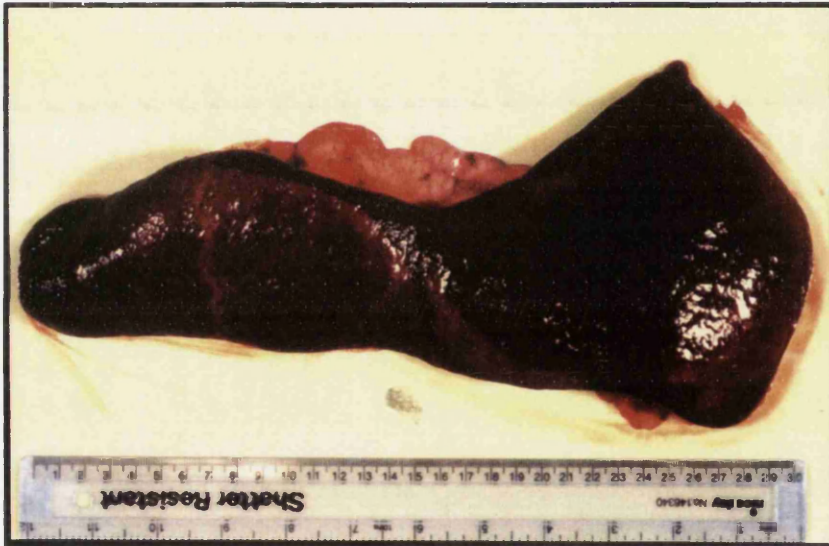


Figure 4.28.
Grossly enlarged and congested spleen from case no. 12.

Case number 13

Subject. Crossbred terrier, 13 year old, entire female. Weight 12 kg.

History and clinical

Polyuria and polydipsia, weight loss, lethargy, the dog whined most of the time. On physical examination, it was pale, dull and had abdominal distension with a palpable abdominal mass.

Laboratory test results

Haematology. The following red cell parameters were slightly reduced: RBC ($5.22 \times 10^{12}/L$), haemoglobin (9.2 g/dl), Hct (30.6%), MCV (59 fl), MCH (17.6 pg) and MCHC (30 g/dl). In addition, there was also a leukocytosis ($22.7 \times 10^9/L$) due to neutrophilia ($20.430 \times 10^9/L$). The platelets were aggregated and increased in size.

Biochemistry. Increased alkaline phosphatase (638 IU/L), total protein (90 g/L) and globulin (57 g/L).

Tentative clinical diagnosis: abdominal mass with mild anaemia, hyperproteinaemia and hyperglobulinaemia.

Radiography was not done.

Ultrasonography

A 6 cm circular mass was seen in the centre of a small spleen. The mass was poorly-defined and was hypoechoic with some bright echoes giving it a speckled appearance (Figure 4.29).

Assessment of the liver was not possible due a large amount of gas.

Ultrasound diagnosis: splenic neoplasia.

Further examination and treatment

A splenectomy was performed and the spleen submitted for histopathological examination.

Pathology

A large smooth surfaced spherical mass protruded from the parietal surface of the spleen. On section, the mass was composed of mottled grey-white tissue with some foci of haemorrhage. Foci of haemorrhage were present in the omentum.

Histopathology showed a mixture of large and small lesions of nodular hyperplasia with irregular accumulations of mainly white pulp with smaller areas of red pulp. There was no evidence of malignancy.

Histopathological diagnosis: splenic nodular hyperplasia.

Outcome

The dog made an uneventful clinical recovery but further tests were not done to check whether the haematology and biochemistry had returned to normal.

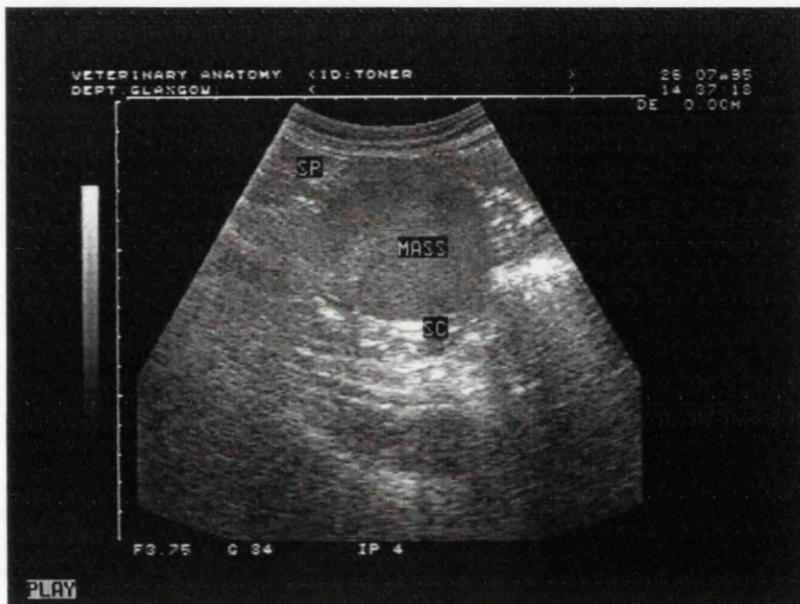

Figure 4.29.

Ultrasound image of the spleen of case no. 13 showing a poorly-defined hypoechoic mass covered by a splenic capsule (SC). Normal splenic echotexture (SP) is visible.

Case number 14

Subject. Domestic short-haired cat, 8 year old, entire female.

History and clinical signs

Presented for ultrasonography following the discovery of a cranial abdominal mass during a routine examination. The cat was obese but had a normal appetite.

Radiography

Was not carried out due to economic reasons

Ultrasonography

Anechoic well-defined masses showing acoustic enhancement, were seen on the spleen (Figure 4.30).

Ultrasound diagnosis: multiple splenic cystic masses.

Further examination and treatment

Exploratory surgery was performed and the cystic masses were found to be on the liver, overlapping the spleen but not attached to it.

Pathological examination

A post mortem examination was refused.

Outcome

The cat was euthanased on the operating table following discussion with the owner.

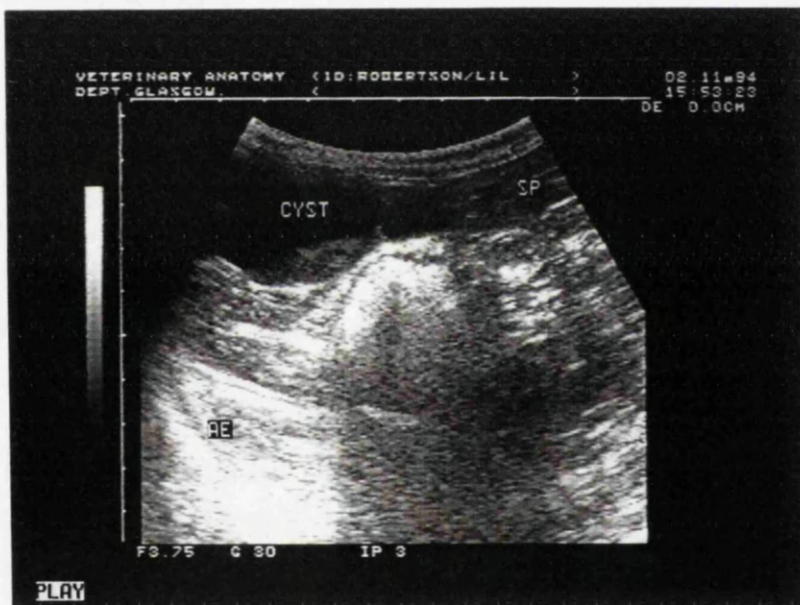

Figure 4.30.

Ultrasound image of case no. 14 showing hepatic anechoic cystic masses overlying the spleen.

Chapter 5.

Results.

All the 14 cases in this study were presented for ultrasonography due to the presence of an abdominal mass discovered either during routine clinical examination or suggested by the presence of a soft tissue density in an abdominal radiograph. Thirteen were dogs and one was a cat. The following dog breeds were represented: German Shepherd dogs (3), crossbred German Shepherd dog (1), Crossbred terriers (3), and Hungarian Vizsla (1), Cocker Spaniel (1), Boxer (1), Golden Retriever (1), Labrador (1), crossbred Labrador (1). The one cat was a domestic shorthaired. The sex distribution of the dogs was 6 females, three of which were neutered and 7 males, three of which were neutered. The cat was female (see Table 5.1.). The mean age of the dogs represented in the study was 8.5 years and standard deviation of 2.4 years. The mean weight of the patients in the study was 26.7 kilograms with a standard deviation of 12.2 kilograms.

The major clinical features of each case are summarised in Appendix 4.1.

The laboratory results showed non-specific changes in both the haematology and biochemistry, with the former being more remarkable.

Changes in the red cell parameters were as follows: reduced RBC in 5 dogs, reduced haematocrit in 5 dogs, reduced haemoglobin in 4 dogs, thrombocytopenia in 6 dogs. Changes in the white cell parameters were as follows: leukocytosis was seen in 6 dogs, leukopenia in 3 dogs, neutropenia was found in 2 dogs and neutrophilia in 6 dogs. Lymphocytopenia was found in 3 dogs and decreased monocytes in 2 dogs (Appendix 4.2). Other haematological findings were: schistocytosis in 3 dogs, normoblasts were found in 2 cases, reduced MCHC in 4 dogs, reduced MCH in 2 dogs and 1 dog showed increase in MCH. Aggregated thrombocytes were found in 3 cases with increase in size in one case (no. 13). Auto-agglutination was seen on the tubes of the two blood samples which clotted.

The plasma biochemistry results were generally unremarkable in 5 cases apart from some slight elevations from normal which could not be interpreted with respect to splenic disease. However, in 8 cases, there were more significant elevations in the following parameters: globulin (4); (case nos. 3, 5, 6 & 13), total protein (2), (case nos. 5 & 13), serum alkaline phosphatase (4), (case nos. 3, 4, 5 & 13), aspartate aminotransferase (4), (case nos. 2, 4, 6, & 10) and alanine aminotransferase (3), (case nos. 4, 6 & 7). One case (no. 4) had increased lipase and amylase levels associated with a pancreatic lesion. Case no. 6 with anal sac adenocarcinoma showed classical paraneoplastic hypercalcaemia (Appendix 4.3.).

CASE NO.	AGE (yrs)	WEIGHT (Kg)	BREED	SEX
1	7	30	Labrador	FN
2	6	53	GSD	MN
3	7	20.5	H. Vizsla	FI
4	8	14.6	C. Spaniel	MI
5	10	14	Terrier X	MI
6	10	36	GSDx	MN
7	11	38	GSD	FN
8	7.5	22	GSD	FN
9	8.5	34	Boxer	MN
10	12	13	Terrier X	FI
11	8	27	Labrador cross	MI
12	5	32.5	G. Retriever	MI
13	13	12	Terrier X	FI
14	8	-	DSH	FI

GSD = German Shepherd dog; X = crossbreed; DSH = Domestic shorthaired
M = male; F = female
I = intact; N = neutered
- = not done

Table 5.1. Age, weight, breed and sex distribution of the 14 cases presented.

Of the 13 canine cases, 7 were radiographed in either the lateral and/or dorsoventral positions. In all but one (case no. 4) of the patients, the radiographs showed evidence of an abdominal mass either in the cranial or mid-abdominal area. Three of these cases (case nos. 2, 7 & 9) also showed loss of abdominal detail in addition to a recognisable soft tissue density.

Using ultrasonography, splenic lesions were categorised as either focal or diffuse, with the focal group being further divided into either unifocal or multifocal masses, with dimensions ranging from large lesions (12 cm) to smaller ones of less than half a centimetre (Table 5.2.). Multifocal lesions were detected in 3 dogs which had pathological diagnoses of metastatic adenocarcinoma (case nos. 4 & 6) and unidentified nodular lesions (case no. 11). Table 5.4. shows a summary of primary sites and sites of metastases. Unifocal lesions were seen in 8 dogs with the following pathological diagnoses: haemangiosarcoma (case nos. 2 & 7), haemangioma (case no. 1), splenic abscess (case no. 3), splenic nodular hyperplasia (case nos 3, 5 & 13) and splenic haematoma (case no. 9). Of these, in 3 cases (case nos 3, 9 & 14) the structures were cystic and showed acoustic enhancement and edge shadowing.

PATIENT NUMBER	SIZE (c m)	ULTRASOUND APPEARANCE	INTRASPLENIC MARGINATION
1	1 0	Mixed	Well-defined
2	9.3	Mixed	Well-defined
3	5.3	Mixed	Encapsulated
3	6.6	Hypoechoic	Encapsulated
4	0.5-1.5	Hypoechoic	Poorly-defined
5	1 1	Mixed	Encapsulated
6	0.5-2	Hypoechoic	Poorly-defined
7	6	Mixed	Well-defined
8	<0.5	Hypoechoic	Poorly-defined
9	1 2	Mixed	Well-defined
1 0	1 0	Mixed	Encapsulated
1 1	<0.5	Hypoechoic	Poorly-defined
1 2	<0.5	Hypoechoic	Poorly-defined
1 3	6	Hypoechoic	Poorly-defined

Table 5.2. Ultrasound characteristics of the splenic lesions seen in the 13 dogs.

Diffuse ultrasonographic alterations were seen in two cases (nos. 8.& 12). All the cases in the study showed splenomegaly except case no. 4. Peritoneal effusion was noted on ultrasonograms of case nos 2 & 7 and the fluid accumulations were generalised throughout the whole abdomen.

Hepatic sonographic alterations were noted in only 3 patients (cases 4, 5 & 6), see Table 5.3. However, the ultrasonographic examination of the liver in these 3 dogs was regarded as incomplete because in each case, most of the organ was obscured by overlying gas.

The ultrasonographic findings in 13 of the cases correlated with the gross findings. In the cat (case no. 14), the lesion was on the liver and overlay the spleen. The ultrasound and gross findings differed from the histopathological findings (case no. 11), where only splenic EMH was diagnosed.

The control group all showed splenic echogenicity to be slightly more

echogenic than that of the liver (Table 5.7.)

Definitive diagnoses were made via histopathological examination in all but 2 cases (nos. 8 & 10) which were diagnosed by cytological examination. Table 5.6. shows a summary of the clinical, radiographic, ultrasonographic and histopathologic diagnoses.

Splenectomy was carried out in 5 dogs and one other in which splenectomy had been considered was euthanased on the operating table after the discovery of disseminated disease . Altogether 5 dogs were euthanased due to poor prognosis. Two dogs died, one in the immediate post-splenectomy period (case no. 5) and the other after a massive haemorrhagic episode (case no. 9). Drug therapy was attempted in two patients; case nos. 8 (chemotherapy) and 11 (palliative analgesics). The cat was euthanased on the operating table on discovery of hepatic lesions.

All the splenectomised dogs recovered uneventfully and were alive at the time of writing up. One dog (case no. 8) was lost to follow-up.

CASE NUMBER	SPLENIC ULTRASOUND	HEPATIC ULTRASOUND
1	Unifocal, mixed	Normal
2	Unifocal, mixed	Normal
3	Unifocal, hypoechoic	Normal
4	Multifocal, hypoechoic	Multifocal, hypoechoic
5	Unifocal, mixed	Multifocal, hyperechoic
6	Multifocal, hypoechoic	Multifocal, mixed
7	Unifocal, mixed	ND
8	Multifocal, hypoechoic	Normal
9	Unifocal, mixed	ND
10	Unifocal, mixed	Normal
11	hypoechoic	Normal
12	Multifocal, hypoechoic	Normal
13	Unifocal, hypoechoic	Normal
14	-	Multifocal, anechoic

ND = not done

- = normal

Table 5.3. Distribution and echogenicity of splenic and hepatic lesions in 14 cases studied.

Case number	Primary tumour site.	Metastases site
1	Spleen	—
2	Right atrium	Spleen Omentum Mesentery Peritoneum
3	Spleen	—
4	Pancreas	Spleen Liver
5	Spleen	—
6	Anal sac	Spleen Long bones Vertebrae
7	Spleen	Liver
8	Lymph node	Spleen
9	Spleen	—
10	Spleen	—
11	Spleen	—
12	Spleen	—
13	Spleen	—
14	Liver	—

- = no metastases seen

Table 5.4. Primary and secondary tumour sites in 14 cases of suspected splenic disease.

CASE NO.	CLINICAL DIAGNOSIS	RADIOLOGY DIAGNOSIS	ULTRASOUND DIAGNOSIS	HISTOPATH. DIAGNOSIS
1	abdominal mass	ND	splenic neoplasia	haemangioma
2	ruptured haemangiosarcoma	abdominal mass and PE	splenic neoplasia and PE	disseminated haemangiosarcoma
3	abdominal mass	ND	cystic splenic mass and neoplasia	splenic abscess and SNH
4	chronic pancreatitis	NAD	splenic neoplasia	metastatic adenocarcinoma
5	abdominal mass	ND	splenic neoplasia	SNH
6	neoplasia	soft-tissue mass	splenic neoplasia	metastatic adenocarcinoma
7	neoplasia	soft-tissue mass	splenic neoplasia and PE	splenic haemangiosarcoma
8	multicentric lymphosarcoma	hepato-splenomegaly	splenic neoplasia	multicentric lymphosarcoma
9	brain lesion	soft-tissue mass	cystic splenic mass	splenic haematoma
10	Cushing's disease	ND	splenic neoplasia	splenic malignant histiocytosis
11	splenic mass	ND	splenic neoplasia	EMH
12	haemangiosarcoma	splenomegaly	splenic neoplasia	EMH
13	abdominal mass	ND	splenic neoplasia	SNH

PE = peritoneal effusion

ND = not done

NAD = no abnormalities

Table 5.5. Clinical, radiographic, ultrasonographical and histopathologic diagnosis of the 13 dogs with splenic disease.

Number	Breed	Sex	Age (years)	Spleen	Echotexture
1	GSD	FN	7	Palpable	Normal
2	Labrador	FN	4	Palpable	Normal
3	Schnauzer	FN	2.5	Palpable	Normal
4	GSD	MI	3	Palpable	Normal
5	Mixed	MI	4	Palpable	Normal
6	Greyhound	FN	4	Palpable	Normal
7	Greyhound	FN	5	Palpable	Normal
8	Cocker Spaniel	FN	6 months	Not palpable	Normal
9	Mixed	MI	1	Not palpable	Normal
10	Greyhound	MN	5	Palpable	Normal

GSD = German Shepherd
F = female; M = male
I = intact; N = neutered

Table 5.6. Breed, sex, age and splenic echogenicity in 10 dogs which comprised the control group.

Chapter 6

Discussion and Conclusions.

Ultrasound is an important modality for scanning the abdominal organs and although there are reports of its application to the canine spleen in health and disease (Hosgood 1987, Prymak and others 1988, Schelling and others 1988, Johnson and others 1989), to our knowledge, this is the first study in the dog in which splenic ultrasound findings have been compared with radiographic and pathomorphological findings. A similar study of the canine liver was carried out by Vörös and others (1991). In this study all ultrasound findings, except those described in case no. 14, correlated with the morphological findings. Splenic ultrasound appears to be more accurate than radiography because the latter depends on changes in the size and position of the organ, whereas ultrasound demonstrates changes in echotexture and hence cellular composition. This superiority was typified by case no. 4, which appeared to be radiographically normal but showed significant abnormalities on ultrasound. Radiography is, however, important in non-invasive diagnosis especially in the thorax, where the presence of air limits the use of ultrasound. Ultrasound is also limited in that it does not offer a definitive diagnosis although when its findings are combined with clinical signs, some conditions may be ruled out. Although linear transducers have certain limitations as regards the size and large contact area, the 3.75 MHz curvilinear transducer was found to be adequate for this work. The small sample size in this study is regrettable and precludes any statistical conclusions. The small number of cases is partly due to GUVS being a referral centre and therefore not receiving primary access material. In addition, a number of practices regularly referring cases have acquired ultrasound machines which may have further influenced the type of cases now being referred. Most clients were reluctant to permit fine needle aspiration biopsy of the spleen in the light of the probable grave prognosis for the underlying splenic disease.

The association of anaemia with neoplasia is common both in man and animals (Rebar and others 1980). However, since anaemia due to neoplasia is non-specific, it is of little diagnostic, therapeutic or prognostic significance. Anaemia diagnosed in animals in the present study was probably haemorrhagic, due to either intraperitoneal haemorrhage (case nos. 2 and 7) or intra-lesional haemorrhage (case no. 9). In all 3 cases the anaemia was regenerative with normocytic and normochromic red blood cells. Only case no. 7 had a low mean corpuscular haemoglobin concentration (MCHC) implying a mild hypochromic anaemia. As chronic bleeding within a body cavity does not result in net iron loss (Hirsch and others 1981), the concurrent chronic colitis in this particular

dog may have been responsible. Reticulocytosis is also associated with a reduced MCHC due to the lesser content of haemoglobin in reticulocytes compared to mature red blood cells (RBC). Reduced ability of the bone marrow to respond to anaemia may occur with iron sequestration or with a reduced rate of iron mobilisation (Madewell and Feldman 1980). The presence of neoplasia may also deplete the body folate reserves, thus interfering with haematopoiesis (Ng and Mills 1985).

All the dogs with haemorrhagic anaemia (case nos. 2, 7 and 9) showed schistocytosis on a blood smear. Schistocytes signify red cell fragmentation and hence microangiopathic haemolytic anaemia (MAHA), (Ng and Mills 1985). Cell fragmentation in RBCs and platelets follows squeezing as they attempt to traverse the altered vascular pathways of the tumour which are narrowed by fibrin networks (Rebar and others 1980, Brown 1985) and also because the passage of RBCs through enlarged spleens is delayed, resulting in early senescence due to reduced oxygen tension and pH; aged red cells being particularly susceptible (Rebar and others 1980). Schistocytosis is also associated with disseminated intravascular coagulation (DIC) in the dog (Harvey 1980, Rebar and others 1980, Hammer and others 1991). The association of chronic DIC and haemangiosarcoma has been well established in dogs (Legendre and Krehbiel 1977, Madewell and Feldman 1980). Two patients in the present study (case nos. 5 & 10) showed auto-agglutination in the blood sample tubes. Autoagglutination is the aggregation of RBCs into grape-like clusters and is an indication of immune-mediated haemolytic anaemia (Tvedten 1994), one of the conditions associated with DIC (Slappendel 1988).

Thrombocytopenia is the most common platelet abnormality seen in dogs with malignancy (Helfand 1988). In the present study of the cases, 54% (6 out of 11) showed apparently reduced platelet numbers. Thrombocytopenia associated with neoplastic conditions in dogs may be due to several underlying causes including decreased platelet production, as seen in many bone marrow conditions (myelophthisis, myelodysplasia, etc.); increased platelet destruction, especially through immune-mediated thrombocytopenia (IMT); shortened platelet survival, and microangiopathy. IMT is a paraneoplastic syndrome, recognised in both man and dogs, and was initially only associated with haematopoietic neoplasia but more recently, it has been confirmed in dogs with solid tumours (Helfand and others 1985). IMT may be due to antibodies directed against circulating tumour antigens or immune complexes adsorbed onto the platelet membranes or alternatively the tumours themselves may produce specific antiplatelet antibodies (Brown 1985). Increased platelet sequestration

as seen in lymphosarcoma is an important cause of thrombocytopenia. Other neoplasms such as haemangiosarcoma and haemangioma (Brizel and Raccuglia 1965), may also cause thrombocytopenia through hypersplenism (Helfand 1988). A concurrent DIC may also result in consumption of thrombocytes. The presence of large platelets, as seen in case no. 13, suggests increased platelet production and can also occur with increased erythrocyte production (Ng and Mills 1985).

Dogs with haemangiosarcoma have also been associated with acanthocytosis (Gelberg and Stackhouse 1977, Rebar and others 1980, Hirsch and others 1981). Acanthocytes are described as erythrocytes of normal volume but having two to ten irregularly shaped spicules of varying length (McBride and Jacob 1970). The pathogenic mechanism of acanthocyte formation is unclear, blood stasis in the spleen has been implicated, however, splenic involvement is not a constant feature (Rebar and others 1980). In man, acanthocytosis is associated with abetalipoproteinemia, congenital lipid disorders and hepatic cirrhosis or neoplasm (McBride and Jacob 1970). In the present study however, acanthocytes were not seen.

In splenic disease, mild to moderate neutrophilic leukocytosis is commonly present because any stimulus of the erythropoietic marrow also affects the myeloid elements. Blood in the peritoneal cavity or degenerative changes in the tumour may exert a leukocyte-stimulating effect (Brodey 1964).

Vomiting was a feature in four dogs in the present study (case nos. 3, 4, 6 & 8). In splenic disease, gastrointestinal (GIT) signs such as inappetence, vomiting, constipation and flatulence are related to mechanical displacement of the viscera by the splenic mass if it is large (Brodey 1964). However, in case no. 1, a dog with haemangioma, no such clinical signs were noted despite the large size of the splenic mass. Even though in case no. 4 (metastatic adenocarcinoma) vomiting was a prominent sign, this was due primarily to the pancreatic lesion since the spleen, although diseased, was not grossly enlarged. According to Brodey (1964), GIT signs are very common in cases of splenic haematoma, attributable to the insidious development of a large mass before clinical signs occur. In this study, however, these signs were not a feature in the one dog with a haematoma (case no. 9). Radiographically the circular shape of the mass was discernible but ultrasonographically the ventral border appeared to be concave. According to Hill and Sanders (1978), unlike other cystic masses, haematomata tend to shape themselves around adjacent organs rather than displace them.

Abdominal enlargement is frequently noticed by the owner. It usually develops slowly and insidiously except in cases of traumatic haemoperitoneum, rupture of the urinary bladder, gastric dilatation or volvulus. Abdominal enlargement may also be associated with other clinical entities such as pregnancy, pyometra, hydrometra, hepatomegaly, renomegaly, masses on the spleen and other organs. In addition a slowly enlarging abdomen may be associated with Cushing's disease. All but two (case nos. 10 & 13) of the cases in the study which had abdominal enlargement showed abdominal pain. Abdominal pain may be due to acute abdominal conditions such as gastric dilation and volvulus, intestinal foreign bodies, splenic torsion, acute inflammation of any of the organs and peritonitis. Peritonitis may occur in haemoperitoneum due to rupture of a mass and also release of neoplastic cells (Ettinger 1989).

Malignant disease often results in weight loss. A condition known as malignant cachexia has been recognised in both human and animal cancer patients and is a complex paraneoplastic syndrome of progressive involuntary weight loss, even with adequate nutritional intake (Ogilvie 1993). Anorexia is the main component of cancer cachexia resulting from altered gustatory and olfactory senses, early satiety or partial obstruction of the gastrointestinal tract (Whiteley and Willard 1987). The two major contributing factors to cachexia are alterations in the metabolic pathways due to the tumour and its primary effects or therapy (Vail and others 1990), with the most remarkable disturbances occurring in carbohydrate metabolism (Ogilvie 1993). Evidence exists that tumours and hosts have different nutritional requirements with the tumour acting like an obligatory parasite growing at its own rate and competing effectively with the host for limited available nutrients (Vail and others 1990). Complications of increased risk to infections and decreased immune competence are seen in these patients (Whiteley and Willard 1987). Relief of cachexia in dogs may be achieved through dietary manipulations (Vail and others 1990). Studies have failed to show increased tumour growth or rate of metastasis with these dietary changes. In the present study, typical cancer cachexia was not a feature of the cases of malignant disease with associated weight loss (case nos. 7 & 8).

Of the cases in which there was radiographic examination (case nos. 2, 4, 6, 7, 8, 9 & 12), findings were consistent with mid or cranial abdominal masses, except for case no. 4, where there was no radiographic evidence of splenic pathology. The two cases of haemangiosarcoma (case nos. 2 & 7) showed loss of serosal detail but soft tissue masses were still discernible. This discernibility is dependent on the amount of peritoneal fluid present. A study by Henley and others (1989) showed that in dogs, ultrasonography could detect 2-3 ml/lb body weight of peritoneal fluid whereas radiography required 4 ml/lb body weight of

fluid. Evaluation of ascites was one of the earliest uses of abdominal ultrasound, which was shown to be ideally suited for distinguishing solid tissue from fluids (Edell and Geftter 1979). Peritoneal effusions are classically categorised into transudates, modified transudates and exudates and can be differentiated by means of the specific gravity, protein content and cellularity (Ettinger 1989). Ultrasonographically, true transudates should be completely anechoic (cell content $<500\text{-}1000/\mu\text{l}$) whereas modified transudates and exudates will be increasingly echogenic (cell counts $<5000/\mu\text{l}$ and $>5000/\mu\text{l}$ respectively), (Spaulding 1993). Both cases with haemangiosarcoma (case nos. 2 & 7) had some echoes in the effusion suggesting that the fluid was either a modified transudate or an exudate. As the cellularity increases, the fluid generally contains more and larger reflectors and becomes more echogenic. Fluid with abnormal echoes is seen in exudates such as purulent and serosanguinous fluids and blood. An echogenic effusion can be confused with a solid mass, especially if the fluid is very viscous (Spaulding 1993). However swirling-of the fluid due to patient movement, breathing or manipulation may be helpful in distinguishing this. Ultrasonographically the mass may show poor acoustic enhancement of the deeper tissues and may also show edge shadowing at the sides as a result of the refraction of the sound (seen in case nos. 3 & 9). These artifacts would confirm the fluid nature of the contents of the mass (Bree and Silver 1979, Kremkau and Taylor 1986). Peritoneal effusion provides a perfect acoustic window for viewing the abdomen and therefore other organs such as intestines may be more easily evaluated. Normally the loops should be consistently freely mobile and separated by fluids on several scans despite change in position (Edell and Geftter 1979). Matting of the intestinal loops is suggestive of neoplasia (Edell and Geftter 1979).

The clinical signs seen associated with the cases of splenic haemangiosarcoma (SHS) in this study were non-specific, a finding which concurs with those of other workers (Waller and Rubarth 1967, Pearson and Head 1976, Brown and others 1985). In SHS, clinical signs may not be seen until rupture results in a bleeding episode, when shock and collapse may be the predominant signs. In a study by Brown and others (1985), 60 out of 104 dogs were examined due to rupture of the primary tumour or because of metastatic disease. In the present study the 2 cases (nos. 2 & 7) with SHS had a haemoperitoneum, with case no. 2 showing only polydipsia, anorexia and abdominal distension. The polydipsia was probably due to blood loss within and outwith the tumour mass (Waller and Rubarth 1967).

In case no. 2, right atrial haemangiosarcoma was present. Brown and others (1985), in a retrospective study of canine haemangiosarcoma, considered the

spleen to be the most important primary site for haemangiosarcoma, whereas other workers (Kleine and others 1970, Pearson and Head 1974, Hirsch and others 1981) showed cardiac haemangiosarcoma to be more prevalent (33% and 55%, 28% and 40%, respectively). The clinical signs of cardiac haemangiosarcoma are also non-specific and mimic those of other cardiac diseases, such as neoplasia, infectious pericarditis and benign pericardial effusion. Pericardial effusion is an important secondary manifestation of an underlying cardiac disease (Jones 1979, Brown and others 1985). Studies on dogs with pericardial effusion showed that neoplasia was the predominant cause with haemangiosarcoma being the most common type (Jones 1979, Sisson and others 1984, Holt and others 1992). The pericardial effusion, which is often haemorrhagic, probably results from "weeping" from the tumour surface after it has eroded through the thin-walled right atrium or auricle (Kleine and others 1970). Case no. 2 in the present study, however, did not have a pericardial effusion at post mortem. Metastasis of cardiac haemangiosarcoma occurs to other organs particularly the lungs (Waller and Rubarth 1967, Hirsch and others 1981). In the present study only case no. 12 had lung metastases but unfortunately the presence of a cardiac lesion could not be established as neither cardiac ultrasonography nor post mortem examinations were carried out. The lung metastases were only seen on the second set of thoracic radiographs taken 6 weeks later. Radiographic detection of lung metastasis is affected by size, shape, opacity and margin of mass, superimposition of intra- and extra-thoracic structure, number of films, contrast and detail, and factors related to interpretation (Lang and others 1986). The radiographic views of the animal are also important. In the study by Lang and others (1986), the highest sensitivity was obtained with a three view combination. However, other studies have shown that opposite lateral views were adequate (Holt and others 1992). In case no. 12 only one lateral view was taken. It is also possible that tumours on the dependent lung lobes may be obscured by the heart or diaphragmatic shadows, or masked by compression atelectasis and hypostatic congestion (Lang and others 1986). This may have been so in case no. 12, where the tumour metastases were initially undetected. Metastasis of haemangiosarcoma occurs rapidly from any primary site, including the spleen (Hirsch and others 1981) and in case no. 12, from a subcutaneous lesion. It is recommended that surgery only be performed in dogs without obvious metastases (Aronsohn 1985) and euthanasia during surgery when metastases are detected (Johnson and others 1989) emphasising the importance of accurate staging (neoplasia confined to primary site or secondary sites involved) where possible, when haemangiosarcoma is suspected.

The prognosis of dogs with SHS is very poor and the presence of

haemoperitoneum further shortens the animal's life-span. In the study by Brown and others (1985), dogs with only primary splenic lesions had a survival period of 151 days, those with ruptured primary tumours 107 days and with metastases 73 days. Some workers have suggested that FNA, is of limited value in cases of suspected haemangiosarcoma due to possibilities of transcoelomic seeding or of causing iatrogenic splenic rupture (O'Keefe and Couto 1987, Osborne 1974a, Osborne 1974b, Osborne and others 1974). However, it has been hypothesised that these tumour cells are destroyed by the immune system or by some other mechanism (Levéillé and others 1993). Furthermore, Johnson and others (1989) found no difference in the mean survival time of dogs with primary splenic neoplasia and primary disease (ruptured or intact) with intra- or extra-abdominal metastasis or both. Therefore FNA is unlikely to affect the long term survival of the patient.

The sonographic appearance of the tumours in the present two cases of haemangiosarcoma was of mixed echogenicity, similar to findings by other authors (Wrigley and others 1988b). The variability of the tumour echogenicity is due to other lesions present within the tumour mass, including haematomata, cystic and necrotic areas (Jubb and Kennedy 1970). Anechoic areas are attributed to the cysts and necrotic areas whereas the hyperechoic areas are usually due to fibrosis, mineralisation and recent haematomata in the tumour (Wicks and others 1978, Mittelstaedt and Partain 1980, Solbiati and others 1983, Feeney and others 1984).

In the present study, hepatic lesions were not present ultrasonographically, even though case no. 7 had evidence of liver involvement when examined at post mortem. Metastatic hepatic haemangiosarcoma has been reported to appear as ill-defined hypoechoic and anechoic lesions (Nyland and Park 1983, Feeney and others 1984, Wrigley and others 1988b). Although ultrasonography is a reliable method for detection of metastatic spread of haemangiosarcoma, complete visualisation of the organ may be impeded by intestinal gas, leading to false negative results. Sector real-time imaging allows for more complete imaging of the canine liver (Nyland and others 1989).

Splenic haemangioma (SHG) shows non-specific clinical signs similar to SHS and other splenic neoplasia. In other reported studies, SHG is discussed together with SHS (Brodey 1964, Srebernik and Appleby 1991) probably due to their similar vascular origin and difficulty in distinguishing them. In humans, haemangioma is the most common benign tumour in children and unlike in adults, is associated with high morbidity and mortality (Taylor 1985).

The sonographic appearance of SHG is variable. In case no. 1 in the present study, the mass did not appear to contain distinct cystic areas with enhancement, as was seen in the cases of SHS. In man hepatic haemangioma has variable sonographic appearance depending on whether the tumour is cavernous or capillary type; the latter shows a hyperechoic lesion and the former a relatively echo-free one (Cosgrove 1983).

In both animals and man, the clinical signs of splenic haematoma are vague; human patients complain of pain in the upper abdomen, left flank or left shoulder, postural dizziness, fever, nausea, vomiting and weight loss (Lupien and Sauerbrei 1984). In dogs the clinical signs include lethargy, nausea, vomiting, weight loss, and abdominal distension (Wrigley and others 1989). Pain is not a consistent finding in dogs. However, a horse with a splenic haematoma showed pain on rectal and caudal hemithorax palpation (Spiers and others 1986). In case no. 9 of this study, although pallor was the only clinical sign of shock, hypovolaemia was evident on the thoracic radiograph. There was no sign of peritoneal effusion on ultrasound, therefore the hypovolaemic shock may have been the result of intra-lesional haemorrhage and the resultant large haematoma (>12 cm). The dog, however, died following rupture of this mass. Some cases of splenic haematomata may resolve with time (Hanson and Penninck 1994) or may continue to enlarge, as with case no. 9, and in some instances persist for years (Lamb 1990). Haematomata may later degenerate into cysts (Jubb and Kennedy 1970). As in our case, splenic rupture and subsequent haemoperitoneum constitute an emergency usually requiring splenectomy to control haemorrhage (Bartels 1970, Frey and Betts 1977), unless the large amount of blood lost in a single bleeding episode is fatal. Myocardial ischaemia and hypoxia may result from decreased circulating blood volume and hypovolaemic shock associated with bleeding from a ruptured splenic mass (Knapp and others 1993). In the study by Knapp and others (1993), ventricular arrhythmias were observed in dogs with splenic masses due to haemangiosarcoma, haematoma and leiomyosarcoma. A large cystic splenic mass or a suspected haematoma must therefore be treated as an emergency and the patient's vital signs monitored before an exploratory operation is considered.

Haematomata show a diverse sonographic appearance due to the changes which occur during the clotting process, and altered echogenic patterns have been observed in man after acute bleeding into the kidneys, liver and spleen (Van-Sonnenberg and others 1983). *In vitro* studies revealed clotted blood to be echogenic. Stagnant non-clotted blood appeared anechoic when viewed with a 3 MHz transducer (Sigel and others 1980). A study by Coelho and others

(1982) showed that clot echogenicity decreased with decrease in the number of erythrocytes and that haemolysed blood clots were not echogenic even with high resolution transducers. The sonographic appearance of the haematoma seen in this study is similar to that seen by other workers (Wrigley and others 1989). It would be difficult to say how old the haematoma was in case no. 9 but it is unlikely to have occurred acutely as the rapid stretching of the splenic capsule would have caused pain to be a predominant feature. In people, haematomata of less than one month duration are generally echogenic with variable amounts of internal echoes and may subsequently develop an anechoic appearance (Wicks and others 1978). In another study, some old haematomata had irregular walls and echogenic material which was laminated on the dependent side of the lesion (Doust and others 1977). Haematomata should be considered a potential cause of virtually any mass lesion identified by ultrasound (Lamb 1990).

Splenic abscesses are an uncommon entity both in animals and humans. It is not clear what may have caused the abscess in case no. 3, although one possibility could have been haematogenous spread of pathogens from another focus of infection (Chulay and Lankerani 1976), in this case the concurrent chest infection. In human patients splenic abscessation has been a complication of otitis media, suppurative parotitis, cutaneous infections, lung abscess, pneumonia, cholecystitis and osteomyelitis. Trauma is another possible initiator of the condition. In a study by Caldarella (1938) into the pathogenesis of splenic abscess in rabbits, the condition could only be produced following an intravenous injection of *Staphylococcus aureus* if their spleens had been first traumatised, or a branch of the splenic artery ligated. Splenic abscess resulting from trauma is usually single and well localised (Jubb and Kennedy 1970). A case of nodular hyperplasia and abscess in the liver is reported in the literature with trauma being cited as the inciting cause (Lord and others 1982). Hunting and working dogs are at particularly high risk of grass awn migration due to increased contact in the field (Brennan and Ihrke 1983). The most common site of grass awn localisation is the external ear canal, others include the interdigital webs, eye, nose, lumbar area and thoracic cavity (Brennan and Ihrke 1983). Other areas may be involved through more complicated migratory routes thus affecting internal organs such as the urinary bladder (Brennan and Ihrke 1983) and the lumbar vertebrae following migration from the duodenum (Johnston and Summer 1971). Splenic abscesses due to foreign body penetration have been reported in the literature (Swan 1968). Solitary abscesses are relatively uncommon (Dubbins 1980, Solbiati and others 1983). Haemoglobinopathies also appear to predispose to the development of splenic abscess (Chulay and Lankerani 1976). The infrequency

with which splenic abscessation occurs may, as in the case of the liver (Lord and others 1982), be due to the spleen's rich blood supply and presence of phagocytic reticuloendothelial cells. These factors may combine to provide an effective defence against localisation of infection and subsequent development of an abscess.

Pathogens isolated from the abscess in case no. 3 were *Pseudomonas aureofaciens* and *Enterobacter agglomerans*, which are both aerobic bacteria and found as normal flora of the gastrointestinal tract. Organisms isolated from other reported splenic abscesses have been mainly *Staphylococcus aureus*, various *Streptococci* and gram negative bacilli (Chulay and Lankerani 1976). In the rare human cases, a variety of unusual organisms have been reported including *Brucella*, *Actinomyces*, *Pseudomonas* species, *Nocardia*, *Streptococcus*, *Yersinia enterocolitica* and also interestingly, *Salmonella* species. Anaerobic bacteria have been isolated from 5% of splenic abscesses while 24% were found to be sterile (Dubbins 1980). In grass awn migration *Staphylococcus*, *Streptococcus*, *Pasteurella multocida* and more commonly *Actinomyces* species have been isolated (Brennan and Ihrke 1983).

The ultrasonographic appearance of the splenic abscess is quite variable depending on the cellularity of the contents at the time of the scan. They may appear as irregular, poorly-defined anechoic masses, with varying internal echogenicity and acoustic transmission (Pawar and others 1982). In humans, abscesses are usually seen as sonolucent irregular lesions within the splenic substance, splenomegaly and an echogenic area around the sonolucent area indicating an inflammatory reaction (De Graaff and others 1979). In the present case, the echogenic area was not seen, as the abscess appeared to be expanding outwards and not into the parenchyma. Abscesses may be similar in appearance to lymphomatous masses, haematomata and fresh infarcts but the clinical findings may be helpful in disqualifying some of these (De Graaff and others 1979). Some abscesses may contain gas in the cavity and acoustic shadowing may be seen distal to some bright echoes (Pawar and other 1982). The abscess in the present study showed echogenic debris and later became more hypoechoic. According to Hill and Sanders (1978), when compared with haematomata, septa were found to be more common in abscesses than haematomata and to have thicker echo septa. In our case septation was not a feature and neither was the fluid-fluid interface seen in some abscesses in man. Occasionally in an abscess, echogenic material may form a separate layer below an echo-free one resulting in a fluid-fluid interface (Thurber and others 1979). Our findings concur with those of Konde and others (1986), who found most abdominal abscesses to be hypoechoic with none or minimal

enhancement and no abscess walls. In this case, acoustic enhancement and an echogenic abscess wall, were prominent features.

The most common form of canine lymphosarcoma is multicentric characterised by peripheral lymph node or hepatic and splenic enlargement due to infiltration by neoplastic lymphocyte cells. Other forms are more localised, such as alimentary and thymic. Splenic lymphosarcoma has been described in human beings (Skarin and others 1971). The one case of lymphosarcoma in the present series (case no. 8) was multicentric. Hypercalcaemia is mainly associated with immunophenotype, T-cell lymphosarcoma being more common (Weir and others 1988). Dogs with T-cell-type lymphosarcoma have a poorer prognosis than those with B-cell-type (Greenlee and others 1990). In the case presented in this study, the immunophenotype was not established and hypercalcaemia was not a feature.

Lymphosarcoma is one of the malignancies in dogs which respond to chemotherapy and several chemotherapeutic agents have been studied and reported over the years (MacEwen and others 1981). This has led to 80-90% response rates and median survival rates of 250-300 days (Rosenthal and MacEwen 1990). In the treatment of lymphosarcoma, the goal of therapy is prolonged remission and not a cure. In this case a cyclophosphamide, vincristine and prednisolone regime was used. Splenectomy was found to be valuable in the treatment of patients with lymphosarcoma because it removes the greatest source of tumour cells (Moldovanu and others 1966).

In case no. 8 (lymphosarcoma), sonographic splenic lesions were very distinct, poorly-defined, multifocal lesions which were hypoechoic to anechoic areas. According to Bree and Silver (1979), distinguishing between artifactual echoes and real echoes is especially difficult when the mass is smaller than 2 cm. However, Nyland and Kantrowitz (1986), suggested that a mass as small as 5 mm may be identified if its echogenicity is sufficiently different from that of the surrounding parenchyma. Despite radiographic evidence of hepatomegaly, there were no sonographic signs of liver involvement. According to a study by Lamb and others (1991), whereas splenic lymphosarcoma was readily seen, ultrasonography was found to be an insensitive technique for detecting hepatic lymphosarcoma (only 3 out of 14 dogs, had abnormal liver echo-pattern). This contradicts work by other workers (Whiteley and others 1989) who reported a 100% success rate. There is no clear reason for these differences, as the sonographic appearance of lymphosarcoma may be hypoechoic or hyperechoic, while in other cases there may be no change in organ echotexture (Lamb and others 1991). It remains unclear whether ultrasound is insensitive

due to an inadequate spatial resolution, or an inability to make absolute back-scatter measurements or because the cellular infiltrates in lymphosarcoma usually have similar echogenicity to the liver (Lamb and others 1991). The absence of hepatic lesions in an attempt to stage the cancer, does not necessarily mean the organ is uninvolved. Since the hepatic and splenic echogenicities are compared during routine scanning, diseases like lymphosarcoma which involve many organs make this comparison quite unreliable. However in a study by Wrigley and others (1988a), out of 9 dogs that had splenic and liver lymphosarcoma, 8 had reduced splenic echoes when compared to the liver. As an alternative, since the renal cortex is less commonly affected by lymphosarcoma, echo intensities of the other organs may be better compared to this (Wrigley and others 1988a).

Metastatic adenocarcinoma was seen in two cases (nos. 4 & 6) with the primary sites of the neoplasm being pancreas and anal sac, respectively. Primary adenocarcinoma of the spleen does not occur but metastasis of carcinomas from other sites is an infrequent finding (Bartels 1970, Jubb and Kennedy 1970, Taylor 1978). Case no. 6, which had metastatic adenocarcinoma lesions had ultrasonographic evidence of splenic infarcts, probably due to valvular endocarditis, as any disease process causing splenomegaly or embolisation can produce infarction (Schelling and others 1988). Torsion and sickle cell anaemia in man are also examples of common predisposing causes of splenic infarction within each species (Solbiati and others 1983, Maresca and others 1986).

Case no. 6 (adenocarcinoma of the anal sac) showed paraneoplastic hypercalcaemia. In people with malignant neoplasia, metastasis to bone is the most common cause of hypercalcaemia (Muggia and Heinemann 1970). When hypercalcaemia is associated with neoplasia, inactive parathyroid glands and the absence of bone metastases, the syndrome is referred to as pseudohyperparathyroidism (Osborne and Stevens 1973). Several cases of hypercalcaemia associated with anal sac adenocarcinoma have been reported previously (Beebe 1980, Meuten and others 1981). The most common cause of paraneoplastic hypercalcaemia is lymphosarcoma (Osborne and Stevens 1973); other causes being mammary adenocarcinoma and adenocarcinoma of undetermined origin. In humans, several humoral substances such as prostaglandins, osteoclastic-activating factors, vitamin D-like sterols and parathormone-like peptides are produced by tumours and result in hypercalcaemia (Beebe 1980). The mechanisms involved in paraneoplastic hypercalcaemia in dogs are as yet not fully explained (Fox 1995).

Ultrasonographically, metastatic adenocarcinoma had a similar appearance in both cases (nos. 4 & 6) i.e. multiple poorly-defined hypoechoic masses. In man splenic metastases, including carcinoma, generally appear hyperechoic except for focal lymphoma which is normally hypoechoic (Talmont 1980, Cosgrove 1983).

Ultrasonographically the infarcts were well-defined and hypoechoic, with distortion of the splenic margins suggesting the presence of a mass. This mass effect seen in dogs has also been described by Schelling and others (1988). It is not possible sonographically to differentiate these from other splenic masses, such as abscesses, mycotic lesions or metastatic involvement, as was seen case no. 6. In man, however, this effect is not seen, although round infarcts tend to simulate other splenic masses, "wedge-shaped" lesions, when seen, represent a classic splenic infarct (Maresca and others 1986). The shape and sonographic appearance (hypoechoic to hyperechoic) of an infarct tends to change with age of the lesion (Maresca and others 1986).

The normal ultrasonographic appearance of the liver parenchyma is coarsely granular but with a uniform echotexture in which large vessels and the gall bladder are visible (Barr 1990, Lamb 1990). The portal veins are more echogenic than hepatic veins and the gall bladder is anechoic with smooth well-defined margins and acoustic enhancement in the distal tissues.

In these two cases (nos. 4 & 6), hepatic involvement was established using ultrasonography. Complete parenchymal distortion was evident, giving the organs a "moth-eaten" appearance. Case no. 6 had "bull's eye" or target lesions (hyperechoic areas with an anechoic rim around it). The sonographic finding may be caused by a central region of necrosis and haemorrhage, surrounded by more homogeneous tumour (Nyland and Park 1983). The observation of such a halo suggests an expansile mass lesion (Marchal and others 1985). In man echogenic metastases are frequently found in cases of primary colonic cancer (Taylor and Jacobson 1980). Approximately a third of metastatic lesions seen are hypoechoic and originate from various neoplasms including carcinoma (Taylor and Jacobson 1980).

Malignant fibrous histiocytoma (MFH) is the most common soft tissue sarcoma in man but only occurs rarely in dogs, cats, pigs and rats. However, MFH of the canine spleen appears to be more common than that of the human spleen. Metastasis of soft tissue MFH to other organs is very rare, but when it does occur, it affects the liver (Weinstein and others 1989), spleen and kidneys (Tanimoto and others 1988). The tumours are usually locally invasive and

recurrence is also localised and metastasis rare (Rogers and others 1994). Splenic MFH on the other hand, has different biological behaviour which results in very high metastasis. In case no. 10, although no distinct disturbance of the liver echotexture was seen, liver metastasis cannot be discounted. The patient was euthanased due to poor prognosis. In the study of 6 dogs by Hendrick and others (1992), two of the dogs were euthanased due to metastasis by the tumour and one due to unrelated causes, the remaining 3 dogs were alive at the time of publication of the report. Like all the other malignant splenic tumours, MFH appears to be as aggressive as haemangiosarcoma (Weinstein and others 1989) but variants of the tumour may exist (as in humans) to explain the behaviour of this tumour. In humans the distinction between the types of MFH can be clinically useful since the myxoid inflammatory infiltrate appears to have a slightly better prognosis than the storiform/pleomorphic variant (Enzinger and Weiss 1988).

Fine needle aspiration (FNA) was used to obtain a splenic biopsy in case no. 10. Post-biopsy complications in the spleen include haemorrhage, damage to abdominal viscera and localised peritonitis caused by penetration of the intestinal lumen (Osborne and others 1974). Others include the danger of puncturing parasitic cysts and biopsy of less accessible areas is more risky (Livraghi and others 1983). With ultrasound-guided biopsy the risks are reduced as the needle is visualised and guided to the target organ thus increasing accuracy (Smith 1989). Due to the high risk of bleeding, it is recommended that patients to be biopsied must first be evaluated for abnormal haemostasis (Smith 1989). In case no. 10, a blind puncture was done and a specimen was easily obtained due to the size of the mass. Due to the unavailability of the scanning equipment at the time, the patient was not assessed for evidence of post-biopsy bleeding.

In case no. 10, the splenic mass seen was large (10 cm), of mixed echogenicity and well circumscribed. The non-visualisation of normal tissue suggests that the tumour mass may have totally replaced this. Hendrick and others (1992) in a study of 6 dogs also described masses, some of which were greater than 15 cm. A mixed pattern was seen in two cases reported by Rogers and others (1994).

Splenic nodular hyperplasia (SNH) is a benign condition that is well recognised by pathologists but not by clinicians (Stowater and others 1990), as it was initially thought to be subclinical (Moulton 1978). However, more recently, clinical signs have been reported (Stowater and others 1990, Hashimoto and others 1991). All the cases in the present study showed variable clinical signs, some which may not have been directly related to the condition but to other co-

existing diseases (case no. 3). Non-specific signs such as vomiting, weight loss, abdominal pain, anorexia, pallor, lethargy, dullness and syncope (case no. 5), were a feature in this series. These findings were the same as those described by other workers although other additional clinical signs may have been noted. One case reported by Hashimoto and others (1991) showed vomiting, anorexia, blood-tinged faeces and generalised lymphadenopathy, all of which disappeared after splenectomy. Another case (Stowater and others 1990) also had hepatic involvement and showed only signs of abdominal pain. The initial supposition that these lesions did not cause signs may have arisen due to post mortem of dogs with smaller lesions (0.5-3 cm); however, in the reported cases larger masses were found, possibly leading to gastrointestinal disturbances, thrombosis and ischaemia (Moulton 1978) as the masses enlarged. The presence of numerous germinal mitotic figures in case no. 5 does not suggest a neoplastic condition (Moulton 1978). Lymph node biopsies are usually performed in dogs to differentiate SNH from lymphosarcoma.

SNH has a variable ultrasonographic appearance. The hypoechoic speckly echo-pattern has also been described in the case reported by Hashimoto and others (1991), which concurs with the findings in case no. 13. Case no. 3 showed a hyperechoic lesion. The mixed echotexture seen in case no. 5 has been regularly reported (Stowater and others 1990) but only one report in the literature refers to a hyperechoic lesion, as in case no. 3 (Nyland and Park 1983). The mass seen in case no. 5 was very large, measuring 11 cm, implying the involvement of underlying neoplasia. However, a larger SNH mass (16 cm) has been reported (Stowater and others 1990). Because of the vascularity of these lesions, there is a high likelihood of bleeding and ischaemia due to the disturbance of the blood supply, leading to thrombosis. These features may contribute to the variable sonographic appearance. In the case of hepatic nodular hyperplasia, the cells in the lesions become progressively filled with lipid vacuoles and in larger lesions this is compounded by blood supply disturbances (Stowater and others 1990, Fabry and others 1982). Fat is an important contributor to echogenicity (Rosenfield and others 1980, Taylor and others 1986) and therefore may account for the hyperechogenicity of certain lesions in the liver. In case no. 5, hyperechoic lesions in the liver suggested involvement of that organ but these lesions were not confirmed pathologically. The sonographic appearance of SNH mimics that of splenic neoplasia and therefore is an important differential diagnosis for any lesion present in the spleen. This is further complicated by the fact that hyperplastic nodules/splenic haematoma and haemangiosarcoma are found virtually at the same mean age, 10.5 and 10.4 years respectively, according to a study by Spangler and Culbertson (1992). Haemangiosarcoma has always been reported as the most

frequently encountered splenic disease (Brown and others 1985, Johnson and others 1989, Hosgood 1987, Frey and Betts 1977), although a report by Spangler and Culbertson (1992) found that nodular hyperplasia and haematoma are more prevalent than haemangiosarcoma; hyperplastic nodules contributing 23% of all cases and haemangiosarcoma 10%.

In this study, two cases had splenic extramedullary haematopoiesis (EMH), (Case nos. 11 & 12). EMH was the most common cytological diagnosis in a study of splenomegalic dogs sampled using FNA (O'Keefe and Couto 1987). It is associated with a variety of conditions including immune haemolytic anaemia, haemangiosarcoma, eosinophilic gastroenteritis and bone marrow hyperplasia. EMH can occasionally be found in animals with asymptomatic splenomegaly with no evidence of haematological or inflammatory disorders, and in animals with systemic inflammatory processes not involving the spleen; the significance of this is unknown (O'Keefe and Couto 1987). Both these cases (nos. 11 & 12) had conditions which would increase the demand for haematopoiesis: case no. 12 had a subcutaneous haemangiosarcoma and case no. 11 had thrombocytopenia and leukopenia of unknown cause, as the etiology of the nodular lesions was not established. However, since there was haematological recovery following splenectomy, this could be attributed to hypersplenism. Hypersplenism refers to splenomegaly, any combination of cytopenias (anaemia, leukopenia and/or thrombocytopenia), compensatory bone marrow hyperplasia and improvement following splenectomy (Eichener 1979). The pathogenesis of the cytopenias in hypersplenism is usually attributed to increased splenic sequestration or phagocytosis of blood cells and expansion of plasma volume causing dilution of blood cells (Kuehn and Gaunt 1986). Thus, conditions such as splenic vein thrombosis, splenomegaly, agnogenic myeloid metaplasia (EMH) and certain types of leukaemia may lead to the condition (Eichener 1979). One report of hypersplenism of splenomegaly due to EMH and a hypocellular bone marrow (Kuehn and Gaunt 1986) and another of primary hypersplenism have been reported (Sawasima and others 1990). Besides hypersplenism, a large spleen may also, like a genuine tumour, exert pressure on adjacent organs such as the pancreas and gall bladder, causing outflow problems (Bartels 1970)

Sonographically, EMH along with erythropoietic disorders and myeloproliferative diseases, appears as splenomegaly with a normal echoic spleen. This was seen in case no. 12, with a generalised subtle change of the splenic parenchyma due to multiple linear, poorly-defined hypoechoic areas. From the shape of these lesions, it may be concluded that they were dilated intrasplenic blood vessels, as the spleen was quite congested. A similar change

is seen in severe congestion due to torsion, with a hypoechoic spleen and linear echoes separating anechoic areas, representing dilated sinusoids and blood vessels (Konde and others 1989). In case no. 11, there were distinct hypoechoic masses of various sizes. As lesions were distinct in the gross specimen, the error may have arisen due to inadequate sampling. Multiple sections of splenic neoplasms should be examined by the pathologist, because there may be several neoplastic cell types as well as extensive haemorrhage or necrosis which would decrease the chances for obtaining a diagnosis (Weinstein and others 1989).

In the present study, splenic involvement was misdiagnosed during ultrasonography (case no. 14) while at exploratory laparotomy, masses which originated from the liver were found to be overlying the spleen. Vörös and others (1991) suggested that in such cases artificial hydroperitoneum may be used to separate abdominal organs from each other.

This study has described the appearance of splenic haemangioma whose description is lacking in the veterinary literature. The sonographic appearance of splenic metastases from adenocarcinoma has also been described. The importance of splenic disease as a possible life-threatening condition requiring immediate intervention, as seen in case no. 9, has been highlighted. In conclusion, the results of this study have demonstrated the value of ultrasound in canine splenic disease. However, further work should be done on a larger sample size to show the consistency of the diagnostic capability of ultrasonography in canine splenic disease.

Appendix 4.1.

Case no.	Abdominal enlarge.	Palpable mass	Abdominal pain	Vomiting/ diarrhoea	Polyuria/ polydipsia	Anorexia	Pale membranes	Weight loss	Collapse	Lethargy/ dullness	Respiratory signs
1	-	-	-	+	-	-	-	-	-	-	+
2	+	+	+	-	+	+	+	-	-	+	+
3	-	+	+	+	-	-	-	+	-	+	+
4	-	-	+	+	-	-	-	-	-	+	-
5	+	+	+	-	-	-	-	-	+	-	-
6	-	-	-	+	+	+	-	-	-	-	-
7	-	-	+	+	-	+	+	+	-	+	-
8	-	+	-	-	-	-	-	+	-	-	-
9	+	+	+	-	+	+	+	+	+	+	-
10	+	+	-	-	+	+	+	-	-	+	+
11	-	+	+	-	-	-	-	-	-	+	-
12	-	+	-	-	-	+	-	-	-	+	-
13	+	+	-	-	+	+	+	+	-	+	-

- = not seen

+ = seen

Clinical signs of the 13 dogs with splenic disease

Appendix 4.2.

Case no.	RBC	Hb	Hct	MCV	MCH	MCHC	Plt.	MPV	PCT	PDW	WBC	Band	Seg. Neutro.	Lympho- cytes	Mono- cytes	Eosino- phils	Normo- blasts
	10 ¹² /L	g/dl	%	fL	pg	g/dl	10 ⁹ /L	fL	%		10 ⁹ /L		10 ⁹ /L	10 ⁹ /L	10 ⁹ /L	10 ⁹ /L	10 ⁹ /L
1	7.26	17.8	53	73	24.5	33.5	94	9.1	0.085	19.7	4	0	3.12	0.54	0.14	0.2	-
2	4.04	8.3	25.4	63	20.5	32.6	160	10	0.16	22	19.5	0	18.135	1.072	0.292	0	-
3	6.72	15.7	49.5	74	23.3	31.7	168	11.1	0.186	18	24.4	0.61	20.13	2.196	0.976	0.122	-
4	6.94	16.5	51.1	63	23.7	32.2	229 (A)	-	-	-	12.8	0	9.344	2.56	0.256	0.64	-
6	6.69	15.3	45.7	68	22.8	33.4	(A)	-	-	-	17.2	0.172	14.96	0.602	1.032	0.43	-
7	4.18	8.8	28.7	69	21	30.6	98	11.1	0.108	24.3	20.1	0.1	17.487	1.206	0.804	0.1	0.402
8	6.43	13.9	42.2	66	21.6	32.9	(A)	-	-	-	5.5	0	4.262	0.888	0.247	0.11	-
9	3.17	8.2	24.1	76	25.8	34	189	-	-	-	9.6	0	6.43	1.2	0.144	0.576	-
11	6.23	14.7	41.2	66	23.5	35.6	100	8.5	0.085	18.8	3.5	0	2.52	0.525	0.315	0.122	-
12	5.18	13.2	36.2	70	25.4	36.4	329	7.1	0.233	15.4	17.5	0	14.437	2.625	0.437	0	0
13	5.22	9.2	30.6	59	17.6	30	433	11	0.476	20	22.7	0	20.43	1.589	0.681	0	0

Plt. = Platelets; MPV= mean platelet volume; PCT= Plateletcrit; PDW= platelet distribution width
MCV = mean corpuscular volume; Neutro. = neutrophils
- = normal; A = aggregated

Haematology results for the 11 dogs whose results were available.

Appendix 4.3.

ASSAY (Units)	1	2	3	4	5	CASE NO.	6	7	8	9	10	11	12	13
Urea (mmol/L)	4.4	10.8	2.4	2	5.4	2.1	4.8	9.6	3	13.4	7.1	5.1	5.2	
Sodium (mmol/L)	147	143	-	144	130	142	143	149	143	153	149	146	141	
Potassium (mmol/L)	3.9	4.6	5.9	4.8	3.6	4.5	4.2	4	3.7	5.2	4	3.3	3.7	
Chloride (mmol/L)	110	108	105	123	105	119	114	115	112	110	114	110	106	
Calcium (mmol/L)	2.47	2.44	2.39	2.22	2.43	4.64	2.5	2.43	2.57	2.35	2.62	2.28	2.7	
Magnesium (mmol/L)	0.61	0.67	0.68	-	0.59	0.46	0.9	0.62	-	0.94	0.96	0.82	1.01	
Phosphate (mmol/L)	0.77	1.91	1.14	1	1.18	1.99	1.4	1.22	1.24	1.64	1.05	1.11	2.06	
Glucose (mmol/L)	-	5.7	-	5	4.9	4.6	4.8	5.3	6.3	-	-	5.8	-	
Cholesterol (mmol/L)	4.38	5.66	7.3	7.9	3.01	-	6.4	2.49	5.31	6.1	6.35	6.61	4.8	
Creatinine (μmol/L)	130	92	69	36	83	-	106	95	94	111	73	90	83	
Bilirubin (μmol/L)	0	4	0	35	1	2	2	2	1	-	0	1	0	
SAP (IU/L)	25	87	248	2229	310	198	55	51	104	41	98	47	638	
AST (IU/L)	22	62	33	973	17	62	34	31	38	207	20	23	33	
ALT (IU/L)	35	-	24	349	17	89	70	31	23	-	38	33	30	
TP (g/L)	73	60	77	58	113	70	57	56	57	76	59	66	90	
Albumin (g/L)	37	31	30	24	24	30	31	35	25	35	31	32	33	
Globulin (g/L)	36	29	47	34	89	40	26	21	32	41	28	34	57	

- = not done

TP = total protein

Biochemistry results for the 13 dogs in the study.

Appendix 4.4.

Haematology	Normal range
MCV (fl)	60-75
Hct (%)	35-50
Hb (g/dl)	12-18
RBC (10 ¹² /L)	5.5-8.5
WBC (10 ⁹ /L)	6-13
Neutro. (10 ⁹ /L)	3-11.8
Lympho. (10 ⁹ /L)	1-4.8
Mono. (10 ⁹ /L)	0.15-1.35
Eosino. (10 ⁹ /L)	0.1-1
MCH (pg)	19-20
MCHC (g/dl)	33-37
Platelets (10 ⁹ /L)	200-500

Biochemistry	Normal range
Urea (mmol/L)	3-8
Sodium (mmol/L)	136-160
Potassium (mmol/L)	3-6
Chloride (mmol/L)	95-110
Calcium (mmol/L)	2.3-3
Phosphate (mmol/L)	1.3-3
Glucose (mmol/L)	2.5-5
Cholesterol (mmol/L)	3-6.5
Creatinine (μmol/L)	45-130
Bilirubin (μmol/L)	0-10
SAP (IU/L)	<230
AST (IU/L)	<35
ALT (IU/L)	<35
T. protein (g/L)	50-80
Albumin (g/L)	30-35
Globulin (g/L)	30-35

Normal values for haematology and biochemistry results

List of References

- Ackerman N. and Silverman S.** (1978) Radiographic interpretation of splenic disease. *Modern Veterinary Practice* **59**, 53-57.
- Aronsohn M.** (1985) Cardiac haemangiosarcoma in the dog: a review of 38 cases. *Journal of the American Veterinary Medical Association* **187** (1), 922-926.
- Aster R.H.** (1966) Pooling of platelets in the spleen: role in the pathogenesis of "hypersplenic" thrombocytopenia. *Journal of Clinical Investigation* **45** (5), 645-657.
- Banks W.J.** (1993) The Lymphatic System and Immunity. Applied Veterinary Histology, third edition. Mosby. Philadelphia. pp 277-297.
- Barcroft J.** (1930) Alterations in the volume of the normal spleen and their significance. *American Journal of Medical Sciences* **179**, 1-10.
- Bardet J.F., Weisbrode S. and Dehoff W.D.** (1983) Extraskkeletal osteosarcoma: Literature review and a case report. *Journal of American Animal Hospital Association* **19**, 601-604.
- Barr F.** (1990) Diagnostic Ultrasound in the Dog and Cat. Blackwell Scientific Publications. Oxford. pp 1-20, 36-45.
- Bartels S P.** (1970) Indications for splenectomy and post-operative survival rate. *Journal of Small Animal Practice* **10**, 781-785.
- Barton C.L.** (1981) The Spleen: pathophysiology of disease. In Bojrab M.J. (editor) Pathophysiology in Small Animal Surgery. Lea and Febiger. Philadelphia. pp 502.
- Bartrum R.J. and Crow L.H.** (1977) Gray-scale Ultrasonography: A manual for physicians and technical personnel. W.B. Saunders Company. Philadelphia. pp 1-67.
- Beebe M.A.** (1980) Pseudohyperparathyroidism associated with adenocarcinoma in a dog. *Modern Veterinary Practice* **61** (7), 582-585.
- Berendes M.** (1959). The proportion of reticulocytes in the erythrocytes of the

spleen as compared with those of the circulating blood with special reference to haemolytic states. *Blood* 4, 558-563.

Bingel S.A., Brodey R.S., Allen H.L. and Riser W.H. (1974) Haemangiosarcoma of bone in the dog. *Journal of Small Animal Practice* 15, 303-322.

Bloom M.W. and Fawcett D.W. (1968) The Spleen. In Textbook of Histology, ninth edition. W.B. Saunders Company. Philadelphia. London. Toronto. pp 403-416.

Bree R.L. and Silver T.M (1979) Differential diagnosis of hypoechoic and anechoic masses with gray-scale sonography: New observations. *Journal of clinical Ultrasound* 7, 249-254.

Brennan K.E. and Ihrke P.J. (1983) Grass awn migration in dogs and cats: A retrospective study of 182 cases. *Journal of the American Veterinary Medical Association* 182 (11), 1201-1204.

Brizel H.E. and Raccuglia G. (1965) Giant haemangioma with thrombocytopenia. *Blood* 26 (6), 751-756.

Brodey R.S. (1964) Vascular tumours of the canine spleen. *Modern Veterinary Practice* 45, 39-46.

Brown N.O. (1985) Haemangiosarcomas. *Veterinary Clinics of North America (Small Animal Practice)* 15, 569-575.

Brown N.O., Patnaik A.K. and MacEwen E.G. (1985) Canine haemangiosarcoma: retrospective analysis of 104 cases. *Journal of the American Veterinary Medical Association* 186 (1), 56-58.

Caldarera E. (1938) Acute abscess of the spleen. *Surgical Gynaecology and Obstetrics* 67, 265-268.

Chulay J.D. and Lankerani M.R. (1976) Splenic abscess. *The American Journal of Medicine* 61, 513-522.

Coakley W.T., Slade J.S. and Braeman J.M. (1972) Examination of lymphocytes for chromosome aberrations after ultrasonic irradiation. *British Journal of Radiology* 45, 328-332.

Coelho J.C.U., Sigel B., Ryva J.C., Machi J.M. and Renigers S.A. (1982). B-Mode sonography of blood clots. *Journal of Clinical Ultrasound* **10**, 323-327.

Constantopoulos A., Najjar V.A., Wish J.B., Necheles T.H. and Stolbach L.L (1973) Defective phagocytosis due to tuftsin deficiency in splenectomised subjects. *American Journal of Diseases of Children* **125**, 663-665.

Cosgrove D.O. (1983) The Abdomen. In Goldberg B.B. and Wells P.N.T. *Ultrasonics in Clinical Diagnosis*, third edition. Churchill Livingstone. Edinburgh. P 57-86.

Couto C.G. (1989) Diseases of the Lymph nodes and Spleen. In Ettinger S.J. *Textbook of Veterinary Internal Medicine*, third edition. W.B. Saunders Company. Philadelphia. pp 2225-2245.

Couto C.G. (1990). A diagnostic approach to splenomegaly in cats and dogs. *Veterinary Medicine* **85**, 220-228.

Crosby W.H. (1959). Normal functions of the spleen relative to red blood cells: A review. *Blood* **14**, 399-408.

Crosby W.H. (1963). Hyposplenism: An inquiry into normal functions of the spleen. *Annals of Review Medicine* **14**, 349-369.

Crosby W.H. (1977) Splenic remodelling of red cell surfaces. *Blood* **50** (4), 643-645.

De Graaff C.S., Taylor K.J.W. and Jacobson P. (1979). Gray-scale echography of the spleen: follow-up in 67 patients. *Ultrasound Medicine and Biology* **5**, 13-21.

Doust B.D., Quiroz F. and Stewart J.M. (1977) Ultrasonic distinction of abscesses from other intra-abdominal fluid collections. *Radiology* **125**, 213-218.

Dubbins P.A. (1980) Ultrasound in the diagnosis of splenic abscess. *British Journal of Radiology* **53**, 488-489.

Edell S.L and Gefter W.B. (1979) Ultrasonic differentiation of types of ascitic fluid. *American Journal of Roentgenology* **133**, 111-114.

Eichener E.R (1979) Splenic function: Normal, too much and too little. *The American Journal of Medicine* **66**,311-320.

Enzinger F.M. and Weiss S.W. (1988) Soft Tissue Tumours, second edition. Mosby. St. Louis. pp 273-299.

Erakis M.D., Kevy S.V., Diamond L.K. and Gross R.E. (1967) Infection after splenectomy. *The New England Medical Journal* **276** (22), 1225-1229.

Ettinger S.J. (1989) Textbook of Veterinary Internal Medicine, third edition. W.B. Saunders Company. Philadelphia. pp131-138.

Fabry A., Benjamin S.A. and Angleton G.M. (1982) Nodular hyperplasia of the liver in the beagle dog. *Veterinary Pathology* **19**, 109-119.

Feeney D.A., Johnson G.R and Hardy R.M. (1984) Two-dimensional gray-scale ultrasonography for assessment of hepatic and splenic neoplasia in the dog and cat. *Journal of the American Veterinary Medical Association* **184** (1), 68-80.

Fox L.E. (1995) The paraneoplastic disorders. In Kirk's Current Veterinary Therapy (Small Animal Practice). W.B. Saunders Company, Philadelphia. pp 530-542.

Frey F.J. and Betts C.W. (1977) Splenectomy in the dog. *Journal American Animal Hospital Association* **13**, 730-734.

Gelberg H. and Stackhouse L.L. (1977) Three cases of canine acanthocytosis associated with splenic neoplasia. *Veterinary Medicine* **72**, 1183-1184.

Greenlee P.G., Fillipa D.A., Quimby F.W., Patnaik A.K., Calvano S.E., Matus R.E., Kimmel M., Hurvitz A.I. and Lieberman P.H. (1990) Lymphoma in dogs. *Cancer* **66** (3), 480-489.

Hammer A.S., Couto C.G., Swardson C. and Getzy D. (1991) Haemostatic abnormalities in dogs with haemangiosarcoma. *Journal of Veterinary Internal Medicine* **5**, 11-14.

Hanson J.A. and Penninck D.G. (1994) Ultrasonographic evaluation of a traumatic splenic haematoma and literature review. *Veterinary Radiology and Ultrasound* **35** (6), 463-466.

Hardy W.D. (1981) Haematopoietic tumours of cats. *Journal of the American Animal Hospital Association* **17**, 921.

Harvey J.W. (1980) Canine haemolytic anaemia. *Journal of the American Veterinary Medicine Association* **176** (10), 970-974.

Hashimoto A., Kudo T. and Suzuki H. (1991) Nodular hyperplasia of the spleen in a dog. *Research Bulletin of the Faculty of Agriculture, Gifu University* **56**, 147-155.

Helfand S.C. (1988) Platelets and neoplasia. *Veterinary Clinics of North America (Small Animal Practice)* **18** (1), 131-155.

Helfand S.C., Couto C.G. and Madewell B.R. (1985) Immune-mediated thrombocytopenia associated with solid tumour in dogs. *Journal American Animal Hospital Association* **21**, 787-794.

Hendrick M.J., Brooks J.J. and Bruce E.H. (1992) Six cases of malignant fibrous histiocytoma of the canine spleen. *Veterinary Pathology* **29**, 351-354.

Henley R.K., Hager D.A. and Ackerman N. (1989) A comparison of two-dimensional ultrasonography and radiography for the detection of small amounts of free peritoneal fluid in the dog. *Veterinary Radiology* **30** (3), 121-124.

Herring D.S. and Bjornton G. (1989) Physics, facts and artifacts of diagnostic ultrasound. *Seminars in Veterinary Medicine and Surgery (small animal)* **4** (1), 2-12.

Hill M. and Sanders R.C. (1978) Gray-scale characteristics of intra-abdominal cystic masses. *Journal of Clinical Ultrasound* **6**, 217-221.

Hill-Zobel R.L., McCandless B., Kang S.A., Chikkappa G. and Tsan M. (1986) Organ distribution and fate of human platelets: studies of asplenic and splenomegalic patients. *American Journal of Hematology* **23**, 231-238.

Hirsch V.M., Jacobson J. and Mills J.H.L. (1981) A retrospective study of canine haemangiosarcoma and its association with acanthocytosis. *Canadian Veterinary Journal* **22**,152-155.

Hirsh J. and Dacie J.V. (1966) Persistent post-splenectomy thrombocytosis and thromboembolism: A consequence of continuing anaemia. *British Journal of Haematology* **12**, 44-56.

Holt D., Winkle T.V., Schelling C. and Prymak C. (1992) Correlation between thoracic radiographs and postmortem findings in dogs with haemangiosarcoma: 77 cases (1984-1989). *Journal of the American Veterinary Medical Association* **200** (10), 1535-1539.

Hosgood G. (1987) Splenectomy in the dog: A retrospective study of 31 cases. *Journal of the American Animal Hospital Association* **23**, 277-283.

Hurley R.E. and Stone M.S. (1994) Isolated torsion of the splenic pedicle in a dog. *Journal of the American Animal Hospital Association* **30**, 119-122.

Ishmael J. and Howell J.M. (1968) Neoplasia of the spleen of the dog with a note on nodular hyperplasia. *Journal of Comparative Pathology* **78**, 59-66.

Jabara A.G. and McLeod B.J. (1988) A primary extraskkeletal osteogenic sarcoma arising in the spleen of a dog. *Australian Veterinary Journal* **66**, 27-29.

Jacobsen E. and Plum C.M. (1942) The role of the reticuloendothelial system in the ripening of reticulocytes. *Acta Physiology Scandinavica* **5**, 5- 12.

Jaffe C.C. and Taylor K.J.W. (1979) The clinical impact of ultrasonic beam focusing patterns. *Radiology* **131**, 469-472.

Jandl J.H. and Aster R.H. (1967) Increased splenic pooling and the pathogenesis of hypersplenism. *American Journal of the Medical Sciences* **253**, 383-397.

Johnston D.E. and Summer B.A. (1971) Osteomyelitis of the lumbar vertebrae in dogs caused by grass seed foreign bodies. *Australian Veterinary Journal* **47**, 289-294.

- Johnson K.A., Powers B.E., Withrow S.J ., Sheetz M.J., Curtis C.R and Wrigley R.H.** (1989) Splenomegaly in dogs: predictors of neoplasia and survival after splenectomy. *Journal of Veterinary Internal Medicine* **3**,160-166.
- Jones C.L.** (1979) Pericardial effusion in the dog. *Compendium of Continuing Education for the Practicing Veterinarian* **1**, 680-684.
- Jubb K.V.F. and Kennedy P.C.** (1970) Pathology of Domestic Animals. volume 2. Academic Press. New York. pp 239-249.
- Kealy K.J.** (1979) Diagnostic Radiology of the Dog and Cat. W.B. Saunders Company. Philadelphia. pp 34-37.
- King J.M.** (1993) Splenic nodular hyperplasia and myelolipoma in a dog. *Veterinary Medicine* **88** (2), 104-105.
- Kleine L.J.** (1984) Interpreting radiographic signs of abdominal disease in cats and dogs. *Veterinary Medicine* **79**, 1489-1497.
- Kleine W., Zook B.C. and Munson T.O.** (1970) Primary cardiac haemangiosarcoma in dogs. *Journal of the American Veterinary Medical Association* **157**, 326-337.
- Knapp D.W., Aronsohn M.G. and Harper N.K.** (1993).Cardiac arrhythmias associated with mass lesions on the canine spleen. *Journal of the American Animal Hospital Association* **29**, 122-128.
- Kolata R.J. and Johnston E.** (1975) Motor vehicle accidents in urban dogs: A study of 600 cases. *Journal of the American Veterinary Medical Association* **167** (10), 938-940.
- Konde L.J., Lebel J.L., Park R.D. and Wrigley R.H.** (1986) Sonographic application in the diagnosis of intra-abdominal abscess in the dog. *Veterinary Radiology* **27** (4), 151-154.
- Konde L.J., Wrigley R.H., Lebel J.L., Park R.D., Pugh C. and Finn S.** (1989) Sonographic and radiographic changes associated with splenic torsion in the dog. *Veterinary Radiology* **30** (1), 41-45.
- Kremkau F.W. and Taylor K.J.W.** (1986) Artifacts in ultrasound imaging.

Krumbhaar E.B. (1932) The changes produced in the blood picture by removal of the normal mammalian spleen. *American Journal of Medical Science* 184, 215-237.

Kuehn N.F. and Gaunt S.D. (1986) Hepatocellular marrow and extramedullary haematopoiesis in a dog: haematologic recovery after splenectomy. *Journal of the American Veterinary Medical Association* 188 (11), 1313-1315.

Laing C.F. (1983) Commonly encountered artifacts in clinical ultrasound. *Seminars in Ultrasound* 4 (1), 27-43.

Lamb C.R. (1990) Abdominal ultrasonography in small animals: Examination of the liver spleen and pancreas. *Journal of Small Animal Practice* 31, 6-15

Lamb C.R., Hartzband L.E., Tidwell A.S. and Pearson S.H. (1991) Ultrasonographic findings in hepatic and splenic lymphosarcoma in dogs and cats. *Veterinary Radiology* 32 (3), 117-120.

Lang J., Wortman J.A. and Glickman L.T. (1986) Sensitivity of radiographic detection of lung metastasis in the dog. *Veterinary Radiology* 27, 74-78.

Legendre A.M. and Krehbiel J.D. (1977) Disseminated intravascular coagulation in a dog with haemothorax and haemangiosarcoma. *Journal of the American Veterinary Medical Association* 171 (10), 1070-1071.

Levéillé R., Partington B.P., Biller D.S. and Miyabashi T. (1993). Complications after ultrasound-guided biopsy of abdominal structures in cats and dogs: 246 cases. *Journal of the American Veterinary Medical Association* 203 (3), 413-415.

Likhite V.V. (1976) Immunological impairment and susceptibility to infection after splenectomy. *Journal of the American Medical Association* 236 (12), 1376-1377.

Liska W.D., MacEwen E.G., Zaki F.A. and Garvey M. (1979) Feline systemic mastocytosis: a review and results of splenectomy in seven cases. *Journal of the American Animal Hospital Association* 15, 589-597.

- Livraghi T., Damascelli B., Lombardi C. and Spagnoli I.** (1983) Risk in fine needle abdominal biopsy. *Journal of Clinical Ultrasound* **11**, 77-81.
- Lorber M.** (1958) The effects of splenectomy on the red cells of the dog with particular emphasis on the reticulocyte response. *Blood* **13**, 972-985.
- Lord P.F., Halliwell W.H., Carb A. and Preuter J.C.** (1982) Emphysematous hepatic abscess associated with trauma, necrotic hepatic nodular hyperplasia and adenoma in a dog: a case history report. *Veterinary Radiology* **23** (2), 46-49.
- Lupien C. and Sauerbrei E.** (1984) Healing in the traumatised spleen: Sonographic investigation. *Radiology* **151**, 181-185.
- MacEwen E.G., Brown N.O., Patnaik A.K., Hayes A.A. and Passe S.** (1981) Cyclic combination chemotherapy of canine lymphosarcoma. *Journal of the American Veterinary Medicine Association* **178**, 1178-1181.
- Macintosh I.J.C. and Davey D.A.** (1970) Chromosomal aberration induced by an ultrasonic foetal pulse detector. *British Medical Journal* **4**, 92-93.
- Macintosh I.J.C. and Davey D.A.** (1972) Relationship between intensity of ultrasound and induction of chromosome aberrations. *British Journal of Radiology* **45**, 320-327.
- Madewell B.R. and Feldman B.F.** (1980) Characterisation of anaemias associated with neoplasia in small animals. *Journal of American Veterinary Medical Association* **176**, 419-425.
- Marchal G.J., Pylyser K., Tshibwabwa E.A., Verbeken E.K., Oyen R., Baert A.L. and Lauweryns J.M.** (1985) Anechoic halo in solid liver tumours: sonographic, microangiographic, and histologic correlation. *Radiology* **156**, 479-483.
- Maresca G., Mirk P., Gaetano A., Barbaro B. and Colagrande C.** (1986) Sonographic patterns in splenic infarct. *Journal of Clinical Ultrasound* **14**, 23-28.
- McBride J.A. and Jacob H.S.** (1970) Abnormal kinetics of red cell

membrane cholesterol in acanthocytes: studies in genetic and experimental abetalipoproteinemia and spur cell anaemia. *British Journal of Haematology* **18**, 383-397.

McNee J.W. (1931) The spleen: Its structure, functions and diseases. *Lancet* **1**, 951-957.

Meuten D.J., Cooper B.J., Capen D.J. and Kociba G.J. (1981) Hypercalcaemia associated with an adenocarcinoma derived from the apocrine glands of the anal sac. *Veterinary Pathology* **18** (4), 454-471.

Mittelstaedt C.A. and Partain C.L. (1980) Ultrasonic-pathological classification of splenic abnormalities: Gray-scale patterns. *Radiology* **134**, 697-705.

Moldovanu G., Friedman M. and Miller D.G. (1966) Treatment of canine malignant lymphoma with surgery and chemotherapy. *Journal of the American Veterinary Medical Association* **148** (2), 153-156.

Moulton J.E. (1978) Tumours of Domestic Animals. University of California Press. Berkeley. pp 273-275.

Muggia F.J. and Heinemann H.O. (1970) Hypercalcaemia associated with neoplastic disease. *Annals of Internal Medicine* **73**, 281-290.

Ng C.Y. and Mills J.N. (1985). Clinical and haematological features of haemangiosarcoma in dogs. *Australian Veterinary Journal* **62**, 1-4.

Nielsen S.W. (1983) Classification of tumours in dogs and cats. *Journal of American Animal Hospital Association* **19**, 13-60.

Nyland T.G. and Park R.D. (1983) Hepatic ultrasonography in the dog. *Veterinary Radiology* **23**, 74-78.

Nyland T.G. and Hager D.A. (1985) Sonography of the liver, gall-bladder and spleen. *Veterinary Clinics of North America (Small Animal Practice)* **15**, 1123-1148.

Nyland T.G. and Kantrowitz B.M. (1986) Ultrasound in the Diagnosis and Staging of Abdominal Neoplasia. In Gorman N.T. Oncology, Volume 6. Churchill Livingstone. New York. pp 1-24.

Nyland T.G., Hager D.A. and Herring D.S. (1989) Sonography of the liver, gall bladder and spleen. *Seminars in Veterinary Medicine and Surgery* **4** (1), 13-31.

Ogilvie G.K. (1993) Alterations in metabolism and nutrition support for veterinary cancer patients: Recent advances. *Compendium on Continuing Education for the Practicing Veterinarian* **15** (7), 925-936.

O'keefe D. and Couto C.G. (1987) Fine needle aspiration of the spleen. *Journal of Veterinary Internal Medicine* **1** (3), 102-109.

Osborne C.A. (1974a) General principles of biopsy. *Veterinary Clinics of North America (Small Animal Practice)* **4** (2), 213-232.

Osborne C.A. (1974b) Needle biopsy of the spleen. *Veterinary Clinics of North America (Small Animal Practice)* **4** (2), 311-316.

Osborne C.A. and Stevens J.B. (1973) Pseudohyperparathyroidism in the dog. *Journal of the American Veterinary Medicine Association* **162**, 125-135.

Osborne C.A., Perman V. and Stevens J.B. (1974) Needle biopsy of the spleen. *Veterinary Clinics of North America (Small Animal Practice)* **4** (2), 311-316.

Park R.D., Nyland T.G., Lattimer J.C., Lebel J.L. and Miller C.W. (1981) B-Mode gray-scale ultrasound: imaging artifacts and interpretation principles. *Veterinary Radiology* **22** (5), 204-210.

Pawar P., Kay C.J., Gonzalez R., Taylor K.J.W. and Rosenfield A.T. (1982) Sonography of splenic abscess. *American Journal of Roentgenology* **138**, 259-262.

Pearson G.R. and Head K.W. (1976) Malignant haemangioendothelioma (angiosarcoma) in the dog. *Journal of Small Animal Practice* **17**, 737-745.

Pechman R.D. (1994) The Liver and Spleen. In Thrall D.E. Textbook of Veterinary Diagnostic Radiology, second edition. W.B. Saunders Company. Philadelphia. pp 426-435.

Prymak C., Mckee L.J., Goldschmidt M.H. and Glickman L.T. (1988)

- Epidemiological, clinical, pathological, prognostic characters of splenic haemangiosarcomas and splenic haematomas in dogs: 217 cases (1985). *Journal of the American Veterinary Medical Association* **193** (6), 706-712.
- Pulley L.T. and Stannard A.A.** (1978) Skin and Soft Tissues. In Moulton J.E. Tumours of Domestic Animals. University of California Press. Berkeley. pp 45-48.
- Rantanen N.W. and Ewing R.L.** (1981) Principles of ultrasound application in animals. *Veterinary Radiology* **22** (5), 196-203.
- Rebar A.H., Hahn F.F., Denicola D.B. and Benjamin S.A.** (1980) Microangiopathic haemolytic anaemia associated with radiation-induced haemangiosarcomas. *Veterinary Pathology* **17**, 443-454.
- Robinson W.L.** (1928) Some points on the mechanism of filtration by the spleen. *American Journal of Pathology* **4**, 309-319.
- Rogers K.S., Helman R.G., Hurley K.J. and Earley J.W.** (1994) Splenic malignant fibrous histiocytoma in two dogs. *Journal of the American Animal Hospital Association* **30**, 253-256.
- Root C.R.** (1974) Interpretation of abdominal survey radiography. *Veterinary Clinics of North America (Small Animal Practice)* **4**, 763-804.
- Root C.R.** (1994) Abdominal masses. In Thrall D.E. Textbook of veterinary diagnostic radiology, second edition. W.B. Saunders Company. Philadelphia. pp. 388-435.
- Rosenfield A.T., Taylor K.J.W. and Jaffe C.C.** (1980) Clinical applications of ultrasound tissue characterisation. *Radiological Clinics of North America* **18** (1), 31-58.
- Rosenthal R.C. and MacEwen E.G.** (1990) Treatment of lymphoma in dogs. *Journal of the American Veterinary Medical Association* **195** (5), 774-781.
- Rubin J.M., Adler R.S., Bude R.O., Fowlkes B.J. and Carson P.L.** (1991) Clean and dirty shadowing at ultrasound: a reappraisal. *Radiology* **181**, 231-236.

- Sawasima K., Shitaka H., Sawasima Y. and Maede Y. (1990)** Primary hypersplenism in a dog. *Journal of the Japan Veterinary Medical Association* **43** (3), 203-206.
- Schelling C.G., Wortman J.A., and Saunders H.M. (1988)** Ultrasonic detection of splenic necrosis in the dog. *Veterinary Radiology* **29**, 227-233.
- Shirley I.M., Blackwell R.J., Cussick G., Farman D.J. and Vicary F.R. (1978)** A User's Guide to Diagnostic Ultrasonography. Pitman Medical. Kent. pp 1-15.
- Sigel B., Coelho J.C.U. and Spigos D.G. (1980)** Ultrasonography of blood during stasis and coagulation. *Investigative Radiology* **16**, 71-76.
- Singer K. and Weisz L. (1945)** The life cycle of the erythrocyte after splenectomy and the problems of splenic haemolysis and target cell formation. *American Journal of Medical Science* **210**, 301-323.
- Sisson D., Thomas W.P. and Ruehl W.W. (1984)** Diagnostic value of pericardial fluid analysis in the dog. *Journal of the American Veterinary Medical Association* **184**, 51-55.
- Skarin A.T., Davey F.R. and Maloney W.C. (1971)** Lymphosarcoma of the spleen. *Archives of Internal Medicine* **127**, 259-265.
- Skolnick M.L., Meire H.B. and Lecky J.W. (1975)** Common artifacts in diagnostic scanning. *Journal of Clinical Ultrasound* **3** (4), 273-280.
- Slappendel R.J. (1988)** Disseminated intravascular coagulation. *Veterinary Clinics of North America (Small Animal Practice)* **18** (1), 169-184.
- Smith S. (1989)** Ultrasound-guided biopsy. *Seminars in Veterinary Medicine and Surgery (small animal)* **4** (6), 95-104.
- Smolowitz R.M. and Carpenter J.L. (1988)** Canine splenic sarcomas with an osteosarcomatous component. *Veterinary Pathology* **25**, 246-248.
- Solbiati L., Bossi C.M., Bellotti E., Ravetto C. and Montali G. (1983)** Focal lesions in the spleen: sonographic patterns and guided biopsy. *American Journal of Roentgenology* **140**, 59-65.

Spangler W.L. and Culbertson M.R. (1992) Prevalence, type and importance of canine splenic disease: 1480 cases (1985-1989). *Journal of American Veterinary Medical Association* **200** (6), 829-834.

Spaulding K.A. (1993) Sonographic evaluation of peritoneal effusion in small animals. *Veterinary Radiology and Ultrasound* **34**, 427-431.

Spiers S., Carlson G.P., Nyland T.G., Synder J.R. and Fisher P.E. (1986) Splenic haematoma and abscess as a cause of chronic weight loss in a horse. *Journal of American Veterinary Medical Association* **189** (5), 557-559.

Spirer Z., Zakuth V., Diamant S., Mondorf W., Stefanescu T., Stabinsky Y. and Fridkin M. (1977) Decreased tuftsin concentration in patients who have undergone splenectomy. *British Medical Journal* **2**, 1574-1576.

Srebernik N. and Appleby E.C. (1991) Breed prevalence and sites of haemangioma and haemangiosarcoma in dogs. *Veterinary Record* **129** (18), 408-409.

Stevenson S., Chew D.J. and Kociba G.J. (1981) Torsion of the splenic pedicle in the dog: a review. *Journal of the American Animal hospital association* **17**, 239-244.

Stouffer J.R. and Westervelt M.S. (1977) A review: applications in animal science reverberations in echocardiograms. *Journal of Clinical Ultrasound* **5**, 124-128.

Stowater J.L., Lamb C.R. and Schelling S.H. (1990) Ultrasonographic features of canine hepatic nodular hyperplasia. *Veterinary Radiology* **31** (5), 268-272.

Suter P.F. (1982) Radiographic diagnosis of liver disease in dogs and cats. *Veterinary Clinics of North America (Small Animal Practice)* **12**, 153-

Swan R.A. (1968) Splenitis in horses. *Australian Veterinary Journal* **44**, 459-461.

Talmont C.A. (1980) Spleen. In Taylor K.J.W., Jacobson P., Talmont C.A. and Winters R. Manual of ultrasonography. Churchill Livingstone. New York. pp 157-164.

- Tanimoto T., Ohtsuki H., Takashi R. and Nomura Y.** (1988) Malignant fibrous histiocytoma in the spleen of a pig. *Veterinary Pathology* **25**, 330-332.
- Taylor K.J.W.** (1978) Atlas of Grey Scale ultrasound. Churchill Livingstone. New York. pp 1-14.
- Taylor K.J.W.** (1985) Atlas of ultrasonography, second edition. Churchill Livingstone. New York. pp 1-23, 472.
- Taylor K.J.W. and Milan J.** (1976) Differential diagnosis of chronic splenomegaly by gray-scale ultrasonography: Clinical observations and digital A-scan analysis. *British Journal of Radiology* **49**, 519-525.
- Taylor K.J.W. and Jacobson P.** (1980) Liver. In Taylor K.J.W., Jacobson P., Talmont C.A. and Winters R. Manual of Ultrasonography. Churchill Livingstone. New York. pp 97-125.
- Taylor K.J.W., Jacobson P. and Jaffe C.C.** (1979) Lack of an acoustic shadow on scans of gallstones: A possible artifact. *Radiology* **131**, 463-464.
- Taylor K.J.W., Jacobson P., Talmont C.A. and Winters R.** (1980) Manual of Ultrasonography. Churchill Livingstone, New York. pp 1-45.
- Taylor K.J.W., Riely C.A., Hammers L., Flax S., Weltin G., Garcia-Tsao G., Conn H.O., Kuc R. and Barwick K.W.** (1986) Quantitative ultrasound attenuation in normal liver and in patients with diffuse liver disease: importance of fat. *Radiology* **160**, 65-71.
- Teske E., Van Heerde P., Rutteman R., Kurzman I.D., Moore P.F. and MacEwen E.G.** (1994) Prognostic factors for treatment of malignant lymphoma in dogs. *Journal of the American Veterinary Medical Association* **205** (12), 1722-1728.
- Thacker J.** (1973) The possibility of genetic hazard from ultrasonic radiation. *Current Topics in Radiation Research Quarterly* **8**, 235-258.
- Thellen G.H. and Madewell B.R.** (1987) Tumours of the Skin and Subcutaneous Tissues. Veterinary Cancer Medicine, second edition. Lea and Febiger. Philadelphia. p. 295-297.

- Thickman D.I., Ziskin M.C., Goldenberg N.J. and Linder B.E. (1983).** Clinical manifestation of comet-tail artifacts. *Journal of Ultrasound Medicine* **2**, 225-230.
- Thomas W.B., Hudson J.A. and Cartee R.E. (1991)** Ultrasonographic diagnosis. *Veterinary Radiology* **32** (3) 227-228.
- Thomson R.G. (1978)** General Veterinary Pathology. W.B. Saunders Company. Philadelphia. pp. 267-278.
- Thurber L.A., Cooperberg P.L., Clement J.G., Lyons E.A., Gramaik R. and Cunningham J. (1979)** Echogenic fluid: A pitfall in ultrasound diagnosis of cystic lesions. *Journal of Clinical Ultrasound* **7**, 273-278.
- Tvedten H. (1994)** Erythrocytic Disorders in Small Animal Clinical Diagnosis by Laboratory Methods. In Willard M.D., Tvedten H. and Turnwald G.H. Saunders W.B. Philadelphia. pp 40-41.
- Vail D.M., Ogilvie G.K. and Wheeler S.L. (1990)** Metabolic alterations in patients with cancer cachexia. *Compendium on Continuing Education for the Practicing Veterinarian* **12** (3), 381-386.
- Vail D.M., Wheeler S.L., Fettman M.J., Johnston S.D. and Hegstad R.L. (1990)** Alterations in carbohydrate metabolism in canine lymphoma. *Journal of Veterinary Internal Medicine* **4** (1), 8-11.
- Van-Sonnenberg E., Simeone J.F., Mueller P.R, and Wittenberg J., Hall D.A. and Ferrucci J.T. (1983)** Sonographic appearance of haematoma in the liver, spleen and kidney: a clinical, pathologic and animal study. *Radiology* **147**, 507-510.
- Vörös K., Vrabély T., Papp L., Horvath L. and Karsai F. (1991)** Correlation of ultrasonographic and pathomorphological study in canine hepatic diseases. *Journal of Small Animal Practice* **32**, 627-634.
- Waldmann Ta., Weissman S.M. and Berlin N. (1959)** The effect of splenectomy on erythropoiesis in the dog. *Blood* **15**, 873-883.
- Waller T. and Rubarth S. (1967)** Haemangioendothelioma in domestic animals. *Acta Veterinarian Scandinavica* **8**, 234-261.

- Waters D.J., Caywood D.D., Hayden D.W. and Klausner J.S. (1988)** Metastatic pattern in dogs with splenic haemangiosarcoma: Clinical implications. *Journal of Small Animal Practice* **29**, 805-814.
- Weingarten M.J., Fakhry J., McCarthy J., Freeman S.J. and Bisker J.S. (1984)** Sonography after splenic embolisation: the wedge-shaped acute infarct. *American Journal of Roentgenology* **141**, 957-959.
- Weinstein M.J., Carpenter J.L. and Schunk M.C.J. (1989)** Nonangiogenic and non-lymphomatous sarcomas of the canine spleen: 57 cases (1975-1987). *Journal of American Veterinary Medical Association* **195** (6), 784-788.
- Weir E.C., Greenlee P. and Matus R. (1988)** Hypercalcaemia in canine lymphosarcoma is associated with T-cell sub-type and with secretion of a PTH-like factor. *Journal of Bone Mineral Research* **3**, 106.
- Weiss L. (1988)** The Spleen. In *Histology. Cell and Tissue Biology*, sixth edition. Urban and Schwarzenberg. Munich. pp 517-573.
- Whiteley H.M. and Willard T.R. (1987)** Dogs, diet, and cancer: Exploring the connections. *Veterinary Medicine* **82** (9), 892-902.
- Whiteley M.B., Feeney D.D., Whiteley L.O. and Hardy R.M. (1989)** Ultrasonographic appearance of primary and metastatic canine hepatic tumours- a review of 48 cases. *Journal of Ultrasound Medicine* **8**, 621-630.
- Wicks J.D., Silver T.M. and Bree R.L. (1978)** Gray-scale features of haematomata: an ultrasonic spectrum. *American Journal of Roentgenology* **131**, 977-980.
- Wild J.J. (1978)** The Use of Pulse-Echo Ultrasound for Early Tumour Detection: history and prospects. In Hill C.R., McCready V.R. and Cosgrove D.O. (editors) *Ultrasound in Tumour Diagnosis*. Pitman Medical. England. pp 1-47.
- Withrow S.J. (1979)** Dental extraction as a probable cause of septicaemia in a dog. *Journal of the American Animal Hospital Association* **15**, 345-346.
- Wong P.L. (1981)** Pneumoperitoneum associated with splenic necrosis and clostridial peritonitis in a dog. *Journal of the American Animal Hospital Association* **17**, 463- 467.

Wood A.K.W., McCarthy P.H. and Angles J.M. (1990) Ultrasonographic-anatomic correlation and imaging protocol for the spleen in anaesthetised dogs. *American Journal of Veterinary Research* **51**, 1433-1438.

Wrigley R.H. (1991) Ultrasonography of the spleen: life threatening splenic disorders. *Problems in Veterinary Medicine* **3** (4), 574-581.

Wrigley R.H., Konde L.J., Park R.D and Lebel J.L. (1988a) Ultrasonographic features of splenic lymphosarcomas in dogs. *Journal of American Veterinary Medical Association* **193** (12) 1565-15

Wrigley R.H., Park R.D., Konde L.J. and Lebel J.L. (1988b) Ultrasonographic features of splenic haemangiosarcomas in the dogs; 18 cases (1980-1986). *Journal of American Veterinary Medical Association* **192** (8), 1113-1116.

Wrigley R.H., Konde L.J., Park R.D. and Lebel J.L. (1989) Clinical features and diagnosis of splenic haematoma in dogs: 10 cases (1980-1987). *Journal of American Animal Hospital Association* **25**, 371-375.

Yeh H. and Zacks J. (1981) Ultrasonography of splenic infarct. *Mount Sinai Journal of Medicine* **48**, 466-468.

