

**SURGICAL TREATMENT OF PATELLAR
LUXATION IN DOGS**

**Retrospective findings after wedge recession sulcoplasty
and/or tibial tuberosity transposition**

A dissertation presented to
the Faculty of Veterinary Medicine
Glasgow University
for the Degree of Master of Veterinary Medicine

September 1994

Hilde de Rooster

© Copyright

ProQuest Number: 13818550

All rights reserved

INFORMATION TO ALL USERS

The quality of this reproduction is dependent upon the quality of the copy submitted.

In the unlikely event that the author did not send a complete manuscript and there are missing pages, these will be noted. Also, if material had to be removed, a note will indicate the deletion.



ProQuest 13818550

Published by ProQuest LLC (2018). Copyright of the Dissertation is held by the Author.

All rights reserved.

This work is protected against unauthorized copying under Title 17, United States Code
Microform Edition © ProQuest LLC.

ProQuest LLC.
789 East Eisenhower Parkway
P.O. Box 1346
Ann Arbor, MI 48106 – 1346



Thesis
9883
Copy 1

Table of Contents

Summaryiii

List of Chaptersiv

List of Tablesvi

List of Figuresvii

List of Picturesviii

Dedicationix

Declarationx

Acknowledgementsxi

Summary

The study opens with a review of literature on canine patellar luxation. Detailed reference is made to the occurrence, aetiology and pathogenesis, pathomechanics and classification of the range of patellar luxation in dogs. Diagnostic means are discussed. In the chapter on treatment, a survey is made of the majority of existing surgical and non surgical treatments available. Brief comments on prognosis conclude the search of existing literature.

A clinical follow-up was carried out on fifty cases of medial patellar luxation which had been treated by recession wedge sulcoplasty (group A: 23), tibial tuberosity transposition (group B: 10) or a combination of both procedures (group C: 17) at Glasgow University Veterinary Hospital during the five-year period from June 1988 till December 1993. All post-operative information was gained via a client questionnaire.

The hypothesis was that deepening the trochlear groove slows down the rate of recovery from surgery, as opposed to the more accepted practice of simply correcting the quadriceps axis by transposition of the tibial tuberosity.

Ninety six per cent of dog owners across the three groups reported that they were pleased with the final outcome of the surgery performed. Only eight per cent of patients failed to become completely sound on the leg that was operated on. In a further ten per cent of cases, occasional stiffness was recorded.

The availability of suitable dogs was limited, thus rendering group size relatively small. Another consequence of availability was that the distribution across the three groups was unavoidably unbalanced. These conditions combined to render the sample too small to reject the null hypothesis that no difference in outcome of surgery exists between the various groups of dogs.

List of Chapters

1. Literature review	1
1.1. Introduction	1
1.2. Normal anatomy and biomechanics of the femoropatellar joint	3
1.2.1. Regional structural and functional anatomy of interest in patellar luxations	3
1.2.1.1. Structural anatomy	3
1.2.1.2. Functional anatomy	4
1.2.2. Biomechanical basis	4
1.3. Occurrence, aetiology and pathological changes associated with patellar luxation	7
1.3.1. Occurrence of patellar instability	7
1.3.2. Aetiology and pathogenesis	10
1.3.3. Pathomechanics and resulting anatomic abnormalities	12
1.3.3.1. Medial patellar luxation	12
1.3.3.2. Lateral patellar luxation	15
1.4. Classification of patellar luxation	17
1.4.1. Classes	17
1.4.2. Clinical syndromes	17
1.4.3. Grading system	18
1.5. Associated injuries	20
1.6. Diagnosis	21
1.6.1. History	21
1.6.2. Clinical examination	21
1.6.3. Radiographic examination	23
1.7. Treatment	24
1.7.1. Conservative treatment	24
1.7.2. Surgical treatment	25
1.7.2.1. Soft-tissue reconstructive procedures	25

Desmotomy/Release	26
Capsular imbrication and retinacular overlap	26
Fascia lata overlap	27
Tension procedures and antirotational sutures	28
Myoplasty	29
1.7.2.2. Bone reconstructive procedures	31
Trochlear groove arthroplasty	31
Tibial tuberosity transposition	36
Fibular head transposition	40
Corrective osteotomy	40
Implants	42
Epiphysiodesis	43
Patellectomy	45
Arthrodesis of the stifle joint	45
1.7.3. Post-operative care	46
1.7.4. Treatment of bilateral patellar luxation	47
1.8. Prognosis after treatment	48
1.8.1. Prognosis after conservative treatment	48
1.8.2. Prognosis after surgical treatment	48
2. Retrospective study	50
2.1. Materials and methods	50
2.1.1. Patients	50
2.1.2. Pre-operative examination	54
2.1.3. Surgical procedures	57
2.1.4. Post-operative evaluation	59
2.2. Results	61
2.3. Discussion	68
2.4. Conclusion	71
References	72

List of Tables

Table 1. Information recorded from the medical case reports52

Table 2. Breed distribution across survey53

Table 3. Classification of the degree of medial patellar luxation56

Table 4. Group A : WS (23)61

Table 5. Group B : TTT (10)62

Table 6. Group C : WS+TTT (17)62

List of Figures

Figure 1. Vector diagrams	5
Figure 2. Fascia lata overlap	27
Figure 3. Trochlear recession sulcoplasty	33
Figure 4. The principles of recession wedge sulcoplasty (concept of similar triangles)	35
Figure 5. Tibial tuberosity transposition in case of medial luxation of the patella	37
Figure 6. Sex incidence across survey	53
Figure 7. Age incidence across survey	53
Figure 8. Duration of lameness prior to surgery (34 cases)	54
Figure 9. Luxation grade and required surgical procedure	56
Figure 10. Ratio of surgical techniques	57
Figure 11. Questionnaire completed by the dog owners	59
Figure 12. Pain following surgery	63
Figure 13. Cumulative number of dogs starting to use the operated leg in relation to the time following surgery	64
Figure 14. Cumulative number of sound dogs related to the post-operative interval	65
Figure 15. Improvement after surgical interference	67

List of Illustrations

Picture 1. Structural anatomy of the stifle	2
Picture 2. Shallow trochlear groove	13
Picture 3. Shallow trochlear groove (Skyline view)	13
Picture 4. Conformational deformities in a severe case of medial patellar luxation in a 3 months old, male Yorkshire terrier (Craniocaudal view)	23
Picture 5. Trochlear recession sulcoplasty	34
Picture 6. Skyline view of trochlear groove	55
Picture 7. Trochlear recession sulcoplasty	58

Dedication

Dedicated to my parents who gave me the opportunity and all support to study abroad.

Declaration

I, Hilde de Rooster, do hereby declare that the work carried out in this thesis is original, was carried out by myself or with due acknowledgement, and has not been presented for the award of a degree at any other University.

Acknowledgements

I acknowledge the help I have received not only from my supervisor, Mr A. Miller, but also from my friend Mrs J. Macdonald, who read this work prior to the final print and made valuable suggestions.

I am indebted to Ms S. Cain and to Mr A. May, respectively technician and photographer of the Department of Veterinary Anatomy, for the friendly and prompt supply of fresh dog cadavers and for the grand close-ups of the prepared specimens.

I also wish to thank all other members of the Department of Veterinary Surgery, who showed real interest in the evolution of my dissertation and created a pleasant working-atmosphere.

Finally, I am very grateful to the owners of the dogs included in my retrospective study for their willing co-operation in providing me with post-operative data.

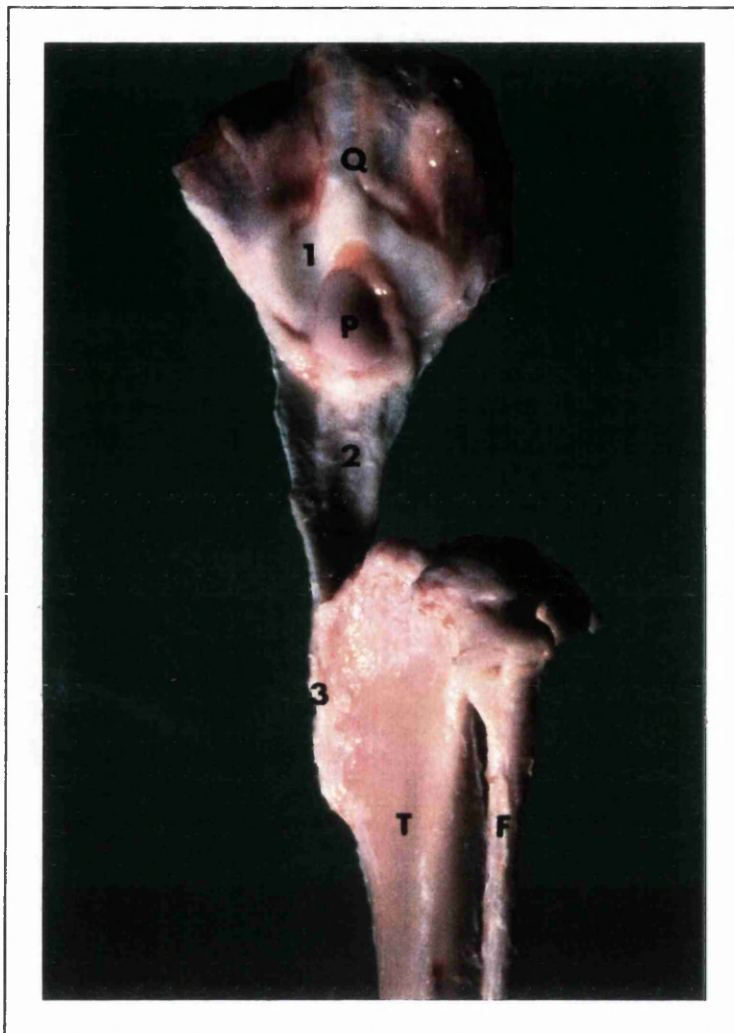1. Literature review

1.1. Introduction

Patellar luxation is a condition which is very often met with in small animal practices. It occurs most frequently in young dogs, with the highest incidence in the smaller breeds (Hobday 1905; Stader 1944; Vierheller 1959; Kodituwakku 1962; Pearson and Ramsey 1963; Rudy 1966; Herron 1969; DeAngelis 1971; Horne 1971; Campbell and Pond 1972; Harrison 1975a; Schröder and Schirmacher 1980; Hulse and Shires 1985; Denny 1993). Canine congenital medial patellar dislocation is considered one of the five most important hereditary defects in dogs (Hodgman 1963; Knight 1963; Priester 1972; Clark and Stainer 1983; Ruble and Hird 1993).

Different types of patellar instability can be discerned in dogs. The patellar luxation can be medial or lateral, congenital or traumatic. Medial displacement is far more common in dogs than lateral luxation. As well, most cases of patellar luxation are congenital in origin, and a purely traumatic dislocation occurs rather rarely. A method of classifying the degree of luxation into four groups has been made by Singleton (1969), with grade IV being the most severe.

The earliest suggestions at correcting patellar luxation in dogs were mostly non-operative in nature, such as bandages, splints, and applications which provoke local inflammation. Advancements made in the field of veterinary surgery during the past five decades revealed more specific surgical techniques which can be better attuned to individual clinical cases.



- T : tibia
- F : fibula
- P : patella
- Q : quadriceps
- 1 : parapatellar fibrocartilages
- 2 : straight patellar ligament
- 3 : tibial crest

Picture 1. Structural anatomy of the stifle.

1.2. Normal anatomy and biomechanics of the femoropatellar joint

1.2.1. Regional structural and functional anatomy of interest in patellar luxations

1.2.1.1. Structural anatomy

The patella is a sesamoid in the tendon of insertion of the most powerful extensor of the stifle, the quadriceps femoris (Evans and de Lahunta 1988) (Picture 1). The convex and smooth inner articular surface of the patella conforms fully to the concave shape of the femoral trochlear groove so as to articulate intimately (McCurnin 1976). The trochlea in dogs lies at an average angle of 37° to the femoral axis (Slocum *et al.* 1982). In an extended stifle, the quadriceps mechanism, the trochlear groove, the patellar ligament, and the tibial tuberosity are all aligned at an 180° angle in the same vertical plane. Medial and lateral prominent ridges bound the articular groove. The medial trochlear lip is usually thicker than the lateral (Evans and de Lahunta 1988). On either side of the patella fibrocartilages are found as attachments of the vastus medialis and vastus lateralis of the quadriceps muscle group (Singleton 1957). By increasing the surface area, those extensions to the patella disperse the force of the muscles (Arnoczky and Tarvin 1983). In toy breeds, such cartilaginous structures are often very small or even absent (Shuttleworth 1935). Medially and laterally there are also the femoropatellar ligaments. They are delicate, broad but poorly defined bands of loose connective tissue from the patella to the periosteum of the medial femoral epicondyle and to the lateral fabella (Stader 1944; Rudy 1974; Nunamaker 1985).

The joint capsule of the stifle is the most extensive one in the body (Shuttleworth 1935; McCurnin 1976). It attaches to the margins of the articular surface of the patella (Rudy 1974). A proximal-cranial pouch of the capsule allows a free range of movement of the patella, even in full extension of the joint (Shuttleworth 1935).

The quadriceps tendon, together with the biceps femoris and the sartorius muscle, continues distally as a single straight patellar ligament, which courses from the patella to the tibial tuberosity. This process is a large quadrangular structure on the proximocranial surface of the tibia, and inclines more distally laterally on the body (Evans and de Lahunta 1988).

1.2.1.2. Functional anatomy

The patella aids in the protection of the stifle joint and the tendon of insertion of the quadriceps, but its chief purpose is redirection of this tendon (Evans and de Lahunta 1988). The patella seems to have an effect also upon the physiology of quadriceps contraction (Kaufer 1979). Although the sesamoid itself is a passive structure in the body, it plays a very important role in the so-called extensor mechanism of the knee (Arnoczky and Tarvin 1983). The patella increases the mechanical advantage of the quadriceps by its ability to provide leverage (Singleton 1957). The whole dynamic system is composed of the quadriceps muscle group, the trochlea, the patella plus its straight ligament, and the tibial tuberosity (Evans and de Lahunta 1988). Normal physiologic movement and stability of the stifle joint can only be attained by an anatomical correct angular and torsional configuration of both femur and tibia (Rudy 1974). Contraction of the quadriceps muscles results in extension of the stifle, by which the patella rides in the trochlear groove (Arnoczky and Tarvin 1983). The sesamoid is forced tightly against the femoral trochlea (Rudy 1974). When the extensors are relaxed, the femoropatellar retinacula exert a stabilising influence on the patella (Rudy 1974), which sinks into the intercondylar region as the knee flexes (Kaufer 1979). The stability of the patella in the trochlear groove contributes to the prevention of cranial and rotary instability of the joint (Hulse and Shires 1985). The normal gliding is also necessary to maintain the nutritional requirements of the articular cartilage of the patella and the trochlear groove (Hulse 1981a).

1.2.2. Biomechanical basis

In a normal standing position, the stifle joint in dogs is held at an angle of about 140° , varying with the breed and position of the limb (Rudy 1974). The amplitude during movement alters from 30° in the walking gait to 60° at the trot (Roy 1971).

The hip, stifle, hock and paw are all interconnected via a series of muscles and tendons with their origins and insertions proximal and distal to the joints (Robins 1990). The normal interrelationship of the femur and tibia is of great importance. The femoral neck-femoral shaft axis is near 130° . This neck angle normally is constant from birth through all ages of development. The anteversion or forward inclination angle of the femoral head and neck increases from 0° in puppies to an average of 25° in mature dogs (Riser 1975; Hulse 1981b). Distally, the trochlear groove is accurately directed to be in alignment with the quadriceps femoris, patellar ligament and tibial tuberosity.

During flexion of the knee, a physiologic internal rotation of the tibia tends to occur. The pull of the extensors is therefore not perfectly vertical, but under an angle of 170° , with the patella as central point (Perot 1984). As the knee is extended, the lateral femoral condyle moves cranially causing external rotation of the tibia. In man, this motion has been classically described as the “screw-home” mechanism (Arnoczky *et al.* 1977).

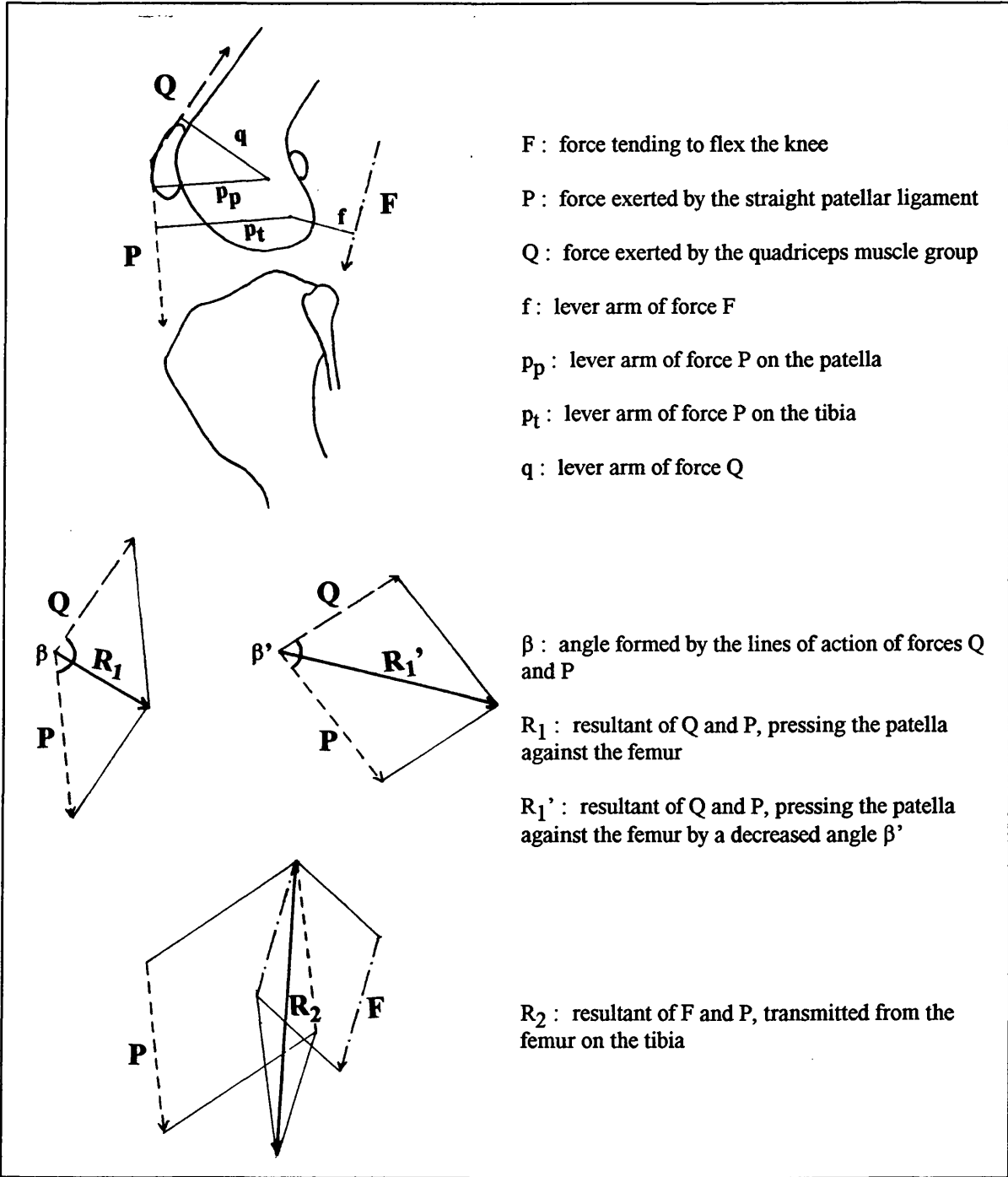


Figure 1. Vector diagrams.

Maquet (1979) studied the forces acting on the human stifle joint, by means of vectors in the sagittal plane. These forces can be grossly extrapolated to the dog's knee (Hulse 1981a; Hulse and Shires 1985; Fritz 1989) although interpolation across species may prove to be erroneous. The patella is pulled upward and backward by contraction of the quadriceps. At the same time, the straight patellar ligament, which has its distal attachment on the tibial tuberosity, exerts a downward and backward pull on the patella. These forces Q and P are shown in Fig. 1. They act on the patella, respectively with lever arms q and p . The knee extensor moment is the product of the extensor muscle force multiplied by the moment arm upon which it acts. The angle β is formed by the lines of action of the forces of the quadriceps and the patellar ligament. The backward pull from both quadriceps and patellar ligament results in a force R_1 . The patella bears sole responsibility for transmitting this resultant force to the femur and is compressed tightly against the femoral trochlea (Hungerford and Barry 1979). The magnitude of the compressive force alters with the β angle : the more acute the angle, the higher the degree of force. R_1 increases generally during flexion and decreases during extension. F is the force tending to flex the knee, which is counterbalanced by the force of the patella tendon (P) on the femorotibial joint. Together they form the resultant vector R_2 (Maquet 1979).

1.3. Occurrence, aetiology and pathological changes associated with patellar luxation

1.3.1. Occurrence of patellar instability

The occurrence of patellar luxation is a very commonly found condition in dogs yet it has much less frequently been reported in cats (Leighton 1978; Hohn and Turner 1984; Nunamaker 1985; Johnson 1986; Shires 1990). The true incidence in the latter is probably higher than generally thought, because the condition seems to be more often clinically silent in cats (Flecknell 1977; Johnson 1986; Denny 1993). In canine toy breeds dislocation of the patella is so frequently diagnosed that Etor (1966) even considered it to be a normal abnormality.

The majority of affected dogs are diagnosed as suffering from the congenital type of patellar luxation. Seventy-five to ninety-five per cent of all the cases are recorded as inherited (Denny and Minter 1973; Hutter *et al.* 1983; Hohn and Turner 1984; Hayes and Boudrieau 1992). Most cases of congenital patellar luxation occur as medial luxations (Denny and Minter 1973; Harrison 1975b; Schröder and Schirrmacher 1980), even in large and giant breed dogs (Hayes and Boudrieau 1992; Remedios *et al.* 1992). Dislocation of the patella in a lateral direction is infrequent. In some patients, the patella can be luxated both medially and laterally on the same leg (Horne 1971; Rudy 1974; Schröder and Schirrmacher 1980).

Traumatic patellar luxation is rather rare and can occur at any age, in any breed (Shuttleworth 1935; Kodituwakku 1962; DeAngelis 1971; Robins 1990) but even this type of luxation is observed primarily in toy and miniature breeds (DeAngelis 1971; Horne 1971 and 1979; Brinker *et al.* 1990).

In case of bilateral involvement, the dislocation of the patella is either as a doubly medial or doubly lateral condition (Kodituwakku 1962). If there is rather extreme patellar instability, the syndrome is almost always bilateral (Rudy 1974). Hohn and Turner (1984) and Brinker *et al.* (1990) only mentioned a percentage of bilateral luxation of 20 to 25% in the presented congenital cases. Others (Kodituwakku 1962; Denny and Minter 1973; Rudy 1974; Schröder and Schirrmacher 1980; Hutter *et al.* 1983; Fritz 1989) reported a much higher incidence of 35% up to as many as half of the affected dogs having some kind of bilateral medial patellar instability. Lateral patellar luxation is even more commonly a bilateral condition (Kodituwakku 1962; Riser *et al.* 1969; Rudy 1974).

Little has been published about the condition in feline cases of luxating patella. In the cats included in his study, Johnson (1986) found the luxation to be bilateral in more than half of the animals.

Risk factors

Breed

Definitive answers on the genetic aspects of medial patellar luxation are not yet available, but the magnitude of risk for individual breeds has been shown in many series (Loeffler and Meyer 1961; Kodituwakku 1962; Hodgman 1963; Knight 1963; DeAngelis and Hohn 1970; Priester 1972; Denny and Minter 1973; Rudy 1974; Schröder and Schirmacher 1980; Clark and Stainer 1983; Hutter *et al.* 1983; Ruble and Hird 1993). It is disputable to try to assess the real incidence of this disease in any particular breed, due to changes and differences in popularity of those dogs. However, the existence and prevalence may be determined. It is clear that congenital dislocation is commonly a disease of miniaturised pedigree dogs. Very small breeds with a tendency to be bowlegged are more susceptible than others (Stader 1944; House 1961). Up to seventeen different pure-breds are described by Clark and Stainer (1983) as having a recessive inheritance of patellar luxation. In many surveys, the poodle appears to be over represented (Vierheller 1959; Kodituwakku 1962; DeAngelis and Hohn 1970; Denny and Minter 1973; Schröder and Schirmacher 1980; Hutter *et al.* 1983; Fritz 1989). Chondromalacia due to recurrent patellar luxation is recorded to be most commonly seen in Staffordshire and English bull terriers (Bennett, reported by Coughlan 1994).

Traumatic dislocation of the patella is a relatively rare injury that can occur in any breed. Here again, small breeds are considered to be more susceptible (DeAngelis 1971; Horne 1971 and 1979; Brinker *et al.* 1990).

A dramatic increase in the observation of congenital medial patellar luxation in large and giant breeds has been noted in the past few years (Hayes and Boudrieau 1992; Remedios *et al.* 1992). Previously, medial dislocation of the patella in those breeds was thought to be rather of traumatic origin (Knight 1963; Priester 1972; Brinker *et al.* 1990).

Lateral luxations in large and giant breeds occur most commonly in Saint Bernards, Great Danes, Irish wolfhounds, Malamutes, and Irish setters (Rudy 1974; Hulse 1981a; Hulse and Shires 1985). These dogs often also show genu valgum and dysplastic hips (Riser *et al.* 1969; Olmstead 1981; Arnoczky and Tarvin 1983;

Newton 1985; Brinker *et al.* 1990). Brinker *et al.* (1990) noted an unusual incidence of lateral patellar dislocation in certain strains of flat-coated retrievers.

In veterinary literature, references to feline patellar luxation are very rare. There appears to be a greater incidence of the condition in the Devon Rex (Flecknell 1977; Flecknell and Gruyffydd-Jones 1979; Prior 1985). A genetic breed predisposition has been postulated.

Age

While patellar luxation may occur in animals of any age, the condition is predominantly seen in young or growing dogs. A routine check of puppies of the toy and miniature breeds can reveal the presence of congenital patellar laxity at the early age of eight weeks (Foster 1966). However, a peak incidence of the onset of lameness is only seen when the animals are about six months of age, due to the rapid growth in bone length (Kodituwakku 1962; Knight 1963; Riser *et al.* 1969; Campbell and Pond 1972; Rudy 1974; Schröder and Schirrmacher 1980; Clark and Stainer 1983; Nunamaker 1985; Brinker *et al.* 1990; Denny 1993). By this time, congenital patellar luxation has become evident, but in a large percentage of dogs, the deformity is progressive for another six months. Afterwards, the degree of lameness usually does not worsen (Kodituwakku 1962; Knight 1963; Riser *et al.* 1969; Rudy 1974).

Traumatic patellar dislocation can occur at any age. If luxation is only diagnosed in the mature animal, trauma is recognised as the initiating agent in the majority of the cases (Kodituwakku 1962; DeAngelis 1971; Horne 1971; Robins 1990).

Denny (1993) reported the occurrence of patellar luxation in toy poodles. At an average age of eight years, a spontaneous lateral luxation can occur which is directly responsible for the onset of lameness seen in those dogs.

Sex

In most of the retrospective studies (Kodituwakku 1962; DeAngelis and Hohn 1970; Denny and Minter 1973; Hutter *et al.* 1983) no significant difference in gender incidence could be determined. Priester (1972) described an excess risk of congenital patellar luxation in female dogs of one and a half times that for males. Hulse (1981b) shared his idea of sex predilection. It has been suggested more than once that congenital dislocation is autosomal recessive or polygenic whereby several genes are mixed up with the expression of one feature (Loeffler and Meyer 1961; Kodituwakku 1962; Clark and Stainer 1983). Therefore, increased risk for

female individuals might be related to the expression of patellar dislocation under hormonal influence or by X-linked factors (Priester 1972). Other investigators (Kuwabara *et al.* 1980) studied the silhouettes of the distal end of the femur in both sexes. They reported that in female dogs the development of the distal femur was incomplete whereas this condition in males was only seen in a few individuals.

1.3.2. Aetiology and pathogenesis

The primary causes of patellar luxation have been attributed to many factors. They remain, at present, controversial. The veterinary literature contains a paucity of information regarding the relationship between cause and effect of the disease.

Aetiological factors responsible for luxation of the patella may be either congenital or acquired.

A large number of cases of dislocation have undoubtedly an inherited predisposition (Shuttleworth 1935; Loeffler and Meyer 1961; Kodituwakku 1962; Pearson and Ramsey 1963; Naserke 1966; Rudy 1966; Herron 1969; Priester 1972; Clark and Stainer 1983; Alexander 1985). It is likely that several underlying abnormalities play their role in the pathogenesis of the congenital dislocating patella, any of which may be a cause or an effect. Up to 95% of the canine patients affected with patellar luxation have some type of associated structural deformity (Singleton 1969). The primary cause of lateral luxation in giant breeds is apparently a valgus deformity of the distal femoral shaft due to a selective arrest of normal skeletal development (Riser *et al.* 1969; Harrison 1975b; Newton 1985). A defective development of the distal end of the femur has been described as the primary cause of congenital medial luxation (Pearson and Ramsey 1963; Kuwabara *et al.* 1980). Several investigators, however, have shown a relation between changes in the hip and stifle abnormalities. The primary defect is still not clear, and there is not enough evidence to definitively establish the sequence of events leading to the musculoskeletal changes. Most authors (Hobday 1905; Putnam 1968; Riser *et al.* 1969; Campbell and Pond 1972; Olmstead 1981; Alexander 1985; Brinker *et al.* 1990) believe that the quadriceps displacement is related to primary congenital hip problems. Putnam (1968) concluded that the occurrence of medial patellar luxation is characterised by coxa vara and a decrease in the femoral neck anteversion. Also hip luxation can predispose to the problem of the developmental luxation of the patella (Brinker *et al.* 1990). Changes in the direction of the extensor pull are then responsible for the development of the other pathological deformities (Kodituwakku 1962). The open physis of the distal femur is very susceptible to abnormal forces, which cause secondary angular and torsional abnormalities (Arkin and Katz 1956; Rudy 1971;

Hulse and Shires 1985; Robins 1990). Abnormal pressure by malalignment of muscles and by abnormal weight-bearing can be resolved in vectors of forces acting on the growing epiphysis. Loading in a direction parallel to the direction of epiphyseal growth slows such growth. Perpendicular forces will result in an angular deposition of the newly-formed bone.

A lot of authors questioned to what extent direct trauma can be classified as a sole aetiological factor. Traumatic dislocation is rather rare, because the patella is quite small to be subjected to direct violence and it is moreover protected by the trochlear ridges, as long as the leg is not fully extended (Shuttleworth 1935). Indirect forces applied to the fascial attachments on the lateral side of the patella, weakened by inward rotation of the tibia and intense muscular stress, may cause dislocation (Formston 1932; McCunn 1932; Horne 1979; Alexander 1985). Relatively mild trauma can act as a secondary factor to cause the patella to luxate. In such cases, the dislocation is presumably a result of a congenital deformity which makes the femoropatellar joint more vulnerable, and the violence is only contributory to the problem (Shuttleworth 1935; Pearson and Ramsey 1963; Rudy 1966; Herron 1969; Ticer 1974; Brinker *et al.* 1990).

Of course, patellar luxation can also be caused by a developmental deformity after an injury or a disease. Poor reconstruction of the periarticular soft tissues following e.g. cruciate repair or early post-operative overactivity of the patient may result in an iatrogenic dislocated patella (Rudy 1966; Harrison 1975b; Hohn and Turner 1984).

Fox (1975) proposed the theory of dysplasia of the quadriceps muscle mass, leading to an imbalance of force between the vastus medialis and vastus lateralis. This problem is well known in humans, but hardly discussed in veterinary literature (Hulse 1981b).

Priester (1972) used "low risk" findings to eliminate certain hypotheses of disease aetiology. Thus, he stated that achondroplasia, characteristic of some breeds, did not seem to assume much significance as a cause of congenital patellar luxation.

On account of the unilateral incidence of the condition in a large number of the cases, nutritional deficiency as a cause for the deformities associated with luxation of the patella should also be eliminated (Kodituwakku 1962). Rohwer (1966), however, believed that the diet is more important than most clinicians consider. He usually saw the condition of patellar instability in puppies who, like their mother, were kept almost exclusively on titbits of lean meat, sweets and biscuits.

1.3.3. Pathomechanics and resulting anatomic abnormalities

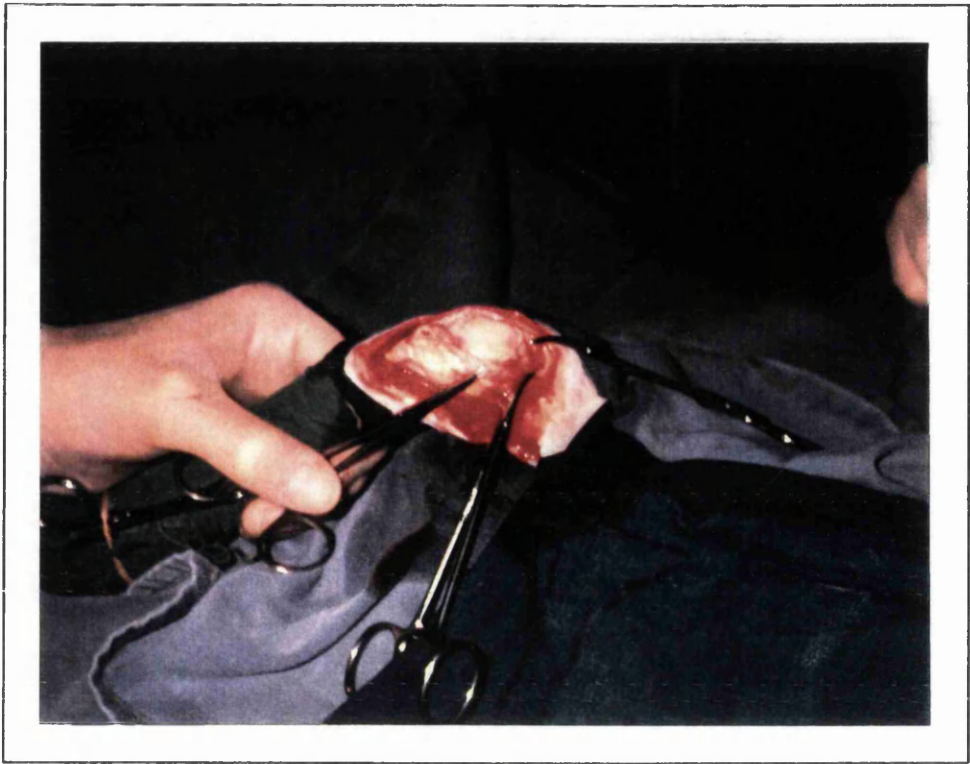
1.3.3.1. Medial patellar luxation

The degree of skeletal changes varies considerably between the mildest and severest form of patellar luxation. An extremely wide range of pathological musculoskeletal deformities can be seen, from mild changes in soft tissue to marked skeletal abnormalities (Putnam 1968; Singleton 1969). The sequence of events resulting in the anatomic derangement has not yet been established definitively, and some aspects remain, up to present, rather controversial and speculative. All of the following changes are not present in every case of patellar dislocation, but they should be considered as contributory to the clinical syndrome.

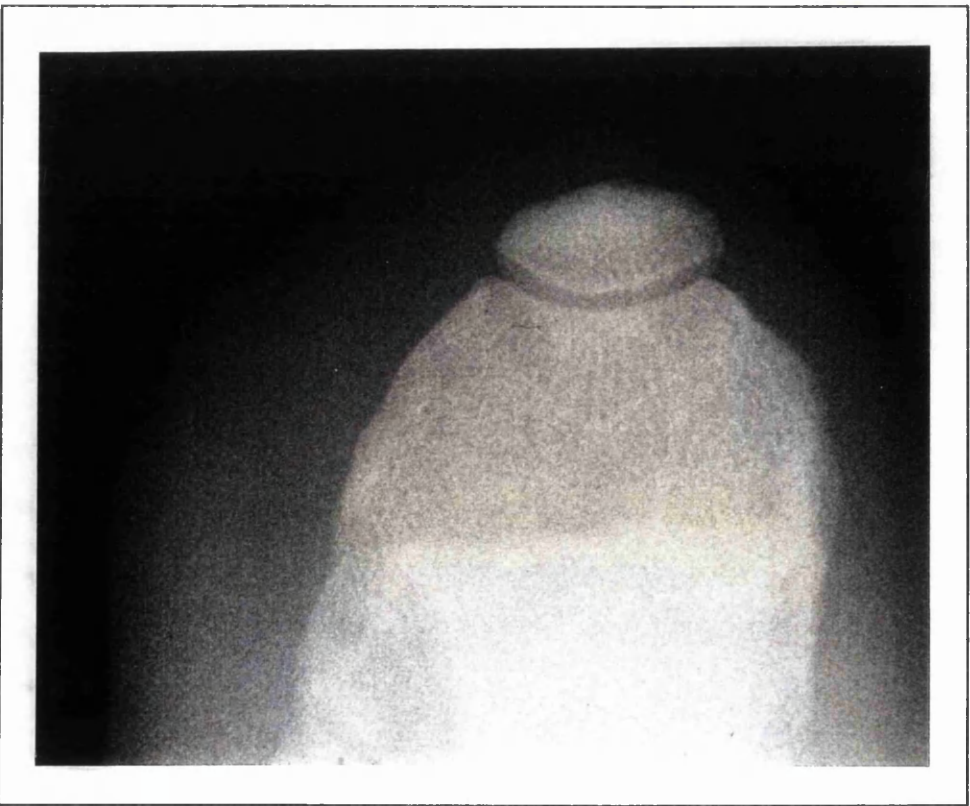Lateral torsion of the distal femur is frequently seen with medial patellar luxation. The whole lower epiphysis is canted from its normal plane, and the trochlear ridges become quite out of alignment to the femoral shaft (Shuttleworth 1935). Deforming forces are likely to result in a rotation of the distal femoral end, because the epiphyseal cartilage columns will be deflected away from the forces (Arkin and Katz 1956). A relative decrease in the anteversion angle of the femoral head and neck itself may produce such a type of stress on the open epiphysis of the distal femur (Putnam 1968). Internal rotation of the hind leg to compensate for an abnormal anteversion could be another possibility to result in those abnormal forces (Hulse 1981b).

Decrease in the femoral neck-femoral shaft axis (coxa vara) is a condition often dealt with in congenital cases of patellar luxation. Any abnormal stresses from muscles, ligaments, or weight-bearing, which cause retardation of the growth of the proximal femoral epiphysis, will result in a varus deformity of the hip joint (Hulse 1981b). Coxa vara and a reduced femoral anteversion angle are interrelated, and tend to intensify one another (Montavon *et al.* 1985). The limb will be held more laterally, resulting in a pronounced medial displacement of the quadriceps muscle force (Hulse and Shires 1985).

Medial displacement of the extensor muscle group is generally agreed to be part of the anatomic abnormalities associated with medial patellar luxation. Due to the laterally rotated femoral trochlea, the line of action of the quadriceps runs more medially. It also brings the tibial tuberosity, to which the muscle is indirectly attached by means of the patellar ligament, more medially relative to the trochlear groove. As a result of the combination of those factors, muscle contraction will dislocate the patella. This malalignment of the extensor apparatus is of extreme



Picture 2. Shallow trochlear groove.



Picture 3. Shallow trochlear groove (Skyline view).

importance in producing other musculoskeletal deformities associated with patellar luxation (Hulse 1981b; Robins 1990).

Recently, the hypothesis of dysplasia of the quadriceps mechanism in man has gained popularity. The different muscles of this group function as synergists, as far as extension of the stifle is concerned. The vastus medialis and vastus lateralis, however, antagonise one another in the sideways pull on the patella (Hulse 1981b). In humans it is believed that an imbalance between those quadriceps heads can force the patella to luxate (Fox 1975). If a similar condition is seen in some cases of canine patellar luxation it is not yet documented.

Dysplasia of the femoral condyles seen with medial patellar luxation is a hypoplasia of the medial and an elongation of the lateral condyle (Loeffler and Meyer 1961; Putnam 1968; Campbell and Pond 1972). The degree of this abnormality is proportional to the permanency of quadriceps displacement. Increased pressure on the distal femoral epiphysis medially slows down the growth of the medial condyle. Exactly the opposite occurs to the lateral aspect (Hulse 1981b).

The femoral trochlea is of deficient depth in most cases of congenital patellar luxation in the dog (Pictures 2 and 3). The groove will be slightly shallow in mild grades of luxation, and is almost non-existent or even convex in the most severe cases (Singleton 1969; Vaughan and Robins 1975). Articular cartilage responds to changes in pressure in the same way as an epiphyseal growth plate does. If there is no proper articulation of the patella with the trochlea, accelerated bone growth is seen because of lack of normal physiologic pressure, exerted by the patella on the distal femur (Harrison 1975a). The trochlea fails to gain proper depth, and is covered with a thin cartilage and sometimes even partially overgrown by the marginal joint capsule (Rudy 1974). On the other hand, repeated dislocation may result in severe erosion of the medial trochlear lip, which changes the normal architecture of the groove and makes it less defined (Singleton 1969; Campbell and Pond 1972; Rudy 1974; Sommer 1975). Moreover, the medial ridge is not always as well developed as the lateral one (Ticer 1974; Kuwabara *et al.* 1980).

The affected limb can show an S-shaped conformation, with the femorotibial joint space sloping distally towards the lateral aspect of the joint. Lateral bowing of the distal third of the femur and medial bowing of the proximal tibia is caused by unequal pressure on their respective growth plates by altered ligamentous pull (O'Brien 1971; Ramadan and Vaughan 1979). Medial misalignment of the quadriceps muscles produces sufficient increase of the pressure on the medial aspect of the distal femoral growth plate to retard growth. Accelerated growth on the

lateral side is noted at the same time, due to decreased pressure parallel to that side of the distal epiphyseal growth plate (Hulse 1981b). The resulting angulation of the distal femoral shaft accentuates the muscular malalignment, so that the condition grows worse (Rudy 1974). Compensatory internal rotation of the tibia develops because of abnormal forces on the proximal tibial growth plate, which increase the growth from the medial side, and decrease it laterally (Robins 1990). The degree of hind limb bowing is totally dependent on the grade of patellar luxation, since the extensor apparatus displacement also varies considerably with the grade.

Apart from a medial bowing, which is a conformational deformity, the proximal tibia additionally undergoes inward rotation. The responsible torsional forces are partially produced by the quadriceps malalignment on the tibial tuberosity, and partially by postural abnormalities (Kodituwakku 1962; Hohn and Turner 1984). If the condition is not extremely severe, the hock and paw are generally in a normal, forward pointing position. This is only possible if the distal tibial growth plate has undergone a concurrent lateral torsion, so that the distal tibia is in an approximately normal plane (Rudy 1974).

Medial patellar luxation is accompanied by increased rotational instability of the stifle joint. The soft tissue lateral to the patella is stretched beyond its physiological limits of elasticity by the medial displacement of the extensor muscles and concurrent internal rotation of the tibia (Kodituwakku 1962; Campbell and Pond 1972). In its turn, relaxation of those supporting structures adds to the rotary instability (Shuttleworth 1935). Tissue on the medial aspect of the stifle is similarly contracted and thickened (DeAngelis 1971).

In the later stages of congenital patellar luxation in dogs, marked degenerative joint disease can be diagnosed. The articular cartilage surfaces are submitted to unphysiologic motion and increased wear and tear by repeated luxation and relocation. Abnormal stresses across the cartilages are exerted and the biomechanics of the articulation have altered. Cartilage degeneration will occur as a reaction to this abnormal loading (Pearson and Ramsey 1963; Pederson and Pool 1978; Arnoczky and Marshall 1981; Hulse 1981b; Robins 1990).

1.3.3.2. Lateral patellar luxation

As with medial patellar luxation, deformities in the stifle region also occur in the syndrome of lateral luxation of the patella. Bony defects seem to be relatively minor in the smaller breeds, although the affected dogs often show more functional disability than in case of medial luxation (Brinker *et al.* 1990; Butterworth 1993).

In many respects, the structural abnormalities are basically the converse of those described for medial dislocation. Presumably, the pathogenesis of the musculoskeletal changes is also similar, but opposite to the one already described. The exception is that the trochlear groove is also found to be shallow, because here, too, sufficient physiologic pressure of the patella on the distal femoral epiphysis fails to occur (Hulse 1981b).

In large and giant breeds, components of hip dysplasia are often associated with some aspects of the deformities in a high percentage of dogs (Riser *et al.* 1969; Olmstead 1981; Arnoczky and Tarvin 1983; Newton 1985; Brinker *et al.* 1990).

One may find an increased femoral head and neck anteversion angle, coxa valga or genu valgum, medial bowing and torsion of the distal femur, lateral bowing and torsion of the proximal tibia, lateral displacement of the tibial tuberosity, hypodevelopment of the lateral trochlear ridge or lateral condyle, and hypoplasia of the vastus medialis muscle (Riser *et al.* 1969; DeAngelis 1971; Rudy 1974). Farther, a shallow acetabulum and thickening of the femoral neck can be present (Robins 1990).

1.4. Classification of patellar luxation

1.4.1. Classes

Two general types are seen in dogs : congenital and traumatic patellar luxation. Those types fall into several classes.

Congenital patellar luxation

- Medial luxation in toy, miniature and large breeds
- Lateral luxation in toy and miniature breeds
- Lateral luxation in large and giant breeds
- Combined medial and lateral luxation of the patella

Traumatic patellar dislocation

- Acute
- Chronic

Subluxation of the patella

This type has, in contrast with publications found in human literature (Hughston 1968; Cross and Waldrop 1975; Outerbridge and Dunlop 1975), not been described as being responsible for hind limb lameness in dogs.

1.4.2. Clinical syndromes

Coughlan (1994) distinguished six groups of clinical signs among his patients affected by patellar luxation.

Syndrome 1

The diagnosis of patellar laxity is only an incidental finding during a routine check, and is not responsible for any discomfort or lameness at all. Pekinese and Yorkshire terriers are especially well represented in this group. It is possible that the condition becomes clinically significant at some stage, later in the dog's life, although a lot of animals will never develop clinical signs.

Syndrome 2

Onset of the clinical hind limb problem occurs within the first year of life. The degree of gait abnormality is likely to depend upon the degree of underlying deformities.

Syndrome 3

Dogs categorised in this group are only presented when they are about two to three years of age. The severity of the lameness is again very variable.

Syndrome 4

In these cases, chondromalacia is present due to recurrent luxation of the patella. When the animal was younger, no obvious gait abnormalities were reported. But marked degenerative joint disease of the femoropatellar joint has already developed by the time lameness shows clinically. Patients are generally middle aged.

Syndrome 5

Uncorrected patellar luxation can cause degeneration in the cranial cruciate prior to the ultimate rupture of this ligament (Herron 1969; Rudy 1974; Vasseur *et al.* 1985). By unilateral failure of the cranial cruciate ligament in older dogs, unrepresented grade II or III patellar luxations can aggravate the present lameness, since the endorotation of the tibia will increase. Limping will be recorded as being of a sudden onset, although the underlying patellar problem is chronic.

Syndrome 6

Bilateral degenerative joint disease due to chronic intermittent patellar luxation can extremely weaken the cruciates, which will then rupture and this may cause sudden inability to rise. Although the condition is seldom dealt with, one should be careful not to confuse such a case with an acute neurological problem.

1.4.3. Grading system

The following classification system is adopted from Singleton (1957 and 1969). He categorised the degree of deformity associated with patellar luxation into four grades based entirely on clinical examination.

Grade I

There is an intermittent patellar luxation, causing the limb to be carried occasionally. The patella easily luxates manually at full extension of the stifle joint,

but returns to the trochlea when released. No crepitation is apparent. The medial, or very occasionally, lateral deviation of the tibial crest (with lateral luxation of the patella) is only minimal, with very slight rotation of the tibia. Flexion and extension of the stifle is in a straight line with no abduction of the hock.

Grade II

There is frequent patellar luxation which, in some cases, becomes more or less permanent. The limb is sometimes carried, although a little weight bearing may occur with the stifle remaining slightly flexed. Especially under anaesthesia it is often possible to reduce the luxation by manual rotation of the tibia laterally but the patella relaxates with ease when manual tension of the joint is released. The tibia is rotated up to 30° and a slight deviation of the tibial crest may exist. When the patella is resting medially, the hock is slightly abducted. If the condition is bilateral, more weight is thrown onto the forelimbs. Many cases in the grade live with the condition reasonably well for many years, but the constant luxation of the patella over the medial lip of the trochlea causes erosion of the articulating surface of the patella and also the proximal area of the medial lip. This results in crepitation becoming apparent when the patella is luxated manually and calls for a quite different surgical approach.

Grade III

The patella is permanently dislocated. There is a rotation of the tibia and a deviation of the tibial crest of 30° to 60° from the craniocaudal plane. Although the luxation is not intermittent, many cases use the limb with the stifle held in a semi-flexed position. Flexion and extension of the joint causes abduction and adduction of the hock. The trochlea is very shallow or even flattened.

Grade IV

The tibia is rotated and the tibial crest may show further deviation medially with the result that it lies 60° to 90° from the craniocaudal plane. The patella is permanently luxated. It lies just above the medial condyle and a "space" can be palpated between the patellar ligament and the distal end of the femur. The limb is carried or the animal moves in a crouched position with the limb partly flexed. The trochlea is absent or even convex.

1.5. Associated injuries

Abnormalities in the stifle joint are often interrelated. Chronic cases of medial patellar luxation can be complicated by concurrent cranial cruciate rupture (Herron 1969; DeAngelis and Hohn 1970; DeAngelis 1971; Denny and Minter 1973; Rudy 1974; Schmidtke 1981; Hulse and Shires 1985; Vasseur *et al.* 1985; Brinker *et al.* 1990; Remedios *et al.* 1992; Doverspike *et al.* 1993). In the series of Remedios *et al.* (1992) on patellar luxation in large breed dogs, the occurrence of associated cranial cruciate ligament injury turned out to be less than that mentioned in small dogs (Brinker *et al.* 1990). A luxating patella increases the loading of the cranial cruciate. The stifle joint is less stable when the patella does not ride tightly in the trochlear groove, and internal rotation of the tibia will be accentuated (Arnoczky and Tarvin 1980; Schmidtke 1981; Hulse and Shires 1985; Brinker *et al.* 1990; Doverspike *et al.* 1993). This stresses the ligament which tries to prevent the axial instability. Additionally, uncorrected cases of patellar luxation are prone to secondary osteoarthritis which reduces the tensile strength of the cruciate ligaments (Herron 1969; Rudy 1974; Vasseur *et al.* 1985). It is, on the other hand, not always very obvious whether the patellar luxation is the cause or the result of increased rotational instability. Occult medial patellar luxation can become manifest only after cranial cruciate ligament injury (DeAngelis 1971; Rudy 1974). Surgical cruciate reconstruction often also solves concomitant patellar luxation (Lieben 1986), although some surgeons approach these combined surgeries by repairing the patellar luxation first during the operation (Wright 1979; Kirby 1993).

Some authors suggest that there may be a greater risk to collateral instability (Herron 1969; Rudy 1974), while others (DeAngelis and Hohn 1970; Willauer and Vasseur 1987) claim the opposite. According to Pearson (1969), patellar luxation can be seen secondary to ruptured collateral ligaments. One case has been described (Bardet and Piermattei 1983) where the mechanical trauma exerted by a chronically laterally luxated patella caused avulsion of the long digital extensor tendon. Similar observations have been reported by Brinker *et al.* (1990) who described that beside cases of long digital extensor avulsion in young long-legged dogs, the condition can occur even in mature animals, especially those with lateral patellar luxation. However, it must be considered to be very rare.

Structural changes to remote tissues of the limb can be attributable to recurrent patellar luxation. Kodituwakku (1962) advanced that coxofemoral subluxation and osteoarthritis of the hip in two of the cases in his study were probably due to luxation of the patella.

1.6. Diagnosis

1.6.1. History

The typical history in the most common congenital patellar luxation is that of an insidious progressive lameness (Turner 1982). The owners complain about recurrent episodes of total lameness for several paces after which the dog walks perfectly normally again. Most clients report that their pet is holding its hind leg noticeably flexed at the stifle joint and seems to be in considerable distress at that particular moment (Lacroix 1930; Kodituwakku 1962; Singleton 1957; Robins 1990). Some animals extend the affected limb backwards, presumably in an effort to reduce the luxation (Singleton 1957; Horne 1971). A stiff gait, on the contrary, appears if the dog tries to avoid dislocation by not flexing its stifle (Harrison 1975b). In very severe cases, abnormalities are observed once the dogs start to ambulate (Hammer 1979; Willauer and Vasseur 1987) and many owners will immediately seek professional advice.

Even in cases of traumatic luxations, there is only very rarely a definite history of specific trauma to the leg (Stader 1944; Horne 1971). Most of those dogs became suddenly 100% lame in the affected limb when they were running.

Often the simple history given by the dog owners, leads to the tentative diagnosis of patellar luxation.

1.6.2. Clinical examination

Inspection

The peculiar gait of the affected dogs should cause the clinician to examine the stability of the patella. A thorough clinical examination starts by observation of the posture and gait of the patient (Robins 1990). At rest, the stifle joint may be in a flexed position, pointing outwards, with the hock rotated medially (Blaney 1951; Vierheller 1959; Kodituwakku 1962). Bilaterally affected dogs may move both hind legs at the same time, which makes them hop in rabbit or kangaroo fashion (Vierheller 1959; Kodituwakku 1962; Horne 1971; Hammer 1979). If the patella displaces during the gait, the stifle joint cannot be extended, as the quadriceps muscle group has lost its lever (Shuttleworth 1935).

Of course, the deformity varies considerably, and early changes are sometimes so subtle that they are not appreciated before they get worse (Riser *et al.* 1969). It is also not unusual to find looseness of the patella in clinically normal dogs

(Shuttleworth 1935; DeAngelis and Hohn 1970; Wright 1979). In cats, patellar luxation is even more often an incidental finding, as many affected cats will not show any lameness (Flecknell 1977; Johnson 1986; Denny 1993).

Palpation

Digital palpation is the most valuable technique in the diagnosis of patellar luxation (Alexander 1985). Manipulations are usually not painful for the dog (Blaney 1951; Horne 1971; Rudy 1974; Nunamaker 1985). For a correct evaluation of possible pathological changes, the clinician should first examine the leg in weight-bearing posture (Roy 1971; Willauer and Vasseur 1987; Robins 1990; Coughlan 1994).

Joint effusion is characteristic for the acute traumatic type of patellar dislocation (Hohn and Turner 1984). Usually, there is no obvious swelling of the affected joint (Fritz 1989), although the stifle can have a bony enlargement in severe congenital cases (Blaney 1951). Muscle atrophy can be present and is an indicator for the degree of lameness (Fritz 1989).

If the patella can be displaced from the trochlea without excessive pressure or if it is found to be luxated, the condition is pathologic (Rudy 1966; Herron 1969). False positive patellar stability can be seen as the result of muscle forces in agitated dogs (Rudy 1974).

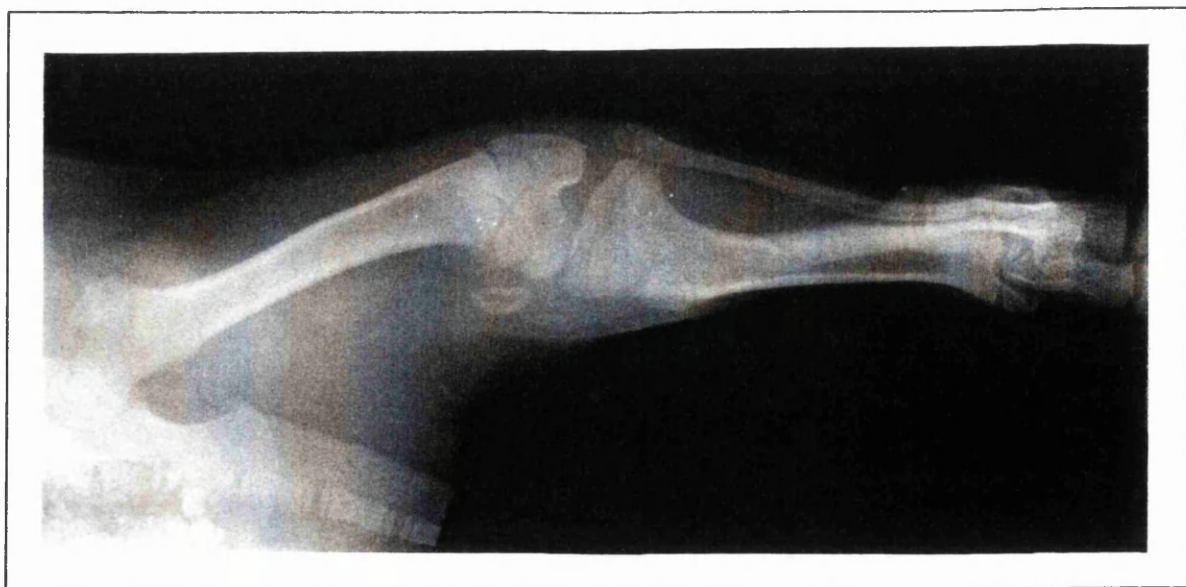The degree of tibial crest deviation and quadriceps displacement is best visible by extending the limb (Horne 1971). Extending the limb however, relaxes the quadriceps and may allow derotation, which can provoke a false negative result. Ideally, the patella is relocated and held in the trochlear groove while the patient is forced to bear weight on the limb to measure the amount of deviation (Robins 1990). The depth of the trochlear groove, on the contrary, can best be determined on the leg in flexion (Horne 1971) or by palpating the travel of the patella while performing a passive range of movement of the stifle joint (Turner 1982). In many cases, the real depth cannot be assessed prior to arthrotomy (Rudy 1974; Robins 1990).

All the other joints and all the long bones of the affected limb should be examined for abnormalities (Herron 1969). A differential diagnosis with traumatic stifle ligament injuries, Legg-Perthes disease or coxofemoral subluxation has to be made (Tangner and Hulse 1988), and other common causes of hind limb lameness as hip dysplasia or osteochondrosis lesions have to be ruled out.

1.6.3. Radiographic examination

Although radiography is seldom necessary to confirm the diagnosis of patella luxation, X-rays are advisable to eliminate other causes of hind limb lameness (Herron 1969; Fritz 1989) and to rule out fractures of the patella and avulsion or tearing of the patellar ligament (Brinker *et al.* 1990). They can be also useful to determine the degree of skeletal deformities, and the amount of osteoarthritic changes resulting from increased wear and abnormal stresses across the articular surfaces in more chronic cases (Singleton 1957; Kodituwakku 1962; Herron 1969; Zaslow 1972; Alexander 1985; Tangner and Hulse 1988; Robins 1990).

Craniocaudal and lateral views are recommended to fully evaluate skeletal abnormalities (Zaslow 1972; Alexander 1985; Robins 1990) (Picture 4). Moreover, pre-operative radiographs can be necessary to determine the amount of corrective osteotomy required (Schmidtke 1981; Slocum *et al.* 1982; Boone *et al.* 1983; Slocum and Devine 1985). Information about the bony depth of the femoral groove can be gathered from a tangential view of the trochlea. Such a skyline view is taken from the stifle in maximal flexion, with the central X-ray beam just proximal to the tibial tuberosity (Loeffler and Meyer 1961; Zaslow 1972; Park 1979; Fritz 1989; Robins 1990).



Picture 4. Conformational deformities in a severe case of medial patellar luxation in a 3 months old, male Yorkshire terrier (Craniocaudal view).

1.7. Treatment

1.7.1. Conservative treatment

Most authors do not really believe in the benefits of conservative management. On the other hand, patellar laxity is quite often an incidental finding during examination and some dogs do manage well with a lifelong occult patellar luxation (Wright 1979; Perot 1984; Nunamaker 1985; Tangner and Hulse 1988). If minimal to no clinical signs are present, conservative treatment may be tried. Weight reduction is a first thing to pursue (Wright 1932; Naserke 1966; Rohwer 1966; Tangner and Hulse 1988). Many dogs with grade I or II medial patellar luxation learn to extend their legs in order to reduce the luxated patella (Foster 1966) and do very well with rest and analgesics (Nunamaker 1985; Tangner and Hulse 1988). Bandages, splints and applications which provoke local inflammation in the lateral parapatellar area were often used in the past (Hobday 1905; Lacroix 1930; Shuttleworth 1935; Blaney 1951; Singleton 1957; Naserke 1966), but were difficult to control and did not seem extremely successful in cases of congenital medial patellar luxation. Permanent non surgical control is doubtful in long-standing cases because of secondary changes (Horne 1971).

Many puppies, especially growing puppies, have a period of patellar laxity, but the patellar usually becomes more stable as the supporting structures tighten and the muscle mass develops as the dogs mature (Blaney 1951; Foster 1966; Rohwer 1966; Rudy 1966 and 1974). In giant breeds the adjustment by the dog itself to developmental deformities is normally satisfactory when activity is temporarily restricted (Riser *et al.* 1969). In dogs with grade I luxation in both a medial and lateral direction, the initial management should consist of increased exercise in an effort to strengthen the quadriceps and the parapatellar tissues (Coughlan 1994).

Traumatic cases of patellar luxation in adult dogs tend to have a good outcome after conservative treatment in quite a high percentage of cases. Before resorting to surgical intervention, rest in a plaster cast or splint (Singleton 1957; Horne 1971; Brinker *et al.* 1990) and the use of counter-irritation (Shuttleworth 1935; Singleton 1957; Horne 1971) are well worthy of trial as the patellar may become stable again when the retinacular structures heal (Rudy 1974).

1.7.2. Surgical treatment

Surgical treatment of the syndrome of patellar luxation has distinct aims and is directly related to the functional alterations (Rudy 1974). In the first place, the patella has to be reinforced and stabilised in the femoral groove. Moreover, the surgery deals with quadriceps muscle malalignment and some of the eventual skeletal deformities. Only seldom is the condition of patellar dislocation so painful that pain relief becomes the major objective of the surgical intervention.

Most authors (O'Brien 1971; Rudy 1974; Hammer 1979; Trotter 1980; Turner 1982; Hulse and Shires 1985; Tangner and Hulse 1988; Shires 1990; Robins 1990; Butterworth 1993) advised not to delay surgery, especially in rather severely affected dogs in which the growth plates are still open, to prevent accentuation of the underlying anomalies.

Numerous different techniques have been published. The procedures depend upon the type of patellar luxation, and on the surgeon's preference. In most cases, a combination of two or more procedures is needed to achieve the optimum result. Nevertheless, the techniques requiring the least amount of surgical interference which can provide satisfactory results should always be used, as long as they correct adequately (Campbell and Pond 1972). Each case must be treated on an individual basis, and proper pre- and intra-operative assessment are extremely important (Singleton 1969; DeAngelis and Hohn 1970; Alexander 1985; Slocum and Devine 1985; Robins 1990). It may be argued that most operations which fail do so because too little is done during the pre- and intra-operative stages.

1.7.2.1. Soft-tissue reconstructive procedures

Most of these stabilising techniques are simple, and moreover, quick procedures. They have a high success rate, if used in selected cases. Often, treatment of patellar luxation in skeletally immature individuals is attempted by soft tissue reconstruction rather than by bony realignment. The major drawback is the inadequate compensation for even slight bony deformities. Their use as a single procedure for correcting patellar dislocation is consequently fairly limited.

The vast majority of techniques is equally applicable for medial as for lateral patellar luxation, but, of course, employed in reverse.

Desmotomy/Release

The supporting tissues on the side toward which the dislocation exists, are often contracted and thickened. The synovium can be contracted as well. In severe cases, this tension can be responsible for a tendency to easily reluxate, or can prevent proper reduction of the patella in the trochlear groove.

The earliest operative treatment for patellar luxation was a parapatellar desmotomy (Lacroix 1930). A simple release of the parapatellar supportive tissue on one side, mostly employed in combination with another procedure, can cause great improvement (Lacroix 1930; DeAngelis and Hohn 1970; DeAngelis 1971; Perot 1984; Brinker *et al.* 1990).

Technique : A deep incision with a scalpel is made on the side of the contracted tissues, both through the retinacular tissues and the two layers of the joint capsule. Distally, the release starts at the tibial plateau. The cut is continued further proximally, as far as necessary to alleviate the exerted tension caused by the restricting tissues. In severely bowlegged patients, partial tendonotomy of the muscle insertions on the patella can additionally be carried out (Hulse and Shires 1985). Some degree of sideways pull can reoccur when attempting to suture the created gap. Also redevelopment of the tension remains a risk. Closure of the incision is unnecessary since a layer of synovium will quickly cover the defect and reseal the joint (Vierheller 1959; Alexander 1985). Palumbo (1971) closed the medial retinacular defect in cases of medial patellar luxation with a transplant from the lateral fascia lata, pulled over the quadriceps muscle group, to increase the width of the previously contracted medial retinaculum.

Capsular imbrication and retinacular overlap

While retinacular tissues on the side toward which the patella luxates tend to shorten, a compensatory stretching of those tissues occurs at the opposite side. This allows the patella to track sideways even more. By applying overlap procedures, the patella is pulled back and held in articulation with the trochlear groove.

Technique : A normal parapatellar approach is carried out, on the side of the relaxed connective tissues. Both retinacular ligaments and joint capsule are incised parallel to and about half a centimetre away from the patella. The incision runs from the proximal tibia, and extends as a fascial incision to the midshaft of the femur. Everted mattress or Lembert sutures commence far caudally through the fascia. They cross the incision and pass through the joint capsule and the cranial

border of the fascia which is attached to the patella (Herron 1969; DeAngelis 1971). Preferably, a non-absorbable material is used.

Firstly, one can pull the two layers of the joint capsule over one another separately (Campbell and Pond 1972). Alternatively, an elliptical section of tissue is to be excised both out of the fibrous layer of the joint capsule and the femoropatellar ligament. A normal interrupted suture pattern is then used to close the created defect (Singleton 1969; DeAngelis 1971; Perot 1984). Since the synovial layer of the joint capsule can remain intact, earlier use of the limb is seen as compared to capsular overlap (Denny and Minter 1973).

Fascia lata overlap

By pulling the biceps femoris muscle more cranially, lateral tension is exerted on the quadriceps muscles and indirectly on the patella (Flo and Brinker 1970; Nunamaker 1985; Brinker *et al.* 1990).

The above can be useful as a single procedure, but only in grade I or traumatic cases where there are no skeletal deformities at all (Flo and Brinker 1970; DeAngelis 1971; Campbell and Pond 1972). A fascia lata overlap is often combined with other techniques and provides extra restraint of the patella (Rudy 1974). This method can only be used for treating patellar luxations toward the medial side.

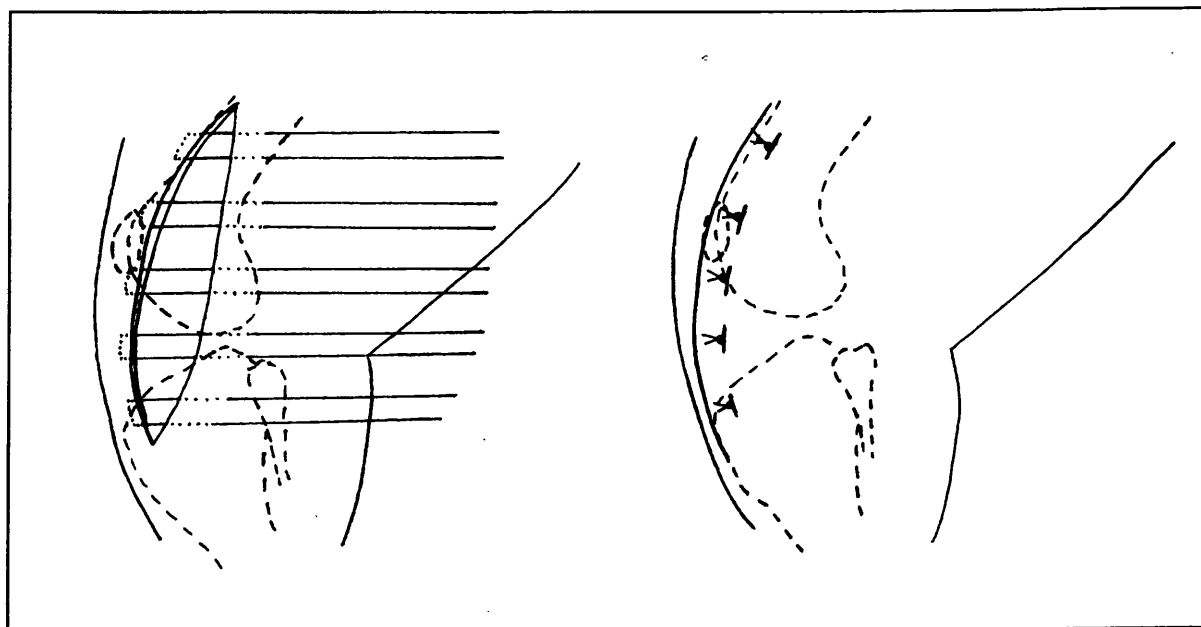


Figure 2. Fascia lata overlap. The caudal portion of the fascia lata is advanced over the cranial layer. All sutures are preplaced before being tied.

Technique : If the procedure is used alone, a standard lateral skin incision is made, after which all subcutaneous tissues are dissected away from the underlying fascia lata and the lateral retinacular tissues. The incision commences laterally from the patella, only incising the superficial fascia. Proximally, it extends along the cranial edge of the biceps femoris to the femoral midshaft. Distally, the cut continues parallel to the straight ligament. The fascia lata is bluntly separated from the underlying muscles on both sides of the incision to allow sufficient overlap of the fascial planes. Sutures are preplaced, using non- or slowly absorbable material in a mattress suture-like “vest-over-pants” pattern (Fig. 2). The first suture is placed near the patella. In the original technique described by Flo and Brinker (1970), the edge of the biceps femoris was brought forward beneath the flap of fascia lata attached to the patella. Rudy (1974) started to use the overlapping flap in the reverse direction, which appeared to be superior in achieving firm and lasting lateral support. Pull at all the placed stitches is exerted simultaneously whereby the fascia flap is pulled cranially. Then, the knots are tied one by one. An additional continuous row of sutures can be placed, holding the free flap of the cranial fascia in place.

Instead of overlapping the fascia, an elliptical piece can be excised to increase the lateral tension on the patella after suturing (Horne 1971).

Tension procedures and antirotational sutures

Dogs with a grade I luxation or those clinically affected only at an older age often do not have marked displacement of the proximal tibial crest. Increased internal rotation of the whole tibia during flexion of the stifle can be prevented by a taut ligament which pulls the patella away from the luxation side. This may be prosthetic, using suture material or autogenous tissues. The sutures are mostly anchored around the fabella, which is the pivotal point of the track of the patella. During the whole range of movement, the prosthetic loop will remain uniformly tense (Stader 1944; Brinker *et al.* 1990). Fibrous tissues will form around the artificial ligament and will maintain the patella and tibia in the right position, even if the material should stretch or even rupture. Stader (1944) was the first to describe a lateral reinforcement using a fascia lata strip, leaving the end attached to the patella intact, looped directly around the fabella as treatment for medial patellar luxations. Analogously, a few years later a portion of the tendon of the pectineal muscle was used to reinforce the medial femoropatellar ligaments in cases of lateral patellar luxation, from the fabella through the tissue above the patella and back (Blaney 1951). Another modification (Swaim and Miller 1969) of Stader’s technique in case of lateral patellar luxations employs a medial strip of the dense connective tissue

attached to the patella. This artificial ligament is then wrapped around a screw, positioned close to the medial fabella, instead of around this sesamoid itself. Later, non-absorbable sutures and stainless steel wire were tried in similar patterns. Wright (1979) always applied bilateral sutures.

Antirotational sutures are usually combined with overlap procedures. They can be applied in both medial and lateral patellar luxations.

Technique : Through an incision in the superficial fascia, the fabella on the side opposite the luxation is deeply exposed underneath the muscles. A curved needle with a non-absorbable material attached is introduced just proximal and behind the sesamoid. Cranially, the suture can be placed in several locations, forming a loop. Various sutures can be combined. The synthetic material can be attached to the tissues immediately around the patella, the distal patellar ligament, through the patella, or through a hole in the proximal tibial crest (Price 1955; DeAngelis 1971; Zaslow 1972; Rudy 1974; Trotter 1980; Brinker *et al.* 1990). The suture is tied in a figure of eight pattern, tightened enough to prevent tibial rotation, particularly during flexion when the tendency of internal rotation is maximal.

Several further modifications have been developed. Leighton (1970) made a hole through both the lateral condyle (emerging under the lateral fabella), and the patella. A type of superficial purse-string suture is inserted around the patella, using a double synthetic ligament (Schäfer *et al.* 1982). The sutures are buried underneath the connective tissues at the side opposite the dislocation, and passed two by two through two divergating transcondylar bone tunnels in the femur, made with a hand chuck. They are tied under slight tension. In very young puppies, a wire mattress suture of stainless steel can be successfully placed through tunnels in the patella, the lateral condyle, and the tibial crest at the same time (Hammer 1979).

Myoplasty

Quadriceps release

Sometimes, a sideways pull on the patella is exerted by severe malalignment of the extensor muscle group. The quadriceps has to be additionally separated from its attachments to the distal half of the femur to abolish the remained tension after other reconstructive procedures (Horne 1971; Nunamaker 1985; Brinker *et al.* 1990).

Technique : The stifle joint is approached bilaterally through the retinacular tissue and joint capsule. The lateral dissection runs up between the biceps femoris and the vastus lateralis of the quadriceps. On the medial side, the caudal sartorius is

separated from the vastus medialis of the quadriceps. Afterwards, all the bellies of the quadriceps muscle group are freed from the femoral shaft. The fascia lata is closed routinely.

Transplantation of the cranial head of the sartorius

Both the quadriceps muscles and the cranial sartorius muscle attach to the patella. The latter can contribute to a proximomedial pull. Release of this abnormal tension by repositioning of the sartorius muscle is not advised as a single procedure for treatment of medial patellar luxation, yet accounts for a higher success rate after other techniques (Horne 1979).

Technique : The cranial belly of the sartorius muscle is completely freed from the surrounding fascia and muscles at the medial side of the stifle, as to make it mobile. On the lateral aspect of the joint, an elliptical fascia strip is removed at the level of the cranial border of the biceps femoris. The cranial sartorius is pulled craniolateral and incorporated in the closure of the fascia lata defect. An additional mattress suture is placed through the straight patellar ligament to provide an extra lateral pull.

Realignment of the quadriceps muscle group

In small dogs, and in dogs with only slight deviation of the tibial crest, a modification (Horne 1971) of the tibial tuberosity transposition can be used.

Technique : The straight patellar ligament is isolated from the underlying joint capsule and its fascial attachment. Two horizontal mattress sutures in a non-absorbable synthetic material or in stainless steel are placed. They pass through the distal part of the freed ligament and through the fascia on the opposite side of the original dislocation.

Myoplasty of the vastus lateralis

Realignment of the straight patellar ligament by lateral transplantation of the tibial tuberosity can be completed by transposing a graft of vastus lateralis over the patella and the patellar ligament which pulls in the opposite way to the original dislocation and which fills up the defect in the same time (Cazieux 1967).

Technique : After freeing the tibial tuberosity from the crest, a transplant is prepared out of the vastus lateralis of the quadriceps muscle. A strip of fascia and muscular fibres of about half a centimetre is created, and isolated distally. The flap is passed over the patella to the medial side, after reattachment of the tibial

tuberosity in its new position. The fascia is sutured in place, using a synthetic material or steel wire.

After desmotomy covered by an elevated flap of fascia, a Z-suture line can be performed in the quadriceps tendon proximal to the patella to shorten this structure in order to restrain the patella tighter into the trochlea (Palumbo 1971). Likewise, the stretched patellar ligament can be corrected with an "accordion suture" (Pearson 1969; McCurnin 1976) what adds to the stability of the patella.

1.7.2.2. Bone reconstructive procedures

Trochlear groove arthroplasty

The normal physiologic pressure, exerted by the patella on the distal femur is essential to create a trochlear groove of an adequate depth (Harrison 1975a). If less than 50% of the patella is below the level of the trochlear ridges, arthroplasty of the femoral groove is indicated (Hulse and Shires 1985; Hulse *et al.* 1986; Fritz 1989). Approximately 35% of the dogs surgically treated for medial congenital patellar luxation, have abnormally shallow grooves (Vierheller 1967; DeAngelis 1971; Campbell and Pond 1972). This condition is seen in most grade III or IV luxations, where the groove remains flat or even becomes convex (Singleton 1969; Vaughan and Robins 1975). A possible exception can be made in early presented dogs, which are still skeletally immature. By restraining the patella within the confines of the trochlea by quadriceps realignment alone, sufficient load will be exerted to remodel the groove (Nunamaker 1985; Coughlan 1994).

Severe erosion of a trochlear ridge due to recurrent luxation of the patella, occurring particularly in grade II cases, will also need some type of sulcus reconstruction (Vierheller 1967; DeAngelis 1971; Rudy 1974; Robins 1990). Also in the case of a deficient trochlear ridge, because of a developmental problem, it is necessary to increase the depth of the groove.

The newly created groove has to be deep and broad enough to house the patella during all positions of its movement (DeAngelis and Hohn 1970; DeAngelis 1971; Rudy 1974; Arnoczky and Tarvin 1980; Slocum *et al.* 1982; Boone *et al.* 1983). Special care should be taken to gain a rather abrupt ridge at the side of luxation to have an optimal buttress.

The principle of deepening an abnormal shallow trochlear sulcus is certainly valid as part of the treatment of patellar luxation, since increasing the depth will restrain the patella. This may be accomplished by three different procedures.

Technique : After a standard parapatellar approach and arthrotomy, the patella is luxated medially to expose the trochlea. At this time, the joint can be examined to rule out any possible concurrent stifle joint problem.

Trochleoplasty : With a scalpel blade, two parallel cuts are made in the articular cartilage, just axial to the highest point of the trochlear ridges. All the cartilage in between requires abrasion, until the underlying cancellous bone is exposed (Vierheller 1959). Some of the subchondral bone is also removed, using a rasp or rongeurs. Then, the surface is smoothed again. It is well known that the excised articular cartilage fails to regenerate properly. Granulation tissue is quickly formed upon the vascular subchondral bone. This layer will undergo metaplasia to a more fibrous type of tissue. Later, it will reorganise and differentiate into fibrocartilage, and will fully cover the induced defect (DeAngelis 1971; Rudy 1974; Vaughan and Robins 1975; Horne 1979; Wright 1979; Mankin 1982; Slocum *et al.* 1982; Boone *et al.* 1983; Hulse and Shires 1985; Slocum and Devine 1985; Fritz 1989; Moore and Banks 1989). This cartilaginous substitute responds less ideally to weight-bearing articulation (Brinker *et al.* 1990). This procedure is easy and very quick, but has a major drawback in that the smooth articular cartilage in the bottom of the sulcus is by no means preserved, and pronounced osteoarthritic changes will occur. Resurfacing the abraded trochleoplasty site with an inverted periosteal graft, harvested on the proximal tibia, accelerates the production of cartilage, but also here it is of a more fibrocartilaginous nature (Hulse *et al.* 1986). The erosion of the articular surface of the patella by its tracking over the irregular and roughened trochlear sulcus in the early postsurgical period can be prevented by application of a periosteum strip. Fritz (1989) observed in individual cases that the deepened groove had grown back to its original shallowness three to six years after surgery.

Cartilage flap sulcoplasty : The technique is started in the same way as the procedure described above, but the cartilage in between the parallel scalpel incisions is elevated as a rectangular flap, which remains attached distally or proximally. Some of the exposed subchondral bone has to be removed to provide a sufficient groove, after which the cartilage is replaced. Additional procedures to stabilise the flap are unnecessary, since the restraint of the patella will exert enough pressure to keep the graft in place. This procedure can be only employed in puppies under four to six months of age. The working-method is quite similar to the trochleoplasty, however, without the articular cartilage being destroyed. In mature dogs, the cartilage becomes too brittle, and also far too thin, which makes it impossible to prepare it free from the underlying bone (Flo 1969; Harrison 1975b; Hohn and Turner 1984; Hulse and Shires 1985; Slocum and Devine 1985; Brinker *et al.* 1990).

Wedge recession sulcoplasty : With a fine saw blade, V-shaped cuts are made from the highest rim of the trochlear ridges, both laterally and medially (Fig. 3 and Picture 5). An isosceles triangle of subchondral bone, covered by intact articular cartilage is thus created. The grafted wedge is then freed as a block, and preserved in a moistened swab. Owing to the width of the saw cut (kerf), the base and the depth of the V-groove will be slightly larger than the removed osteochondral wedge. This amount of recession of the trochlear groove will already provide a sufficient deepening in small breed dogs. It is sometimes recommended to remove the sharp caudal edge of the graft, by which the wedge will fit more securely in a lower position after replacement. In larger animals or if more deepening is required, extra slices of bone parallel to the first cut have to be removed from either one or both sides of the trochlear defect to make the deepening adequate (Fig. 4).

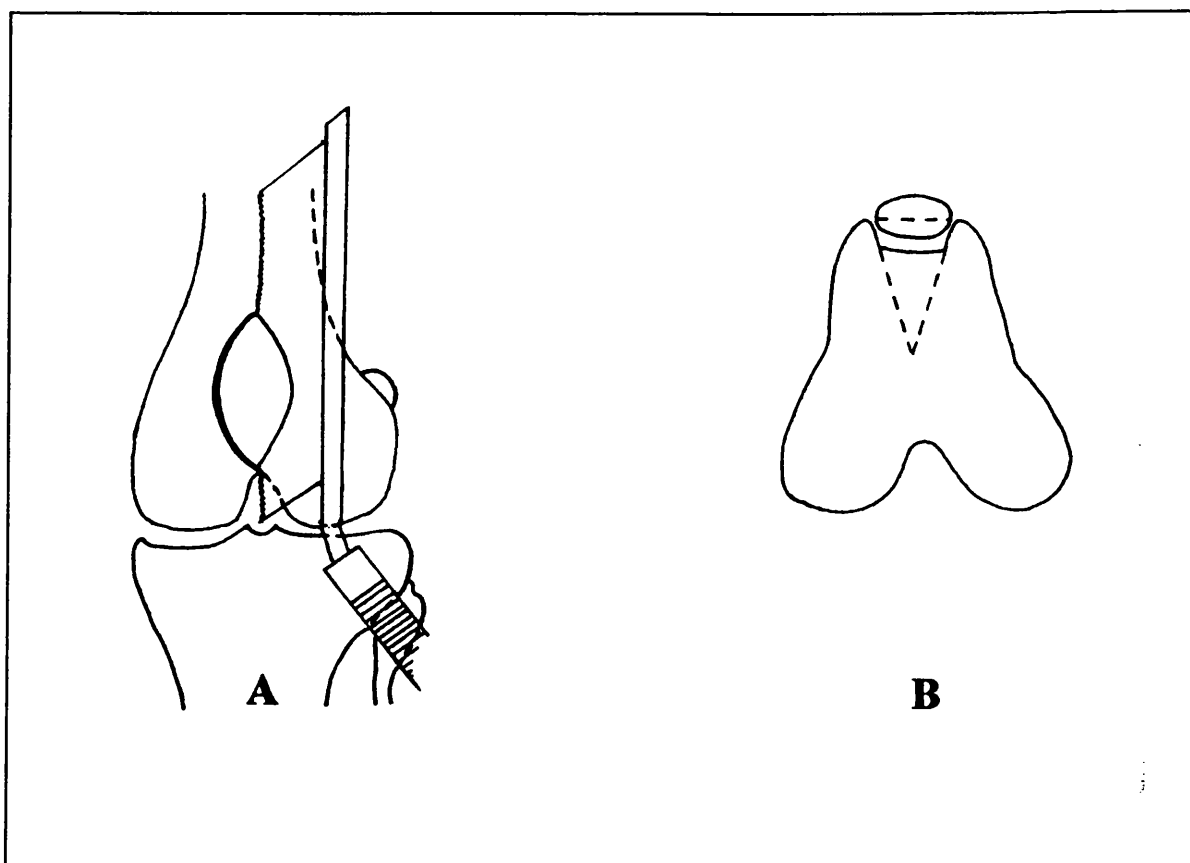
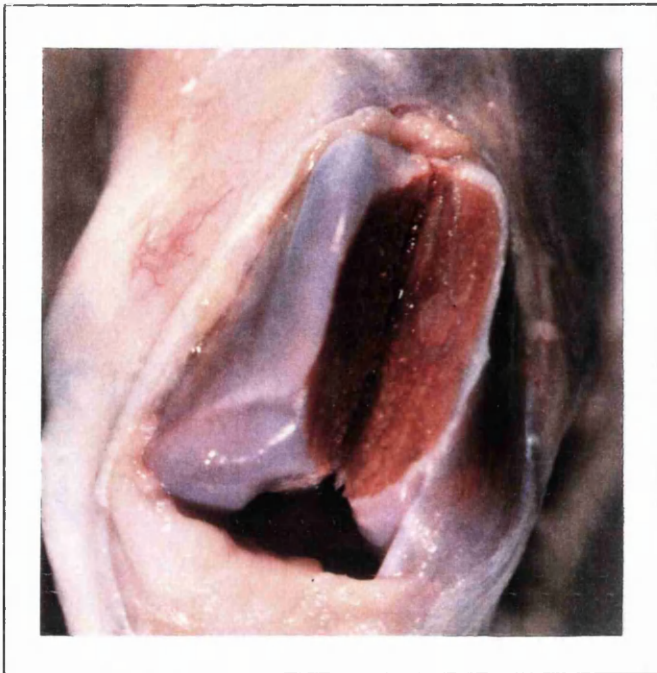


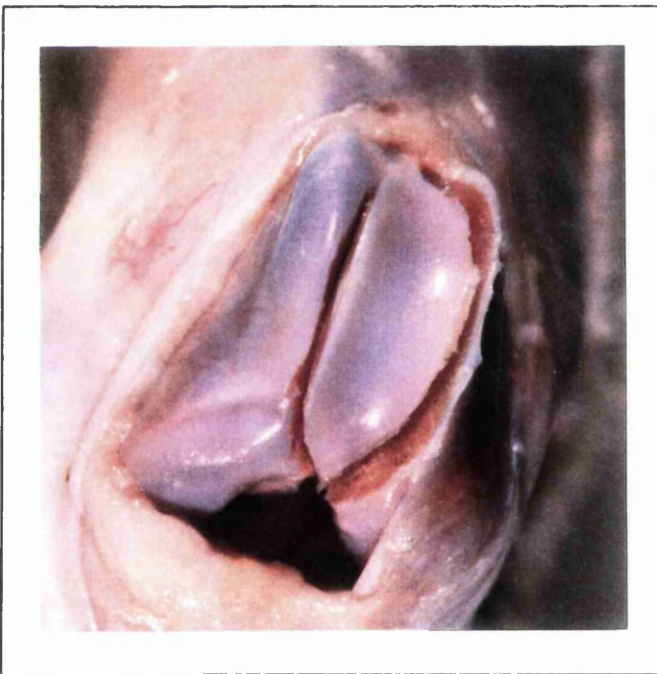
Figure 3. Trochlear recession sulcoplasty.

A V-shaped cuts are just axial to the trochlear ridges, using a hacksaw.

B The sulcus depth after replacement of the grafted wedge has to be at least half of the patellar height.



A



B

Picture 5. Trochlear recession sulcoplasty.

A The trochlea after removal of the wedge.

B The graft in its new, recessed position.

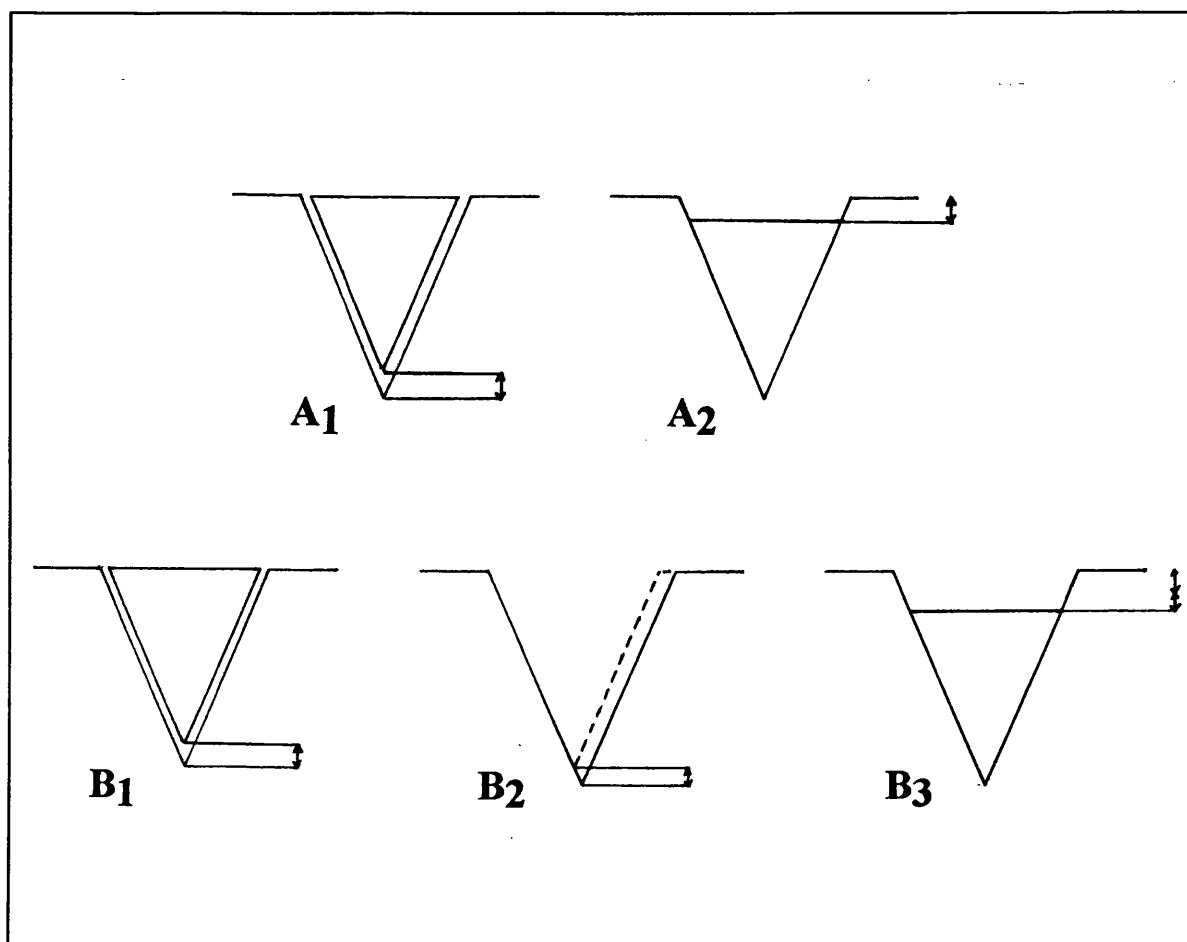


Figure 4. The principles of recession wedge sulcoplasty (concept of similar triangles).

A Smaller breeds

A₁ A wedge shaped piece of subchondral bone and articular cartilage is cut from the trochlear groove. Due to the kerf, the height of the bone graft will be slightly smaller than the depth of the cut in the distal femur.

A₂ In the smaller breeds, generally enough recession is achieved by removing the bone dust and replacing the wedge. Removal of the sharp apex of the graft can make it sit lower and more securely in position.

B Larger breeds

B₁ A wedge shaped piece of subchondral bone and articular cartilage is cut from the trochlear groove.

B₂ An extra slice of bone is removed parallel to the first cut at the side opposite the luxation.

B₃ Repositioning of the grafted wedge will show an increased amount of recession.

A sufficient wedge recession will be present if the sulcus depth after replacing the original wedge approximates at least 50% of the height of the patella (Hulse and Shires 1985; Hulse *et al.* 1986; Fritz 1989). Once the graft is repositioned in the recessed trochlea, stabilisation occurs merely by the conformation of the new trochlea, helped by the compressive force of the patella. Thus, any additional procedure is unnecessary. Since surgeons started to use this technique, only one case of trochlear wedge migration has ever been reported (Remedios *et al.* 1992).

The greatest advantage of the wedge recession technique is certainly the effective deepening of the groove, while the integrity of the articular cartilage is optimally maintained, even in mature animals (Slocum *et al.* 1982; Boone *et al.* 1983; Slocum and Devine 1985; Fritz 1989; Slocum and Devine 1993). After this procedure, the bottom of the new sulcus remains as living and smooth articular cartilage, supported by its original underlying bone. Only along the sides, some fibrocartilage will line the borders of the wedge.

Tibial tuberosity transposition

In veterinary literature, much attention has been paid to the position of the tibial tuberosity and its relocation if deviated. Correction of patellar luxation by transposing the tibial tuberosity to a more cranial position is performed fairly commonly in veterinary practice. The purpose of the surgical interference is to move the insertion of the patellar ligament to realign the quadriceps mechanism, which in turn will reposition the patella in the trochlear groove. The surgery is rather quick and the procedure is relatively simple.

Numerous long-term surveys involving a large number of patients have demonstrated successful results (Mackey and McCune 1967; Singleton 1969; DeAngelis and Hohn 1970; Venker-Van Haagen 1975; Hutter *et al.* 1983; Fritz 1989; Arnoczky and Tarvin 1990). Only in the series of Denny and Minter (1973) have poor results after transposition of the tibial tuberosity been recorded. The technique may be equally well employed to correct lateral patellar luxation as it can for medial luxation. Generally the response on a medial transplantation of the tibial tuberosity is likewise satisfactory, because of the existant genu valgum (Horne 1971; Denny 1985).

Surgical indications are directly related to the tibial rotation and the deviation of the tibial crest, as occurs in grade II, III and IV patellar luxations (Horne 1971; Rudy 1974; Denny 1985). Independently of the degree, correction by transplantation should be employed in all cases in which deviation of the tibial tuberosity can be appreciated (Campbell and Pond 1972; Arnoczky and Tarvin 1990; Robins 1990).

The wide majority of patients with congenital patellar luxation, presented in a referral practice, seem to require relocation of the tibial tuberosity to achieve more consistent realignment of the quadriceps (Coughlan 1994). Equally in some cases of old untreated luxations of a traumatic origin, the procedure has proved to be valuable (Perot 1984). Indicated by the degree and type of deformity, additional bone and soft-tissue reconstructive procedures can be employed.

One major drawback of this procedure has been reported. Although Perot (1984) considered the transposition as a direct application of the aetiopathogenesis, shifting the tibial tuberosity to a more cranial position does not prevent further medial rotation of the tibia (Rudy 1974; Nunamaker 1985). Deformity of the lower limb and outward pointing of the hocks will occur as the animal moves. Concurrent fibular head transposition should be helpful to compensate for this internal rotation as it tenses the lateral collateral ligament, thus rotating the tibia externally (Nunamaker 1985).

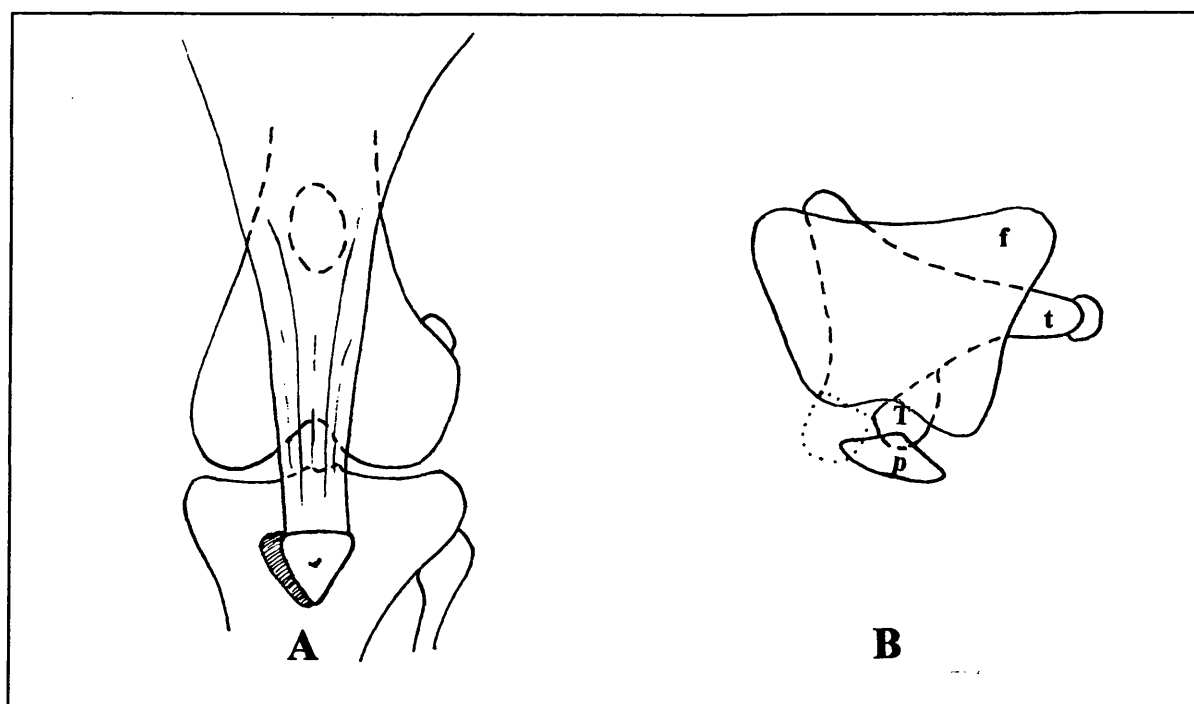


Figure 5. Tibial tuberosity transposition in case of medial luxation of the patella.

A The partially osteotomised tubercle is moved to a more lateral position and reattached with a K-wire under the elevated cranial tibial muscle.

B Relationship between the distal femur (f), the proximal tibia (t) with its relocated tuberosity (T), and the patella (p).

Technique : Singleton (1957) was the first veterinary surgeon to describe this operation, based on the Hauser technique in humans. Later, the procedure gained a widespread application after several simplifications and modifications (Vierheller 1959; Brinker and Keller 1962; Mackey and McCune 1967; Singleton 1969; DeAngelis and Hohn 1970; Campbell and Pond 1972; Zaslow 1972; Rudy 1974; Venker-Van Haagen 1975; Hutter *et al.* 1983; Perot 1984; Brinker *et al.* 1990; Riih  1993).

The stifle joint is approached by a lateral parapatellar incision. Beside a lateral arthrotomy, a short incision is made parallel to the patellar ligament on the medial aspect, and the straight ligament is separated from the fat pad and the joint capsule. The cranial tibial muscle has to be partially elevated from the proximal tibia by blunt dissection in cases of medial patellar luxation where the tuberosity has to be transplanted laterally. On the medial aspect, soft tissue attachments are incised to further isolate the tibial tuberosity.

Assessing the most suitable new position for the insertion of the quadriceps tendon can cause some difficulty, and remains somewhat subjective. The degree of shifting is based on the realignment of the extensor mechanism whereby the stifle joint flexes and extends without observable torsion. Assessment of the necessity of transplantation already has been determined during pre-operative clinical examination, but is more accurately done at the time of the surgery (DeAngelis 1971; Campbell and Pond 1972; Venker-Van Haagen 1975; Hulse and Shires 1985; Robins 1990). Permanent patellar luxations are sometimes followed by secondary shortening of the quadriceps muscle and its tendon of insertion. On the one hand, to avoid excessive tension, the tuberosity graft has to be fixed in a more proximal position (Robins 1990). While on the other, Venker-Van Haagen replaced all the grafts not only sideways, but simultaneously also distally, so that they came under some tension by slight stifle flexion.

A bone curette, a periosteal elevator, or a rongeur is used to roughen the cortex, creating a graft bed. Just above the planned site, a groove can be created in the tibial plateau with rongeurs, to accept the straight patellar ligament in its new position with relieved tension on this structure (Mackey and McCune 1967; Singleton 1969). A triangular portion of the proximal tibial crest with the insertion of the patellar ligament is cut, using bone cutters, an osteotome, a hacksaw, or Gigli wire. Care should be taken not to transect the distal soft tissue attachments. Distally, the attached periosteum and fascial extension will prevent the grafted bone being pulled proximally by quadriceps contraction (Vierheller 1959). Only if the tibial tuberosity has to be moved much further than its original location will a total

osteotomy need to be performed (DeAngelis and Hohn 1970; Venker-Van Haagen 1975; Hutter *et al.* 1983; Nunamaker 1985; Brinker *et al.* 1990). The bone transplant is levered cranially for the predetermined distance (Fig. 5). The sharp corner of the tibial osteotomy site can be cut off to obtain a new surface that smoothly runs out into the intact cortex of the proximal tibia (Brinker *et al.* 1990). Stability of the patella in the trochlear groove should be tested at this stage. If the quadriceps mechanism is correctly realigned by transposing the tuberosity, little tendency for luxation should be noted, even before closure or imbrication of the soft tissues (Arnoczky and Tarvin 1983; Robins 1990). Different ways of fixation are applicable, but the risk of fragmentation of the graft in very small dogs will limit the possibilities. A single Kirschner wire is most often used. In larger dogs, one or two K-wires in combination with tension band fixation might guarantee a more rigid fixation. The pins have to be angled caudally and slightly proximally across the tibia, to optimally resist the quadriceps pull. They are inserted until their points just emerge through the trans cortex. Other means to achieve secure reattachment of the grafted bone include a lag screw, or a wire suture in a mattress pattern to one or two predrilled holes (Singleton 1957; DeAngelis and Hohn 1970; Fritz 1989). The cranialis tibialis muscle is sutured over the osteosynthesis implants. Recently, very encouraging results of the use of biodegradable rods to fix osteotomy sites have been reported (Räihä 1993).

For biomechanical reasons, Maquet (1979) combined in humans tibial tuberosity transposition with significant advancement of the tuberosity by inserting iliac grafts. The lever arm of the patellar ligament was improved and simultaneously intra-articular pressure by the patella against the femur decreased considerably. For a similar reason, Singleton (1959) preferred to carry out a transposition of the tibial crest as a whole in large breed dogs and short-legged breeds with prominent crests. The proper function of this prominent ridge in leverage is thus retained. On the other hand, DeAngelis (1971) advised to place the bone block in large dogs into a window, cut in the cranial aspect of the proximal tibia. In this way, subcutaneous protrusion will be avoided, although the grafted piece might be rather thick.

In very young puppies, especially those of the smaller breeds, an early correction of bony deformations can be achieved by cutting the attachment of the patellar ligament on the proximal tibia, and reattaching it by suturing so that the extensor mechanism is realigned (Perot 1984). The hazards of transferring the tibial tubercle in the skeletally immature patient are thus avoided.

Fibular head transposition

Originally, this procedure was designed to be an extracapsular method of cranial cruciate repair (Smith and Torg 1985). Nunamaker (1985) considered the principle of this technique even more appropriate to be part of the treatment of severe grades of medial patellar luxation in dogs. By shifting the fibular head cranially, the attached lateral collateral ligament will tense, thereby creating external rotation of the tibia, which in turn realigns the deviated tibial tuberosity, and thus the whole extensor apparatus.

Technique : Following inspection of the joint through a medial parapatellar approach, the fibular head and attached collateral are carefully dissected free from the tibia. Reattachment in a more cranial position under the cranial tibial muscle is done with a tension band wire and a Kirschner wire driven into the fibular head, or a Kirschner wire placed just behind it (Nunamaker 1985; Smith and Torg 1985; Brinker *et al.* 1990).

Corrective osteotomy

The application of transverse, oblique, or wedge osteotomy of the distal femur and proximal tibia has been described as correction for severe conformational defects (Shuttleworth 1935; Rudy 1974; Schmidtke 1981; Perot 1984). Osteotomy just proximal to the trochlea should be carried out in the first place. Only when the malalignment is total should tibial osteotomy also be considered as the final stage of the repair (Rudy 1971). The surgery aims to re-establish the physiological axis of motion, muscle pull, and articulation with the axis of the long bones. Frequently, both angular and rotational correction is necessary simultaneously (Rudy 1971; Schmidtke 1981; Perot 1984).

The involved procedures, however, are fairly complex and impractical. There is a great risk of postsurgical complications, and a satisfactory outcome is not guaranteed (Horne 1971; Brinker *et al.* 1990; Coughlan 1994). Corrective osteotomy is therefore only indicated if rotation and lateral angulation of the femorotibial joint are so pronounced that normal procedures are not sufficient to create a functionally normal joint. Some of those corrective techniques, however, remain necessary in combination with the osteotomy.

Technique :

Correction of varus deformity of the femur associated with medial patellar luxation :

The distal third of the femur is approached laterally by fascial incision in between

the biceps femoris and the vastus lateralis muscle. A wedge-shaped section of bone is removed. The base of the wedge is at the convex surface of the deformity, thus has to be laterally. The cuts can be made by using a saw, by means of an osteotome after predrilling several transverse holes, or with bone cutters (Shuttleworth 1935; Rudy 1974; Schmidtke 1981; Perot 1984). Generally, only a small bone slice has to be removed in order to straighten the femur. To avoid limb shortening in extreme cases, an oblique osteotomy can be advantageous. The point of the proximal fragment will be placed into the medullary cavity of the distal bone, thus providing a pivotal point (Rudy 1971; Newton *et al.* 1984). Schmidtke (1981) described a transverse corrective osteotomy of the femur. Inward rotation of the distal limb by about 12° realigns the trochlea with the straight patellar ligament. The created defect between the two fragments can best be filled with autogenous cancellous bone graft to accelerate the healing process (Brinker *et al.* 1990). According to the surgeon's preference, an intramedullary pin, a plate, screws, Kirschner wires, orthopaedic wires through bone tunnels, or an external fixator can be applied. Skeletal fixation of the osteotomy ideally should not interfere with normal stifle movement. For this reason, external splinting or casting should be avoided, and moreover have they proved to be usually ineffective as a single stabilisation technique after osteotomies (Shuttleworth 1935; Rudy 1971 and 1974; Schmidtke 1981; Perot 1984).

Correction of valgus deformity of the femur associated with lateral patellar luxation in small breeds : A closing wedge osteotomy or an oblique osteotomy of the distal femoral shaft is carried out to correct for the retarded growth of the lateral side of the distal epiphysis. The procedure is exactly the same as the one to correct varus deformity, but the base of the wedge will be medial (Rudy 1971).

Correction of valgus deformity of the femur associated with lateral patellar luxation in large and giant breeds : In those breeds, the cuts will be more proximal in the femur, since the angulation is seen in the diaphysis of the bone, and osteotomy is optimally accomplished at the site of maximal deformity (Newton *et al.* 1984). A transverse or wedge osteotomy in the midshaft or even in the proximal third of the femur is performed. The femur is derotated and placed so that the patella remains again in the centre of the trochlear groove. Bone plate fixation is most often used (Rudy 1971; Brinker *et al.* 1990).

Correction of angulation and torsion of the proximal tibial shaft : Two different corrective procedures have been described. Via a dorsal skin incision a medial wedge osteotomy of the tibial plateau can be carried out. Kirschner wires are used to fix the fragments (Perot 1984). Because the angular deformity is usually less

pronounced than the axial torsion, Rudy (1971 and 1974) preferred a medial approach to the proximal third or even the middle of the tibia, to employ an osteotomy of the tibial shaft. Fixation by means of intramedullary pinning is very satisfactory, but other fixation techniques are also possible.

Correction of hypodevelopment of the medial condyle : The procedure is directly adopted from human medicine, and only reported in the veterinary literature by Perot (1984). A lateral arthrotomy is performed to expose the femoral condylar region. A so-called combination opening-closing wedge osteotomy is performed (Newton *et al.* 1984). Hereby, the cuts for creating a wedge are started just proximal to the trochlear ridges, the base of the wedge facing laterally. The graft is removed, inverted and replaced in between the two major fragments, so that its base is now on the medial side which lengthens the proximal aspect of the medial condyle. Lag screwing the fragments together is the recommended way of osteosynthesis.

Implants

To compensate for aplasia or hypoplasia of the femoral condyle, surgical implantations of different types were designed to increase the height of the trochlear ridge of the dislocated side. Such implants function by keeping the quadriceps muscle tendon in proper alignment, which in turn maintains the patella in the trochlear groove (Pearson and Ramsey 1963). Polytetrafluoroethylene, alloy and bows of steel have been successfully implanted, both in experimental and clinically affected dogs (Pearson and Ramsey 1963; Pearson 1967; Sommer 1975).

Good clinical results are claimed for all of the implant types, if surgery is properly performed (Pearson and Ramsey 1963; Pearson 1967; Sommer 1975). Horne (1971), however, did not see any definite advantage in these techniques over others, since the implants are only a mechanical means of preventing the patella from luxating. As time goes by, connective tissue capsules will cover the implant. Some degree of bone necrosis and periosteal thickening is found with plastic and alloy implants, because these synthetic materials cause a foreign body reaction in the stifle joints (Pearson and Ramsey 1963; Pearson 1967).

Technique : To treat a medial luxating patella, a medial approach to the stifle joint is used. The implant is placed just proximal to the joint capsule, its dorsal part in line with the medial trochlear ridge. Wire or screws are used to anchor the synthetic prosthesis. The bow of steel is hammered itself into the femur.

Epiphysiodesis

Where marked bony deformities associated with patellar luxation have already developed in young, growing patients, there is the possibility of stapling the growth plate of the distal femur and proximal tibia (Perot 1984). Excessive growth on the convex side is controlled and further bowing of the long bones will be prevented or even corrected by undisturbed growth across the contralateral growth plate. Indirectly, these corrective changes will also improve the alignment of the quadriceps muscle group.

This procedure is quite delicate and needs a thorough follow-up to avoid overcorrecting.

Technique : Through a standard lateral arthrotomy of the stifle, staples are placed across the growth plates on the convex sides of the deformed bones. Proper placement is difficult to achieve, and is necessary to get the desired growth retardation.

The previous procedure can be combined with periosteal elevation on the opposite, concave side of the growth plate. A similar technique is often used in young foals to correct angular limb deformities (Auer *et al.* 1982), and has also been employed successfully in severe cases of genu valgum in giant breed puppies (Miller, personal communication).

Patellectomy

The main indication for patellectomy in dogs is marked erosion and eburnation of the articular cartilage, where further trauma to the exposed subchondral bone makes the condition extremely painful. This pain is likely to persist and the lameness does not improve at all or is even exacerbated after the patella has been replaced and is maintained securely in the trochlear groove (Schmoker 1960; Singleton 1969; DeAngelis 1971; Campbell and Pond 1972; Brinker *et al.* 1990; Robins 1990). Long-standing grade II patellar luxations predispose to the condition because the patella is frequently luxating and relocating (Singleton 1969; Robins 1990). According to Bennett (reported by Coughlan 1994), the problem is most commonly seen in Staffordshire and English bull terriers.

Fortunately, such severe cartilage damage is seen only infrequently in dogs. It is clear that surgical removal of the patella is a rather radical procedure. Recovery is recorded to be rather slow. Patellectomy is generally associated with some degree of quadriceps atrophy, because the presence of the patella seems to have a

beneficial effect on the efficiency of the contraction mechanism (Singleton 1969; Kaufer 1979; Hulse 1981b). Absence of the sesamoid bone interferes with the physiological biomechanics of the stifle joint, and it may result in progressive degenerative osteoarthritis (DePalma and Flynn 1958; Rudy 1974; Worrell 1975; Steurer *et al.* 1979; Arnoczky and Tarvin 1980). Removal of the patella increases considerably the intra-articular compressive force transmitted from the femur to the tibia, because the patellar tendon is now allowed to sink deeper in the trochlear groove. It may be the immediate cause of the aggravation of the femorotibial osteoarthritis (Maquet 1979). Absence of the sesamoid is also responsible for some increase in the stifle joint instability (Hulse 1981b). One survey records an oval radiopacity at the patellectomy site which was considered as being an ossific nucleus of a regenerating patella (Worrell 1975).

In case of doubt about the significance of the cartilage lesions, it is often recommended firstly to await further evolution without removal of the patella. If the problem is really refractory to all other therapies, one can still decide to a patellectomy at a second operation (Hohn and Turner 1984; Robins 1990). It is clear that this does not correct any existing anatomical abnormality, but at least it permits the quadriceps tendon to slip over the femur without electing further pain (Vierheller 1959). Following the implantation of patellar prosthesis in dogs no gross pathological changes were seen by Worrell (1975), and in addition the overall function of the stifle was much better than after patellectomy. Experimental transplantation of a patella from one dog to another has been used as a model for transplantaion of sections of joints in general (Vaughan and Formston 1973). The clinical results were hopeful, despite the fact that crepitus was present and radiographic changes in the transplant were obvious 1 year after the surgery. Sometimes, patellectomy is the only alternative for the even more radical stifle arthrodesis (Perot 1984).

Technique : A lateral and a medial parapatellar approach are used to dissect the patella from the surrounding tissues. Sharp dissection is conducted from the poles of the articular surface side towards the centre. The patellar ligament, the quadriceps tendon, and the fascia are elevated by means of a periosteal elevator. In order to preserve the continuity of the ligamentous tissues as much as possible, the excision has to be carried out very carefully on the periosteal surface of the patella (Craver 1938; Rudy 1974; Brinker *et al.* 1990; Robins 1990). Some surgeons (Singleton 1969) prefer to split the bone longitudinally and in the midline, prior to removal. Schmoker (1960) removed only that half of the patella to which the stronger femoropatellar ligament was attached, to facilitate the preservation of the ligamental structures. The created defect is closed in a single mattress suture

pattern or in a combination with longitudinal locking loop sutures, using a non-absorbable material. The latter suture type will shorten the quadriceps tendon, and reinforce the straight patellar ligament (Arnoczky and Tarvin 1990). In addition to the removal of the patella, realignment of the extensor group is carried out (Robins 1990). Post-operatively, splinting of the limb is recommended for about one to three weeks (Craver 1938; Gibbens 1957; Schmoker 1960; Brinker *et al.* 1990). Return to a normal exercise level should be attained within six to eight weeks (Brinker *et al.* 1990).

Arthrodesis of the stifle joint

In very rare cases stifle arthrodesis is one option for the surgical treatment of patellar luxation. However, it is sometimes the only alternative to limb amputation in chronic grade IV luxations where there is enormous deformation and severe secondary degenerative joint disease of the stifle (Newton and Nunamaker 1984; McLaughlin 1993). Flexure contraction and periarticular fibrosis are totally unresponsive to conventional surgical intervention, and there is no way to restore proper use of the limb. The stifle joint has to be fused at almost the normal standing angle, which allows placing of the paw on the ground, without excessive abnormal angles in the joints of the opposite leg (Denny and Minter 1973; Brinker *et al.* 1990; Cofone *et al.* 1992). The appropriate angle at which to arthrodesise the stifle is selected by measuring the angle on the sound contralateral side, while the animal is standing. Five to ten degrees are added to allow for limb shortening caused by the femoral and tibial osteotomies (Newton and Nunamaker 1984; Lesser 1985).

Although post-operative function of the leg is not normal at all, especially not at an higher speed, it is certainly acceptable for a pet dog, for this “mechanical” lameness is now a pain-free condition (Brinker *et al.* 1990; Cofone *et al.* 1992; McLaughlin 1993).

Technique : The main principles of arthrodesing a joint such as scrupulous removal of all cartilage, use of cancellous bone graft, and rigid fixation in a physiologically functional joint angle have to be pursued. Several methods have been described (Newton and Nunamaker 1984; Lesser 1985; Brinker *et al.* 1990; Cofone *et al.* 1992; McLaughlin 1993).

1.7.3. Post-operative care

Surgical correction affects the success rate of the procedure much more than the application of a post-operative splint or bandage (DeAngelis 1971).

A lot of authors recommend to immobilise the operated leg temporarily in full extension, certainly in very active dogs. Stader (1944), Herron (1969), Flo and Brinker (1970) and DeAngelis and Hohn (1970) apply a modified Thomas splint for one to two weeks. Others (DeAngelis 1971; Zaslow 1972; Venker-Van Haagen 1975; Arnoczky and Tarvin 1983; Hohn and Turner 1985; Brinker *et al.* 1990; Riih  1993) advise just a padded bandage. A cast can also be used (Swaim and Miller 1969; Horne 1971; Denny and Minter 1973) to immobilise the joint structures.

Certainly not all surgeons are convinced that joint movement very soon after surgery should be avoided. After the surgical intervention, biomechanically unsound forces are dissolved (Vierheller 1959) and early use is beneficial to the range of movement of the operated stifle joint (Vierheller 1959; Palumbo 1971; Rudy 1974; McCurnin 1976). Although use of the limb should be encouraged, only moderate exercise on a leash is allowed (Palumbo 1971; Rudy 1974; McCurnin 1976; Horne 1979; Denny 1985; Hohn and Turner 1985; Tangner and Hulse 1988; Brinker *et al.* 1990; Robins 1990) for about the first four weeks. After this period, activity is gradually increased. Stairs (Palumbo 1971) and jumping (Horne 1979; Brinker *et al.* 1990; Robins 1990) should be avoided absolutely.

Physiotherapy is recommended in dogs with severe deformation of the limbs (Robins 1990) or if the animal refuses to bear weight on the operated leg for more than four weeks (Brinker *et al.* 1990). Active physiotherapy is preferable, but swimming is impracticable most of the time. Repeated passive flexion-extension may be very useful in such a cases.

Antibiotics can be administered as prophylaxis for three to five days after surgery (Blaney 1951; Vierheller 1959; Swaim and Miller 1969; Zaslow 1972; Denny 1985).

Since toy breeds have not proved to be especially tolerant of pain, a course of non-steroidal anti-inflammatory drugs can be useful to help to stimulate early attempts to use the limb (Brinker *et al.* 1990).

1.7.4. Treatment of bilateral patellar luxation

Not all the dogs with bilateral involvement need surgical intervention in both knees (Fritz 1989). Once full function of the most severely affected limb is regained by means of surgery, some patients seem to walk surprisingly well, as has been reported in humans as well (Brattström 1964). By using the steady leg, weight can be taken off the other, unoperated one. As a matter of routine, only few authors (McCurnin 1976; Hammer 1979; Brinker *et al.* 1990) would operate on both affected legs at the same time, basically to avoid extra costs and dangers associated with a second anaesthesia. Where surgery is required on both hind limbs, surgical interference is carried out first on the more severely affected leg (Herron 1969; Arnoczky and Tarvin 1983). An interval of four to eight weeks is left between the operations on each stifle (Blaney 1951; Kaplan 1971; Rudy 1974; Arnoczky and Tarvin 1983; Hutter *et al.* 1983; Denny 1985; Remedios *et al.* 1992; Butterworth 1993). In this way, the dog may avoid the total discomfort resulting from the immediate post-operative lack of use of its hind legs.

1.8. Prognosis after treatment

1.8.1. Prognosis after conservative treatment

Non surgical treatment of medial patellar luxation with rest and analgesics has been suggested (Nunamaker 1985). Conservative treatment usually gives only a temporary relief (Horne 1971). Affected dogs in which the patellar luxation is not corrected tend to develop secondary osteoarthritis of the stifle joint. They are at a greater risk of tearing the cruciate (DeAngelis and Hohn 1970; DeAngelis 1971; Denny and Minter 1973; Rudy 1974; Vasseur *et al.* 1985; Brinker *et al.* 1990; Remedios *et al.* 1992; Doverspike *et al.* 1993) and collateral (Herron 1969; Rudy 1974; Hulse and Shires 1985) ligaments in the affected leg as they get older.

In cats, non operative measures seem to be recommended in most patellar luxations (Nunamaker 1985).

1.8.2. Prognosis after surgical treatment

In the literature, one can find more agreement on the merit of surgical intervention for treatment of patellar luxations. There is no single technique, however, recommended as being superior to all the others (Leighton 1970). A proper assessment before surgical repair leads to better ultimate success rates (Singleton 1969; DeAngelis and Hohn 1970; Slocum and Devine 1985; Robins 1990). But even surgical reduction does not necessarily prevent the progression of osteoarthritis (Reinhard 1966; Willauer and Vasseur 1987; Roy *et al.* 1992).

Age of the patient does not significantly influence the prognosis for the outcome (Singleton 1969; Willauer and Vasseur 1987). But, in general, success after surgery is inversely related to the age of the patient at the time of onset of the patellar problems (Nunamaker 1985).

The outcome of surgical intervention is likely to depend on the stage at which the luxation becomes clinically manifest (Livesey 1913; Schröder and Schirrmacher 1980). The more severe the bony changes, and/or in cases of concurrent stifle or hip problems, the poorer is the prognosis (DeAngelis 1971; Alexander 1985; Nunamaker 1985) although there will be a vast improvement in the performance and ability of the animal (Singleton 1969; Kaplan 1971; Hammer 1979; Slocum and Devine 1985; Robins 1990). If at the moment of surgery there is contracture of the caudal muscles and the soft tissues, especially caudally to the joint, inability to fully extend the stifle joint can be persistent (Denny 1985; Butterworth 1993).

An overall success rate after surgery of 80 to 90% has been recorded by most of the authors (Singleton 1969; DeAngelis and Hohn 1970; Venker-Van Haagen 1975; Horne 1979; Robins 1990). Some series carry markedly poorer results (Denny and Minter 1973), using the same surgical techniques. Success is usually measured on the absence of lameness, and not on the patellar position at the time of the follow-up evaluation. Willauer and Vasseur (1987) questioned therefore whether or not a clinically sound post-operative gait is related to the type of surgery, since the absence of lameness seems rather unrelated to the perfect restabilisation of the patella.

Good use of the operated limb is regained, on average, a period of three weeks after most procedures (Livesey 1913; Pearson and Ramsey 1963; Boone *et al.* 1983).

Post-operative complications are rare (Campbell and Pond 1972; Remedios *et al.* 1992). Rupture of the anterior cruciate ligament after surgical reduction of a luxating patella could be caused by the new stresses applied to this ligament secondary to the correction (Willauer and Vasseur 1987). Recurrent grade I luxations can be palpated in quite a high percentage of operated stifles, although lameness is usually absent (Willauer and Vasseur 1987; Remedios *et al.* 1992) while, on the contrary, in cases of lateral patellar luxations in toy poodles the recurrence of luxation does cause problems (Denny 1993). Kodituwakku (1962) thinks that recurrent patellar luxation in adult animals in some cases may lead to a persistent form of dislocation of the patella.

2. Retrospective study

2.1. Materials and methods

2.1.1. Patients

The first wedge sulcoplasty at GUVH was performed in June 1988. In cases of canine patellar luxation it provided a corrective surgical procedure for the condition known as shallow trochlear groove .

Over a 5 year period (1988-1993) the orthopaedic records at Glasgow University Veterinary Hospital were searched for cases of dogs with luxation of the patella. From these, dogs with medial patellar luxation that underwent a surgical correction by wedge sulcoplasty (WS), by transposition of the tibial tuberosity (TTT), or by a combination of both techniques (WS+TTT) were selected. Patients with grade IV luxations were excluded from this survey. Additional criteria for selection included the absence of any concurrent orthopaedic problem in the hind legs. Not all patients fulfilling the conditions were available for follow-up. A few dogs had died or were euthanased for an unrelated problem, while some dog owners could no longer be contacted.

A total of 44 dogs was available for follow-up. Six patients had needed bilateral treatment by one of the above-mentioned surgical procedures. Bilateral surgeries were carried out 6 weeks apart in 4 of these dogs, while the remaining 2 dogs had the contralateral patella stabilised with an interval of 8 and 23 months respectively. A larger group of the selected dogs was diagnosed to have bilateral medial luxation of the patella. A high percentage of them, however, only needed unilateral surgical correction of the disorder, or only had a soft-tissue reconstructive procedure carried out on the second stifle. Bilateral cases were assessed as two individual cases. Thus, 50 stifles were considered. Breed, sex, age, weight, grade of luxation and surgical techniques were recorded from the medical case reports in the Department of Veterinary Surgery (Table 1).

At the Veterinary Hospital, 18 different breeds had been seen which required one of the aforementioned techniques to correct their dislocated patella. The breed distribution is recorded in Table 2. The Cavalier King Charles spaniel was the most represented breed (26%). Thirty-two patients (64%) belonged to the small breeds. One quarter (25%) of the larger breed dogs were Labradors.

Case	Breed	Sex	Age (y)	Wght (kg)	Grade	Procedure
109636	Boxer	F	1.5	20	2	WS
110011	Bull Terrier	F	2.5	24	2	WS
110011	Bull Terrier	F	3	28	2	WS
110721	Cairn Terrier	FN	1.3	8.5	1	WS
110721	Cairn Terrier	FN	1.5	8.5	1	WS
114625	Cavalier King Charles Spaniel	F	0.67	10	2	WS
110287	Cavalier King Charles Spaniel	F	1	11	2	WS
109585	Cavalier King Charles Spaniel	MN	1.4	13	2	WS
119102	Cavalier King Charles Spaniel	F	3	7	1	WS
111833	Cavalier King Charles Spaniel	FN	5.1	15	2	WS
113615	Dachshund	F	9	5.5	2	WS
113335	English Bulldog	M	0.58	24	3	WS
111095	Labrador	M	0.8	30	3	WS
111095	Labrador	M	1.4	31	2	WS
114303	Labrador	M	1.6	31.5	2	WS
105484	Labrador	M	2.5	37.5	2	WS
112301	Miniature Poodle	M	3	7	2	WS
114186	Stafford Bull Terrier	F	3	18	1	WS
115996	Tibetan Spaniel	F	0.5	3.8	2	WS
108367	X-bred	FN	1	14	2	WS
116222	Yorkshire Terrier	M	1.3	4.3	2	WS
114097	Yorkshire Terrier	F	2.5	3.5	3	WS
115793	Yorkshire Terrier	F	6.5	4	2	WS
122850	Bull Terrier	F	0.7	21	1	TTT
122469	Cavalier King Charles Spaniel	M	0.6	5.5	2	TTT
122469	Cavalier King Charles Spaniel	M	0.95	5	2	TTT
117434	Cavalier King Charles Spaniel	M	1.3	11.5	2	TTT
121235	Labrador	M	0.42	25.5	2	TTT
118705	Papillon	F	0.83	1.5	2	TTT
118586	Stafford Bull Terrier	M	1.9	20.5	1	TTT
116420	Welsh Terrier	F	1	12.5	2	TTT
120419	Yorkshire Terrier	F	2.5	1	2	TTT
122253	Yorkshire Terrier	FN	7	4.2	2	TTT
112350	Cairn Terrier	M	1	6.5	3	WS+TTT
123142	Cavalier King Charles Spaniel	M	0.9	12.5	2	WS+TTT
121958	Cavalier King Charles Spaniel	M	0.92	8	2	WS+TTT
122741	Cavalier King Charles Spaniel	M	1.6	14	2	WS+TTT
116801	Cavalier King Charles Spaniel	F	3	10	3	WS+TTT
112528	Cavalier King Charles Spaniel	FN	5	4	2	WS+TTT
116788	Chihuahua	M	1	2	2	WS+TTT
121319	Chow Chow	M	0.58	24	2	WS+TTT
112386	Collie	FN	1.5	20	3	WS+TTT
117843	Labrador	M	1.9	36	3	WS+TTT
111157	Miniature Poodle	M	6	5	3	WS+TTT
107901	Shetland Sheepdog	F	8.8	8	3	WS+TTT
119723	Stafford Bull Terrier	F	4	14.5	2	WS+TTT
114186	Stafford Bull Terrier	F	5	18	2	WS+TTT
116517	Yorkshire Terrier	M	5.1	4	2	WS+TTT
116184	Yorkshire Terrier	F	6	2.7	3	WS+TTT
122253	Yorkshire Terrier	FN	7	4.5	3	WS+TTT

Table 1. Information recorded from the medical case reports.

Breed	Total (50)
Cavalier King Charles Spaniel	13
Yorkshire Terrier	8
Labrador	6
Stafford Bull Terrier	4
Bull Terrier	3
Cairn Terrier	3
Miniature Poodle	2
Boxer	1
Chihuahua	1
Chow Chow	1
Collie	1
Dachshund	1
English Bulldog	1
Papillon	1
Shetland Sheepdog	1
Tibetan Spaniel	1
Welsh Terrier	1
X-bred	1

Table 2. Breed distribution across survey.

The average body weight of the patients was 13.2 kg., ranging from 1.0 to 37.5 kg. (Table 1).

The sex incidence is represented in Fig. 6. Eight of the female dogs were neutered, whereas only one male was castrated. The overall sex ratio was 28 female to 22 male animals. This difference in number, however, is not significant, since the calculated χ^2 for the sexes does not exceed the table value for χ^2 for a probability of 95% ($\chi^2 = 0.72$ by $P < 0.05$) (Owen and Jones 1990).

The age at the time of surgical correction of the luxating patellae is shown in Fig.7. The age incidence ranged from 5 months to 9 years, and the average age of presentation stands at 2 years 7 months. Seventeen dogs (34%) underwent surgery before they reached the age of 1 year. Eleven dogs (22%) were 5 years or over before they had their patellae stabilised.

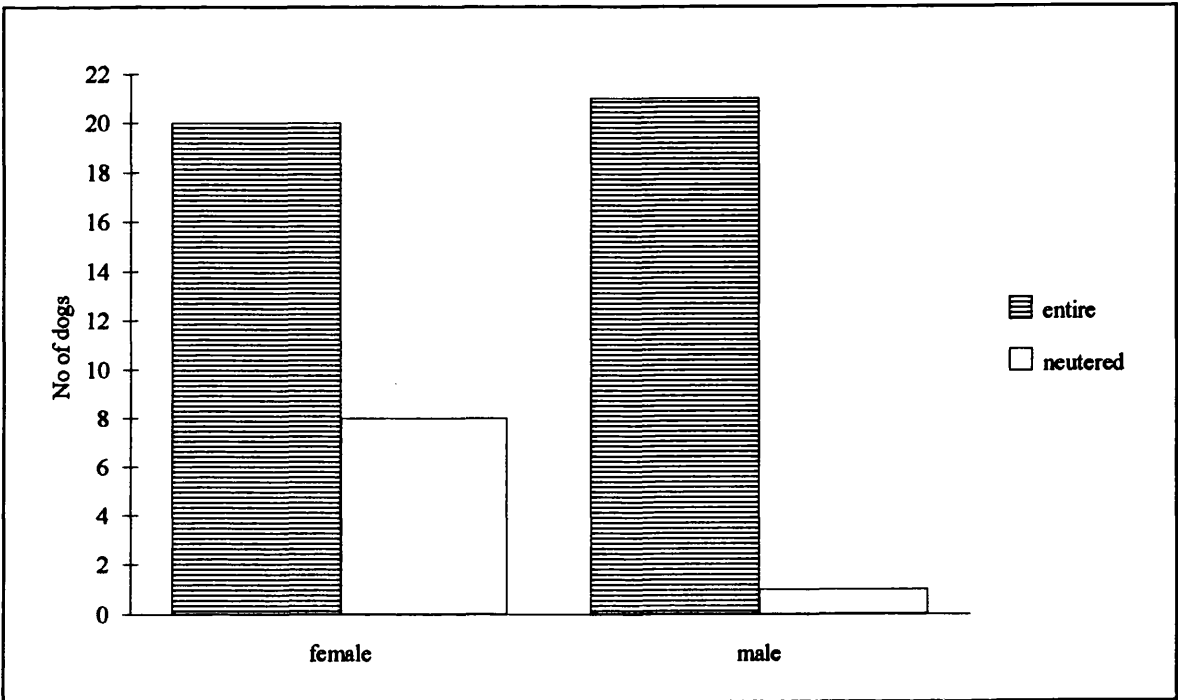


Figure 6. Sex incidence across survey.

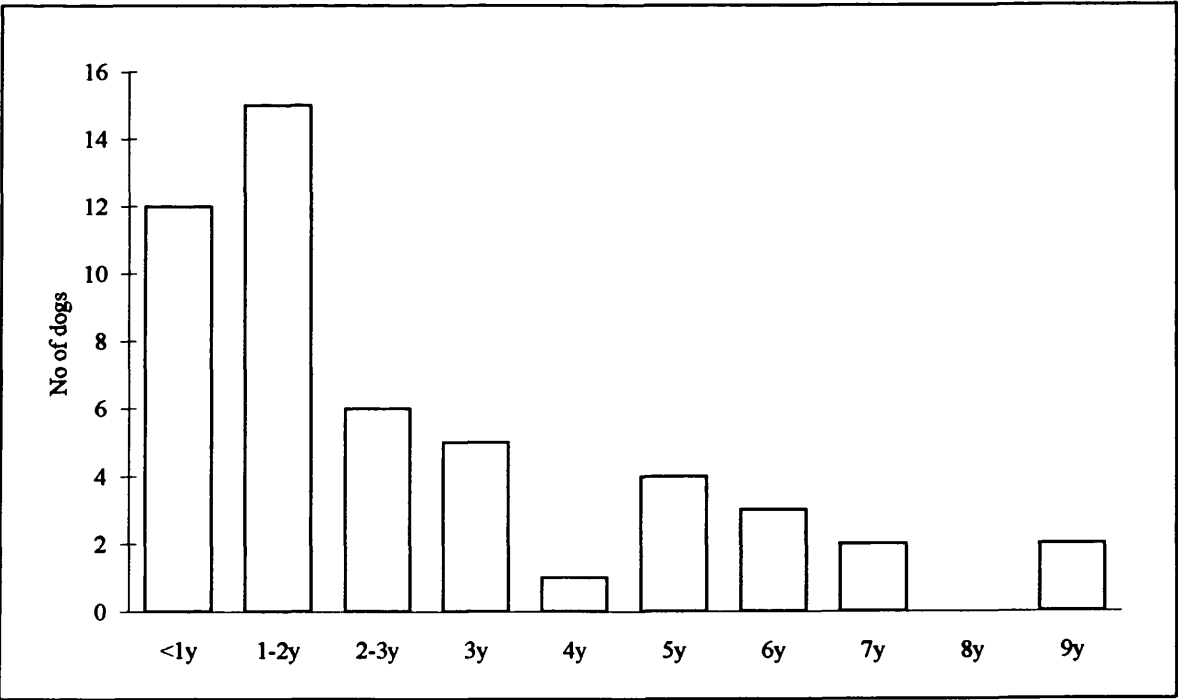


Figure 7. Age incidence across survey.

2.1.2. Pre-operative examination

Of the initial case histories, gathered by the Veterinary School from the owners, only 34 owners (68% of cases) had reported any details concerning the duration of symptoms prior to surgery (Fig. 8). From those for whom information exists, only one case was referred within the first week of the start of the clinical problems. Ten of the cases were brought into the Veterinary Hospital within one month of the onset. In 7 dogs the lameness had been present for about 2 months. The luxating patella in the remaining patients was recorded to be of a rather chronic nature. Some of these dogs underwent soft-tissue reconstructive procedures by the referring veterinarian prior to their presentation at Glasgow University. In these cases, the surgical techniques used had failed to adequately resolve the patellar instability.

Each dog was examined by observation for gait abnormalities and by palpation of the stifle joint. The stability of the patella was assessed, and deviation of the tibial tuberosity if present, was noted. Cases which had concurrent laxity of the joint due to cranial cruciate ligament rupture were excluded from this survey to avoid disturbance of the clinical results.

A standard lateral radiograph of the affected stifle was taken before starting the surgery. Skyline views were not carried out routinely since they were not considered necessary to choose the most appropriate surgical procedure (Picture 6).

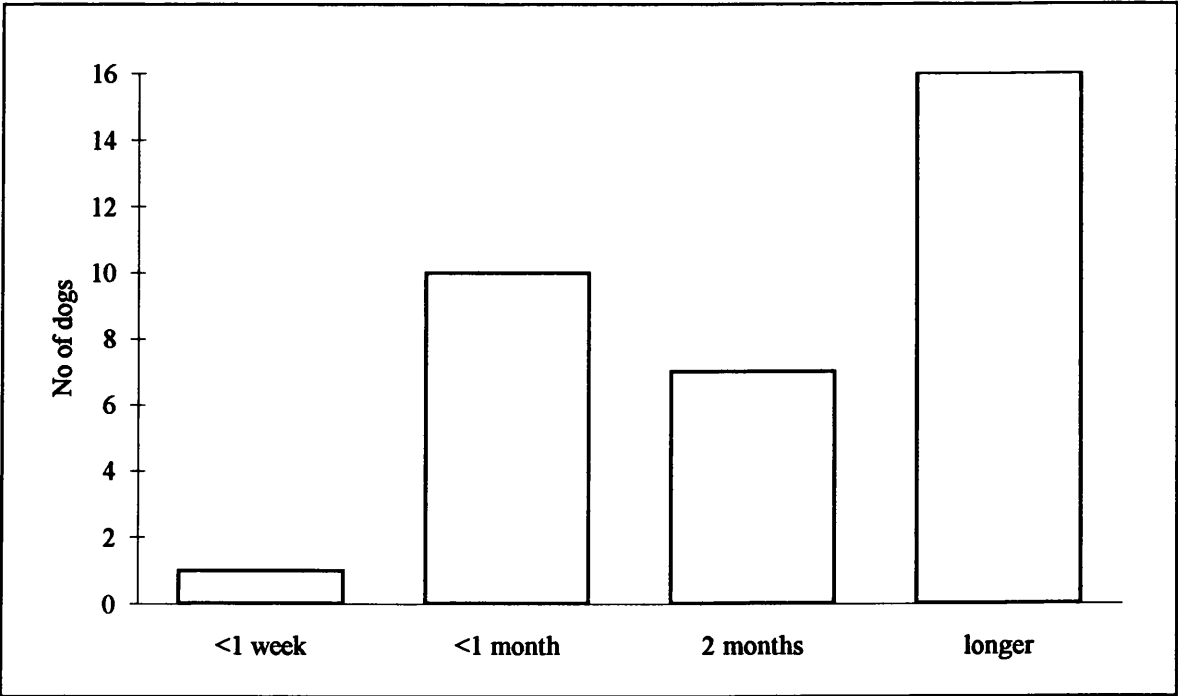
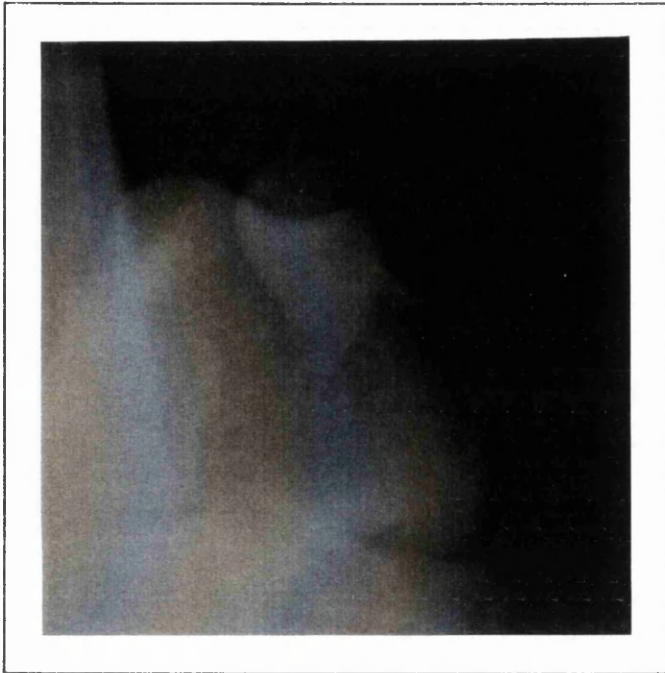
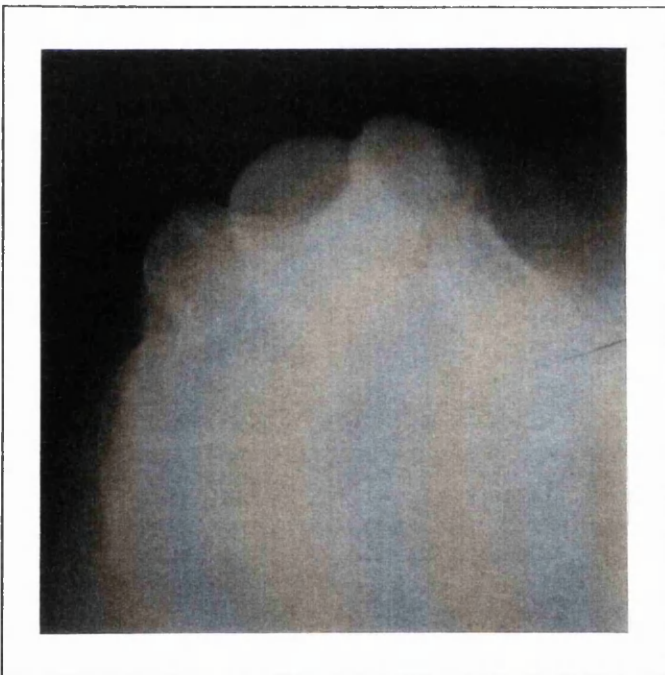


Figure 8. Duration of lameness prior to surgery (34 cases).



A



B

Picture 6. Skyline view of trochlear groove.

A Prior to surgical deepening.

B After wedge sulcoplasty.

To assign a grade of medial luxation, the criteria proposed by Singleton (1969) were used (Table 3). The classification was made on clinical examination before and at the time of surgery. Only 6 dogs with grade I medial patellar luxation were considered to require a recession wedge sulcoplasty (4) or a tibial tuberosity transposition (2). None of them required the combination of both procedures. Most of the cases (66%) were classified as having a grade II type of dislocating patella. Another 22% showed grade III luxations. The majority of dogs in this category needed the combination-surgery. The ratio of the luxation grades in combination with the procedures they required is shown graphically in Fig. 9.

Grade I	* intermittent dislocation of the patella	* patella easily luxates, but returns to normal position when manual tension is released * no or minimal deviation of the tibial crest
Grade II	* frequent luxation of the patella * leg sometimes carried	* manual reduction of the patella is possible, but relaxation occurs easily * up to 30° of tibial torsion
Grade III	* permanently luxated patella * weight bearing with the stifles semi-flexed	* tibia medially twisted between 30° and 60° * hock abducts and adducts by flexion and extension of the stifle

Table 3. Classification of the degree of medial patellar luxation.

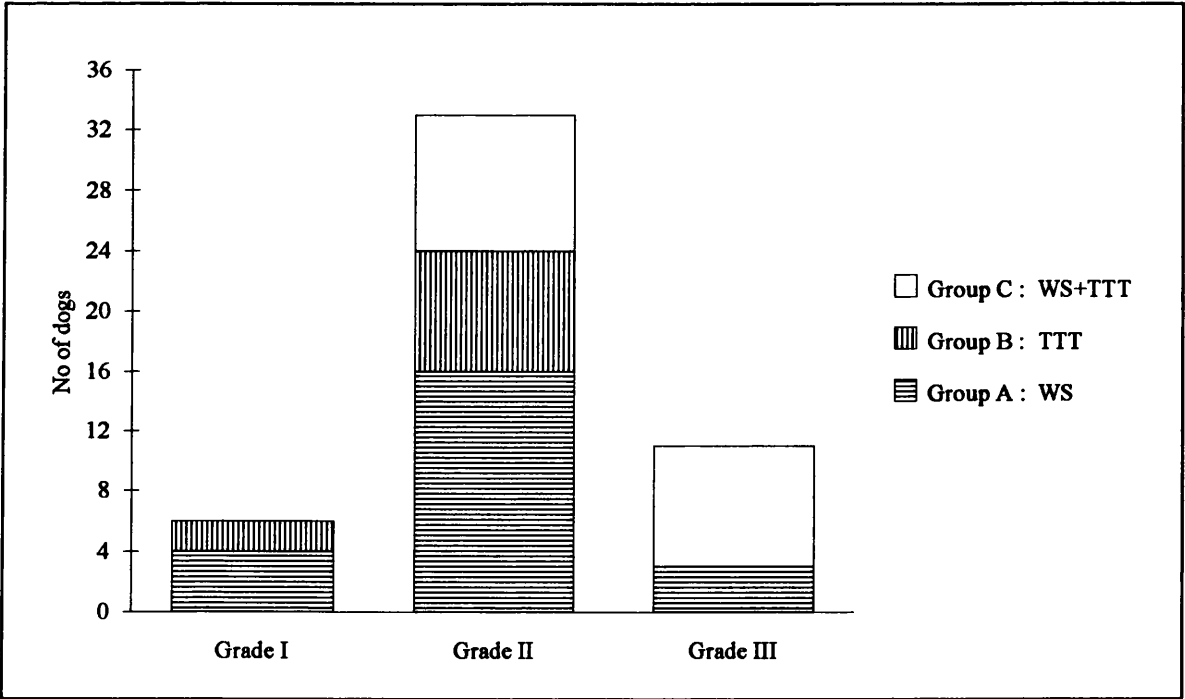


Figure 9. Luxation grade and required surgical procedure.

2.1.3. Surgical procedures

The assessment of the necessity for transposition of the tibial tuberosity and/or deepening of the trochlear groove was mainly based on evaluation during surgery.

The joints were always examined for any combined pathology. All types of surgery were routinely accompanied by a fascia lata overlap during the closure.

All dogs were operated on at the Veterinary Hospital of Glasgow University by the faculty surgeons or by postgraduate students.

Twenty-three dogs (46%) were considered to need deepening of the trochlear groove by the wedge recession technique, while realignment by tibial tuberosity transposition appeared to be unnecessary (group A : WS) (Picture 7). During the 5 year period, only 20% of the selected patients (10 dogs) has been treated solely by a transposition of the tibial tuberosity to a more lateral position (group B : TTT). In 34% of the selected cases (17 animals), a combination of both above-mentioned procedures was employed at the time of surgery for adequate correction of the present skeletal abnormalities (group C : WS+TTT). The ratio is reflected in Fig. 10.

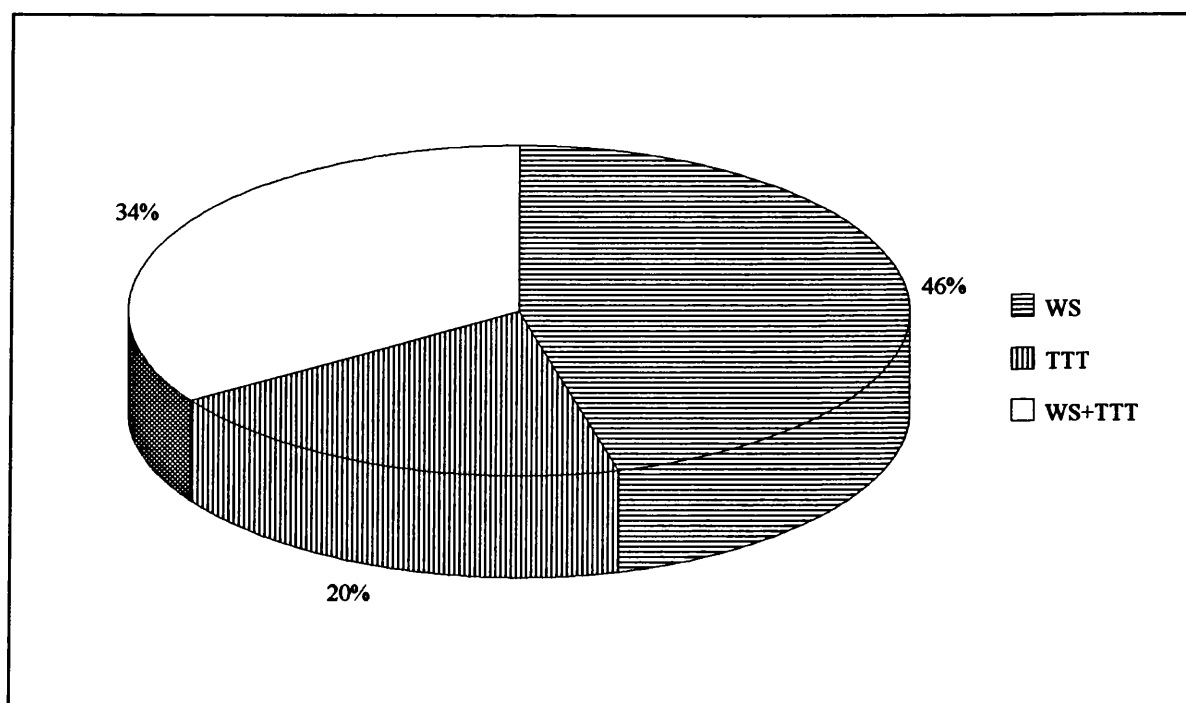
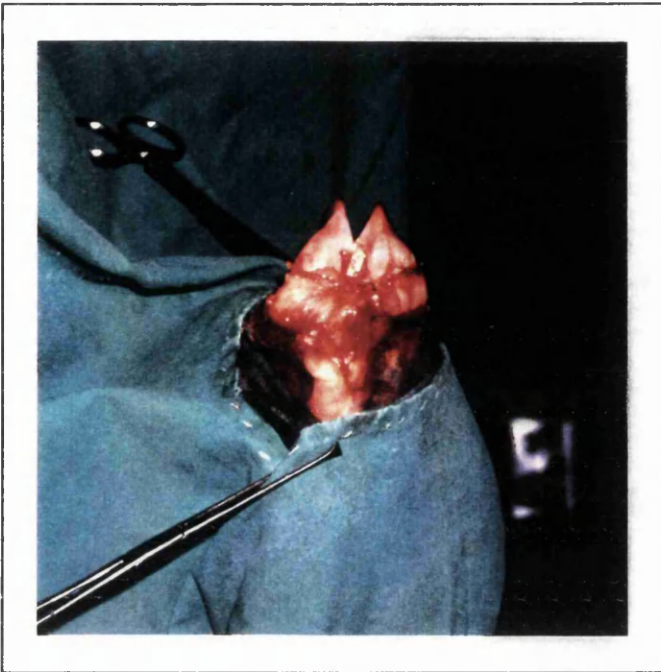
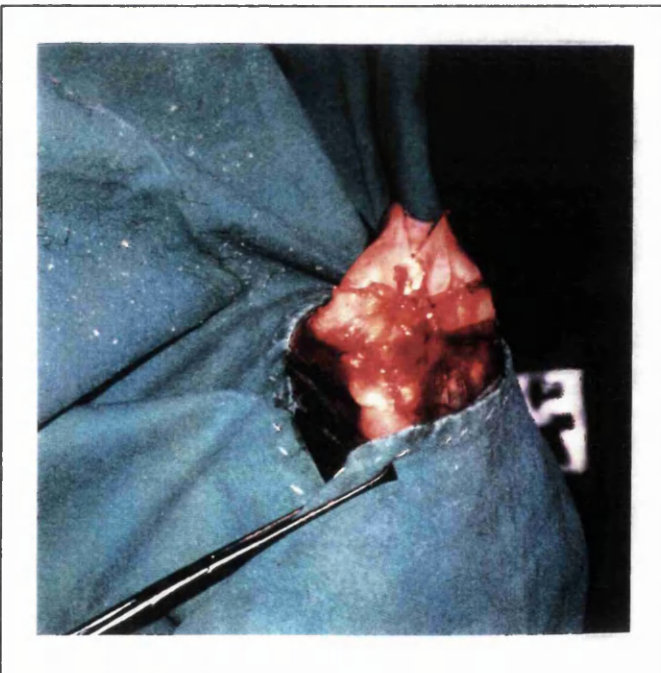

Figure 10. Ratio of surgical techniques.



A



B

Picture 7. Trochlear recession sulcoplasty.

A The trochlea after removal of the wedge.

B The graft in its new, recessed position.

2.1.4. Post-operative evaluation

CLIENT QUESTIONNAIRE

1. DID THE ANIMAL APPEAR TO BE IN PAIN FOLLOWING SURGERY?

☐ no

☐ yes

IF YES

☐ mild

☐ severe

2. HOW LONG DID IT CARRY THE LIMB FOR?

☐ less than 1 week

☐ 1 week

☐ 2 weeks

☐ 3 weeks

☐ 4 weeks

☐ longer

3. HOW LONG DID IT TAKE TO BECOME COMPLETELY SOUND ON THE OPERATED LEG?

☐ less than 1 month

☐ 1 to 2 months

☐ 2 to 3 months

☐ longer than 3 months

☐ never

4. WAS THE SURGERY SUCCESSFUL?

☐ yes

☐ no

IF NO

☐ slight improvement

☐ no improvement

☐ worse than before surgery

5. ANY ADDITIONAL COMMENTS?

Figure 11. Questionnaire completed by the dog owners.

A routine clinical check had been carried out on all patients 6 weeks post-operatively. At this time, 2 dogs were found to need repeated surgical interference since the first operations had failed to adequately stabilise the patella. In one dog, initially only a recession wedge sulcoplasty had been employed, and during the second surgery the tibial tuberosity was transplanted. In the second dog, a wedge sulcoplasty, a tibial tuberosity transplantation, and a fascia lata overlap had been performed in the first operation. Further lateral movement of the tibial tuberosity and a medial desmotomy was done at the time of the second surgery, and the patella was found to be stable at the follow-up examination 6 weeks later. In both cases, it is the final outcome which is included in the survey.

The long-term information was gathered principally via a client questionnaire (Fig. 11). All owners were first contacted by post. An extremely high response (46 out of the total 50 cases were available for the selective follow-up) was achieved. Post-operative information about the remaining 4 dogs was obtained by telephoning the owners.

The Chi Square test (χ^2) was selected as the most convenient significance test to statistically evaluate the information gathered. Three different groups, in accordance with the type of surgery, were compared at the 5% level ($P < 0.05^*$) (Owen and Jones 1990).

2.2. Results

The total number of cases with adequate post-operative information is 50. The overall results for each surgical procedure (wedge sulcoplasty, tibial crest transposition, or the combination) are summarised in Tables 4, 5 and 6, and in Fig. 15.

Breed	Age	Grade	Reported result	Additional Comments
Tibetan Spaniel	0.5	2	successful	
English Bulldog	0.58	3	successful	stiff in rising, no pain
Cavalier King Charles Spaniel	0.67	2	successful	still stiff, no pain
Labrador	0.8	3	successful	slight rotation when sitting
X-bred	1	2	successful	
Cavalier King Charles Spaniel	1	2	successful	
Yorkshire Terrier	1.3	2	successful	
Cairn Terrier	1.3	1	successful	straight leg when sitting
Labrador	1.4	2	successful	
Cavalier King Charles Spaniel	1.4	2	successful	
Boxer	1.5	2	successful	
Cairn Terrier	1.5	1	successful	straight leg when sitting
Labrador	1.6	2	successful	straight leg when sitting
Bull Terrier	2.5	2	successful	
Yorkshire Terrier	2.5	3	successful	
Labrador	2.5	2	successful	only stiff after hill climbing
Cavalier King Charles Spaniel	3	1	successful	
Bull Terrier	3	2	successful	
Stafford Bull Terrier	3	1	successful	
Miniature Poodle	3	2	successful	
Cavalier King Charles Spaniel	5.1	2	successful	
Yorkshire Terrier	6.5	2	successful	sensitive scar site
Dachshund	9	2	successful	

Table 4. Group A : WS (23).

Breed	Age	Grade	Reported result	Additional Comments
Labrador	0.42	2	successful	
Cavalier King Charles Spaniel	0.6	2	successful	
Bull Terrier	0.7	1	successful	
Papillon	0.83	2	successful	occasionally hops, no pain
Cavalier King Charles Spaniel	0.95	2	successful	
Welsh Terrier	1	2	successful	
Cavalier King Charles Spaniel	1.3	2	successful	lame after excessive exercise
Stafford Bull Terrier	1.9	1	slight improvement	muscle loss, no pain
Yorkshire Terrier	2.5	2	successful	
Yorkshire Terrier	7	2	successful	

Table 5. Group B : TTT (10).

Breed	Age	Grade	Reported result	Additional Comments
Chow Chow	0.58	2	successful	required second surgery
Cavalier King Charles Spaniel	0.9	2	successful	
Cavalier King Charles Spaniel	0.92	2	successful	lame after excessive exercise
Chihuahua	1	2	vast improvement	inward rotation, lifts leg occas.
Cairn Terrier	1	3	successful	
Collie	1.5	3	successful	
Cavalier King Charles Spaniel	1.6	2	vast improvement	on constant painkillers
Labrador	1.9	3	successful	required second surgery
Cavalier King Charles Spaniel	3	3	successful	
Stafford Bull Terrier	4	2	worse than before	very stiff, carries leg quite often
Stafford Bull Terrier	5	2	successful	
Cavalier King Charles Spaniel	5	2	successful	
Yorkshire Terrier	5.1	2	successful	
Miniature Poodle	6	3	successful	leg "bends outward" at times
Yorkshire Terrier	6	3	successful	
Yorkshire Terrier	7	3	successful	
Shetland Sheepdog	8.8	3	successful	

Table 6. Group C : WS+TTT (17).

Half of the dogs did not seem to be in any pain at the time they were collected, one or two days after the surgery. Assessment of pain by the dog owners was based on yelping, early toe-touching and appetite, but is undoubtedly a subjective matter. The reported number of pain-free patients was slightly higher in group B, where the dogs only underwent a tibial tuberosity transposition ($\chi^2 = 0.70$ by $P < 0.05$, non significant). Mild pain was reported by the owners in 20 dogs. Two dogs in group A (WS) and another dog in group C (WS+TTT) were reported to be in severe discomfort following the surgery. An overall picture is given in Fig. 12.

An equal number of patients in groups A and B (40%) started to use the operated leg within a few days after the surgery, while a smaller number of dogs in group C (17.6%) did so after the combination-surgery. However, a significant statistical difference between recovery after single and recovery after combination surgery could not be demonstrated ($\chi^2 = 2.94$ by $P < 0.05$). By 2 weeks after the surgery, 70% of all dogs equally divided over the groups, were bearing some weight on the limb. Three dogs that underwent a recession wedge sulcoplasty (13%) and another three that had both surgical procedures combined (17.6%) continued carrying the leg for more than 3 weeks (Fig. 13). The expression of pain the first days after the surgery did not seem to interfere with the early post-operative use of the leg, since 6 of the patients with pain started to toe-touch within the first week, as opposed to 10 of the dogs without pain ($\chi^2 = 1.57$ by $P < 0.05$).

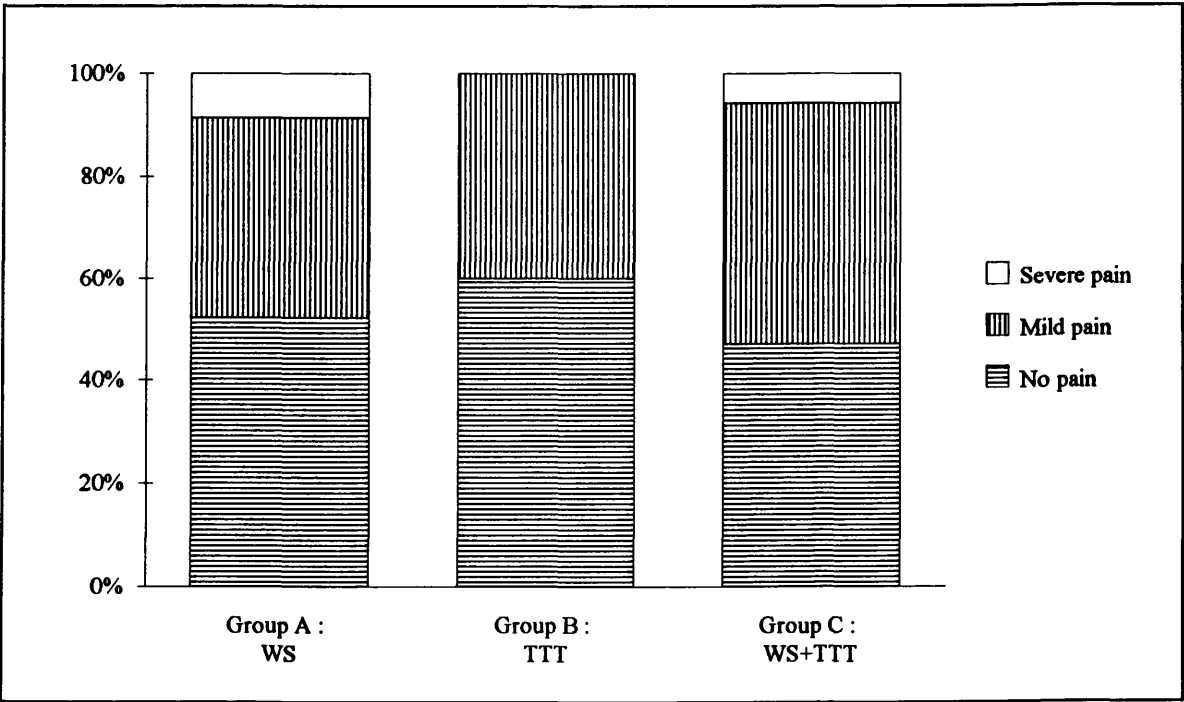


Figure 12. Pain following surgery.

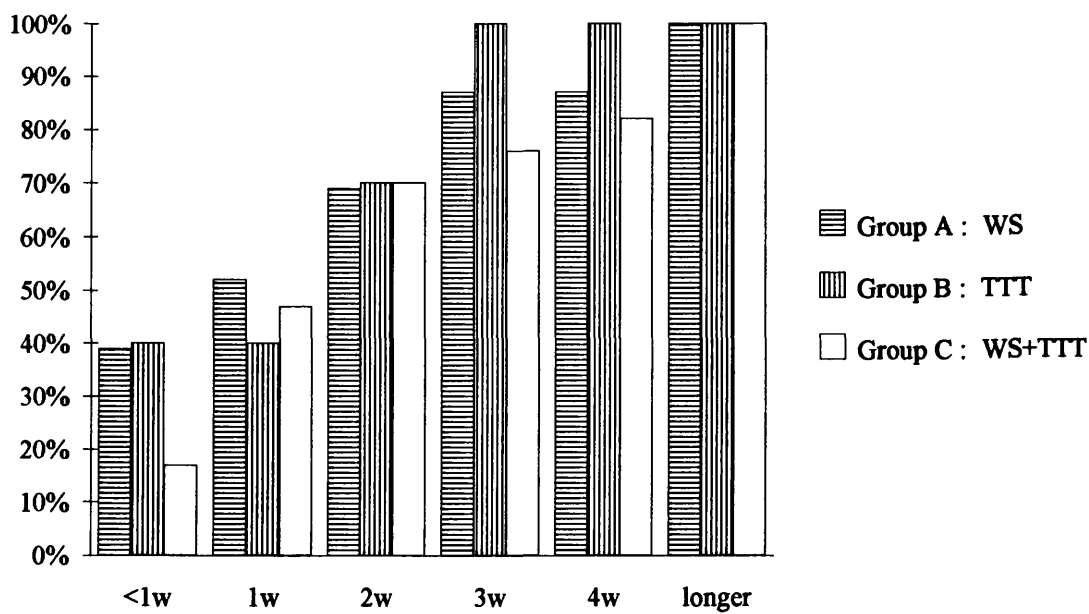
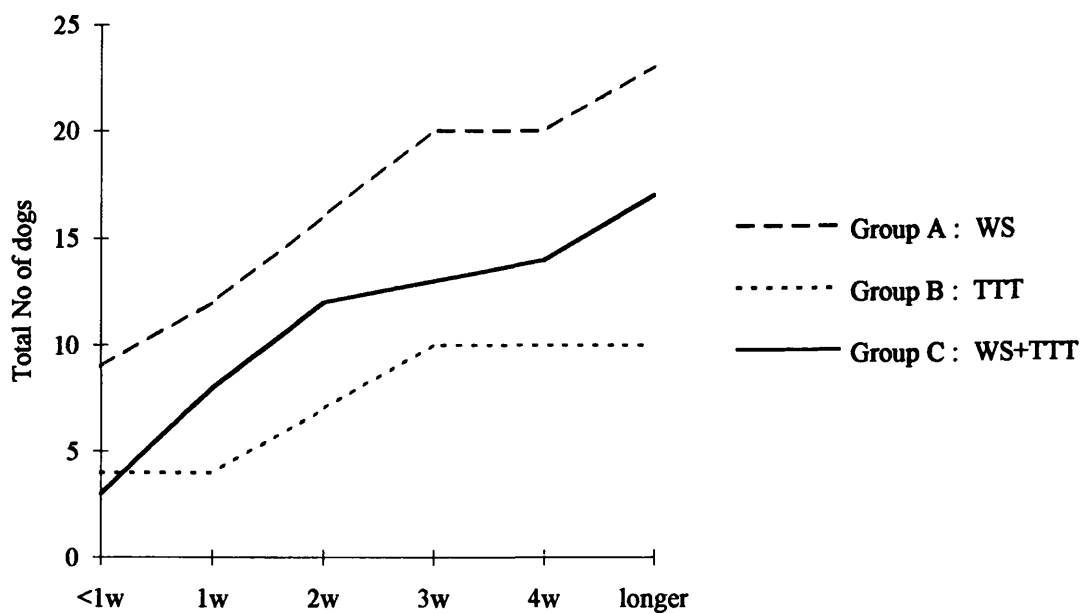


Figure 13. Cumulative number of dogs starting to use the operated leg in relation to the time following surgery.

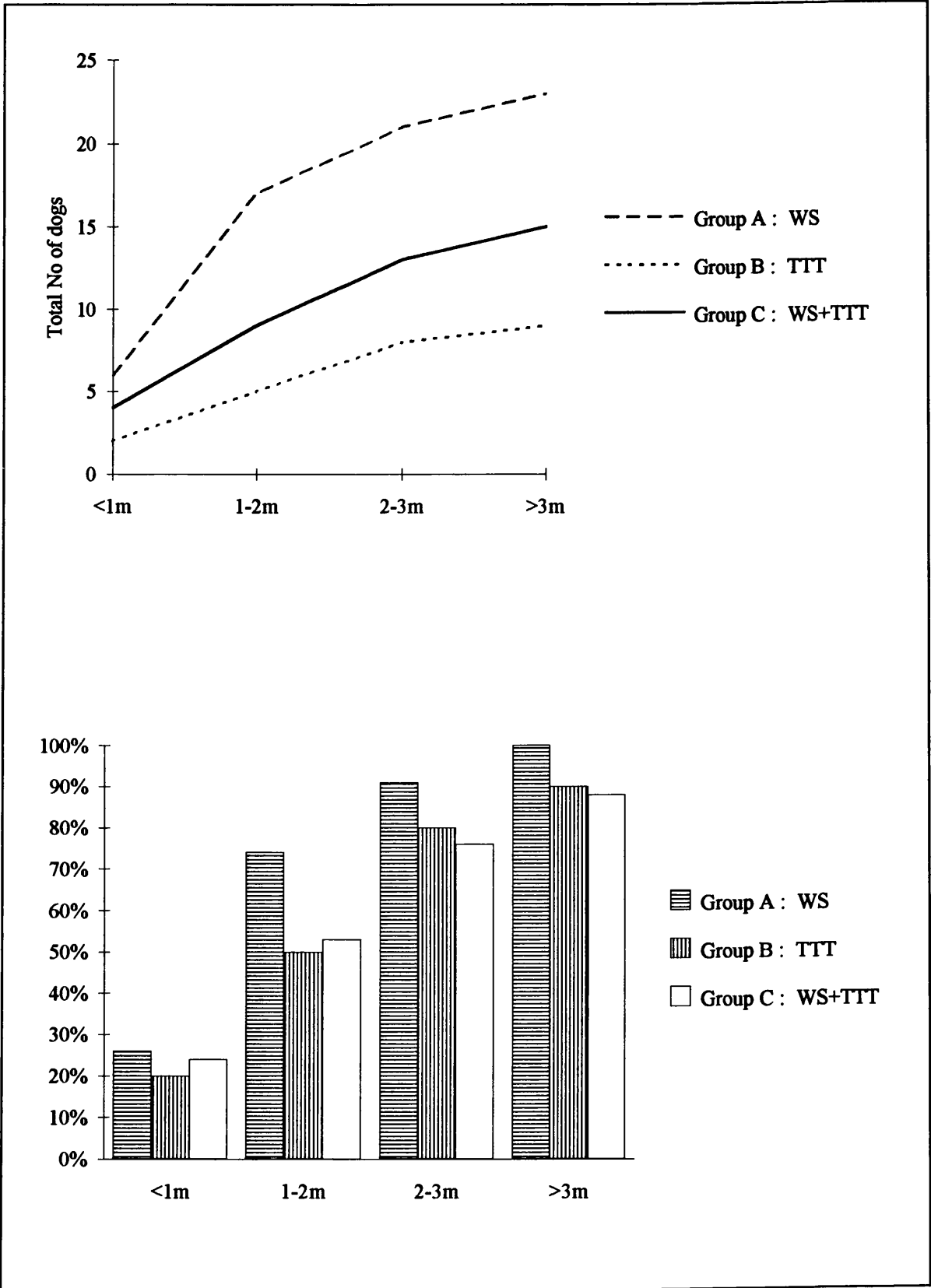


Figure 14. Cumulative number of sound dogs related to the post-operative interval.

Full use of the leg was achieved within the first month in about a quarter of the patients. Half of the dogs belonging to group A fully recovered from the surgery in 1 to 2 months. For groups B and C alike, the number which responded that early was smaller (30%), but the differences were not significant ($\chi^2 = 1.74$ by $P < 0.05$). The recovery intervals of the different groups of patients are shown in Fig. 14.

An overall successful outcome due to surgical intervention was claimed by the pet owners in 96% of the cases. Except for 4 dogs, all remaining dogs gradually recovered until they finally became sound (Table 3, 4, 5 and Fig. 15).

Stiffness was reported by 5 owners of sound dogs in group A, but was never accompanied by pain. In one of these patients, the condition was only perceived after the dog had been taken out for a hill climb. The animal remained completely sound after any other type of exercise. In the other 4 dogs, abnormalities were only seen when they were sitting up. While one dog held its affected leg obviously rotated inwards, the others always held theirs in a straightened position beside their bodies. This did not bother any of them.

One dog of group C sometimes walked with its leg "bending outward" at the hock, but never indicated any discomfort. Another owner reported that his dog (group B) still occasionally hopped while running, otherwise, he moved very quickly, and never seemed to be in any pain. Two other patients (group B and group C) only started limping after excessive exercise. After a short rest, both regained a sound gait without the aid of drugs.

From the 4 dogs (8%) that did not become sound again after the operation, the first one had undergone only a transposition of the tibial tuberosity. The owner recorded a slight improvement in the use of the limb in comparison with the situation prior to surgery. The condition was no longer painful. Yet, some degree of muscle loss could be observed over the hind leg. At the time of the surgery, considerable damage to the articular cartilage of the femoral trochlea had been appreciated. The dog had been operated on by the referring veterinary surgeon a few weeks earlier. Information about the applied procedures was uncertain. It is quite likely, however, that he performed a trochleoplasty which would have accounted for the irregular cartilage surface. The second unsuccessful surgery was a combination of both a tibial tuberosity transposition and a recession wedge sulcoplasty. The patient had not responded to the treatment at all. He was found to be even worse after the surgical interference. The animal had a very stiff gait and quite often carried its leg. Only a small area of eburnation had been detected on the distal portion of the patella at the time of the arthrotomy. The 2 remaining dogs also had had double

surgery. Both owners noticed a vast improvement in the quality of life of their pets, although at the time of writing they are not yet 100% normal. In one, the leg is still constantly rotating inwards when the dog walks. The leg will be only occasionally lifted during normal exercise. The other patient was operated on 6 months ago, and has been kept on painkillers ever since, which allows him to use the leg in a normal way.

Apart from the 2 operations that had to be revised, no specific complications of either surgical procedure were seen.

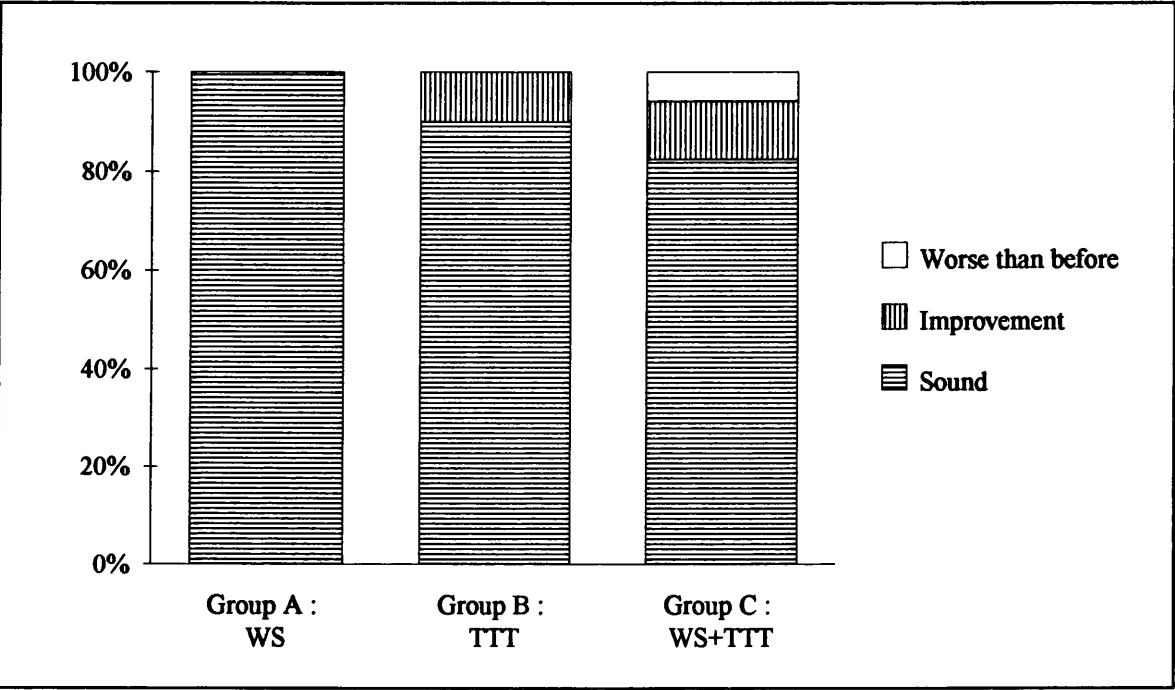


Figure 15. Improvement after surgical interference.

2.3. Discussion

Luxation of the patella is one of the most common causes of lameness in the pelvic limb in the dog, medial displacement being far more common than lateral. In all our patients, the dislocation was to the medial side.

Since not all of the case reports mentioned whether or not the contralateral patella was unstable, the true incidence of bilateral patellar instability could not be determined in the selected group. Incidence of bilateral involvement in veterinary literature varies from 20% to 50% and more (Kodituwakku 1962; Denny and Minter 1973; Rudy 1974; Schröder and Schirmacher 1980; Hutter *et al.* 1983; Horne and Turner 1984; Fritz 1989; Brinker *et al.* 1990).

Sixty-four per cent of the patients in this follow-up were the small breed dogs. In many previous series by others, the poodle was over represented (Vierheller 1959; Kodituwakku 1962; DeAngelis and Hohn 1970; Denny and Minter 1973; Schröder and Schirmacher 1980; Hutter *et al.* 1983; Fritz 1989). Only two of our dogs belonged to this particular breed, while thirteen were Cavalier King Charles spaniels. The breed presentation, however, is likely to vary with a certain breed's popularity, and therefore does not always give an accurate idea about the true incidence.

Both sexes were equally represented. Only a few people in the veterinary world (Priester 1972; Kuwabara *et al.* 1980; Hulse 1981b) believe there is a greater risk of congenital patellar luxation in female dogs.

Thirty-four per cent of the patients were presented with hind limb lameness before they reached the age of one year. The youngest dog in this series had been lame for nearly one month before the owners brought it to the Veterinary Hospital at five months of age. In the oldest patient, the patellar luxation remained clinically silent till the dog reached the age of nine years, at which point it became suddenly lame. There was no history of real trauma. Most of the other dogs that were operated on when they were already 5 years or over, suffered from a more chronic problem of patellar instability. Their lameness had grown gradually worse over time.

The post-operative evaluation was obtained from the dog owners by means of a client questionnaire. Although such information cannot be considered as being perfectly accurate, one can get a valuable notion of long-term parameters of results of surgical treatment. Assessment of limb function is a subjective parameter. Presumably, the dog owners are in the best position to determine whether or not surgery has been clinically successful for their pet.

No significant differences in results between the different groups could be demonstrated in this study. Since the 50 clinical cases were subdivided into 3 different categories, the final number in a single class was rather small. All the statistic significance test χ^2 could tell, therefore, was that the sample sizes were too small to reject the null hypothesis that there is no difference in recovery after the different types of surgery.

Wedge sulcoplasty, tibial tuberosity transposition, or the combination of both were successful in the owners' eyes in the majority of cases. In 96% of the 50 cases reviewed a pleasing beneficial effect of surgery on the limb use was reported. A few of the dogs were sound most of the time, although still occasionally stiff or lame after exercise.

In the literature, the best prognosis is given when the bony correction can be minimised to tibial crest transposition alone (Fritz 1989; Matis and Fritz 1990). Consequently, although wedge sulcoplasty has proved to be superior to the traditional sulcoplasty (Boone *et al.* 1983; Fritz 1989), the procedure should only be employed when tibial tuberosity transposition alone is insufficient to adequately correct or when transposition is not indicated (Fritz 1989). Obviously, it follows that the final outcome is likely to be directly related to the fact that combination-surgery is required only when the degree of skeletal abnormality increases. Whether or not the luxation grade had an influence on the interval of time between surgery and full recovery in the dogs of this study after the different types of surgery could not be accurately assessed since the frequencies in any cell were too small to be statistically interpreted.

Shallowness of the femoral groove is often seen in conjunction with dislocation of the patella (Singleton 1969; Vaughan and Robins 1975). In eighty per cent of our dogs, deepening was carried out, with or without tibial tuberosity transposition. Forty-six per cent of the patellar luxations in our follow-up patients were treated by wedge recession alone. None of these operations was unsuccessful.

Recession wedge sulcoplasty is widely assumed to be the preferred procedure to correct for a shallow trochlea. By this technique the normal hyaline cartilage surface on the trochlear groove is optimally maintained, since it is a form of autogenous osteochondral transplantation. A smooth sliding motion of the patella on the distal femur is guaranteed. A quicker recovery of function was seen after trochlear wedge recession than after the traditional sulcus rasping in a comparative study carried out by Boone *et al.* (1983). Nevertheless, the wedge sulcoplasty can be rather technically demanding to employ in the small and toy breed dogs (Hulse *et*

al. 1986). The alternative, then, is rasping a rectangular section of articular cartilage and underlying subchondral bone, and is certainly a quicker and a much easier procedure by which an inexperienced surgeon may deepen the sulcus of the trochlea. Healing of the articular cartilage after trochlear arthroplasty is similar to the physiological repair of full-thickness cartilaginous injuries. The exposed cancellous bone is first covered by granulation tissue which reorganises itself into more cartilage-like material. However, it differentiates more to a mixture of fibrocartilage and fibrous scar tissue than to real hyaline cartilage (DeAngelis 1971; Rudy 1974; Vaughan and Robins 1975; Wright 1976; Horne 1979; Mankin 1982; Slocum *et al.* 1982; Boone *et al.* 1983; Hulse and Shires 1985; Slocum and Devine 1985; Fritz 1989; Moore and Banks 1989). Resurfacing the abraded trochleoplasty site with an inverted periosteal graft accelerates the production of new cartilage. Even then it is of a more fibrocartilaginous nature than the original articular surface (Hulse *et al.* 1986). The weight-distributing properties of fibrocartilage are far less ideal (Slocum *et al.* 1982; Brinker *et al.* 1990), while the bottom of the trochlea is just the area of maximum compressive forces between the patella and the femur. Although fibrocartilage is smooth, it is thinner than the original cartilage, and is not able to retain synovial fluid in the same way as hyaline cartilage does (Slocum *et al.* 1982). Moreover, this type of cartilaginous substitute appears to undergo localised degeneration and also becomes more fibrous and less cartilaginous with the passage of time (Mankin 1982; Hulse *et al.* 1986).

One case was represented nine months after successful treatment for medial patellar luxation by a single wedge sulcoplasty. A cranial cruciate injury was diagnosed. During the surgery, the femoral groove could be inspected for changes following the recession technique. Only two very fine lines of fibrocartilage were noticeable on the level of the original cuts. On the weight bearing surface normal and healthy hyaline cartilage was still present. No marked increase in degenerative changes in the stifle was observed.

Pronounced arthritic changes tended to occur after deepening the femoral groove with cartilage rasping. After wedge sulcoplasty, less obvious degenerative joint disease was seen and single tibial tuberosity transposition operations showed hardly any progression of the osteoarthritic changes in most of the patients (Fritz 1989; Matis and Fritz 1990).

2.4. Conclusion

In other studies with experimental dogs, wedge recession sulcoplasty has proven to be less traumatic than the traditional trochlear chondroplasty.

Despite our inability to compare results of the different types of surgery statistically, there is a clinical impression that trochlear deepening by wedge recession sulcoplasty does not slow down the rate of recovery after surgery as compared to tibial tuberosity transposition. Dogs that had combined procedures did not seem to take longer to recover and they did not seem to have poorer results than dogs that had either technique in isolation.

From these findings, it appears that wedge recession sulcoplasty can be recommended as a safe, effective technique for deepening a deficient femoral trochlea.

References

- Alexander, J.W. (1985) Luxations in the pelvic limb - Patellar luxations. In : *Leonard's Orthopaedic Surgery of the dog and the cat*. Ed. J.W. Alexander. W.B. Saunders, Philadelphia, 152-157.
- Arkin, A.M. & Katz, J.F. (1956) The effects of pressure on epiphyseal growth - The mechanism of plasticity of growing bone. *Journal of Bone and Joint Surgery* 38-A, 1056-1076.
- Arnoczky, S.P. & Marshall, J.L. (1981) Secondary degenerative joint disease. In : *Pathophysiology in Small Animal Surgery*. Ed. M.J. Bojrab. Lea & Febiger, Philadelphia, 574-575.
- Arnoczky, S.P. & Tarvin, G.B. (1980) Surgery of the stifle - The patella. *Clinical Orthopaedics and Related Research* 2, 200-207.
- Arnoczky, S.P. & Tarvin, G.B. (1983) Patellar surgery. In : *Current Techniques in Small Animal Surgery*. Ed. M.J. Bojrab. Lea & Febiger, Philadelphia, 650-655.
- Arnoczky, S.P. & Tarvin, G.B. (1990) Surgical repair of patellar luxations and fractures. In : *Current Techniques in Small Animal Surgery*. Ed. M.J. Bojrab. Lea & Febiger, Philadelphia, 714-721.
- Arnoczky, S.P., Torzilli, P.A. & Marshall, J.L. (1977) Biomechanical evaluation of anterior cruciate ligament repair in the dog - An analysis of the instant centre of motion. *Journal of the American Animal Hospital Association* 13, 553-558.
- Auer, J.A., Martens, R.J. & Williams, E.H. (1982) Periosteal transection for correction of angular limb deformities in foals. *Journal of the American Veterinary Medical Association* 181, 459-466.
- Bardet, J.F. & Piermattei, D.L. (1983) Long digital extensor and popliteal tendon avulsion associated with lateral patellar luxation in a dog. *Journal of the American Veterinary Medical Association* 183, 465-466.
- Blaney, A.J. (1951) Surgical repair of a bilateral, lateral luxation of the patellae in a dog. *The North American Veterinarian* 32, 101-105.
- Boone, E.G., Hohn, R.B. & Weisbrode, S.E. (1983) Trochlear recession wedge technique for patellar luxation : An experimental study. *Journal of the American Animal Hospital Association* 19, 735-742.

- Brattström, H. (1964) Shape of the intercondylar groove normally and in recurrent dislocation of patella. *Acta Orthopaedica Scandinavica suppl.* 68, 25-39.
- Brinker, W.O. & Keller, W.E. (1962) Rotation of the tibial tubercle for correction of luxation of the patella. *Michigan State University Veterinarian* 22, 92-94.
- Brinker, W.O., Piermattei, D.L. & Flo, G.L. (1990) The stifle - Patellar luxation. In : *Handbook of Small Animal Orthopedics & Fracture Treatment*. Eds. W.O. Brinker, D.L. Piermattei and G.L. Flo. W.B. Saunders, Philadelphia, 377-397.
- Butterworth, S.J. (1993) Congenital medial patellar luxation in the dog. In : *The Veterinary Annual (thirty-third issue)*. Eds. M.-E. Raw and T.J. Parkinson. Blackwell Scientific Publications, Oxford, 193-200.
- Campbell, J.R. & Pond, M.J. (1969) In : Letters to the Editor. *Journal of Small Animal Practice* 10, 319-320.
- Campbell, J.R. & Pond, M.J. (1972) The canine stifle joint - II. Medial luxation of the patella - An assessment of lateral capsular overlap and more radical surgery. *Journal of Small Animal Practice* 13, 11-18.
- Cazieux, A. (1967) La myoplastie des vastes, associée à la transplantation du ligament rotulien dans les luxations congénitales de la rotule de chien. *Revue de Médecine Vétérinaire* 118, 95-100.
- Clark, R.D. & Stainer, J.R. (1983) Hereditary and congenital diseases in purebred dogs. In : *Medical and Genetic Aspects of Purebred Dogs*. Veterinary Medicine Publishing Company, Kansas, 475-552.
- Cofone, M.A., Smith, G.K., Lenehan, T.M. & Newton, C.D. (1992) Unilateral and bilateral stifle arthrodesis in eight dogs. *Veterinary Surgery* 21, 299-303.
- Coughlan, A. (1994) In : Joint surgery (2) - Patellar luxation. In : *Small Animal Orthopaedics*, module 4, 26-27 febr, Glasgow, 69-80.
- Craver, N.S. (1938) Removal of patella and its possibilities. *The North American Veterinarian* 19, 55-57.
- Cross, M.J. & Waldrop, J. (1975) The patella index as a guide to the understanding and diagnosis of patellofemoral instability. *Clinical Orthopaedics and Related Research* 110, 174-176.

DeAngelis, M. (1971) Patellar luxation in dogs. *Veterinary Clinics of North America : Small Animal Practice* 1, 403-415.

DeAngelis, M. & Hohn, R.B. (1970) Evaluation of surgical correction of canine patellar luxation in 142 cases. *Journal of the American Veterinary Medical Association* 156, 587-594.

Denny, H.R. (1985) Luxation of the patella. In : *A Guide to Canine Orthopaedic Surgery*. Ed. H.R. Denny. Blackwell Scientific Publications, Oxford, 254-260.

Denny, H.R. (1993) The canine stifle : Developmental lesions. In : *A Guide to Canine and Feline Orthopaedic Surgery*. Ed. H.R. Denny. Blackwell Scientific Publications, Oxford, 336-343.

Denny, H.R. & Minter, H.M. (1973) The long term results of surgery of canine stifle disorders. *Journal of Small Animal Practice* 14, 695-713.

DePalma, A. & Flynn, J.J. (1958) Joint changes following experimental partial and total patellectomy. *Journal of Bone and Joint Surgery* 40-A, 395-413.

Doverspike, M., Vasseur, P.B., Harb, M.F. & Walls, C.M. (1993) Contralateral cranial cruciate ligament rupture : Incidence in 114 dogs. *Journal of the American Animal Hospital Association* 29, 167-170.

Etor, F.R. (1966) In : Our panel reports - Patellar "looseness". *Modern Veterinary Practice* 47, 54-58.

Evans, H.E. & de Lahunta, A. (1988) The skeletal and muscular systems. *Miller's guide to the dissection of the dog*. Eds. H.E. Evans and A. de Lahunta. W.B. Saunders, Philadelphia, 7-122.

Flecknell, P.A. (1977) Luxation of the patella in cats. *Veterinary Record* 100, 536-537.

Flecknell, P.A. & Gruffydd-Jones, T.J. (1979) Congenital luxation of the patella in the cat. *Feline Practice* 9, 18-20.

Flo, G.F. (1969) Surgical correction of a deficient femoral trochlear groove in dogs with extreme congenital patellar luxations utilizing a cartilage flap and subchondral grooving. *Masters thesis* Michigan State University, East Lansing.

Flo, G.F. & Brinker, W.O. (1970) Fascia lata overlap procedure for surgical correction of recurrent medial luxation of the patella in the dog. *Journal of the American Veterinary Medical Association* 156, 595-599.

Formston, C. (1932) Common joint conditions in canine patients - Discussion. *Veterinary Record* 12, 407-414.

Foster, E.G. (1966) In : Our panel reports - Patellar "looseness". *Modern Veterinary Practice* 47, 54-58.

Fox, T.A. (1975) Dysplasia of the quadriceps mechanism - Hypoplasia of the vastus medialis muscle as related to the hypermobile patella syndrome. *Surgical Clinics of North America* 55, 119-226.

Fritz, R.M. (1989) Zur Luxatio patellae des Hundes - Klinisches und Röntgenologisches Spätergebnis nach Transposition der Tuberositas tibiae und/oder Vertiefung der Trochlea ossis femoris. *Inaugural - Dissertation* Ludwig-Maximilians-Universität, München.

Gibbens, R. (1957) Patellectomy and a variation of Paatsama's operation on the anterior cruciate ligament of a dog. *Journal of the American Veterinary Medical Association* 131, 557-558.

Hammer, D.L. (1979) Surgical treatment of grade IV patellar luxation in the neoambulatory dog. *Journal of the American Veterinary Medical Association* 174, 815-818.

Harrison, J.W. (1975a) III. The pelvic limb - Patellar dislocation. In : *Scientific presentations of the 42nd annual meeting, American Animal Hospital Association, Ohio* 1, 453-456.

Harrison, J.W. (1975b) Patellar dislocation. In : *Current Techniques in Small Animal Surgery*. Ed. M.J. Bojrab. Lea & Febiger, Philadelphia, 479-484.

Hayes, A.G. & Boudrieau, R.J. (1992) In : *Scientific Meeting Abstracts - Distribution of medial versus lateral patellar luxation in the dog : 124 cases (1982-1992)*. *Veterinary Surgery*. Abstracts 27th Annual Meeting American College of Veterinary Surgeons 21, 391-392.

Herron, M.R. (1969) Medial luxation of the canine patella - A simple technic for surgical correction. *Modern Veterinary Practice* 50, 30-33.

- Hobday, F. (1905) Congenital malformation and displacement of the patella joint in the dog. *Veterinary Journal* 60, 256-258.
- Hodgman, S.F.J. (1963) Abnormalities and defects in pedigree dogs - I. An investigation into the existence of abnormalities in pedigree dogs in the British Isles. *Journal of Small Animal Practice* 4, 447-456.
- Hohn, R.B. & Turner, T.M. (1984) Stifle ligaments and meniscal injuries. *American Animal Hospital Association's Annual Meeting Proceedings* 51, 341-344.
- Horne, R.D. (1971) Canine patellar luxation - A review. *Veterinary Medicine & Small Animal Clinician* 66, 211-218.
- Horne, R.D. (1979) Transplantation of the cranial head of the sartorius muscle for correction of medial patellar luxations. *Journal of the American Animal Hospital Association* 15, 561-565.
- House, D. (1961) Surgical repair of medial patellar luxations in dogs. *Canadian Veterinary Journal* 2, 425.
- Hughston, J.C. (1968) Subluxation of the patella. *Journal of Bone and Joint Surgery* 50-A, 1003-1026.
- Hulse, D.A. (1981a) Pathophysiology and management of medial patellar luxation in the dog. *Veterinary Medicine & Small Animal Clinician* 76, 43-51.
- Hulse, D.A. (1981b) Medial patellar luxation in the dog. In : *Pathophysiology in Small Animal Surgery*. Ed. M.J. Bojrab. Lea & Febiger, Philadelphia, 631-637.
- Hulse, D.A., Miller, D., Roberts, D., Shires, P. & Shoji, H. (1986) Resurfacing canine femoral trochleoplasties with free autogenous periosteal grafts. *Veterinary Surgery* 15, 284-288.
- Hulse, D.A. & Shires, P.K. (1985) The stifle joint. In : *Textbook of Small Animal Surgery*. Ed. D.H. Slatter. W.B. Saunders, Philadelphia, 2193-2235.
- Hungerford, D.S. & Barry, M. (1979) Biomechanics of the patellofemoral joint. *Clinical Orthopaedics and Related Research* 144, 9-15.
- Hutter, H., Punzet, G. & Kopf, N. (1983) Patellaluxation nach medial beim Hund - Modification der Fixation der versetzten Tuberositas tibiae. *Wiener Tierärztliches Monatschrift* 70, 269-276.

- Johnson, M.E. (1986) Feline patellar luxation - A retrospective case study. *Journal of the American Animal Hospital Association* 22, 835-838.
- Kaplan, B. (1971) Surgical palliation of bilateral congenital medial patellar luxation in a dog. *Veterinary Medicine & Small Animal Clinician* 66, 571-574.
- Kaufer, H. (1979) Patellar biomechanics. *Clinical Orthopaedics and Related Research* 144, 51-54.
- Kirby, B.M. (1993) Decision-making in cranial cruciate ligament ruptures. *Veterinary Clinics of North America : Small Animal Practice* 23, 797-819.
- Knight, G.C. (1963) Abnormalities and defects in pedigree dogs - III. Tibiofemoral joint deformity and patella luxation. *Journal of Small Animal Practice* 4, 463-464.
- Kodituwakku, G.E. (1962) Luxation of the patella in the dog. *Veterinary Record* 74, 1499-1507.
- Kuwabara, M., Kobayashi, M. & Sato, K. (1980) Studies on patellar luxation in dogs : On analysis of the silhouette of the distal end of the femur. *Japanese Journal of Veterinary Science* 42, 73-81.
- Lacroix, J.V. (1930) Recurrent luxation of the patella in dogs. *The North American Veterinarian* 11, 47-48.
- Leighton, R.L. (1970) A technic for repair of medial patellar luxation in the dog. *Veterinary Medicine & Small Animal Clinician* 65, 365-368.
- Leighton, R.L. (1978) Repair of bilateral medial patellar luxation in a cat. *Feline Practice* 8, 23-26.
- Lesser, A.S. (1985) Arthrodesis. In : *Textbook of Small Animal Surgery*. Ed. D.H. Slatter. W.B. Saunders, Philadelphia, 2263-2276.
- Lieben, N.H. (1986) Intra-articulaire kniestabilisatie met synthetisch materiaal. Een praktijkgerichte stabilisatietechniek. *Tijdschrift voor Diergeneeskunde deel III* 23, 1160-1166.
- Livesey, G.H. (1913) Notes on some problems of everyday dog practice - Luxation of patella. *Veterinary Record* 25, 457.
- Loeffler, K. & Meyer, H. (1961) Erbliche Patellarluxation bei Toy-Spaniels. *Deutsche Tierärztliche Wochenschrift* 21, 619-622.

Mackey, H.W. & McCune, R.F. (1967) Surgical correction of congenital patellar luxation. *Modern Veterinary Practice* 48, 5222-56.

Mankin, H.J. (1982) The response of articular cartilage to mechanical injury. *Journal of Bone and Joint Surgery* 64-A, 460-466.

Matis, U. & Fritz, R.M. (1990) Patellar luxation - Long-term results of surgical treatment. *Veterinary Compendium on Orthopaedics and Traumatology* 3, 39.

Maquet, P. (1979) Mechanics and osteoarthritis of the patellofemoral joint. *Clinical Orthopaedics and Related Research* 144, 70-73.

McCunn, J. (1932) Common joint conditions in canine patients - Discussion. *Veterinary Record* 12, 407-414.

McCurnin, D.M. (1976) Surgery of the canine stifle joint - A brief clinical review. *Veterinary Medicine & Small Animal Clinician* 71, 1217-1222.

McLaughlin, R. (1993) Intra-articular stifle fractures and arthrodesis. *Veterinary Clinics of North America : Small Animal Practice* 23, 877-895.

Miller, A. (1994) Personal communication. Glasgow University Veterinary Hospital, Glasgow.

Montavon, P.M., Hohn, R.B., Olmstead, M.L. & Rudy, R.L. (1985) Inclination and anteversion angles of the femoral head and neck in the dog. *Veterinary Surgery* 14, 277-282.

Moore, J.A. & Banks, W.J. (1989) Repair of full-thickness defects in the femoral trochlea of dogs after trochlear arthroplasty. *American Journal of Veterinary Research* 50, 1406-1413.

Neserke, E.I. (1966) In : Our panel reports - Patellar "looseness". *Modern Veterinary Practice* 47, 54-58.

Newton, C.D. (1985) Genu valgum. In : *Textbook of Small Animal Orthopaedics*. Eds. C.D. Newton and D.M. Nunamaker. J.B. Lippincott Company, Philadelphia, 633-636.

Newton, C.D. & Nunamaker, D.M. (1984) Arthrodesis. In : *Manuel of Internal Fixation in Small Animals*. Eds. W.O. Brinker, R.B Hohn and W.D. Prieur. Springer-Verlag, Berlin, 265-272.

Newton, C.D., Nunamaker, D.M. & Prieur, W.D. (1984) Osteotomy. In : *Manuel of Internal Fixation in Small Animals*. Eds. W.O. Brinker, R.B Hohn and W.D.Prieur. Springer-Verlag, Berlin, 255-264.

Nunamaker, D.M. (1985) Patellar luxation. In : *Textbook of Small Animal Orthopaedics*. Eds. C.D. Newton and D.M. Nunamaker. J.B. Lippincott Company, Philadelphia, 941-947.

O'Brien, T.R. (1971) Development deformities due to arrested epiphyseal growth. *Veterinary Clinics of North America : Small Animal Practice* 1, 441-454.

Olmstead, M.L. (1981) Lateral luxation of the patella. In : *Pathophysiology in Small Animal Surgery*. Ed. M.J. Bojrab. Lea & Febiger, Philadelphia, 638-640.

Outerbridge, R.E. & Dunlop, J.A.Y. (1975) The problem of chondromalacia patellae. *Clinical Orthopaedics and Related Research* 110, 177-196.

Owen, F. & Jones, R. (1990) The Chi Square Test. In : *Statistics*. Eds. F. Owen and R. Jones. Pitman Publishing, London, 386-407

Palumbo, N.E. (1971) A new technic for repair of canine patellar luxation. *Modern Veterinary Practice* 52, 51-53.

Park, R.D. (1979) Radiographic evaluation of the canine stifle joint. *Compendium on Continuing Education* 1, 833-841.

Pearson, P.T. (1967) Reactions of stifle joint tissues to alloy and plastic surgical implants in the dog. *American Journal of Veterinary Research* 28, 592-596.

Pearson, P.T. (1969) The canine stifle joint. *American Animal Hospital Association's Annual Meeting Proceedings* 36, 397-404.

Pearson, P.T. & Ramsey, F.K. (1963) Evaluation of polytetrafluoroethylene implants to correct canine medial patellar luxations. *Journal of the American Veterinary Medical Association* 143, 843-853.

Pederson, N.C. & Pool, R. (1978) Canine joint disease. *Veterinary Clinics of North America : Small Animal Practice* 8, 465-493.

Perot, F. (1984) Luxations de la rotule chez le chien (2° partie). *Point Vétérinaire* 16, 557-573.

Price, D.J. (1955) A method for correcting patellar luxations in the dog. *The North American Veterinarian* 93, 132-133.

Priester, W.A. (1972) Sex, size, and breed as risk factors in canine patellar dislocation. *Journal of the American Veterinary Medical Association* 160, 740-742.

Prior, J.E. (1985) Luxating patellae in Devon Rex cats. *Veterinary Record* 117, 154-155.

Putnam, R.W. (1968) Patellar luxation in the dog. *Masters Thesis* University of Guelph, Ontario, Canada.

Räihä, J.E. (1993) Fixation of transposed tibial tuberosities with biodegradable rods in dogs with luxating patellas. *Journal of the American Animal Hospital Association* 29, 151-156.

Ramadan, R.O. & Vaughan, L.C. (1979) Disturbance in the growth of the tibia and femur in dogs. *Veterinary Record* 104, 433-435.

Reinhard, R.A. (1966) In : Our panel reports - Patellar "looseness". *Modern Veterinary Practice* 47, 54-58.

Remedios, A.M., Basher, A.W.P., Runyon, C.L. & Fries, C.L. (1992) Medial patellar luxation in 16 large dogs - A retrospective study. *Veterinary Surgery* 21, 5-9.

Riser, W.H. (1975) The dog as a model for the study of hip dysplasia. Growth, form, and development of the normal and dysplastic hip joint. *Veterinary Pathology* 12, 264-278.

Riser, W.H., Parkes, L.J., Rhodes, W.H. & Shirer, J.F. (1969) Genu valgum : A stifle deformity of giant dogs. *Journal of the American Veterinary Radiology Society* 10, 28-37.

Robins, G.M. (1990) The canine stifle joint - Diagnosis and treatment of congenital abnormalities. In : *Canine Orthopedics*. Ed. W.G. Whittick. Lea & Febiger, Philadelphia, 707-724.

Rohwer, H.H. (1966) In : Our panel reports - Patellar "looseness". *Modern Veterinary Practice* 47, 54-58.

- Roy, R.G., Wallace, L.J., Johnston, G.R. & Wickstrom, S.L. (1992) A retrospective evaluation of stifle osteoarthritis in dogs with bilateral medial patellar luxation and unilateral surgical repair. *Veterinary Surgery* 21, 475-479.
- Roy, W.E. (1971) Examination of the canine locomotor system. *Veterinary Clinics of North America : Small Animal Practice* 1, 53-70.
- Ruble, R.P. & Hird, D.W. (1993) Congenital abnormalities in immature dogs from pet store : 253 cases (1987-1988). *Journal of the American Veterinary Medical Association* 202, 633-636.
- Rudy, R.L. (1966) Inheritance of patellar anomalies in dogs. *Modern Veterinary Practice* 47, 54.
- Rudy, R.L. (1971) Corrective osteotomy for angular deformities. *Veterinary Clinics of North America : Small Animal Practice* 1, 549-563.
- Rudy, R.L. (1974) Stifle joint. In : *Canine Surgery* Ed. J. Archibald. American Veterinary Publications Inc, California, 1104-1159.
- Schäfer, G., Nolte, I., Reinhard, F. & Rudolph, R. (1982) Die Luxatio patellae congenita des Hundes - I. Experimentelle Untersuchungen - II. Klinik, Ätiologie und Therapieergebnisse. *Kleintierpraxis* 27, 121-130.
- Schmidtke, H.-O. (1981) Rotationsosteotomie zur Behandlung der habituellen Patellaluxation. *Kleintierpraxis* 26, 133-138.
- Schmoker, E.A. (1960) In the clinic - The removal of the patella in the dog. *Modern Veterinary Practice* 41, 48.
- Schröder, E. & Schirrmacher, A. (1980) Die Luxatio patellae congenita des Hundes Möglichkeiten und Ergebnisse der chirurgischen Behandlung. *Monatshefte für Veterinärmedizin* 35, 742-744.
- Shires, P.K. (1990) The musculoskeletal system - Congenital patellar luxation. In : *Veterinary Pediatrics*. Ed. J.D. Hoskins. W.B. Saunders, Philadelphia, 346-347.
- Shuttleworth, A.C. (1935) Dislocation of the patella in the dog. *Veterinary Record* 15, 765-774.
- Singleton, W.B. (1957) The diagnosis and surgical treatment of some abnormal stifle conditions in the dog. *Veterinary Record* 69, 1387-1394.

Singleton, W.B. (1969) The surgical correction of stifle deformities in the dog. *Journal of Small Animal Practice* 10, 59-69.

Slocum, B. & Devine, T. (1985) Trochlear recession for correction of luxating patella in the dog. *Journal of the American Veterinary Medical Association* 186, 365-369.

Slocum, B. & Devine, T. (1993) Trochlear wedge recession for medial patellar luxation - An update. *Veterinary Clinics of North America : Small Animal Practice* 23, 869-875.

Slocum, B., Slocum, D.B., Devine, T. & Boone, E.G. (1982) Wedge recession for treatment of recurrent luxation of the patella. *Clinical Orthopaedics and Related Research* 164, 48-53.

Smith, G.K. & Torg, J.S. (1985) Fibular head transposition for repair of cruciate-deficient stifle in the dog. *Journal of the American Veterinary Medical Association* 187, 375-388.

Sommer, W. (1975) Operative Versorgung der Patella-Luxation durch Einsetzen eines Stahlbügels. *Tierärztliche Umschau* 30, 74-77.

Stader, O. (1944) Reinforcement of the lateral patellar ligament for correction of recurrent patellar luxation in the dog. *The North American Veterinarian* 25, 737-738.

Steurer, P.A., Gradisar, I.A., Hoyt, W.A. & Chu, M. (1979) Patellectomy - A clinical study and biomechanical evaluation. *Clinical Orthopaedics and Related Research* 144, 84-90.

Swaim, S.F. & Miller, L.N. (1969) A surgical technic for correction of lateral patellar luxation in the dog. *Veterinary Medicine & Small Animal Clinician* 64, 512-517.

Tangner, C.H. & Hulse, D.A. (1988) Joint diseases - Congenital disorders. In : *Handbook of Small Animal Practice*. Ed. R.V. Morgan. Churchill Livingstone Inc, New York, 873-875.

Ticer, J.W. (1974) Radiographic interpretation. *Modern Veterinary Practice* 55, 39-43.

Trotter, E.J. (1980) Medial patellar luxation in the dog. *Compendium on Continuing Education* 2, 58-66.

Turner, T.M. (1982) Patellar luxation. *American Animal Hospital Association's Annual Meeting Proceedings* 49, 309-310.

Vasseur, P.B., Pool, R.R., Arnoczky, S.P., Lau, R.E. (1985) Correlative biomechanical and histologic study of the cranial cruciate ligament in dogs. *American Journal of Veterinary Research* 46, 1842-1854

Vaughan, L.C. & Formston, C. (1973) Experimental transplantation of the patella in dogs. *Journal of Small Animal Practice* 14, 267-279.

Vaughan, L.C. & Robins, G.M. (1975) Surgical remodelling of the femoral trochlea An experimental study. *Veterinary Record* 96, 447-450.

Venker-Van Haagen, A.J. (1975) Crista tibiae transplantatie, een chirurgische correctie van de patella luxatie bij de hond. *Tijdschrift voor Diergeneeskunde* 100, 251-258.

Vierheller, R.C. (1959) Surgical correction of patellar ectopia in the dog. *Journal of the American Veterinary Medical Association* 134, 429-433.

Vierheller, R.C. (1967) Grooving the femoral trochlea. *American Animal Hospital Association's Annual Meeting Proceedings* 34, 201.

Willauer, C.C. & Vasseur, P.B. (1987) Clinical results of surgical correction of medial luxation of the patella in dogs. *Veterinary Surgery* 16, 31-36.

Worrell, R.V. (1975) A comparison of patellectomy with prosthetic replacement of the patella. *Clinical Orthopaedics and Related Research* 111, 284-289.

Wright, J.G. (1932) Common joint conditions in canine patients - Discussion. *Veterinary Record* 12, 407-414.

Wright, J.R. (1979) Combined patellar luxation – cruciate repair. *Journal of the American Animal Hospital Association* 15, 85-91.

Zaslow, I.M. (1972) Repair of chronic patellar luxation. *Modern Veterinary Practice* 53, 43-45.

