



University
of Glasgow

<https://theses.gla.ac.uk/>

Theses Digitisation:

<https://www.gla.ac.uk/myglasgow/research/enlighten/theses/digitisation/>

This is a digitised version of the original print thesis.

Copyright and moral rights for this work are retained by the author

A copy can be downloaded for personal non-commercial research or study, without prior permission or charge

This work cannot be reproduced or quoted extensively from without first obtaining permission in writing from the author

The content must not be changed in any way or sold commercially in any format or medium without the formal permission of the author

When referring to this work, full bibliographic details including the author, title, awarding institution and date of the thesis must be given

Enlighten: Theses

<https://theses.gla.ac.uk/>
research-enlighten@glasgow.ac.uk

ALCOHOLIC FATTY LIVER
IN
POST-MORTEM FORENSIC PRACTICE

*A thesis submitted in part fulfilment of
the requirements for admission to the Degree of*

Doctor of Philosophy

by

Dr Abdulridha Hussain Alwan Alkalfa

July, 1989

**Department of Forensic Medicine and Science,
The University of Glasgow**

ProQuest Number: 10999385

All rights reserved

INFORMATION TO ALL USERS

The quality of this reproduction is dependent upon the quality of the copy submitted.

In the unlikely event that the author did not send a complete manuscript and there are missing pages, these will be noted. Also, if material had to be removed, a note will indicate the deletion.



ProQuest 10999385

Published by ProQuest LLC (2018). Copyright of the Dissertation is held by the Author.

All rights reserved.

This work is protected against unauthorized copying under Title 17, United States Code
Microform Edition © ProQuest LLC.

ProQuest LLC.
789 East Eisenhower Parkway
P.O. Box 1346
Ann Arbor, MI 48106 – 1346

ACKNOWLEDGMENTS

Foremost I acknowledge the assistance and guidance of Professor Alan A. Watson, Head of the Department of Forensic Medicine and Science, The University of Glasgow. Particular thanks also go to Dr. John C. Clark and Dr. Marie T. Cassidy, Senior Lecturers in this Department, for their help. I am indebted to Mrs. Kate Clapperton, histology technician, and to Mrs. Elizabeth Doherty for her help in typing this thesis. Thanks go to Professor Hugh Simpson and the Staff of the Pathology Department, Glasgow Royal Infirmary, particularly Mr. Ewan McDonald, Mr. Russell Weir, Mr. J.T. Hendrie and Miss A.E. Walsh, who supported me in the technical side of my work. Last, but not least, I wish to acknowledge gratefully, the computer assistance furnished by Dr. Ian C. McKay from Glasgow Western Infirmary.

To
Everyone who taught me a letter.

C O N T E N T S

	Page
<u>CHAPTER - ONE</u>	
INTRODUCTION	1
<u>CHAPTER - TWO</u>	
FOUNDATION OF THE STUDY	
2.1 ALCOHOL	6
2.1.1 INTRODUCTION	6
2.1.2 ETHANOL METABOLISM	8
2.1.3 ETHANOL TOXICITY	10
2.2 ALCOHOLISM	10
2.3 ALCOHOLIC LIVER DISEASE	12
2.4 ALCOHOLIC FATTY LIVER	13
2.4.1 INTRODUCTION	13
2.4.2 AETIOLOGY	14
2.4.3 INCIDENCE	15
2.4.4 PATHOGENESIS	15
2.5 ALCOHOLIC FATTY LIVER - HISTOPATHOLOGY	21
2.5.1 STEATOSIS	21
2.5.2 CHOLESTASIS	28
2.5.3 FIBROSIS	32
2.5.4 SIDEROSIS	53
2.5.5 COPPER	58
2.6 ALCOHOLIC FATTY LIVER - DIAGNOSIS	62
2.7 SUDDEN FATTY LIVER DEATHS	64
<u>CHAPTER - THREE</u>	
MATERIALS AND METHODS	
3.1 OBJECTIVES	70
3.2 SUBJECTS	73
3.3 MORPHOLOGICAL STUDIES	75
<u>CHAPTER - FOUR</u>	
RESULTS	
4.1 DEMOGRAPHIC CHARACTERISTICS	89
4.1.1 AGE	89
4.1.2 SEX	89
4.1.3 MARITAL STATUS	89
4.1.4 OCCUPATIONAL STATUS	92
4.2 MODE OF DEATH	93
4.3 LOCATION AND CIRCUMSTANCES OF DEATH	93
4.4 POST-MORTEM BLOOD ALCOHOL LEVELS	99

4.5	ALCOHOLIC FATTY LIVER - HISTOPATHOLOGY	99
4.5.1	STEATOSIS	99
4.5.2	PARENCHYMAL INFLAMMATION	120
4.5.3	CHOLESTASIS	120
4.5.4	FIBROSIS	124
4.5.5	SIDEROSIS	139
4.5.6	COPPER: MEGAMITOCHONDRIA: IMMUNOGLOBULIN-A and GLYCOGEN	146
4.6	ALCOHOLIC - SCORE	147
4.7	MECHANISMS OF DEATH IN CASES OF SUDDEN FATTY LIVER DEATHS	158

CHAPTER - FIVE

CONCLUSION

5.1	DISCUSSION	161
5.2	SUMMARY AND CONCLUSIONS	175

REFERENCES

177

ooOoo

LIST OF TABLES

<u>Table</u>	<u>Title</u>	<u>Page</u>
1	Sex Distribution of Alcoholics and Controls	91
2	Death Rates of Alcoholics and Controls in Relation to Marital Status	92
3	Occupational Status of Alcoholics and Controls	93
4.	Causes of Death of Alcoholics and Controls	94
5	Location and Circumstances of Death of Alcoholics and Controls	98
6	Distribution of Alcoholics and Controls as to the Degree of Hepatic Steatosis	101
7	Distribution of Lipogranulomas Among Alcoholics and Controls	118
8	Distribution of Alcoholics and Controls by Types of Cholestasis	121
9	Frequency of Patterns of Fibrosis Among Alcoholics and Controls	125
10	Distribution of the Alcoholics and Controls as to the Grade of Histochemically Demonstrable Hepatic Iron	140
11	Alcoholic Scores for Alcoholics and Controls	150
12	Age, Sex, Grade of Steatosis and Fat Embolism in Sudden Fatty Liver Deaths	160

LIST OF FIGURES

<u>Figure</u>	<u>Title</u>	<u>Page</u>
1	Distribution of Alcoholics and Controls by Age Group	90
2	Mode of Death in Alcoholics and Controls	97
3	Distribution of Post-mortem Blood Alcohol Levels Among Alcoholics and Controls	100
4	Alcoholic Fatty Degeneration	
4a.	Severe macro-vesicular fatty change of the central and midzonal portions of the lobules	104
4b.	Very severe (panlobular) macro-vesicular steatosis	105
4c.	Micro-vesicular fatty degeneration	108
4d.	Alcoholic foamy degeneration	110
4e.	Fatty cysts	113
4f.	Lipogranuloma - Type I	114
4g.	Lipogranuloma - Type II	115
4h.	Lipogranuloma - Type III	116
4i.	Portal steatosis.	117
5	Alcohol-Induced Cholestasis	
5a.	Cholestasis - Type IIA	122
5b.	Cholestasis - Type IIB	122
5c.	Bile plug in secondary canaliculus	123
5d.	Perinodular cholestasis	123
6	Terminal Hepatic Venule Sclerosis	
6a.	THVS-Grade 1	128
6b.	THVS-Grade 2	129
6c.	THVS-Grade 3	130
6d.	THVS-Grade 4	131
7	Centrilobular Pericellular Fibrosis	
7a.	Moderately thick centrilobular pericellular fibrosis.	132
7b.	Thick centrilobular pericellular fibrosis.	132
8	Septal Fibrosis	
8a.	Early septum	133
8b.	Established septa	134
9	Stress Fissures	
9a.	Early stress fissure	135
9b.	Completed stress fissure	136
10	Portal Fibrosis	
10a.	Portal fibrosis - Grade 1	137
10b.	Portal fibrosis - Grade 2	137
10c.	Portal fibrosis - Grade 3	138
10d.	Portal fibrosis - Grade 4	138
11	Hepatic Siderosis in Alcoholics and Controls	142
12	Hepatic Siderosis	
12a.	Hepatic siderosis - Grade 1	143
12b.	Hepatic siderosis - Grade 2	143
12c.	Hepatic siderosis - Grade 3	144
12d.	Pericanalicular haemosiderin granules	144
12e.	Portal tract siderosis	145
12f.	Haemosiderin granules in portal tract connective tissue and macrophages	145
13	Copper accretion in alcoholic cirrhosis	146
14	Distribution of Alcoholic Scores Among Alcoholics and Controls	156

C H A P T E R - O N E

INTRODUCTION

Ethanol is the active ingredient of all major alcoholic beverages. It has been used since the dawn of history for no clear reason, and now it is of little therapeutic value but is a socially abused drug. Its main metabolic pathway is the hepatic alcohol dehydrogenase (ADH) system; and its direct toxicity has been linked to its oxidation and the ensuing metabolic derangements such as those of lipid, protein, carbohydrate, uric acid, lactate, proline and possibly collagen, particularly as a result of increase in NADH/NAD ratio.

The involuntary, excessive, repeated, uncontrolled use of alcohol with the consequent disturbance of the total life pattern of the individual, has been defined as alcoholism which among its characteristics is the organ and tissue damage it inflicts. The well known spectrum of alcoholic liver disease consists mainly of three categories, namely, steatosis, hepatitis and cirrhosis.

The latter is an irreversible condition and is ultimately fatal; whereas alcoholic hepatitis is associated with some mortality. Fatty liver, which means an increase in liver fat detected histologically or by chemical analysis, can be caused by several factors; a well recognized and common cause is alcohol abuse. It is the most common hepatic microscopical abnormality in alcoholics. The direct toxic role played by ethanol in the liver represents a major pathogenic pathway in steatosis. It includes altered redox potential, decreased lipoprotein production and release, mitochondrial changes and enhanced lipid peroxidation. The degree of steatosis is variable and mainly dependent upon the amount of the daily consumption of ethanol; the quantity of protein in the diet and the time of exposure are also important. Its characteristic localization is the centrilobular area and its main morphological forms are the macrovesicular, microvesicular, foamy and mixed types of fatty metamorphosis. In addition to steatosis, other histological features have been looked for in fatty livers submitted for microscopy. These include: cholestasis, various patterns of fibrosis, Siderosis, copper accretion, megamitochondria and immunoglobulin-A deposition,

in addition to parenchymal and portal inflammation.

Several morphological characters have been proposed as markers for the diagnosis of alcoholic liver disease, e.g. terminal hepatic venule sclerosis, giant mitochondria, alcoholic hepatitis and Immunoglobulin-A deposition.

Fatty liver is sometimes the only positive finding in post-mortem examination to which the cause of death will be referred, and the condition has been called 'sudden fatty liver death'. Several mechanisms have been linked to the latter, amongst which hypoglycaemia, hypomagnesaemia and inhibitory false neurotransmitter development; most of these are short of exclusive pathognomic significance. This is because of uncertain post-mortem intervals, and post-mortem putrefaction.

The present study is directed at achieving two goals:

- (1) The identification of reliable markers in the livers of alcoholics to indicate the diagnosis of alcoholism.
- (2) to illuminate a difficult forensic

medicine problem, that is, the sudden fatty liver deaths where this is the only significant necropsy finding.

For these purposes, 200 necropsy cases, who died from natural and other causes, have been randomly selected. They were grouped into 100 chronic alcoholics and 100 normal controls, these being defined by the results of the post-mortem examination and background information based on what was stated in the deceased's police report.

Without knowledge of these data, selected histological hepatic sections were submitted to microscopy, looking for various histological manifestations which have been identified, diagnosed, assessed and correlated according to fixed parameters. Furthermore, to investigate the possible mechanisms of sudden fatty liver deaths, selected brain, lung and kidney samples were examined. Histologically, they were meticulously examined for cerebral, pulmonary and renal fat-embolism, to assess the latter mechanism as a possible explanation for sudden fatty liver death which can be proved after life extinct, at a time when other mechanisms are

possibly obscured by post-mortem change.

C H A P T E R - T W O

FOUNDATION OF THE STUDY

2.1 ALCOHOL

2.1.1 INTRODUCTION

The term 'alcohol', which in Arabic means 'finely divided spirit', was first coined in the Middle Ages (about 800 A.D.) when the process of distillation was introduced. It has been believed that it is the panacea. Whisky (in Gaelic, usquebaugh) the word which has become widely known means 'water of life'. Beer and wines are among the oldest fermented alcoholic beverages reported. Ethyl alcohol (ethanol) is the chief ingredient of all the major alcoholic beverages - beers, wines, liqueurs and distilled spirits. The concentration is usually about 4% by volume in beers, 12-20% in wines, 22-50% in liqueurs and 40-50% in distilled spirits.

Although people have used alcohol since the dawn of history, a clear reason for its use is not known. It has little therapeutic value and is a socially abused drug. There are three routes of administration in man: orally for social or therapeutic purposes; subcutaneously as a local anaesthetic, e.g. in the treatment of the highly painful condition tic douloureux; and intravenously in some cases of threatened premature labour. The

development of chronic alcoholism in man is solely through the oral administration of alcohol.

Ethanol, which is lipid soluble, is rapidly absorbed from the stomach, small intestine and colon, by diffusion across the mucosa. Consequently, many factors modify the rate of its absorption from the stomach such as,

(i) the concentration - the greater the alcohol concentration of the beverage, the more rapidly the alcohol is absorbed.

(ii) the speed of drinking - the more rapidly the beverage is ingested, the higher will be the peak blood alcohol concentration.

(iii) the body weight - the greater the body weight of an individual, the lower will be the blood alcohol concentration resulting from the ingestion of a standard amount.

Absorption from the small intestine is extremely rapid and complete, regardless of the concentration of alcohol ingested and the presence of food.

Over 90% of the absorbed ethanol is metabolized in the body yielding carbon dioxide and water on complete oxidation. The remainder is excreted unchanged in the urine, breath and sweat. The main site of ethanol metabolism is the liver, although some other tissues, such as kidney, muscle, lung, intestine and possibly even brain, may metabolize smaller quantities.

It is impossible to determine the ethanol content of the brain directly and the blood is most often used, since the latter is proportionately representative of cerebral

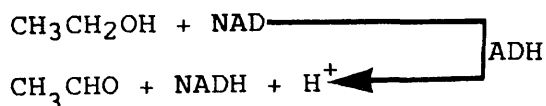
ethanol concentration, as has been demonstrated by various studies, probably because of the copious cerebral blood supply (Erickson, 1979; and Blum, 1984).

2.1.2 ETHANOL METABOLISM

There are three pathways for ethanol oxidation. Each is located in a different subcellular compartment: viz. cytosol, microsomes and mitochondria (Lieber, 1973; and 1984).

(a) Alcohol dehydrogenase system (ADH)

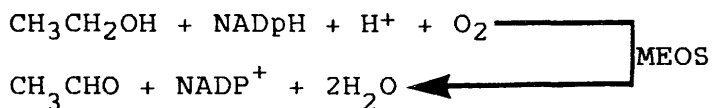
It is part of the cytosol and represents the main pathway for in vivo ethanol metabolism as indicated by the striking slowing of ethanol metabolism by the potent ADH inhibitor, pyroazole. It requires nicotinamide adenine dinucleotide (NAD) as a co-factor which is then reduced to NADH by the hydrogen ions generated upon ethanol oxidation. Consequently, the NADH:NAD ratio will be increased, reflected by immediate concomitant metabolic alterations including inhibition of the citric acid cycle in the mitochondria.



(b) Microsomal Ethanol - Oxidizing System (MEOS)

The microsomes, comprising the smooth endoplasmic reticulum SER, are contributing to ethanol metabolism as


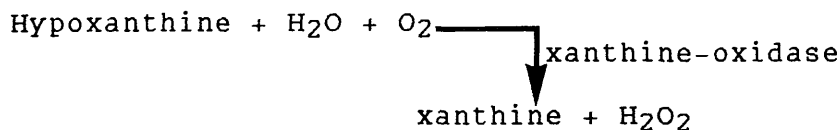
evidenced by the ethanol-induced proliferation of the SER and corroborated by the observation of the inhibition of methanol microsomal oxidation by ethanol. It requires either NADPH or NADPH-generating system.



(c) Catalase System



Catalase which resides primarily in the mitochondria is also capable of oxidizing ethanol. It requires a H_2O_2 -generating system:

(i) In the cytosol in the form of hypoxanthine-xanthine oxidase:



(ii) Microsomal - H_2O_2 -generating system:

(NADPH - Oxidase)



2.1.3 ETHANOL TOXICITY

The direct toxicity of ethanol has been linked to its pathways of oxidation and the ensuing metabolic disturbances (Lieber, 1984). Some toxic effects have been attributed to the generation of NADH via ADH pathway of ethanol oxidation, leading to lipid, protein, carbohydrate, uric acid, lactate, proline and possibly collagen metabolic derangements. Others were shown to result from ethanol-induction of liver microsomes which result in many changes, including activation of hepatotoxic agents and carcinogens, accelerated metabolism of drugs, vitamin A depletion and lysosomal lesions. Ethanol also inter-reacts with membranes, e.g. mitochondrial, causing their alterations.

Acetaldehyde plays a part in ethanol toxicity causing many adverse reactions, amongst which are lipid-peroxidation, protein retention, increase collagen synthesis and possibly stimulation of immunological reactivity.

Some toxic effects have been attributed to the consumption of oxygen in the oxidation process with the consequent possible hypoxic damage.

2.2 ALCOHOLISM

Alcoholism is a progressive illness which may be defined as the excessive and repeated use of alcohol. It

disturbs the total life pattern of the individual so that his work, home and social life are adversely affected to the extent that it latterly engulfs the individual and little else matters but the obtaining of more alcohol. It is, as any addiction, a complex condition constituted by:

(a) psychological dependency, the compulsive use of and craving for alcohol;

(b) physical dependency, including withdrawal, manifested by a series of physiological events when alcohol is discontinued; and,

(c) tolerance, when increasing amounts of alcohol are required to produce a given effect or to maintain a normal function.

These are in addition to tissue damage. Upon detoxification, withdrawal and tolerance are quickly reversed but little can be done to modify the psychological dependence.

Certainly, there is no single cause for alcoholism but it appears established that it is often a familial disorder. Such familial transmission develops from a complicated interaction of:-

(a) Genetic predisposition which requires a trigger of specific environmental factors, namely exposure to alcohol;

(b) Psychological factors - it is believed that

alcoholics are psychologically different, having what is called an alcoholic personality. They are neurotic, maladjusted and unable to relate effectively to others, and are sexually and emotionally immature. Isolated, dependent and unable to withstand frustration or tension, they are poorly integrated. Consequently, it has been suggested that alcoholism is a misguided attempt at self-cure of an unseen inner conflict; and,

(c) Sociocultural factors - for example, the low alcoholism rates among Mormons and Moslems because of religious beliefs (Fox, 1967; Goodwin, 1971; and Blum, 1984).

2.3 ALCOHOLIC LIVER DISEASE

The chronic abuse of alcohol may cause disease of one or more organs, but usually one organ is affected more than the others and may be the cause of death. The organ most obviously affected is the liver, causing 'alcoholic liver disease' in the form of a sequence consisting mainly of three categories that often overlap. These are steatosis with or without fibrosis, hepatitis and cirrhosis, where the lesions cannot be ascribed to any other cause (Edmondson, 1980).

It is still uncertain why one lesion or other develops in a particular patient, but the severity of the lesions can be linked to the amount of alcohol imbibed

(Christoffersen, 1970; and Leibach, 1967).

Alcoholic liver diseases except cirrhosis are potentially reversible on the cessation of alcohol ingestion. Fatty liver is generally a benign disorder being easily reversible upon discontinuation of alcohol abuse; alcoholic hepatitis is associated with a mortality of 10-30%; but cirrhosis is irreversible and usually ultimately fatal (Emanuel, 1974; and Fleming, 1984).

2.4 ALCOHOLIC FATTY LIVER

2.4.1 INTRODUCTION

Fatty liver, fatty metamorphosis of the liver, or hepatic steatosis is an increase in liver fat detected histologically or by chemical analysis.

The normal liver contains 5% fat, wet weight, but in morbid states, the amounts may exceed 40% (Billing, 1953).

Accumulation of fat in the liver is a regular finding in association with any degree of continued alcohol intake and is thus an almost invariable finding in the early stages of alcohol abuse, and is the commonest abnormality in the liver of alcoholics, both after acute or chronic abuse (Edmondson, 1980; and Popper, 1981).

The presence of fat is not essential for the diagnosis of alcoholic liver disease, its absence seems to be mainly determined by alcohol withdrawal before necropsy or biopsy (International Group, 1981), and its presence is

not pathognomonic of alcohol-induced injury (Patrick and McGee, 1980).

Fat accumulation can readily be produced in non-alcoholics by the administration of alcohol (Lieber et al., 1965; and Rubin and Lieber, 1968). It appears within a few days and is quickly lost after alcohol withdrawal. Even in its most severe degree it may disappear in 3-4 weeks (MacSween, 1986).

2.4.2 AETIOLOGY

Alcohol abuse is well recognized by pathologists as one of the main causes of excessive fat accumulation in the liver in this country.

Increased amounts of fat have also been noted in many other conditions including severe anaemia, tuberculosis, various xanthomatoses, chloroform or phosphorus ingestion and chronic congestion (Bockus, 1946).

Similarly, fatty livers are encountered in malnutrition like those associated with gastro-intestinal diseases (Popper and Schaffner, 1957), and particularly in tropical populations, Kwashiorkor. The latter is the classical example of dietary protein deficiency (Ramalingaswami, 1964; and Trowell et al., 1954), in which the caloric intake, in the form of high carbohydrate or high fat diet is adequate in contrast to the low protein, and it affects particularly weaned growing children in whom the demand for protein is especially high (Christoffersen and Poulsen, 1979).

Hepatic steatosis is also observed in endocrine conditions, e.g. diabetes mellitus (Zimmerman et al., 1950), obesity, abetalipoproteinaemia, or in association with drugs such as Steroids and methotrexate (Patrick and McGee, 1980).

2.4.3 INCIDENCE

Leevy et al. (1953), found that more than two thirds of the patients admitted for delirium tremens exhibited a significant increase in liver fat.

The observations of Edmondson and colleagues (1967) have confirmed the findings of Leevy and co-workers (1953) where they observed in a series of 45 chronic alcoholic patients without evidence of cirrhosis, that steatosis was the most common microscopical abnormality (91.1%), and often occurred in the absence of any clinical liver enlargement.

Lelbach (1967) also examined liver biopsies from a series of 320 non-consecutive alcoholics and found in approximately 66% that there was evidence of fatty change without cirrhosis. These results are in accord with what was found latterly by Christoffersen and Nielsen (1972) who showed fatty change in 64% of the liver biopsies, not showing cirrhosis.

2.4.4 PATHOGENESIS

Many mechanisms contribute to the production of

hepatic fatty change in chronic ethanol imbibition,

(a) The Direct Role of Alcohol

Malnutrition can readily develop in the alcoholic for many reasons including the fact that the alcoholic's appetite is reduced as a result of fulfilling the caloric need from the alcoholic beverages, where each gram of ethanol provides 7.1 calories, which means that 20 ounces (586ml) of 43% v/v beverage represent about 1500 calories or half to two-thirds of the normal daily caloric requirement. Furthermore, ethanol, which does not contain protein, vitamins and minerals, interferes with food digestion and absorption, a matter that becomes complicated by the poor economic status of many alcoholics which reduces the consumption of nutrient-rich diets (Lieber, 1977).

In spite of this, evidence has accumulated that alcohol per se, independent of nutritional deficiencies, can be incriminated in the pathogenesis of liver injury, in the form of fat accumulation and significant ultra-structural changes. These findings are substantiated in experimental animals as well as in alcoholic and non-alcoholic volunteers (Lieber, 1973 and 1977) who were given full diets, supplemented with large amounts of protein, minerals and vitamins. In all, ethanol administration resulted in fatty liver which was evident both structurally and by chemical analysis of the lipid content of the liver biopsies which revealed up to a 15-fold rise in the triglyceride concentration.

The role of other factors, namely, protein and lipotropic factors (choline and methionine), which might contribute to the evolution of alcoholic steatosis, have also been investigated. Lieber and Rubin (1968) gave alcoholic and non-alcoholic volunteers, ethanol and adequate high protein, low fat diets plus massive supplementation with choline. This diet comprised 25% of total calories as protein, 25% of calories as fat and the remaining 50% as carbohydrate. When alcohol was given the overall composition of the diet remained the same, except for the isocaloric replacement of carbohydrate-rich foods (sugar, bread, orange juice, cereals, sweet pears, peached and apricots) by ethanol, considered to have a caloric value of 7 calories per gram. Alcohol (95% ethanol) was given in a 15% aqueous solution. The dose of alcohol was divided into six to eight equal daily portions and given in increasing amounts: 24% of total calories for four days, 36% for two days and 46% for two to twelve days. All individuals developed steatosis, demonstrated by both morphological and chemical analysis of the liver biopsies. This was associated with ultrastructural changes characterized by enlarged mitochondria, decreased parallel arrays of rough endoplasmic reticulum and vesiculation of smooth endoplasmic reticulum. This study demonstrates that the decrease in the fat content, the increase in the protein composition of the associated diet and the massive supplementation with choline failed to prevent the fatty liver produced by alcohol in volunteer subjects.

Thus, the direct hepatotoxic effect of ethanol in

humans has been confirmed. It appears that the lack of nutrients in the diet plays at most a secondary role in the development of alcoholic hepatic steatosis. However, the administration of ethanol with a diet deficient in protein and lipotropic factors proved to have more pronounced effects than that of ethanol alone (Lieber et al., 1969). Protein and/or choline deficiency results in impaired lipoprotein secretion, which can be expected to markedly potentiate hepatic lipid accumulation secondary to alcohol (Lieber, 1983).

Ethanol toxicity in the induction of steatosis can be explained in many ways.

(i) Altered redox potential

The increased NADH/NAD ratio appears to play a key role in explaining fat accumulation, where both decreased lipid oxidation and enhanced lipogenesis can be related to ethanol metabolism and the associated increased generation of NADH (Lieber, 1973, 1975 and 1981; Lieber and Davidson, 1962; Lieber and Schmid, 1961; Lieber et al., 1967; MacSween and Burt, 1986; Mezey, 1982; and Rebouca and Isselbacher, 1961).

Decreased lipid oxidation

The hydrogen ions generated upon the oxidation of ethanol can be transferred into the mitochondria. They supplant the citric acid cycle as a source of hydrogen and will be utilized as a fuel for the hepatic mitochondria instead of the normal one derived from the oxidation of the carbon

fragments of fatty acids.

Consequently, lipid oxidation is reduced, which will increase the availability of fatty acids.

Increased lipogenesis

Ethanol has been found to increase hepatic production of triglyceride, which is the main form of lipid that accumulates in the liver cells, as a result of increased fatty acid liberation as the way to dispose of excess hydrogen ions and enhanced microsomal activity which results in more alpha-glycerophosphate (a precursor of triglyceride synthesis).

(ii) Decreased lipoprotein production and release

Ethanol interferes with protein synthesis: a reduction of the rough endoplasmic reticulum has been shown to result from chronic ethanol abuse (Ishii, et al., 1973). Perin and co-workers (1974) have incriminated acetaldehyde to provoke such a block in protein production. Furthermore, longstanding alcohol consumption is also found to impair the hepatocyte secretory function with consequent retention of lipoprotein (Lieber, 1981; MacSween and Burt, 1986; and Mezey, 1982).

(iii) Mitochondrial changes

Hepatic steatosis is further aggravated by the decrease in mitochondrial function and altered structure which eventually culminates in mitochondrial death, probably, the result of the severe metabolic disturbances consequent upon

ethanol oxidation, in addition to the toxic effects of acetaldehyde (Lieber, 1975).

(iv) Enhanced lipid peroxidation

Increased lipid peroxidation has been proposed as a mechanism for ethanol induced fatty liver (Dianzani, 1985; DiLuzio and Hartman, 1967; and Lieber and DeCarli, 1970) where increased microsomal-NADPH-Oxidase activity after ethanol consumption could result in enhanced H_2O_2 production, thus, favouring lipid peroxidation. This could be an initiating event in the accumulation of triglycerides due to the formation of lipo- peroxides from unsaturated fatty acids with the consequent peroxidative degeneration of structural membranous lipids of the cells and subcellular elements, and the ensuing enzymatic and ultrastructural alterations.

(b) The Role of Dietary Fat

The role of dietary fat in the pathogenesis of alcohol-induced liver injury depends on two factors:

(i) The amount of dietary fat

It has been shown in volunteers that for a given alcohol intake much more steatosis developed with diets of normal fat content than in those with a low fat content (Lieber and Spirtz, 1966).

(ii) The chemistry of dietary fat

In addition to the amount, the dietary fatty acid chain-length is also important. Replacement of

dietary triglycerides containing long-chain fatty acids by fat containing medium chain fatty acids has been shown to reduce markedly the capacity of alcohol to produce a fatty liver in rats (Lieber et al., 1967).

The reduction in the steatogenic effect of ethanol upon replacement of dietary long chain fatty acids by medium-chain ones is explained by the tendency of the latter to oxidation rather than esterification (Lieber, 1977).

2.5 ALCOHOLIC FATTY LIVER - HISTOPATHOLOGY

2.5.1 STEATOSIS

(a) Parenchymal Steatosis

(i) Degree

The amount of fat in the liver of alcoholics varies considerably from involvement confined to vacuolation of a few liver cells, to severe involvement of almost the entire lobule with only a few periportal hepatocytes spared in the process.

The degree of fatty degeneration probably depends upon the amount of daily ingested ethanol. It has been shown that steatosis occurs in volunteers whose daily alcohol intake constitutes 50% of the total caloric intake (Lieber, 1977); and the quantity of protein in the diet. The latter can

be very small during episodes of heavy drinking (Edmondson, 1980). The time factor is also important as shown by Edmondson (1980) who confirmed that at least five years of heavy drinking is necessary before clinical liver disease appears in the form of a large palpable liver with or without cholestasis.

(ii) Hepatic Lobule Localization

There is considerable variation in the zonal distribution of fat, and consequently the pattern of distribution is of no great diagnostic value in distinguishing alcoholic steatosis from fatty metamorphosis seen in other disease states (International Group (1981); and MacSween et al., 1986). Fat, however, preferentially accumulates in zone 3 (centrilobular zone) and 2 (mid zone) of the lobule (Popper et al., 1981). In severe cases there is a diffuse, panlobular distribution of fat (Christoffersen and Poulsen, 1979; International Group, 1981; and MacSween et al., 1986).

(iii) Morphological forms

Microvesicular fatty change is the initial form of steatosis. Many very small, 1-3µm in diameter, fat droplets are seen in the cytoplasm of the affected hepatocytes (Christoffersen and Poulsen, 1979).

Foamy type of fatty metamorphosis is sometimes demonstrated in a degenerative process called 'alcoholic foamy degeneration' which represents an

acute alcoholic liver disease without acute-inflammatory reaction. The condition develops in patients with a significant history of chronic alcoholism, usually as the first episode of hepatic decompensation, but without features of encephalopathy or portal hypertension. Clinically there is jaundice in addition to persistent elevation of serum alkaline phosphatase but there is no peripheral blood leucocytosis. Upon abstaining from alcohol, complete rapid recovery may be achieved. It contrasts with other forms of steatosis, structurally and by obvious organelle damage ultrastructurally, in addition to decreased or absent functional activity as shown by enzyme-histochemical staining. It was first described by Uchida and colleagues (1983) and reviewed later by MacSween and Burt (1986). Histologically, the perivenular centrally nucleated hepatocytes were shown to be markedly swollen, 3-6 times the normal size, and laden with innumerable microvacuoles throughout the cytoplasm, confirmed to contain fat by oil red-O and Sudan Black B staining in some cases. Cells with macrovesicles or mixed forms of fatty change were also present. In addition other features have been demonstrated such as intracellular and canalicular cholestasis, focal liver cell necrosis, giant mitochondria, delicate intrasinusoidal creeping collagenosis and terminal hepatic venule sclerosis, but not polymorphnuclear

reaction. Ultrastructurally, foamy hepatocytes show numerous intracytoplasmic non-membrane bound fatty globules; fragmented or absent smooth endoplasmic reticulum; dilated and disrupted rough endoplasmic reticulum; occasional discontinuity and apparent rupture of cell membranes; with marked compression of the space of Disse, by expanded hepatocytes, which frequently contain fine collagen fibrils. Heterogeneous mitochondrial abnormalities comprising atrophy, deposition of amorphous material in the matrix, loss of cristae and giant forms. Furthermore, enzyme chemistry of these cells demonstrates abnormalities with marked decrease or absence of glucose-6-phosphatase; decreased succinic dehydrogenase; decreased alkaline phosphatase along the canalicular but not the sinusoidal membranes; and increased gamma glutamyl-transpeptidase activity along the hepatocyte cell membrane. The condition shares similarities with some other conditions, namely, tetracycline-induced liver injury (Peters, 1967); acute fatty liver of pregnancy (Haemmerlie, 1975; and Rolfes and Ishak, 1985); and Reye's syndrome in which the lesion is particularly severe at the periphery of the hepatic lobules (Bove et al., 1975; and Mowat, 1983). These conditions can be ruled out by the absence of tetracycline intake history and in females gestational history, in addition to the presence of very pale cytoplasm in alcoholic foamy degeneration

accompanied by conspicuous intrasinusoidal collagenosis and striking cholestasis. The pallor of the cytoplasm of the foamy cells is attributed to the deficiency of rough endoplasmic reticulum and mitochondria (Uchida et al., 1983).

Macrovesicular steatosis or what is some times described as 'large droplet' or 'signet-ring' fatty metamorphosis, is the usual microscopical picture and forms upon enlargement and fusion of microvesicular fat globules, which then displace the cytoplasm and nucleus to the periphery of the cell with varying degrees of compression. Even when the steatosis is mainly macrovesicular, hepatocytes with smaller fat droplets are often seen intermixed, which may reflect continued alcohol intake (Christoffersen and Poulsen, 1979); Fleming, 1984; International Group, 1981; MacSween and Burt, 1986; and Popper et al., 1981).

Fat cysts are common and consist of small extracellular lipid filled spaces in the liver lobule, formed apparently by rupture of contiguous lipid filled hepatocytes. They are of little importance apart from reflecting the severity of steatosis (Fleming, 1984).

Lipogranulomas may develop as an inflammatory reaction round fatty cysts, possibly as a result of irritation caused by free fatty acids with secondary repair fibrosis (Christoffersen et al., 1971; Christoffersen and Poulsen, 1979; and International Group, 1981). They appear in forms which are different

in composition, localization, frequency and significance. Christoffersen and co-workers (1971) have classified them into three types:-

Type I Solitary nodule consisting of a central large extracellular fat vacuole, surrounded by histiocytes, sometimes with lymphocytes and eosinophils;

Type II Solitary nodule composed of histiocytes, lymphocytes and sometimes eosinophils and giant-cells. Collagen fibres are few or absent;

Type III Multinodular structure built up of confluent nodules of type I and/or type II, in addition to a certain amount of fibroblasts and collagen fibrils in and between the individual nodules.

They occur focally, singly or in small groups, in parts of the lobule where the liver cells contain fat. Lipogranulomas (type III) are most commonly encountered in relation to the terminal hepatic venules (Christoffersen et al., 1971).

Their frequency was 30-50% of fatty livers (MacSween and Burt, 1986). Christoffersen et al. (1971) considered lipogranulomas type I and II as very frequent in livers with fatty metamorphosis, while lipogranulomas of type III are infrequent.

To ascertain the significance of the different types of lipogranulomas, Christofferson et al.

(1971), in a follow-up study, showed that lipogranulomas type I and II usually disappear without sequelae and therefore, have no significance in the development of parenchymal fibrosis and the progress of fatty liver towards cirrhosis. By contrast lipogranulomas type III showed a tendency to fibrosis with transition from lipogranulomas with fine collagen fibres to ones with dense connective tissue in the same perivenular localization. This leads to the belief that these type III lipogranulomas may give rise to the development of cirrhosis (Christoffersen and Poulsen, 1979). They are found in all forms of prolonged hepatic steatosis and not only in alcoholic fatty metamorphosis, but are more numerous in the latter, probably as a result of heavier fat accumulation (Popper et al., 1981).

(b) Portal Steatosis

Fat droplets with or without granulomatous reaction may be seen in the portal tracts in cases of prolonged fatty metamorphosis. Under light microscopy they appear to be extracellular, but electron microscopy shows them within macrophages. Portal fat may be a cause of portal fibrosis in alcoholic liver disease. It may lead to an increase in portal tract connective tissue in addition to minimal portal chronic inflammatory-cell infiltrate (International Group, 1981; and Popper et al., 1981).

2.5.2 CHOLESTASIS

(a) Definition

Cholestasis has been described as the appearance of visible bile pigments in microscopical sections of liver tissue (Desmet et al., 1970).

(b) Localization

The pigments can be seen in two forms: intracellular accumulation of fine and coarse granules in liver cells, Kupffer cells and macrophages; and extracellular thrombi in bile canaliculi and/or hepatocellular tubules (secondary canaliculi). Intrahepatic, including alcoholic, cholestasis is characteristically of predominantly centrilobular distribution (Biava, 1964; and Elias and Boyer, 1979). This distribution of bile pigment has been explained by Elias et al. (1979) on the basis of lobular gradient, the concept of microcirculatory unit of Rappaport (1958). The blood from the portal vein and hepatic artery radicles bathe in sequence Zone 1 hepatocytes, Zone 2 hepatocytes and Zone 3 hepatocytes; it is then drained by the hepatic vein tributaries. Consequently substances removed from the blood stream by the liver would diminish in concentration from portal to central veins, whereas, the reverse is true with the substances secreted into the blood by the liver.

The hypotheses drawn from this basis were:

- (i) Bile acids cleared normally from the portal blood, predominantly by Zone 1 hepatocytes and that

Zone 3 (pericentral) are exposed to low concentrations of circulatory bile acids. Bile acid secretion into the canaliculus is a major determinant of bile flow, thus, Zone 1 is probably the main contributor to bile-acid-dependent bile flow and that there is much less perfusion of Zone 2 and 3 canaliculi by biliary fluid which is generated by mechanisms progressively independent of bile acids. Such zonal differences would predispose to a primarily centrilobular intracanalicular deposit during cholestasis;

(ii) Since the centrilobular area has the maximal activity of the drug-metabolizing enzymes and it is the major site of bile-acid-independent bile flow; certain drug metabolites may have a major inhibitory effect on the bile acid-independent bile flow.

Lobular gradient for oxygen and ATP would further contribute to centrilobular cholestasis.

(c) Degree

It has been shown that cholestasis is a relatively inconspicuous finding in alcoholic liver disease, apart from severe alcoholic hepatitis and in terminal cirrhosis (Christoffersen and Poulsen, 1979).

(d) Frequency

While cholestasis is common in the advanced decompensated stages of alcoholic liver disease, it has

been shown to be a relatively infrequent finding otherwise (MacSween and Burt, 1986).

(e) Composition

Using histochemical techniques, Desmet and colleagues (1970) showed that,

(i) the fine liver cell granules are constituted mainly of conjugated bilirubin;

(ii) the coarse deposits usually contain unconjugated pigments;

(iii) the extracellular thrombi mostly contain conjugated bilirubin; and,

(iv) the Kupffer cell pigment is predominantly of the unconjugated type.

(f) Aetiology

Cholestasis observed in alcoholics may be due to severe alcoholic hepatitis, alcoholic cirrhosis, acute or chronic alcoholic pancreatitis and mechanical biliary obstruction from gallstones, cholangitis or tumours; it may also be due to superimposed drug-induced or viral hepatitis (Afroudakis and Kaplowitz, 1981; Christoffersen and Nielsen, 1971; Morgan et al., 1978; Popper et al., 1981; and Scott et al., 1977).

Uncommonly, fatty liver without fibrosis but with cholestasis is seen in alcoholic patients presenting with apparent obstructive jaundice. Leevy et al. (1953) reported 20 patients with this type of jaundice, in whom, liver biopsy revealed steatosis without fibrosis. Davidson

and Philips (1954) commented on three jaundiced patients in whom the diagnosis of extrahepatic biliary obstruction was made but the biopsy specimens revealed fatty degeneration without cirrhosis.

Ballard and co-workers (1961), presented 5 patients with apparent obstructive jaundice and their liver biopsies showed mainly large amount of fat and bile stasis. Morgan and colleagues (1978) also reported 3 patients presenting with acute cholestasis and hepatocellular failure without evidence of extrahepatic biliary obstruction, in whom liver biopsy displayed severe fatty change with cholestasis.

The jaundice in these cases may be explained by:

- (i) Hepatocellular dysfunction; although without appreciable hepatic necrosis, it may represent damage to cell organelles such as the endoplasmic reticulum (Morgan et al., 1978), or possibly a direct toxic effect of alcohol or its metabolites;
- (ii) Idiosyncratic cholestatic responses to alcohol (MacSween and Burt, 1986).
- (iii) Compression of intrahepatic biliary radicles by fat cells or fatty cysts and/or increased permeability of ductules for biliary substances with inspissation of bile and only secondary periductular reactive inflammation (Popper and Szanto, 1956 and 1957).

(g) Significance

Cholestasis may be considered a marker of heavy drinking. Edmondson (1980) demonstrated that the patient

who has a fatty liver and is drinking heavily may become jaundiced, and liver biopsy may disclose only cholestasis or cholestasis plus foci of perivenular lytic necrosis. Apart from this, cholestasis is not specific, neither by its type nor its nature, to any particular aetiology (Desmet et al., 1970), and cannot discriminate liver diseases of alcoholic origin from those due to other causes.

(h) Morphology

(i) Colour

The intracellular or intracanalicular clumps show a characteristic light green colour.

(ii) Shape

Hepatocellular bile pigment appears as distinct round or ovoid masses. Sometimes they become confluent, forming irregular blocks. The canalicular thrombi appeared as masses of variable size occluding the bile canaliculi around which the liver cells are often arranged in acinar or pseudoglandular fashion.

2.5.3 FIBROSIS

Hepatic fibrosis is the most common alteration in alcoholic steatosis, hepatitis and cirrhosis. It is the key factor in assessing the chronicity of liver disease (Kent et al., 1976; and Popper et al., 1981).

Collagen normally represents 1-2% of the liver mass, but may show a multifold increase in alcoholic liver

disease (Popper et al., 1981). This increase of connective tissue was previously regarded as a result of collapse of the pre-existing framework, but now it is accepted that it is chiefly due to active fibrogenesis, i.e. the new collagen formation following increase in collagen synthesis (Christoffersen and Poulsen, 1979; Popper and Orr, 1970; Rojkind and Dunn, 1979; and Rojkind and Martinez-Palomo, 1976).

(a) Collagen - Structure

Connective tissue consists of a matrix of glycoproteins, proteoglycans and scleroproteins of which collagen is the most important in the liver (Popper, 1977).

Collagen fibres constitute the main component in the majority of vertebrate connective tissue (Miller and Matukas, 1974), indeed the most abundant protein in the body (Risteli and Kivirikko, 1974). It is an heterogeneous class of extracellular protein characterized by an amino-acid composition, about 30% glycine, 20% proline with hydroxyproline, and a variable content of hydroxylysine (Rojkind and Dunn, 1979).

(b) Collagen - Types

As many as fifteen different types of collagen are now recognized and more may exist. These collagens differ in their amino-acid content, primary sequence and immunological reactivity (Gay and Miller, 1978; Kent et al., 1976; Miller and Matukas, 1974; Popper, 1977; Popper and Martin, 1982; and Wolman, 1975). The interstitial

hepatic collagens include:

(i) Collagen - type I ($[\alpha 1(I)]_2\alpha_2$)

It is characteristic of skin, bone and tendon; it is also found in the liver, in the portal tracts, around hepatic veins and sparsely in the normal hepatic parenchyma. It can be demonstrated as thick, well-formed collagen bundles by connective tissue stains such as Martius Scarlet Blue (MSB) and Masson's Trichrome.

(ii) Collagen - type II ($[\alpha 1(II)]_3$)

Does not occur in normal or fibrotic liver, but it is characteristic of hyaline cartilage.

(iii) Collagen - type III ($[\alpha 1(III)]_3$)
(Reticulin)

It is characteristic of embryonal tissue and blood vessels; it corresponds to the hepatic reticulum in the lobular parenchyma, central and portal canals and can be demonstrated by silver impregnation.

(iv) Collagen - type IV ($[\alpha 1(IV)]_3$)

This represents basement membranes within vessels in the portal and central canals, bile ducts and ductules. It cannot be demonstrated by conventional light microscopy, but can be visualized by electron microscopy.

Following hepatic injury, the initial fibres formed have the characteristics of type III collagen (reticulin) as demonstrated by Rojkin and Martinez-Palomo (1976),

using immuno-fluorescence and confirmed by chemical analysis. This has been corroborated by the work of Kent and his colleagues (1976) using integrated light and electron microscopy, and immunofluorescent analysis, of hepatic injury in rats receiving carbon tetrachloride. They revealed an accumulation of type III collagen in centrilobular areas and in the septa which was subsequently followed by the deposition of type I collagen in the latter. This is the same sequence of collagen deposition which occurs after the implantation of catgut in a rat liver.

(c) Collagen - Biosynthesis

(i) Fibrogenesis

Collagen synthesis occurs in a series of sequential steps consisting of assembly of a proline-rich and lysine-rich polypeptide precursor of collagen (procollagen alpha-chains), enzymatic hydroxylation of some of the prolyl and lysyl residues and glycosylation of some of the hydroxylysyl residues (Fuller et al., 1976). The activity of prolyl hydroxylase is increased in alcoholic liver disease accompanied by a parallel increase in the rate of collagen biosynthesis, and, thus, can be used as a marker of active collagen formation (Fleming and McGee, 1984). The largest increase is found in lysyl hydroxylase activity and to a lesser extent the activities of collagen glycosyltransferase. Thus for increased collagen

synthesis a smaller increase is required in the glycosyltransferase activities than in the hydroxylase activities (Risteli and Kivirikko, 1974).

The formation of collagen fibres most often takes place in relation to inactive surfaces which seem to form templates for the fibre formation. Examples of these are basement membranes of capillaries and bile ducts, the sinusoidal basement membrane around damaged liver cells, and macrophages containing phagocytosed material (Christoffersen and Poulsen, 1979).

(ii) Fibrogenic Cells

Several cell-types in culture are able to synthesize the polypeptide chains of collagen and have been found to contain prolylhydroxylase (Layman et al., 1977; Popper and Piez, 1978; Rojkind and Kershenovich, 1976; and Wu et al., 1978). Immunofluorescent studies with monospecific antibodies against type I and type III collagen have shown that the same cell may produce more than one type of collagen (Gay et al., 1976). Fibroblasts in culture synthesize more type I than type III collagen, the reverse produced by smooth muscle cells (Hayne et al., 1977 and 1978). The fibrogenic cells may include:

Fibroblasts

They are the cells chiefly responsible for fibre formation in the portal tracts.

Myofibroblasts

Studies conducted by Nakano and co-workers (1982) have shown that the myofibroblast is the most common cell round the terminal hepatic venules in the connective tissue or immediately under the endothelial cells, and in the persinusoidal space, and that after chronic excess alcohol consumption there is proliferation of myofibroblasts in association with increased collagen. This occurs even before the thickening of the venules. Myofibroblasts are believed to synthesize the various types of collagen, Types I, III and IV (Bailey et al., 1977; and Gabbiani et al., 1976).

Ito Cells

Ito cells or lipocytes are located in the space of Disse between the sinusoidal endothelium and hepatocytes. These cells contain small fat droplets rich in vitamin A and some rough endoplasmic reticulum, but are free from phagosomes (Bronfenmajet et al., 1966). Morphological investigations have suggested that they are resting precursors of fibroblasts. Transitional forms between fibroblasts and lipocytes have been demonstrated in experimentally increased fibrogenesis, carbon tetrachloride-induced hepatocellular necrosis in rats, and have

been associated with the formation of type III collagen (reticulin). Thus, they have been held responsible for parenchymal fibrogenesis (Christoffersen and Poulsen, 1979; Kent et al., 1976 and 1977; McGee and Patrick, 1972; and Popper, 1977). It has also been shown that after chronic excessive ethanol consumption about half the lipocytes were replaced by cells showing an appearance transitional between fibroblasts and lipocytes. They are surrounded by abundant net-like collagen fibres and can be seen in the perisinusoidal spaces throughout the lobule, sometimes linking up with the perivenular lesions. Furthermore, lipocytes, myofibroblasts and fibroblasts may belong to the same cell family, with possible transformation of It0 cells into myofibroblasts (Lieber, 1984); while Nakano et al. (1982) have demonstrated the absence of typical It0 cells in the perivenular space and the presence of a few It0 cells in the mid-zonal perisinusoidal spaces, and concluded that It0 cells cannot be considered the main cells contributing to the collagen production in the perivenular area as is the case in experimental conditions with more severe hepatocellular damage.

Vascular Myoblasts

Voss et al. (1982) have cultured specimens of liver tissue from patients with chronic active liver diseases, mainly related to alcohol consumption. Two types of connective tissue - producing cells grew out which from their morphology and biosynthetic products they resembled smooth muscle cells and endothelial cells from blood vessel walls. Synthesis of collagen types I and III and basement membrane collagen types IV and V by both cell types was observed by immunofluorescence microscopy. The outgrowth of these cells from fibrotic liver tissue under culture conditions may reflect their capacity to proliferate in vivo in fibrotic liver.

Hepatocytes

Liver cells can produce collagen in vitro (Guzelian et al., 1981; and Tseng et al., 1982) but whether they play a significant fibrogenic role in vivo or not is unknown (Lieber, 1984). Clement et al. (1986) studied alcoholic human liver by light and electron microscopy using the indirect immunoperoxidase technique and concluded that in fibrosis, hepatocytes which normally did not synthesize types III and IV collagen may produce these collagens.

(iii) Fibrogenic Factors

The factors that possibly initiate fibrogenesis may include,

Necro-inflammation

Hepatocellular necrosis and the ensuing inflammation have been considered the most important and potent stimulus for parenchymal fibrosis (Popper, 1977; and Popper et al., 1981). Probable stimuli for fibroplasia are pharmacologically active agents, such as kinins and serotonin derivatives formed or present in liver and inflammatory cells and released from them upon their death and possibly even when they are alive (Popper, 1975).

This explains the major role of alcoholic hepatitis in fibroplasia and its contribution to cirrhosis (Popper et al., 1981); but it is not the sine qua non of such progression (Lieber, 1981 and 1984; and Orrego et al., 1981). It has been shown that in some populations, as in Japan, cirrhosis commonly develops in alcoholics without a preceding stage of florid alcoholic hepatitis (Karasawa et al., 1980; and Takada et al., 1982). Furthermore alcohol-induced hepatic fibrogenesis occurs in the absence of alcoholic hepatitis in one third of alcohol-fed baboons (Popper and Lieber, 1980) and in 20 alcoholics studied by sequential liver biopsies by Nakano and his colleagues (1982). Thus, alcoholic hepatitis may not be a necessary intermediate step in the development of alcoholic cirrhosis

and fibrosis may be initiated by mechanisms other than necro-inflammation;

Mononuclear Inflammation

Alcoholic liver injury is often associated with an increased number of mononuclear leukocytes (Lieber, 1984) and there is increasing evidence that lymphocytes are important in auto-immune tissue-damaging reactions, and a cell-mediated mechanism has been suspected in the development of chronic liver injury (Lieber and Leo, 1986). Lue and colleagues (1981) have shown that mononuclear cells of both controls and alcohol-fed animals were more cytotoxic against alcohol-fed baboons' hepatocytes than against controls, even when the liver exhibits only fatty infiltration, which indicated mononuclear cell cytotoxicity and increased vulnerability of the hepatocytes particularly fatty degenerate liver cells due to the possible alteration of membrane structure consequent upon direct ethanol toxicity. Thus in some vulnerable patients sensitization of lymphocytes against liver antigens e.g. hepatic cell membrane antigen develops; such sensitized lymphocytes could be directly cytotoxic, or more likely through the release of mediators (lymphokines and monokines) stimulating fibrogenesis by possible

amplification of pre-existing liver cell damage of myofibroblasts, lipocytes and transitional cells (Lieber, 1984; Mergenhagen, et al., 1980; Popper, 1977; and Popper et al., 1981);

Ethanol and its Metabolites

It has been shown that there is a lack of a direct ethanol-stimulatory effect on collagen production in cultured liver fibroblasts (Galambos et al., 1977). But the effects of its metabolites on connective tissue metabolism have to be considered.

Holt and co-workers (1984) found that acetaldehyde at concentrations found in the liver during alcohol abuse, stimulate collagen and non-collagen protein production by human fibroblasts.

Savolainen et al. (1984) have substantiated the above findings of Holt et al. (1984) by their demonstration that acetaldehyde and lactate increased collagen synthesis of cultured baboon liver myofibroblasts. Thus, acetaldehyde may play an important role in the alcohol-induced hepatic fibrogenesis;

Ethanol-induced Redox change

Increased lactate-pyruvate ratio and the ensuing hyperlactacidemia are among the metabolic effects of the enhanced NADH/NAD ratio secondary to ethanol oxidation as a

result of decreased utilization and enhanced production of lactate by the liver (Lieber, 1969 and 1975; and Lieber et al., 1962).

Lactate has been shown by Savolainen et al. (1984) to increase collagen synthesis of baboon liver myofibroblasts. This was also corroborated by Green et al. (1964) and Lindy et al. (1971). The elevated lactate concentration is associated with enhanced collagen proline hydroxylase activity, both in vitro (Green and Goldberg, 1964) and in vivo (Lindy et al, 1971). Thus, the possible lactate-induced fibroplasia may operate through increasing proline hydroxylase activity;

Reduced Collagen Degradation

Collagenase activity may decrease with alcohol abuse, contributing to collagen accumulation (Maruyama et al., 1982).

Reduced oxygen tension probably inhibits collagen breakdown thus explaining, at least in part, the favoured collagen deposition in the relatively oxygen-poor Zone 3 of Rappaport's acinus (centrilobular area) (Popper, 1977);

Hepatocellular Enlargement

Orrego et al. (1981) investigated the relationship between the amount of collagen in the space of Disse and the height of the

intrahepatic pressure in a group of alcoholic patients. An increase in intrahepatic pressure has been shown to result from hepatomegaly alone, in the absence of Disse space abnormalities. This increase in liver size is due mainly to an increase in intracellular water and, to a lesser degree of proteins and lipids, with a corresponding increase in cell size and compression of the extracellular space against the liver capsule. A highly significant correlation was found between the degree of collagenization in the Disse space and intrahepatic pressure. They further commented that the sinusoids might behave as tubular structures viz. arteries, bile ducts and ureters which respond to an increase in intraluminal pressure with an enhancement of the synthesis of collagen.

Siderosis

Leevey and TenHove (1967) have reported that in under-nourished alcoholics a considerable increase in hepatic iron is found before the development of cirrhosis. It has also been shown in the beer-drinking Southern African negroes that the prevalence of significant portal fibrosis correlates directly with the greatest concentration of iron in the liver; but subjects with the greatest concentration of iron in the liver tend to be the heaviest

drinkers and not all subjects with severe siderosis showed significant portal fibrosis. Thus, it has been concluded that iron is a low-grade fibrogenic factor which requires to be present in high local concentrations for protracted periods to exert its effects, and that in most cases other factors contribute to the process, the most important of which is alcohol itself. In addition a role may be played by malnutrition and noxious adulterants (Bothwell et al., 1979).

(d) Patterns of Fibrosis

In the liver of an alcoholic increased collagen deposition may show several patterns and various localizations which eventually merge into the final picture of cirrhosis. Such patterns may represent at the same time pathways of the progressive cirrhotic process. They include,

(i) Terminal Hepatic Venule Sclerosis (THVS)

It has also been called perivenular fibrosis or sclerosis, terminal hepatic venule fibrosis or thickening. It represents the early fibrosis or collagen deposition around the central hepatic vein radicles (Lieber, 1984). It is mainly in the form of the hard, type I collagen, initially as plaques and then spreading to form a continuous collar (Popper et al., 1981).

THVS has been illustrated by Van Waes and

Lieber (1977) to be associated with collagen deposition around sinusoids, a finding corroborated later by Nasrallah and colleagues (1980) and Nakano et al. (1982) who pointed out that the deposition of collagen fibrils was not limited to the perivenule area but was also seen in the perisinusoidal spaces associated with a net-like fibrosis, sometimes linking with the perivenule lesions. Furthermore, Lieber (1984) found THVS commonly associated with pericellular as well as perisinusoidal fibrosis a finding which was confirmed later by MacSween and Burt (1986), who demonstrated that perivenule fibrosis has always been accompanied by pericellular fibrosis; it comprises 5% of their alcoholic liver disease biopsies, while alcoholic hepatitis presents in 30%, and in a small number of cases which have been followed-up, there was progression to cirrhosis.

They further showed using electron microscopy that the inflammatory reaction associated with THVS comprises, in approximately equal proportion, lymphocytes or monocytes and myofibroblasts. It is not accompanied by acute inflammation nor by Mallory bodies. The latter were first described by Mallory in 1911 and found to be specific for acute alcoholic liver injury when they are centrilobular in hepatocytes surrounded by neutrophil and mononuclear cellular infiltrate in specimens with intact lobular architecture (Gerber et al., 1973). On light microscopy, they are seen as intracytoplasmic, often

paranuclear, homogeneous, irregularly outlined eosinophilic inclusions with a clumped appearance (Nenci, 1975), which by electron microscopy appear as randomly oriented filaments of 12-20nm diameter (Fleming and McGee, 1984). There is evidence to suggest that these hyaline bodies might act as an antigenic stimulus in the initiation or perpetuation of alcoholic liver damage. Mallory bodies are chemotactic, since cells that contain this material are often surrounded by polymorphonuclear leukocytes (Kanagasundaram et al., 1977a.). Mallory's hyaline antigen and antibody have been detected in the serum of patients with active alcoholic liver disease (Zinnemann, 1975). In addition, liver and kidney from patients with advanced alcoholic hepatitis or active alcoholic cirrhosis have immune complexes which contain anti-Mallory IgG and IgA immunoglobulins; these immune complexes deposited in the liver may induce chemotaxis and cell necrosis (Kanagasundaram et al., 1977b). Lymphocyte cytotoxicity and increased production of migration inhibitory and fibrogenic factors can be induced by adding purified Mallory's hyaline to lymphocytes from patients with alcoholic hepatitis; such immunological hyper-reactivity of lymphocytes to alcoholic hyaline may be of key importance in the pathogenesis and sequelae of alcoholic hepatitis (Zetterman et al., 1976). Thus, Mallory bodies induce lymphocytes from patients with alcoholic

liver disease to elaborate fibrogenic factors which then act directly or indirectly through the activation of macrophages to stimulate collagen synthesis by fibroblasts or perisinusoidal cells (Fleming and McGee, 1984). Mallory bodies, however, have also been demonstrated in other disorders such as Indian childhood cirrhosis, primary biliary cirrhosis, hepatocellular carcinoma, Wilson's disease, diabetes and intestinal by-pass surgery for morbid obesity (French, 1981).

(ii) Centrilobular Pericellular Fibrosis

The collagen fibres are laid down in a perisinusoidal distribution, sometimes they occur as fine strands which enclose normal or ballooned hepatocytes, singly or in groups, producing a lattice-like or 'chicken-wire' appearance encasing the liver cells within its meshes (Fleming et al., 1984; and International Group, 1981). The collagen fibres are initially reticulin, but longer and harder collagen fibres, mainly of type I and elastic fibres subsequently appear, in addition to proven deposition of collagen type IV (Popper and Martin, 1982);

(iii) Septal Fibrosis

Pericellular fibrosis endangers the life of the isolated hepatocytes, the encircling fibres interfere with the hepatocytes nutrition and lead to their atrophy and gradual disappearance.

Consequently, aggregation and later extension

of newly formed collagen fibres around hepatocytes engorged with fat occur, resulting in the primary formation of fibrous bridges or what is called septal fibrosis within the lobular parenchyma (Popper and Elias, 1955; and Popper and Martin, 1982). They are slightly curved or irregularly bent strands, usually hypocellular without prominent inflammatory cell infiltrate, and encompass proliferated bile ductules and narrow vascular spaces derived from sinusoids which are converted into thin-walled venules by collagenous bundles. They often end blindly within the parenchyma but, on occasion, link with septa from centrilobular and/or portal canals dissecting the lobular architecture, resulting finally in cirrhosis (Christoffersen and Poulsen, 1979; Popper, 1977; and Popper et al., 1955 and 1981);

(iv) Stress Fissures

In livers with advanced fatty metamorphosis, two hepatic territories may break apart owing to uneven expansion, producing what are called 'stress fissures', within which liver cells disappear and collagenous fibres are deposited, initially on borders and later fuse to form straight septa.

Different degrees of expansion may occur as a result of irregular fat deposition in different hepatic regions; varying degrees of regeneration or necrosis (Popper and Elias, 1955; and Popper et al., 1955);

(v) Perigranulomatous Fibrosis

All types of lipogranuloma, except type III, have been shown to disappear without any sequelae, while type III lipogranuloma shows a tendency to fibrosis with transition of the fine connective tissue into a denser one, suggesting that this type of lipogranuloma may give rise to parenchymal fibrosis (Christoffersen and Juhl, 1971; Christoffersen and Poulsen, 1971; and Christoffersen et al., 1971). This fibrosis is sometimes considerable, in their usual centrilobular place which joins with other patterns of fibrosis extending from central or portal canals, dissecting the lobular parenchyma leading to frank cirrhosis (Fleming and McGee, 1984);

(vi) Portal Fibrosis

Alcohol does not characteristically produce portal fibrosis. The latter is not a recognized feature of the spectrum of alcoholic liver disease (Morgan et al., 1978), since many alcoholics with steatosis, or even alcoholic hepatitis show normal portal canals (Popper et al., 1981).

Sometimes there is insidious fibrogenesis with the formation of stellate fibrous tissue extensions, in the form of small connective tissue septa, which radiate from the portal fields into the surrounding parenchyma and which may connect with other portal tracts (portal-portal septa) or with centrilobular canals (portal-central septa), frequently associated

with inflammation and bile duct proliferation (Christoffersen and Poulsen, 1979; Morgan et al., 1978; Popper, 1977; and Popper et al., 1981). The occurrence of portal fibrosis in cases of alcoholic steatosis in the absence of alcoholic hepatitis, might be caused by one or more of the following factors:

Portal Fat

Irritation by portal fat droplets has been regarded as a minor cause of portal fibrosis in alcoholics (Popper et al., 1981);

Parenchymal Steatosis

Parenchymal fat per se may be incriminated in the pathogenesis of portal fibrosis, since it is also seen in the Kwashiorkor type of fatty change. In the latter, however, the fibrosis is never pronounced though in long-standing cases, some increase in the stellate form may be seen, and cirrhosis is never developed (Nayak, 1979; and Popper et al., 1981);

Pancreato-Biliary System Disease

Portal fibrosis may be induced by extrahepatic factors. These include subclinical cholangitis; obstruction to the intrapancreatic bile duct as by oedema and swelling of the pancreas, if not by fibrosis during the course of chronic pancreatitis. Diseases of the pancreato-biliary system were found to be the most likely cause of portal

zone fibrosis in the alcoholic patients studied by Morgan and co-workers (1978). The combination of portal fibrosis, bile duct proliferation and a mixed inflammatory infiltrate often suggest the possibility of distal extrahepatic biliary-tree disease, notably chronic pancreatitis, even in the absence of histological cholestasis which was found to be an infrequent and unimpressive histological feature, which suggests that the ducts were not seriously obstructed but presented partial or recurrent obstruction (Afroudakis and Kaplowitz, 1981).

Auto-immune Reaction

As it is seen in various types of chronic liver disease (Popper et al., 1981);

Hepatitis of Independent Aetiology

Morgan and co-workers (1978) found a high incidence (56%) of positive HBsAb., in their alcoholic patients with portal fibrosis. Thus, subclinical viral hepatitis may contribute to portal fibrosis, and the same may be true for subclinical forms of drug-induced hepatic injury as caused by isoniazid (Black et al., 1975; Mitchell et al., 1976).

2.5.4 SIDEROSIS

(a) Normal Iron Stores

Since ionic iron is potentially toxic, it is the role of the iron stores to bind excessive amounts of the metal, thus hepatocytes can store large quantities of iron without significant toxicity developing. A variable quantity of iron is normally deposited in the tissues in two forms: ferritin and haemosiderin, which are closely related, both structurally and functionally.

Ferritin, is the diffuse, soluble fraction and consists of variable amounts of ferric hydroxyphosphate, which is preserved in solution by encasement in a protein shell.

Haemosiderin, is the insoluble fraction and contains variable quantities of carbohydrate, proteins, lipids and iron. The latter is probably a degraded ferritin as is indicated by the rise of haemosiderin proportion relative to ferritin as the tissue iron content increases.

The parenchymal cells of the liver; the cells of the reticulo-endothelial system, e.g. the spleen and bone marrow; and the skeletal muscles, are the major sites of iron storage in the body in which there is marked difference in the predominant type of stored iron. For example, ferritin is present in its largest amount in the liver parenchyma in addition to a good deal in the cells of the reticulo-endothelial system. On the contrary, insignificant amounts of haemosiderin are often observed at high magnification in liver cells and other parenchymal

cells.

The hepatocytes remove excess iron from the circulation and supply stored iron when needed. Hepatocytes are also involved in the recovery of plasma haemoglobin degradation. The iron of the reticulo-endothelial system is derived mainly from phagocytosed erythrocytes (Bissell et al., 1972; Kent and Bahu, 1979; Bothwell et al., 1979; Ritcher, 1959; Scheuer et al., 1982; and Wohelr, 1964).

(b) Iron Overload

For iron stores to be increased above normal limits, additional iron must gain access to the body. There are different ways in which this can happen, e.g. blood transfusion, parenteral iron administration and increased iron absorption; this in turn may result from excessive dietary iron or from the uptake of a larger portion of the normal amounts of ingested iron in the food. In iron overload, the ferritin content of the tissues does not rise in parallel with the haemosiderin, where the relative proportion of the two storage forms alters with a progressively larger haemosiderin fraction as the concentration of storage iron increases. Furthermore, different patterns of iron distribution may occur with the different ways in which iron enters the body in excess. The iron derived from blood transfusion is deposited in the reticulo-endothelial system and parenchymal siderosis is not an early feature, whereas in primary haemochromatosis, due to increased absorption from normal diets, iron is

deposited in hepatocytes and septa and there is little true Kupffer cell siderosis which, if it occurs, is seen restricted to areas of disintegrating iron containing hepatocytes. Both types of siderosis, parenchymal and Kupffer cell, may occur in association with increased absorption due to excessive dietary iron. This is typical of the siderosis in the Bantu (South African negroes) and at least in part the siderosis seen in alcoholics (Bothwell et al., 1979; Kent and Bahu, 1979; and MacDonald, 1964).

There is a relationship between iron overload and excessive alcohol consumption, the prime example of which is encountered in the South African negroes who develop siderosis as a result of drinking home-brewed beer containing large amounts of iron. Iron excess is evidenced in both parenchymal cells, i.e. liver cells and the reticulo-endothelial system Kupffer cells. As the hepatic concentration rises to above normal, the deposits in these cells become denser and portal tract macrophages are involved. With prolonged and massive iron overload, iron may accumulate in other parenchymal tissue, including the pancreas, heart and endocrine organs, which is probably the result of inadequacy of the iron storage system, particularly in cases of cirrhosis where the capacity of the cirrhotic liver to store iron becomes overwhelmed (Bradlow et al., 1961; Bothwell et al., 1979; Isaacson et al., 1961; Kent and Bahu, 1979; and MacDonald et al., 1968). Hepatic siderosis in alcoholics has been linked to several mechanisms, which include the following:

(i) The High Iron Content of some Alcoholic Beverages

Some alcoholic beverages may contain appreciable amounts of iron. The highest amounts have been found in wines, particularly red wines. On this basis of increased iron intake hepatic siderosis is explained in some alcoholics especially red wine abusers (Andre, 1961; Diluzio, 1964; Gilbert and Gernet, 1896; Bothwell et al., 1979; Lereboullet et al., 1956; MacDonald, 1961; and Powell, 1966). This concept has been contradicted by Miralles and colleague (1976) who showed that despite a mean intake of iron from red wines, of approximately 23mg/day and in the absence of overt gastro-intestinal bleeding, there was no correlation between the iron ingested from alcohol and chemically estimated liver iron. A finding which was later confirmed by Jakobovits and co-workers (1979) who found no relationship between the amount of iron in the alcoholic drinks and the degree of hepatic siderosis. Distilled spirits such as whisky and gin were proved to contain very small quantities of iron, and studies conducted on their abusers showed that there was no increase in hepatic iron storage; on the contrary, there may be a diminished iron store as compared with controls (Lundin et al., 1971; Lundvall et al., 1969; and Powell, 1966);

(ii) Increased Iron Absorption

The role of Alcohol

It has been shown in acute experiments that alcohol enhances the absorption of ferric iron (Charlton et al., 1964). The importance of this, however, is doubtful since it appears to do so by stimulating acid secretion in the stomach (Powell, 1966), which is crucial for the solubilization of the non-haem food iron to be available for absorption (Bothwell et al., 1979), and many alcoholics have chronic gastritis.

The Role of Alcohol-induced Diseases

It has been claimed that pancreatic damage, as chronic pancreatitis, might produce excessive iron absorption owing to the possible inhibitory action of the pancreatic enzymes on iron absorption (Davis and Badenoch, 1962; and Bothwell et al., 1979).

Alcoholic liver disease may, by itself, be responsible for increased iron absorption, the latter, was reported in association with steatosis in man (Dittrich, 1965) and in cirrhosis (Delier, 1965).

(iii) Folic Acid Deficiency

Gillman and Gillman, 1947) have suggested that alcoholism or chronic malnutrition may impair hepatic enzyme systems involved in iron utilization and storage.

Herbert et al. (1963) demonstrated that 93% of their alcoholic subjects had serum folate deficiency, and commented that this strongly suggests that folate deficiency is the rule in association with alcoholism. Later, folic acid deficiency has been suggested to result in poor utilization of iron and is probably held responsible for iron deposition in the liver and other organs (MacDonald et al., 1965; and Sullivan and Herbert, 1964).

(iv) Factors Complicating Cirrhosis

Factors complicating cirrhosis such as portocaval shunts may be responsible for siderosis seen in some cirrhotic alcoholics (Kent and Bahu, 1979).

2.5.5 COPPER

Copper is relatively abundant in our food and need never be added to a human diet therapeutically or prophylactically; human copper deficiency occurs very rarely, if at all. On the contrary, it may be found excessive from the widespread use of copper for plumbing, kitchen utensils, beer-brewing kettles and whisky stills, in addition to occupational exposure of many kinds of workers to high concentrations of copper. In spite of that, poisoning by this metal is almost as unusual as copper deficiency (Biondi, 1958; Chatterji and Granguly, 1950; Copper and Brass Bulletin, 1959; Mallory, 1925; and Scheinberg, 1960).

(a) Aetiology

Excess copper was demonstrated both quantitatively and histochemically in livers of patients suffering from various diseases. Such hypercupric conditions may include Wilson's disease, chronic cholestatic conditions such as primary biliary cirrhosis, extrahepatic biliary obstruction, sclerosing cholangitis and biliary atresia. Indian childhood cirrhosis and alcoholic cirrhosis may be added (Beresford et al., 1980; Bush et al., 1955; Goldfischer et al., 1980; Howell, 1959; Hunt et al., 1963; Milman et al., 1986; and Scheinberg and Sternlieb, 1960).

(b) Pathogenesis

Several mechanisms have been proposed to explain the pathogenesis of excess hepatic copper amongst which are:

(i) Cholestasis

The liver is the key organ in the body economy of copper. The major pathway for the excretion of the latter is the biliary system, where up to 80% of the absorbed copper is excreted through bile; small amounts are excreted directly into the bowel and traces voided through the urinary system (Cartwright and Wintrobe, 1964). Thus, despite the abundance of dietary copper in relation to the body need, the concentration of copper remains remarkably stable throughout life, mainly through the biliary excretion of excess

copper (Committee on Medical and Biologic Effects of Environmental Pollutants, 1977; Frommer, 1974; and Scheinberg and Sternlieb, 1960). Consequently interference with this process by a genetic defect or by obstruction of the biliary passages as in primary biliary cirrhosis and longstanding extra-hepatic biliary obstruction, may result in retention of copper by the liver, and increased levels of copper would be expected on quantitative analysis with its possible accumulation within the hepatocytes and its consequent demonstration by histochemical methods (Berresford et al., 1980; Goldfischer et al., 1980; and Hunt et al., 1963). This concept has been contradicted by the last two investigations:

1. Absence of correlation between hepatic copper and cholestasis

Although Vierling et al. (1978) have suggested a direct relationship between liver copper concentration and the degree of intra-hepatocytic cholestasis no such correlation was subsequently found in primary biliary cirrhosis (Epstein et al., 1979); Indian childhood cirrhosis (Popper et al., 1979; and Turner et al., 1979); or in alcoholic liver disease (Berresford et al., 1980).

2. Absence of actual reduction in biliary copper excretion

It has been shown, using radioactive copper,

that patients with Wilson's disease excrete less copper in the faeces than normal individuals; this has been attributed to the likelihood that a smaller proportion of radioactive copper is carried to the liver and not to the impairment of copper excretion. It was found also that patients with alcoholic cirrhosis excreted a normal quantity (Bush et al, 1955; and Scheinberg and Sternlieb, 1960). Thus, other factors may be responsible for the excess tissue copper;

(ii) Increased Gastro-intestinal Copper Absorption

It has been claimed that elevated copper levels are possibly due to increased copper absorption from the gastro-intestinal tract (Hunt et al., 1963). This has been proved by radio-active copper studies which showed that copper absorption is greater in patients with Wilson's disease than in control subjects and such increased absorption has been held primarily responsible for the excessive accumulation of copper in the tissues of patients with the disease (Bush et al., 1955; and Scheinberg and Sternlieb, 1960); but no reference is made to alcoholic liver disease.

(iii) Derangement of Hepato-cellular Function

Hunt and colleagues (1963) have suggested failure of the hepatocytes to excrete copper or some other disturbance of copper metabolism, as possible mechanisms that can result in excessive

deposition of copper in the liver. Such factors may be applicable to alcoholic cirrhosis. They might be linked to ethanol toxicity, nutritional or microcirculatory disturbances.

2.6 ALCOHOLIC LIVER DISEASE - DIAGNOSIS

Many morphological features have been proposed as markers of alcoholic hepatic injury which have been tested by Swerdlow and associates (1981), who concluded that:

- (i) Pericentral (THV) Sclerosis is characteristic but not specific for alcoholic liver disease;
- (ii) Giant mitochondria.

The presence of giant mitochondria under light microscopy is characteristic of alcoholic hepatic injury;

- (iii) Alcoholic hepatitis (the centrilobular lesions consisting of THVS; liver cell ballooning degeneration and/or necrosis; inflammatory cell infiltrate predominantly neutrophilic; Mallory bodies and the almost always present feature: steatosis (MacSween and Burt, 1986)), it is the most morphologically characteristic lesion supporting the diagnosis of alcoholic lesions of the liver;

- (iv) Immunoglobulin (A) deposition

IgA deposition in a continuous pattern in the hepatic sinusoids is a specific marker for alcoholic liver disease.

IgA, is normally produced by plasma cells. Its secretion is possibly enhanced and reaches the liver in excess via the portal circulation, as a result of inflammation of the bowel induced by alcohol (Trevisan et al., 1983). It has been found bound to the membranes of liver cells in alcoholic liver disease, possibly as a result of antigen modification of these membranes by alcohol itself or its metabolites; and thus it may have pathogenic importance as a contributor to alcoholic hepatic injury (Triger et al., 1973). Its hepatic deposition is found to be in two patterns (Swerdlow and Chowdhury, 1984):

- 1 Continuous, which may be linear, outlining the perisinusoidal spaces along the liver plates or pericellular, surrounding liver cells singly or in small groups;
- 2 Discontinuous interrupted pattern.

Swerdlow and co-workers (1982, 1983, 1984) have described immunoglobulin deposition in liver diseases, using immunofluorescence, and suggested that a continuous IgA deposition pattern along the sinusoidal walls is relatively specific for diseases of alcoholic aetiology. This observation is in accordance with what was later found by Golden and colleagues (1986) using the indirect immunoperoxidase technique on formalin-fixed paraffin embedded material.

Thus, although there are some relatively specific

histological features, no single manifestation is pathognomonic.

2.7 SUDDEN FATTY LIVER DEATHS

Deaths in chronic alcoholics secondary to steatosis occur exceptionally (Morgan et al., 1978), from mechanisms, many of which are not established and remain unknown where they are short of confirmation because of uncertain post-mortem intervals and putrefaction (Randall, 1980). These mechanisms may include,

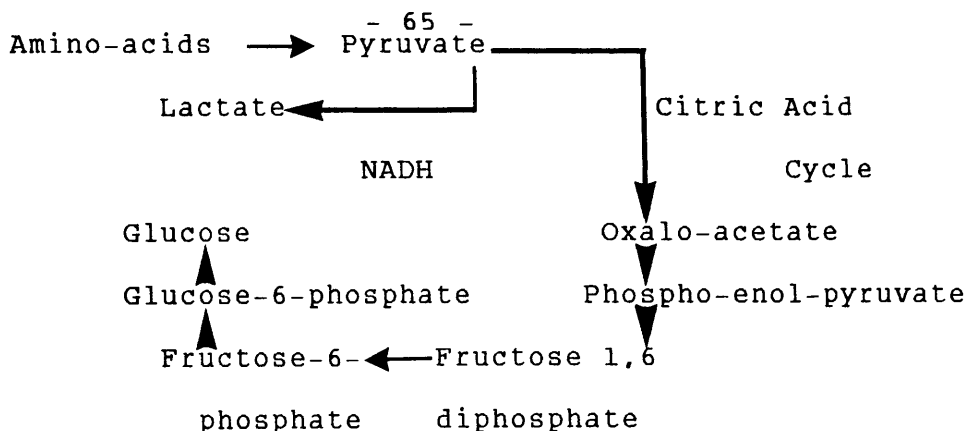
(i) Hypoglycaemia

This is related to the marked reduction in hepatic gluconeogenesis, consequent upon the marked elevation in NADH/NAD ratio within the liver cells during ethanol oxidation (Madison, 1968). Such elevation is attributed to the usually more rapid alcohol metabolism relative to NADH oxidation for the oxidative phosphorylation of ADP to ATP. Thus many H^+ ions are available from ethanol oxidation in the form of NADH which, in turn, inhibit many oxidative reactions particularly the citric acid cycle and force some reactions, from oxidative to reductive pathways as in the process of hepatic gluconeogenesis (Randall, 1980).

During the fasting state, the gluconeogenic precursors of glucose are:

Amino Acids

they take the following pathway to form glucose -



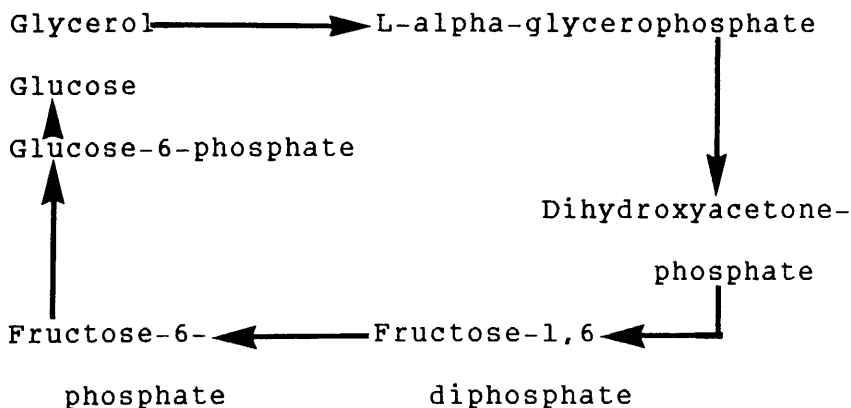
As a result of increased NADH and the consequent inhibition of the citric acid cycle, in addition to the rapid reduction of pyruvate to lactate, the availability of both oxalacetate and pyruvate is reduced;

Lactate

It cannot be considered as a precursor for glucose during ethanol metabolism, since more lactate leaves the liver than is brought to it;

Glycerol

This forms when adipose tissue lipolysis, especially during fasting produces glucose in a special pathway -



The production sequence is probably obstructed at the alpha-glycerophosphate stage, since a decreased conversion of glycerol to glucose and an

accumulation of alpha-glycerophosphate have been demonstrated.

Therefore, the whole process of gluconeogenesis is markedly inhibited. In addition, two other factors may play a part in the production of hypoglycaemia (Neame and Joubert, 1961). These should be considered, namely:

- 1 The period of inadequate food intake preceding alcohol consumption, wherein the majority of the reported cases of alcohol hypoglycaemia, low income and poor diet contributed.

- 2 increased utilization of glycogen during alcohol metabolism.

In contrast to hypoglycaemia, ethanol may produce hyperglycaemia, when the hepatic glycogen stores are adequate, possibly through the stimulation of glycogenolysis via phosphorylase which has been shown to increase upon administration of ethanol (Majchrowicz and Noble, 1979).

(ii) Hypomagnesaemia

Magnesium is one of the most vital elements for many essential enzyme systems, e.g. activation of membrane-bound adenosine triphosphatase. The latter is active in regulating the distribution of sodium and potassium across the cell membrane as well as being active in oxidative phosphorylation with consequent energy production. The clinical manifestations ascribed to magnesium depletion are mostly neurological such as gross tremors, convulsions, stupor and coma. Serious cardiac arrhythmias can also

occur. Cardiac arrhythmias e.g. ventricular fibrillation may be related to hypokalaemia induced by magnesium depletion, since magnesium is essential for activation of adenosine triphosphatase which maintains the concentration of intracellular potassium. Magnesium deficiency can occur in many conditions, namely, congestive heart failure, diuresis with frusemide, digitalis (digoxin) intoxication, diabetic ketoacidosis and malabsorption syndromes (Iseri et al., 1975). Chronic alcoholics often have slightly decreased serum magnesium levels. These may fall sharply with the cessation of chronic alcohol ingestion, causing sudden unexpected death (Konig and Fraser, 1954; and Randall, 1980). The depletion of magnesium is noted in serum, erythrocytes and skeletal muscle in patients during alcohol withdrawal and has been attributed to increased plasma-free fatty acids which may chelate magnesium (Harris, 1979).

(iii) Ethanol-Induced Inhibitory False Neuro- transmitters

It has been proposed that false neuro-transmitters (inhibitory biogenic amines, e.g. tetrahydro-isoquinoline) can be produced by chronic alcoholism, possibly as the action of acetaldehyde, a metabolic product of ethanol oxidation (Cohen, 1976; Cohen and Collins, 1970; and Reis, 1973).

(iv) Alcoholic Cardiomyopathy

Alcohol is apparently associated with congestive cardiomyopathy. Clinically, the advanced stages of the disorder consists of congestive heart failure of

undetermined cause, usually in a man under middle age who has none of the features of the common types of heart disease, but has a history of excessive drinking (Evans, 1959; and Saunders, 1970). At necropsy, the heart is large and flabby and the left ventricle, and occasionally also the right ventricle, is dilated in the absence of significant coronary artery disease. On microscopic examination, there is vacuolar degeneration and interstitial fibrosis with small scars that replace muscle fibres. In some case, recent foci of necrosis and fatty change have been observed (Edmondson, 1980). The earlier manifestations of alcoholic cardiomyopathy may not be obvious to the naked eye or even under light microscopy and require electron microscopic examination of the heart muscle for verification. Ultrastructurally, there is loss of contractile myofibrils, swelling of mitochondria, cystic dilatation of sarcoplasmic reticula and an increased number of liposomes (Saunders, 1970). Electron microscopic investigation, unfortunately, is of limited value in post-mortem practice. Cardiac arrhythmias, which are impossible to determine from post-mortem examination, have been suspected as the cause of death in cases of fatty liver death because of the rapidity of death as well as the lack of specific symptoms before death (Karger et al., 1968). Possibly, the combination of metabolic changes such as acidosis (resulting from the accumulation of beta-hydroxy butyrate, aceto-acetate and lactate in the blood) or elevated free fatty acids together with the early phases of cardiomyopathy may result in fatal ventricular

arrhythmias (Kuller, 1974).

(v) Fat-Embolism

Intrahepatic fat may enter the sinusoids as a result of increased intra-abdominal pressure as with minor abdominal trauma or vomiting. The fat then enters the systemic circulation with subsequent pulmonary, cerebral and other visceral forms of embolism (Hartroft and Ridout, 1951; and Randall, 1980).

However it has been shown by many investigators that although primary fat embolism is common with fatty liver, the condition was occasionally severe enough to account for death and it was concluded that fat embolism, is an occasional cause of sudden death in fatty liver (Cuppage, 1963; Holler et al., 1958; Lynch et al., 1957; Palmovic and McCarroll, 1965; and Randall, 1980).

C H A P T E R T H R E E

M A T E R I A L S A N D M E T H O D S

3.1 O B J E C T I V E S

The present study is aimed at achieving two goals:

(i) Diagnosis of Alcoholism and Alcoholic Liver Disease

The identification of markers to confirm the diagnosis of alcoholism and alcoholic liver disease becomes urgent, particularly now, because of the following:

(a) The nature of alcoholics

It is hardly surprising that the alcoholic frequently resorts to rationalization and to denial of the precise realities of his problems. Even when denial is no longer possible, he may try to misinterpret his symptoms and problems and misconstrue his course of action. He cannot accept as a fact that his alcohol use is out of control or follows a pathologically deviant pattern (Hoff, 1967). Alcoholism is the only real front in his life behind which he hides the whole of his false personality; it is the film, though false, which presents him as a hero, confident and luxurious, on the ashes of his weakness and poverty. Thus, it is the secret of living that he never thinks to

disclose until it is too late. When his drinking problem becomes more sharply focused and his life has failed, he can look forward to nothing but pain and misery as long as he continues to use alcohol;

(b) The size of the problem

There is an explosive increase in alcohol consumption all over the world, especially the West, particularly affecting young people, resulting in a sinister increase in the incidence of alcoholic liver disease (Fleming and McGee, 1984). Heavy alcohol consumption now accounts for at least 15,000 premature deaths per annum in Great Britain (Saunders et al., 1984). In the United States, it is estimated that 205,000 individuals die prematurely each year from a variety of ethanol-induced factors including cirrhosis, cancer, heart disease, suicide, homicide, highway fatalities and other accidents, which bring psychological pain and desolation to the alcoholics, their family and friends (Majchrowicz and Noble, 1979);

(c) The economic and social impact

Today, the economic cost of alcohol-related problems is estimated to run into billions of pounds in the form of industrial and fire losses, traffic accidents, violent crime, losses incurred through diseases exacerbated by alcohol abuse, and

through alcohol-related poor decision-making in industry, education and medicine, in addition to the maintenance of social mechanisms to deal with all these problems (Froede and Gordon, 1980; and Blum, 1984).

Even more devastating are the social costs that involve family life, with the emergence of marital problems and poor child-rearing practice when an alcoholic individual attempts to maintain a family and deal with alcohol abuse at the same time. Poor job performance or absence, divorce, child neglect or abuse, heavy financial debts and other problems may cause the alcoholic to drink more heavily or even desert his family;

(d) The prognosis for alcoholic liver disease

The prognosis for alcoholic liver disease, before irreversible changes, is better than in any other form of chronic liver disease (Swerdlow et al., 1981). That is why early diagnosis of the alcoholic aetiology of liver disease is vital to ensure complete recovery upon withdrawal of alcohol. Thus, a problem of such magnitude, representing one of the major health, social and economic issues facing the world, particularly the industrialized nations, makes it imperative that the medical profession have useful and accurate means of diagnosing alcoholism and direct their efforts to

its treatment. Unfortunately, not enough progress has been made and most of the markers proposed for its diagnosis are still vague, non-specific, and not very sensitive. A picture which becomes depressing in the practice of forensic medicine where criteria for its diagnosis, obligatory and probable, are clinical, and cannot be proved after death, apart from some pathology, particularly that found in the liver, e.g. alcoholic hepatitis. That is why the liver was chosen as a target to identify useful markers for the diagnosis of alcoholism by establishing histological features of the chronic alcoholic aetiology of hepatic fatty degeneration.

(ii) Investigation of Sudden Fatty Liver Deaths

The second object of our study was to explore an important area in forensic medicine, viz. sudden fatty liver deaths, by examining the possibility of establishing the mechanism. These are deaths that have been attributed to fatty metamorphosis of the liver, indeed often the only positive necropsy finding.

3.2 SUBJECTS

The present study concerns 232 necropsy cases of different age groups, who died from a variety of natural and unnatural causes, presenting as sudden and unexpected deaths. They were submitted to post-mortem examination on

instruction of the Procurator-Fiscal according to Scottish Law. These were performed in the City Mortuary, Glasgow, by Regius Professor A.A. Watson, Head of the Department of Forensic Medicine, and Drs. John C. Clark and Marie T. Cassidy, Senior Lecturers in the Department of Forensic Medicine and Science, The University of Glasgow.

The deceased's previous history was obtained from Police Reports concerning demographic characteristics, medical history, medical treatment, alcohol, drug and tobacco use, prodromata and circumstances of death. On the basis of this background information obtained by questioning by the police of the deceaseds' relatives or as revealed in the deceaseds' medical records, 132 cases have been designated by the police as 'chronic alcoholics' having a history of long-standing alcohol abuse. From this pool of 132 'chronic alcoholics', 32 cases were excluded. They showed gross and/or microscopical evidence of other liver disease, apart from fatty change, including cirrhosis. The remaining 100 necropsies represented the study population of chronic alcoholics with fatty livers uncomplicated by alcoholic hepatitis, chronic venous congestion, cirrhosis or other forms of hepatic injury.

As a control group, 100 other cases were selected for comparison. They have no history of alcohol abuse, but some cases were described by the police as social drinkers. Their livers were normal with no evidence, grossly and microscopically, of liver diseases including

those due to alcohol abuse.

For the proper histochemical iron estimation, no subject included in the study had a history of recent significant blood loss, had undergone gastric resection or had received blood transfusion or iron medication.

There was a detailed external and internal post-mortem examination on all cases, including histological investigations, with specimens taken from different organs for microscopical study to confirm the pathologist's diagnosis and find the actual cause of death or any other contributory conditions. Liver, blood and urine samples were taken in 63% of alcoholic and control cases for drug and/or alcohol screening and estimation using gas chromatography, ultraviolet and mass spectrometry.

Fatty liver was cited as the cause of death ('Sudden Fatty-Liver Death') only when no other cause could be established at necropsy, and where it was the sole positive pathological finding.

3.3 MORPHOLOGICAL STUDIES

Specimens, each 3 x 1 x 1cm in size, were obtained at the time of post-mortem examination on the alcoholic and control cases, from areas in the right lobe of the liver, selected 2cm below the capsule and away from obvious hepatic vessels.

They were fixed in 10% neutral buffered formalin for 48 hours approximately and were then embedded in paraffin and sectioned at approximately 5um in thickness.

Staining of sections was completed using the following techniques (Bancroft and Stevens, 1982; and Howell, 1959).

Haematoxylin and Eosin (H and E)

- (1) The sections were brought to water. Stained with Gill's haematoxylin solution for 10 minutes.
- (2) Washed briefly in water and differentiated in acid-alcohol.
- (3) Washed well in water and blueed with Scott's Tap Water Substitute (STWS).
- (4) Stained with the eosin solution for 5 minutes.
- (5) Washed quickly in water and dehydrated in alcohol. Cleared and mounted.

Martius, Scarlet, Blue - For Collagen (M.S.B.)

- (1) The sections stained with celestin blue for 8 minutes; rinsed in water; stained with Gill's iron haematoxylin solution for 5 minutes; washed in water and blueed; and finally rinsed in 95% alcohol.
- (2) Stained with the Martius yellow solution for 5 minutes. Washed briefly in water.
- (3) Stained with the brilliant crystal-scarlet solution for 10 minutes. Washed in water.
- (4) Treated with the phosphotungstic acid solution for

5 minutes. Washed.

- (5) Stained with the soluble blue solution for 5 minutes until the collagen was sufficiently coloured. Washed, dehydrated, cleared and mounted.
- (6) The collagen in the sections was stained blue.

Gordon and Sweet's method - for Reticulin Fibres

- (1) The dewaxed section was brought to water and treated with 1% potassium permanganate solution for 5 minutes. Rinsed in tap water.
- (2) Bleached in 1% oxalic acid solution. Rinsed in tap water.
- (3) Treated with 2.5% iron alum solution for at least 15 minutes. Washed well in distilled water.
- (4) Placed in silver solution for 2 minutes. Rinsed well in distilled water.
- (5) Reduced in 10% aqueous formalin solution for 2 minutes. Rinsed in tap water.
- (6) Treated with 5% sodium thisulphate solution for 3 minutes. Rinsed in tap water.
- (7) Toned in 0.2% gold chloride solution for 3 minutes. Rinsed in tap water.
- (8) Counterstained, dehydrated through alcohols, cleared in xylene and mounted in DPX.
- (9) The reticular fibres were shown black.

Fouchet's method - for Bile Pigments

- (1) The sections (test and controls) were taken to distilled water.

- (2) Stained with filtered Fouchet's reagent (100ml 25% aqueous trichloroacetic acid + 100ml 10% aqueous ferric chloride) for 5 minutes. Rinsed in distilled water.
- (3) Counterstained with vanGieson's solution (100ml saturated aqueous picric acid + 10ml 1% aqueous acid fuchsin), for 2 minutes.
- (5) Rinsed in distilled water, dehydrated through graded alcohols to xylene, cleared and mounted.
- (6) Examined. Bile pigments were stained green and collagen fibres appeared red.

Oil Red O Method - for Lipids

- (1) The frozen sections dried onto slides and rinsed in 60% triethylphosphate.
- (2) Stained for 10 minutes in Oil Red O.
- (3) Dipped quickly in 60% triethylphosphate to differentiate.
- (4) Washed in water and nuclei counterstained with Mayer's haemalum for 1½ minutes.
- (5) Washed in water, blued with STWS, mounted in glycerine jelly and the edges of coverslips sealed with nail varnish.
- (6) Examined. The lipids were stained red.

Osmium tetroxide method - for Lipids

- (1) The formalin fixed specimens, washed well in running water over approximately 4 hours.
- (2) Put in 1% OsO_4 in cupboard overnight at room temperature. Washed well.

- (3) Process on Histokine for paraffin embedding.
- (4) Blocked out, cut 2 sections, one only stained with neutral red for 10 seconds and then mounted in glycerine jelly.
- (5) Lipids were demonstrated black.

Periodic-Acid Schiff Technique (P.A.S.) - For Glycogen.

- (1) The sections taken to distilled water.
- (2) Treated with the periodic acid solution for 5 minutes. Rinsed well in distilled water.
- (3) Treated with Schiff's reagent (1g basic fuchsin + 200ml distilled water) for 15 minutes. Washed in running water for 5 minutes.
- (4) Stained with Gill's iron haematoxylin solution. Differentiated and blued. Dehydrated, cleared and mounted.
- (5) Glycogen was stained magenta.

Diastase - PAS Technique

- (1) The sections (two test and two positive control sections) taken to distilled water.
- (2) One of the test sections and one control section treated with the aqueous diastase solution for 1 hour at 37°C. Washed well in water for 5 minutes.
- (3) All sections treated with periodic acid and Schiff's reagent (1g basic function + 200ml distilled water) and counterstained with haematoxylin.
- (4) Dehydrated, cleared and mounted.
- (5) Glycogen was absent from the digested sections.

Iron Haematoxylin Technique - for Mitochondria

- (1) The sections taken to water.
- (2) Treated with the iron alum solution (5% aqueous ferric ammonium sulphate) for 1 hour in 60°C oven. Washed in water.
- (3) Stained with the Heidenhain's haematoxylin solution (0.5% haematoxylin in 10ml ethanol and 90ml distilled water; allowed to ripen for 6 weeks before use) for 1 hour in 60°C oven.
- (4) Washed in water and differentiated in the iron alum solution at room temperature.
- (5) Washed well in water for several minutes. Dehydrated, cleared and mounted.

Perl's Prussian Blue Reaction - for Ferric Iron

- (1) The sections (test and control) taken to distilled water.
- (2) Filtered on them, a mixture of equal parts of 2% aqueous potassium ferrocyanide and 2% hydrochloric acid. Left for 30 minutes at room temperature.
- (3) Washed for several minutes in water. Stained with 1% aqueous neutral red solution for 20 seconds. Washed in water.
- (4) Dehydrated, differentiated in alcohol, cleared and mounted.
- (5) Haemosiderin (ferric iron salts) showed blue.

Sodium Diethyl Dithio Carbamate (SDDC) - for Copper

- (1) The sections were taken to water then flooded with a freshly prepared and filtered saturated aqueous

solution of 1% sodium diethly dithio-carbamate and left for 90 minutes at room temperature. Rinsed in distilled water.

- (2) Counterstained with haemtoxylin. Rinsed in water and blued with STWS.
- (3) Washed, mounted and the edges of the coverslips sealed with nail varnish.
- (4) Copper stained as distinct yellow-brown granules in positive control cases.

Indirect Immunoperoxidase method - for IgA

- (1) The sections (test and control) were dewaxed and taken to water.
- (2) Treated with a solution of 400ml methanol with 0.8ml hydrochloric acid and 2ml hydrogen peroxide for 30 minutes to inhibit endogenous peroxidase activity. Rinsed in water then in TRIS/saline.
- (3) Trypsinised. A water bath was preheated to 37°C; two staining dishes, each containing 100ml TRIS/buffer were placed in the water bath; 100mg trypsin and 100mg CaCl_2 added to one dish; sections were placed in TRIS/buffer at 37°C for 10 minutes and then transferred to trypsin solution for 10 minutes. Washed in two changes of TRIS/saline for 15 minutes.
- (4) Incubated in normal swine serum, diluted in TRIS/saline for 15 minutes.
- (5) Incubated in primary antiserum for 30 minutes. Washed in TRIS/saline for 5 minutes.

- (6) Incubated in peroxidase - conjugated swine antirabbit IgG for 30 minutes.
- (7) Excess antiserum washed off and then sections were washed in TRIS/saline for 5 minutes.
- (8) Incubated in DAB medium for 1 minute. Washed in running water for 10 minutes; counterstained in Harris' haematoxylin for 30 seconds, dehydrated, cleared and mounted.

Various features were examined and assessed in each section under light microscopy without knowledge of the data in the deceased's police history or whether the case was an alcoholic or control. These include steatosis, lipogranulomas, cholestasis, various patterns of fibrosis (terminal hepatic venule sclerosis, perisinusoidal fibrosis, centrilobular pericellular fibrosis, septal fibrosis, stress fissures and portal fibrosis), Siderosis, copper deposition, giant mitochondria and IgA deposition in addition to inflammation, the presence or absence of alcoholic hepatitis and Mallory bodies were noted.

These features were assessed and then compared according to the following,

(I) Fatty Degeneration (Steatosis)

The presence of liver cells displaying empty vacuoles of variable sizes and shapes within their cytoplasm in H and E and MSB stained sections. They ranged from micro- to macro-vesicles, which were histologically proved to contain fat in 10

cases by means of Oil Red O (frozen sections) and Osmium tetroxide stains for lipid.

(II) Fat Cysts

The exhibition of small extracellular, lipid filled spaces, in the liver lobules.

(III) Lipogranulomas

The development of inflammatory reaction with or without collagen deposition, around the fatty cysts, which can be seen in H and E and MSB stained sections.

(IV) Cholestasis

The appearance of intra- or extra-cellular greenish bile thrombi in Fouchet-stained sections.

(V) Fibrosis

(1) Terminal Hepatic Venule Sclerosis (THVS)

The deposition of collagen around the terminal hepatic venule (central vein) in the form of an interrupted or continuous collar of variable thickness.

(2) Centrilobular Pericellular Fibrosis

The demonstration of a lattice-like or chicken-wire appearance of collagen strands in the perivenular area, encasing the liver cells individually or in groups, within its meshes.

(3) Septal Fibrosis

Slightly curved or irregularly bent fibrous bridges, linking central-central and/or

portal canals.

(4) Stress Fissures

Straight strands of fibrous tissue which develop in areas of different degrees of expansion due to irregular fat deposition.

(5) Portal Fibrosis

The formation of fibrous tissues extensions which might bridge portal-portal and/or central fields.

(VI) Siderosis

The appearance of intense Prussian blue-stained intracellular haemosiderin granules in hepatocytes, Kupffer cells and portal tracts, in Perls' Prussian Blue-stained sections.

(VII) Copper - Deposition

The identification of golden yellow intrahepatocytic granules in Sodium Diethyl Dithio Carbamate-stained sections.

The amount of histologically visible fat was determined on a scale of 0-4 grades based on the H and E and MSB stained sections.

Grade 0, no fat.

Grade 1, less than 25% of the liver cells affected.

Grade 2, 25% to slightly less than 50%.

Grade 3, 50% to 75%.

Grade 4, over 75% of the cells affected.

Cholestasis, has been scaled quantitatively according to the types of cholestasis defined by Desmet and co-workers, (1970).

Type O, no cholestasis.

Type I, Intracellular fine granules of bilirubin.

Type IIA, Fine intracellular bilirubin granules and extracellular thrombi.

Type IIB, Fine and coarse intracellular granules and extracellular thrombi.

Type III, Intra- and extracellular pigment deposits and bile pigment within Kupffer cells and/or macrophages.

The patterns of fibrosis were quantitatively estimated on the MSB, Fouchet's, and Gordon and Sweet's stains.

Terminal hepatic venule sclerosis, has quantitatively been estimated on a scale of 5 grades,

Grade 1, Thin, non-uniform, patchy rim of fibrosis.

Grade 2, Thin, uniform rim of fibrosis.

Grade 3, Thick, uniform, stratified collar of fibrosis.

Grade 4, Grade 3 plus septa connecting adjacent central and/or portal zones.

Grade 5, Complete cirrhosis.

Centrilobular pericellular fibrosis as well as perisinusoidal fibrosis were assessed using a three grade scale,

Grade 1, Delicate.

Grade 2, Moderately thick.

Grade 3, Thick.

The degree of Portal Fibrosis was expressed as grade 0-4, representing increasing amounts of collagenosis,

Grade 0, No increase in portal fibrosis;

Grade 1, Slight;

Grade 2, Moderate;

Grade 3, Moderate - marked, plus septal formation;

Grade 4, marked plus septal formation and distortion of lobular architecture.

Parenchymal and Kupffer cell-siderosis was graded histochemically on a scale comparable to that used by Lundvall and his colleagues (1969), using Perls' stain,

For parenchymal siderosis,

Grade 0, no stainable iron.

Trace, Isolated fine granules in the whole preparation (difficult to determine whether artefacts or not).

Grade 1, Definite fine haemosiderin granules in single cells or small scattered cell groups.

Grade 2, Fine haemosiderin granules in a few or several cells present in most lobules.

Grade 3, Mainly fine but also coarse haemosiderin granules present in the periphery of all lobules.

Grade 4, Substantial amount of mainly coarse haemosiderin granules in the major part of the lobule.

For Kupffer cell Siderosis,

Grade 0, No stainable iron.

Trace, Haemosiderin in single Kupffer cells, difficult to determine whether artefacts or not.

Grade 1, Definite intracellular haemosiderin in single Kupffer cells.

Grade 2, Moderate amount of haemosiderin in one or several Kupffer cells in all fields.

Grade 3, Gross haemosiderin aggregation in most of the identifiable Kupffer cells.

Grade 4, Gross haemosiderin aggregation in all of the identifiable Kupffer cells.

The severity of other histological features (parenchymal and portal inflammation, portal siderosis, bile ductular proliferation and hepatic glycogen) have been quantitated according to four levels:

minimal, mild, moderate and marked.

When fatty liver was found at post-mortem examination to be the only prominent pathological finding and the leading cause of death, additional selected cerebral, pulmonary and renal sections were taken. A

block (3 x 2cm in area and 1cm in thickness) was taken from each lung - from the lateral aspect of the upper portion of the lower lobe. When the brain was investigated, 2-4 blocks were taken at the time of the necropsy. These blocks were chosen from selected areas namely, the frontoparietal cortex and underlying white matter, basal ganglia, mid-brain or pons and white matter around lateral ventricles including the corpus callosum. Fixation was accomplished in buffered neutral formalin and frozen sections were cut at 25u-35u. These were then stained with oil red O and examined, particularly, to exclude or confirm cerebral or pulmonary fat-embolism as a factor being relatively resistant to post-mortem changes in contrast to other mechanisms of sudden fatty liver death. The severity of fat-embolism was estimated on a three-grade scale,

Grade 1, Light.

Grade 2, Moderate.

Grade 3, Heavy.

Statistical analysis of our survey was made using the following tests: Chi-square test, Fisher's exact test, T-test and Mann-Whitney U-test. In addition, discriminant analysis was carried out for the calculation of the alcoholic scores of both alcoholic and control groups.

C H A P T E R - F O U R

RESULTS

4.1 DEMOGRAPHIC CHARACTERISTICS

4.1.1 AGE

The application of the T-test has proved that there is no significant difference between alcoholic and control groups in their age distribution at death (Figure 1). The mean age of the entire chronic alcoholic group was 56, with a range of 25-87 years. However, the peak age incidence was in the seventh decade.

4.1.2 SEX

The composition of the entire sample 200 with regard to sex displayed no significant difference between alcoholics and controls, as noted in Table 1. There is a male preponderance in both groups.

4.1.3 MARITAL STATUS

Death rates in relation to marital status (Table 2) revealed some interesting groupings. Rates were low for the married. Those who were separated and divorced had the highest rates among alcoholic; while for single and

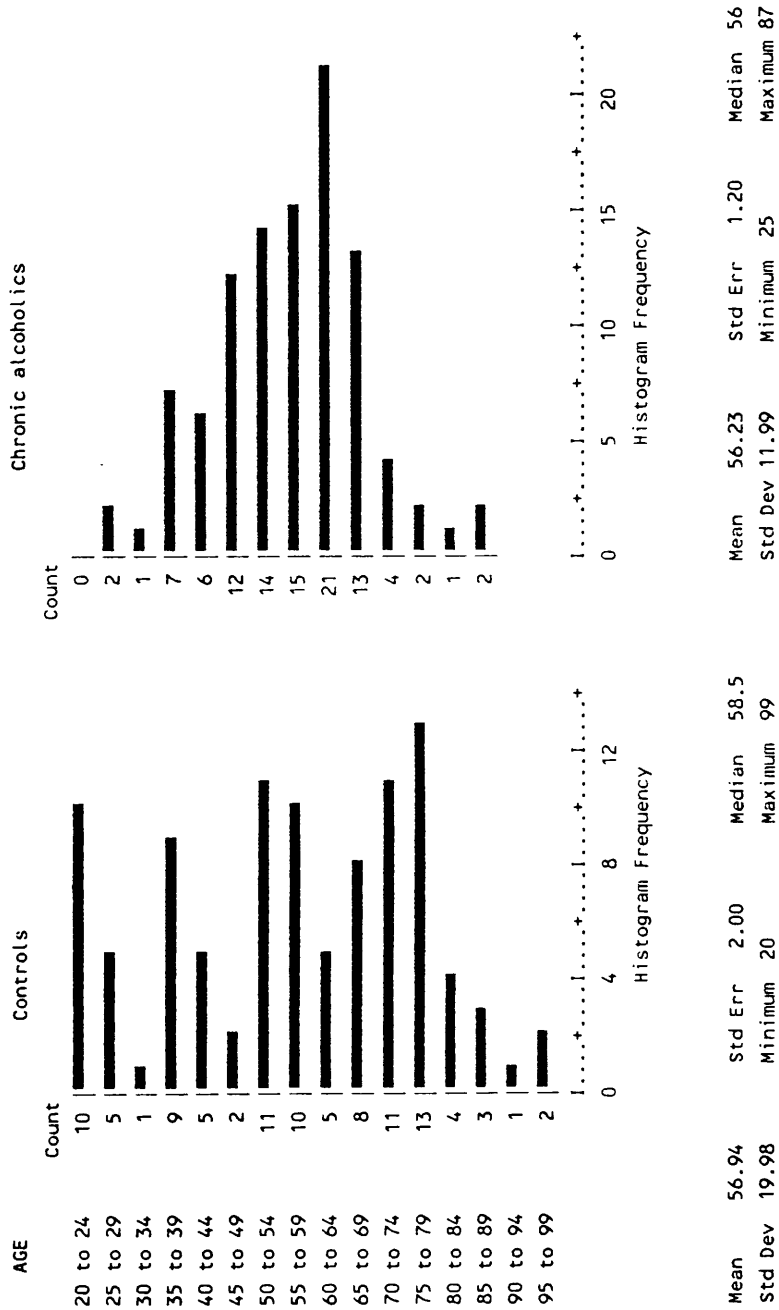


FIGURE 1. DISTRIBUTION OF ALCOHOLICS AND CONTROLS BY AGE GROUP

TABLE 1.
SEX DISTRIBUTION OF ALCOHOLICS AND CONTROLS

SEX	Controls	Chronic Alcoholics	Row Total
Male	72 0.7	60 -0.7	132 66%
Female	28 -1.0	40 1.0	68 34%
Column	100	100	200
Total	50%	50%	100%

Chi-Square

2.69608

3.20856

Significance

0.1006

0.0733

*In each cell of this and similar tables, there are two numbers. The first is a count of the cases which fall into the particular category defined by the row and column labels. The second number is the standard residual, which measures the extent to which the count exceeds the expected count, expressed relative to the standard error of the expected count. The expected count is the count that would be expected, given the row and column totals, on the basis of the null hypothesis that membership of the row categories has no influence on membership of the column categories and vice versa.

In algebraic terms, the expected count for any cell is the row total multiplied by the column total and divided by the grand total. The standard residual is the observed count minus the expected count divided by the square root of the expected count.

Thus, cells with large positive standard residuals are those in which the count is unexpectedly high; those with large negative standard residuals are those in which the count of cases is unexpectedly low. Standard residuals in the range (-2 to +2) are not significant.

widowed people the rates were highest in the controls. Whether alcoholism was the cause of marital dissolution, or marital problems led to alcoholism obviously cannot be determined from our data.

TABLE 2.
DEATH RATES OF ALCOHOLICS AND CONTROLS IN RELATION TO
MARITAL STATUS

Marital Status	N u m b e r o f C a s e s	
	Alcoholics	Controls
Married	37	26
Separated	10	03
Divorced	14	07
Single	16	39
Widowed	23	25
Total	100	100

4.1.4 OCCUPATIONAL STATUS

Of 100 alcoholics, 30 were unemployed, 19 were housewives, 30 were of unknown previous occupation, 3 were production workers, 2 were clerical and sales personnel, 5 were service workers and 11 were professional and technical workers. Whereas the controls were, 28 unemployed, 8 housewives, 40 of unknown previous occupation, 3 production workers, 2 sales personnel, 11 service workers and 8 professional and technical workers (Table 3).

TABLE 3
OCCUPATIONAL STATUS OF ALCOHOLICS AND CONTROLS

Occupational Status	N u m b e r o f	
	Alcoholics	C a s e s Controls
Unemployed	30	28
Housewives	19	8
Production Workers	3	3
Clerical and Sales Personnel	2	2
Service Workers	5	11
Professional and Technical Workers	11	8
Unknown Previous Occupation	30	40
Total	100	100

4.2. MODE OF DEATH

The causes of death among alcoholics showed highly significant differences from controls ($P = 8 \times 10^{-7}$ as judged by chi-square test). The differences are noted in detail in Table 4A. and B. The most conspicuous differences between the two groups were seen in the incidence of death due to gastro-intestinal causes (1 control; 26 alcoholics), and cardiovascular causes (44 controls; 21 alcoholics) (Figure 2). The outstanding feature in the category of gastro-intestinal causes was fatty degeneration of the liver. It is responsible for 16 cases of sudden fatty liver deaths in which severe hepatic steatosis is the only major post-mortem finding.

4.3. LOCATION AND CIRCUMSTANCES OF DEATH

Commonly the victim, especially among alcoholics, is simply found dead in bed, on the floor of the house, or elsewhere (Table 5). Fourteen of 16 deaths due to fatty

liver were unwitnessed. Only 2 were observed and, therefore, detailed information about symptoms and signs at onset were not available. As with much forensic pathology, the home is the common location. Sixty-five of all alcoholics' deaths occurred at home, including 14 of 16 of the deaths certified as due to fatty liver, and 51 of 84 deaths from other causes. Apart from that, distribution of place and circumstances at onset were comparable in both series of deaths.

TABLE 4.

CAUSES OF DEATH OF ALCOHOLICS AND CONTROLS

(A) (see also Table 1. for format of number entries)

CAUSES OF DEATH	Controls	Chronic Alcoholics	Row Total
Central Nervous	3 0.0	3 0.0	6% 3.0%
Cardiovascular	44 2.0	21 -2.0	65% 32.5%
Respiratory	13 -1.0	21 1.0	34 17.0%
Gastro-intestinal	1 -3.4	26 3.4	27 13.5%
Acute Alcohol Intoxication	0 -1.4	4 1.4	4 2.0%
Acute Alcohol and Drug Intoxication	2 -1.0	6 1.0	8 4.0%
Drug Intoxication	6 1.3	1 -1.3	7 3.5%
Fire	6 0.0	6 0.0	12 6.0%
Trauma	7 0.2	6 -0.2	13 6.5%
Asphyxia	14 1.9	3 -1.9	17 8.5%
Other	4 0.3	3 -0.3	7 3.5%
Column Total	100 50.0%	100 50.0%	200 100.0%

To avoid very small expected frequencies in chi-square testing, the 3 row categories of intoxication were combined and CNS category merged with 'Other'.

Chi-Square
40.9142

Significance
 8×10^{-7}

(B)

Cause of Death	Number of Cases	
	Alcoholics	Controls
<u>Central Nervous System</u>		
1. Cerebral Infarction	1	0
2. Cerebral Haemorrhage	1	1
3. Extradural Haemorrhage	0	1
4. Subarachnoid Haemorrhage	1	1
<u>Cardiovascular System</u>		
1. Acute Myocardial Infarction	2	11
2. Cardiomyopathy	0	1
3. Coronary Thrombosis	2	4
4. Coxsackie B4 (virus) Myocarditis	1	0
5. Ischaemic Heart Disease	14	24
6. Left Ventricular Failure	1	0
7. Pulmonary Thrombo-Embolicism	0	2
8. Ruptured Abdominal Aortic Aneurysm	1	2
<u>Respiratory System</u>		
1. Acute Exacerbation of Chronic Bronchitis	3	2
2. Acute Pulmonary Oedema	0	2
3. Bronchopneumonia	10	3
4. Inhalation of Gastric Contents	8	6
5. Acute Asthmatic Bronchitis	0	1
<u>Gastro-intestinal System</u>		
1. Acute Gastric Erosions	1	0
2. Acute Pancreatitis	2	0
3. Acute Perforation of Duodenal Ulcer	2	1
4. Carcinoma of the Ascending Colon	1	0
5. Fatty Degeneration of the Liver	16	0
6. Perforation of Sigmoid Colon Diverticulum	1	0
7. Pyloric Stenosis	2	0
8. Ruptured Oesophageal Varices	1	0
<u>Intoxication</u>		
1. Acute Alcohol Intoxication (>300mg)	3	0
2. Acute Alcohol and Drug Intoxication:-		
a. Alcohol and Coproxamol	1	0
b. Alcohol and Dextropropoxyphene	1	0
c. Alcohol and Chlormethiazole	1	0
d. Alcohol, Heroin and Phenobarbitone	0	1
e. Alcohol and Nitrazepam	1	0
f. Alcohol and Propranolol	0	1
g. Alcohol and Temazepam	2	0
3. Acute Drug Intoxication:-		
a. Amitriptyline and Temazepam	0	1
b. Chlormethiazole and Paracetamol	1	0
c. Coproxamol	0	1
d. Heroin	0	1
e. Morphine Sulphate	0	1
f. Temazepam	0	1
4. Acute Alcohol Intoxication (<300mg) Combined with Natural Disease	1	0

(B) Contd.

<u>Fire</u>	6	6
<u>Asphyxia</u>		
1. Choking	0	1
2. Drowning	2	5
3. Hanging	1	8
<u>Trauma</u>		
1. Head Injury	2	3
2. Fractured Cervical Spine	0	1
3. Stab-wounds of Neck and Chest	0	1
4. Ruptured Spleen (Fractured Ribs)	1	0
5. Fractured Pelvis	1	0
6. Fractured Neck of Femur	1	0
7. Multiple Injuries	1	2
<u>Other</u>		
1. Adrenal Heamorrhage	1	0
2. Chronic Alcoholism and Self-Neglect	1	0
3. Hypothermia	1	2
4. Post-operative Death	0	1
5. Unascertained	0	1
<u>Total</u>	100	100

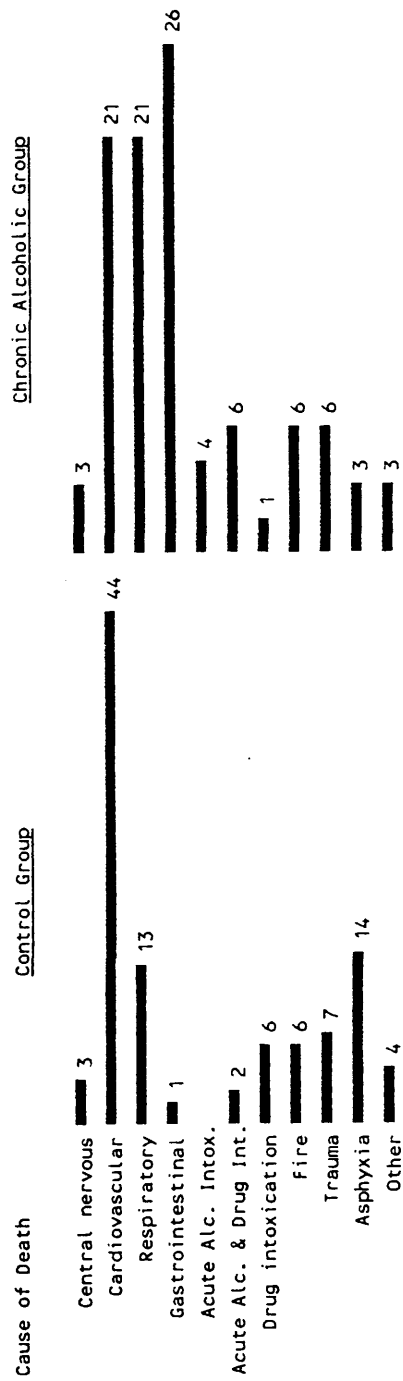


FIGURE 2. MODE OF DEATH IN ALCOHOLICS AND CONTROLS

TABLE 5.
LOCATION AND CIRCUMSTANCES OF DEATH OF ALCOHOLICS AND CONTROLS

<u>Circumstances</u>	<u>Location</u>	<u>N u m b e r o f</u>		<u>C a s e s</u>
		<u>A l c o h o l i c s</u>		<u>C O N T R O L S</u>
		<u>S.F.L.D.S.*</u>	<u>Others</u>	
<u>Found Dead:-</u>				
	Home:			
	Bedroom	8	25	23
	Lounge	4	18	13
	Bathroom	1	4	2
	Kitchen	1	2	2
	Hallway	0	2	3
	Staircase	0	0	1
	Hostel:	0	1	1
	Garage:	0	0	1
	School:	0	0	1
	Street:	0	1	1
	Cinema:	0	0	1
	Custody:	0	1	0
	Caravan:	0	0	2
<u>Found in Coma or Intoxicated:</u>				
	Home	0	1	1
<u>Found Floating in Body of Water:</u>				
	River	0	1	6
<u>Collapsed Suddenly:</u>				
	Home	2	13	13
	Pub	0	1	2
	Street	0	2	0
	Church	0	0	1
	Shop	0	0	2
<u>Fire:</u>				
	Home	0	6	6
<u>Road Traffic Accident:</u>				
	Road	0	2	4
<u>Hanging:</u>				
	Home	0	1	6
	Hospital	0	0	1
	Custody	0	0	1
<u>Died in Hospital after Lengthy Stay or at Home:</u>				
	Home	0	1	0
	Hospital	0	2	4
<u>Died after Operation:</u>				
	Hospital	0	0	2
<u>T O T A L</u>		16	84	100

* S.F.L.D.s = Sudden Fatty Liver Deaths.

4.4 POST-MORTEM BLOOD ALCOHOL LEVELS

Post-mortem blood alcohol levels were ascertained in most deaths (Figure 3). There were no significant differences in the blood alcohol levels between alcoholics and controls according to the Mann-Whitney U-Test (Wilcoxon's Ranks Sum W Test). However, 4 deaths among alcoholics were attributed to acute alcoholism because of the very high blood alcohol levels. The direct toxic effects of high blood alcohol levels were believed to be the cause of death. In all of these cases there was also a fatty liver. Blood alcohol levels have been measured in 14 of the 16 sudden fatty liver deaths and in the majority of these cases the levels were either negative or very low. Only a small percentage was in the intoxication range of 100mg/100ml or greater.

4.5 ALCOHOLIC FATTY LIVER - HISTOPATHOLOGY

4.5.1 STEATOSIS

The incidence of each degree of parenchymal steatosis among both alcoholic and control groups is shown in Table 6. The latter revealed highly significant differences between the two groups ($p < 0.0001$). The most apparent differences were seen in the incidence of the following grades of steatosis:

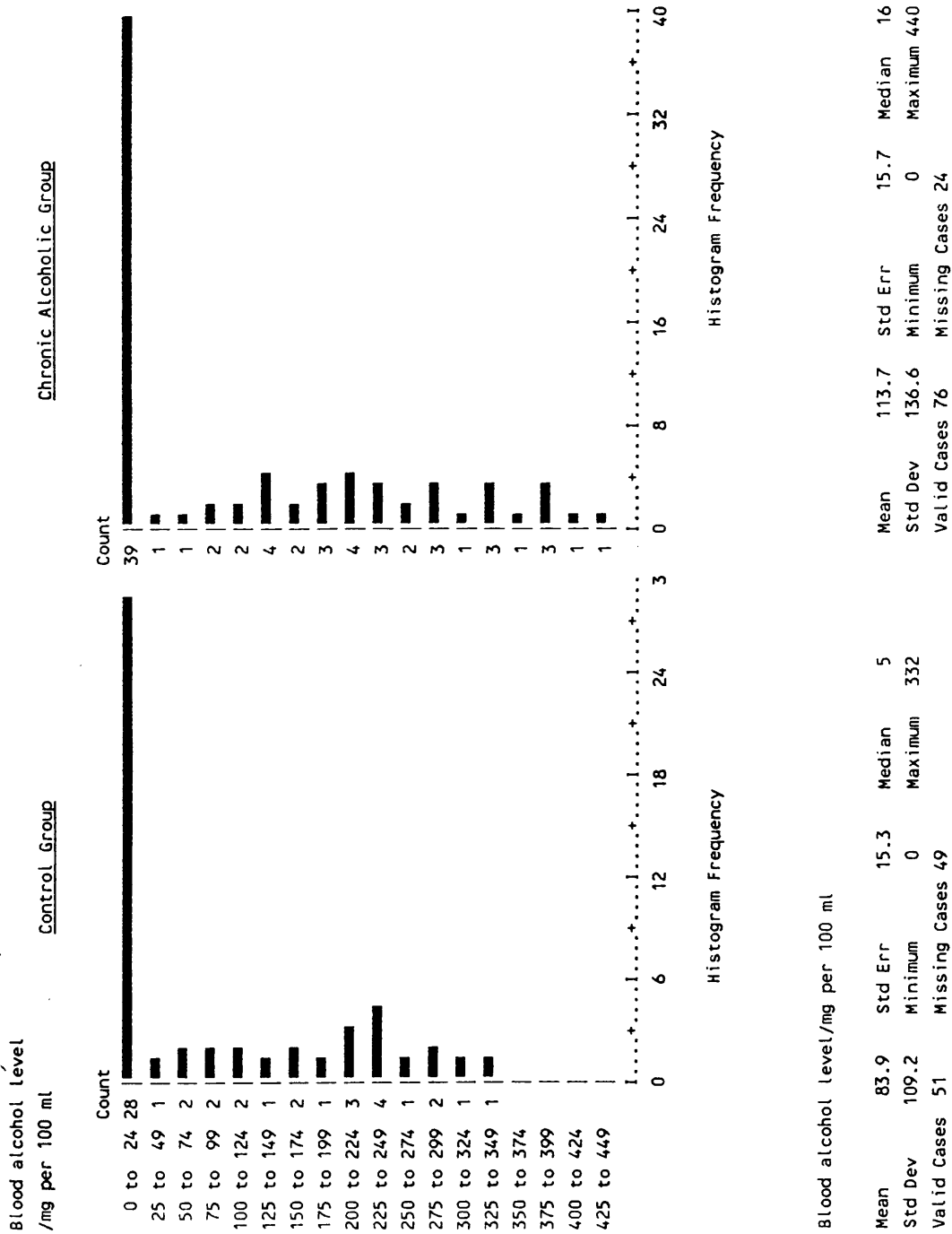


FIGURE 3. DISTRIBUTION OF POST-MORTEM BLOOD ALCOHOL LEVELS AMONG ALCOHOLICS AND CONTROLS

grade 0 (0 alcoholics; 48 controls);
grade 3 (28 alcoholics; 0 controls); and,
grade 4 (41 alcoholics; 0 Controls).

TABLE 6.
DISTRIBUTION OF ALCOHOLICS AND CONTROLS AS TO THE DEGREE OF
HEPATIC STEATOSIS

Steatosis Degree	Controls	Chronic Alcoholics	Row Total
0	48 4.9	0 -4.9	48 24.0%
1	39 1.6	21 -1.6	60 30.0%
2	13 0.4	10 -0.4	23 11.5%
3	0 -3.7	28 3.7	28 14.0%
4	0 -4.5	41 4.5	41 20.5%
Column Total	100 50.0%	100 50.0%	200 100.0%

Chi-Square

122.79130

Significance

0.0001

The amount of histologically visible fat, which was graded on a four-degree scale, was severe and diffuse (panlobular) in the majority of alcoholics (Figure 4b); but in cases of chronic alcoholism associated with a less pronounced degree of fatty change, the pathological process was more marked in the central and mid-zonal areas (Figure 4a). In some cases, even in those in which the fatty changes were very severe, a few rows of periportal hepatic cell cords were spared the fatty metamorphosis.

Microscopically, the fat was demonstrated in various

forms. Commonly the hepatic cells showed large single vacuoles of fat, macrovesicular steatosis, displacing the nucleus peripherally, markedly distending the cell and practically occluding the adjacent sinusoids (Figure 4b). A mosaic pattern of hepatic parenchyma was produced as a result. Microvesicular fatty degeneration, small multiple vacuoles, was seen in 24 alcoholics and 19 controls (Figure 4c). Few cases in both test and control groups showed mixed sizes of fatty vacuoles. The least encountered type of fatty change was the foamy fatty variety (Figure 4d), which was demonstrated in only 5 chronic alcoholics and in none of the controls. The foamy appearance of the swollen hepatocytes was due to innumerable microvacuoles throughout the characteristically pale cytoplasm. In some cases, mixed types of fatty change can be seen particularly in the mid-zonal and periportal areas. Severe degrees of this type of steatosis were seen in all cases which were associated with some other histological manifestations such as minimal diffuse lymphocytic though not neutrophilic cell infiltration. Fibrosis in many forms, terminal hepatic venule sclerosis, perisinusoidal, septal, portal, and centrilobular pericellular fibrosis were sometimes a concomitant change. Cholestasis, mostly type IIA and siderosis were inconstant.

Commonly, fat cysts were noted particularly in association with severe fatty change (Figure 4e). They are sometimes seen linked with sinusoids. On occasion, collagen fibres and inflammatory reaction were seen around

these fat cysts, forming lipogranulomas. Different types of lipogranulomas were found especially in alcoholics. The distribution of these types among the latter and controls is noted in Table 7A. The structure recorded as lipogranuloma presented one of the following appearances:

Type I, Figure 4f;

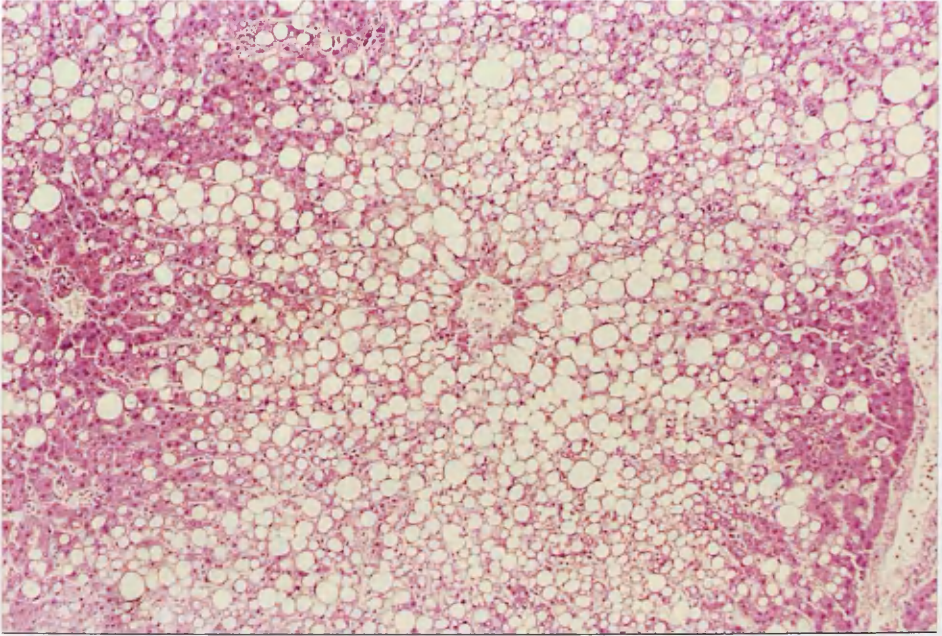
Type II, Figure 4g;

and Type III, Figure 4h.

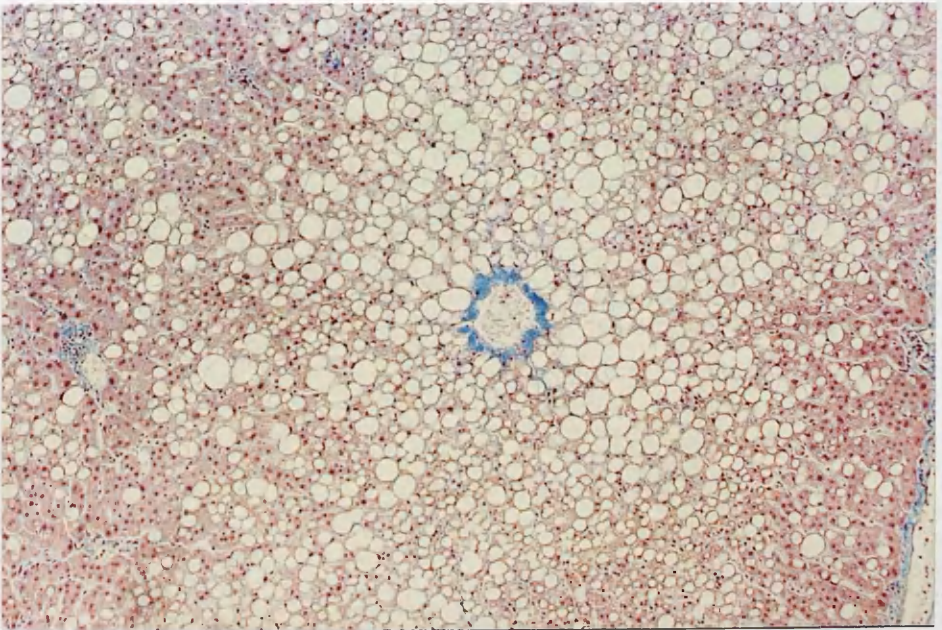
The number of lipogranulomas varies from 1-21 per section (Table 7B) to several per lobule. If many were present, they were usually evenly distributed throughout the field. Multinodular lipogranulomas, Type III, were most frequently found in relation to the terminal hepatic venules.

Portal steatosis (Figure 4i) was occasionally associated with granulomatous reaction, and was more frequent in alcoholics than in controls (30 alcoholics; 6 controls).

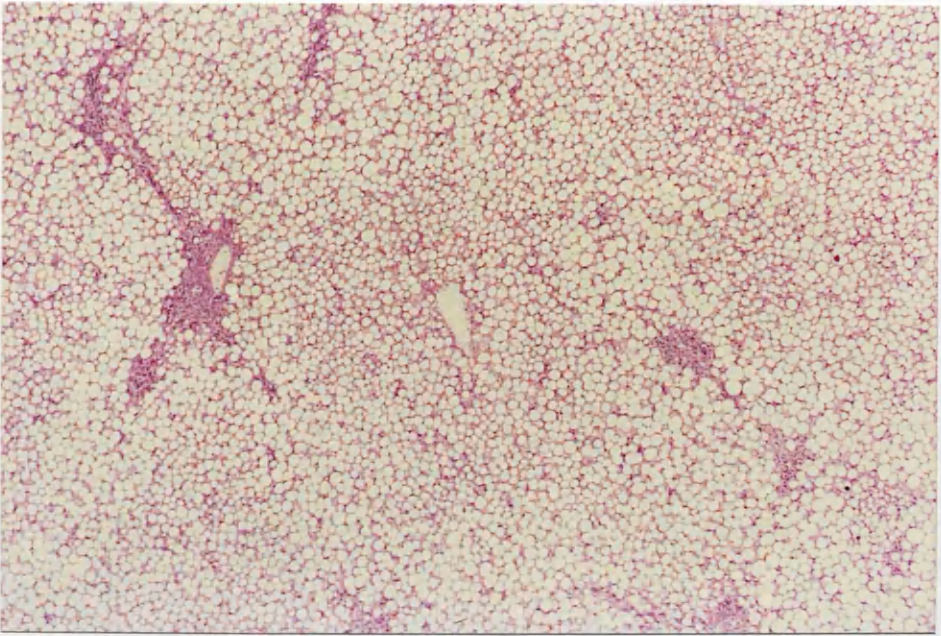
FIGURE 4. ALCOHOLIC FATTY DEGENERATION



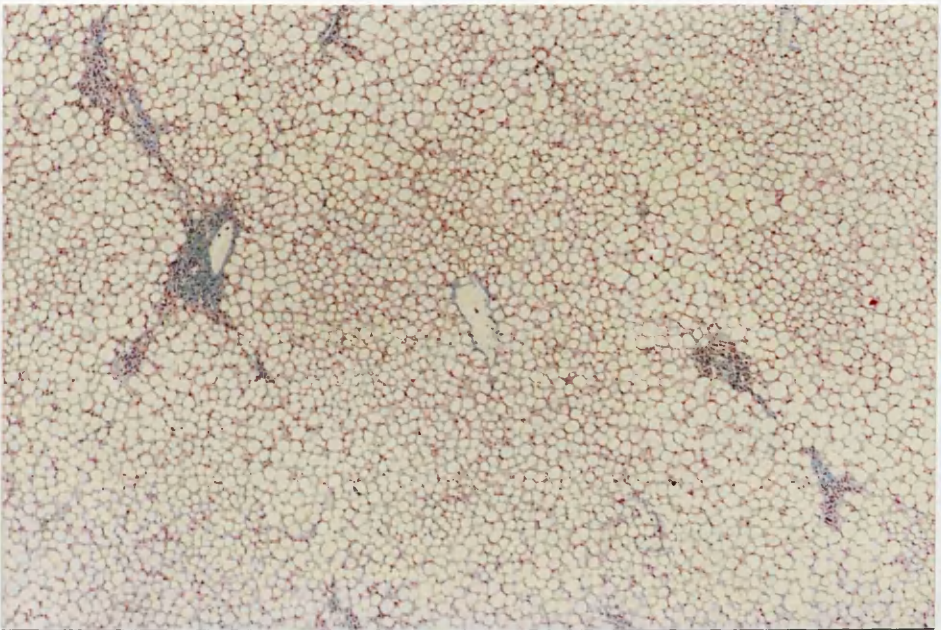
4a. Severe macro-vesicular fatty change of the central and midzonal portions of the lobules (Grade 3). (H. and E.; x 100).



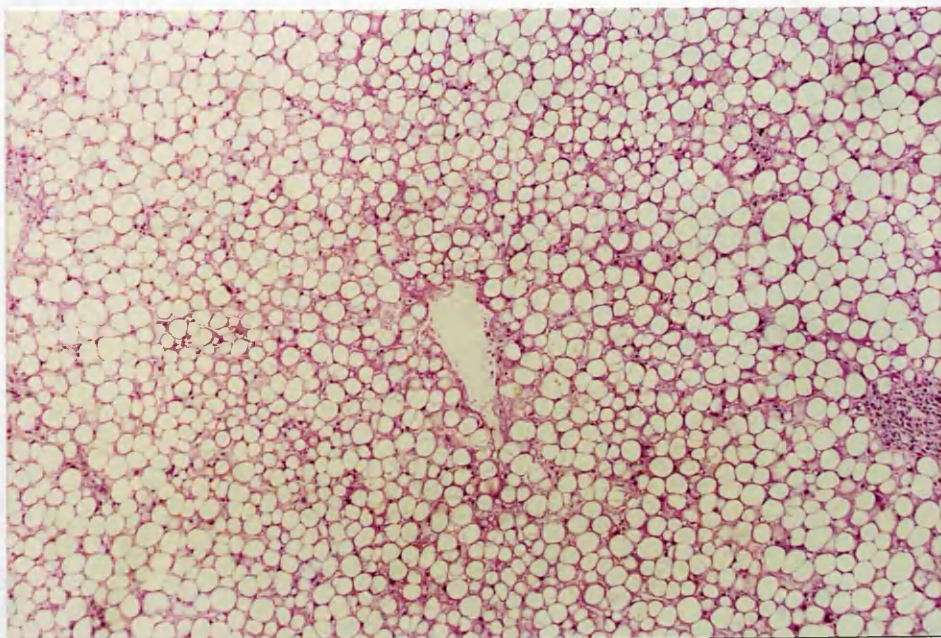
Idem. (M.S.B.; x 100)



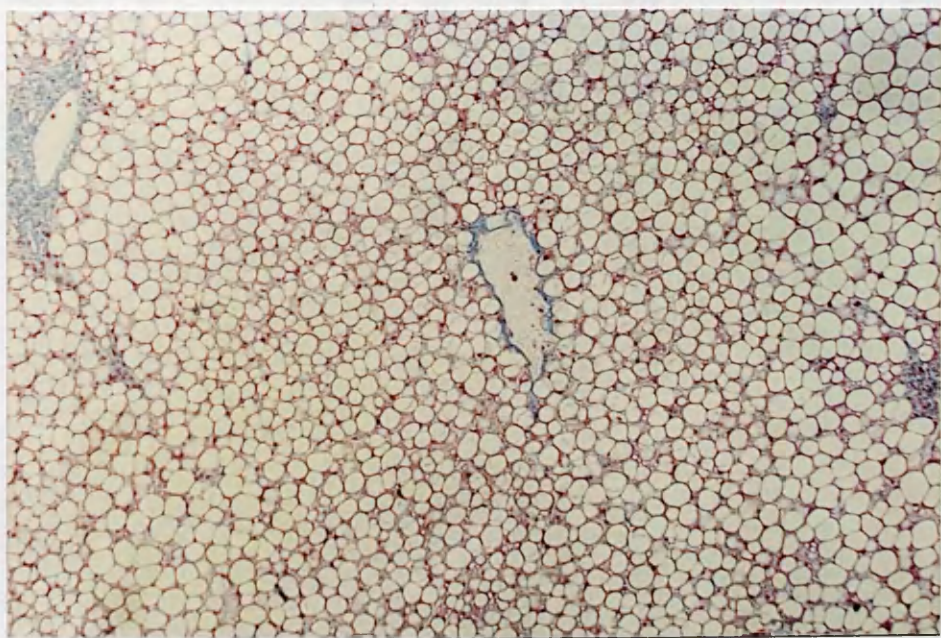
- 4b. Very severe macro-vesicular steatosis showing panlobular involvement of liver cells (Grade 4). The nuclei of hepatocytes are displaced and a mosaic appearance is produced. (H. and E.; x 40)



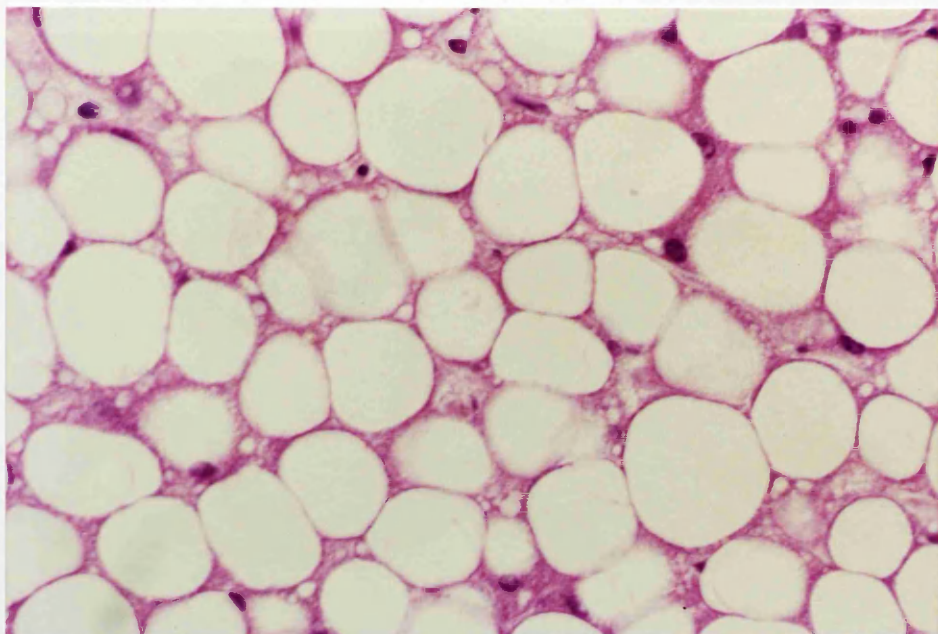
Idem. (M.S.B.; x 40)



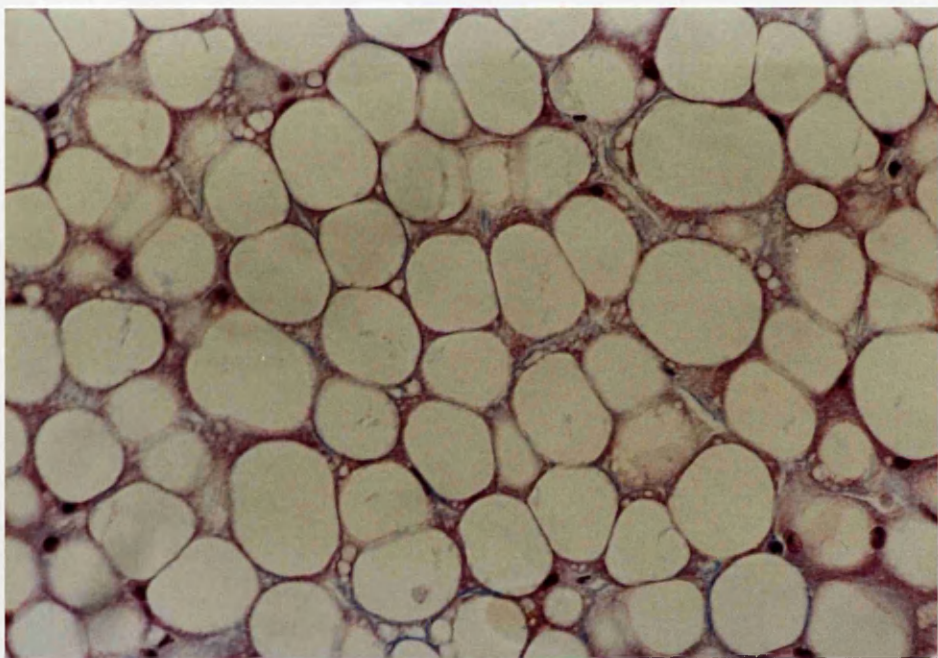
Idem. (H. and E.: x 100)



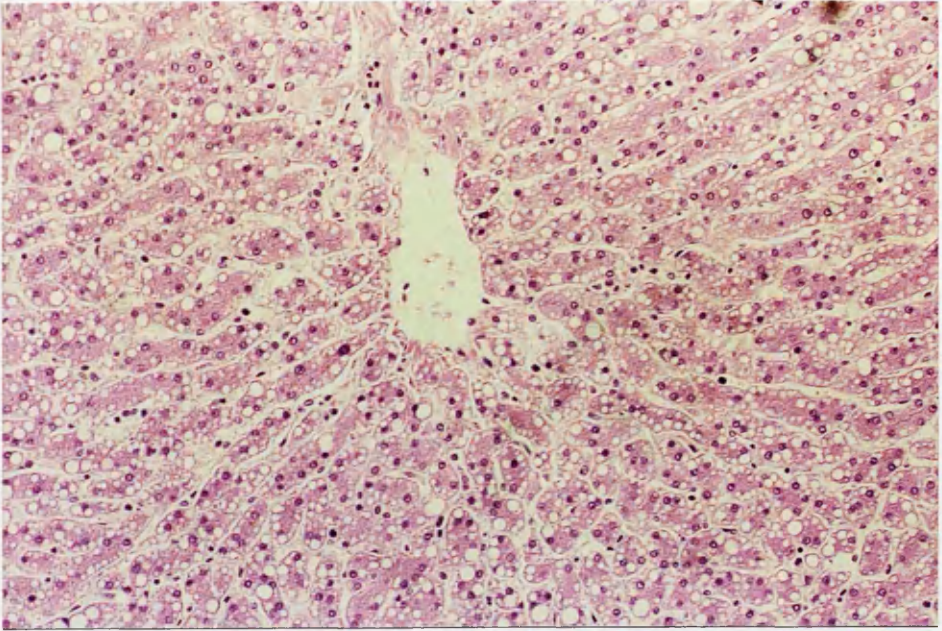
Idem. (M.S.B.; x 100)



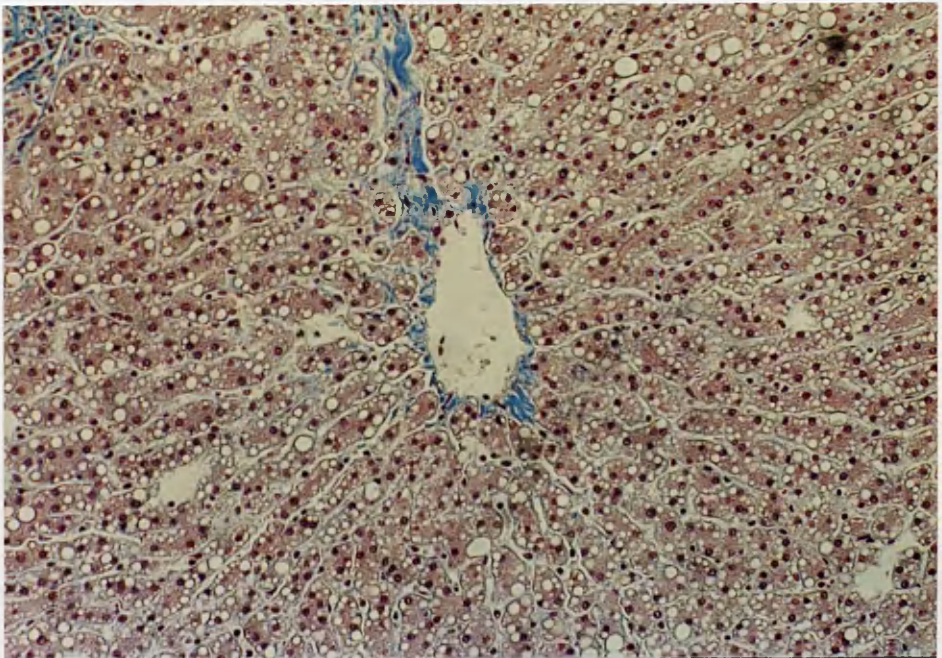
Idem. (H. and E.: x 400)



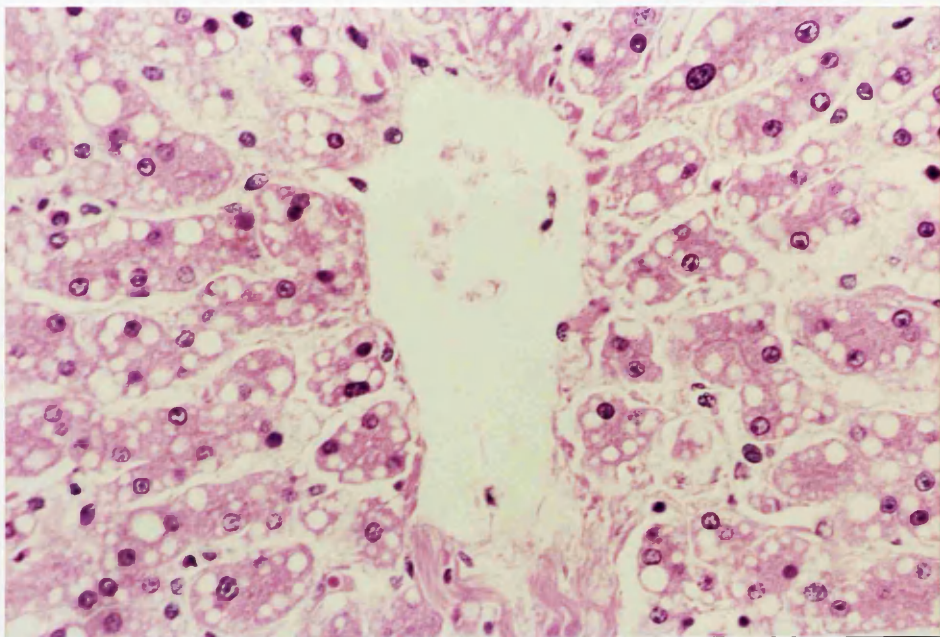
Idem. (M.S.B.; x 400)



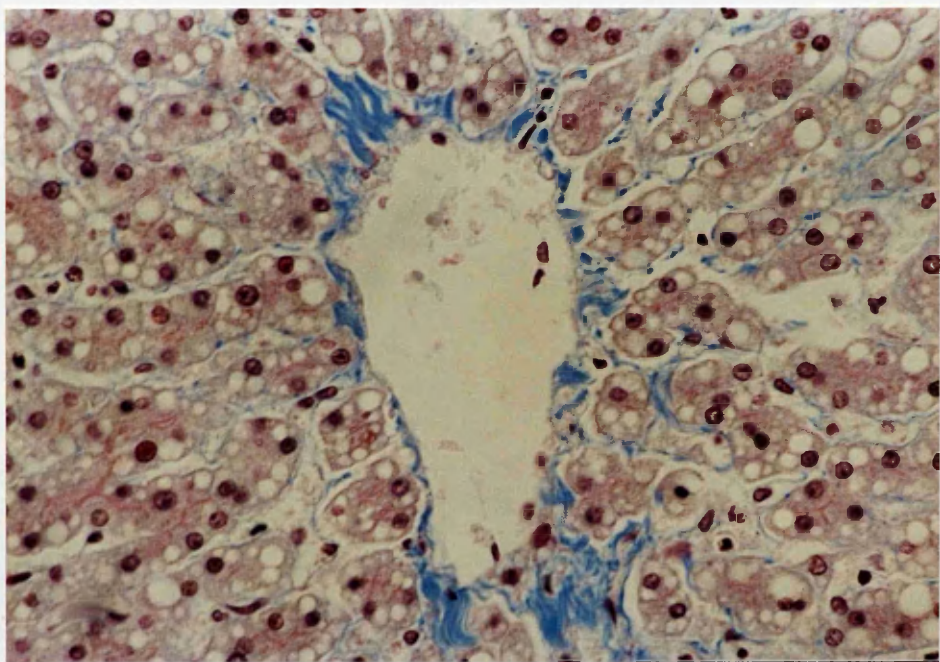
4c. Micro-vesicular fatty degeneration. Multiple small vacuoles accumulate within hepatocytes, which do not displace the nuclei. (H. and E.; x 100)



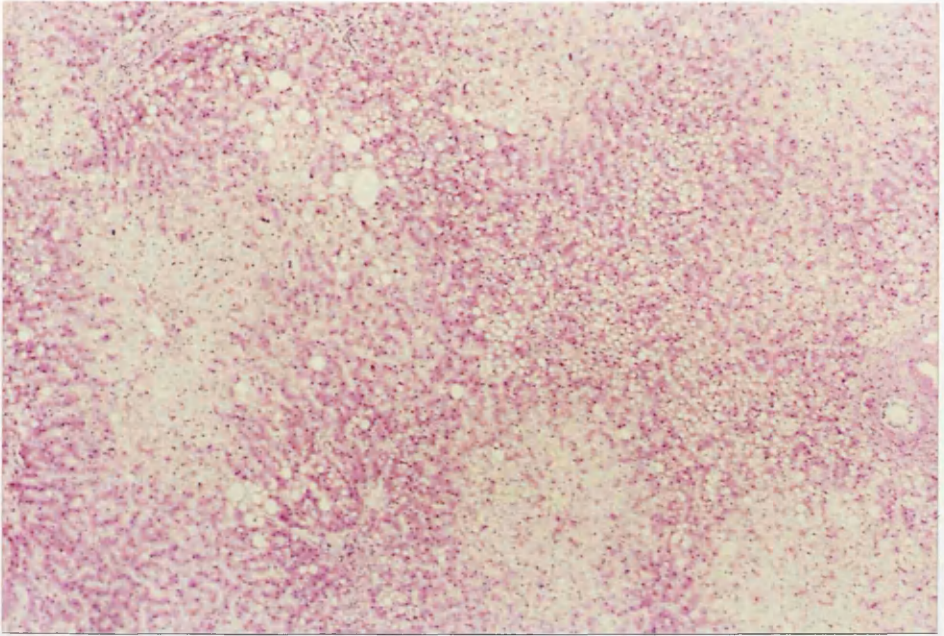
Idem. (M.S.B.; x 100)



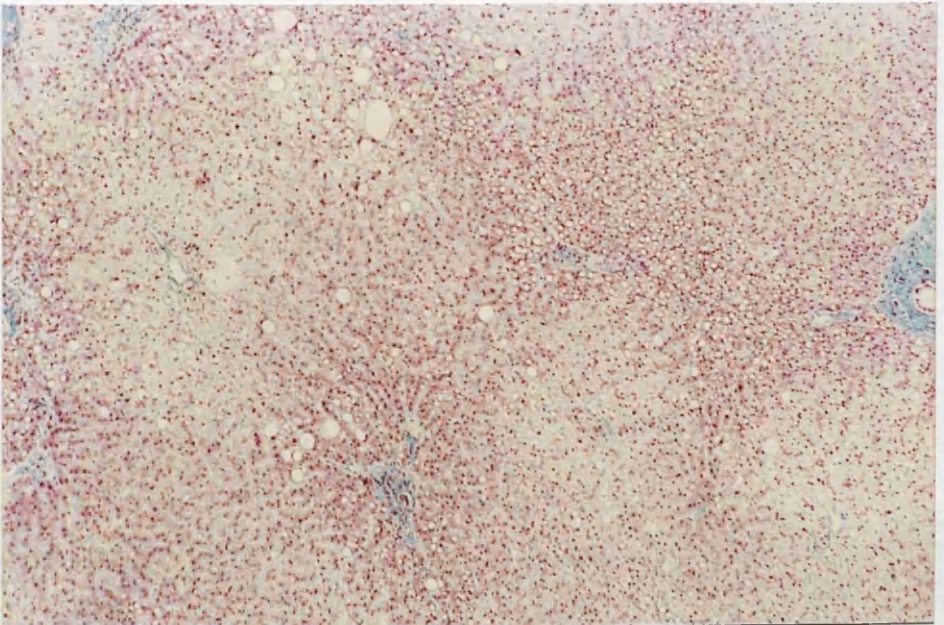
Idem. (H. and E.: x 400)



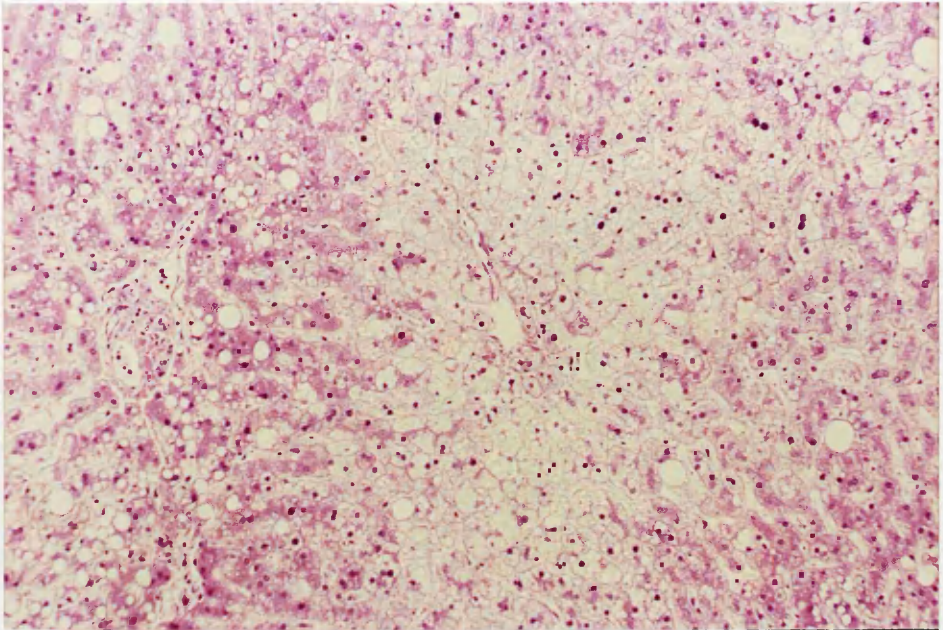
Idem. (M.S.B.: x 400)



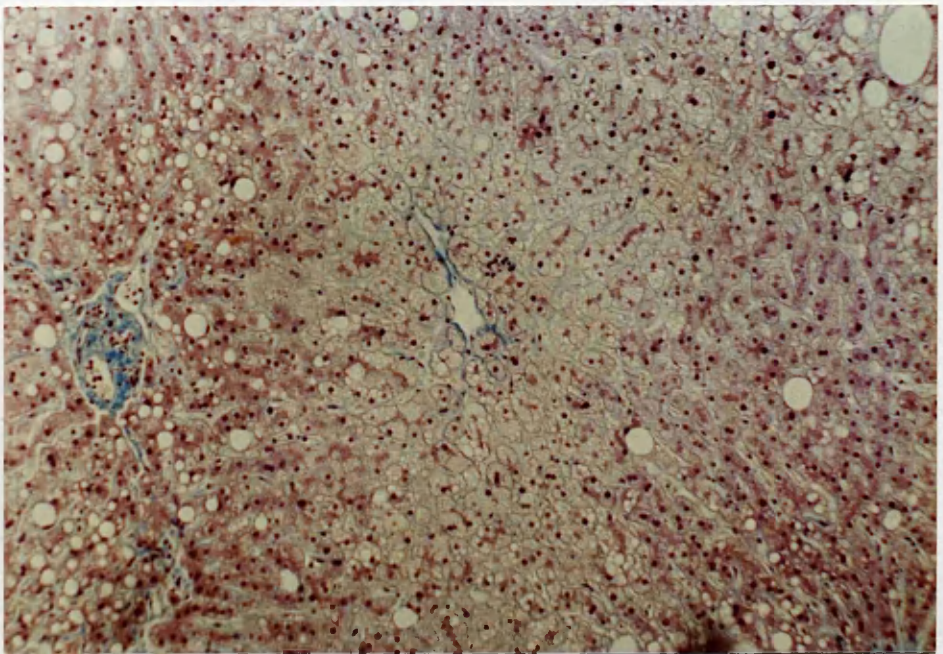
- 4d. Alcoholic Foamy Degeneration. The pale, swollen perivenular liver cells characterized by massive accumulation of tiny fat droplets with shrunken central nuclei. There is also some periportal-macrovesicular steatosis and occasionally cells with both patterns of fat accumulation can be seen.
(H. and E.; x 40).



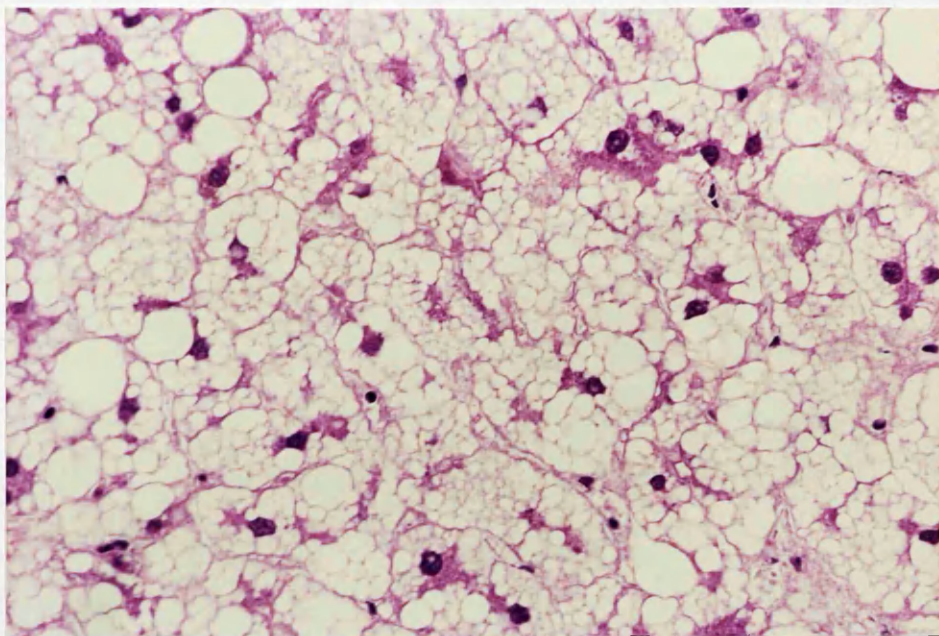
Idem. (M.S.B.; x 40)



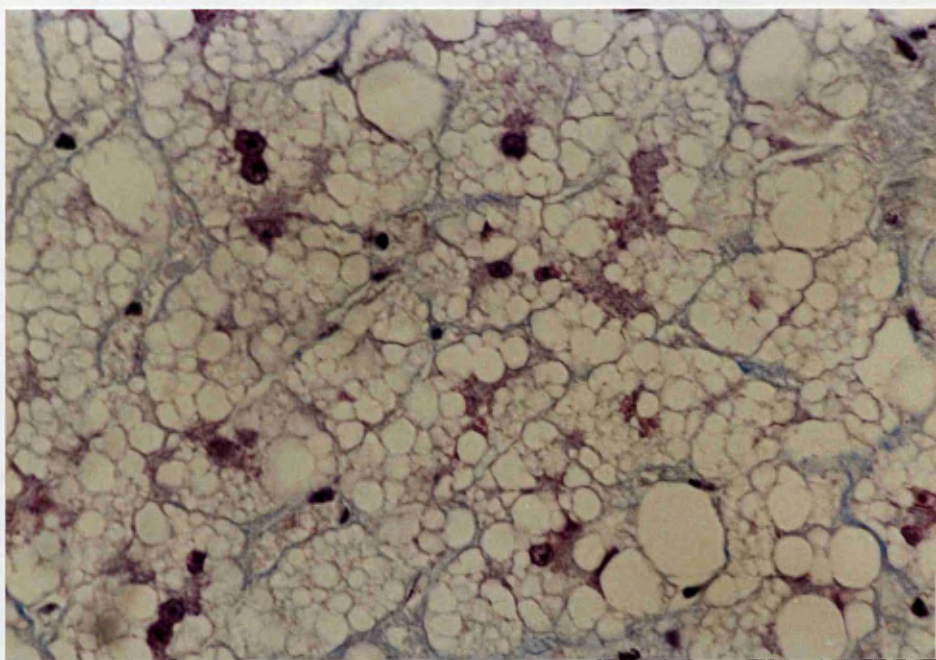
Idem. (H. and E.: x 100)



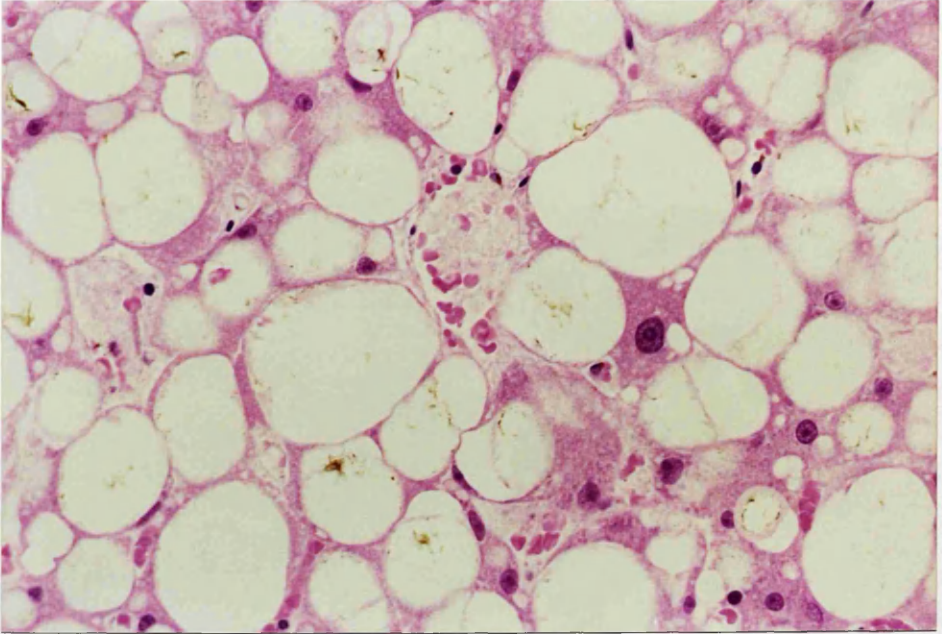
Idem. (M.S.B.; x 100)



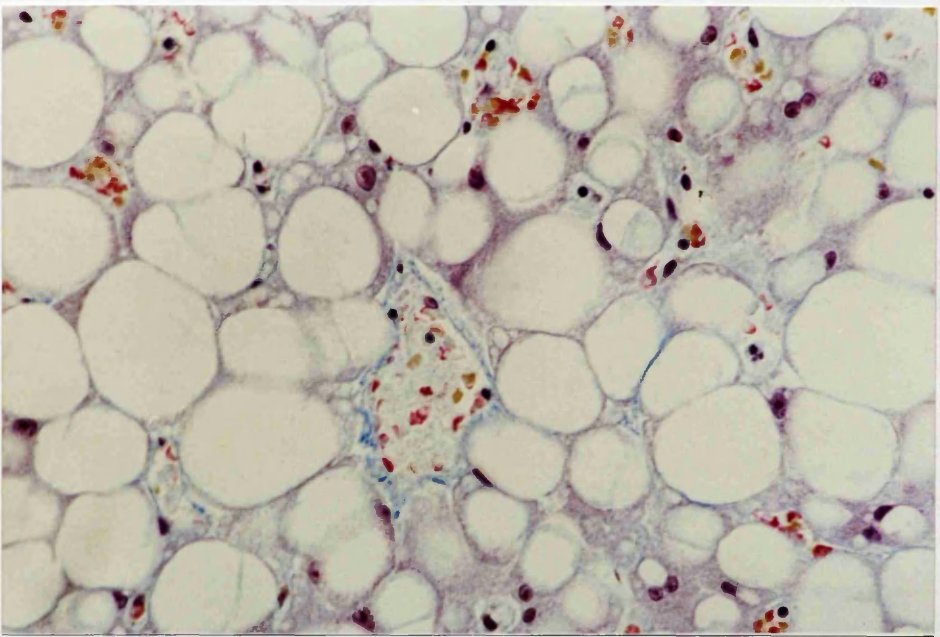
Idem. (H. and E.: x 400)



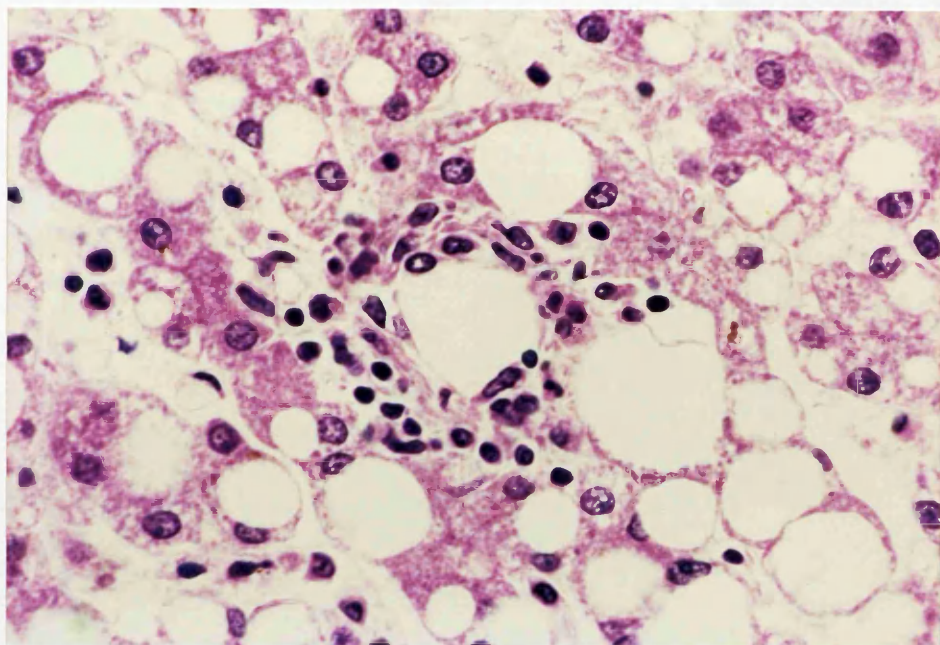
Idem. (M.S.B.; x 400)



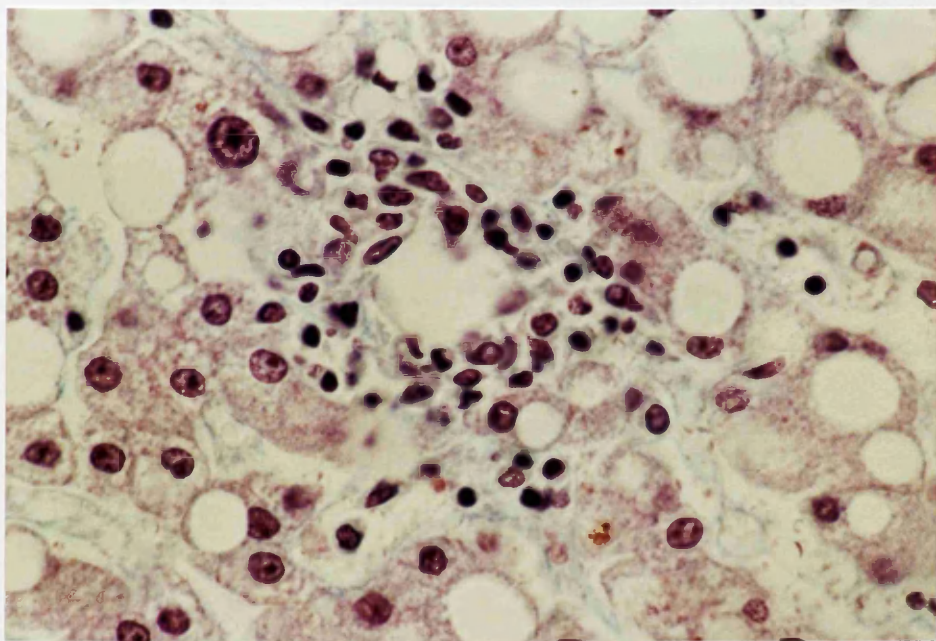
4e. Fatty cysts due to coalescence of fat droplets
in several liver cells.
(H. and E.; x 400)



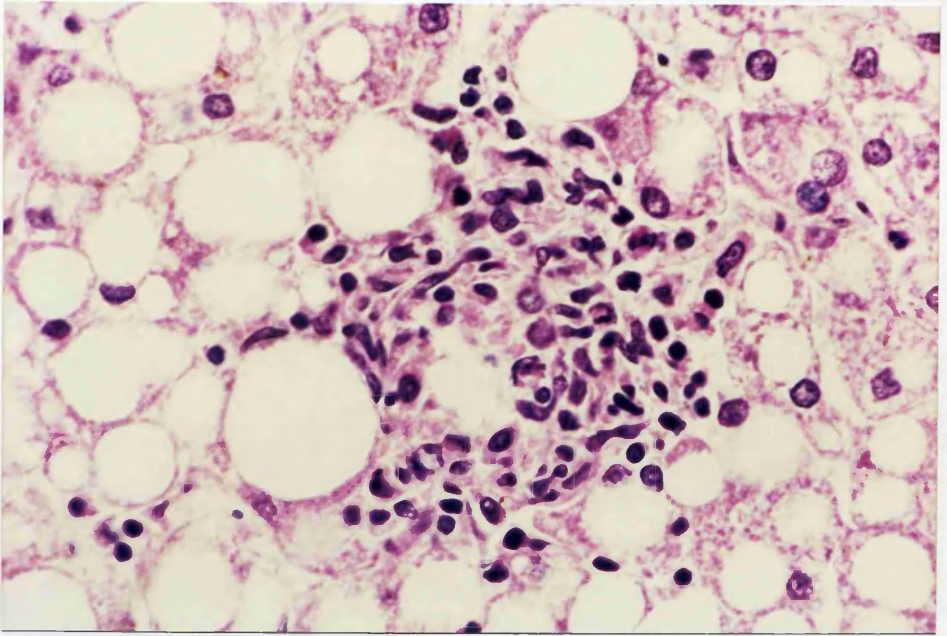
Idem. (M.S.B.; x 400)



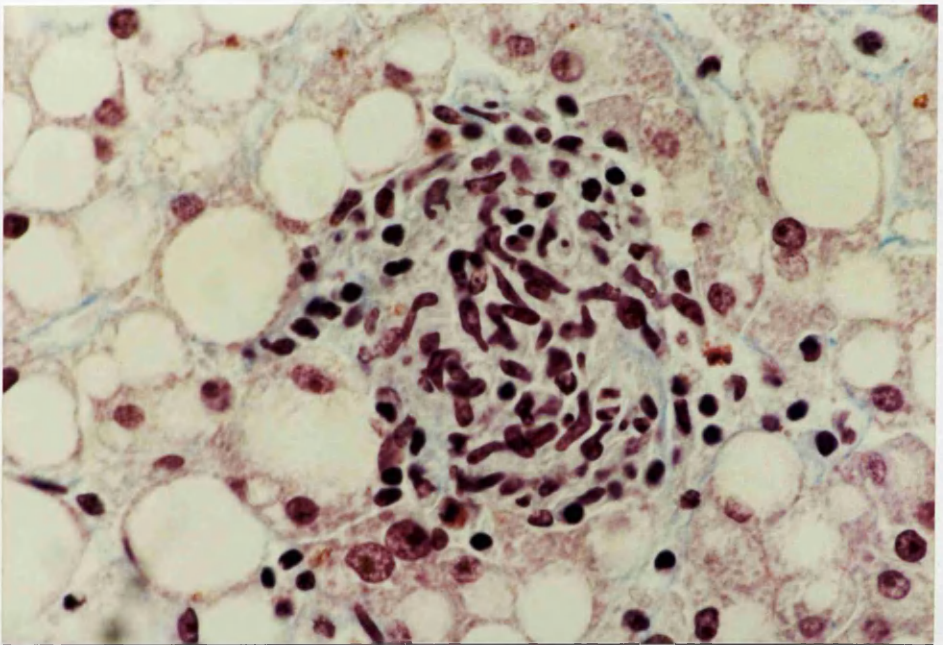
4f. Lipogranuloma - Type I (H. and E.; x 400)



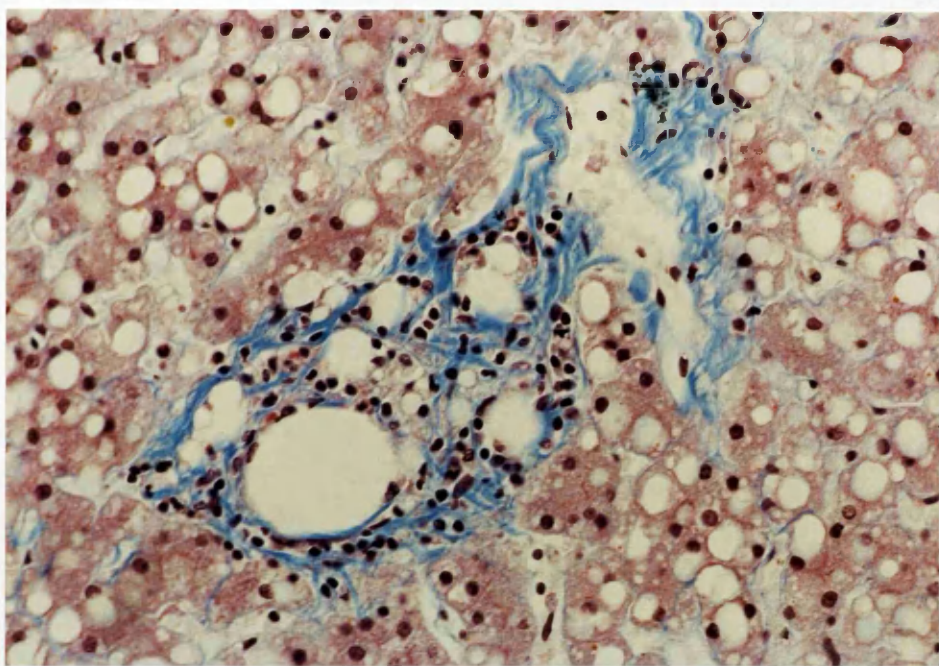
Idem. (M.S.B.; x 400)



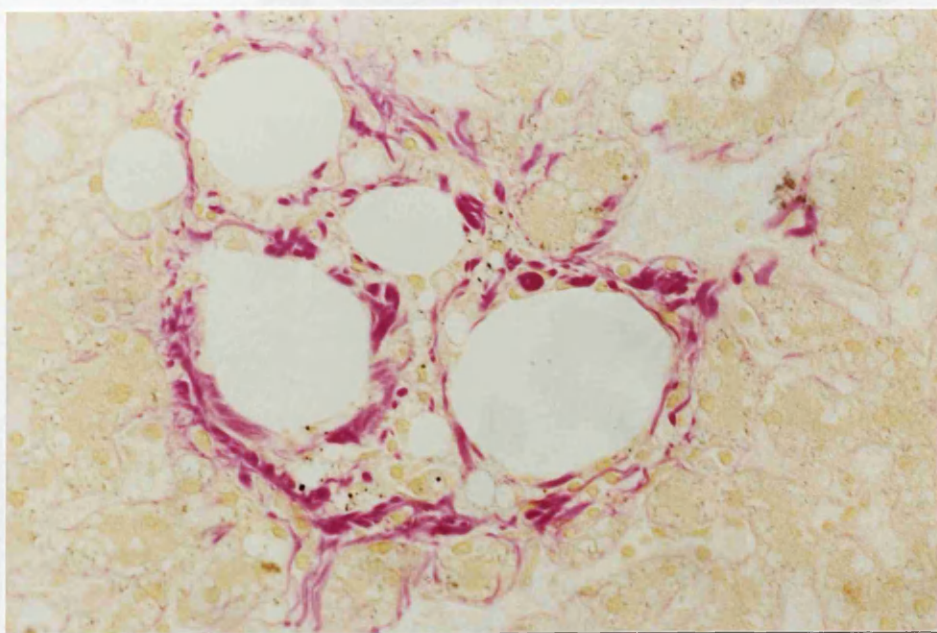
4g. Lipogranuloma - Type II (H. and E.; x 400)



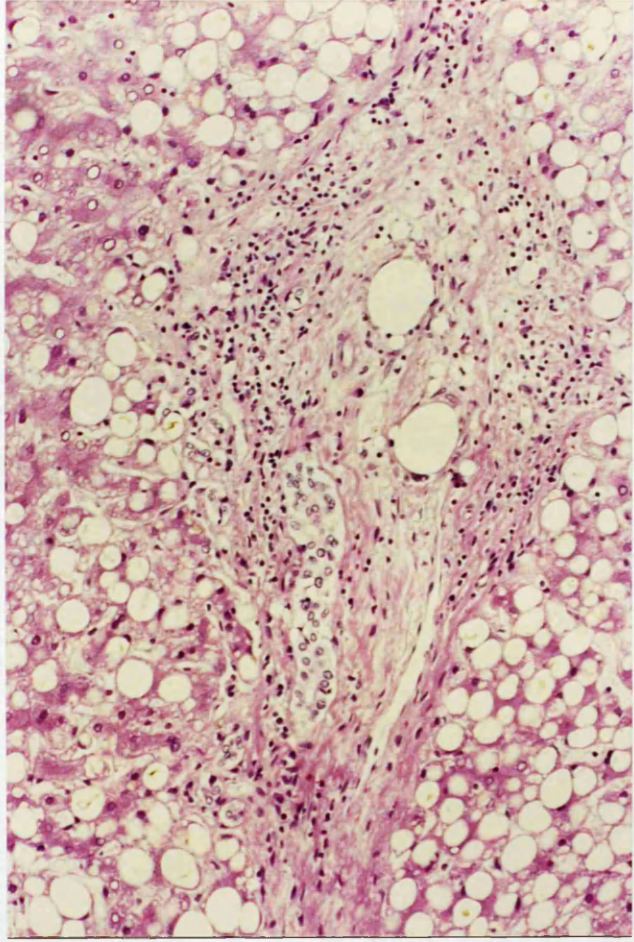
Idem. (M.S.B.; x 400)



4h. Lipogranuloma - Type III. (M.S.B.; x 100)



Idem. (Fouchet; x 400)



4i. Portal steatosis. A portal tract exhibits steatosis, bile duct proliferation and fibrosis.
(H. and E.; x 100)

TABLE 7.
DISTRIBUTION OF LIPOGRANULOMAS AMONG ALCOHOLICS AND CONTROLS
(A) Types of lipogranulomas

Lipogranuloma - Types	Controls	Chronic Alcoholics	Row Total
None	99 0.9	82 -0.9	181 90.5%
Type I	0 -1.2	3 1.2	3 1.5%
Type II	1 0.0	1 0.0	2 1.0%
Type III	0 -1.2	3 1.2	3 1.5%
Type I & II	0 -0.7	1 0.7	1 0.5%
Type II & III	0 -1.7	6 1.7	6 3.0%
Type I, II & III	0 -1.4	4 1.4	4 2.0%
Column Total	100 50.0%	100 50.0%	200 100.0%

(B) Number of lipogranulomas per section

Lipogranuloma - No./Section	Controls	Chronic Alcoholics	Row Total
0	99 0.9	82 -0.9	181 90.5%
1	0 -1.6	5 1.6	5 2.5%
2	1 -0.7	3 0.7	4 2.0%
3	0 -0.7	1 0.7	1 0.5%
4	0 -0.7	1 0.7	1 0.5%
5	0 -1.0	2 1.0	2 1.0%
7	0 -0.7	1 0.7	1 0.5%
9	0 -0.7	1 0.7	1 0.5%
10	0 -1.0	2 1.0	2 1.0%
12	0 -0.7	1 0.7	1 0.5%
21	0 -0.7	1 0.7	1 0.5%
Column Total	100 50.0%	100 50.0%	200 100.0%

Chi-Square

16.8072

Significance

4 x 10⁻⁵

4.5.2 PARENCHYMAL INFLAMMATION

The prominent inflammatory manifestation among both groups was that of lymphocytic infiltration. The alcoholics' inflammatory picture was significantly different from that of controls ($P < 2 \times 10^{-5}$). It was mostly minimal in degree and more frequently associated with some plasma cells (10 alcoholics; 1 control).

4.5.3 CHOLESTASIS

The incidence of cholestasis among alcoholics was significantly different from that of controls ($P < 1 \times 10^{-6}$). Different types of cholestasis have been recorded (Figure 5a-d) commonly in the form of Type IIA (Table 8). Cholestasis was always centrilobular. With increasing cholestasis mid-zones might also become involved. It was never perilobular in contrast to the perinodular cholestasis in cases of cirrhosis (Figure 5d). Two forms of bile thrombi have been encountered:

1. canalicular, occluding the bile canaliculi which were sometimes surrounded by liver cells in acinar or pseudoglandular patterns (Figure 5c), and,
2. hepatocellular as distinct; were round, ovoid, or irregular masses (Figure 5a and b).

There was no correlation between the degree of cholestasis (expressed as types) and that of steatosis; fibrosis; and siderosis.

TABLE 8.
DISTRIBUTION OF ALCOHOLICS AND CONTROLS BY TYPES OF CHOLESTASIS

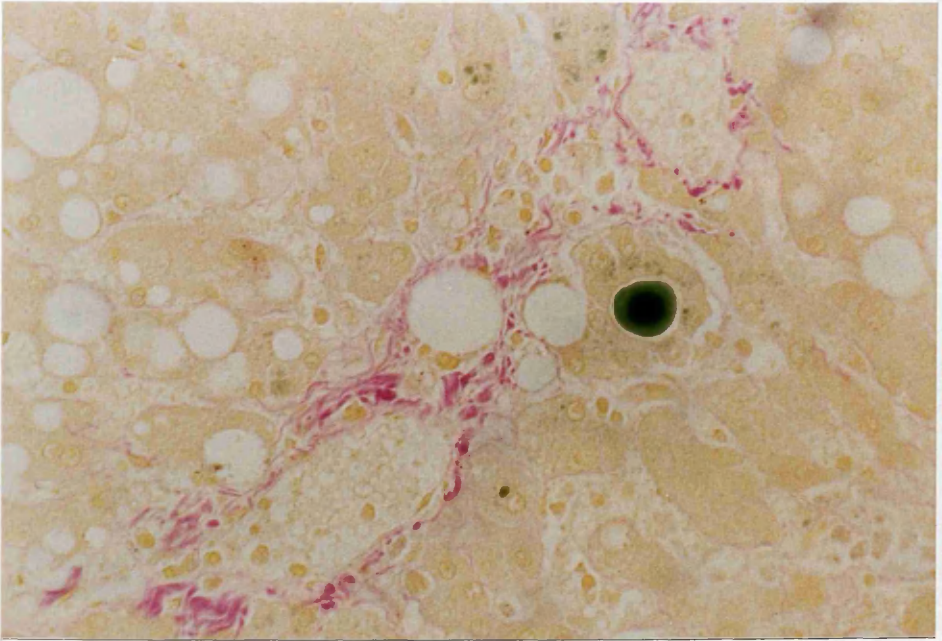
Cholestasis - Types	Controls	Chronic Alcoholics	Row Total
None	97 1.4	72 -1.4	169 84.5%
Type I	3 -0.7	6 0.7	9 4.5%
Type IIA	0 -2.6	14 2.6	14 7.0%
Type IIB	0 -1.9	7 1.9	7 3.5%
Type III	0 -0.7	1 0.7	1 0.5%
Column Total	100 50.0%	100 50.0%	200 100.0%

To avoid very small expected frequencies in chi-square testing, the row categories I, IIA, IIB and III of cholestasis had to be pooled.

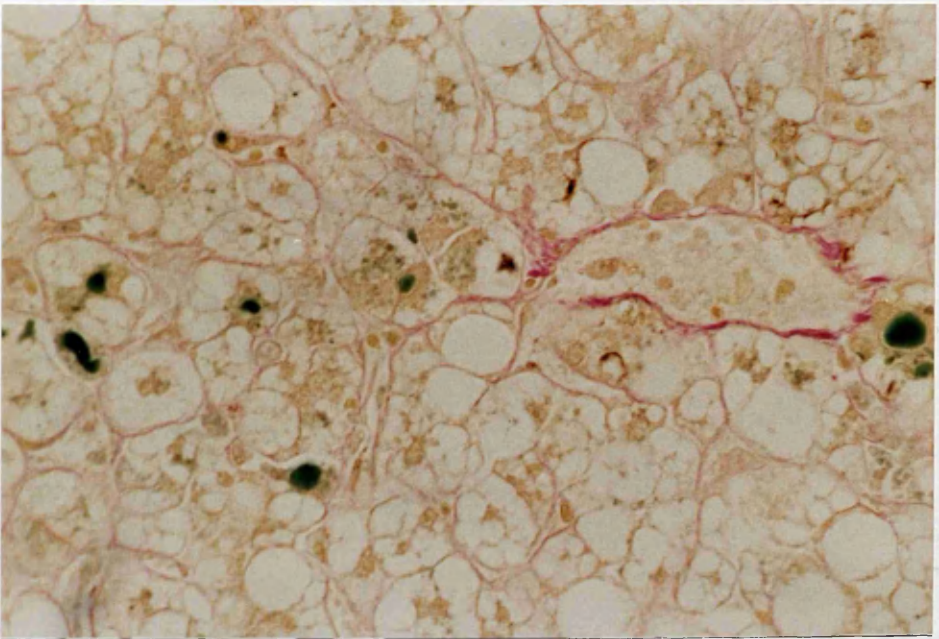
Chi-Square
23.8596

Significance
1 x 10⁻⁶

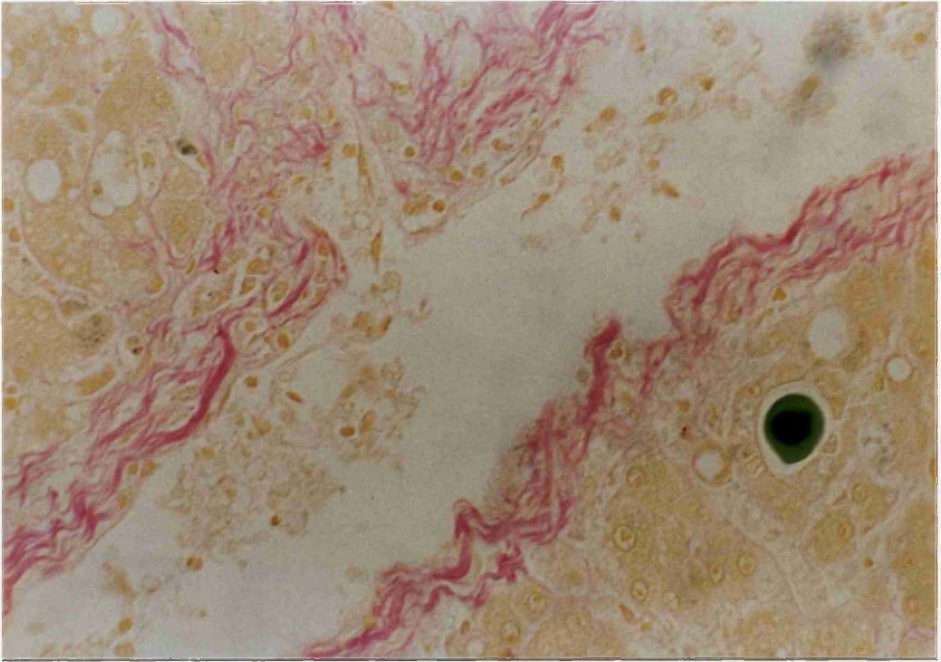
FIGURE 5: ALCOHOL-INDUCED CHOLESTASIS



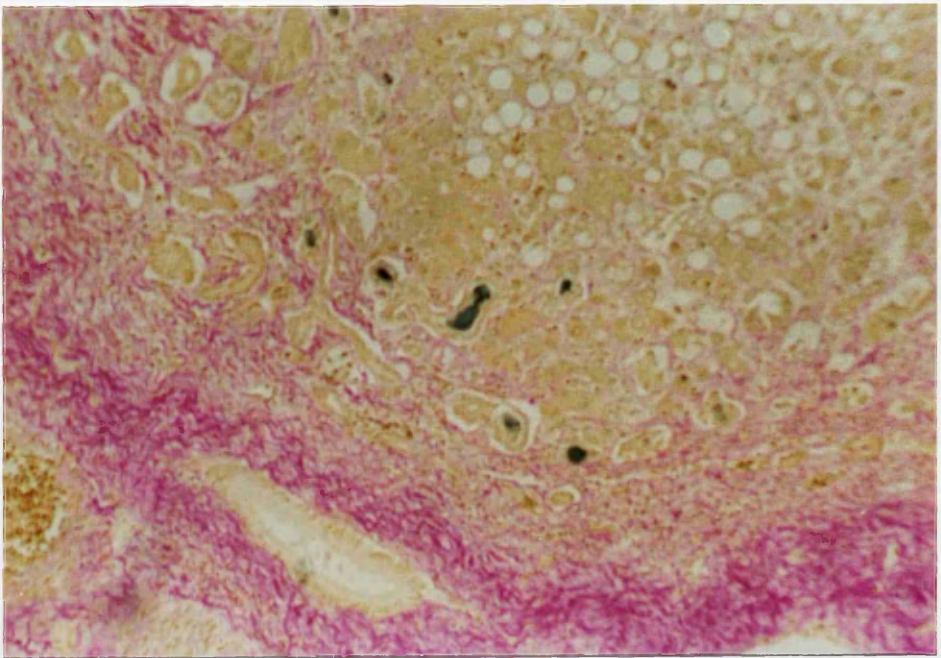
5a. Cholestasis - Type IIA (Fouchet: x 400)



5b. Cholestasis - Type IIB (Fouchet: x 400)



5c. Bile plug in dilated bile canaliculus, surrounded by liver cells in pseudoglandular pattern. (Fouchet: x 400)



5d. Alcoholic Cirrhosis. Bile stasis is present in liver cells and bile canaliculi in the periphery of nodule. (Fouchet; x 100)

4.5.4 FIBROSIS

In alcoholics, the frequency of all different patterns of fibrosis (Table 9A-F) was significantly different from that in controls, particularly Grade 0 terminal hepatic venule sclerosis, centrilobular pericellular fibrosis and septal fibrosis. The different histological forms of fibrosis (Figure 6-10) were shown to have no significant correlation with the degree of steatosis, cholestasis and siderosis. As far as the possible association between the different types of fibrosis is concerned, there was no significant association with portal fibrosis, nor stress fissures. The association was significant between THVS, perisinusoidal fibrosis (more than Grade 1) and centrilobular pericellular, but not with septal fibrosis. The association between perisinusoidal and centrilobular pericellular fibrosis was highly significant, ($P < 0.001$). It was greater than either with THVS (perisinusoidal fibrosis [$P = 0.0062$]; centrilobular pericellular fibrosis [$P = 0.0093$]).

TABLE 9.
FREQUENCY OF PATTERNS OF FIBROSIS AMONG ALCOHOLICS AND CONTROLS

(A) Terminal Hepatic Venule Sclerosis (THVS)

T H V S	Controls	Chronic Alcoholics	Row Total
0	13 2.5	0 -2.5	13 6.5%
1	84 -0.1	86 0.1	170 85.0%
2	2 -1.9	12 1.9	14 7.0%
3	1 -0.4	2 0.4	3 1.5%
Column Total	100 50.0%	100 50.0%	200 100.0%

To avoid very small expected frequencies in chi-square testing, the row categories 2 and 3 of THVS had to be pooled.

Chi-Square

20.1412

Significance

4 x 10⁻⁵

(B) Centrilobular Pericellular Fibrosis

Centrilobular Pericellular Fibrosis	Controls	Chronic Alcoholics	Row Total
0	100 3.2	46 -3.2	146 73.0%
1	0 -3.7	27 3.7	27 13.5%
2	0 -3.3	22 3.3	22 11.0%
3	0 -1.6	5 1.6	5 2.5%
Column Total	100 50.0%	100 50.0%	200 100.0%

To avoid very small expected frequencies in chi-square testing, the row categories 2 and 3 of centrilobular pericellular fibrosis had to be pooled.

Chi-Square

73.9727

Significance

8 x 10⁻¹⁷

(C) Perisinusoidal Fibrosis

Perisinusoidal Fibrosis	Controls	Chronic Alcoholics	Row Total
1	93 1.1	73 -1.1	166 83.0%
2	7 -2.0	22 2.0	29 14.5%
3	0 -1.6	5 1.6	5 2.5%
Column Total	100 50.0%	100 50.0%	200 100.0%

To avoid very small expected frequencies in chi-square testing, the row categories 2 and 3 of perisinusoidal fibrosis had to be pooled.

Chi-Square

14.1743

Significance

1×10^{-4}

(D) Septal Fibrosis

Septal Fibrosis	Controls	Chronic Alcoholics	Row Total
Absent	100 1.1	79 -1.1	179 89.5%
Present	0 -3.2	21 3.2	
Column Total	100 50.0%	100 50.0%	200 100.0%

Chi-Square

21.28226
23.46369

Significance

0.0001
0.0001

(E) Stress Fissures

Stress Fissures	Controls	Chronic Alcoholics	Row Total
Absent	100 0.4	92 -0.4	192 96.0%
Present	0 -2.0	8 2.0	8 4.0%
Column Total	100 50.0%	100 50.0%	200 100.0%

Chi-Square

6.38021

8.33333

Significance

0.0115

0.0039

(F) Portal Fibrosis

Portal Fibrosis	Controls	Chronic Alcoholics	Row Total
0	54 1.7	32 -1.7	86 43.0%
1	35 -0.6	42 0.6	77 38.5%
2	9 -0.3	11 0.3	20 10.0%
3	2 -2.0	13 2.0	15 7.5%
4	0 -1.0	2 1.0	2 1.0%
Column Total	100 50.0%	100 50.0%	200 100.0%

To avoid very small expected frequencies in chi-square testing, the row categories 3 and 4 of portal fibrosis had to be pooled.

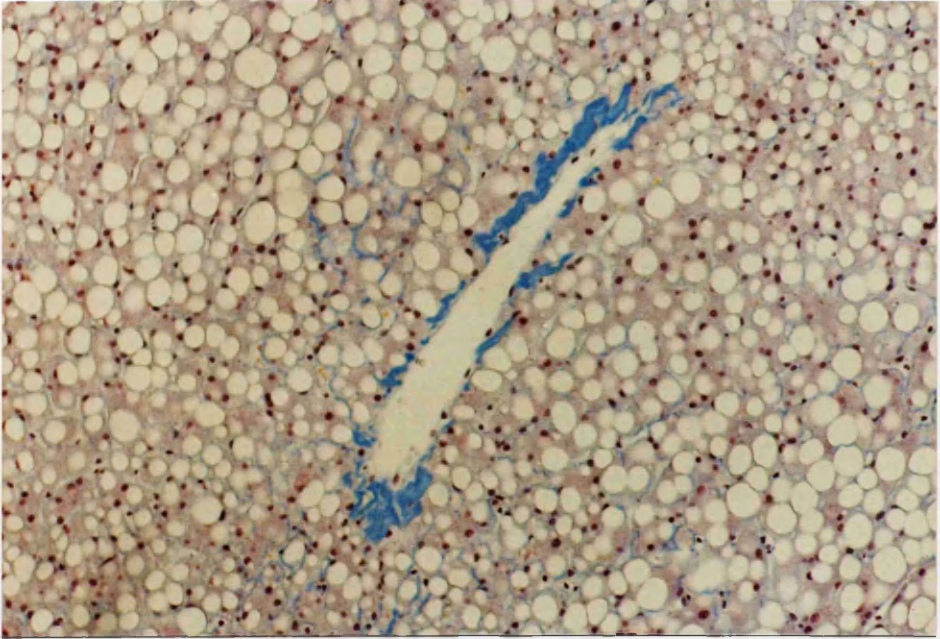
Chi-Square

16.4055

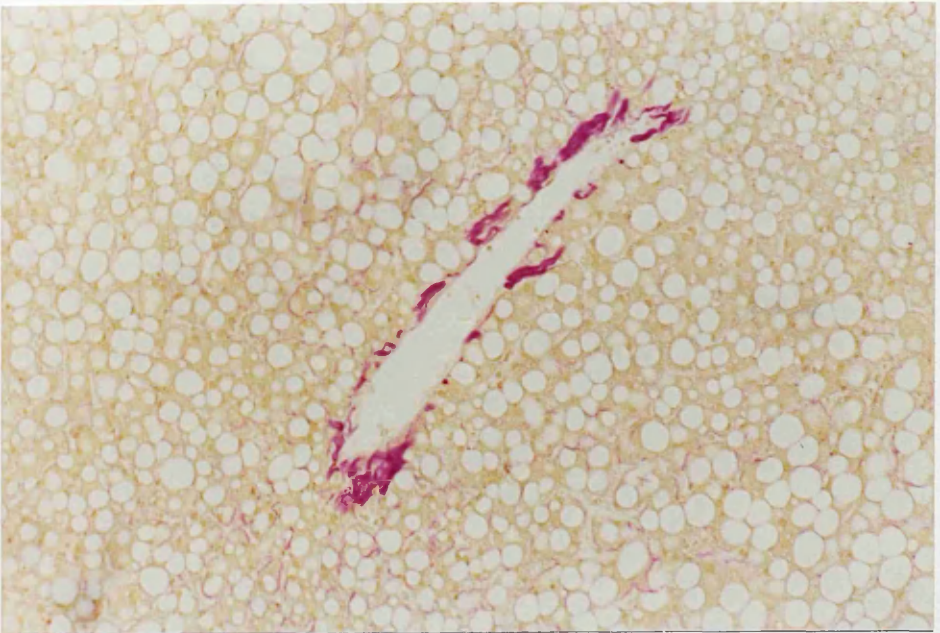Significance

9 x 10⁻⁴

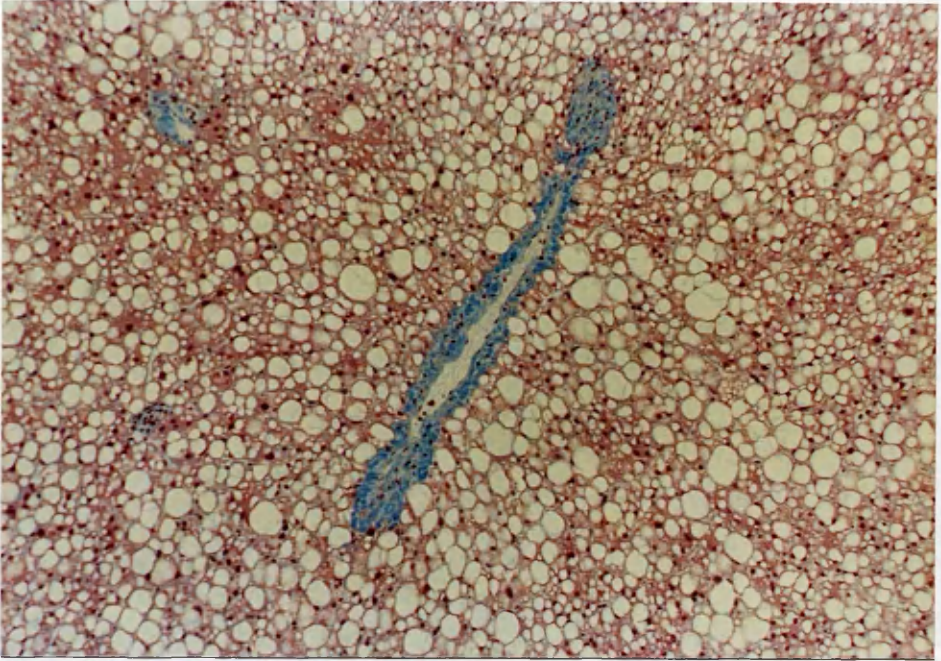
FIGURE 6. TERMINAL HEPATIC VENULE SCLEROSIS



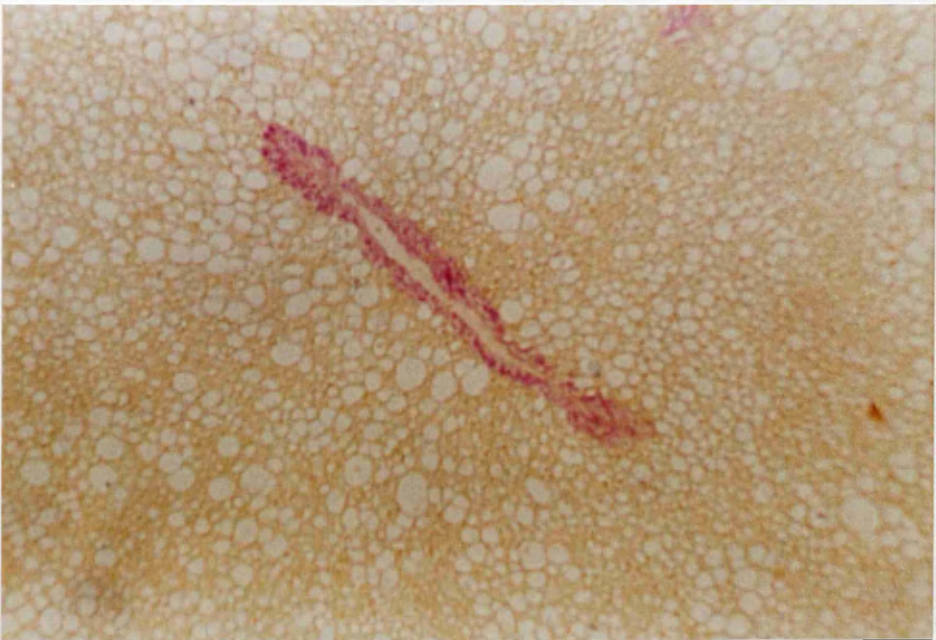6a. THVS-Grade 1. Thin, non-uniform, patchy rim of fibrosis. Note also the mild thickening of sinusoidal walls. (M.S.B; x 100)



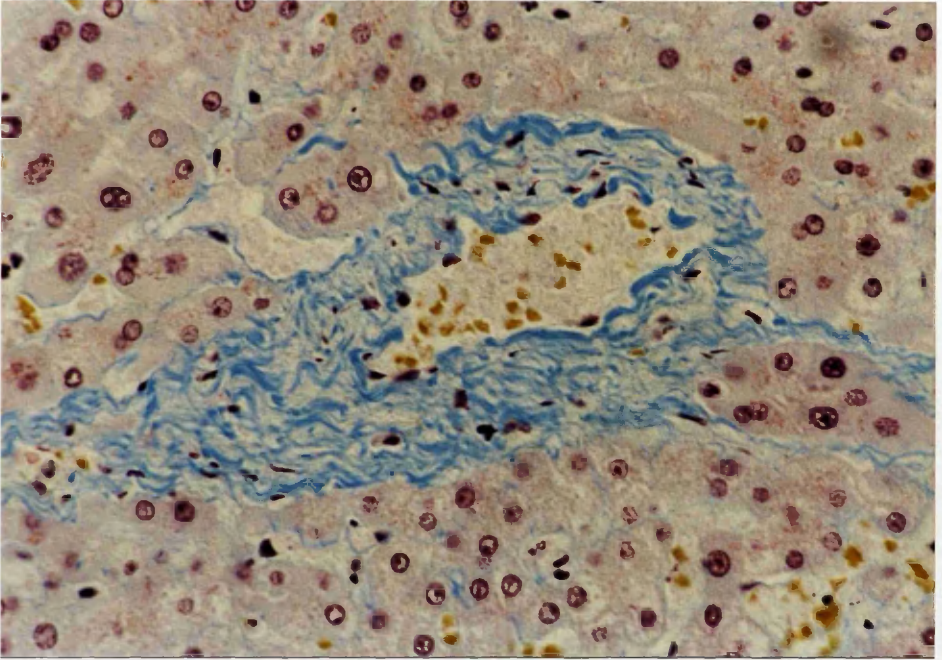
Idem. (Fouchet; x 100)



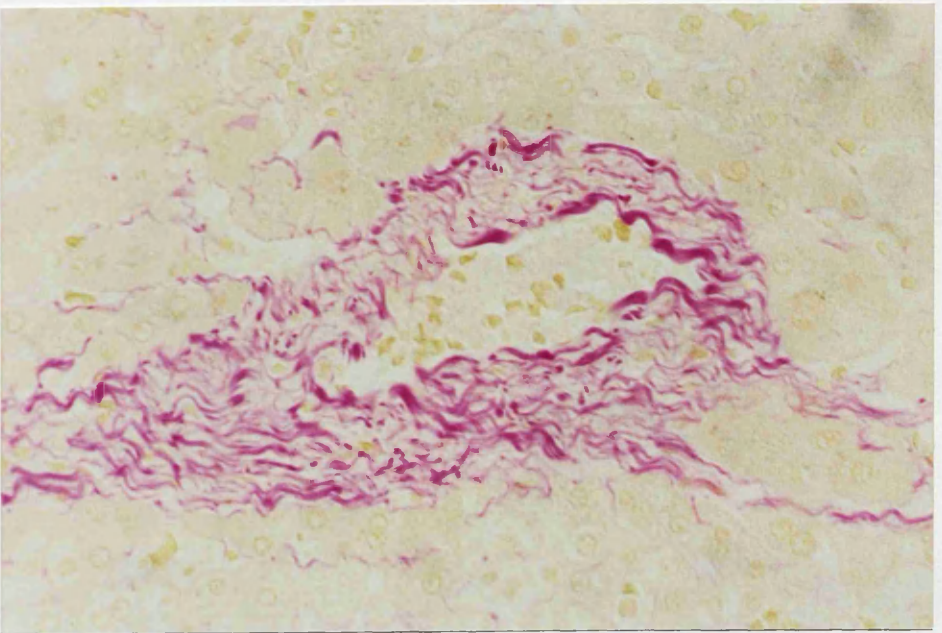
6b. THVS-Grade 2. Thin, uniform rim of fibrosis.
(M.S.B; x 100)



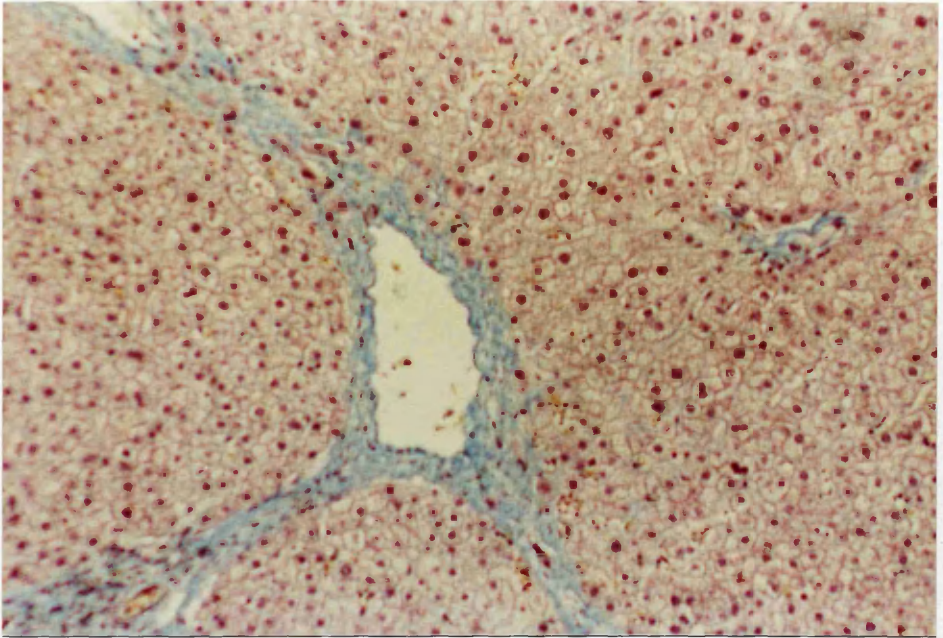
Idem. (Fouchet; x 100)



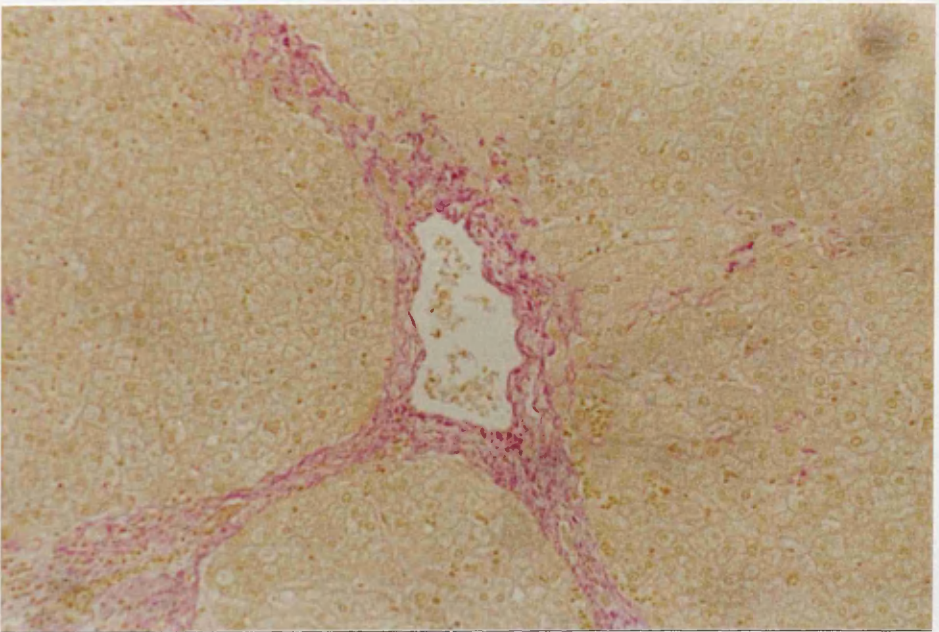
6c. THVS-Grade 3. Thick, uniform, laminated collar of fibrosis. (M.S.B; x 400)



Idem. (Fouchet; x 400)

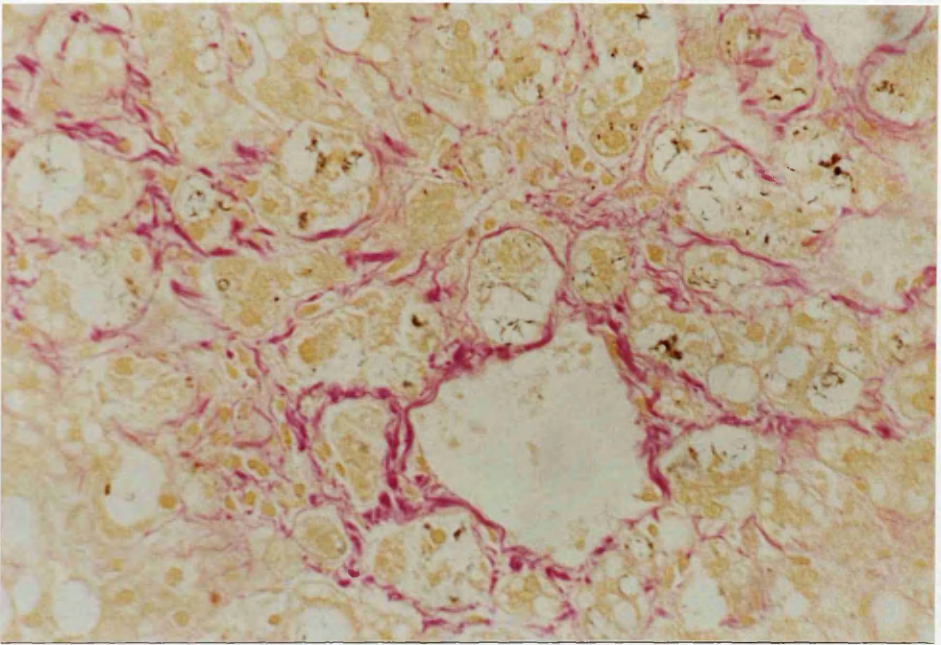


6d. THVS-Grade 4. Thick collar plus septa connecting adjacent central and/or portal zones. (M.S.B; x 100)

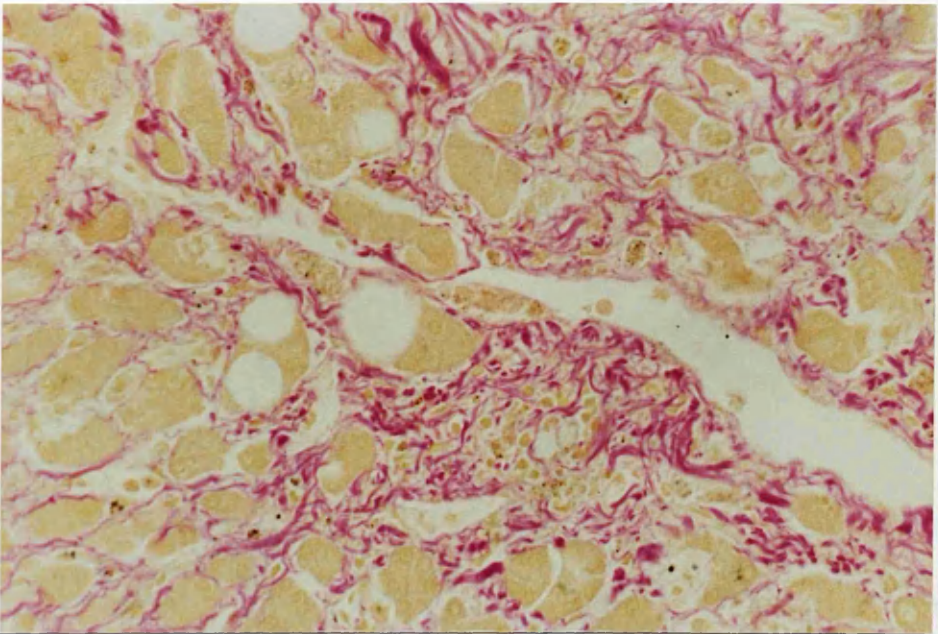


Idem. (Fouchet; x 100)

FIGURE 7. CENTRILOBULAR PERICELLULAR FIBROSIS

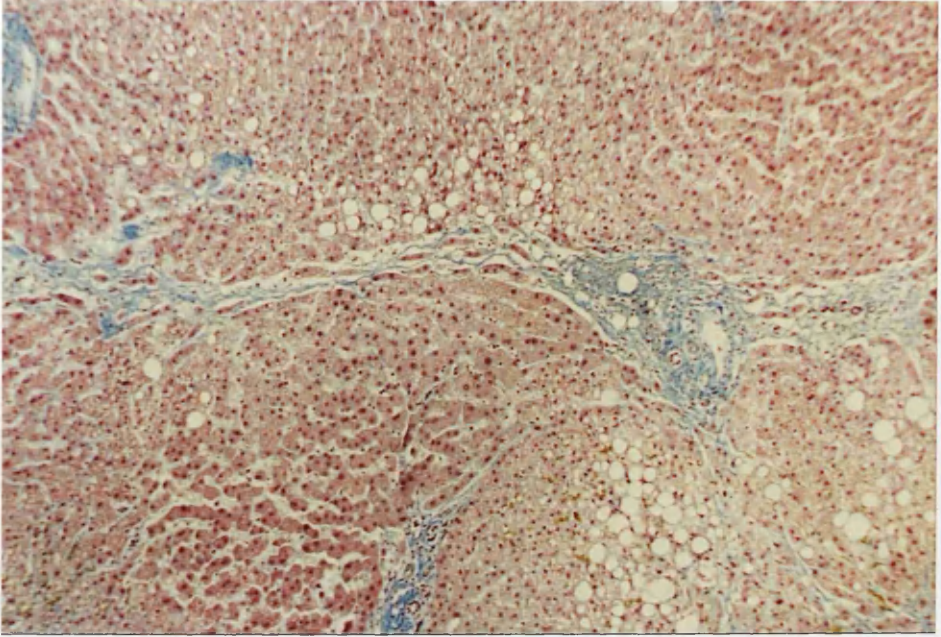


7a. Moderately thick centrilobular pericellular fibrosis, ensnaring small clusters of hepatocytes. (Fouchet; x 400)

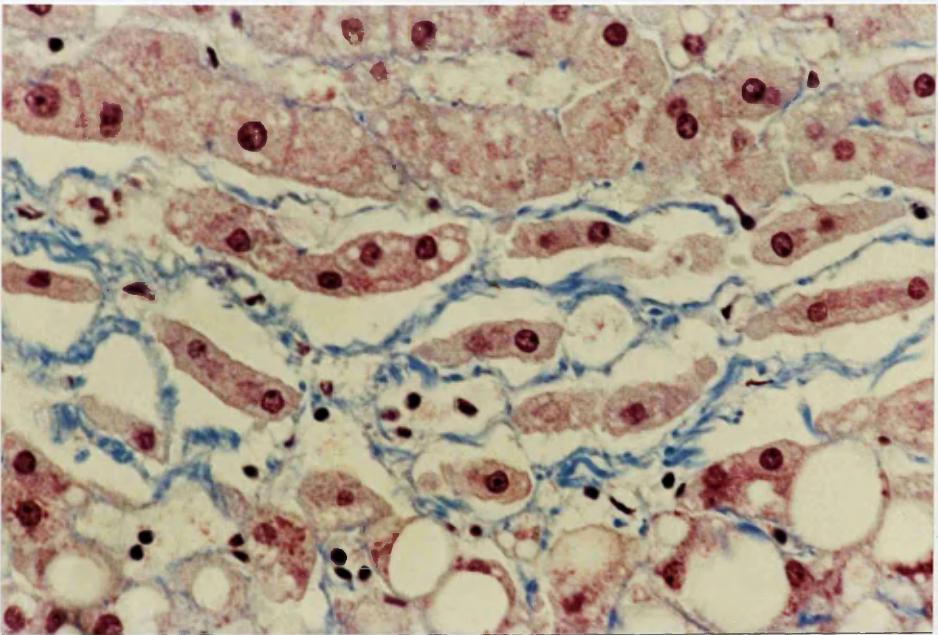


7b. Thick centrilobular pericellular fibrosis enveloping individual cells or small groups of hepatocytes. (Fouchet; x 400)

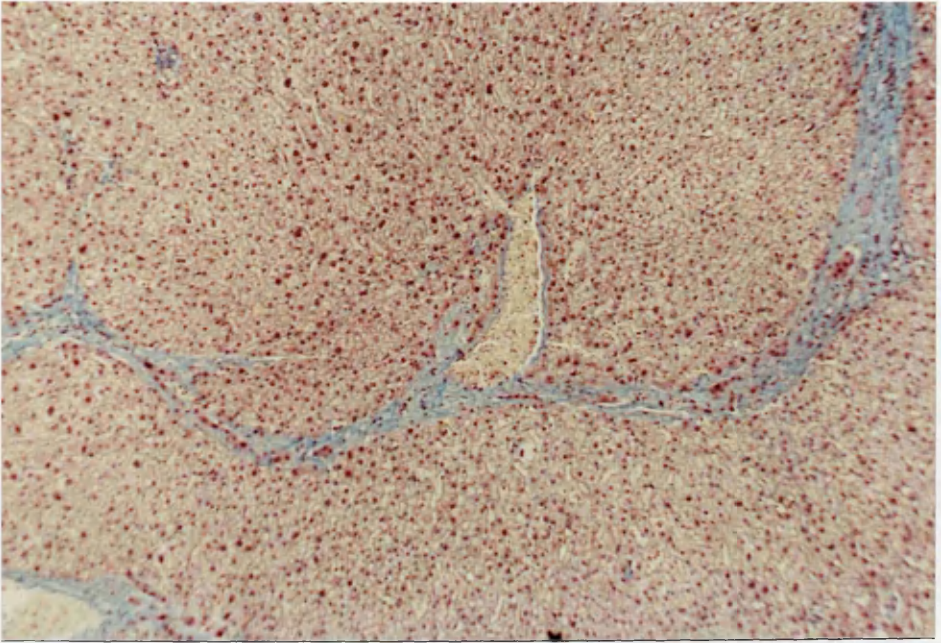
FIGURE 8. SEPTAL FIBROSIS



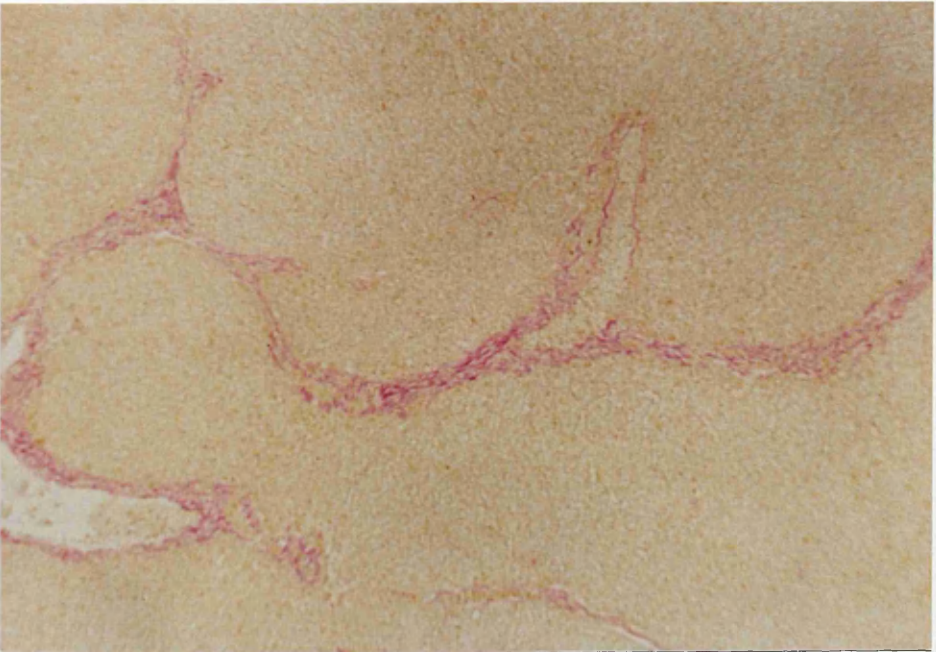
8a. A slightly curved early septum is seen connecting central field with portal tract. (M.S.B.; x 100)



Idem. (M.S.B.; x 400)

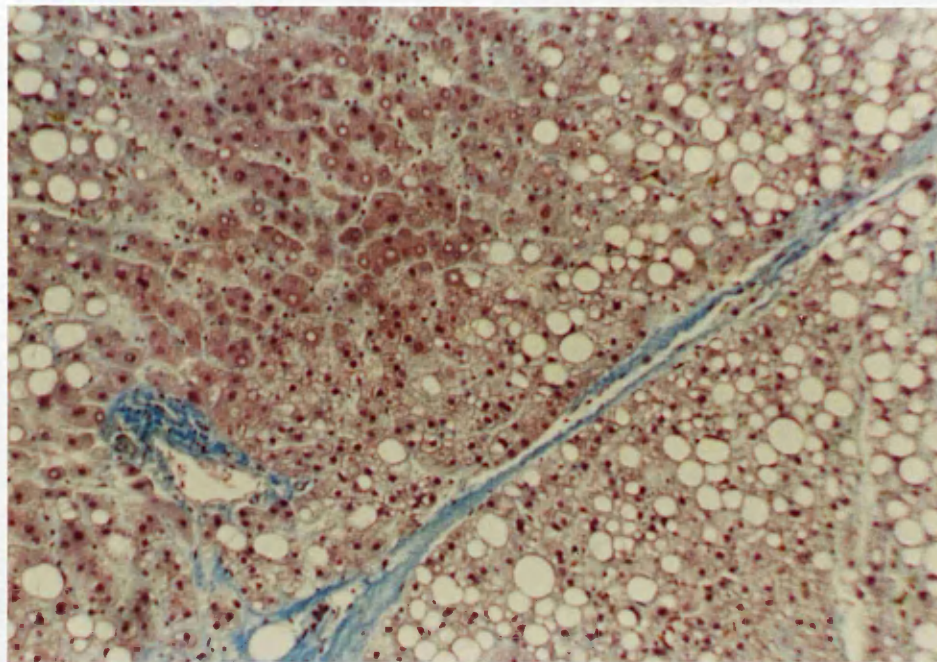


8b. Septa traversing the parenchyma, linking central vein (centre) with another central vein (left) and portal tract (right). (M.S.B.; x 100)

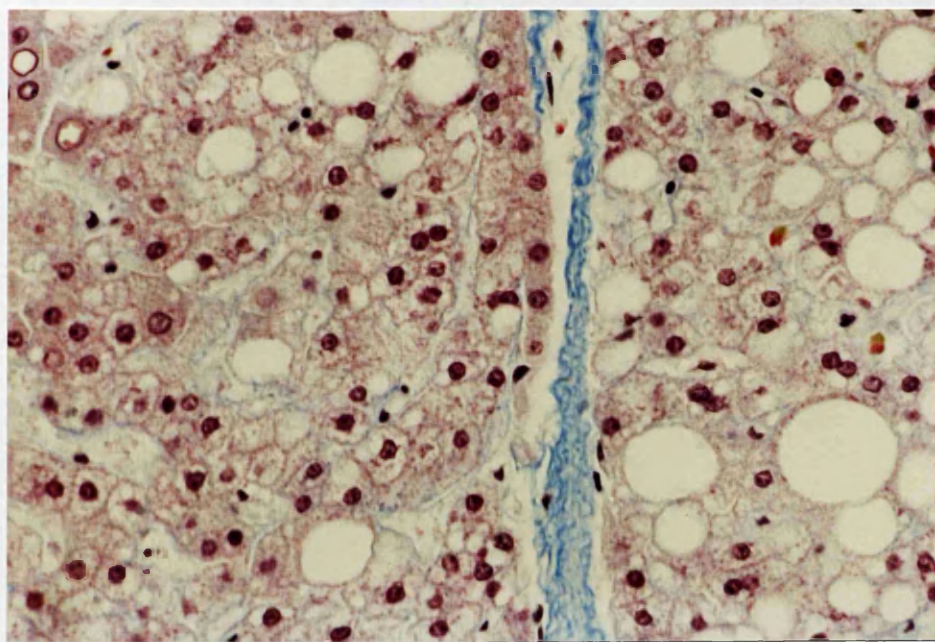


Idem. (Fouchet; x 100)

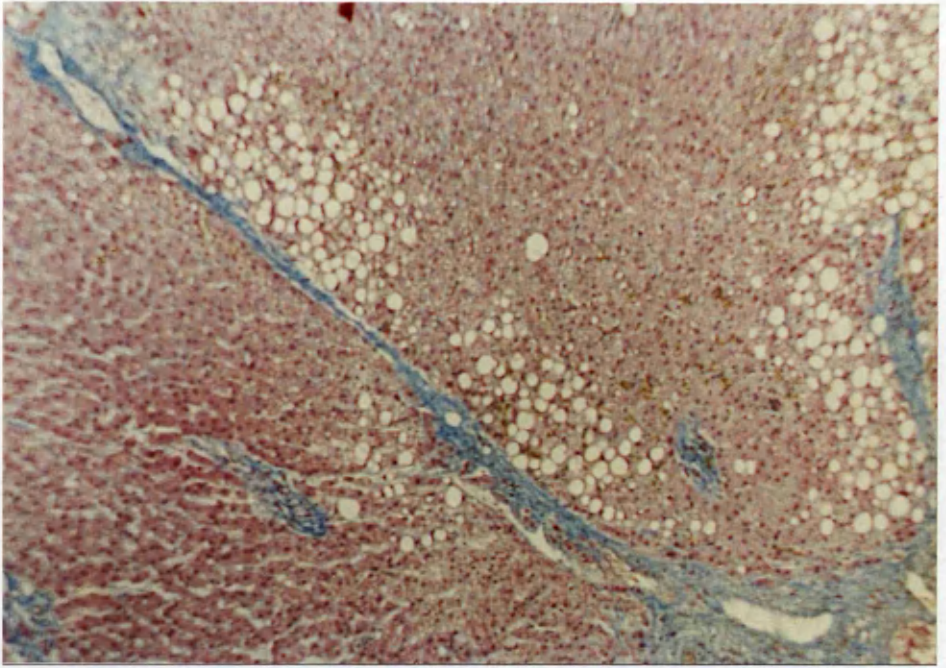
FIGURE 9 STRESS FISSURES



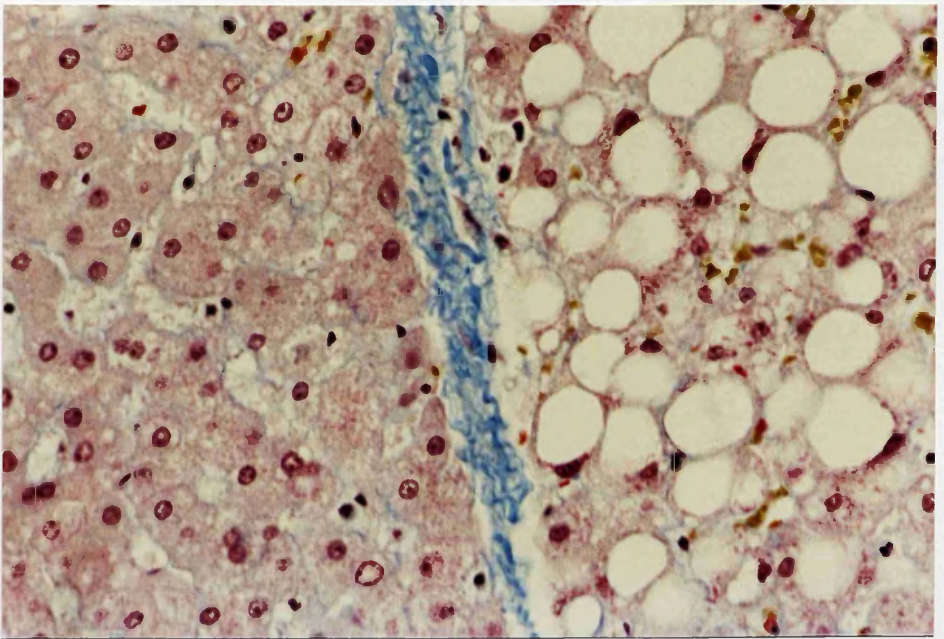
9a. Beginning deposition of collagenous fibres in fissure separating territories of different fat content. (M.S.B.; x 100)



Idem. (M.S.B.; x 400)

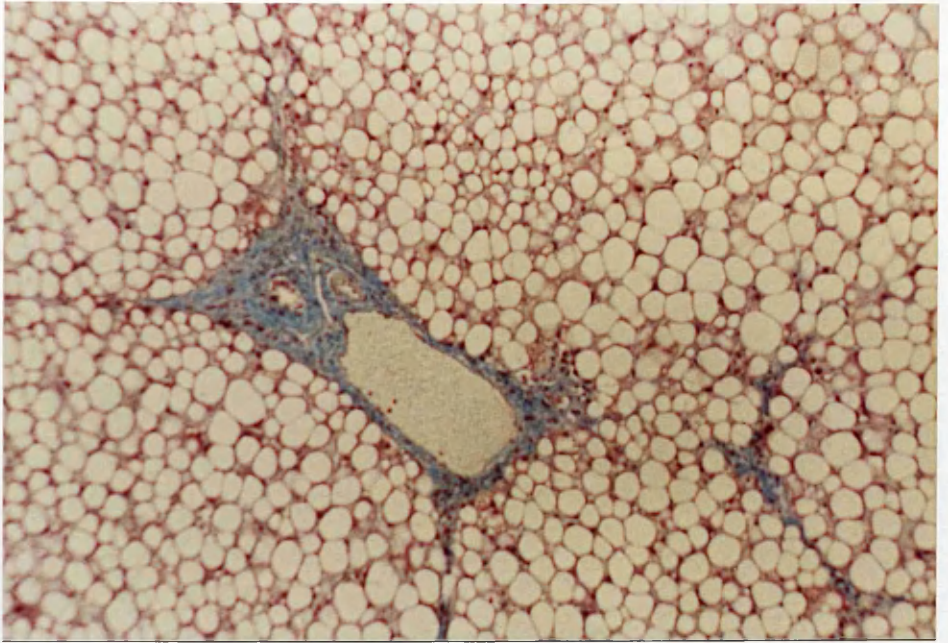


9b. Completed straight septum formed in stress fissure separating unevenly expanded lobular territories. (M.S.B.; x 100)

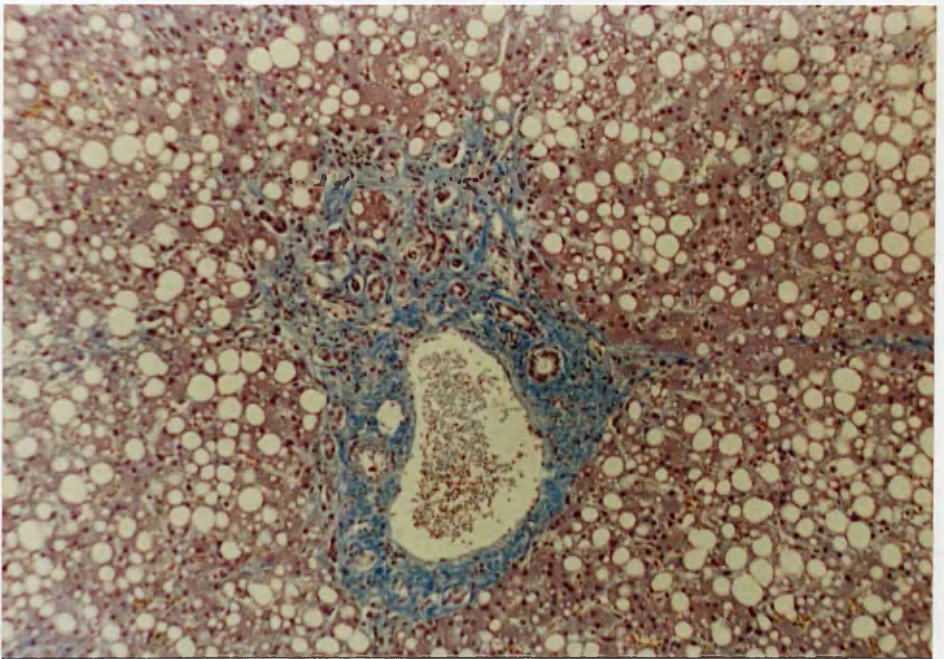


Idem. (M.S.B.; x 400)

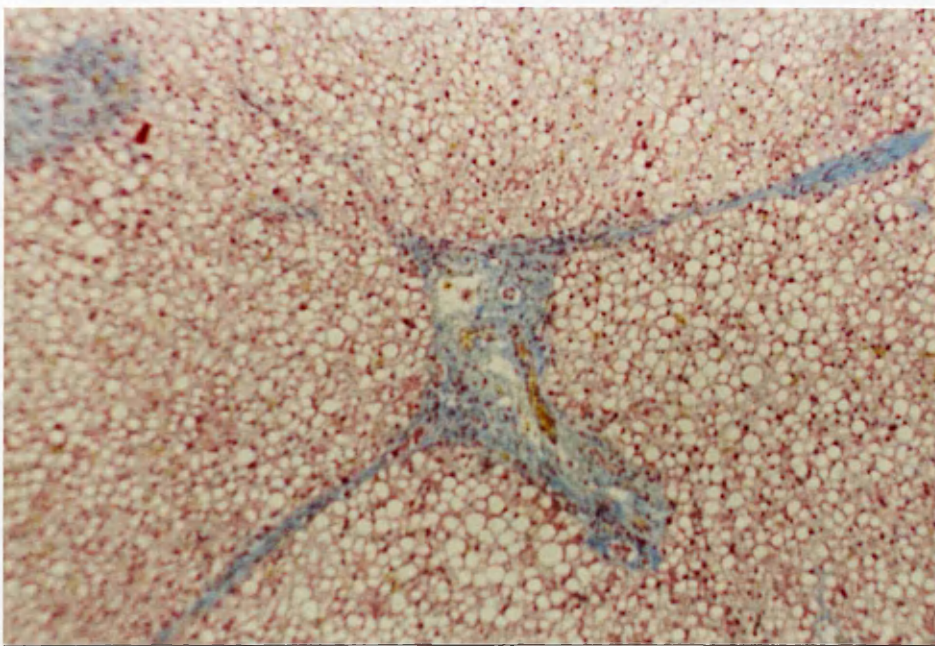
FIGURE 10 PORTAL FIBROSIS



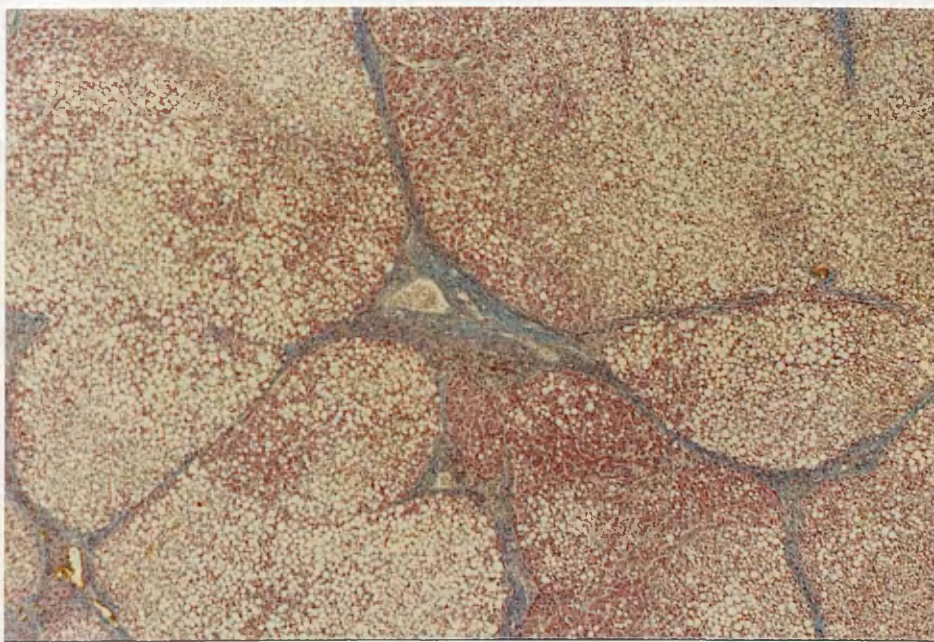
10a. Portal Fibrosis - Grade 1. (M.S.B.; x 100)



10b. Portal Fibrosis - Grade 2 (M.S.B.; x 100)



10c. Portal Fibrosis - Grade 3. (M.S.B.; x 40)



10d. Portal Fibrosis - Grade 4 (M.S.B.; x 40)

4.5.5 SIDEROSIS

The incidence and degree of hepatic siderosis are shown in Table 10A-C and Figure 11. The overall incidence of siderosis among alcoholics was significantly different from that of controls, especially in Grade 3 liver cell-siderosis, Kupffer cell-iron overload, and portal tract connective tissue deposition of haemosiderin. The incidence of Grade 3 siderosis in alcoholics was 21%.

The different types and grades of hepatic siderosis were recorded in Figure 12a-f which showed at the same time the characteristic lobular, intracellular and portal distribution of the intense prussian blue haemosiderin granules. The periportal zone was the elective site of haemosiderin-containing liver cells, in contrast to Kupffer cell siderosis which was irregularly distributed throughout the lobule without any zonal predilection. Within liver cells haemosiderin granules took a pericanalicular location and appeared in the centre of the liver cell plates. In portal tracts it appeared to be confined to the connective tissue and none was demonstrated in bile duct epithelium. No significant correlation has been recorded between the degree of hepatic siderosis and that of steatosis; cholestasis and fibrosis.

TABLE 10.

DISTRIBUTION OF THE ALCOHOLICS AND CONTROLS AS TO THE GRADE OF HISTOCHEMICALLY DEMONSTRABLE HEPATIC IRON

(A) Stainable Iron in Liver Cells.

Stainable iron in Liver Cells	Controls	Chronic Alcoholics	Row Total
0	88 1.8	58 -1.8	146 73.0%
Trace	0 -1.2	3 1.2	3 1.5%
1	3 -0.9	7 0.9	10 5.0%
2	7 -0.7	11 0.7	18 9.0%
3	2 -2.8	21 2.8	23 11.5%
Column Total	100 50.0%	100 50.0%	200 100.0%

To avoid very small expected frequencies in chi-square testing, the row categories Trace and 1 had to be pooled.

Chi-Square

26.5182

Significance

7 x 10⁻⁶

(B) Stainable Iron in Kupffer cells.

Stainable iron in Kupffer Cells	Controls	Chronic Alcoholics	Row Total
0	100 1.1	80 -1.1	180 90.0%
Trace	0 -1.2	3 1.2	3 1.5%
1	0 -2.3	11 2.3	11 5.5%
2	0 -1.6	5 1.6	5 2.5%
3	0 -0.7	1 0.7	1 0.5%
Column Total	100 50.0%	100 50.0%	200 100.0%

To avoid very small expected frequencies in chi-square testing, the row categories Trace to 3 had to be pooled.

Chi-Square

22.2222

Significance

2×10^{-6}

(C) Stainable Iron in Portal Tracts.

Stainable iron in Portal Tracts	Controls	Chronic Alcoholics	Row Total
0	100 0.8	85 -0.8	185 92.5%
Minimal	0 -2.1	9 2.1	9 4.5%
Mild	0 -0.7	1 0.7	1 0.5%
Moderate	0 -1.6	5 1.6	5 2.5%
Column Total	100 50.0%	100 50.0%	200 100.0%

To avoid very small expected frequencies in chi-square testing, the row categories Minimal to Moderate had to be pooled.

Chi-Square

16.2164

Significance

5×10^{-5}

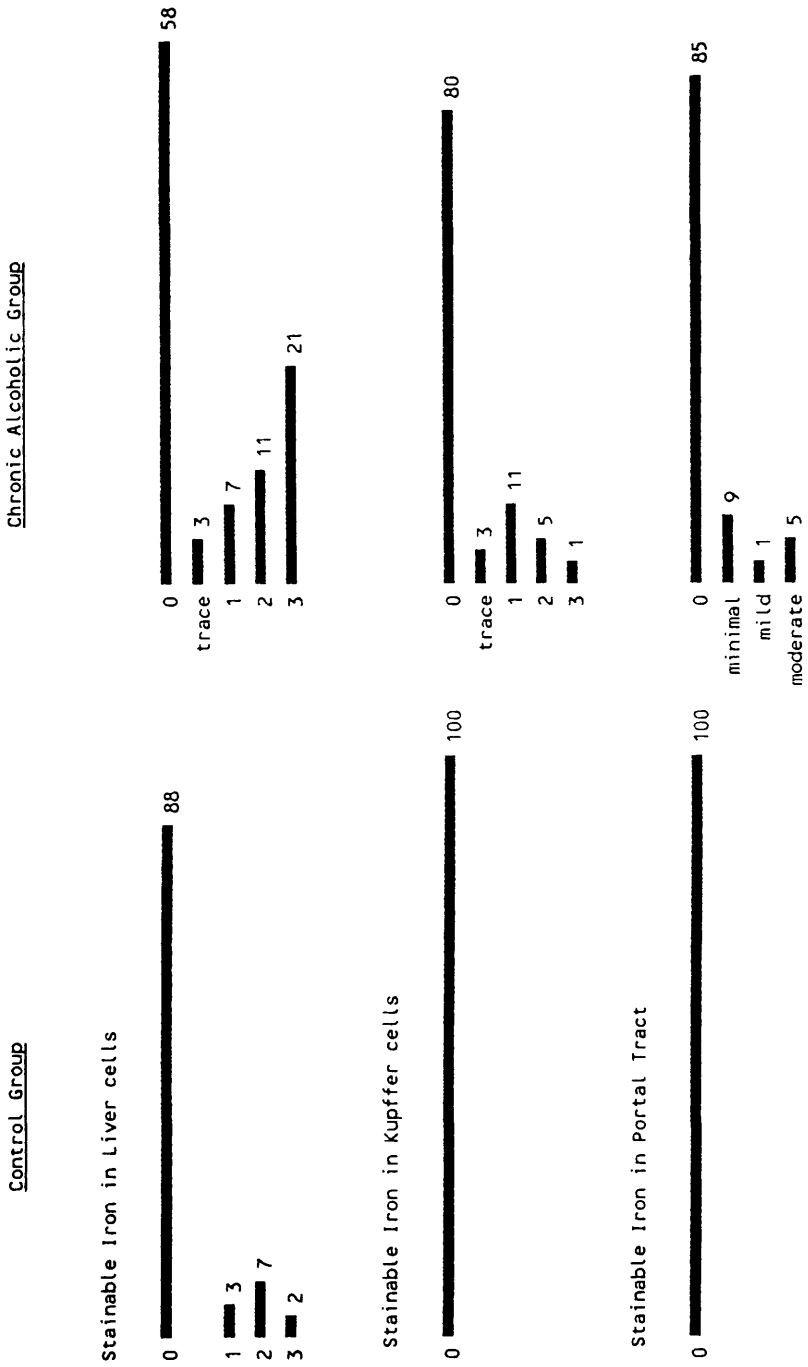
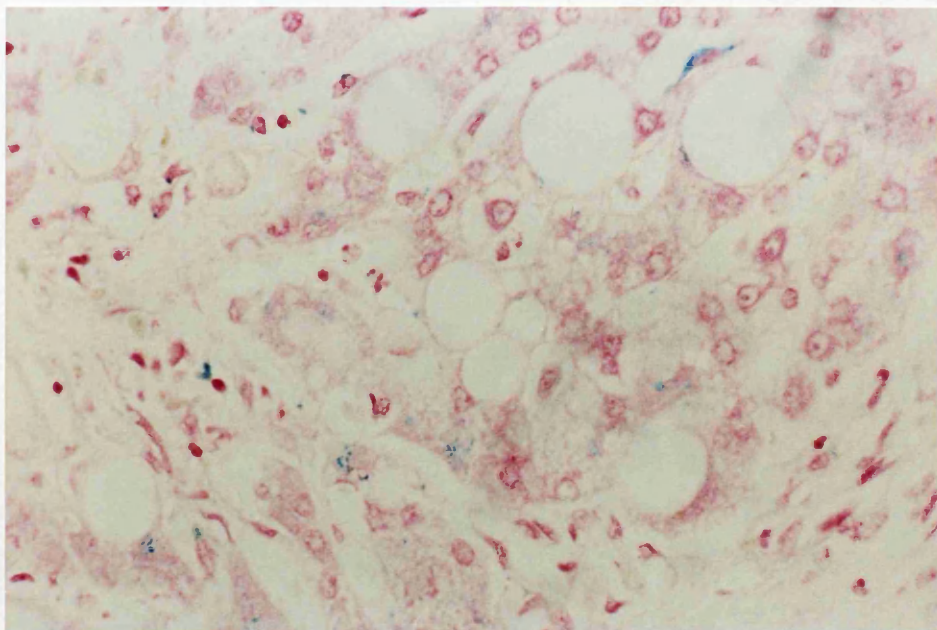
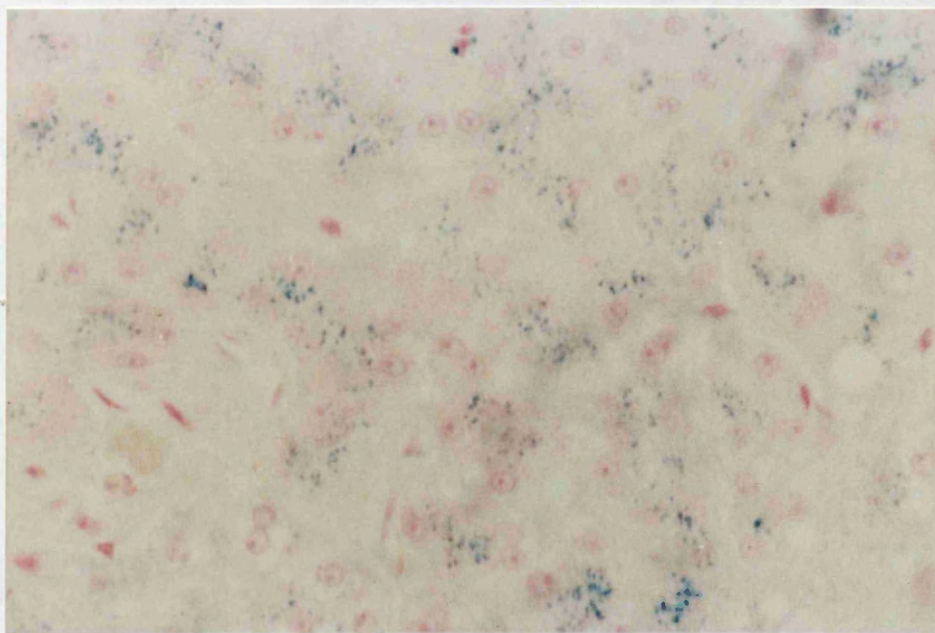


FIGURE 11. HEPATIC SIDEROSIS IN ALCOHOLICS AND CONTROLS

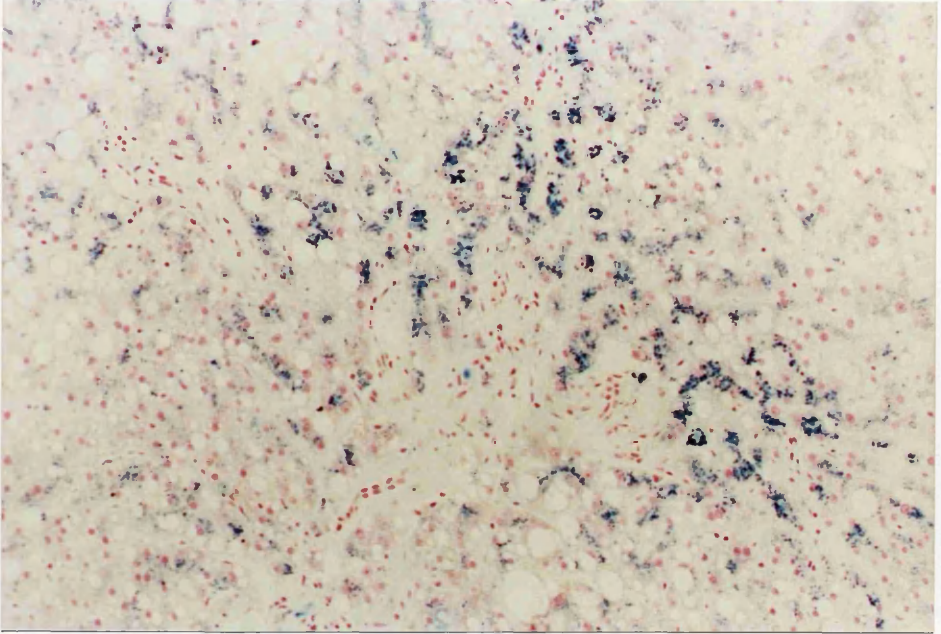
FIGURE 12 HEPATIC SIDEROSIS



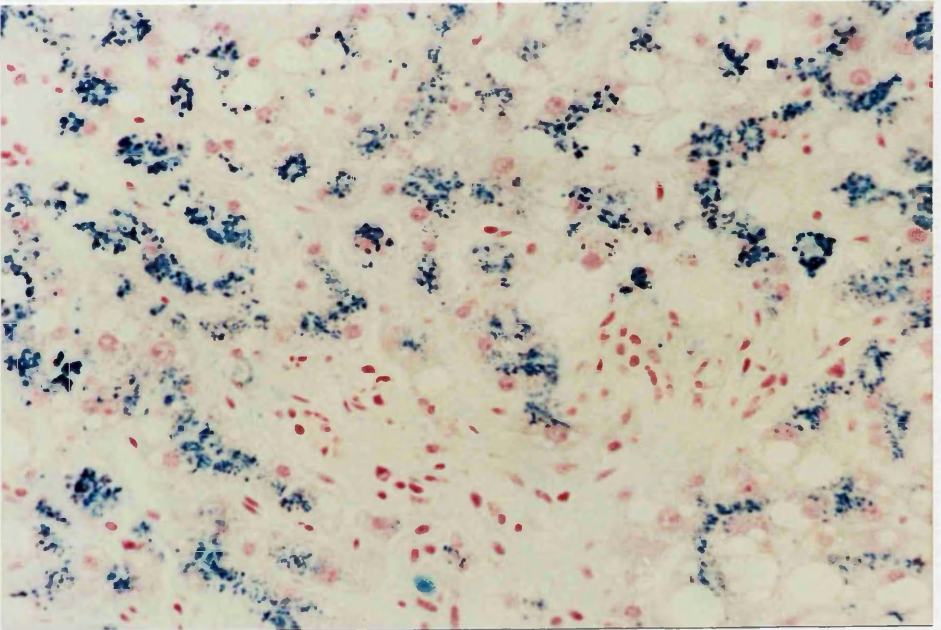
12.a Liver with Grade 1 iron in liver epithelium
and Kupffer cells (Perl's stains; x 400)



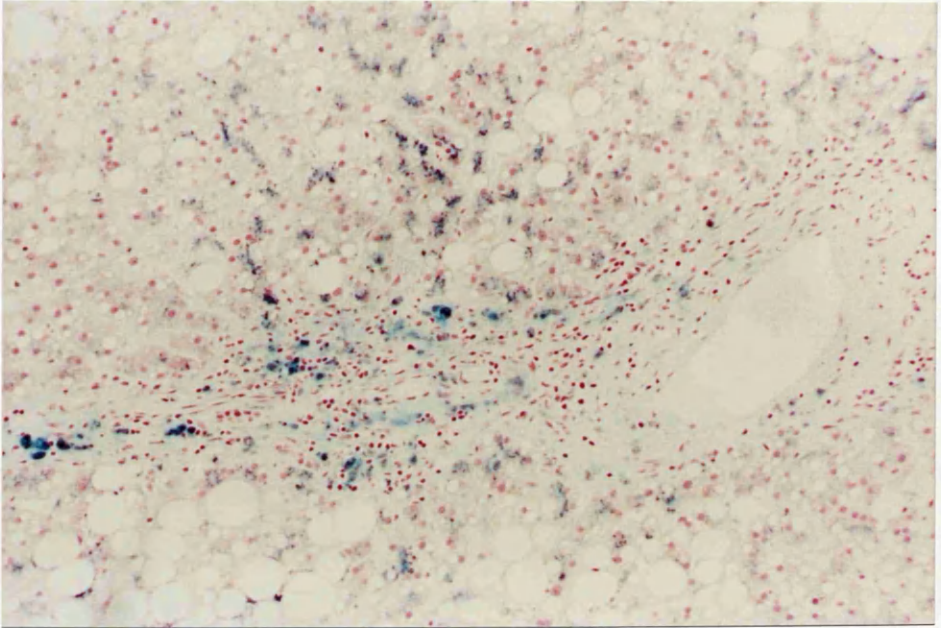
12.b Liver with Grade 2 iron. (Perl's stain; x 400)



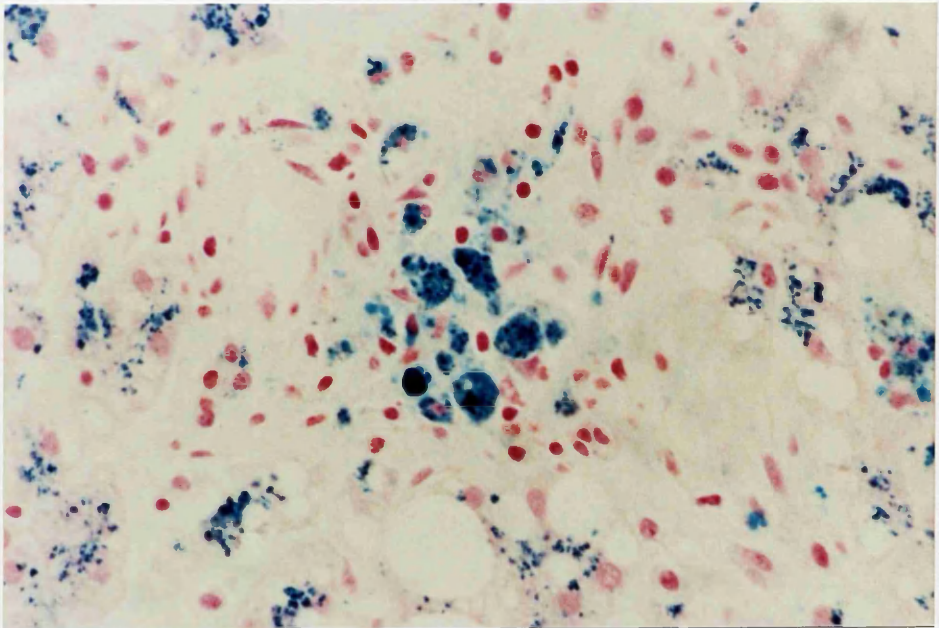
12.c Liver with Grade 3 iron. (Perl's stain; x 100)



12.d Haemosiderin granules are prominent at the biliary poles of the liver cells. (Perl's stain; x 400)



12.e Portal Tract Siderosis. (Perl's stain; x 100)



12.f Portal Tract displays haemosiderin granules in connective tissue and macrophages. (Perl's stain; x 400)

4.5.6 COPPER; MEGAMITOCHONDRIA; IMMUNOGLOBULIN-A and GLYCOGEN

Histochemically stainable intrahepatocytic copper granules, as demonstrated in one of our positive controls of alcoholic cirrhosis, Figure 13, were not recorded in any of our fatty liver series or controls. Nothing positive has also been recorded with respect to giant mitochondria and immunoglobulin-A in both test and control groups.

Apart from the complete absence of glycogen deposits in liver cells of PAS/stained sections in most cases, only traces were demonstrated in some cases, in an incidence which was comparable in both alcoholics and controls (8 controls: 10 alcoholics).

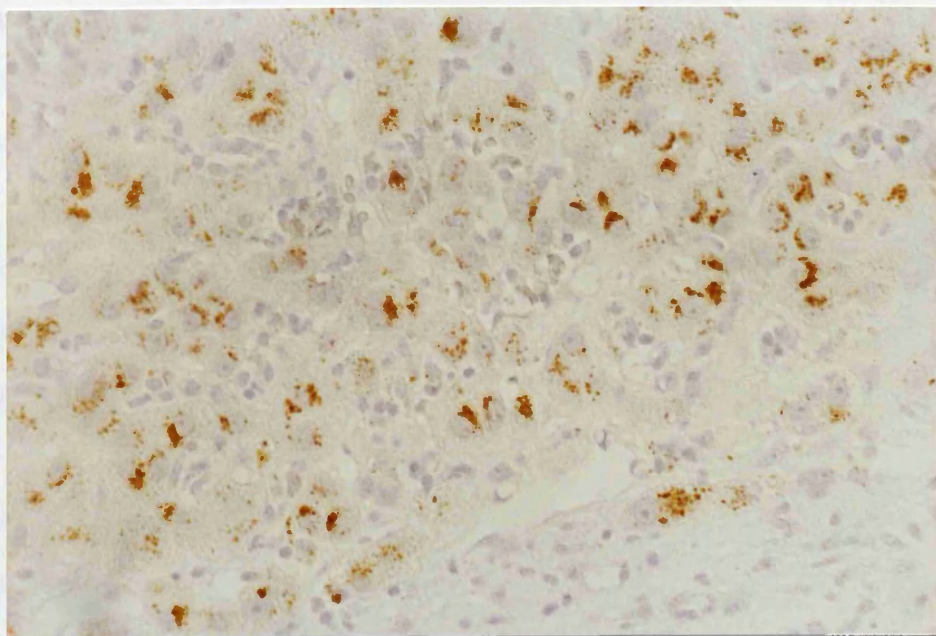


FIGURE 13 ALCOHOLIC CIRRHOSIS - edge of a regenerative nodule showing yellowish-brown-copper granules. (Sodium Diethyl Dithio Carbamate: x 400)

4.6 ALCOHOLIC - SCORE

Critical analysis was exercised to obtain a broad overview of the differences or patterns of difference between the alcoholics and the controls. The simplest way of explaining the principle of this analysis is to say that it is a technique of constructing and optimising a scoring system by which the histopathological data considered in aggregate, may be used to predict to which group (alcoholic or control) a case belongs. The score (or 'discriminant function') is a linear function of all of the primary observations (sex, age, blood alcohol, degree of steatosis, etc.) excluding those observations which cannot be arranged in any natural order (namely, cause of death, lipogranuloma type and type of steatosis).

The theoretical basis of Discriminant analysis

If a diagnosis is to be made by considering several different diagnostic observations together, one method is to define a diagnostic score or 'discriminant function', in this example and alcoholic score, as a weighted average of the observations, with some of the weighting factors being negative if necessary. This idea is sometimes expressed by saying that the discriminant function is a linear combination of the discriminating variables. Thus, if the original observations are $x_1, x_2, x_3, \dots, x_{36}$ then the discriminant function y may be defined as

$$y = a_1x_1 + a_2x_2 + a_3x_3 + \dots a_{36}x_{36}$$

where the coefficients a_1, a_2, \dots, a_{36} are to be chosen

so as to make the discriminant function as efficient as possible for distinguishing between or among the different diagnostic categories. The efficiency or discriminating power of the function is usually measured by an F-ratio derived by one-way analysis of variance of y , i.e. by the ratio of between-categories mean square to the within-categories mean square. However, in the case of a two-category discrimination as used here, it is simpler to use an equivalent measure of discriminating power, namely student's t -statistic, which is the mean value of y for the alcoholic group, minus the mean value for the control group, divided by the standard error of the difference. It should be emphasised that this t -statistic is not in fact calculated, but is used by the theoreticians as a criterion on which to base the procedure. The problem then is to choose the coefficients $a_1, a_2 \dots a_{36}$ in such a way as to maximise t . It has been shown that, subject to certain simplifying assumptions (Cooley and Lohnes, 1971), the criterion of maximum F or maximum t may be satisfied in the case of two categories as follows:

First we calculate the pooled covariance c_{ij} between every possible pair of the discriminating variables x_i and x_j using the formula

$$c_{ij} = \frac{1}{N_A + N_B - 2} \left[\sum_A (x_i - \bar{x}_{iA})(x_j - \bar{x}_{jA}) + \sum_B (x_i - \bar{x}_{iB})(x_j - \bar{x}_{jB}) \right]$$

where the first summation is made over all N_A individuals in diagnostic group A and the second summation over all N_B individuals in group B. We also calculate each of the 36 pooled variances c_{ii} using the same formula, but with $i = j$.

The next step is to calculate each of the 36 mean differences

$$d_1, d_2 \dots d_{36} \text{ using the formula } d_i = \frac{1}{N_A} \sum_A x_i - \frac{1}{N_B} \sum_B x_i,$$

$$\text{i.e. } d_i = \bar{x}_{iA} - \bar{x}_{iB}$$

The final step is to construct and solve a set of 36 simultaneous equations with 36 unknowns, as follows:

$$a_1^c_{1,1} + a_2^c_{1,2} + a_3^c_{1,3} + a_4^c_{1,4} + \dots a_{36}^c_{1,36} = d_1$$

$$a_1^c_{2,1} + a_2^c_{2,2} + a_3^c_{2,3} + a_4^c_{2,4} + \dots a_{36}^c_{2,36} = d_2$$

$$a_1^c_{3,1} + a_2^c_{3,2} + a_3^c_{3,3} + a_4^c_{3,4} + \dots a_{36}^c_{3,36} = d_3$$

$$\dots\dots\dots$$

$$a_1^c_{36,1} + a_2^c_{36,2} + a_3^c_{36,3} + a_4^c_{36,4} + \dots a_{36}^c_{36,36} = d_{36}$$

Solutions of these equations, which is hardly practicable without the help of a computer, give values for the 36 coefficients

$a_1, a_2 \dots a_{36}$ which define the discriminant function y :

$$Y = a_1 x_1 + a_2 x_2 + a_3 x_3 + \dots a_{36} x_{36}$$

The whole of the previous discriminant analysis was carried out with the help of a proprietary computer program known as SPSS-PC + (Statistical Package for Social Sciences, PC version 2).

Accordingly, the alcoholic-score was calculated for each alcoholic and control and the results are demonstrated in Table 11. and Figure 14a.-c. The percentage of chronic alcoholics correctly classified was 90% and that of controls 100%.

TABLE 11.
ALCOHOLIC SCORES FOR ALCOHOLICS AND CONTROLS

CASE NUMBER	ACTUAL GROUP	ALCOHOLIC SCORE
1	Alcoholic	2.4642
2	Alcoholic	2.9429
3	Alcoholic	2.7478
4	Alcoholic	2.0288
5	Alcoholic	2.5514
6	Alcoholic	2.0749
7	Alcoholic	1.1545
8	Alcoholic	3.6476
9	Alcoholic	2.9604
10	Alcoholic	2.4873
11	Alcoholic	3.6628
12	Alcoholic**	-0.6347
13	Alcoholic	1.7688
14	Alcoholic	1.9488
15	Alcoholic**	-0.7647
16	Alcoholic	2.2861
17	Alcoholic	1.8948
18	Alcoholic	2.0375
19	Alcoholic	3.2949
20	Alcoholic	3.2406
21	Alcoholic	3.4177
22	Alcoholic	3.5630
23	Alcoholic	0.6330
24	Alcoholic	2.5665
25	Alcoholic	1.3004
26	Alcoholic	1.7210
27	Alcoholic**	-0.1437
28	Alcoholic	1.5958
29	Alcoholic	2.1580
30	Alcoholic	2.2719
31	Alcoholic	2.3683
32	Alcoholic	1.3131
33	Alcoholic	2.5734
34	Alcoholic	2.0487
35	Alcoholic	2.9861

TABLE 11. Continuation(a)

CASE NUMBER	ACTUAL GROUP	ALCOHOLIC SCORE
36	Alcoholic	0.2186
37	Alcoholic	1.1396
38	Alcoholic	1.0972
39	Alcoholic	0.7803
40	Alcoholic	1.0337
41	Alcoholic	1.5211
42	Alcoholic	2.6859
43	Alcoholic	1.1539
44	Alcoholic	1.4379
45	Alcoholic	2.3876
46	Alcoholic	1.4382
47	Alcoholic	1.2963
48	Alcoholic	2.4352
49	Alcoholic	0.9847
50	Alcoholic	2.5526
51	Alcoholic	2.0430
52	Alcoholic	2.4451
53	Alcoholic	1.0930
54	Alcoholic	1.3639
55	Alcoholic	1.8242
56	Alcoholic	3.2422
57	Alcoholic**	-0.4261
58	Alcoholic	1.9933
59	Alcoholic	2.3948
60	Alcoholic	0.4110
61	Alcoholic	2.2936
62	Alcoholic	3.7097
63	Alcoholic	0.1879
64	Alcoholic	0.1679
65	Alcoholic**	-1.3718
66	Alcoholic	4.0445
67	Alcoholic**	-1.4157
68	Alcoholic	0.6816
69	Alcoholic	0.8386
70	Alcoholic	2.5916
71	Alcoholic	1.5059

TABLE 11.Continuation(b)

CASE NUMBER	ACTUAL GROUP	ALCOHOLIC SCORE
72	Alcoholic	0.1849
73	Alcoholic	3.4406
74	Alcoholic	1.7529
75	Alcoholic	2.1210
76	Alcoholic**	-0.3676
77	Alcoholic**	-0.5643
78	Alcoholic	2.7367
79	Alcoholic	1.1481
80	Alcoholic	1.2821
81	Alcoholic	2.1446
82	Alcoholic	3.4511
83	Alcoholic	1.4942
84	Alcoholic	3.2351
85	Alcoholic	3.6669
86	Alcoholic	1.4035
87	Alcoholic**	-0.9535
88	Alcoholic	1.9978
89	Alcoholic	4.1423
90	Alcoholic	1.2409
91	Alcoholic	2.2861
92	Alcoholic	1.1185
93	Alcoholic**	-0.1507
94	Alcoholic	0.1369
95	Alcoholic	0.1419
96	Alcoholic	1.5345
97	Alcoholic	0.9179
98	Alcoholic	0.8907
99	Alcoholic	2.8996
100	Alcoholic	1.2843
101	Control	-1.5444
102	Control	-0.4253
103	Control	-2.2460
104	Control	-0.9955
105	Control	-2.2068
106	Control	-1.6760
107	Control	-0.5311

TABLE 11. Continuation (c)

CASE NUMBER	ACTUAL GROUP	ALCOHOLIC SCORE
108	Control	-2.1631
109	Control	-1.4361
110	Control	-2.2167
111	Control	-2.2727
112	Control	-1.5928
113	Control	-1.3618
114	Control	-2.0849
115	Control	-1.8840
116	Control	-2.2455
117	Control	-2.3068
118	Control	-0.5185
119	Control	-0.7438
120	Control	-1.8908
121	Control	-0.2280
122	Control	-1.9173
123	Control	-1.8565
124	Control	-2.2471
125	Control	-2.5582
126	Control	-2.4505
127	Control	-0.6879
128	Control	-2.3508
129	Control	-1.7134
130	Control	-2.3245
131	Control	-1.6298
132	Control	-2.0914
133	Control	-2.7563
134	Control	-0.3531
135	Control	-2.1022
136	Control	-1.9714
137	Control	-2.0830
138	Control	-2.3504
139	Control	-2.1070
140	Control	-2.3466
141	Control	-1.9700
142	Control	-2.0957
143	Control	-2.1290

TABLE 11. Continuation (d)

CASE NUMBER	ACTUAL GROUP	ALCOHOLIC SCORE
144	Control	-2.1136
145	Control	-1.1349
146	Control	-2.3844
147	Control	-2.0292
148	Control	-2.1452
149	Control	-2.0069
150	Control	-1.7414
151	Control	-2.2261
152	Control	-1.6358
153	Control	-0.3276
154	Control	-2.7967
155	Control	-2.2910
156	Control	-0.8263
157	Control	-1.6473
158	Control	-2.3662
159	Control	-2.0248
160	Control	-1.4169
161	Control	-1.8299
162	Control	-1.9710
163	Control	-1.4654
164	Control	-1.6714
165	Control	-0.9766
166	Control	-2.3645
167	Control	-0.1927
168	Control	-2.0152
169	Control	-2.2331
170	Control	-2.0477
171	Control	-2.7098
172	Control	-1.8510
173	Control	-1.9414
174	Control	-2.0137
175	Control	-2.1170
176	Control	-1.8069
177	Control	-2.2552
178	Control	-0.4952
179	Control	-0.9518

TABLE 11. Continuation (e)

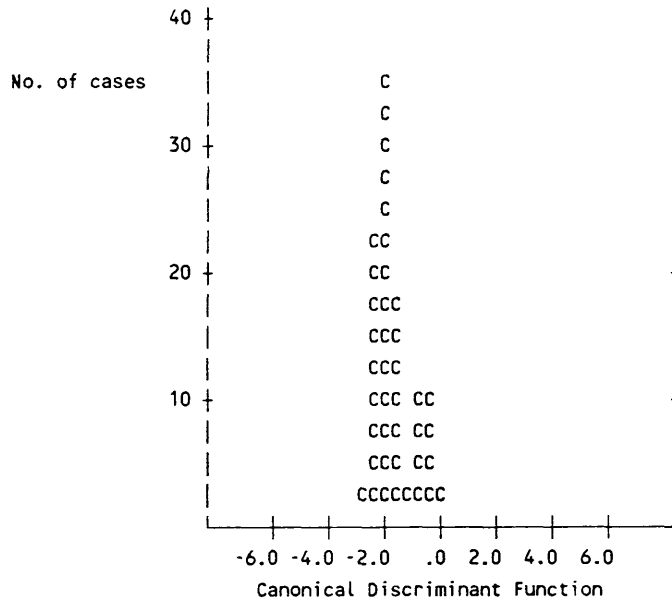
CASE NUMBER	ACTUAL GROUP	ALCOHOLIC SCORE
180	Control	-1.6763
181	Control	-2.0007
182	Control	-2.3800
183	Control	-0.3023
184	Control	-1.6855
185	Control	-0.6309
186	Control	-2.1114
187	Control	-1.4221
188	Control	-0.8796
189	Control	-2.1768
190	Control	-2.1878
191	Control	-0.2616
192	Control	-1.8708
193	Control	-1.5541
194	Control	-1.9464
195	Control	-1.4233
196	Control	-2.2166
197	Control	-0.1481
198	Control	-1.7581
199	Control	-0.4638
200	Control	-0.7836

** Marks the wrongly designated case as chronic alcoholic.

FIGURE 14 **DISTRIBUTION OF ALCOHOLIC SCORES AMONG ALCOHOLICS AND CONTROLS**

(Symbols used in plots: C = Controls;
A = Alcoholics)

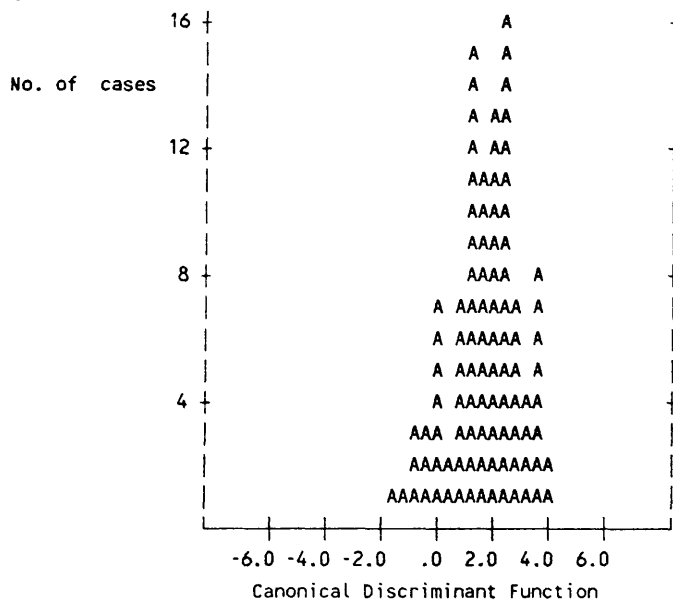
(A) Histogram for Group C (Controls)



Predicted class CCCCCCCCCCCCCCCCCCAAAAAAAAAAAAAAAAAA

Centroid C

(B) Histogram for Group A (Chronic Alcoholics)



Predicted Class CCCCCCCCCCCCCCCCCCAAAAAAAAAAAAAAAAAA

Centroid A

4.7 MECHANISMS OF DEATH IN CASES OF SUDDEN FATTY LIVER DEATHS

Several possible direct mechanisms for sudden deaths in cases of fatty liver have been postulated. These range from such biochemical mechanisms as a low peripheral blood glucose concentration and low blood magnesium concentration, to the inhibition of neurotransmitters (Cohen, 1976; Konig and Fraser, 1954; Madison, 1968; and Randall, 1980). It was not possible, as in all other autopsy series, to attempt to demonstrate these phenomena because biochemical parameters often change post-mortem and these changes are very variable and are particularly marked with the onset of decomposition and putrefaction. The time interval between death and autopsy, and between death and the recovery of the body are also very unpredictable in terms of their relationship to any post-mortem changes in biochemical assays.

The association of fatty livers with an alcohol-induced cardiomyopathy is also well documented (Edmondson, 1980; Evans, 1959; and Saunders, 1970). It is unlikely, however, that unless the cardiomyopathy is well established and producing cardiac failure that it would have any relevance as to the immediate causation of death. In none of the cases studied was the presence of any significant cardiomyopathy with associated congestive cardiac failure identified. It is of course not possible to exclude incipient or early ethanol related cardiotoxicity. In the absence of features of ventricular failure it is highly unlikely that such a degree of cardiac involvement

would have had a significant effect. Furthermore, there is no conclusive evidence that the conducting system of the heart is involved early in ethanol induced cardiotoxicity and this would tend to exclude the possibility of fatal cardiac arrhythmias, which also would not have been evident at autopsy dissection.

Fat embolism is yet another postulated mechanism of death namely, that fat cysts within the liver rupture into the hepatic sinusoids and cause dissemination of fat emboli (Randall, 1980). In 7 of the cases studied there was some evidence of fat embolism. But in only 3 of these could it be shown that fat embolism present was disseminated, and in all these three cases, the number of fat emboli present was small. It is therefore concluded that the fat embolism in these cases was an epiphenomenon and was not directly contributory to the death.

Alcoholic foamy degeneration of hepatocytes may result in severe acute hepatocellular failure as a consequence of organelle damage within hepatocytes and subsequent severe hepatocellular dysfunction (Uchida et al., 1983). In 2 of the 16 cases of sudden fatty liver death a very severe (Grade 4) alcoholic-induced foamy degeneration was identified (Figure 4d). In these cases acute hepatocellular failure may have been the immediate pathogenetic mechanism of death.

TABLE 12.

AGE, SEX, GRADE OF STEATOSIS AND FAT EMBOLISM IN SUDDEN FATTY LIVER DEATHS

AGE	SEX	Degree of Steatosis	Degree of Fat Embolism		
			Cerebral	Pulmonary	Renal
42	M	4	0	0	0
48	M	3	0	Light	0
53	M	3	0	Light	Light
53	M	4	0	0	0
55	M	4	Light	Light	Light
61	M	4	0	0	0
35	F	4	0	0	0
45	F	4	0	0	0
45	F	3	0	0	0
45	F	4	Light	Light	Light
54	F	3	0	Light	0
55	F	4	0	0	0
60	F	4	Light	Light	Light
60	F	3	0	0	0
66	F	4	0	0	Light
70	F	4	0	0	0

C H A P T E R - F I V E

CONCLUSION

5.1 DISCUSSION

Many factors determine our drinking habits but of particular importance are the availability and the price of alcoholic beverages and the social pressures applied by peer groups and by society in general towards alcohol as a socially and morally acceptable drug. The interaction of genetic, psychological and socio-cultural factors might lead to the involuntary excessive consumption of alcohol, i.e. alcoholism.

Alcoholic injury to the liver induces a broad spectrum of morphological changes varying from simple steatosis to cirrhosis and in the current context fatty change has been considered specifically.

Fatty liver is the most common type of liver damage seen in alcoholics. It is however not always a benign disease for it carries a potential risk of sudden death. It is a predictable metabolic response to chronic alcohol abuse, and can occur within a few hours or days of the onset of heavy drinking (Rubin and Lieber, 1968). It is due to the direct hepatotoxic effect of ethanol; malnutrition which is a usual concomitant feature of the chronic consumption of alcohol only aggravates the condition

(Lieber, 1973 and 1977). The direct toxicity of ethanol which leads to fatty degeneration is mainly reflected by decrease lipid oxidation and increase lipogenesis as a result of an increased NADH/NAD ratio consequent upon ethanol oxidation (Lieber, 1981).

In this study a histological examination of specimens taken from fatty livers from 100 alcoholics was carried out; none of these subjects demonstrated alcoholic hepatitis or cirrhosis, so there was an opportunity to study the specific significance of fatty liver, particularly with respect to the pre-labelling of the patient as suffering from alcoholism and the link with sudden death. The most common 'chronic alcoholic' seen in this survey was an elderly male found dead at home. Fatalities have occurred with blood ethanol levels as low as 261mg/100ml in this series (Figure 3). In these cases additional concomitant significant natural diseases, e.g. coronary atherosclerosis or chronic pulmonary disease were usually present and were contributory to death. The blood alcohol levels in the majority of sudden fatty liver deaths were either negative or very low. This is in agreement with what was found in the majority of sudden fatty liver deaths recorded by Kuller and co-workers (1974) and Randall (1980) and are also in accord with the biochemically suggested acute ethanol withdrawal pathogenesis of these deaths such as hypoglycaemia, hypomagnesaemia and false neurotransmitters. The common hepatic histological picture of our

'alcoholics' was that of a severe mosaic form of fatty change (Figure 4b) which can indirectly indicate the large amount of daily ingested alcohol for a long time before death perhaps accompanied by a low protein diet. This can be substantiated by the findings of Edmondson (1980) and Lieber (1977), who noted that the degree of steatosis is related to the length of time and the amount of the daily ingested alcohol and protein.

Lipogranulomas were seen in 18% of alcoholics' fatty livers, most frequently in combination as types II and III (Table 7A) whereas their frequency in the series of MacSween and Burt (1986) was 30-50%.

Cholestasis is believed to be a relatively inconspicuous and infrequent finding in alcoholic liver disease (apart from when it is associated with severe alcoholic hepatitis and in the terminal stages of cirrhosis (Christoffersen and Poulsen, 1979; and MacSween and Burt, 1986), our Fouchet-stained sections frequently showed intrahepatocytic bile pigment with or without intracanalicular bile stasis, commonly in the form of type IIA (Table 8 and Figure 5). Cholestasis has been attributed to several causal factors such as idiosyncratic cholestatic response to alcohol (MacSween and Burt, 1986), and hepatocellular dysfunction as a result of damage to cell organelles due to direct toxic effects of alcohol or its metabolites (Morgan et al., 1978). Cholestasis has been shown to arise as an artifact after death and therefore no substantial conclusion can be reached from

this observation on its own.

Hepatic fibrosis is regarded as a key indicator of the chronicity of liver disease (Kent et al., 1976; and Popper et al., 1981). In our specimens, active fibrogenesis must have been initiated by factors other than necro-inflammation, since alcoholic hepatitis was completely absent. These factors may include:

1. Acetaldehyde (Holt et al., 1984; and Savolainen et al., 1984).
2. lactate (Green and Goldberg, 1964; and Lindy et al., 1971);
3. reduced collagenase activity (Maruyama et al., 1982); and,
4. siderosis was regarded as a mild fibrogenic factor except when present in high local concentrations for long periods (Bothwell et al., 1979).

The fibrogenic process among our alcoholics took several patterns of different grades of severity. The most common were: Grade 1-THVS, perisinusoidal and pericellular fibrosis; septal fibrosis and stress fissures, (Figure 6-10). The latter only require mechanical forces as those of uneven expansion of hepatic territories due to irregular fat deposition. In spite of that they can be seen only in our alcoholics, and never in controls (Table 9E). This can be attributed to the more advanced fatty change in the alcoholics in addition to the

chronicity of the process which on occasions is interrupted by periods of irregular drinking and withdrawal. Such periods might result in scattered irregular fat-free and regenerating islands causing uneven expansion and fissuring. Portal fibrosis was seen in 68 alcoholics, mostly in the form of grade 1, i.e. slight fibrosis (Table 9F). In 15 of these, it can be related to chronic pancreatitis as judged by the portal triad of fibrosis, bile duct proliferation and a mixed inflammatory infiltrate. This is not necessarily associated with intrahepatic cholestasis. The latter was found to be an infrequent and unimpressive histological feature which indicates that the ducts were under partial and/or recurrent obstruction (Afroudakis and Kaplowitz, 1981; and Morgan et al., 1978).

Histochemical examination of liver specimens for iron permits the diagnosis of iron overload and assessment of the quantity of iron in both the parenchymal and reticulo-endothelial cells (Bothwell et al., 1979). Histological grading has been found to be superior to assess this than serum iron determination, and also is more practical than chemical analysis of hepatic iron, in addition to the fact that there is a significant correlation between the histochemical grading of siderosis and chemical estimation of liver iron (Kent and Bahu, 1979; Lundvall et al., 1969; Sheuer et al., 1962; and Weinfeld et al., 1968). Hepatic siderosis was considered

for a long time to be abnormal. Powell (1966) suggested that hepatic storage iron is abnormal when histochemical preparations reveal more than grade 1 iron deposition. Later, Jakobivits and co-workers (1979), commented that while grade 1 and 2 siderosis can occur in normal subjects, significant siderosis grade 3 and 4 invariably indicate increased liver iron content which was present in only 7% of their patients. Significant liver cell siderosis, represented only by grade 3, was seen in 21% of alcoholic necropsies and 2% in controls (Table 10 and Figure 12). This indicates that the incidence of significant hepatic siderosis in alcoholics is probably not as low as recorded by Jakobovits and colleagues (1979).

Stainable intrahepatocytic copper granules were not demonstrated in the fatty livers of our series by the histological methods used. This is consistent with the findings of Berresford and colleagues (1980), who indicated that intrahepatocytic copper deposition is a late manifestation in alcoholic liver disease as it is confined to cases of cirrhosis (Figure 13). Alcoholic cirrhosis is the commonest form of cirrhosis in which stainable intrahepatocytic copper can be found (Hodgson and Thompson, 1976; and MacSween and Scott, 1973). In both alcoholic and primary biliary cirrhosis, stainable copper was seen in the form of hepatocellular lysosomal granules which proved to be innocuous in contrast to the diffuse

cytoplasmic cytotoxic form seen in Wilson's disease (Epstein et al., 1979; Goldfischer and Sternlieb, 1968; Goldfischer et al., 1980); Sternlieb, 1972; and Sternlieb and Goldfischer, 1976). No direct evidence is forthcoming to indicate that copper is hepatocytotoxic and in part responsible for the evolution of cirrhosis in alcoholic liver disease.

The accumulation of fat per se in hepatic steatosis has been proved not to be toxic (Lieber, 1975), this is supported by the observations in Kwashiorkor where fibrosis is never very marked and cirrhosis is not seen (Nayak, 1979). Consequently, it cannot be incriminated in the progression of alcoholic fatty liver to cirrhosis (Lieber and deCarli, 1974). The accumulation of fat is a reflection of severe metabolic disturbance and such metabolic aberration can initiate the fibrogenic process by changes in collagen metabolism. The fibrogenic process may take the form of one or more of many patterns of collagenosis, viz. terminal hepatic venule sclerosis, centrilobular pericellular fibrosis, septal fibrosis, and portal fibrosis. Fibrous thickening of the terminal hepatic venule (THVS) is common both in alcoholic hepatitis (Bianchi et al., 1977; Edmondson et al., 1963; and Goodman and Ishak, 1982), and in alcoholic steatosis without any evidence of alcoholic hepatitis (Edmondson et al., 1967; and Waes

and Lieber, 1977).

Nasrallah and colleagues (1980) showed that THVS occurred with equal frequency in non-alcoholic liver biopsy specimens as in those with various forms of alcoholic liver injury, ranging from fatty liver to severe alcoholic hepatitis. In more than 50% of their patients the thickening was patchy and minimal (grade 1) and labelled as being within normal limits. This is in agreement with the results of investigation made by Brunelli et al. (1985), in which grade 1 THVS was shown in 80% of non-alcoholic specimens. These findings match those in this study where both the series of patients labelled as 'alcoholic' and the non-alcoholic specimens (86 alcoholics; 84 non-alcoholic) demonstrated grade 1 THVS (Figure 6a).

The value of THVS as an index of an eventual progression towards cirrhosis is controversial. Nakano and co-workers (1982) and Waes and Lieber (1977) concluded that its presence has some predictive value as a possible indicator of ultimate progression to cirrhosis. This conclusion was contradicted by Nasrallah et al. (1980), who found that THVS is an inconstant feature in that it disappeared in some patients who had follow-up biopsy specimens.

Cirrhosis is more likely secondary to perisinusoidal fibrosis. In our material, mild

perisinusoidal fibrosis (Figure 6a), occurred in both alcoholics and non-alcoholics, but the difference between the two groups is not as significant as with the centrilobular pericellular fibrosis (Figure 7), and septal fibrosis (Figure 8), which occurred in none of the controls (Table 9B-D). Furthermore, we found that the association between perisinusoidal and centrilobular pericellular fibrosis was highly significant ($P;0.001$) and much more than that with any one of them and THVS. Centrilobular pericellular fibrosis has been suggested as the pathway of progression of alcoholic hepatitis towards cirrhosis (Christoffersen and Poulsen, 1979; Fleming and McGee, 1984; Gerber and Popper, 1972; and Popper and Martin, 1982), obviously through septal fibrosis. The latter, was regarded by the International Group (1981), as more significant than pericellular fibrosis in indicating a risk of progression to cirrhosis. This was corroborated by the findings of Nasrallah and colleagues (1980) who showed that the progression to cirrhosis in their followed-up cases was particularly related to with septal fibrosis, which they referred to as 'active lobular fibrosis'. Our findings are in accordance with the observations of Lieber (1984), and of MacSween and Burt (1986), that centrilobular pericellular fibrosis can occur in the stage of alcoholic fatty change even in the absence of alcoholic hepatitis; septal fibrosis was also noted

in our necropsy livers showing alcoholic steatosis without alcoholic hepatitis. If this is the case, and since the pathogenesis of septal fibrosis appears to represent an advanced stage in the progression of pericellular fibrosis towards complete cirrhosis, it is wise to consider centrilobular pericellular fibrosis and/or primary septal fibrosis as more significant predictive markers than any other pattern of fibrosis, in indicating a potential risk of development of cirrhosis in the chronic alcoholics, particularly if ethanol consumption progresses too. These histological features should be regarded as stern warning signs which strongly indicate the requirement for the patient to stop drinking alcohol in order to prevent the development of more advanced, irreversible and sinister hepatic injury. Surprisingly, the incidence of septal fibrosis among our 'chronic alcoholics' necropsies was 21% (Table 9D), a figure which is comparable to that of 10-30% found clinically in chronic alcoholic patients who will ultimately develop cirrhosis (Popper and Lieber, 1980).

Several histological features have been suggested as markers for the diagnosis of alcoholic fatty degeneration and other forms of alcoholic liver disease. Terminal hepatic venule sclerosis (THVS) has been regarded as characteristic of alcoholic liver disease (Lieber, 1983; and Swerdlow et al., 1981). While others like Nasrallah et al.

(1980) and Brunelli and co-workers (1985) found that grades 1 and 2 THVS are non-specific and of little help in arriving at a definitive diagnosis. Grade 3 THVS is however of major significance. Our results, which were based on the same scale of THVS used by Nasrallah et al. and Brunelli et al. showed that grade 2 and 3 THVS have significantly higher prevalence in alcoholics than in controls (Table 9A) and therefore that their demonstration is perhaps of more real diagnostic value. Centrilobular pericellular and septal fibrosis have also been considered highly characteristic of alcoholic liver disease and of considerable diagnostic importance (Fleming and McGee, 1984; International Group, 1981; and Popper et al., 1981). This conclusion is supported by our failure to demonstrate either of these two forms of fibrosis in the non-alcoholic patients and their high incidence in the alcoholic (54% centrilobular pericellular fibrosis; 21% septal fibrosis).

Grades 3 and 4 fatty degeneration (Figure 4a and b), particularly of the foamy type (Figure 4d), were totally absent in our non-alcoholic group and occurred in relatively high frequency in the alcoholics (Table 6). Thus, these histological criteria can also be regarded as helpful in discriminating alcohol-induced hepatic injury.

There are two other characteristic histological features for alcoholic hepatic injury, i.e. giant

mitochondria and immunoglobulin-A deposition in a continuous or linear perisinusoidal pattern (Swerdlow et al., 1981). Unfortunately, I was unable to trace any of these findings in in our necropsy specimens but is to a large extent due to necropsy nature of our material and the time interval between death and the autopsy. Giant mitochondria are among the first cytoplasmic organelles to undergo degeneration after death (Bancroft and Stevens, 1982). Our staining technique for IgA, i.e. an indirect immunoperoxidase technique, which is considered more sensitive than other techniques, proved ineffective in demonstrating IgA in our material.

In conclusion, one must consider that there is no single feature which is pathognomonic of alcohol induced liver injury. Only by resorting to a combined 'alcoholic score' can a more definitive conclusion of ethanol induced hepatotoxicity be reached particularly in autopsy cases. In this scoring system the raw observations, i.e. the histopathological data that can be arranged in any natural order considered in aggregate, and used to predict to which group (alcoholic or non-alcoholic) an individual case belongs. Statistical analysis of how informative each variable is as an indicator of chronic alcoholism, showed that the most useful histological criteria of fatty livers in the absence of alcoholic hepatitis, which can be related to chronic alcohol abuse, are the

following:-

1. Grade 3 and 4 Hepatic Steatosis.
2. Centrilobular Pericellular Fibrosis.
3. Septal Fibrosis.
4. Grade 2 and over THVS
5. Hepatic Siderosis.
6. Intrahepatic Cholestasis.
7. Parenchymal Minimal Diffuse Lymphocytic Inflammation.
8. Mixed (Lymphocytic and Neutrophilic) Portal Inflammation.

Our investigation of the mechanisms of sudden fatty liver deaths was successful in finding the proximate mechanism of the cause of death of 2 of our 16 sudden 'fatty liver' deaths, i.e. alcoholic foamy degeneration (Figure 4d) which is known to cause severe hepatocellular failure, and death due to the damage of intracellular organelles and consequent functional derangement of the hepatocyte (Uchida et al., 1983). Fat embolism is another suggested mechanism of death in fatty livers but in none of our cases was it considered to be sufficiently severe as to cause death (Table 12). As in all the instances when it was demonstrable it was slight in degree. These findings were consistent with the observations of other investigators who showed that although primary systemic fat emboli were common in association with fatty livers, the condition was only occasionally

sufficiently severe to account for death (Cuppage, 1963; Holler et al., 1958; Lynch et al., 1957; Palmovic and McCarrol, 1965; and Randall, 1980). Other proposed mechanisms are hypoglycaemia, hypomagnesaemia and ethanol-induced inhibitory false neurotransmitters (Madison, 1968; Neame and Joubert, 1961; and Randall, 1980). Hypoglycaemia cannot be confirmed neither histologically, there was a complete absence of glycogen liver deposits in our PAS/stained sections in most of alcoholic and non-alcoholic cases, or biochemically. Blood glucose levels are notoriously inaccurate due to putrefactive changes which include glycolysis in blood found in the peripheral blood vessels and an elevation of blood glucose concentration in the right atrium from glycogenolysis in the liver (Hill, 1941). Other body fluid analyses are unhelpful. Fekete and Kerenyi (1965) reported that cerebrospinal fluid (C.S.F.) glucose fell very rapidly after death as a result of glycolysis and ante-mortem hypoglycaemia could not be recognized by post-mortem cerebrospinal fluid sugar determinations. Attempts were made to compare post-mortem C.S.F. glucose levels in fatty liver sudden deaths and with levels found in sudden deaths from other causes. This was not successful, as the C.S.F. glucose levels were generally very low in both groups probably due to the delay between the time of death and the post-mortem examination (Kuller, 1974). There is also a post-mortem decrease in vitreous humour glucose

and this is erratic and that it could be impossible to make a diagnosis of hypoglycaemia from this estimation (Coe, 1969).

Hypomagnesaemia and ethanol-induced inhibitory false neurotransmitters could not be assessed in our study because the concentration of these substances also changes significantly after death (Coe, 1969; Naumann, 1958; and Pucher and Burd, 1925).

5.2 SUMMARY AND CONCLUSIONS

The present study was an attempt to establish certain criteria for the diagnosis of alcoholism and alcoholic post-mortem fatty livers, and to shed light on the mechanisms of death in persons with fatty livers and no other cause of death.

The definitive diagnosis of alcoholic liver disease proved to be difficult, as no single histological feature could be shown to be absolutely diagnostic. All the histopathological data need to be arranged in natural order, e.g. degree of steatosis, etc., in an aggregate forming part of a scoring system called the 'alcoholic score'. The most informative histological manifestations of our post-mortem fatty livers which can give high scores and established the diagnosis of alcoholism are:

1. Grade 3 and 4 Hepatic Steatosis.

2. Centrilobular Pericellular Fibrosis.
3. Septal Fibrosis.
4. Grade 2 and more - THVS
5. Hepatic Siderosis.
6. Intrahepatic Cholestasis.
7. Parenchymal Minimal Diffuse Lymphocytic
Inflammation.
8. Mixed Portal Inflammation.

It is not necessary that all these features should be present together to obtain a positive alcoholic score, but a high score can be suspected by the presence of 4 of these manifestations in cases of grade 3 and more steatosis, and 5 features in cases below this level.

In investigating the mechanisms of sudden fatty liver deaths, we were convinced in finding the leading mechanism in only 2 of our 16 cases and that was alcoholic foamy degeneration. Fat embolism was also seen in some cases, but it was only slight in degree and thought to be insufficient to cause death.

R E F E R E N C E S

1. Afroudakis, A. and Kaplowitz, N. (1981) Liver histopathology in chronic common bile duct stenosis due to chronic alcoholic pancreatitis. Hepatology, 1, 65-72.
2. Andrè, J. (1961) Le demembrement des hémochromatosis. Revue Internationale d'Hépatologie, 11, 113-174.
3. Bailey, A.J., Sims, T.J. and Gabbiani, G. (1977) Collagen of Dupuytren's disease. Clinical Science and Molecular Medicine, 53, 499-502.
4. Ballard, H., Bernstein, M. and Farrar, J.T. (1961) Fatty liver presenting as obstructive jaundice. American Journal of Medicine, 30, 196-201.
5. Bancroft, J.D. and Stevens, A. (1982) Theory and Practice of Histological Techniques. Edinburgh, London, Melbourne and New York: Churchill Livingstone.
6. Barry, M. (1973) Iron and chronic liver disease. Journal of the Royal College of Physicians of London, 8, 52-62.
7. Bell, E.T. (1955) The relation of portal cirrhosis to haemochromatosis and to diabetes mellitus. Diabetes, 4, 435-446.
8. Berresford, P.A., Sunter, J.P., Harrison, V. and Lesna, M. (1980) Histological demonstrations and frequency of intrahepatocytic copper in patients

suffering from alcoholic liver disease.

Histopathology, 4, 637-643.

9. Bianchi, L., DeGroot, J., Desmet, V.J. and et al. (1977) Acute and chronic hepatitis, revisited. Lancet, 2, 914-919.
10. Biava, C. (1964) Studies on cholestasis. The fine structure and morphogenesis of hepatocellular and canalicular bile pigment. Laboratory Investigation, 13, 1099-1123.
11. Billing, B.H., Conlin, H.J., Hein, D.E. and Schiff, L. (1953) The value of needle biopsy in clinical estimation of liver lipids in man. Journal of Clinical Investigation, 32, 214-225.
12. Biondi, S. (1958) Sull'alavorazione artigiana del rame in altomolise. Folia Medica, Napoli, 41, 521-538.
13. Bissell, D.M., Hammaker, L. and Schmid, R. (1972) Haemoglobin and erythrocyte catabolism in rat liver: the separate roles of parenchymal and sinusoidal cells. Blood, 40, 812-822.
14. Black, M., Mitchell, J.R., Zimmerman, H.J. and et al. (1975) Isoniazid associated hepatitis in 114 patients. Gastro-enterology, 69, 289-302.
15. Blum, K. (1984) Handbook of Abusable Drugs. New York and London: Gardner Press Inc.
16. Bockus, H.L. (1946) Gastro-enterology. Philadelphia and London: W.B. Saunders Co.
17. Boitnott, J.K. and Maddrey, W.C. (1981) Alcoholic liver disease I. Interrelationships among histologic

- features and the histologic effects of prednisolone therapy. Hepatology, 1, 599-612.
18. Bothwell, T.H., Charlton, R.W., Cook, J.D. and Finch, C.A. (1979) Iron Metabolism in Man. Oxford, London, Edinburgh and Melbourne: Blackwell Scientific Publications.
19. Bothwell, T.H., Pirzio-Biroli, G. and Finch, C.A. (1958) Iron absorption. I. Factors influencing absorption. Journal of Laboratory and Clinical Medicine, 51, 24-36.
20. Bove, K.E., McAdams, A.J., Partin, J.C. and et al. (1975) The hepatic lesion in Reye's syndrome. Gastro-enterology, 69, 685-697.
21. Bradlow, B.A., Dunn, J.A. and Higginson, J. (1961) The effect of cirrhosis on iron storage. American Journal of Pathology, 39, 221-227.
22. Bronfenmajer, S., Schaffner, F. and Popper, H. (1966) Fat Storage cells (Lipocytes) in human liver Archives of Pathology, 82, 447-453.
23. Brunelli, E., Macarri, G., Jezequel, A.M. and Orlandi, F. (1985) Diagnostic value of fibrosis of the terminal hepatic venule in fatty liver and chronic hepatitis due to ethanol or other aetiology. Liver, 5, 261-266.
24. Buck, R.E. (1948) Observations on alcoholic fatty liver; use of interval needle biopsy and liver function test. Journal of Laboratory and Clinical Medicine, 33, 555-564.

25. Bush, J.A., Mahoney, J.P., Markowitz, H. and et al.
(1955) Studies on copper metabolism. XVI.
Radioactive copper studies in normal subjects and in
patients with hepatolenticular degeneration. Journal
of Clinical Investigation, 34, 1766-1778.
26. Cartwright, G.E. and Wintrobe, M.M. (1964) Copper
metabolism in normal subjects. American Journal of
Clinical Nutrition, 14, 224-232.
27. Charlton, R.W., Jacobs, P., Seftel, H. and Bothwell,
T.H. (1964) Effect of alcohol on iron absorption.
British Medical Journal, 2, 1427-1429.
28. Chatterji, S.K. and Granguly, H.D. (1950) Copper
content in human urine and faeces. Indian Journal of
Medical Research, 38, 303-314.
29. Christoffersen, P., Braendstrup, O., Juhl, E. and
Poulsen, H. (1971) Lipogranulomas in human liver
biopsies with fatty change. Acta Pathologica et
Microbiologica Scandinavica, Section A., 79, 150-158.
30. Christoffersen, P. and Juhl, E. (1971) Mallory
bodies in liver biopsies with fatty change but no
cirrhosis. Acta Pathologica et Microbiologica
Scandinavica, Section A., 79, 201-207.
31. Christoffersen, P. and Neilsen, K. (1971) The
frequency of Mallory bodies in liver biopsies from
chronic alcoholics. Acta Pathologica et
Microbiologica Scandinavica, Section A., 79, 274-278.
32. Christoffersen, P. and Neilsen, K. (1972)
Histological changes in human liver biopsies from

- chronic alcoholics. Acta Pathologica et Microbiologica Scandinavica, Section A., 80, 557-565.
33. Christoffersen, P. and Poulsen, H. (1971) Correlation of histologic features in two groups of liver biopsies with cirrhosis and fatty change. The first with and the second without Mallory bodies. Acta Pathologica et Microbiologica Scandinavica, Section A., 79, 27-31.
34. Christoffersen, P. and Poulsen, H. (1979) Alcoholic liver disease. In Pathology of the Liver, ed. MacSween, R.N.M., Anthony, P.P. and Scheuer, P.J. Ch.10, pp 232-247. Edinburgh, London and New York: Churchill Livingstone.
35. Clement, B., Grimaud, J-A., Campion, J.P. and et al. (1986) Cell types involved in collagen and fibronectin production in normal and fibrotic human liver. Hepatology, 6, 225-234.
36. Coe, J.I. (1969) Post-mortem chemistries on human vitreous humor. American Journal of Clinical Pathology, 51, 741-750.
37. Cohen, G. (1976) Alkaloid products in the metabolism of alcohol and biogenic amines. Biochemical Pharmacology, 25, 1123-1128.
38. Cohen, G. and Collins, M. (1970) Alkaloids from catecholamines in adrenal tissue: possible role in alcoholism. Science, 167, 1749-1751.
39. Committee on Medical and Biological Effects of Environmental Pollutants, Copper. Publication 0-309-02536-2. (1977) National Academy of Sciences, Washington, D.C.

40. Cooley, W.W. and Lohnes, P.R. (1971) Multivariate Data Analysis. New York: Wiley.
41. Copper and Brass Bulleting, No. 189. (1959) Copper and Brass Research Association. New York.
42. Cuppage, F.E. (1963) Fat embolism in diabetes mellitus. American Journal of Clinical Pathology, 40, 270-275.
43. Davidson, C.S. and Philips, G.B. (1954) Acute hepatic insufficiency in the chronic alcoholic and pathological study. Archives of Internal Medicine, 94, 585-603.
44. Davis, A.E. and Badenoch, J. (1962) Iron absorption in pancreatic disease. Lancet, 2, 6-8.
45. Davids, W.D. and Culpepper, W.S. (1948) Cirrhosis of the liver associated with alcoholism, report of acute exacerbation with serial liver biopsies. Annals of Internal Medicine, 29, 942-958
46. Delier, D.J. (1965) Iron⁵⁹ absorption measurements by whole body counting. Studies in alcoholic cirrhosis, haemochromatosis and pancreatitis. American Journal of Digestive Diseases, 10, 249-258.
47. Desmet, V.J., Bullens, A.M. and Groote, J.D.E. (1970) A clinical and histochemical study of cholestasis. Gut, 11, 516-523.
48. Dianzani, M.U. (1985) Lipid peroxidation in ethanol poisoning: A critical reconsideration. Alcohol and Alcoholism, 20, 161-173.

49. DiLuzio, N.R. (1964) Prevention of the acute ethanol induced fatty liver by simultaneous administration of anti-oxidants. Life Sciences, 3, 113-118.
50. DiLuzio, N.R. and Hartman, A.D. (1967) Role of lipid peroxidation in the pathogenesis of the ethanol induced fatty liver. Federation Proceedings, 26, 1436-1442.
51. Dittrich, H. (1965) Fettleberund eisenstoffwechsel, experimentelle und Klinische probleme. Munchener Medizinische Wochenschrift, 107, 2055-2066.
52. Edmondson, H.A. (1980) Pathology of alcoholism. American Journal of Clinical Pathology, 74, 725-742.
53. Edmondson, H.A., Peters, R.L., Frankel, H.H. and Borowsky, S. (1967) The early stage of liver injury in the alcoholic. Medicine, 46, 119-129.
54. Edmondson, H.A., Peters, R.L., Reynolds, T.B. and Kuzma, O.T. (1963) Sclerosing hyaline necrosis of the liver in the chronic alcoholic: a recognizable clinical syndrome. Annals of Internal Medicine, 59, 646-673.
55. Edwards, C.Q., Carroll, M., Bray, P and Cartwright, G.E. (1977) Hereditary haemochromatosis. Diagnosis in siblings and children. New England Journal of Medicine, 297, 7-13.
56. Elias, E. and Boyer, J.L. (1979) Mechanisms of intrahepatic cholestasis. In Progress in Liver Diseases, ed. Popper, H. And Schaffner, F. Vol.6, Ch.25, pp 457-470. New York: Crune and Stratton.

57. Emanuel, R. and Lieber, C.S. (1974) Fatty liver, alcoholic hepatitis and cirrhosis produced by alcohol in primates. New England Journal of Medicine, 290, 128-135.
58. Epstein, O., Arborgh, B., Wroblewski, R. and et al. (1979) Is copper hepatotoxic in primary biliary cirrhosis? Gastro-enterology, 77, All.
59. Erickson, C.K. (1979) Factors affecting the distribution and measurement of ethanol in the body. In Biochemistry and Pharmacology of Ethanol, ed. Majchrowicz, E. and Noble, E.P. Vol.1, Ch.1, pp 9-29.
60. Evans, W. (1959) The electrocardiogram of alcoholic cardiomyopathy. British Heart Journal, 21, 445-456.
61. Fekete, J.F. and Kerenyi, N.A. (1965) Post-mortem blood sugar and blood urea nitrogen determinations. Canadian Medical Association Journal, 92, 970-973.
62. Fleming, K.A. and McGee, Jo'D. (1984) Review article: Alcohol induced liver disease. Journal of Clinical Pathology, 37, 721-733.
63. Fox, R. (1967) Introduction. In Biochemical Factors In Alcoholism. ed. Maickel, R.P. pp vii-xi. Pergamon Press Ltd.
64. French, S.W. (1981) Thge Mallory body: structure, composition and pathogenesis. Hepatology, 1, 76-83.
65. Froede, R.C. and Gordon, J.D. (1980) Alcoholism - The second great imitator. American Journal of Clinical Pathology., 74, 719-720.
66. Frommer, D.J. (1974) Defective biliary excretion of copper in Wilson's disease. Gut, 15, 125-129.

67. Fuller, G.C., Nolan, J.C., Fink, S. and Rodil, J.V. (1976) Prolyl hydroxylase activity in normal and diseased human liver. Proceedings of the Society for Experimental Biology and Medicine, 151, 61-64.
68. Gabbiani, G., LeLous, M., Bailey, A.J. and Delaunay, A. (1976) Collagen and myofibroblasts of granulation tissue: a chemical, ultrastructural and immunologic study. Virchows Archiv B Cell Pathology, 21, 133-45.
69. Galambos, J.T. (1972) Natural history of alcoholic hepatitis III. Histological changes. Gastroenterology, 63, 1026-1035.
70. Galambos, J.T., Hollingsworth, M.A. Jr., Falek, A. and et al. (1977) The rate of synthesis of glycosaminoglycans and collagen by fibroblasts cultured from adult human liver biopsies. Journal of Clinical Investigation, 60, 107-114.
71. Galambos, J.T. and Shapiro, R. (1973) Natural history of alcoholic hepatitis. IV Glycosaminoglycans and collagen in the hepatic connective tissue. Journal of Clinical Investigation, 52, 2952-2962.
72. Gay, S., Martin, G.R., Muller, P.K. and et al. (1976) Simultaneous synthesis of types I and III collagen by fibroblasts in culture. Proceedings of the National Academy of Sciences of the United States of America, 73, 4037-4040.

73. Gay, S. and Miller, E.J. (1978) Collagen in the Physiology and Pathology of Connective Tissue. New York: Gustav Fischer Verlag, Stuttgart.
74. Gerber, M.A., Orr, W., Denk, H. and et al. (1973) Hepatocellular hyalin in cholestasis and cirrhosis: Its diagnostic significance. Gastro-enterology, 64, 89-98.
75. Gerber, M.A. and Popper, H. (1972) Relation between central canals and portal tracts in alcoholic hepatitis: A contribution to the pathogenesis of cirrhosis in alcoholics. Human Pathology, 3, 199-207.
76. Gilbert, A. and Gernet, A. (1896) Cirrhose alcoolique hypertrophique pigmentaire. Comptes Rendus De L Academie Des Sciences, 3, 1078-1081.
77. Gillman, J. and Gillman, T. (1947) The pathogenesis of cytosiderosis (Haemochromatosis) as evidenced in malnourished Africans. Gastro-enterology, 8, 19-23.
78. Glover, S.C., Mcphie, J.L. and Brunt, P.W. (1977) Cholestasis in acute alcoholic liver disease. Lancet, 2, 1305-1307.
79. Golden, R.D., Cattle, S. and Boylston, A.W. (1986) IgA deposition in alcoholic liver disease. Journal of Clinical Pathology, 39, 1181-1185.
80. Goldfischer, S. and Bernstein, J. (1969) Lipofuscin (aging) pigment granules of the newborn human liver. Journal of Cell Biology, 42, 253-261.
81. Goldfischer, S., Popper, H. and Sternlieb, I. (1980) The significance of variations in the distribution of

- copper in liver disease. American Journal of Pathology, 99, 715-730.
82. Goldfischer, S. and Sternlieb, I. (1968) Changes in the distribution of hepatic copper in relation to the progression of Wilson's disease (Hepatolenticular degeneration). American Journal of Pathology, 53, 883-901.
83. Goodman, Z.D. and Ishak, K.G. (1982) Occlusive venous lesions in alcoholic liver disease. Gastro-enterology, 83, 786-796.
84. Goodwin, D.W. (1971) Is alcoholism hereditary? Archives of General Psychiatry, 25, 545-549.
85. Green, H. and Goldberg, B. (1964) Collagen and cell protein synthesis by an established mammalian fibroblast line. Nature, 204, 347-349.
86. Guzelian, P.S., Qureshi, G.D. and Diegelmann, R.F. (1981) Collagen synthesis by hepatocytes: studies in primary culture of parenchymal cells from adult rat liver. Collagen Research, 1, 83-93.
87. Haemmerli, U.P. (1975) Jaundice during pregnancy. In Diseases of the Liver, ed. Schiff, L.P. Ch.39, pp 1336-1353. Philadelphia: J.B. Lippincott Co.
88. Harris, R.A. (1979) Metabolism of calcium and magnesium during ethanol intoxication and withdrawal. In Biochemistry and Pharmacology of Ethanol, ed. Majchrowicz, E. and Noble, E.P. Vol.2, Ch.1, pp 27-41. New York and London: Plenum Press.

89. Hartroft, W.S. and Ridout, J.J. (1951) Pathogenesis of the cirrhosis produced by choline deficiency. American Journal of Pathology, 27, 951-990.
90. Hayne, R., Vail, M.S., Miller, E.J. and et al. (1977) Collagen polymorphism in cell cultures derived from guinea pig aortic smooth muscle: comparison with three populations of fibroblasts. Archives of Biochemistry and Biophysics, 181, 462-469.
91. Hayne, R., Vail, M.S., Miller, E.J. (1978) Characterization of collagen chains synthesized by cultured smooth muscle cells derived from Rhesus monkey thoracic aorta. Biochemistry, 17, 446-452.
92. Helman, R.A. Temko, M.A., Nye, S.W. and Fallon, H.J. (1971) Alcoholic hepatitis - natural history and evaluation of prednisolone therapy. Annals of Internal Medicine, 74, 311-321.
93. Herbert, V., Zalusky, R. and Davidson, C.S. (1963) Correlation of folate deficiency with alcoholism and associated macrocytosis, anaemia, and liver disease. Annals of Internal Medicine, 58, 977-988.
94. Hill, E. (1941) Significance of Dextrose and nondextrose reducing substances in post-mortem blood. Archives of Pathology, 32, 452-473.
95. Hodgson, H.J.F. and Thompson, R.P.H. (1976) Cirrhosis in South London. Lancet, 2, 118-120.
96. Hoff, E.C. (1967) Motivating the alcoholic to accept rehabilitative therapy. In Biochemical Factors in Alcoholism, ed. Maickel, R.P. pp 241-256. Oxford: Pergamon Press.

97. Holler, J.C. Smythe, C.M. and Pratt-Thomas, H.R. (1958) On the significance of fatty embolism as a cause of sudden death in alcoholics. Southern Medical Journal, 51, 380-382.
98. Holt, K., Bennett, M. and Chojkier, M. (1984) Acetaldehyde stimulates collagen and non-collagen protein production by human fibroblasts. Hepatology, 4, 843-848.
99. Howell, J.S. (1959) Histochemical demonstration of copper in copper-fed rats and in hepatolenticular degeneration. Journal of Pathology and Bacteriology, 77, 473-483.
100. Hunt, A.H., Parr, R.M., Taylor, D.M. and Trott, N.G. (1963) Relation between cirrhosis and trace metal content of the liver with special reference to biliary cirrhosis and copper. British Medical Journal, 2, 1498-1501.
101. International group (1981) Alcoholic liver disease: morphological manifestations. Lancet, 1, 707-711.
102. Isaacson, C., Seftel, H.C., Kelley, K.J. and Bothwell, T.H. (1961) Siderosis in the Bantu: the relationship between iron overload and cirrhosis. Journal of Laboratory and Clinical Medicine, 58, 845-859.
103. Iseri, L.T., Freed, J. and Bures, A.R. (1975) Magnesium deficiency and cardiac disorders. The American Journal of Medicine, 58, 837-846.

104. Ishii, H., Joly, J.G. and Liebr, C.S. (1973) Effect of ethanol on the amount and enzyme activities of hepatic rough and smooth microsomal membranes. Biochimica et Biophysica Acta, 291, 411-420.
105. Jain, S., Scheuer, P.J., Archer, B. and et al. (1978) Histochemical demonstration of copper and copper associated protein in chronic liver disease. Journal of Clinical Pathology, 31, 784-790.
106. Jakobovits, A.W., Morgan, M.Y. and Sherlock, S. (1979) Hepatic siderosis in alcoholics. Digestive Diseases and Sciences, 24, 305-310.
107. Kanagasundaram, N., Kakumu, S., Chen, T. and Leevy, C.M. (1977a.) Alcoholic hyaline antigen (AHAg) and antibody (AHAb) in alcoholic hepatitis. Gastroenterology, 73, 1368-1373.
108. Kanagasundaram, N., Chen, T. and Leevy, C.M. (1977b.) Autoimmunity in alcoholic hepatitis. Gastroenterology, 73, 1227.
109. Karasawa, T., Kushida, T., Shitake, T. and et al. (1980) Morphologic spectrum of liver disease among chronic alcoholics. Acta Pathologica Japan, 30, 505-514.
110. Karmer, K., Kuller, L. and Fisher, R. (1968) The increasing mortality attributed to cirrhosis and fatty liver, Baltimore (1957-1966). Annals of Internal Medicine, 69, 273-282.
111. Kent, G. and Bahu, R.M. (1979) Iron overload. In Pathology of the Liver, ed. MacSween, R.N.M., Anthony, P.P. and Sheuer, P.J. Ch.6, pp 148-163.

Edinburgh, London and New York: Churchill Livingstone.

112. Kent, G., Gay, S., Inouye, T. and et al. (1976) Vitamin A-containing lipocytes and formation of Type III collagen in liver injury. Proceedings of the National Academy of Sciences of the United States of America, 73, 3719-3722.
113. Kent, G., Inouye, T., Minick, O.T. and Aahu, M. (1977) Role of lipocytes (perisinusoidal cells) in fibrogenesis. In Kupffer Cells and Other Liver Sinusoidal Cells, ed. Wisse, E. and Knook, D.L. pp 73-82. Amsterdam: Elsevier/North-Holland. Biomedical Press.
114. Kent, G., Gay, S., Inouye, T. and Popper, H. (1976) types I and III collagen in experimental liver injury. Gastro-enterology, 71, 915.
115. Kent, G. and Popper, H. (1968) Liver biopsy in the diagnosis of haemochromatosis. American Journal of Medicine, 44, 837-841.
116. Konig, T. and Fraser, R. (1954) Magnesium deficiency after prolonged parenteral fluid administration and after chronic alcoholism complicated by delerium tremens. Journal of Laboratory and Clinical Medicine, 43, 169-183.
117. Kuller, L.H. (1974) An epidemic of death attributed to fatty liver in Baltimore. Preventive Medicine, 3, 61-79.

118. Layman, D.L., Epstein, E.H., Dodson, R.F. and et al.
(1977) Biosynthesis of type I and type III collagens
by cultured smooth muscle cells from human aorta.
Proceedings of the National Academy of Sciences of
the United States of America, 74, 671-675.
119. Leevy, C.M. (1962) Fatty liver: a study of 270
patients with biopsy proven fatty liver and a review
of the literature. Medicine, 41, 249-271.
120. Leevy, C.M., Patrylo, I. and Doody, W. (1953)
Hepatic abnormalities in the chronic alcoholic
patient with delerium tremens. Quarterly Journal of
Studies on Alcohol, 14, 568-575.
121. Leevy, C.M. and TenHove, W. (1967) Pathogenesis and
sequelae of liver disease in alcoholic man. In
Biochemical Factors in Alcoholism, ed. Maickel, R.P.
pp 151-165. Oxford: Pergamon Press.
122. Leevy, L.M., Zinke, M.R., White, T.J. and Gnassi,
A.M. (1953) Clinical observations on the fatty
liver. Archives of Internal Medicine, 92, 527-541.
123. Lelbach, W.K. (1967) Leberschäden beichronischem
alkoholismus. Acta Hepato-Splenologica, 14, 9-39.
124. Lereboullet, J., Levillain, R. and Debesse, B.
(1956) L'hepatosiderose Safrequence chezles
alcooliques, etudes statistique de 350 examens
anatomique. Bulletin et Memoires dela Society de
Medicine de Paris, 72, 684-689.
125. Lieber, C.S. (1977) Cytotoxic effects of alcohol on
the liver. Advances in experimental Medicine and
Biology. 85A, 359-398.

126. Lieber, C.S. (1969) Alcohol and the liver. In The Biological Basis of Medicine, ed. Bittar, E.E. pp 317-344. New York: Academic Press.
127. Lieber, C.S. (1983) Precursor lesions of cirrhosis. Alcohol and Alcoholism, 18, 5-20.
128. Lieber, C.S. (1983) Alcohol, protein nutrition and liver injury. Current Concepts In Nutrition, 12, 49-71.
129. Lieber, C.S. (1977) Pathogenesis of alcoholic liver disease: an overview. In Alcohol and the Liver, ed. Fisher, M.M. and Rankin, J.G. pp 197-255. New York: Plenum Press.
130. Lieber, C.S. (1973) Hepatic and metabolic effects of alcohol. Gastro-enterology, 65, 821-846.
131. Lieber, C.S. (1984) Alcohol and the liver: 1984 up date. Hepatology, 4, 1243-1260.
132. Lieber, C.S. (1975) The relationship of alcohol consumption to the development of fatty liver, cirrhosis and excess collagen accumulation. In Collagen Metabolism in the Liver, ed. Popper, H. and Becker, K. pp 62-72. New York: Stratton Inter-continental Medical Book Corporation.
133. Lieber, C.S. (1981) Metabolism and metabolic effects of ethanol. Seminars in Liver Disease, 1, 189-202.
134. Lieber, C.S. and Davidson, C.S. (1962) Some metabolic effects of ethyl alcohol. American Journal of Medicine, 33, 319-327.
135. Lieber, C.S. and DeCarli, L.M. (1970) Reduced nicotinamide adenine dinucleotide phosphate: activity enhanced by ethanol consumption. Science, 170, 78-79.

136. Lieber, C.S. and DeCarli, L.M. (1974) An experimental model of alcohol feeding and liver injury in baboon. Journal of Medical Primatology, 3, 153-163.
137. Lieber, C.S. and DeCarli, L.M. (1976) Animal models of ethanol dependence and liver injury in rats and baboons. Federation Proceedings, 35, 1232-1236.
138. Lieber, C.S., Jones, D.P. and DeCarli, L.M. (1965) Effects of prolonged ethanol intake: production of fatty liver despite adequate diets. Journal of Clinical Investigation, 44, 1009-1021.
139. Lieber, C.S., Jones, D.P., Losowsky, M.S. and Davidson, C.S. (1962) Interrelation of uric acids and ethanol metabolism in man. Journal of Clinical Investigation, 41, 1863-1870.
140. Lieber, C.S., Jones, D.P. Mendelson, J. and DeCarli, L.M. (1963) Fatty liver, hyperlipemia and hyperuricemia produced by prolonged alcohol consumption, despite adequate dietary intake. Transactions of the Association of American Physicians, 76, 289-300.
141. Lieber, C.S. Leevy, C.M., Stein, S.W. and et al. (1962) Effect of ethanol on plasma free fatty acids in man. Journal of Laboratory and Clinical Medicine, 59, 826-832.
142. Lieber, C.S., Lefevre, A., Spritz, N., Feinman, L. and DeCarli, L.M. (1967) Differences in hepatic metabolism of long and medium chain fatty acids: The role of fatty acid chain length in the production of the alcoholic fatty liver. Journal of Clinical Investigation, 46, 1451-1460.

143. Lieber, C.S. and Leo, M.A. (1986) Interaction of alcohol and nutritional factors with hepatic fibrosis. In Progress in Liver Diseases, ed. Popper, H. and Shaffner, F. Vol.8, Ch.14, pp 253-272. New York: Grune and Stratton Inc.
144. Lieber, C.S. and Rubin, E. (1968) Alcoholic fatty liver in man on a high protein and low fat diet. American Journal of Medicine, 44, 200-206.
145. Lieber, C.S. and Rubin, E (1968) Alcohol a hepatotoxic drug. Gastro-enterology, 54, 642-646.
146. Lieber, C.S. and Schmid, R. (1961) The effect of ethanol on fatty acid metabolism: stimulation of hepatic fatty acid synthesis in vitro. Journal of Clinical Investigation, 40, 394-399.
147. Lieber, C.S. and Spirtz, N. (1966) Effect of prolonged ethanol intake in man: Role of dietary, adipose, endogenously synthesized fatty acids in the pathogenesis of the alcoholic fatty liver Journal of Clinical Investigation, 45, 1400-1411.
148. Lieber, C.S., Spritz, N. and DeCarli, L.M. (1969) Fatty liver produced by dietary deficiencies: Its pathogenesis and potentiation by ethanol. Journal of Lipid Research, 10, 283-287.
149. Lieber, C.S., Zimmon, D.S., Kessler, R.E. and et al. (1976) Portal hypertension in experimental alcoholic liver injury. Clinical Research, 24, 278A.
150. Lindy, S., Pedersen, F.B., Turto, H. and Vito, J. (1971) Lactate, lactate dehydrogenase and protocollagen proline hydroxylase in rat skin

autograft. Hoppe-Seyler's Zeitschrift fuer Physiologische Chemie, 352, 1113-1118.

151. Ludwig, J., McDonald, G.S.A., Dickson, E.R. and et al. (1979) Copper stains and the syndrome of primary biliary cirrhosis. Archives of Pathology and Laboratory Medicine, 103, 467-470.
152. Lue, S.L, Paronetto, F. and Lieber, C.S. (1981) Cytotoxicity of mononuclear cells and vulnerability of hepatocytes in alcoholic fatty liver of baboons. Liver, 1, 264-267.
153. Lundin, P., Lundvall, O. and Weinfeld, A. (1971) Iron storage in alcoholic fatty liver. Acta Medica Scandinavica, 189, 541-546.
154. Lundvall, O., Weinfeld, A. and Lundin, P. (1969) Iron stores in alcohol abusers. I. liver iron. Acta Medica Scandinavica, 185, 259-269.
155. Lynch, M.J.G., Raphael, S.S. and Dixon, T. (1957) Fat embolism in chronic alcoholism. Lancet, 273, 123-124.
156. McDonald, R.A. (1961) Idiopathic haemochromatosis. A variant of portal cirrhosis and idiopathic haemosiderosis. Archives of Internal Medicine, 107, 606-616.
157. MacDonald, R.A. (1964) Haemochromatosis and Haemosiderosis. Springfield, Illinois: Charles (Thomas).
158. MacDonald, R.A., Endo, H. and Pechet, G.S. (1968) Studies of experimental haemochromatosis. Archives of Pathology. 85, 366-387.
159. MacDonald, R.A., Jones, R.S. and Pechet, P. Folic acid deficiency and haemochromatosis. Archives of Pathology, 80, 153-160.

160. MacSween, R.N.M. and Burt, A.D. (1986) Histologic spectrum of alcoholic liver disease. Seminars in Liver Disease, 6, 221-232.
161. MacSween, R.N.M. and Scott, A.R. (1973) Hepatic cirrhosis - a clinicopathological review of 520 cases. Journal of Clinical Pathology, 26, 936-942.
162. Madison, L.L. (1968) Ethanol-induced hypoglycemia. Advances in Metabolic Disorders, 3, 85-109.
163. Majchrowicz, E. and Noble, E.P. (1979) Biochemistry and Pharmacology of Ethanol. New York and London: Plenum Press.
164. Mallory, F.B. (1925) The relation of chronic poisoning with copper to haemochromatosis. American Journal of Pathology, 1, 117-133.
165. Maruyama, K., Feinman, L., Fainsilber, Z. and et al. (1982) Measurement of mammalian collagenase in alcohol-fed baboons and patients with alcoholic liver disease: decrease in activity with development of cirrhosis. In Connective Tissue of the Normal and Fibrotic Human Liver, ed. Gerlack, V., Pott, G., Rauterberg, J. and et al. pp 196-198, Stuttgart: George Thieme Verlag.
166. McGee, J.O. and Partick, R.S. (1972) The role of perisinusoidal cells in hepatic fibrogenesis: and electron microscopic study of acute carbon tetrachloride liver injury. Laboratory Investigation, 26, 429-440.
167. Mergenhagen, S.E., Wahl, S.M. and Wahl, L.M. (1980) Regulation of fibroblast function by lymphokines and monokines. In The Reticuloendothelial System and the

- Pathogenesis of Liver Disease, ed. Liehr, H. and Grun, M. pp 69-78. Amsterdam, Elsevier/North Holland: Biomedical Press.
168. Mezey, E. (1982) Alcoholic liver disease. In Progress in Liver Diseases, ed. Popper, H. and Shaffner, F. Vol.7, Ch.32, pp 555-572. New York: Grune and Stratton.
169. Miller, F.J., Maddrey, W.C., Sheff, R.N. and et al. (1975) Hepatic venography and hemodynamics in patients with alcoholic hepatitis. Radiology, 115, 313-317.
170. Miller, E.J. and Matukas, V.J. (1974) Biosynthesis of collagen. Federation Proceedings, 33, 1197-1204.
171. Milman, N., Laursen, J., Podenphant, J. and Asnaes, S. (1986) Trace elements in normal and cirrhotic human liver tissue. I Iron, Copper, Zink, Selenium, Manganese, Titanium and Lead measured by x-ray fluorescence spectrometry. Liver, 6, 111-117.
172. Miralles Garcia, J.M. and deCastrodelpozo, S. (1976) Iron deposits in chronic alcoholics. Special studies in relation to the iron contained in red wine. Acta Hepatogastro-enterol, 23, 10-19.
173. Mitchell, J.R., Zimmerman, H.J., Ishak, K.G. and et al. (1976) Isoniazid liver injury: clinical spectrum, pathology and probably pathogenesis. Annals of Internal Medicine, 84, 181-192.
174. Morgan, M.Y., Sherlock, S. and Scheuer, P.J. (1978) Portal fibrosis in the livers of alcoholic patients. Gut, 19, 1015-1021.

175. Morgan, M.Y., Sherlock, S. and Scheuer, P.J. (1978) Acute cholestasis, hepatic failure and fatty liver in the alcoholic. Scandinavian Journal of Gastroenterology, 13, 299-303.
176. Mowat, A.P. (1983) Reye's syndrome: 20 years on. British Medical Journal, 286, 1999-2001.
177. Nakano, M. and Lieber, C.S. (1982) Ultrastructure of initial stages of perivenular fibrosis in alcohol fed baboons. American Journal of Pathology, 106, 145-155.
178. Nakano, M., Worner, T. and Lieber, C.S. (1982) Perivenular fibrosis in alcoholic liver injury: ultrastructure and histologic progression. Gastro-enterology, 83, 777-785.
179. Nasrallah, S.M., Nassar V.H. and Galambos, J.T. (1980) Importance of terminal hepatic venule thickening. Archives of Pathology and Laboratory Medicine, 104, 84-86.
180. Naumann, H. (1958) Cerebrospinal fluid electrolytes after death. Proceedings of the Society of Experimental Biology and Medicine, 98, 16-18.
181. Nayak, N.C. (1979) Nutritional liver disease. In Pathology of the Liver, ed. MacSween, R.N.M., Anthony, P.P. and Scheuer, P.J. Ch.9, pp 221-231. Edinburgh, London and New York: Churchill Livingstone.
182. Neame, P.B. and Joubert, S.M. (1961) Post-alcoholic hypoglycemia and toxic hepatitis. Lancet, 281, 893-897.
183. Nenci, I. (1975) Identification of actin-like proteins in alcoholic hyaline by immunofluorescence. Laboratory Investigation, 32, 257-260.

184. Niyogy, S.K. (1973) Drug levels in cases of poisoning. Forensic Science, 2, 67-98.
185. Orrego, H. and Blendis, L.M., Crossley, I.R. and et al. (1981) Correlation of intrahepatic pressure with collagen in the Disse space and hepatomegaly in humans and in the rat. Gastro-enterology, 80, 546-556.
186. Orrego, H., Israel, Y. and Blendis, L.M. (1981) Alcoholic liver disease: information in search of knowledge? Hepatology, 1, 267-283.
187. Palmer, E.D. (1967) Clinical implications of fatty liver. General Practitioner, 35, 125-131.
188. Palmovic, V. and McCarroll, J.R. (1965) Fat embolism in trauma. Archives of Pathology, 80, 630-635.
189. Paronetto, F. (1981) Immunologic factors in alcoholic liver disease. Seminars in Liver Disease, 1, 232-243.
190. Patrick, R.S. and McGee, Jo'D. (1980) Biopsy Pathology of Liver, London: Chapman and Hall.
191. Pechet, G.S., French, S.W., Levy, J. and MacDonald, R.A (1965) Histologic and chemical tissue iron. Archives of Pathology, 79, 452-461.
192. Perin, A., Sclabrino, G., Sessa, A. and Arnaboldi, A. (1974) Invitro inhibition of protein synthesis in rat liver as a consequence of ethanol metabolism. Biochemica et Biophysica Acta, 366, 101-108.
193. Perman, G. (1967) Haemochromatosis and red wine. Acta Medica Scandinavica, 182, 281-284.
194. Peters, R.L., Edmondson, H.A., Mikkelsen, W.P. and et al. (1967) Tetracycline-induced fatty liver in non pregnant patients. A report of six cases. American Journal of Surgery, 113, 622-632.

195. Pollack, S., Balcerzak, S.P. and Crosby, W.H. (1963) Transferrin and the absorption of iron. Blood, 21, 33-50.
196. Popper, H. (1977) Pathologic aspects of cirrhosis. American Journal of Pathology, 87, 228-258.
197. Popper, H. (1977) The pathogenesis of alcoholic cirrhosis. In Alcohol and the Liver, ed. Fisher, M.M. and Rankin, J.G. pp 289-305. New York: Plenum Press.
198. Popper, H. (1975) Overview of the past and the future of hepatic collagen metabolism. In Collagen Metabolism in the Liver, ed. Popper, H. and Becker, K. pp 227-242. New York: Stratton Intercontinental Medical Book Corporation.
199. Popper, H. and Elias, H. (1955) Histogenesis of hepatic cirrhosis studies by the three-dimensional approach. American Journal of Pathology. 31, 405-441.
200. Popper, H., Goldfischer, S., Sternlieb, I. and et al. (1979) Cytoplasmic copper and its toxic effects. studies in Indian Childhood Cirrhosis. Lancet, 1, 1205-1208.
201. Popper, H. and Lieber, C.S (1980) Histogenesis of alcoholic fibrosis and cirrhosis in the baboon. American Journal of Pathology, 98, 695-716.
202. Popper, H. and Martin, G.R. (1982) Fibrosis of the liver: the role of the ectoskeleton. In Progress in Liver Diseases, ed. Popper, H. and Schaffner, F. Vol.7, Ch.8, pp 133-156. New York: Grune and Stratton.
203. Popper, H. and Orr, W. (1970) Current concepts in cirrhosis. Scandinavian Journal of Gastroenterology, 6, 203-222.

204. Popper, H. and Piez, K.A. (1978) Collagen metabolism in the liver. American Journal of Digestive Diseases, 23, 641-659.
205. Popper, H. and Schaffner, F. (1957) Liver: Structure and Function. New York: Blakiston Division, McGraw Hill Co.
206. Popper, H. and Szanto, P.B. (1956) Intrahepatic cholestasis (cholangitis). Gastro-enterology, 31, 683-700.
207. Popper, H., Szanto, P.B. and Elias, H. (1955) Transition of fatty liver into cirrhosis. Gastro-enterology, 28, 183-192.
208. Popper, H., Thung, S.N. and Gerber, M.A. (1981) Pathology of alcoholic liver disease. Seminars in Liver Disease, 1, 203-216.
209. Powell, L.W. (1966) Normal human iron storage and its relation to ethanol consumption. Australasian Annals of Medicine, 15, 110-115.
210. Pucher, G. and Burd, L. (1925) A preliminary study of the chemistry of post-mortem blood and spinal fluid. Buffalo General Hospital Bulletin, 3, 11-13.
211. Ramalingaswami, V. (1964) Perspectives in protein malnutrition. Nature, 201, 546-551.
212. Randall, B. (1980) Sudden death and hepatic fatty metamorphosis. Journal of the American Medical Association, 243, 1723-1725.
213. Randall, B. (1980) Fatty liver and sudden death. Human Pathology, 11, 147-153.
214. Rappaport, A.M. (1958) The structural and functional unit in the human liver. (liver acinus). Anatomical Record, 130, 673-689.

215. Rebouca, G. and Isselbacher, K.J. (1961) Studies on the pathogenesis of ethanol induced fatty liver. I. Synthesis and oxidation of fatty acids by the liver. Journal of Clinical Investigation, 40, 1355-1362.
216. Regoeczi, E., Chindemi, P.A. and Debanne, M.T. (1984) Transferrin-glycans: a possible link between alcoholism and hepatic siderosis. Alcoholism, 8, 287-292.
217. Reis, D.J. (1973) A possible role of central noradrenergic neurons in withdrawal states from alcohol. Annals of the New York Academy of Sciences. 215, 249-252.
218. Reynolds, T.B., Hidemura, R., Michel, H. and et al. (1969) Portal hypertension without cirrhosis in alcoholic liver disease. Annals of Internal Medicine, 70, 497-506.
219. Richter, G.W. (1959) The cellular transformation of injected colloidal iron complexes into ferritin and haemosiderin in experimental animals. Journal of Experimental Medicine, 109, 197-216.
220. Risteli, J. and Kivirikko, K.I. (1974) Activities of prolylhydroxylase, lysyl hydroxylase, collagen galactosyltransferase and collagen glucosyltransferase in the liver of rats with hepatic injury. Biochemical Journal, 144, 115-122.
221. Rojkind, M. and Dunn, M.A. (1979) Hepatic fibrosis. Gastro-enterology, 76, 849-863.
222. Rojkind, M. and Kershenobich, D. (1976) Hepatic fibrosis. In Progress in Liver Diseases, ed. Popper,

- H. and Schaffner, F. Vol.5, Ch.18, pp 294-310. New York: Grune and Stratton.
223. Rojkind, M. and Martinez-Palomo, A. (1976) Increase in type I and III collagens in human alcoholic liver cirrhosis. Proceedings of the National Academy of Sciences of the United States of America, 73, 539-543.
224. Rolles, D.B. and Ishak, K.G. (1985) Acute fatty liver of pregnancy: a clinicopathological study of 35 cases. Hepatology, 5, 1149-1158.
225. Rubin, E. and Lieber, C.S. (1968) Alcohol-induced hepatic injury in non-alcoholic volunteers. New England Journal of Medicine, 278, 869-876.
226. Saunders, J.B., Wodak, A.D. and Williams, R. (1984) What determine susceptibility to liver damage from alcohol. Journal of the Royal Society of Medicine, 77, 204-216.
227. Saunders, M. (1970) Alcoholic cardiomyopathy - A critical review. Quarterly Journal of Studies on Alcohol, 31, 324-368.
228. Savolainen, E.R., Leo, M.A., Timpl, R. and et al. (1984) Acetaldehyde and lactate stimulate collagen synthesis of cultured baboon liver myofibroblasts. Gastro-enterology, 87, 777-787.
229. Scheinberg, H. and Sternlieb, I. (1960) Copper metabolism. Pharmacological Reviews, 12, 355-381.
230. Scheuer, P.J., Williams, R and Muri, A.R. (1962) Hepatic pathology in relatives of patients with haemochromatosis. Journal of Pathology and Bacteriology, 84, 53-64.

231. Scott, J., Summerfield, J.A., Elias, E. and et al. (1977) Chronic pancreatitis: a cause of cholestasis. Gut, 18, 196-201.
232. Sherlock, S. (1951) The liver in heart failure: relation of anatomical, functional and circulatory changes. British Heart Journal, 13, 273-293.
233. Simon, M., Bourel, M., Genetet, B. and et al. (1977) Idiopathic haemochromatosis and iron overload in alcoholic liver disease: Differentiation by HLA phenotype. Gastro-enterology, 73, 655-658.
234. Sipponen, P. (1976) Orcein positive hepatocellular material in longstanding biliary diseases. I. Histochemical characteristics. Scandinavian Journal of Gastro-enterology, 11, 545-552.
235. Sternlieb, I. (1972) Evaluation of hepatic lesion in Wilson's disease (Hepatolenticular degeneration). In Progress in Liver Diseases, ed. Popper, H. and Schaffner, F. Vol.4, Ch.29, pp 511-525. New York: Grune and Stratton.
236. Sterlieb, I. and Goldfischer, S. (1976) Heavy metals and lysosomes. In Lysosomes in Biology and Pathology, ed. Dingle, J.T. and Dean, R.T. Vol.5, pp 185-200. New York: Elsevier.
237. Sullivan, L.W. and Herbert, V. (1964) Suppression of heamatopoiesis by ethanol. Journal of Clinical Investigation, 43, 2048-2062.
238. Swerdlow, M.A. and Chowdhury, L.N. (1983) IgA subclasses in liver tissues in alcoholic liver disease. American Journal of Clinical Pathology, 80, 283-289.

239. Swerdlow, M.A. and Chowdhury, L.N. (1984) IgA deposition in liver in alcoholic liver disease. An index of progressive injury. Archives of Pathology and Laboratory Medicine, 108, 416-419.
240. Swerdlow, M., Chowdhury, L.N. and Horn, T. (1981) Morphologic distinctive markers of alcoholic liver disease. Laboratory Investigation, 44, 64A-65A.
241. Swerdlow, M.A., Chowdhury, L.N. and Horn, T. (1982) Patterns of IgA deposition in liver tissues in alcoholic liver disease. American Journal of Clinical Pathology, 77, 259-266.
242. Takado, A., Nei, J., Matsuda, Y. and et al. (1982) Clinicopathological study of alcoholic fibrosis. American Journal of Gastro-enterology, 77, 660-666.
243. Trevisan, A., Cavigli, R., Meliconi, R. and et al. (1983) Detection of immunoglobulins G and A on the cell membrane of hepatocytes from patients with alcoholic liver disease. Journal of Clinical Pathology, 36, 530-534.
244. Triger, D.R., Cyanamon, M.H. and Wright, R (1973) Studies of hepatic uptake of antigen. 1. Comparison of inferior vena cava and portal vein rates of immunisation. Immunology, 25, 941-956.
245. Trowell, H.C., Davies, J.N.P and Dean, R.F.A. (1954) Kwashiorkor. London: Edward Arnold.
246. Tseng, S.C.G., Lee, P.C. Ells, P.F. and et al. (1982) Collagen production by rat hepatocytes and sinusoidal cells in primary monolayer culture. Hepatology, 2, 3-13.

247. Turner, M.S., Portmann, B., Mowat, A.P. and et al. (1979) Increased hepatic copper concentrations in Indian Childhood Cirrhosis. Lancet, 1, 1203-1205.
248. Uchida, T., Kao, H., Quispe-Sjogren, M. and Peters, R.L. (1983) Alcoholic foamy degeneration - A pattern of acute alcoholic injury of the liver. Gastro-enterology, 84, 683-692.
249. VanWaes, L. and Lieber, C.S. (1977) Early perivenular sclerosis in alcoholic fatty liver: an index of progressive liver injury. Gastro-enterology, 73, 646-650.
250. Viel, B., Donoso, S., Salcedo, D., Rojas, P., Varela, A. and Alessandri, R. (1966) Alcoholism and socio-economic status, hepatic damage and arteriosclerosis. Archives of Internal Medicine, 117, 84-91.
251. Vierling, J.M., Shrager, M.A., Warrer, F. and et al. (1978) Incorporation of radiocopper into ceruloplasmin in normal subjects and in patients with P.B.C. and Wilson's disease. Gastro-enterology, 74, 652-660.
252. Voss, B., Rauterberg, J., Pott, G. and et al. (1982) Nonparenchymal cells cultivated from explants of fibrotic liver resemble endothelial and smooth muscle cells from blood vessels walls. Hepatology, 2, 19-28.
253. Weinfeld, A., Lundin, P. and Lundvall, O. (1968) Significance for the diagnosis of iron overload of histochemical and chemical iron in the livers of control subjects. Journal of Clinical Pathology, 21, 35-40.
254. Wheby, M.S. (1966) Regulation of iron absorption. Gastro-enterology, 50, 888-892.

255. Williams, R., Williams, H.S., Scheuer, P.J. and et al. (1967) Iron absorption and siderosis in chronic liver disease. Quarterly Journal of Medicine, 36, 151-166.
256. Wöhler, F. (1964) Ferritin and haemosiderin. German Medical Monthly, 9, 377-385.
257. Wolman, M. (1975) Polarized light microscopy as a tool of diagnostic pathology. Journal of Histochemistry and Cytochemistry, 23, 21-50.
258. Worner, T.M. and Lieber, C.S. (1985) Perivenular fibrosis as precursor lesion of cirrhosis. Journal of the American Medical Association, 254, 627-630.
259. Wu, C.H., Rojkind, M., Rifas, L. and et al. (1978) Biosynthesis of type I and type III collagens by cultured uterine smooth muscle cells. Archives of Biochemistry and Biophysics, 188, 294-300.
260. Zetterman, R.K., Luisada-Opper, A. and Leevy, C.M. (1976) Alcoholic hepatitis: cell-mediated immunological response to alcoholic hyaline. Gastro-enterology, 70, 382-384.
261. Zimmerman, H.J., Chomet, B., Kulesh, M.H. and McWhorter, C.A. (1961) Hepatic haemosiderin deposits. Incidence in 558 biopsies from patients with and without intrinsic hepatic disease. Archives of Internal Medicine, 107, 494-503.
262. Zimmerman, H.J., MacMurray, F.G., Rappaport, H. and Alpert, L.K. (1950) Studies of the liver in diabetes mellitus. I. Structural and functional alterations. Journal of Laboratory and Clinical Medicine, 36, 912-921.
263. Zinneman, H.H. (1975) Autoimmune phenomena in alcoholic cirrhosis. American Journal of Digestive Diseases, 20, 337-345.