

MENINGO-CEREBRAL ADHESIONS : A STUDY TO
PREVENT THEIR FORMATION BY THE USE
OF CORTISONE

by

Lieut. R. Myles Gibson, R.A.M.C.

December 1951.

ProQuest Number: 13838399

All rights reserved

INFORMATION TO ALL USERS

The quality of this reproduction is dependent upon the quality of the copy submitted.

In the unlikely event that the author did not send a complete manuscript and there are missing pages, these will be noted. Also, if material had to be removed, a note will indicate the deletion.



ProQuest 13838399

Published by ProQuest LLC (2019). Copyright of the Dissertation is held by the Author.

All rights reserved.

This work is protected against unauthorized copying under Title 17, United States Code
Microform Edition © ProQuest LLC.

ProQuest LLC.
789 East Eisenhower Parkway
P.O. Box 1346
Ann Arbor, MI 48106 – 1346

A THESIS PRESENTED TO THE
UNIVERSITY OF GLASGOW
IN FULFILLMENT OF THE REQUIREMENTS FOR THE
DEGREE OF DOCTOR OF MEDICINE.

December 1951.

TABLE OF CONTENTS.

INTRODUCTION	4
THE PREVENTION OF MENINGO CEREBRAL ADHESIONS	5
THE INCIDENCE OF POST TRAUMATIC EPILEPSY	32
CORTISONE	43
MATERIALS AND METHODS	76
EXPERIMENTAL RESULTS	81
SUMMARY OF EXPERIMENTAL EVIDENCE	147
CONCLUSIONS	151
ACKNOWLEDGEMENTS	154
BIBLIOGRAPHY	a - u .

INTRODUCTION.

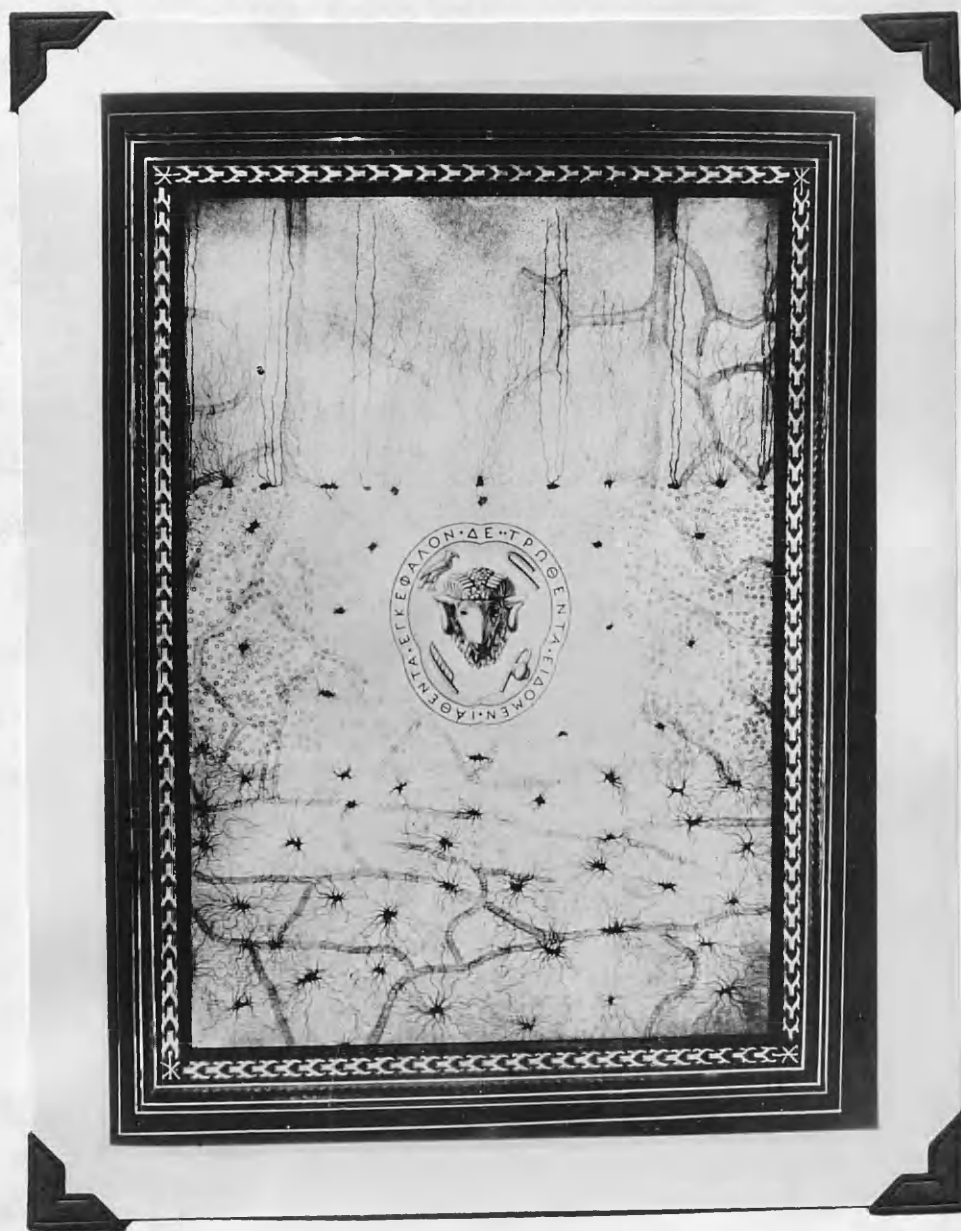
This study was prompted when the writer was engaged on a histological problem regarding the effect of intramuscular cortisone on glial and neuronal elements.

The relationship of meningocerebral adhesions and cerebral cicatrices to the incidence of post traumatic epilepsy is one which is often contested. In this work no attempt is made to emphasise the relationship, or otherwise. The incidence of post traumatic epilepsy is reviewed, the diverse attempts to prevent adhesions are analysed, the physio-biological properties of cortisone are presented and the results of the experimental work, contained herein, are set forth.

The study was carried out within the framework of a limited supply of cortisone. Its object and prime purpose was to suggest the lines and avenues of clinical neurological investigation which might be safely and profitably explored when supplies of cortisone become readily available. It is therefore hoped that the acceptance or rejection of the importance of scar tissue, or an "adhesion hypothesis", will in no way modify the importance of the basic conclusions.

" But I have seen s severely
wounded brain healed "

(from Galen's commentaries on
the Aphorisms of Hippocrates)



THE PREVENTION OF MENINGO-CEREBRAL ADHESIONS.

The disturbances of bodily function due to adhesions are not confined to the brain and its coverings. The investigations related to this problem are few compared to those which concern the other serous spaces of the body, especially the peritoneal cavity. The prevention of adhesions in joint spaces, tendon sheaths and around sutured nerves has likewise attracted a great deal of attention. Richardson (1911) and Ochsner and Garside (1932), in their studies, reviewed the methods and materials which have been used for the prevention of peritoneal adhesions (Fig). It may be contended that the presentation of these reviews contributes little to the problem under discussion. They are testimony to the confusion which has existed in the prevention and treatment of peritoneal adhesions. New methods or materials will have been tried and acclaimed by one, or a number of observers, and then failed in the hard test of time and trial. The problem to this day remains unsolved.

Literature relating to methods and materials employed to prevent adhesions between the brain and its enveloping membranes is scanty in comparison to the writings on adhesion prevention in general. In fact, most of the reports concern various substances which have been utilized primarily to repair dural defects. A suitable substitute for normal human dura is highly desirable for two primary reasons: first, the dura may have to be removed because of its involvement in a disease

process; and second, the dura may^{be} injured with or without damage to the underlying nervous tissue. In order to meet those needs for a protective layer which might be easily available, numerous materials have been studied in the laboratory, and also clinically. These methods of duraplasty have been reviewed by Von Saar (1910), Buné (1933), de Bernardis (1935), Caporale and de Bernardis (1936) and Glaser and Thienes (1938).

These experiments and reports on duroplasty were of great value since they provided a base line for the investigation of other materials. For the purpose of presentation and discussion these materials may best be classified under the following heads:

- a) Metals.
- b) Viable animal membranes.
- c) Non viable animal membranes.
- d) Miscellaneous.

METALS. The debut of the modern period in the surgery of post traumatic epilepsy, which was pioneered by Horsley in the latter part of the 19th century, was followed by the first reports on the use of materials to prevent meningo-cerebral adhesions. Horsley excised the epileptogenic cicatrices, but did not cover the area of removal with protective materials. Beach is credited with the first suggestion to use those substances. In 1890 he reported a case of post traumatic epilepsy

TABLE 1.

**Showing the various metals which have
been used in the prevention of adhesions.**

METALS

<u>MATERIAL</u>	<u>OBSERVERS</u>	<u>YEAR</u>	<u>ANIMAL</u>	<u>LOCATION</u>	<u>PURPOSE</u>	<u>RESULT</u>
GOLD FOIL	BEACH	1892	MAN	CORTICAL SURFACE	PREVENT ADHESIONS	CLINICALLY FAIR- NO AUTOPSY
	OLIVER	1895	MAN	CORTICAL SURFACE	PREVENT ADHESIONS	RE-OPERATED AND RESULT GOOD
	ESTES	1896	MAN	CORTICAL SURFACE	PREVENT ADHESIONS	CLINICALLY GOOD- NO AUTOPSY
	SUMMERS	1897	MAN	CORTICAL SURFACE	PREVENT ADHESIONS	CLINICALLY GOOD- NO AUTOPSY
	WOOLSEY	1897	MAN	CORTICAL SURFACE	PREVENT ADHESIONS	ENCAPSULATION & ADHESIONS
SILVER FOIL	RAY	1901	MAN	CORTICAL SURFACE	PREVENT ADHESIONS	CLINICALLY GOOD NO AUTOPSY
	HARRIS	1904	MAN	CORTICAL SURFACE	PREVENT ADHESIONS	CLINICALLY GOOD- NO AUTOPSY
	PRIME	1909	DOG	CORTICAL SURFACE	PREVENT ADHESIONS	ENCAPSULATION & ADHESIONS
	CHAO HUMPHREYS PENFIELD	1940	CAT	CORTICAL SURFACE	PREVENT ADHESIONS	DENSE ADHESIONS AND MARKED CEL- LULAR REACTION
PLATINUM FOIL	MOREHEAD	1896	MAN	CORTICAL SURFACE	PREVENT ADHESIONS	NOT STATED
	McCOSH	1898	MAN	CORTICAL SURFACE	PREVENT ADHESIONS	NOT STATED
ALUMINUM FOIL	CHAO ET AL.	1940	CAT	CORTICAL SURFACE	PREVENT ADHESIONS	DENSE ADHESIONS AND MILD CELLU- LAR REACTION
NICKEL PLATE	CHAO ET AL.	1940	CAT	CORTICAL SURFACE	PREVENT ADHESIONS	DENSE ADHESIONS AND MARKED CEL- LULAR REACTION
STAINLESS STEEL PLATE	CHAO ET AL.	1940	CAT	CORTICAL SURFACE	PREVENT ADHESIONS	DENSE ADHESIONS & ENCAPSULATION
TANTALUM	PUDENZ	1942	CAT	CORTICAL SURFACE	"	ENCAPSULATION
	DELARUE	1944	DOG	CORTICAL SURFACE	"	DENSE, DENSE ADHESIONS.

treated by lysis of the meningo-cerebral adhesions. At the same time he stated that should the seizures recur, he would reoperate and implant gold foil between the brain and the dura. In 1897 he reported that this plan was effected at a second craniotomy in 1892. The patients attacks recurred, but with diminished frequency and intensity. No further observations on the condition of the foil were reported.

The popularity of the metallic foils in the surgery of epilepsy was maintained well into the first decade of the 20th century. The observations of Beach on gold foil were followed by the reports of Oliver (1896), Estes (1896), Summers (1897), and Woolsey (1897), on the metal; those of Ray (1901), Harris (1904) and Prime (1909), on silver foil, and Morehead (1896) and McCosh (1898) on platinum foil. Chao, Humphreys and Penfield (1940) reported their experiences with silver foil, aluminum foil, nickel plate and stainless steel plate. Pudenz and Odom (1942) reviewed the properties of tantalum and conducted an experimental enquiry into its possible use in the prevention of meningo-cerebral adhesions. Tantalum is an element, the seventy-third in the periodic table. It is a bluish white metal, resembling steel in its physical properties and glass in its chemical characteristics. Pudenz used tantalum foil in 5 animals and the observation period extended over 79 days. While encapsulation of the tantalum occurred, it was very slight. He felt the histologic evidence indicated progressive diminution rather than increase, in the thickness of the capsule. This

is in contradistinction to the progressive capsular proliferation noted with other alloplastic materials eg. celluloid (Penfield 1924). The impenetrable character of tantalum foil had prevented a direct ingrowth of connective tissue from the overlying structures. The only point of attachment between the cerebral wound and the dura was the capsular margin. There was a negligible reaction of inflammatory cells to the tantalum, The removed pieces of foil were always bright and shining, suggesting a complete absence of corrosion by the body fluids.

Robertson (1944), reported the repair of 26 cranial defects with tantalum over a two year period. He felt there was a minimal reaction of tissues to the ~~presence~~ of tantalum. None the less, in one case (reviewed six days after operation), there was a thin, filmy, translucent, gelatinous membrane enveloping the tantalum. Microscopic examination showed it to be composed of "tangled masses of fibrous strands". In the same year Delarue, Linell and McKenzie (1944), published an experimental study on the use of tantalum in the subdural space in 12 dogs. In all these animals there was marked reactive thickening of the dura overlying the tantalum and in many, a similar, but slighter, reactive thickening of the underlying arachnoid membrane was present. The following year Robertson and Beacher (1945), reported the use of tantalum foil immediately over the cortex in six patients. In each instance the findings were invariably similar - a fine, thin, smooth, glistening, diaphanous membrane surrounded the foil. This envelope was very loosely adherent to the arachnoid and dura but was easily separated.

Irrespective of these findings it must be realized that tantalum does not possess the quality of resorbability, and even although it would appear that it is relatively inert in the tissues, this is a definite disadvantage. The study of Pudenz extended over a maximum of 79 days, and it would have been better to have observed the state of affairs over a minimum period of 18 months. The metal used was 1/1,000 inch thick. The grain structure of the metal will not permit the rolling of tantalum into thinner foil. This thickness and rigidity of .001 inch foil is a most definite disadvantage since pieces of some size will not conform to the convolitional pattern of the brain and a dead space is, in consequence, likely. One feature common to all of these metals is encapsulation. The intensity of cellular reaction is variable and would seem dependant on the degree of electrolysis of the metal.

Viable Animal Membranes. At the close of the first decade of the twentieth century the metallic substances were giving way in favor of viable and non-viable animal membranes. These viable membranes have generally been employed for the closure of dural defects and not for the prevention of meningo-cerebral adhesions. This work was originated with Kirshner (1909), who used autoplasic fascia lata for dural restoration in dogs. The first human duroplastic operation with fascia lata was performed by Körte in 1910. A variety of viable membranes have since been employed. Among the autoplasic tissues are dura (Bruning 1911), periosteum (Ronde 1933, Bunè 1933),

TABLE 3.

Showing the viable animal membranes used
by various investigators.

TABLE 2.

**Showing the viable animal membranes used
by various investigators.**

VIABLE ANIMAL MEMBRANES

<u>MATERIAL</u>	<u>OBSERVERS</u>	<u>YEAR</u>	<u>ANIMAL</u>	<u>LOCATION</u>	<u>PURPOSE</u>	<u>RESULT</u>
FASCIA LATA	KIRSCHNER	1909	Dog	DURAL DEFECT	DUROPLASTY	FIRM UNION WITH DURA
	DAVIS	1910	Dog	DURAL DEFECT	DUROPLASTY	FIRM UNION WITH DURA CORTEX UNINJURED AND NO ADHESIONS
	KIRSCHNER	1913	Dog	DURAL DEFECT	DUROPLASTY	FIRM UNION WITH DURA IN 45 DAYS. NO ADHESIONS TO PIA
	CHAO ET AL.	1940	CAT	CORTICAL SURFACE	PREVENT ADHESIONS	MODERATE ADHESIONS AND CELLULAR REACTION
AUTOPLASTIC PERIOSTEUM	FINSTERER	1910	Dog	DURAL DEFECT	DUROPLASTY	DENSELY ADHERENT TO WOUNDED CORTEX
AUTOPLASTIC TEMPORALIS FASCIA	BUNE	1933	Dog	DURAL DEFECT	DUROPLASTY	ADHESIONS IF CORTEX DAMAGED
AUTOPLASTIC PERITONEAL TISSUES	ROHDE	----	Dog	DURAL DEFECT	DUROPLASTY	ADHESIONS IF CORTEX DAMAGED
	BUNE	1933	Dog	DURAL DEFECT	DUROPLASTY	ADHESIONS IF CORTEX DAMAGED
AUTOPLASTIC FAT	REHN	1913	Dog	DURAL DEFECT	DUROPLASTY	ADHESIONS EVEN THOUGH PIA UNDAAGED
	DENK	1914	Dog	DURAL DEFECT	DUROPLASTY	DENSE ADHESIONS TO DAMAGED PIA
	CHAO ET AL.	1940	CAT	CORTICAL SURFACE	PREVENT ADHESIONS	DENSE ADHESIONS AND MARKED CELLULAR REACTION
HUMAN AMNIOTIC MEMBRANE	BURGER	1939	CAT	DURAL DEFECT	DUROPLASTY	RESULTS INCONCLUSIVE

and fat (Rehn 1913, Denk 1914, Chao et al 1940). Homoplastic hernia sac was successfully used in man by Finsterer (1910). Burger (1939) attempted to replace the dura mater in cats with human amniotic membrane obtained in the fresh state at Caesarian section but his results were inconclusive. Chao, Humphreys and Penfield (1940), presented experimental data on the use of viable membranes to prevent meningo-cerebral adhesions specifically. Both fat and fascia lata were used over brain wounds in cats. Adhesions occurred in all of the experiments. The materials became incorporated in a new-formed brain covering which replaced dura and incorporated pia without formation of separate meningeal linings. Fat in particular, produced a most severe cellular reaction

Examination of these facts and the data outlined in table 2, permits of the generalisation that, from the standpoint of dural repair, the autoplasmic viable membranes have been successful. However, when the cortex has been damaged and subsequent examination of the tissues was possible, meningo cerebral adhesions have invariably been the rule.

Non-Viable Animal Membranes. A large number of materials classifiable in this category have been employed over the intact and wounded cerebral cortex. In 1898 Freeman described his two experiments, one on a dog and the other on a rabbit, in which the vitelline membrane of the hen egg was placed over the wounded cerebral cortex. The wound in the dog suppurated, vitiating his results. The rabbit was killed at the end of two months. The brain was yellow at the site of

A table of the non visible animal membranes.

TABIE 3.

MEMBRANE	NO.	WEIGHT	LENGTH	BREADTH	THICKNESS	REMARKS
PERITONEUM	1	1000	100	100	10	...
PLEURA	2	1000	100	100	10	...
DIAPHRAGM	3	1000	100	100	10	...
PERICARDIUM	4	1000	100	100	10	...
ENDOTHELIUM	5	1000	100	100	10	...
EPITHELIUM	6	1000	100	100	10	...
MUSCULUM	7	1000	100	100	10	...
NERVUS	8	1000	100	100	10	...
ARTERIA	9	1000	100	100	10	...
VENA	10	1000	100	100	10	...
LYMPHATIC	11	1000	100	100	10	...
CHLORIDE	12	1000	100	100	10	...
PHOSPHORUS	13	1000	100	100	10	...
SULFUR	14	1000	100	100	10	...
IRON	15	1000	100	100	10	...
COPPER	16	1000	100	100	10	...
ZINC	17	1000	100	100	10	...
LEAD	18	1000	100	100	10	...
SILVER	19	1000	100	100	10	...
GOLD	20	1000	100	100	10	...
PLATINUM	21	1000	100	100	10	...
IRIDIUM	22	1000	100	100	10	...
OSMIUM	23	1000	100	100	10	...
ANTIMONY	24	1000	100	100	10	...
ARSENIC	25	1000	100	100	10	...
COBALT	26	1000	100	100	10	...
NICKEL	27	1000	100	100	10	...
CHROMIUM	28	1000	100	100	10	...
MANGANESE	29	1000	100	100	10	...
ALUMINUM	30	1000	100	100	10	...
MAGNESIUM	31	1000	100	100	10	...
CALCIUM	32	1000	100	100	10	...
STRONTIUM	33	1000	100	100	10	...
BARIUM	34	1000	100	100	10	...
CAESIUM	35	1000	100	100	10	...
FRANCIUM	36	1000	100	100	10	...
RADIUM	37	1000	100	100	10	...
ACTINIUM	38	1000	100	100	10	...
THORIUM	39	1000	100	100	10	...
URANIUM	40	1000	100	100	10	...
PLUTONIUM	41	1000	100	100	10	...
AMERICIUM	42	1000	100	100	10	...
CURIE	43	1000	100	100	10	...
BERKELEY	44	1000	100	100	10	...
SEABERG	45	1000	100	100	10	...
FERMI	46	1000	100	100	10	...
TRACMAN	47	1000	100	100	10	...
REES	48	1000	100	100	10	...
SWERDLOW	49	1000	100	100	10	...
SISSON	50	1000	100	100	10	...
MCCLURE	51	1000	100	100	10	...
CHALKER	52	1000	100	100	10	...
THORNTON	53	1000	100	100	10	...
WATSON	54	1000	100	100	10	...
CHAMBERLAIN	55	1000	100	100	10	...
COOPER	56	1000	100	100	10	...
ANDERSON	57	1000	100	100	10	...
BRIDGES	58	1000	100	100	10	...
ROBERTS	59	1000	100	100	10	...
WILLIAMS	60	1000	100	100	10	...
MITCHELL	61	1000	100	100	10	...
DAVIS	62	1000	100	100	10	...
JOHNSON	63	1000	100	100	10	...
SMITH	64	1000	100	100	10	...
WILSON	65	1000	100	100	10	...
GREEN	66	1000	100	100	10	...
ADAMS	67	1000	100	100	10	...
HARRIS	68	1000	100	100	10	...
WALKER	69	1000	100	100	10	...
PERKINS	70	1000	100	100	10	...
ROBERTSON	71	1000	100	100	10	...
TURNER	72	1000	100	100	10	...
BLACK	73	1000	100	100	10	...
WHITE	74	1000	100	100	10	...
GRAY	75	1000	100	100	10	...
BROWN	76	1000	100	100	10	...
WILSON	77	1000	100	100	10	...
ANDERSON	78	1000	100	100	10	...
BRIDGES	79	1000	100	100	10	...
ROBERTS	80	1000	100	100	10	...
WILLIAMS	81	1000	100	100	10	...
MITCHELL	82	1000	100	100	10	...
DAVIS	83	1000	100	100	10	...
JOHNSON	84	1000	100	100	10	...
SMITH	85	1000	100	100	10	...
WILSON	86	1000	100	100	10	...
GREEN	87	1000	100	100	10	...
ADAMS	88	1000	100	100	10	...
HARRIS	89	1000	100	100	10	...
WALKER	90	1000	100	100	10	...
PERKINS	91	1000	100	100	10	...
ROBERTSON	92	1000	100	100	10	...
TURNER	93	1000	100	100	10	...
BLACK	94	1000	100	100	10	...
WHITE	95	1000	100	100	10	...
GRAY	96	1000	100	100	10	...
BROWN	97	1000	100	100	10	...
WILSON	98	1000	100	100	10	...
ANDERSON	99	1000	100	100	10	...
BRIDGES	100	1000	100	100	10	...

TABLE 3.

A table of the non viable animal membranes.

NON-VIABLE ANIMAL MEMBRANES

<u>MATERIAL</u>	<u>OBSERVERS</u>	<u>YEAR</u>	<u>ANIMAL</u>	<u>LOCATION</u>	<u>PURPOSE</u>	<u>RESULT</u>
EGG SHELL MEMBRANE	FREEMAN	1898	Dog Rabbit	CORTICAL SURFACE	PREVENT ADHESIONS	INCONCLUSIVE
	GREER	1901	MAN	CORTICAL SURFACE	PREVENT ADHESIONS	INCONCLUSIVE
	PRIME	1909	Dog	CORTICAL SURFACE	PREVENT ADHESIONS	ENCAPSULATION AND ADHESIONS IF CORTEX INJURED
CARGILE MEMBRANE	CRAIG & ELLIS	1905	Dog	DURAL DEFECT	DUROPLASTY	INCONCLUSIVE
	PRIME	1909	Dog	CORTICAL SURFACE	PREVENT ADHESIONS	ENCAPSULATION AND ADHESIONS IF CORTEX INJURED
	CHAO ET AL.	1940	CAT	CORTICAL SURFACE	PREVENT ADHESIONS	DENSE ADHESIONS AND MODERATE CELLULAR REACTION
PREPARED HERNIA SAC	FINSTERER	1910	Dog	DURAL DEFECT	DUROPLASTY	FIRM UNION WITH DURA. NO CORTICAL INJURY-NO ADHESIONS
	VON SAAR	1910	Dog Rabbit GUINEA PIG	DURAL DEFECT	DUROPLASTY	ADHESIONS IN MOST CASES
HUMAN AMNIOTIC MEMBRANE	CHAO ET AL.	1940	CAT	CORTICAL SURFACE	PREVENT ADHESIONS	NO ADHESIONS IN MOST CASES FINE ADHESIONS IN OCCASIONAL CASE
	ODOM	1940	CAT	CORTICAL SURFACE	PREVENT ADHESIONS	ADHESIONS IN MOST CASES
BEEF ALLANTOIC MEMBRANE	CHAO ET AL.	1940	CAT	CORTICAL SURFACE	PREVENT ADHESIONS	FEW ADHESIONS AND SLIGHT CELLULAR REACTION
CATGUT MEMBRANE	CHAO ET AL.	1940	CAT	CORTICAL SURFACE	PREVENT ADHESIONS	MODERATE ADHESION FORMATION AND MODERATE CELLULAR REACTION
SHEEP PERITONEUM	HANEL	1909	Dog	DURAL DEFECT	DUROPLASTY	MEMBRANE RESORBED AND DURA-LIKE MEMBRANE SUBSTITUTED. NO ADHESIONS
CALF ARTERY	RITTER	1910	Dog	DURAL DEFECT OVER SPINAL CORD	DUROPLASTY	NO ADHESIONS.

the laceration but was smooth and non adherent except by a few trivial and delicate adhesions around the edge of the dural opening. Greer (1901) and Prime (1909), also reported observations on this membrane. Prime noted adhesions in his dogs in every instance when the cortex was damaged.

Other non-viable animal membranes which have been subjected to investigation are Cargile membrane (Craig and Ellis 1905, Prime 1909, Chao et al 1940), prepared hernia sac (Finster 1910, Von Saar 1910), Human amniotic membranes (Chao et al 1940, Odom 1940), sheep peritoneum (Hanel 1909), and calf artery (Ritter 1910).

These non-viable membranes have, from time to time in the past, shown great promise in the prevention of meningo-cerebral adhesions. This was especially true of amniotic and allantoic membranes. Chao reported (1940) that of all the animal tissue used fat produced the most severe cellular reaction and human amniotic membrane the least. Cargile membrane gave a poor result. When it was placed over pia that had been slightly injured dense adhesions resulted.

Chao and al (1940), extended their observations over intervals extending from 10-60 days after the lacerated brain had been covered with amnioplastine. In no instance was there evidence of gross adhesion. The amnioplastin sheet progressively disappeared. In the 10 day animals a mucoid material which represented the membrane was to be found in the space between

TABLE 4.

A compilation, without reference to worker or date showing materials primarily used in section and also those thought to be primarily chemical in section.

TABLE 4.

A compilation, without reference to worker or date showing materials primarily mechanical in action and also those thought to be primarily chemical in action.

MATERIALS PRIMARILY MECHANICAL IN ACTION DUE TO:

- A. SEPARATION OF DENUDED OR TRAUMATIZED SURFACES
1. VIABLE ANIMAL MEMBRANES
 - PERITONEAL GRAFTS AND FLAPS
 - OMENTAL GRAFTS AND FLAPS
 2. NON-VIABLE ANIMAL MEMBRANES
 - GLOBEATER'S SKIN (SEROSA OF OX CAECUM)
 - SHARK PERITONEUM
 - CARGILE MEMBRANE (OX PERITONEUM)
 - WOVEN CATGUT
 - HUMAN AMNIOTIC MEMBRANE
 - BEEF AMNIOTIC MEMBRANE
 - BEEF ALLANTOIC MEMBRANE
 - CALF PERITONEUM
 3. LUBRICANTS
 - MUCILAGE OF GUM ARABIC
 - LANOLIN
 - PARAFFIN
 - OLIVE OIL
 - LIQUID PETROLATUM
 - VASELINE OIL
 - CAMPHORATED OIL
 - HUMANOL
 - MUCIN
- B. EFFECT ON THE MOTILITY AND MOBILITY OF THE GASTROINTESTINAL TRACT
1. THROUGH PERISTALTIC ACTION
 - CATHARTICS
 - PHYSOSTIGMINE
 - PHYSOSTIGMINE WITH STRYCHNINE
 - GASTRIC LAVAGE
 2. THROUGH VARIOUS PHYSIOTHERAPEUTIC MEASURES
 - MASSAGE OF THE LOWER ABDOMEN
 - POSTURING TO SEPARATE TRAUMATIZED SURFACES
 - PERIODIC DISTENTION OF THE COLON WITH OXYGEN OR ENEMATA
 - PERIODIC DISTENTION OF THE BLADDER WITH BORIC ACID SOLUTION
 - LOCAL HEAT TO THE ABDOMEN

MATERIALS PRIMARILY CHEMICAL IN ACTION DUE TO INHIBITORY EFFECT ON ADHESION FORMATION:

1. SUBSTANCES USED ORALLY
 - SYRUP OF HYDRIODIC ACID
 - THIOSINAMINE
 - FIBROLYSIN (THIOSINAMINE WITH SODIUM SALICYLATE)
 - PHOSPHOROUS
2. SUBSTANCES USED HYPODERMICALLY
 - PEPTONE
 - PHYSOSTIGMINE
3. SUBSTANCES USED INTRAPERITONEALLY
 - 5-20% SOLUTION OF MAGNESIUM SULPHATE
 - NORMAL SALINE WITH ADRENALIN
 - AMMONIUM OXALATE SOLUTION
 - SODIUM CITRATE SOLUTION CONTAINING GUM ARABIC
 - SODIUM CITRATE SOLUTION CONTAINING SODIUM CHLORIDE
 - HIRUDIN SOLUTION
 - FIBROLYSIN SOLUTION
 - PEPTONE SOLUTION
 - AMFETIN (AMNIOTIC FLUID)
 - PEPSIN-PREGL IODINE SOLUTION
 - PAPAIN SOLUTION
 - TRYPSIN SOLUTION
4. MISCELLANEOUS FILMS
 - ARISTOL (THYMOL IODIDE)
 - AGAR
 - GELATIN (PLAIN AND FORMOLIZED)
 - AGAR GELATIN
 - CARRAGEN (ISLAND MOSS)
 - COLLODION
 - VITREOUS HUMOR OF CALF EYE
 - EGG ALBUMIN
 - GUTTA PERCHA SOLUTIONS
 - SILK PROTECTIVE
 - SILVER FOIL
5. LIQUIDS
 - RAW MILK
 - PEPTONIZED MILK
 - HYPERTONIC SALINE
 - HYPERTONIC GLUCOSE
 - NORMAL SALINE
6. GASES
 - OXYGEN
 - NITROGEN WITH AIR

injured cortex and re-forming dura. At 30 days no gross or microscopical evidence of membrane could be found. Microscopically in the ten day group there was no evidence of any foreign body reaction, and no organized adhesions. Chao believed that the growth of fibroblasts beneath ~~and~~ above the membrane was a reaction to the presence of a vanishing foreign body. By twenty days the dural defect had completely filled in, the pia had partially closed over the destroyed brain, and the membrane between the two was represented by a thin amorphous material.

Rogers(1941), reported his experiences in the treatment of peripheral nerve injuries with amnioplastin. None of the cases reported had extended over one year, and Rogers had not had the opportunity to reopen a wound and re-examine a nerve trunk that had been isolated by the membrane some time previously. It need hardly be added that a much longer time will be required to ascertain whether the late results of these peripheral cases are good, and for an opportunity to occur by which it may be ascertained from the condition of the operation field whether neural isolation persists and whether the membrane is absorbed as completely in man as in experimental animals of Chao et al (1940).

Pinkerton(1942) used amnioplastin in the treatment of adherent digital flexor tendons. The membrane used was as recommended by Chao et al (1940), and Penfield(1940). In all cases the superficial tissues remained freely movable over the tendon for three months after operation. In one case the

amnioplastin was examined "in situ" two months after insertion. It was found as a thin, transparent gelatinous membrane, from which the overlying fibrosed tissues were easily separated, and beneath which the tendons could be seen to move freely, Here the cases were only of four months duration when reported, and an observation over a much longer period of time would be of more value.

Pudenz and Odom(1942), in their experimental study found that the amniotic membrane, prepared according to their procedure, was completely absorbed at the end of 92 days. They also felt that this membrane was ~~relatively unassociated~~ with an inflammatory cell reaction, but that an intense inflammatory cell response was associated with the viable type which contained an epithelial layer.

Miscellaneous. There remains for consideration a number of materials which are best classified under the heading of miscellaneous. It includes various substances of plant or mineral origin as well as the newer plastic and synthetic materials. The various substances which have been used with rather poor results include rubber tissue(Abbe 1897), celluloid(Hantsch 1922), parchment(Oberniedermayer 1928), mica(Chao 1940), Cellophane(Chao 1940), Olive oil(Prime 1909), polyvinyl alcohol compounds(Pudenz and Odom 1942).

Cellophane and mica were found to promote dense adhesions and mild cellular reactions. Less is known of the Polyvinyl alcohol compounds. Little has been written of them. These compounds are used commercially in the manufacture of shatterproof glass. Their chief attraction is the change in

A miscellaneous list, including reference to recent work on plastics.

TABLE 2

TABLE 5.

**A miscellaneous list, including reference
to recent work on plastics.**

MISCELLANEOUS

<u>MATERIAL</u>	<u>OBSERVERS</u>	<u>YEAR</u>	<u>ANIMAL</u>	<u>LOCATION</u>	<u>PURPOSE</u>	<u>RESULT</u>
RUBBER TISSUE	ABBE	1897	MAN	CORTICAL SURFACE	PREVENT ADHESIONS	DENSE ENCAPSULATION
CELLULOID	HANTSCH	1922	RABBITS DOGS	SKULL DEFECT WITH DURA EXCISED AND BRAIN DAMAGED	STUDY OF REACTION	ENCAPSULATION WITH ADHESIONS TO CORTEX
PARCHMENT	OBERNIEDERMAYER	1928	RABBIT	DURAL DEFECT	DUROPLASTY	ENCAPSULATION WITH ADHESIONS TO CORTEX
MICA	CHAO ET AL.	1940	CAT	CORTICAL SURFACE	PREVENT ADHESIONS	DENSE ADHESIONS AND MODERATE CELLULAR REACTION
CELLOPHANE	CHAO ET AL.	1940	CAT	CORTICAL SURFACE	PREVENT ADHESIONS	DENSE ADHESIONS AND MILD CELLULAR REACTION
OLIVE OIL	PRIME	1909	DOG	CORTICAL SURFACE	PREVENT ADHESIONS	DENSE ADHESIONS EVEN THOUGH CORTEX NOT WOUNDED
POLYVINYL COMPOUNDS	PUDENZ	1942	CAT	CORTICAL SURFACE	"	DENSE ADHESIONS and INFLAMMATORY CELL REACTION.
FIBRIN FILM	INGRAHAM ET AL	1944	MONKEY	"	DUROPLASTY	MINIMAL CONNECTIVE TISSUE RESPONSE.
POLYTHENE FILM	BROWN ET AL.	1947	DOG	CORTICAL SURFACE	"	SIMILAR TO TANTALUM.

solubility rate obtained by modifying their structural formulas. The replacement of the hydroxyl groups of polyvinyl alcohol with acetate groups eventually changes the compound to polyvinyl acetate. The compounds formed in the stages of transition vary in their solubility. Theoretically the most attractive compound would be one which would remain intact for at least a month. This length of time would permit the protected arachnoid to repair itself without invasion from the overlying structures. Only two papers on the use of polyvinyl alcohol compounds can be traced in the literature. That of Pudenz and Odom(1942), and Dötzer (1938), who reported experiments on the reaction of bacteria in contact with polyvinyl alcohol. The experience of Pudenz and Odom(1942), with polyvinyl alcohol compound is extraordinarily disappointing. In a series of five animal experiments encapsulation was maximal and the response of inflammatory cell types was intense. This included polymorphonuclear leucocytes, small round cells, phagocytic cells and foreign body giant cells. Dense adhesions occurred in all cases. Review of the micro-photographs of this work shows that in some instances the polyvinyl alcohol film showed no evidence of resorption and cellular reaction was most intense. Obviously, the evidence from this study would indicate this material aggravates, rather than retards or prevents, the formation of adhesions. None the less it would be rash to dismiss the material on this basis alone, since if a controlled resorption of one of the many compounds could be established, it might well prove a useful material in clinical practice.

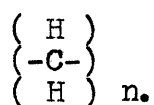
In 1944 Ingraham and Baily published an account of the use of fibrin films in the repair of dural defects and in the prevention of meningo-cerebral adhesions. This substance, fibrin film, was prepared by the fractionation of human blood plasma. This material was subject to wide variation by small alteration in the conditions of preparation. In order to determine the reaction of the cerebral cortex to these fibrin films, Ingraham and Baily 1944, performed craniotomies on 10 monkeys. The cerebral cortex was traumatised by multiple needle wounds (10-25) penetrating the cortex for at least 2 millimeters. These needle wounds were distributed as to cause bleeding in every instance. The animals were sacrificed after periods of observation from 24 hours to 6 months. Up to one week the film had changed its appearance but little, and there were only a few wandering cells about it. As time went on, the film became surrounded by a small amount of fibrous tissue from which it could be easily separated. In monkeys allowed to survive for more than a month, parts of the films could be seen broken up with some giant cells about the small isolated fragments. But the end result was a layer of fibrous tissue about the same thickness as the original films. At the end of six months there were no adhesions, but the layer covering the cerebral cortex was found to be composed of thin transparent tissue rather than film. When the bone had been rongueured away and the skull defect pertained the overlying temporalis muscle was closely adherent to the film although the subdural space was free from adhesions. The film had been used

clinically in 44 patients and different opportunities had arisen for examination of films at intervals varying from 14 hours to 81 days after implantation. Grossly, there was no evidence of inflammatory reaction and there were no adhesions. Histological examination disclosed the same features as described in the experimental animals.

Ingraham, Bailey and Cobb (1945), set out to perfect a sterilisation technique for the fibrin film less cumbersome and more practical than the glycerol method used in the 1944 report. They decided on steam pressure sterilisation and reported animal and clinical studies using the film prepared in this fashion. The arachoid, pia and superficial cerebral fissures were lacerated several times by the use of a curved French needle and the monkeys killed at an interval of one day, two weeks, and one, two, three, five and six months after operation. Pathologic studies indicated that the fibrin films were gradually replaced by a neomembrane of fibrous tissue without the formation of meningo-cerebral adhesions. Absorption of the fibrous film was almost complete at three months, and no film remained at five and six months after operation. A further paper from their laboratories(1947) reported on the insertion of fibrin film between the sutured dura and the intact leptomeninges. Where the fibrin films were inserted, no evidence of adhesion could be seen, whereas on the control side, adhesions were present in all the animals, and when the brain was separated from the dura small fragments of the cortex were pulled out by several of the small firm adhesions.

This experiment demonstrates that in the monkey at any rate, small firm adhesions may form between the brain and dura where silk sutures used to close the dura lie in contact with the leptomeninges.

It is only to be expected that the great strides made by the plastic industry should stimulate interest in the possible application of many of these substances in the surgical field. However, the number of synthetic plastics which can be buried safely within human tissues is surprisingly small. Methyl methacrylate and nylon (Ingraham et al 1947), have been found to be well tolerated by the tissues. The latest material found to fulfil most of the requirements is "Polythene". Polythene is a long chain polymere of ethylene and has, on theoretical grounds the simplest chemical formula of all the plastics. Each molecule is formed of a saturated alophatic hydrocarbon chain, each carbon atom of which carries two hydrogen atoms



As it is now manufactured, Polythene has a molecular weight of about eighteen thousand which is very suitable for extrusion into tube and thin sheets. This form of plastic has a micro crystalline structure which does not require the aid of a plasticizer, which is generally a tissue irritant, to make it flexible and pliable. Polythene stretches without breaking easily, but has relatively little elasticity. It can be extended easily in the form of tubes of any conveient size, or sheets of any desirable thickness.

Ingraham, Alexander and Matson(1947), reported results in the

implantation of polythelene directly into the cerebral cortex(1), and (2) in the replacement of an area of excised dura with polythelene film. Tissue reaction were studied in 65 animals sacrificed at 5, 7, 10, 14, 21, 30, 60, 90, and 150 days. None of the animals showed evidence during life of cerebral irritation or of any unusual behaviour that could be attributed to the presence of the polythelene.

Histologic section through the area of implantation up to 10 days showed no ~~more~~ tissue reaction than was found adjacent to a control stab wound elsewhere in the cortex.. No collections of polymorphonuclear leucocytes were found in any of the sections. Sections made through the implantation sites in experiments lasting more than 10 days showed a thin layer of glial tissue and slightly compressed cerebral tissue around the cavity containing the plastic. The glial layer was one to three cells in thickness and increased gradually over the weeks, until at 90 days it was six to eight cells thick. The surrounding cerebral tissue showed no increased vascularity and no inflammatory or foreign body reaction.

In 32 cats polythelene film 0.002 inch (0.005cm) in thickness was used to replace dura, there being no injury to the cortex. The necessity for obtaining and using only the pure product was emphasised here since in the earlier experiments where presumably an impure quality was used, there developed relatively large hematomas between the arachnoid and the film, which were very gradually absorbed and replaced by fibrous tissue.

In the last 13 cases the pure film apparently was used and no hematomas were encountered. Animals killed in less than 10 days showed no gross or microscopic reaction around the film, and the underlying cortex was plainly seen through it. After 10 days it became apparent that the film was being gradually encapsulated by a thin neomembrane on both the inner and outer surfaces. These layers were apparently derived from the dura. The inner surface was generally adherent to the underlying arachnoid by filmy adhesions. In animals allowed to survive 30-90 days, the film was found completely enclosed by a thin non-adherent fibrous envelope and there was mild thickening of the arachnoid.

In only three animals was polythene placed over damaged cortex, replacing the dura. One animal was re-explored after three days the others after 20 days. There was no gross reaction to the film in the animal explored after three days, but in the animals studied after 20 days there were adhesions to the neomembrane enclosing the film. Systematic experiments had not been performed to determine the effectiveness of polythene film in preventing meningo-cerebral adhesions over damaged cortex, but it would appear that the final stage would be comparable to the findings of Pudenz and Odom(1942) in regard to tantalum, namely, that the film would become encapsulated by a thin fibrous envelope, the undersurface of which was adherent to the cortical cicatrix. Brown, Grindlay and Craig(1948) reported the use of polythene film in duroplasty in 10 animals. In 2 animals the cortex was lacerated. The tissues were inspected at intervals of 2, 4 and

6 months. In all cases the film was entirely non-adherent to the underlying leptomeninges and cerebral cortex. Grossly and histologically a thin subdural neomembrane formed between the film ~~and~~ the arachnoid. This neomembrane was non-adherent and could be easily dissected of the underlying arachnoid in the two wounded and in the unwounded animals. No foreign body giant cells were seen. Clinically these authors had used the film in order to prevent adhesions between the brain and the extracerebral structures in lobotomy. No observations on the efficacy of this procedure are recorded.

Busch, Bing and Hansen(1949), reported on the use of gelatin and polythene film as dural substitutes. They prepared the gelatine films from formalin hardened gelatine to which had been added sulphonated lauryl-alcohol to make the film more flexible and easier to stitch. Four cats were trepanned and the dura corresponding to the trepannation orifice was removed. A piece of gelatine film was then inserted, its margin extending under the edge of the cranial defect. One cat presented a favorable result whereas examination of the others revealed broad adhesions which could not be divided without tearing of a small tissue of cerebral tissue. Accordingly, the gelatine film prepared by this method must be regarded as valuess in the prevention of meningo-cerebral adhesions and a poor dural substitute. Their experiments with polythene film were carried out using film 0.10mm. thick and sterilized with formaline Preliminary subcutaneous, intra-peritoneal and intrathoracal application in rats showed that it was unabsorbable and induced no tissue reaction. Further,

in one rat a bag of polythene was placed about one kidney and slight hemorrhage was caused by the manipulation. Two weeks later there were no adhesions between kidney and films, or between film and surrounding tissues.

The practical usefulness of polythene film was verified by experiments on 3 dogs. In two of the dogs, a small defect was produced in the surface of the brain, as well as a piece of dura removed, with the red hot point of a pair of forceps. The animals were killed 6, 8, and 10 weeks after the operation. In all cases there were adherences between bone and brain on the control side, but in none of the animals were there any adherences between the polythene film and the brain.

Following this experimental investigation Busch et al (1949) used polythene film 0.06 mm. thick in 51 clinical cases where a dural substitute was required with apparently satisfactory immediate results, but no histological studies are presented of re-examination of this material.

POST TRAUMATIC EPILEPSY.

HISTORICAL REFERENCES.

In the Broca museum in Paris there are trephined skulls of neolithic man which Broca argued as evidence of fanciful, ritualistic or religious proceedings. Victor Horsley believed that the trepanations were in some instances attempts to cure Jacksonian convulsions (Ballance 1922). They may well have been traumatic in origin. Hippocrates pointed out that a blow on one side of the head might be followed by contra lateral paralysis or convulsions. The evidence that he used the trephine for such conditions is not definite. Likewise, although Galen and Celsus both used the trephine, that they did so for post traumatic epilepsy is doubtful. References to trepanation for abscess and for fracture of the skull are frequent in the writings of the thirteenth, sixteenth and seventeenth centuries. Percival Pott (1713-1788) indicates clearly that the symptoms following head injury are due to brain injury, not to skull fracture. Jean Louis Petit (1674-1750) lists as indications for trephining: fracture, Unconsciousness, haemorrhage from the nose, mouth and ears, paralysis and convulsions and he goes on to state that trephining should not be done to cure convulsions but to remove the particular cause of them.

Ballance quotes a detailed statement of Peter de Marchettis of a case reported in 1665 (Obs.Medico-Chirurg. vii p.11)
 "I remember having a consultation with D.JULIO SALA , professor at Pavia, about a man who had been wounded in the head with a dagger. Not only was the bone injured, but the

membranes and even the brain. The external wound had been treated by certain practitioners and a cicatrix had formed. After two or three months the patient was troubled with epilepsy and had a fit twice or three times a month. When asked by Professor Sala whether he had ever had an injury to the head, he replied that he had and pointed out the place. I immediately inserted a probe beneath the crust and found a penetrating wound and proceeded at once to operation and the opening of the parts. The next day I applied the trephine; yellow pus escaped. For twenty days I applied black western balsam with the use of which the wound granulated, and in thirty days the patient was cured of his wound and of his epilepsy!"

Writing in the next century, Astley Cooper in his lectures on the Principles and Practice of Surgery relates a cure of Jacksonian epilepsy by the operative removal of a spicule of bone. The epilepsy began six months after the injury. Because of increase in the number of attacks decompression operation was done in 1822 and sixteen years later the man was still attack free (Cutter 1930). George James Guthrie (1785-1856) Surgeon in the Peninsular War, recognised that "local pain and epilepsy may follow fracture of the inner table and require operation (Ballance). Larrey (1766-1842), Napoleon's Surgeon General, makes frequent mention of traumatic epilepsy and relates one case of cure (Cutter).

Wells, writing in 1812 (Cutter) clearly describes the case of a negro who, having sustained a right parietal depression, subsequently developed fits and hemiplegia. Trephining resulted in practical disappearance of the hemiplegia but the patient

was still liable to his seizures when excited. Benjamin W. Dudley, Professor of Surgery in the Transylvanian Medical at Lexington, was the first American surgeon to give special attention to traumatic epilepsy and its cure by decompressive operation. Between 1818 and 1827 he reported five cases. All of these cases had too short follow up periods for any significance to be attached to the results. Bright (1836) should be mentioned because his is the first clear description of Jacksonian epilepsy although not due to trauma but seemingly a vascular accident.

John S. Billings, founder of the Surgeon General's Library at Washington, in his first published medical article (1861) wrote on "The surgical treatment of epilepsy" (Cutter). He lists seventy two cases of decompression with sixteen fatalities, forty two reported cures, four cases unimproved and the remaining ten were classed as improved although not entirely relieved. At least some of these cases were of traumatic epilepsy for he includes Dudleys cases (vide supra).

INCIDENCE OF POST TRAUMATIC EPILEPSY.

Peace time: Lenormant (1921) gathered together the reports of several authors upon the occurrence of traumatic epilepsy in times of peace. Brun, among 221 cranial injuries of all types, reported 18 cases - 8%. Braun in a similar group made up of 291 cases, reported 15 epileptics, - 5.2%. Of these, there were thirty gunshot wounds, one of whom developed epilepsy. Gordon and Wilson record 14 epileptics among 530 fractures of the base - 2.6%. Neumann, among 108 cranial traumata on an infants

service, found 3 cases of epilepsy - about 3%. This finding is in agreement with that of Ford (1926) that 2 or 3% of all epilepsies seen in children are related to birth injury. Muskins (1928) in 1000 cases of head injury seen in private practice found only 8 epileptics. Steinhil (1929) quotes Reichman as finding a .5% incidence among 603 peace time injuries while he himself, among 531 cases seen in his own private practice between 1907 and 1926, saw only one epileptic. Later figures include those of Schou (1933), Russell (1934), Rowbotham (1942), Feinberg (1934) and Penfield (1944). Schou found 4.5% of epilepsy in 200 cases of head injury reported to a Dutch insurance company. Russell 3.5% in 200 cases of head injury and Rowbotham 2.5% in 450 cases. Feinberg found 50 cases (0.1%) of traumatic epilepsy in 47,000 cases of head injury reported to a Swiss insurance company. In this instance, obviously, the background is all types of head injury. This unusually low incidence has been severely criticised by Garland (1942) on the ground that idiopathic epilepsy alone occurs more frequently in the general population. Feinberg's figures however, give the cases of traumatic epilepsy after deduction of cases of epilepsy of other kind (70 cases) and it should be taken into account that idiopathic epileptics with early onset of fits would not have been insured by the company. These figures therefore are the largest unselected group of head injury figures we possess at present, with regard to civil incidence. Penfield (1944) in an analysis of 407 cases of head injury followed up over a 2 - 14 year period found an incidence of 2.7%. Penfield did not include in this "early fits" which

he considered as a symptom only. Were these included the total incidence would be 5.2%.

Figures consequent to war injuries: The incidence of epilepsy consequent to war wounds is much higher than that recorded above during peace time. Allen (1906) notes that among 167 skull injuries of the American Civil War 23 or 13.7% were on the pension list because of epilepsy. Among 571 cases of recovery from gunshot wounds of the skull in the Franco Prussian War, as reported by von Bergmann for the German Army 25 or 4.3% developed epilepsy. If to these cases of epilepsy there be added those with periodic attacks of dizziness, numbness, trembling etc the percentage is raised to 26.7%. In the Russo Japanese War, Eguchi found 35 cases among 1,000 skull injuries (3.5%), but two years later Holbeck succeeded in tracing 65 cases which he had treated in the same war. Of these 19 or 29.2% had become epileptic (Lenormant).

The first World War provided abundant material for the study of this problem, yet the results recorded are very discordant.

Sargent and Holmes (1916), reporting on 610 cases, only 15% of which had been followed for more than a year, found 37 epileptics, 6%. Eight of these cases, however, had had only one seizure; in 11 only were convulsions frequent.

Behague (1919) in a comprehensive study of the cases in P.Marie's clinic, numbering 3,623 head injuries, found an incidence of 12.1% of epilepsy. Two thirds of the cases were generalised, the remaining third were Jacksonian. Lenormant

Lenormant (1921) produced the following figures:

French:

Souques, 9 in 33, 18%

Chiray, 57 in 276, 20.8%.

H. Claude, 24 in 247, 10%.

Villaret, 53 in 256, 20.7%.

Babinski, F. Netter, 34 in 150, 22.6%.

Carriere, in a collection of one thousand wounded, 6%.

Sollier, 15%.

Tuffier and Gullain, 676 in 6,664, 10.4%.

Billet (Statistique de l'Autochir. 6) 26 in 167, 5%.

Belgian:

Derache, 2 in 24, 8.3%.

Janssen-Denot, more than 10%.

American:

H. Neuhof, 3 in 175, 1.8%.

English:

W.W. Wagstaffe, 9 in 710, 1.3%. (See text)

German:

Roper, 16 in 134, 11.9%.

Tilman, 15-20%.

Amelung, 74 in 520, 14.2%.

This compilation must be taken in conjunction with the figures presented in later studies.

Rawlings (1922) among 452 British cases found an incidence of 25%. These results were based upon a questionnaire sent out to 750 men. The results cannot therefore be regarded as entirely reliable but they are of value because a slightly longer time had elapsed since injury than in most of the studies mentioned above.

Turner (1923) in a review of 18,000 cases of gunshot wound of the head among British troops found that only 800 or 4.5% had become epileptic.

Falling between the percentages of Rawlings and Turner is that of Wagstaffe (1928). This was a thorough study with an eleven year survey period. Of a total of 377 cases of all kinds (penetrating dura, fractured skull but dura not penetrated, scalp wound only, concussion and fractured bone), 37 or 9.8% developed seizures.

Schönbauer (1929) cites 95 cases of Bouskin, of gunshot wound of the head, 32 of which developed late epilepsy. He refers also to 43 cases of Bychovsky reported in 1925. Of these 16 or 37% were suffering from Jacksonian attacks.

Steinthal (1929) on the basis of the 639 surviving gunshot wounds studied so carefully with Nagel two years previously arrived at a figure of 28.9% or 185 cases of epilepsy. If von Bergmans inclusion of cases of dizziness, numbness etc are included the percentage is raised to 35.5%. If one compares the figures of Wagstaff with those of Steinthal there appear great differences.. The German incidence (28.9%) is three times that of the British (9.8%). Steinthal maintains that wounding of the dura plays little part whereas Wagstaffe finds epilepsy ten times more common after penetrating

wounds of the dura than after non penetrating. These striking differences can only mean lack of a common basis for classification and interpretation.

The last reported follow up study of wounds resulting from World War I is that of Ascroft (1941) who investigated 317 cases. The material did not include those who died within the first few years as a result of head injury. It is not easy, as a rule, to determine from questionnaires or perhaps records whether or not a patient has had fits, but it is reasonably safe to assume the fits to be genuine when they are accepted as an attributable disability by medical boards. The majority of the men in this series of Ascroft had been admitted to Ministry of Pension Hospitals for observation, often for long periods. Of these 317 cases 107 or 34% had fits. Ascroft is confident this is not an overestimate. He goes on to demonstrate quite clearly that fits are twice as frequent when the dura is penetrated. Nearly half (45%) of such cases were affected. The relation between sepsis and the incidence of fits is also stressed by Ascroft. In his series fits developed twice as often in cases of severe and prolonged sepsis as in those healing by first intention. This fact he convincingly demonstrates by analysis of his figures. Since both fits and sepsis are commonest when the wounds are deep and severe the apparent relation between sepsis and fits might be fictitious. He therefore grouped the cases according to the integrity of the dura mater and showed that the same relationship held.

Relationship between epilepsy and wound sepsis (Ascroft)

Dura intact	Healed in 15 days	12%	% with fits.
	Unhealed in 60 days	32%	
Dura penetrated	Healed in 15 days	36%	
	Unhealed in 60 days	57%	

The importance of injury to the dura had been appreciated by Sargent (1921) and by Foerster and Penfield (1930) and was clearly demonstrated in an analysis of gunshot wound material from the 1914-18 War by Credner (1930). This series numbered 1980 cases, with at least five years follow up, 331 for more than ten years. Credner states implicitly that they are all serious head injuries and excludes those with loss of consciousness of brief duration and without neurological findings. Of the whole group, 755 or 38.2% became epileptic. Open brain injuries (dural wound) - 1234 cases - 49.5% fits. Skull injuries without brain damage - 417 cases - 20.3% fits. The statistics of Credner closely parallel those of Ascroft (1941) and the material from which they are drawn is very similar.

Reviews of the results of cranio cerebral injuries sustained in World War II have made their appearance during the past few years but it is as yet too early to make a final assessment. Maltby (1946) found 17% of 250 penetrating wounds to the head had had convulsions, but his cases were only followed for a short time. Watson (1947) summarised the results of a study dealing with the incidence of "late" epilepsy among 279 penetrating head injuries resulting from the 1939-45 war. The follow up period was two years. In all of the cases seizures continued and they were not included

in the analysis if they did not have recurrent paroxysmal disorders of the same type. Of the 279 cases followed 36.2% developed seizures within the first two years following injury. In a review of 100 cases with surgically proved dural penetration and injury to the brain due to shell fragments or gunshot Aita (1948) reported that 34% had had at least one convulsive seizure since injury.

Ritchie Russell (1951) reviewed 18206 cases of brain wounds, and found that 43% had had one or more fits within the first five years after wounding. All of these wounds were 'penetrators'. Russell himself suggests that this information cannot be considered too accurate as many of the cases had to be assessed from questionnaire or 'fit form', but he believes that the incidence he presents is an underestimate, as all the doubtful cases went into the "no epilepsy" group. He further states that these figures show no striking change from the published records following the first world war, and this in spite of the vastly reduced incidence of infection in his series.

It will be easily seen, therefore, that of all the difficult questions surrounding the problem of traumatic epilepsy, the most difficult is the simple statistical estimate of its frequency. As shown above, the published figures vary from 49% to 1 in 1000 cases of head injury. The wide variation is in part only due to selection. Much depends on what one means by head injury and probably much more on what cases are counted as remaining free from epilepsy.

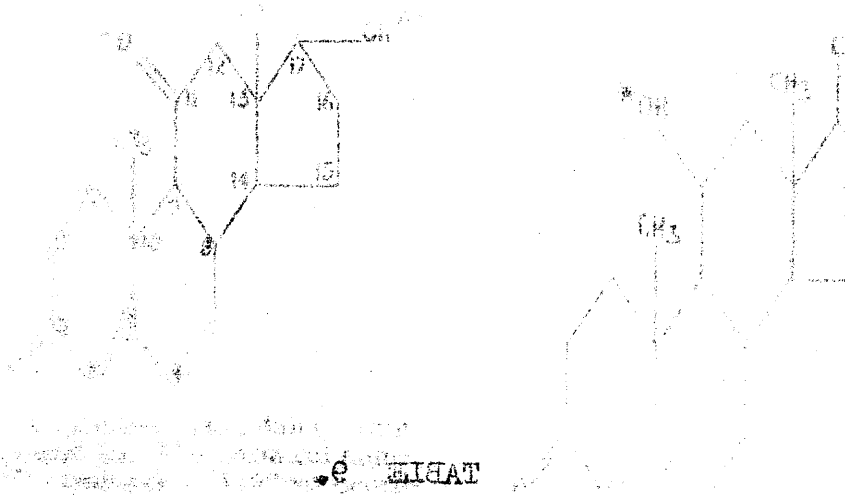
At one extreme is the objection that the experience of an operating military surgeon would include only severe head injury with much brain damage; at the other extreme is the fact that an investigator can hardly scrutinise, with a reasonable degree of accuracy, such a large mass of material as 17,000 or 18,000 cases.

THE PHYSIOLOGY OF THE ADRENAL CORTEX AND THE BIOLOGIC PROPERTIES OF CORTISONE

Cortisone is the name given to a compound which has previously been referred to as 17 - hydroxy - 11 - dehydro-corticosterone or as "Kendall's compound E". The isolation and characterisation of its general physical and chemical properties was accomplished independently by Mason, Meyers and Kendall, Wintersteiner and Pfiffner, and Reichstein (1936). Partial synthesis of cortisone has been accomplished by Sarett (1946).


The physiological effects of cortisone and its use in the treatment of diseases are closely interwoven with our knowledge of the pituitary-adrenal system. It is possible as a result of the advances of the past 20 years to present a satisfactory although incomplete account of the secretory activities of the pituitary and the adrenal cortex. In contrast, there is glaring deficiency in our knowledge concerning the mechanism of action of the cortical hormone on the target cells. Two fundamental principles of adrenocortical physiology have been emphasised by Ingle (1950):-

- 1) No fixed amount of cortical hormone represents a physiological dose; the needs of the organism vary widely, depending upon the activity and the environment of the organism. A dose which is pharmacological under optimal conditions may be less than adequate for the needs of the tissues during stress and may not prevent the development of hypocorticism.



The structure of cortisone and

related compounds.



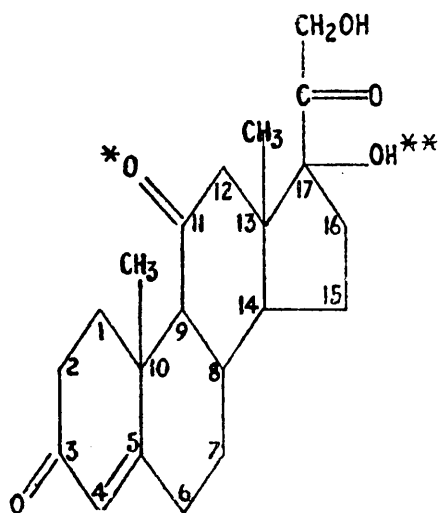
Structure of cortisone and related compounds. The structure of cortisone is shown above. The structure of cortisone is shown above.

Structure of cortisone and related compounds. The structure of cortisone is shown above. The structure of cortisone is shown above.

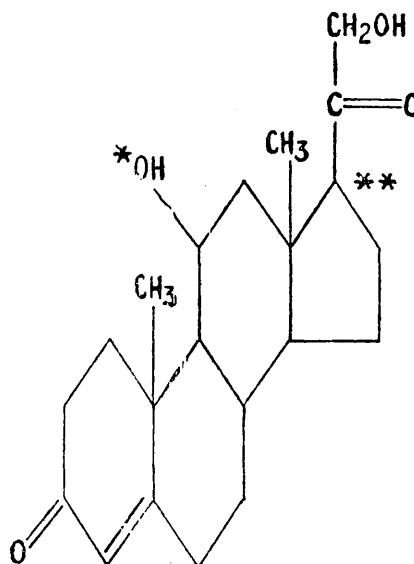
Structure of cortisone and related compounds. The structure of cortisone is shown above. The structure of cortisone is shown above.

TABLE 9.

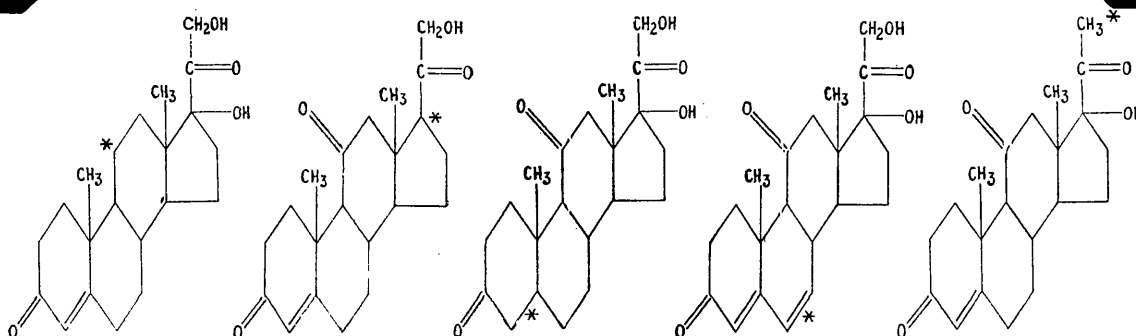
**The structure of cortisone and
related compounds.**



Cortisone (Kendall's compound E). The chemical name, 17 - hydroxy - 11-dehydrocorticosterone, is based upon points of difference and similarity between the molecular structures of cortisone and corticosterone (Kendall's compound B).



Corticosterone (Kendall's compound B)



Reichstein's compound S (11-desoxy-17-hydroxycorticosterone, or "desoxycortisone"). *Molecule differs from cortisone only by the absence of an oxygen atom at position 11.

Kendall's compound A (11-dehydrocorticosterone). *Molecule differs from cortisone only by the absence of a hydroxyl group at position 17.

Dihydrocortisone. *Molecule differs from cortisone only by absence of a double bond at position 4, 5 (presence of an extra hydrogen atom).

6, 7-Dehydrocortisone. *Molecule differs from cortisone only by presence of a double bond at position 6, 7 (absence of a hydrogen atom).

21-Desoxycortisone. *Molecule differs from cortisone only by the absence of an oxygen atom at position 21.

2) The actions of the cortical hormone are determined in no small measure by the functional status of the tissue cells themselves.

It should be realised that the cortical hormone plays a general supportive rather than an initiating role in bodily processes. The adrenal medulla initiates cellular and metabolic changes in response to an emergency, whereas the adrenal cortex plays a passive role and makes it possible for the various regulatory systems to expend the additional effort necessary for homeostatic adjustment.

The secretion of the adrenal cortex.

The exact nature of the secretion of the adrenal cortex is unknown. Present estimates regarding the number and character of steroids elaborated by the gland are purely conjectural and are mainly based on indirect evidence. Twenty eight crystalline steroids have been isolated from adrenal tissue, but this contributes little to the knowledge of the nature of the actual secretion of the gland. Many of the steroids isolated from the gland may represent intermediates in the synthesis of the cortical hormone or artefacts arising from the manipulations of the chemist.

(1) Multisteroid concept. Selye, in an attempt to explain the variety of metabolic patterns which the organism may assume under different environmental conditions, has postulated

the secretion of a "glucocorticoid", a "mineralocorticoid", a "lipocorticoid" and a testocorticoid". This concept implies that the secretion of the adrenal cortex may vary in composition according to the requirements of the organism.

(2) "N and "S" hormone concept. Albright (1947) has presented good evidence to support the view that the adrenal cortex secretes an "S" hormone (cortisone like compound) and an "N" hormone having the anabolic properties of an androgen. He believes the "S" hormone to be secreted under the influence of an adrenocorticotrophin and the "N" hormone under the influence of pituitary luteinizing hormone.

(3) Autonomy concept. It is known that following hypophysectomy the glomerulosa zone of the adrenal cortex thickens, whereas the fasciculata shrinks markedly and the reticularis disappears almost entirely (Deane 1946); phosphatase disappears from the zona fasciculata but persists in the zona glomerulosa. These observations have led Greep and Deane (1947) to assign to the glomerulosa zone the specific function of autonomously elaborating hormone regulating electrolyte balance; ACTH is limited in its action to the fasciculata from which is secreted hormone influencing carbohydrate metabolism. This concept implies that the character of a metabolic disturbance can determine the nature of the secretion of the adrenal cortex.

(4) Unitarian concept. This point of view regards the secretion of the adrenal cortex as relatively fixed in

composition but varying in rate. Furthermore, the possibility is entertained, without conclusive evidence, that a single steroid can account for all the metabolic activities of the gland. At first it is tempting to divide the various metabolic actions of the adrenal cortex among the 11,17-oxysteroids, D.C.A. like steroids and androgens. The conclusion has been reached by many that at least two major types of steroids 11, 17-oxysteroids and D.C.S. like steroids must be secreted by the gland in order to explain the diabetogenic as well as the sodium-retaining properties of ACTH in man. However, Forsham has shown (1949) that cortisone can induce sodium retention in patients with Addison's disease. Among clinical investigators, the impression seems prevalent that the normal adrenal cortex secretes androgen. None the less, the experimental and clinical data presented in support of this view may be explained just as reasonably on the basis of conversion of cortical hormone to androgens by the liver or other tissues.

The nature of the secretion of the adrenal cortex, therefore, remains in doubt. Analysis of adrenal effluent blood may help solve the problem and Nelson et al (1950) have already found only 17-hydroxy-corticosterone and possibly a small amount of cortisone in adrenal vein blood of the dog.

Regulation of the rate of secretion of adrenocortical hormone.

ENDOCRINE SYSTEM—GENERAL

TABLE 10.

Schematic representation of the
pituitary-adrenal relationships
as commonly accepted. See text
for discussion and analysis.

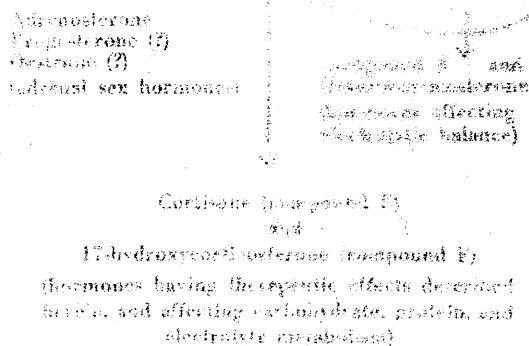
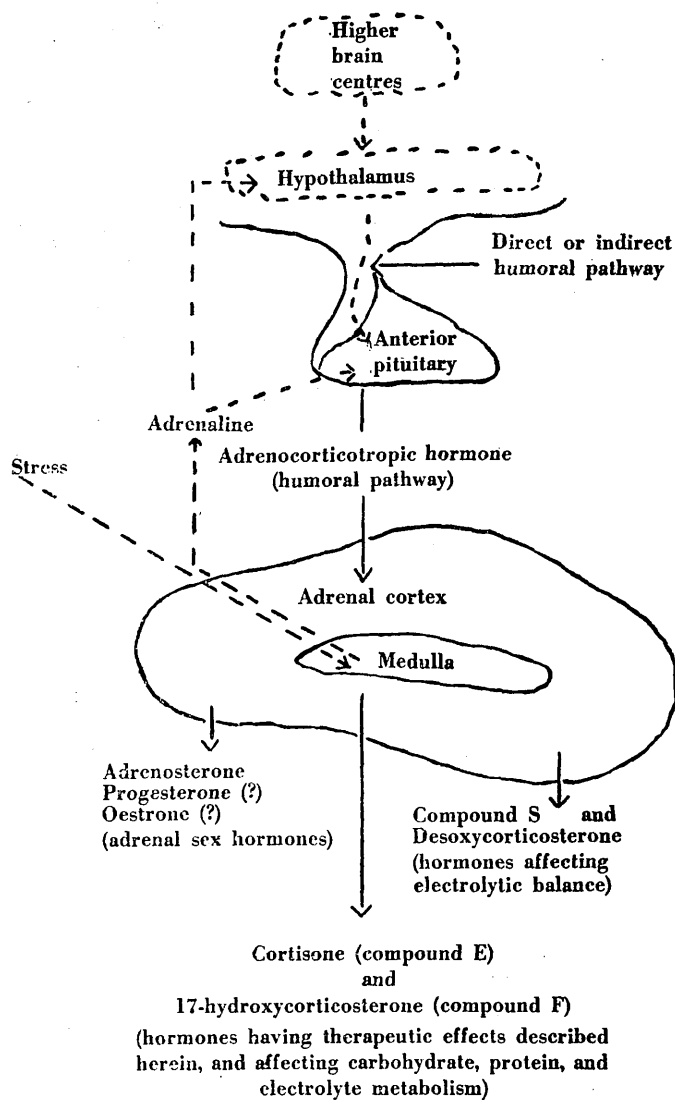


TABLE 10.

Schematic representation of the
pituitary adrenal relationships
as commonly accepted. See text
for discussion and analysis.

PITUITARY—ADRENAL RELATIONSHIPS



(1) Pituitary regulation of secretory activity of the Adrenal Cortex.

It has been firmly established that the discharge of ACTH from the adenohypophysis is an essential link in the series of events, initiated by stress, which activate the adrenal cortex. (Deane 1946, Ingle 1938)

The trophic factor which stimulates the adrenal cortex has been isolated as a homogeneous protein from sheep (Li, 1943) and Hog (Sayers 1943) pituitary tissue. No substance other than ACTH has been demonstrated to have a direct trophic action on the adrenal cortex. There is no evidence from chemical fractionation studies to support the opinion of Selye that the pituitary elaborates a "glucocorticotrophin", a "mineralocorticotrophin", a lipocorticotrophin" and a "testocorticotrophin".


(2) Regulation of Pituitary Adrenocorticotrophic activity.

The question next arises as to the nature of the regulatory mechanism which determines the rate of discharge of ACTH.

(1) A considerable body of indirect evidence can be marshalled in support of the concept that the titer of cortical hormone in the body fluids regulates the rate of discharge of ACTH from the adenohypophysis (Sayers 1950). Discharge of ACTH in response to moderate stress may be completely or partially blocked, depending on the dose of cortical steroid administered. Furthermore, with increasing

TABLE II.

A diagrammatic representation of
Selye's concept of stress.

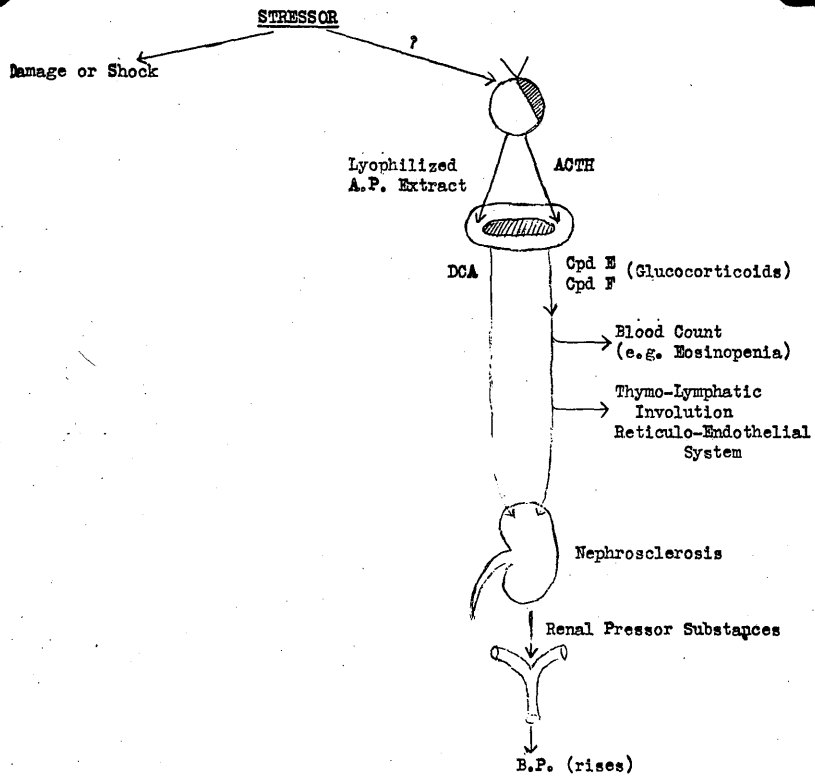


GLUCOCORTICOIDS


Glucocorticoids
decrease

TABLE 11.

**A diagrammatic representation of
Selye's concept of stress.**



COLLAGEN TISSUE



intensity of stress, the amount of cortical steroid required to suppress pituitary adrenocorticotrophic activity becomes correspondingly greater (Sayers and Sayers, 1947).

These quantitative relationships may be adequately explained if it is assumed that the rate of discharge of ACTH from the adenohypophysis fluctuates in accordance with the varying requirements of the organism for cortical hormone. This peripheral-humoral concept of regulatory control considers the activity of the adrenal cortex to be dictated by the requirements of the tissue cells of the organism for cortical hormone. The cortical hormone may act directly on the hypophysis or indirectly through some metabolite which varies in concentration as a result of the excess or a deficiency of the hormone. The multitude and complexity of changes which can occur in the blood bathing the pituitary gland forbids a ready answer to the problem. The peripheral humoral concept implies that a normal pituitary adrenocortical system does not allow an organism to be subjected to a plethora of cortical hormone, such as is suggested by the "diseases of adaptation" thesis of Selye.

(2) Central-neural and Central neuro-humoral mechanism.

The rapidity with which ACTH is released in response

to stress suggests the possibility that a neural or neuro-humoral factor is involved in acute situations. From the work of Cheng et al (1949), it is obvious that the integrity of neural or of neuro-vascular links between the hypothalamus and adenohipophysis is not essential for the discharge of ACTH. The experimental evidence, however, does not rule out the possibility that neural factors may modify the rate of discharge of ACTH from the pituitary.

(3) The role of the sympatho-adrenal system.

The close anatomical approximation of the adrenal medulla and cortex together with the fact that they both play important rôles in homeostasis naturally leads to some speculation regarding a possible integrative functional relation between the sympatho-adrenal and pituitary-adrenocortical systems. Vogt(1944) reached the conclusion that epinephrine has a direct stimulatory effect upon the adrenal cortex. Her experiments, however, do not rule out the possibility that epinephrine acts via the adenohipophysis to bring about a discharge of ACTH. Epinephrine may induce discharge of ACTH from the adenohipophysis by any of the following possible mechanisms:-

- 1) By central action on effector cells in the adenohipophysis or through the hypothalamus which in turn would activate the adenohipophysis.

2) Epinephrine may act like other non-specific agents and stresses to increase tissue utilisation of cortical hormone with a consequent lowering of venous titer of the hormone.

3) Epinephrine may be the denominator common to all types of stress and the specific agent which promotes utilisation of cortical hormone by the tissues.

Sayers (1948) and Long (1947) have suggested that epinephrine acts like other non-specific stresses and does not have a direct action upon the pituitary.

The nature of the regulatory mechanism or mechanisms which are concerned with the discharge of ACTH has an important bearing on the treatment of collagen diseases. The beneficial effects of cortisone or ACTH appear to be associated with the development of hypercorticism rather than replacement of a hormone deficiency. The possibility has been entertained that epinephrene, a substance more readily obtainable than cortisone or ACTH might be of therapeutic benefit by stimulating the discharge of ACTH from the pituitary. Epinephrine may be expected to be of therapeutic benefit if it acts centrally to bring about discharge of ACTH without regard to the rate of utilisation of cortical hormone by the tissues or to the titer of hormone in venous blood. On the other hand, if epinephrine acts by increasing the rate of utilisation of cortical hormone by the peripheral tissues, then it would be expected to be

of slight benefit at most; for the tissues will not be flooded with an excess of cortisol hormone, but rather they will receive quantities of hormone appropriate to the increased needs induced by epinephrine.

The titer of cortical hormones in the body fluids appears to play a major role in the regulation of pituitary adrenocorticotrophic activity. The exact nature of the process by which the changing levels of cortisol hormone in the blood influence the rate of discharge of ACTH from the adenohypophysis is unknown; it is here that the peripheral humoral concept is particularly vague.

Increased rate of utilisation of Cortical hormone during stress.

At the present time, it is not possible to determine whether the increased rate of "utilisation" of cortisol hormone which accompanies stress is

- 1) shared by all cells of the organism,
- 2) involves only those cells affected by the stress stimulus,
- 3) is participated in by both injured cells and buffer organs attempting to restore homeostasis.

Despite the lack of particulars, certain broad aspects of the problem of cortisol hormone "utilisation" in

stress are worthy of consideration. In general, it would appear that rate of cortical hormone "utilisation" parallels cellular activity and that the hormone is necessary for the mobilisation of cellular work. (Means, 1949; Ingle, 1938).

The indices of the rate of secretion of adrenocortical hormone.

It may be stated that there is no entirely satisfactory method for measuring the secretory activity of the adrenal cortex. Indices for the assessment of adrenocortical activity may be classed under four general headings, according to whether measurement is made of:-

- a) alterations in the adrenal cortex.
- b) alterations in the organism
- c) rate of excretion of steroids in the urine.
- d) titer of corticoids in the blood.

Continued hyperactivity of the adrenal cortex is associated with an increase in the size of the gland. (Tepperman, 1943).

Histological techniques have been employed to measure fluctuations in the secretory activity of the adrenal cortex and to differentiate the zones of the adrenal cortex in regard to functional activity. (Sayers, 1948; Deane, 1948). Dougherty and White (1947) have shown that circulating lymphocytes are under the regulatory control of the adrenal cortex and this has made available

a valuable tool for the measurement of the activity of adrenal cortex. The phenomenon is initiated by the discharge of ACTH from the adenohypophysis. But this must be accepted with certain precautions since a few agents, e.g. X-irradiation and urethane, have a direct lymphocytolytic action as shown by the lymphopenia they produce in adrenalectomised animals. Hills et al (1948) observed that the number of circulating eosinophils is determined by the activity of the pituitary-adrenocortical system and this has made available a very simple method for assessing adrenocortical function. Following the administration of ACTH, the drop in the number of eosinophils, expressed in percentage of the pre-injection count, is approximately twice as great as the drop in the number of lymphocytes; furthermore, the eosinophil response is believed to be less variable than the lymphocyte response (Forsham, 1948). In man, absence of an eosinopenia following the administration of ACTH, is indicative of adrenocortical insufficiency (Thorn, 1948). It should be borne in mind also that eosinophils are influenced by factors other than the secretion of the adrenal cortex.

Substances are present in human urine which exhibit certain properties of the cortical hormone. Corticoids which have like biological properties and which are

determined by bioassay may be designated "biocorticoids" and those which have similar chemical properties and which are determined by chemical assay may be designated "chemocorticoids". Obviously, the two groups overlap considerably. The other index which has been much used to date is analysis of urinary 17-ketosteroid output. Sayers (1950) believes this method should be rejected as an index of adrenocortical activity, not because of the uncertainty of its physiological significance, but because of the lack of correlation between the rate of 17-ketosteroid excretion and adrenocortical activity as determined by other means. Considerable confusion has arisen in the clinical literature due to misinterpretation of the significance of urinary 17-ketosteroids.

BIOLOGIC ACTIONS OF CORTISONE.

Hyman and Chambers (1943) noted that adrenal cortex extracts and certain steroids reduced the rate of oedema formation in perfused frog legs. Opsahl (1949) reported effects of adrenal cortical insufficiency, adrenal cortex extracts and steroids upon the spreading action of hyaluronidase. In studies upon mice, it was found that the dermal spread of India Ink was enhanced by adrenalectomy, whereas the administration of adrenal cortex extracts to either normal or adrenalectomised mice inhibited spreading. It was also found that adrenal

cortical extracts inhibit the intradermal spreading of India Ink enhanced by hyaluronidase. (Opsahl, 1949).

Seifter et al (1949) observed that hyaluronidase reversibly accelerates osmosis and abolishes the semi-permeable nature of membranes prepared from the excised bladder of rats. Adrenal cortex extract and oestrone antagonised the effect of hyaluronidase upon the permeability of bladder membrane, whereas 11-desoxycorticosterone enhanced the action of hyaluronidase. In a further study of the effects of hyaluronidase and steroids upon permeability, phenolsulphonphthalein was injected into the joint of a rabbit, and its speed of absorption through the synovial membrane was measured by determining the time and rate of its excretion in the urine. Hyaluronidase markedly increased the permeability of the synovial membrane. The compound 11-desoxycorticosterone acetate also increased permeability, but when given in addition to hyaluronidase, there was no additive effect. Cortisone acetate and, to a lesser extent, adrenal cortex extract were effective in decreasing the permeability of the synovial membrane (Seifter et al 1949). These substances are considered to affect permeability by acting upon the hyaluronate of the ground substance of the membranes.

Organic Metabolism.

Immature adrenalectomised rats treated with cortisone

Anterior Pituitary Gland

TABLE 12.

Current concepts of the endocrine control

of protein metabolism.

Pyruvic Acid
Succinic Acid
or other Carbon
Skeletons

TABLE 13.

Diagrammatic representation of the role

of the adrenal cortex in the blood

sugar regulating mechanism.

(after Thorn, 1950).

Portal Hypertension

Anterior Pituitary Gland

Adrenal Cortex

Posterior Pituitary Gland

TABLE 12.

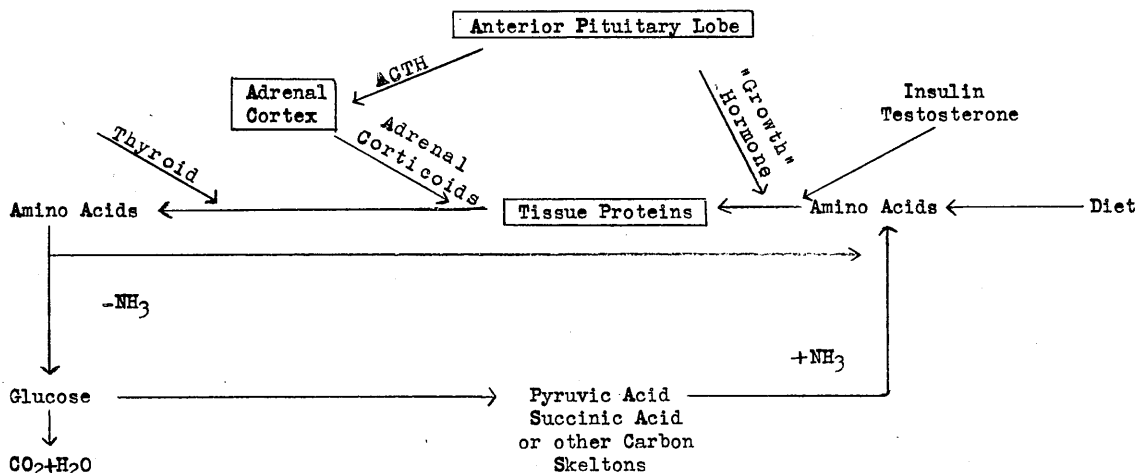
Current concepts of the endocrine control
of protein metabolism.

TABLE 13.

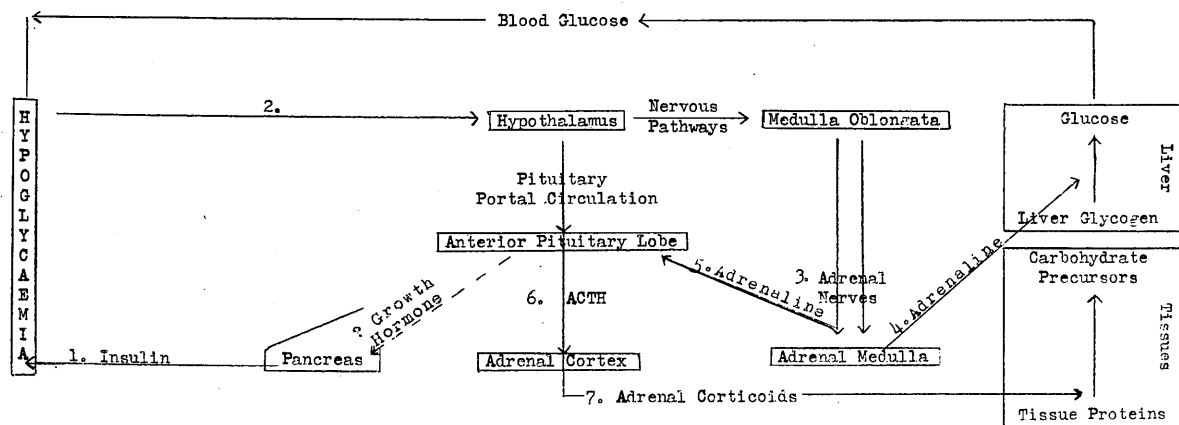
Diagrammatic representation of the role
of the adrenal cortex in the blood
sugar regulating mechanism.

(after Thorn, 1950).

B. Endocrine Control of Protein Metabolism



C. Blood Sugar Regulating Mechanism



in doses of 0.25 to 1.0 mg. daily are able to survive and grow but at a subnormal rate (Kuizerga, 1943).

Larger doses of cortisone inhibited growth in immature normal rats. (Wells, 1940). Cortisone has been shown to fail to sustain growth in young, sexually mature adrenalectomised rats at any dosage level. Ingle (1941) Winter (1951) treated young male rats for a period of six weeks with 3 mg. of cortisone acetate daily and showed that growth ceased during this period. When the injections were stopped, growth was resumed. Addis (1950) found that the normal rat responds to the injection of hog renin by developing an intense proteinuria. Karnofsky, Stock and Rhoads (1950) injected cortisone acetate into the yolk sac of the 4-day chick embryo. At a dose of 1 to 2 mg. per egg, there was a marked retardation of the growth of the embryo. Karnofsky (1950) also demonstrated that cortisone acetate and 17-hydroxycorticosterone inhibit the growth of the young chick.

Whitaker and Baker (1948, 1949) noted that the percutaneous application of cortisone had a local inhibitory effect upon the growth of hair. Baker and Castor (1950) made a study of the cutaneous atrophy induced by the percutaneous application of a highly concentrated extract of adrenal cortex in the rat. Following the cessation of hair growth, thinning of the epidermis occurred and there was a reduction in cellularity of the connective

1999, 2000, 2001, 2002, 2003, 2004, 2005, 2006, 2007, 2008, 2009, 2010, 2011, 2012, 2013, 2014, 2015, 2016, 2017, 2018, 2019, 2020, 2021, 2022, 2023, 2024, 2025, 2026, 2027, 2028, 2029, 2030, 2031, 2032, 2033, 2034, 2035, 2036, 2037, 2038, 2039, 2040, 2041, 2042, 2043, 2044, 2045, 2046, 2047, 2048, 2049, 2050, 2051, 2052, 2053, 2054, 2055, 2056, 2057, 2058, 2059, 2060, 2061, 2062, 2063, 2064, 2065, 2066, 2067, 2068, 2069, 2070, 2071, 2072, 2073, 2074, 2075, 2076, 2077, 2078, 2079, 2080, 2081, 2082, 2083, 2084, 2085, 2086, 2087, 2088, 2089, 2090, 2091, 2092, 2093, 2094, 2095, 2096, 2097, 2098, 2099, 2100, 2101, 2102, 2103, 2104, 2105, 2106, 2107, 2108, 2109, 2110, 2111, 2112, 2113, 2114, 2115, 2116, 2117, 2118, 2119, 2120, 2121, 2122, 2123, 2124, 2125, 2126, 2127, 2128, 2129, 2130, 2131, 2132, 2133, 2134, 2135, 2136, 2137, 2138, 2139, 2140, 2141, 2142, 2143, 2144, 2145, 2146, 2147, 2148, 2149, 2150, 2151, 2152, 2153, 2154, 2155, 2156, 2157, 2158, 2159, 2160, 2161, 2162, 2163, 2164, 2165, 2166, 2167, 2168, 2169, 2170, 2171, 2172, 2173, 2174, 2175, 2176, 2177, 2178, 2179, 2180, 2181, 2182, 2183, 2184, 2185, 2186, 2187, 2188, 2189, 2190, 2191, 2192, 2193, 2194, 2195, 2196, 2197, 2198, 2199, 2200, 2201, 2202, 2203, 2204, 2205, 2206, 2207, 2208, 2209, 2210, 2211, 2212, 2213, 2214, 2215, 2216, 2217, 2218, 2219, 2220, 2221, 2222, 2223, 2224, 2225, 2226, 2227, 2228, 2229, 2230, 2231, 2232, 2233, 2234, 2235, 2236, 2237, 2238, 2239, 2240, 2241, 2242, 2243, 2244, 2245, 2246, 2247, 2248, 2249, 2250, 2251, 2252, 2253, 2254, 2255, 2256, 2257, 2258, 2259, 2260, 2261, 2262, 2263, 2264, 2265, 2266, 2267, 2268, 2269, 2270, 2271, 2272, 2273, 2274, 2275, 2276, 2277, 2278, 2279, 2280, 2281, 2282, 2283, 2284, 2285, 2286, 2287, 2288, 2289, 2290, 2291, 2292, 2293, 2294, 2295, 2296, 2297, 2298, 2299, 2300, 2301, 2302, 2303, 2304, 2305, 2306, 2307, 2308, 2309, 2310, 2311, 2312, 2313, 2314, 2315, 2316, 2317, 2318, 2319, 2320, 2321, 2322, 2323, 2324, 2325, 2326, 2327, 2328, 2329, 2330, 2331, 2332, 2333, 2334, 2335, 2336, 2337, 2338, 2339, 2340, 2341, 2342, 2343, 2344, 2345, 2346, 2347, 2348, 2349, 2350, 2351, 2352, 2353, 2354, 2355, 2356, 2357, 2358, 2359, 2360, 2361, 2362, 2363, 2364, 2365, 2366, 2367, 2368, 2369, 2370, 2371, 2372, 2373, 2374, 2375, 2376, 2377, 2378, 2379, 2380, 2381, 2382, 2383, 2384, 2385, 2386, 2387, 2388, 2389, 2390, 2391, 2392, 2393, 2394, 2395, 2396, 2397, 2398, 2399, 2400, 2401, 2402, 2403, 2404, 2405, 2406, 2407, 2408, 2409, 2410, 2411, 2412, 2413, 2414, 2415, 2416, 2417, 2418, 2419, 2420, 2421, 2422, 2423, 2424, 2425, 2426, 2427, 2428, 2429, 2430, 2431, 2432, 2433, 2434, 2435, 2436, 2437, 2438, 2439, 2440, 2441, 2442, 2443, 2444, 2445, 2446, 2447, 2448, 2449, 2450, 2451, 2452, 2453, 2454, 2455, 2456, 2457, 2458, 2459, 2460, 2461, 2462, 2463, 2464, 2465, 2466, 2467, 2468, 2469, 2470, 2471, 2472, 2473, 2474, 2475, 2476, 2477, 2478, 2479, 2480, 2481, 2482, 2483, 2484, 2485, 2486, 2487, 2488, 2489, 2490, 2491, 2492, 2493, 2494, 2495, 2496, 2497, 2498, 2499, 2500, 2501, 2502, 2503, 2504, 2505, 2506, 2507, 2508, 2509, 2510, 2511, 2512, 2513, 2514, 2515, 2516, 2517, 2518, 2519, 2520, 2521, 2522, 2523, 2524, 2525, 2526, 2527, 2528, 2529, 2530, 2531, 2532, 2533, 2534, 2535, 2536, 2537, 2538, 2539, 2540, 2541, 2542, 2543, 2544, 2545, 2546, 2547, 2548, 2549, 2550, 2551, 2552, 2553, 2554, 2555, 2556, 2557, 2558, 2559, 2560, 2561, 2562, 2563, 2564, 2565, 2566, 2567, 2568, 2569, 2570, 2571, 2572, 2573, 2574, 2575, 2576, 2577, 2578, 2579, 2580, 2581, 2582, 2583, 2584, 2585, 2586, 2587, 2588, 2589, 2590, 2591, 2592, 2593, 2594, 2595, 2596, 2597, 2598, 2599, 2600, 2601, 2602, 2603, 2604, 2605, 2606, 2607, 2608, 2609, 2610, 2611, 2612, 2613, 2614, 2615, 2616, 2617, 2618, 2619, 2620, 2621, 2622, 2623, 2624, 2625, 2626, 2627, 2628, 2629, 2630, 2631, 2632, 2633, 2634, 2635, 2636, 2637, 2638, 2639, 2640, 2641, 2642, 2643, 2644, 2645, 2646, 2647, 2648, 2649, 2650, 2651, 2652, 2653, 2654, 2655, 2656, 2657, 2658, 2659, 2660, 2661, 2662, 2663, 2664, 2665, 2666, 2667, 2668, 2669, 2670, 2671, 2672, 2673, 2674, 2675, 2676, 2677, 2678, 2679, 2680, 26

5. *Phragmites australis* (Cav.) Trin. ex Steud.

41 EIGHT

the time common among us writing names backward

showing the relationships of carbohydrate

•jst bmo nistorg

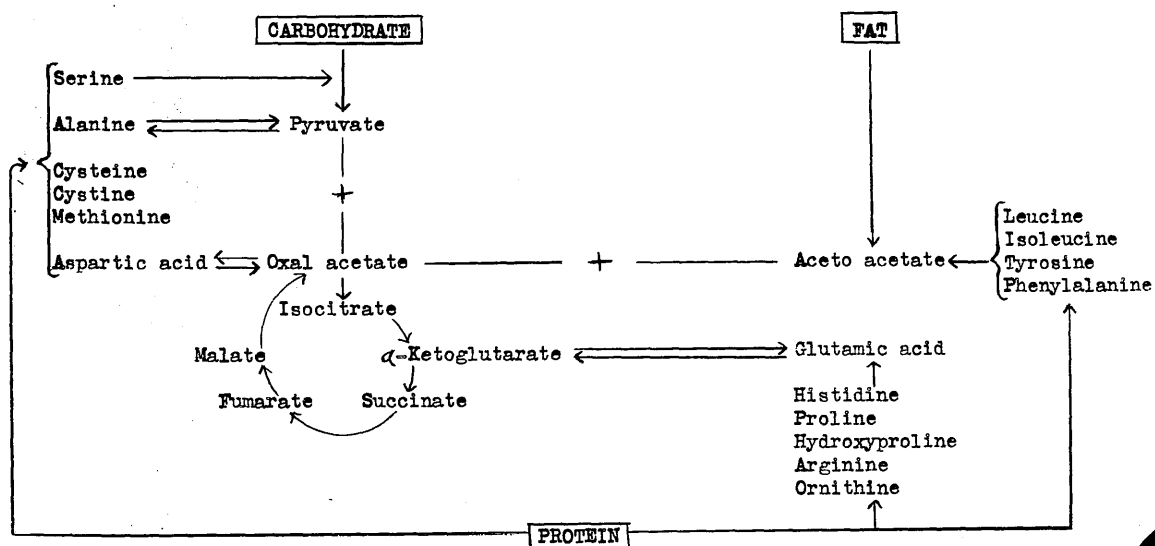
SECRET

1990 1991

Thalidomide
Phenothiazine
Sedative
Anesthetics
Opioids

TABLE 14.

The final common pathway of metabolism
showing the relationships of carbohydrate
protein and fat.

METABOLISMA. The Final Common Pathway of Metabolism

tissue. However, elastic fibers were not reduced by the treatment. Baker and Castor concluded that the 11-oxygenated steroids may act directly on the protein of intercellular structures and the epithelial cells. Winter et al (1951) observed cessation of hair growth during the subcutaneous administration of 3 mg. of cortisone acetate daily in the young male rat.

Schneebeli (1950) has noted specific alterations in the fibroblasts of loose connective tissue following the administration of cortisone acetate to adrenalectomised mice. There were changes in the amorphous ground substance and striking alterations in the fibroblasts four hours after the administration of cortisone acetate. Blunt (1950) administered 25 mg. cortisone acetate daily to rabbits for 3 days prior to fracturing of the femur and thereafter until the animals were killed. Up to the fourth post-fracture day, the inflammatory and reparative responses of connective tissue were the same in both control and cortisone treated animals. After four days, however, there was retardation of all phases of healing in the cortisone treated animals. For example, new blood vessels were more numerous in the control animals.

Ragan (1949) noted that biopsy wounds failed to heal in patients with different diseases treated with

ACTH. Howes et al (1950) investigated the healing of skin defects in the ears of rabbits under the influence of cortisone. These defects still had blood vessels completely uncovered by granulations (8 days after wounding) with doses varying from 6 - 10 mgm/kg. body weight, daily, the cortisone having been started three days before wounding. Microscopically, the tissues in the base of the wound did not increase in thickness. They contained dilated, large blood vessels surrounded by an increased cell population of round cells and fibroblasts with small nuclei. No new blood vessels or new reticulin fibrils were present. Mucopolysaccharides were diminished. Some new granulations appeared, however, under the epithelium that advanced slightly from the edges of the wound. Smaller doses 2-3-6 mgm/kg. delayed the onset of the appearance of granulations for a shorter length of time. Cancellation of the Cortisone resulted in the reappearance of granulations four or five days later. These same workers noted delay in the healing of fractures in the rabbit, using the same scale of dosages, and also that haemorrhage was more slowly absorbed in the cortisone treated animal.

Baker and Ingle (1948) reported an increase in the compactness of the connective tissue fibers of the dermis following daily treatment of rats with 1 - 3 mgm. of

adrenocorticotropin for 21 days. Baker and Whitaker (1948) also demonstrated that adrenocortical steroids inhibit growth of hair and epidermis by local action.

The question which then arose was whether the retardation in growth of tissue resulted from a generalized disturbance of protein metabolism (as indicated by excess excretion of nitrogen) or by direct action of adrenocortical hormones on the peripheral tissues. Baker and Whitaker (1950) tackled this problem by applying directly hog adrenal extract dissolved in 25% alcohol to cutaneous wounds in the rat. They found some delay in closure of the wound, but the treatment did not counteract completely the stimulation to growth caused by cutting the skin. The daily doses were equivalent to 100 or 200 mg. of cortisone. Nevertheless, a definite interference in formation of granulation tissue resulted from this treatment, the effect being limited to the area of treatment. It must be noted that using cortisone itself no significant results could be obtained in this experiment.

Taubenbaus showed (1949) that in granulation tissue accumulating around abscesses induced by turpentine injections in rats, fibroblastic proliferation was profoundly stimulated by the injections of DCA but suppressed to an extreme degree by the prolonged administration of sex

hormones. In order to determine, if possible, whether these effects might be the result of inhibition of the anterior pituitary or a direct peripheral action of steroids he attempted (1950) to analyse the separate influences of the anterior pituitary, the thyroid, the adrenal cortical hormones, and the sex steroids upon the structure of granulation tissue.

It appeared that hypophysectomised rats failed to develop significant amounts of granulation tissue. He concluded that the thyrotropic hormone acted synergistically with the growth hormone, and that they were important factors in promoting the growth of granulation tissue. This is in agreement with the findings of Smith (1933). Cuthbertson (1941) failed to find any influence of pituitary extracts upon wound healing but he used a crude extract in which the exact content of active pituitary hormones was unknown.

Taubenhaus (1950) showed that D.C.S. when administered simultaneously with the development of the turpentine abscess, produced the stimulating effect to a much lesser degree than described before (1949), when the animals had been pretreated with D.C.S. for 3 days. This would indicate that some mechanisms other than direct influence upon granulation tissue must be set into function which ultimately produces the stimulation.

Administration of the compound E oxysteroids produced a marked decrease in actively proliferating fibroblasts. There was also an absolute and relative increase of large phagocytes and less vascularisation was noted in these abscesses. (Taubenhaus, 1950). Baker (1951) has shown that the direct application of cortisone to the wound inhibits granulation.

Cortisone has also been shown to inhibit the growth of tumour tissues under certain conditions. Heilman and Kendall (1944) found that cortisone caused rapid and complete regression of a transplantable lymphosarcoma in the mouse, but that tumors usually recurred and became refractory to treatment. Baker and Whitaker (1949) produced carcinomas of the skin by the local action of 3 - methylcholanthrene in mice. The direct application of solutions of cortisone inhibited the growth of the neoplasms. Ingle et al (1950) found that the injection of 5 mg. of cortisone acetate daily retarded but did not completely suppress the growth of the Walker carcinoma in force-fed rats. Higgins et al (1950) found that the administration of 1 mg. of cortisone acetate daily completely inhibited the growth of transplanted rhabdomyosarcomas in mice. When the administration of the steroid was stopped, the tumor implants began to grow. Re-institution of cortisone acetate therapy inhibited the growth of the tumors but did not cause regression.

Effects upon specific tissues.

Lymphoid tissue. All of the known biologically active 11-oxygenated steroids of the adrenal cortex cause atrophy of the rat thymus when administered in high dosage. This has been found to be true of cortisone (Winter, 1951). It is now also well established that the effects of the 11-oxysteroids upon lymph nodes and spleen are similar to, but less marked than, the regressive changes induced in the thymus. (Dougherty and White 1945). Bogomolets (1943), the Soviet scientist, regarded the reticulo-endothelial system as a vital factor in nutrition and repair and named it the physiological system of the connective tissue. Intent upon this, he developed an apparently satisfactory antiserum specific for this system which was presumed to act by stimulating or depressing, according to dosage given, the function of reticulo-endothelial tissue derivatives. Strauss (1946) studied the healing of experimentally produced fractures of the radius and ulna in rabbits. He concluded that repair of fractures was facilitated by small stimulating doses of anti-reticular cytotoxic serum (A.C.S.). Rifkinson (1950) reported an attempt to influence the healing of incised cerebral wounds by the administration of ACS serum in 136 rats. He felt that in this extensive series there were no significant differences in

the rate of wound healing that were outside the range of the control material. Timiras and Selye (1949) noted a marked increase in the phagocytic activity of the reticulo-endothelial system during the alarm reaction in rats. Histological examination showed increased phagocytosis in the lung, kidneys, adrenals, bone marrow, hibernating gland, thymus and lymph nodes.

Heilman (1945)a reported that in studies on cultures of mammalian lymph node, cortisone decreased the relative number of migrating lymphocytes and increased the rate of lymphocytic degeneration. Following this (1945)b, she reported the effect of cortisone on the migration of macrophages in tissue culture of normal rabbits' spleen. The extent of migration of large wandering cells was increased in cultures containing concentrations of cortisone. It could not be determined whether the stimulation of migration of macrophages was due to a primary effect on the large wandering cell or was secondary to the action of the test substances on other cells present in the culture.

Tissue damage and unfavourable effects.

Following the preparation of biologically active extracts of beef adrenal glands twenty years ago, the erroneous concept developed that hormones of the adrenal

cortex do not damage the organism when administered in high dosage. Adrenal cortex extracts have seldom been found toxic because it is difficult to administer doses which exceed the normal secretory activity of the adrenal cortices of either animals or patients. In the case of the crystalline compounds of the adrenal cortex, however, it is easily possible to administer dosages which cause damage to tissues. Kochakian (1944) and Kendall (1945) each implanted pellets of cortisone in normal mice and noted the occurrence of cardiac and skeletal muscle lesions in these animals. Ingle et al (1945) administered 17-hydroxycorticosterone in doses of 5 mg. daily to normal rats and described deep ulcers in the pyloric portion of the stomach in 2 rats. Winter et al (1951) observed minor cellular damage in rats which received 3 mg. of cortisone acetate daily.

The most complete reports on the unfavourable effects of cortisone acetate in man are by Sprague et al (1950) and Hench et al (1950). The signs of cortisone excess are similar to and probably identical with the symptoms of Cushing' syndrome. Among the patients studied at the Mayo Clinic, a number exhibited rounding of the facial contours as an early sign of cortisone excess. Thinning of the skin with development of striae was observed in 6 patients treated with cortisone acetate. Muscular

weakness and signs of reduced gonadal activity appeared in some of the patients. In general, the undesirable effects were marked in those patients who received 200 mgm. of cortisone acetate per day.

Although it is possible to cause pathologic changes by the administration of very large amounts of cortisone to animals (vide supra), and damage is more likely to occur under certain abnormal conditions, it seems probable that physiologic amounts and dosages equivalent to therapeutic doses in man do not cause any irreversible pathologic changes. It has not yet been determined whether or not large doses of cortisone produce degenerative changes in man. None, so far, has been reported.

Methods and Materials.

In this study forty five cats were used. They were very carefully selected with regard to general fitness and freedom from infection. The operative procedure was carried out under nembutal anaesthesia; .6c.c./kg. body weight being the dose found most suitable, administered intraperitoneally. During the operation the animal was placed in a standard head holder (Gage 1951). Strict aseptic technique was observed throughout. Following the operation the animal was returned to its cage, placed on a clean sheet of paper to avoid insufflation of foreign bodies and watched periodically. Normal feeding was resumed as soon as consciousness returned but in some instances it was necessary to give the animals 20-30 c.c of glucose saline intraperitoneally else they deteriorated rapidly.

Operative technique.

The head was shaved and the skin prepared with application of green soap, alcohol and 'metaphen' in that order. The scalp was dressed as a sterile field. The skin and galea were divided by a longitudinal incision about 1 cm. to one or other side of the midline. The temporal muscles were reflected by incising the fascia along the superior temporal line and separating them from the skull with a periosteal elevator. Openings in the skull were made on one side only, usually the left, and as a rule, this was achieved by the use of

perforator and burr followed by a rongeur. The bony defect was rectangular and averaged $2\frac{1}{2}$ cms by 1 cm. Diploic bleeding was easily controlled by gentle suction and a minimum of Horsley's wax. The dura was picked up, incised longitudinally and gently parted. In all the animals except five, the pia-arachnoid and brain were then incised, to the depth of 1 cm by a sharp scalpel, one incision only being made. The length of the incision averaged 2 cms. A small piece of gelsponge which had previously been moistened by soaking in the cerebro-spinal fluid, and corresponding to the dimensions of the incision, was placed carefully and gently on the brain wound. Great care was taken to see that no haemorrhage persisted. The dura was closed using very fine sutures and eye needles, on the average two or three sutures being used. The muscle and fascia were approximated and the skin closed. In five animals the wounds which were made were lacerated in type and the cortex greatly disturbed, about $1\frac{1}{2}$ cm diameter and some bleeding caused. A minimum of gelsponge was used and then only to control the haemorrhage. In the series of experiments where cortisone was applied locally to the brain the gelatin sponge was soaked directly in the cortisone acetate in saline, in others the acetate tablet was ground into powder and placed sandwich fashion between the slit layers of the piece of gelsponge and then inserted into the wound. In the series using the polythene film between the dura and

the brain, the incised brain wound was carried out as above and when the bleeding had been controlled and the plain piece of gelatin sponge inserted, the film was gently placed between the dura and the arachnoid, without damage to the arachnoid. The dura was sutured and in some instances when this was found to be impossible a small fascial graft was used to close the defect. In order to prevent skin infection the sutures were tied loosely in all wounds and the wound smeared with 'Nueskin' , a proprietary preparation.

The animals were weighed daily. Where the cortisone was given intra muscularly or orally the dose was 10 mgm/kg body wt. Cortisone acetate (Merck brand of cortisone) was used in the form of the injectable saline suspension or in the form of tablets which contained 10 mgm per tablet. Eosinophil counts were performed periodically on all the animals. Electroencephalograms were carried out on certain animals from time to time, pre and post operatively.

Pathological Studies and Techniques.

The animals under observation were sacrificed at intervals of 5 to 43 days. Deep anaesthesia was obtained by the use of nembutal, .65 cc/kg body weight, intraperitoneally. Following this one or other carotid artery was isolated, cannulated and the head perfused with physiological saline followed by 10% formalin. Next the skin was reflected from the head. The muscle and fascia

were removed and the skull defect exposed. This presentation was photographed. The skull was perforated, well away from the midline, on the opposite side from the brain wound. The top of the skull was rongeured right the way round, slowly and deliberately, without damage to the dura. Great care was then exercised in the removal of the brain.

It will be evident that by this method the brain was removed from the skull with the dura relatively intact and with the convexity of the skull and dura 'in situ' over the brain wound. It was then a simple matter to nibble the bone away carefully up to the linear margin of the wound. The dura was then perfectly free and by raising it gently the presence or absence of adhesions could be ascertained and appropriate photographs taken. This method was decided upon and adopted since it was felt that by its use the least possible damage was done to existing structures and moreover it allowed control over every stage of the uncovering of any adhesions and prevented many of the little strains and tugs which can so easily give rise to a false picture.

The brain was usually found to be sufficiently hard and was sectioned coronally, four pieces of tissue being obtained.

1. Placed in 10% formalin and this block later embedded in paraffin: H.V.G., H.E., P.T.A., L.C.T. and Weil stains were made on these sections.

2. Placed in F.A.B. with cobalte nitrate. Silver carbonate stain for oligodendroglia and microglia made.
3. In a few specimens where the cut could be made a very short time after sacrifice a piece of the tissue was placed straightaway into potassium bichromate solution and stained by modifications of the Golgi method.
4. In order to maintain the wound structures intact it was decided to embed the main block in celloidin and stain the sections thereby obtained by the Cresyl violet method.

TABLE OF ANIMALS USED.

Sept 50- Aug 51.

CONTROL.

44.51 8 days
 43.51 15
 28.51 24
 29.51 31
 22.51 40

CORTISONE by MOUTH.

132.51 8 days.
 136.51 14
 133.51 22
 134.51 28.
 137.51 36.

Intra Musc. CORTISONE.

36.51 5 days
 48.51 7
 46.51 15
 49.51 24
 35.51 35
 52.51 25
 51.51 37
 34.51 43
 83.51 50
 84.51 30

LACERATED Wound with CORTISONE.

442.50 9 days
 443.50 20
 459.50 14 cortisone inj.
 460.50 28 through scalp.
 461.50 36

 7.51 8 days
 8.51 15 intra musc. inj.
 21.51 28 of cortisone.

INTRA MUSC. CORTISONE in
conjunction with polythene
film.

149.51 3 days
 150.51 5
 246.51 8
 247.51 14
 248.51 21
 249.51 33
 250.51 45

CORTISONE LOCALLY.

120.51 7 day acetate.
 125.51 14 " acetate.
 124.51 28 " acetate.

 126.51 21 " tablet.
 127.51 14 " tablet.

EXPERIMENTAL RESULTS.

Cat. P. 44.51 Wt. 2.6 kg Control.

Survival time - 8 days.

Gross. In this case a small fascial graft was required to help close the dura. Very soft looking adhesions were present along the entire extent of the wound between the brain and the dura.

Microscopic. There is a very considerable thickening of the meninges adjacent to the wound and extending some distance from it. There is intense phagocytosis throughout the whole wound and gitter cells are numerous. The gelatin sponge is present and is not yet invaded by phagocytes or inflammatory cells but numerous red blood cells are trapped in it. The wound is poorly demarcated from the adjacent brain tissue (fig. 5.). New capillaries are numerous, especially in the white matter. No reticulin or collagen is present.

Cat. P.48.51. Wt. 3.6 kg. Intra musc. cortisone.

Survival time - 7 days.

Gross. This animal had an uneventful course. A very soft adhesion was present only at the centre of the wound between the brain and overlying dura.

Microscopic. The wound is well demarcated from the surrounding brain (fig.6.). There is no thickening or inflammatory reaction of the meninges. Phagocytosis is present and is well marked. Inflammatory cells can be seen. The gelatin sponge is in place but appears to have been invaded by macrophages and is undergoing phagocytosis

The first of these is the fact that the
 evidence is not sufficient to establish
 the fact that the defendant was
 present at the scene of the crime.

The second of these is the fact that the
 evidence is not sufficient to establish
 the fact that the defendant was
 present at the scene of the crime.

The third of these is the fact that the
 evidence is not sufficient to establish
 the fact that the defendant was
 present at the scene of the crime.

Fig. 1.

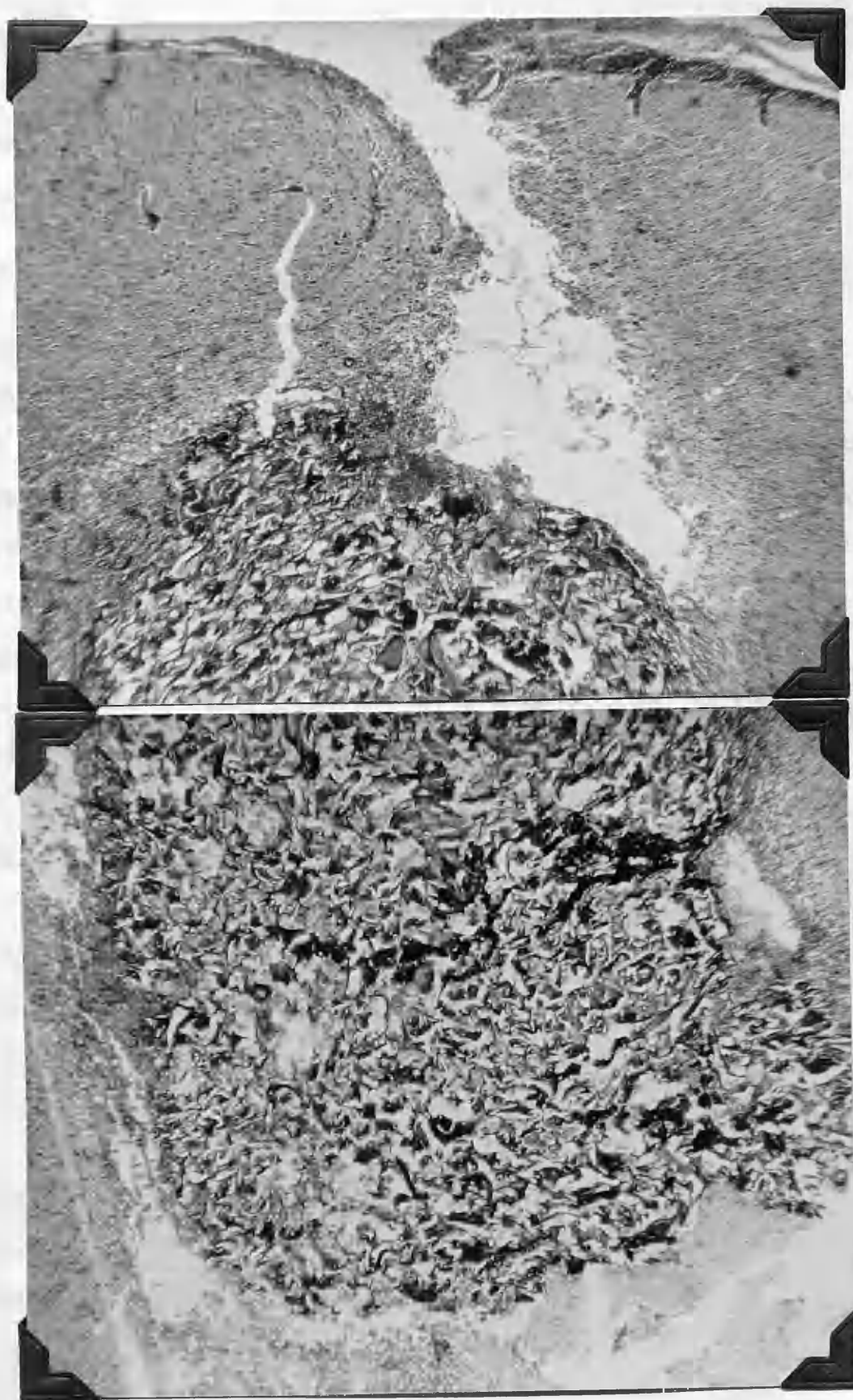
Cat 44.51

8 day control.

This shows the histological appearance of
the incised wounds used in this study.

The gelatin sponge is easily recognised
lying in the wound.

HVG, x 42.



(fig.13). No general effect of cortisone can be recognised on the brain tissue. There is not reticulin to be seen. New capillaries can be seen around the base of the wound but they are not numerous.

Cat.P.43.51. Wt. 2.9kg. Control.

Survival time - 15 days.

Gross. A small fascial graft was required to assist closure of the dura. A small superficial infection occurred at the site of one stitch but cleared quickly on its removal. An adhesion was present, along the entire extent of the wound between brain and dura.

Microscopic. The wound is quite well demarcated from surrounding brain. The meninges show minimal thickening. There is active phagocytosis present in the base of the wound. Plasma cells and occasional giant cells can be seen. Gelatin sponge has been well invaded by phagocytes. Only very occasional fine strands of reticulin can be seen. Collagen has made its appearance. It is pale staining, very fibery and runs in streams. The gold sections show hypertrophy of the astrocytes and a tendency to tangential arrangement.

Cat.P.46.51 Wt. 4kg. Intra musc. cortisone.

Survival time - 15 days.

Gross. The animal had an uneventful course. At sacrifice a soft adhesion was found between brain and dura extending

Fig. 4. 1. 8 day control

This shows poor regeneration of the wound
with brain oedema and slight cell loss
around the lesion.

Fig. 4. 2. 10 day

Fig. 4. 3. 13 day intra ventr. cannulae

Showing relatively good regeneration of wound
and lack of brain oedema.

Fig. 4. 4. 15 day

Fig. 5.

Cat 44.51 8 day control.

This shows poor demarcation of the wound
with brain oedema and glitter cell zone
around the lesion.

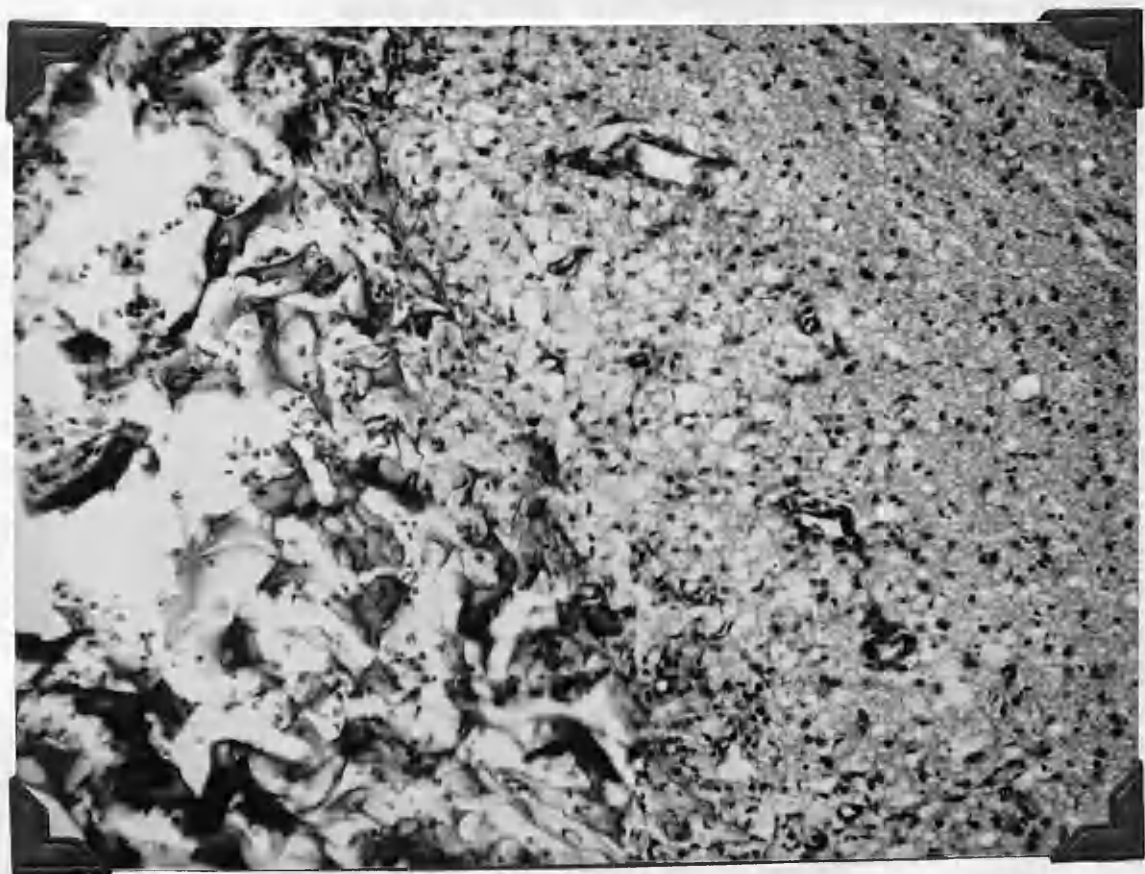
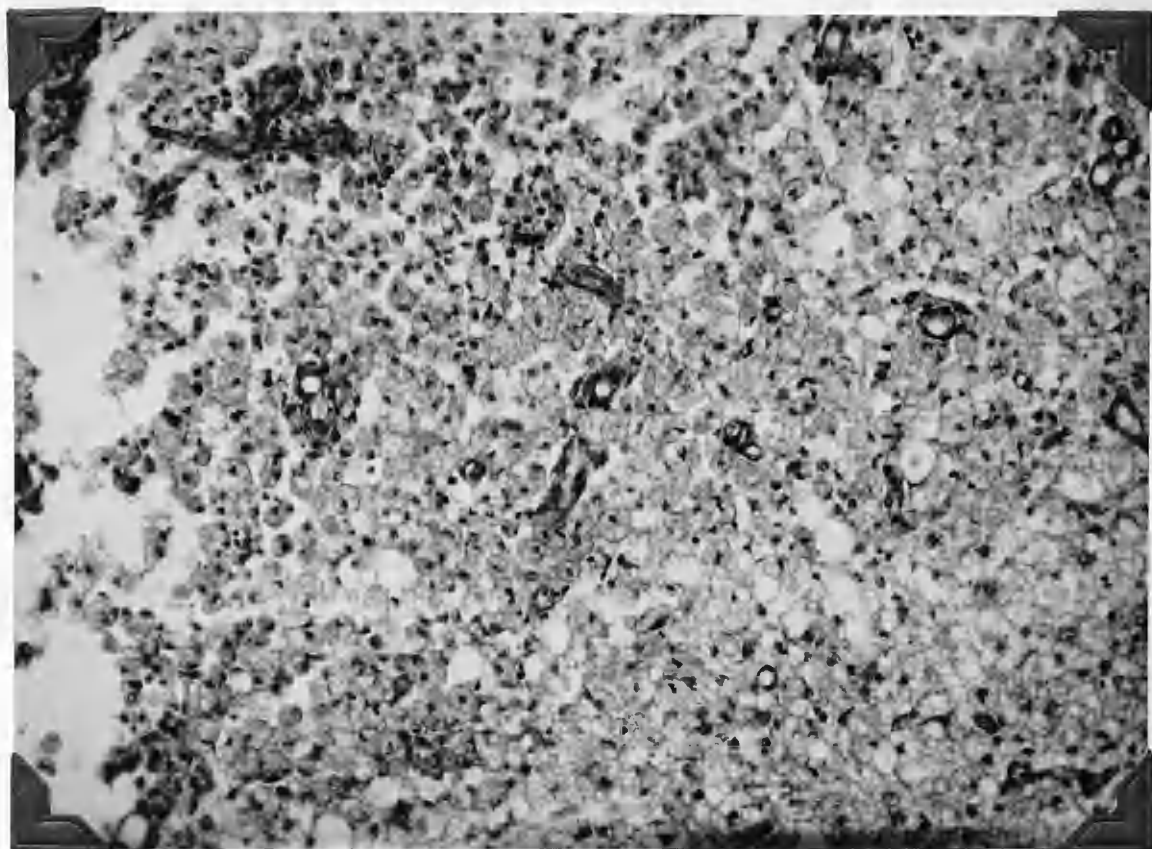
HVG. x 576.

Fig. 6.

Cat 48.51 7 day intra musc. cortisone inj.

Showing relatively good demarcation of wound
and lack of brain oedema.

HVG. x 576.



Showing the heavy defect appearing at
 the bottom and inside wall
 bound at defect.

Photo 31-0-55

Photo 31-0-56

This picture shows the heavy defect at
 the bottom and inside wall
 bound at defect.

Photo 31-0-57

Photo 31-0-58

Photo 31-0-59

Photo 31-0-60

This picture shows the heavy defect at
 the bottom and inside wall
 bound at defect.

Fig. 2.

Cat 28.51 24 day control.

Showing the bony defect presenting at
sacrifice. Muscle and fascia well
bound at defect.

Photo 51-0454.

Fig. 3.

As above - Cat 28.51 24 day control.

This picture shows the dura raised at
sacrifice and a well marked meningo-
cerebral adhesion presenting.

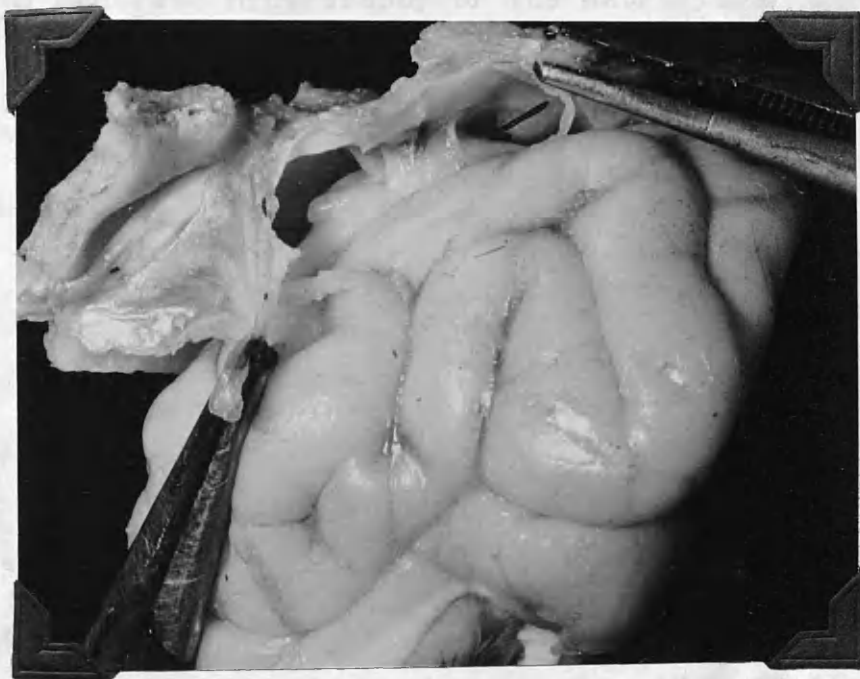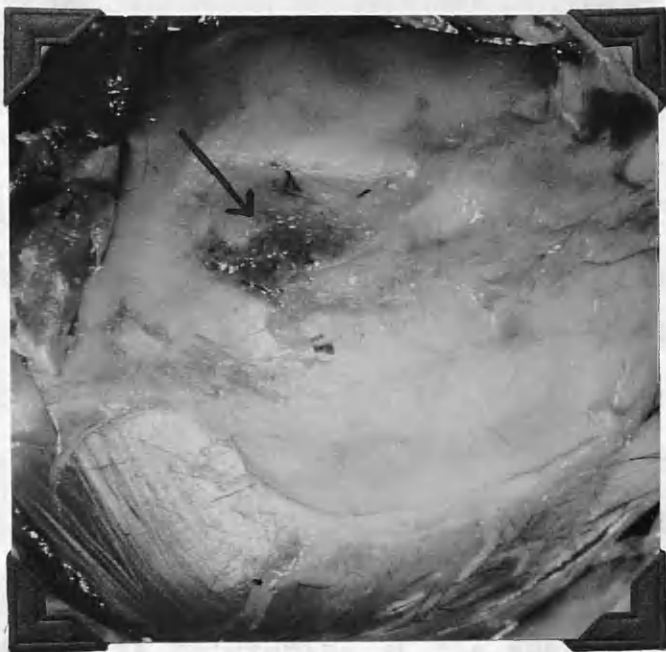
Photo 51-0455

Fig. 4.

Cat 43.51 15 day control.

This demonstrates again a definite
meningo-cerebral adhesion at
sacrifice.

Photo 51-0427.



along entire length of wound.

Microscopic. The wound is reasonably well demarcated. There is no thickening whatsoever of the meninges. Active phagocytosis is taking place throughout. Reticulin is present, but is not plentiful. Along the wound edges fibroblasts can be recognised. Collagen is present, mostly of a fibery nature but sometimes appearing rather homogeneous. There is no recognisable effect of cortisone. Gelatin sponge present. There is thickening of the ependyma closest to the lesion and moderate hypertrophy of the astrocytes.

Cat.P.28.51 Wt.3 kg. Control.

Survival time - 24 days.

Gross. There were no complications in this case. An adhesion was present between the brain and the dura throughout the extent of the wound.

Microscopic. In the chromatic sections an intense cellular reaction about the wound can be seen. Many new capillaries are visible. The meninges show only a minimal degree of thickening over the wound. There is active phagocytosis and many inflammatory cells can be seen. The gelatin sponge is present. Examination of the P.T.A. stain shows some orientation of the glia fibrils towards the wound, and the gold stains show a thick zone of gliosis in the white matter. There is no reticulin present to speak of.

Jan 28.51 24 day control.

This is a high power view, Goldf. 24.51. It was intended to show the base of the wound. Large proliferating cells are seen. It was intended to show a representative set of sections by the Goldf. method to assess the reaction of the cells according to the different methods of administering cortisone to the animals. Unfortunately the staining reaction, using the fixed material, were inconsistent and

disappointing.

Goldf.

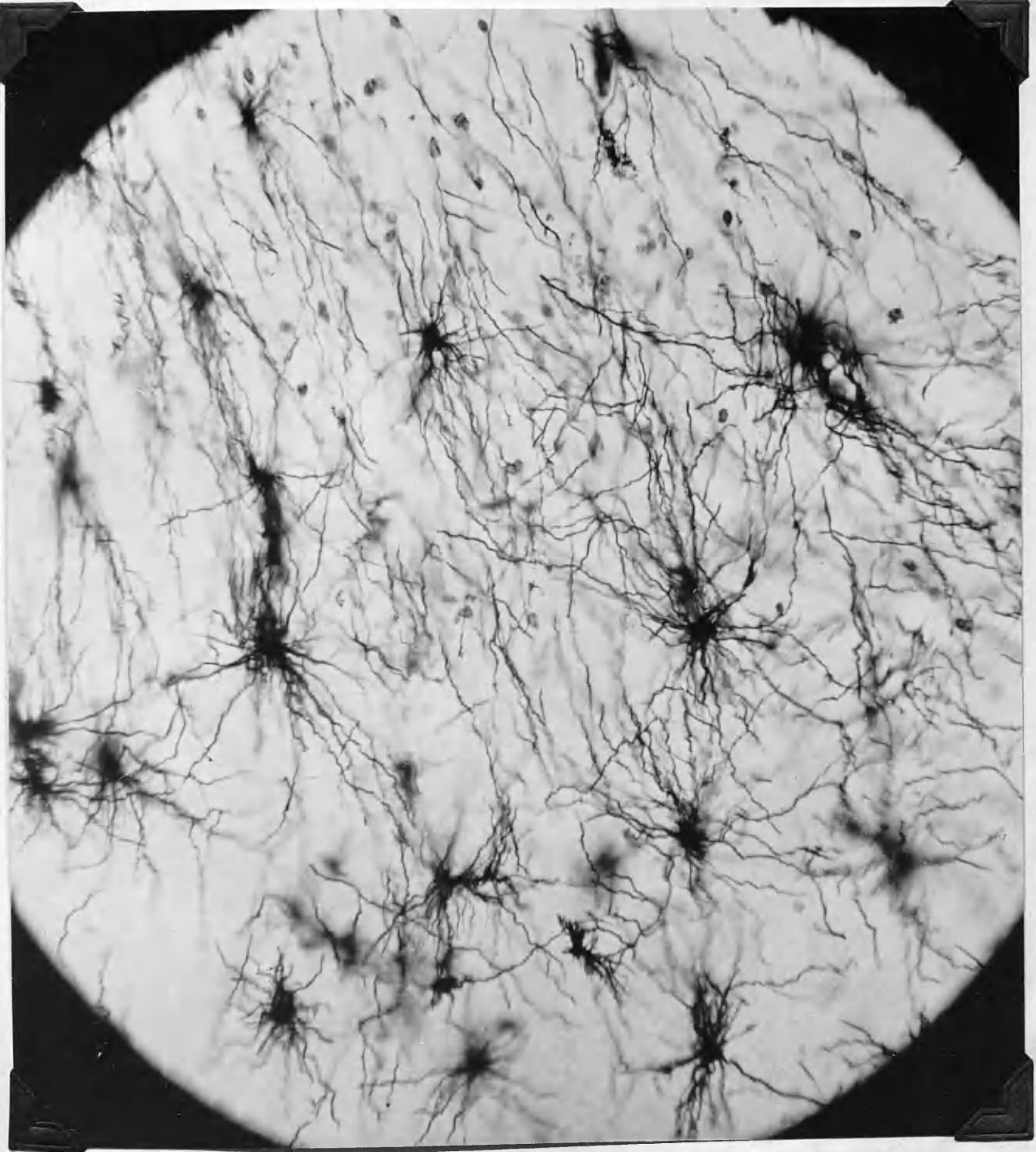
Fig. 7.

Cat 28.51 24 day control.

This is a high power view, Golgi stain, at the base of the wound. Large proliferating astrocytes are seen. It was intended to stain a representative set of sections by the Golgi method to assess the reactions of the astrocytes according to the different methods of administering cortisone to the animals. Unfortunately the staining results, using the fixed material, were inconstant and disappointing.

Golgi.

Albatross 22 *Spizella* 100 *Ammodramus* 100 *Corvus* 100
Empidonax 100 *Geothlypis* 100



Cat.P.49.51 Wt. 2.65 kg. Intra musc. cortisone.

Survival time - 24 days.

Gross. This animal developed a head cold 4 days prior to sacrifice, otherwise unremarkable. Unfortunately, and contrary to the usual practice, the brain with the overlying meninges and skull in place had to be kept in 10% formalin for 3 days prior to photography.

Microscopic. This is a very well demarcated wound. The gelatin sponge is present. There is no orientation of the glia fibrils towards the wound. Reticulin is present but not marked. Collagen is present and appears young. It is very fine and runs in strands. No general effect of cortisone on the brain tissue can be recognised. The meninges are thin and show no cellular reaction. A little gliosis can be recognised in the white matter.

Cat.P.99.51 Wt.2.5 kg. Control.

Survival time - 30 days.

Gross. Following the operation this cat required intraperitoneal fluid, but apart from this its course was unremarkable. A soft adhesion was found between the brain and the dura extending right the way along the wound.

Microscopic. The wound is well demarcated. The meninges do not show any recognisable thickening. There is still phagocytosis going on and inflammatory cells can be seen.

1990

[illegible]

ALL INFORMATION CONTAINED
HEREIN IS UNCLASSIFIED

of initial and final sub-projects

ALL INFORMATION CONTAINED HEREIN IS UNCLASSIFIED

100-443887-100

by vbo 0010001 states meeting to 1011 0000

44-38861-1047

100

1992

• 1st credit 100 2nd 100 3rd 100

100-443887-100

media attention to support the mission?

[illegible]

DATE _____ TIME _____ BY _____

SECRET

SECRET

1997, 1998, 1999, 2000, 2001, 2002, 2003, 2004, 2005, 2006, 2007, 2008, 2009, 2010, 2011, 2012, 2013, 2014, 2015, 2016, 2017, 2018, 2019, 2020, 2021, 2022, 2023, 2024, 2025, 2026, 2027, 2028, 2029, 2030, 2031, 2032, 2033, 2034, 2035, 2036, 2037, 2038, 2039, 2040, 2041, 2042, 2043, 2044, 2045, 2046, 2047, 2048, 2049, 2050, 2051, 2052, 2053, 2054, 2055, 2056, 2057, 2058, 2059, 2060, 2061, 2062, 2063, 2064, 2065, 2066, 2067, 2068, 2069, 2070, 2071, 2072, 2073, 2074, 2075, 2076, 2077, 2078, 2079, 2080, 2081, 2082, 2083, 2084, 2085, 2086, 2087, 2088, 2089, 2090, 2091, 2092, 2093, 2094, 2095, 2096, 2097, 2098, 2099, 2100, 2101, 2102, 2103, 2104, 2105, 2106, 2107, 2108, 2109, 2110, 2111, 2112, 2113, 2114, 2115, 2116, 2117, 2118, 2119, 2120, 2121, 2122, 2123, 2124, 2125, 2126, 2127, 2128, 2129, 2130, 2131, 2132, 2133, 2134, 2135, 2136, 2137, 2138, 2139, 2140, 2141, 2142, 2143, 2144, 2145, 2146, 2147, 2148, 2149, 2150, 2151, 2152, 2153, 2154, 2155, 2156, 2157, 2158, 2159, 2160, 2161, 2162, 2163, 2164, 2165, 2166, 2167, 2168, 2169, 2170, 2171, 2172, 2173, 2174, 2175, 2176, 2177, 2178, 2179, 2180, 2181, 2182, 2183, 2184, 2185, 2186, 2187, 2188, 2189, 2190, 2191, 2192, 2193, 2194, 2195, 2196, 2197, 2198, 2199, 2200, 2201, 2202, 2203, 2204, 2205, 2206, 2207, 2208, 2209, 2210, 2211, 2212, 2213, 2214, 2215, 2216, 2217, 2218, 2219, 2220, 2221, 2222, 2223, 2224, 2225, 2226, 2227, 2228, 2229, 2230, 2231, 2232, 2233, 2234, 2235, 2236, 2237, 2238, 2239, 2240, 2241, 2242, 2243, 2244, 2245, 2246, 2247, 2248, 2249, 2250, 2251, 2252, 2253, 2254, 2255, 2256, 2257, 2258, 2259, 2260, 2261, 2262, 2263, 2264, 2265, 2266, 2267, 2268, 2269, 2270, 2271, 2272, 2273, 2274, 2275, 2276, 2277, 2278, 2279, 2280, 2281, 2282, 2283, 2284, 2285, 2286, 2287, 2288, 2289, 2290, 2291, 2292, 2293, 2294, 2295, 2296, 2297, 2298, 2299, 2300, 2301, 2302, 2303, 2304, 2305, 2306, 2307, 2308, 2309, 2310, 2311, 2312, 2313, 2314, 2315, 2316, 2317, 2318, 2319, 2320, 2321, 2322, 2323, 2324, 2325, 2326, 2327, 2328, 2329, 2330, 2331, 2332, 2333, 2334, 2335, 2336, 2337, 2338, 2339, 2340, 2341, 2342, 2343, 2344, 2345, 2346, 2347, 2348, 2349, 2350, 2351, 2352, 2353, 2354, 2355, 2356, 2357, 2358, 2359, 2360, 2361, 2362, 2363, 2364, 2365, 2366, 2367, 2368, 2369, 2370, 2371, 2372, 2373, 2374, 2375, 2376, 2377, 2378, 2379, 2380, 2381, 2382, 2383, 2384, 2385, 2386, 2387, 2388, 2389, 2390, 2391, 2392, 2393, 2394, 2395, 2396, 2397, 2398, 2399, 2400, 2401, 2402, 2403, 2404, 2405, 2406, 2407, 2408, 2409, 2410, 2411, 2412, 2413, 2414, 2415, 2416, 2417, 2418, 2419, 2420, 2421, 2422, 2423, 2424, 2425, 2426, 2427, 2428, 2429, 2430, 2431, 2432, 2433, 2434, 2435, 2436, 2437, 2438, 2439, 2440, 2441, 2442, 2443, 2444, 2445, 2446, 2447, 2448, 2449, 2450, 2451, 2452, 2453, 2454, 2455, 2456, 2457, 2458, 2459, 2460, 2461, 2462, 2463, 2464, 2465, 2466, 2467, 2468, 2469, 2470, 2471, 2472, 2473, 2474, 2475, 2476, 2477, 2478, 2479, 2480, 2481, 2482, 2483, 2484, 2485, 2486, 2487, 2488, 2489, 2490, 2491, 2492, 2493, 2494, 2495, 2496, 2497, 2498, 2499, 2500, 2501, 2502, 2503, 2504, 2505, 2506, 2507, 2508, 2509, 2510, 2511, 2512, 2513, 2514, 2515, 2516, 2517, 2518, 2519, 2520, 2521, 2522, 2523, 2524, 2525, 2526, 2527, 2528, 2529, 2530, 2531, 2532, 2533, 2534, 2535, 2536, 2537, 2538, 2539, 2540, 2541, 2542, 2543, 2544, 2545, 2546, 2547, 2548, 2549, 2550, 2551, 2552, 2553, 2554, 2555, 2556, 2557, 2558, 2559, 2560, 2561, 2562, 2563, 2564, 2565, 2566, 2567, 2568, 2569, 2570, 2571, 2572, 2573, 2574, 2575, 2576, 2577, 2578, 2579, 2580, 2581, 2582, 2583, 2584, 2585, 2586, 2587, 2588, 2589, 2590, 2591, 2592, 2593, 2594, 2595, 2596, 2597, 2598, 2599, 2600, 2601, 2602, 2603, 2604, 2605, 2606, 2607, 2608, 2609, 2610, 2611, 2612, 2613, 2614, 2615, 2616, 2617, 2618, 2619, 2620, 2621, 2622, 2623, 2624, 2625, 2626, 2627, 2628, 2629, 2630, 2631, 2632, 2633, 2634, 2635, 2636, 2637, 2638, 2639, 2640, 2641, 2642, 2643, 2644, 2645, 2646, 2647, 2648, 2649, 2650, 2651, 2652, 2653, 2654, 2655, 2656, 2657, 2658, 2659, 2660, 2661, 2662, 2663, 2664, 2665, 2666, 2667, 2668, 2669, 2670, 2671, 2672, 2673, 2674, 2675, 2676, 2677, 2678, 26

Figs. 14a and 14b.

Cats 46.51 and 51.51.
15 days 37 days

Intra musc. cortisone inj.

Showing the small but definite
adhesions found at sacrifice in
these animals treated by the intra
musc. inj. of cortisone acetate 10mgm/kg body wt.

Photo 51-1434.

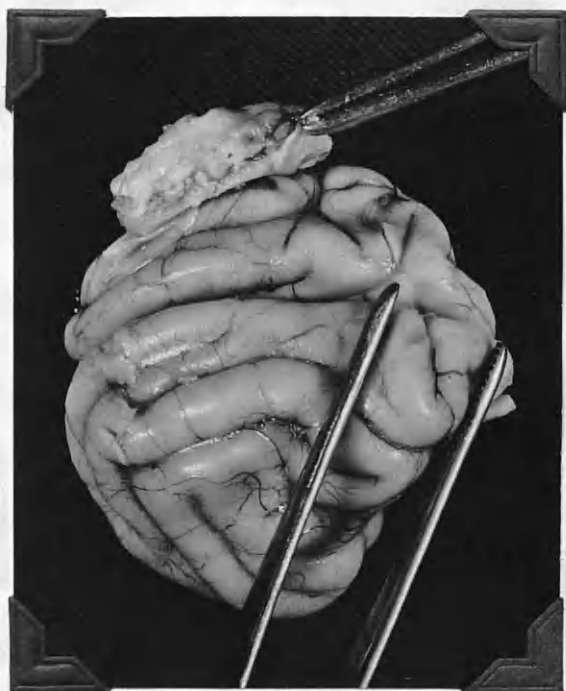Fig. 15.

Cats 46.51 and 51.51.

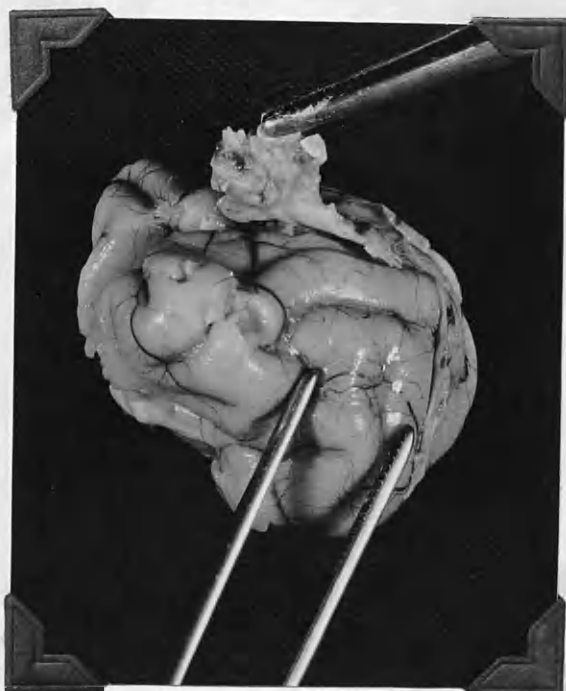
Intra musc. cortisone inj.

Showing the sections of the brains shown
above (figs 14a and 14b) following their
hardening in 10% formalin. The adhesion
in each case is easily seen and in both
the overlying membranes and muscle are
attached to the cicatrix.

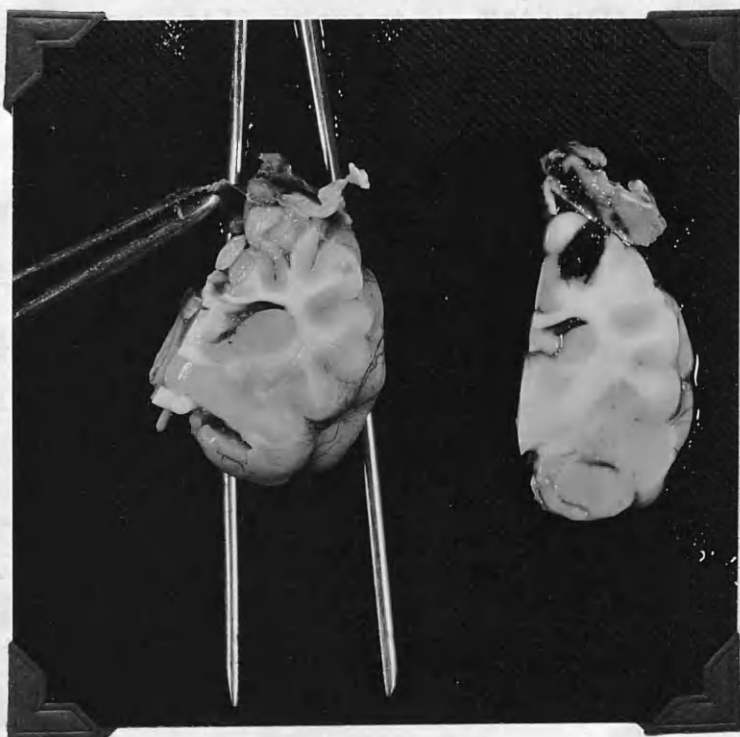
Photo 51-1435.



a



b



The gelatin sponge is present. No orientation of the glia fibrils can be recognised in the P.T.A. stains. There is a lot of reticulin present and this is well outlined. Collagen is present, in the form of fine fibery threads, throughout the scar. Gold stains show some astrocytic hypertrophy.

Cat.P.35.51. Wt.3.2.kg. Intra musc. cortisone.

Survival time - 32 days.

Gross. Course unremarkable. Well marked adhesion was found between the dura and the brain at sacrifice.

Microscopic. The demarcation of the wound from the surrounding brain is not very good. The meninges show no thickening and look well. There is still evidence of phagocytosis and occasionally giant cells are seen. Remnants of the gelatin sponge are still present. Reticulin is very scanty. Collagen in the H.V.G. stains is plentiful. In parts it runs in streams, in others it is a more mature, homogeneous looking material. No general effect of cortisone on the brain can be recognised.

Cat P.51.51 Wt.3.5. kg. Intra musc. cortisone.

Survival time - 37 days.

Gross. It was attempted in this case to obtain a coronal section through the skull, meninges and brain with the structures intact. This was achieved by the use of a small electric saw. The tissue was bound intact with thread and decalcified slowly in hydrochloric and formic acid.

Fig. 8

Cat 22.51

40 day control

Showing the rather delicate young
looking collagen fibres found in
this case.

HVG. x 312.

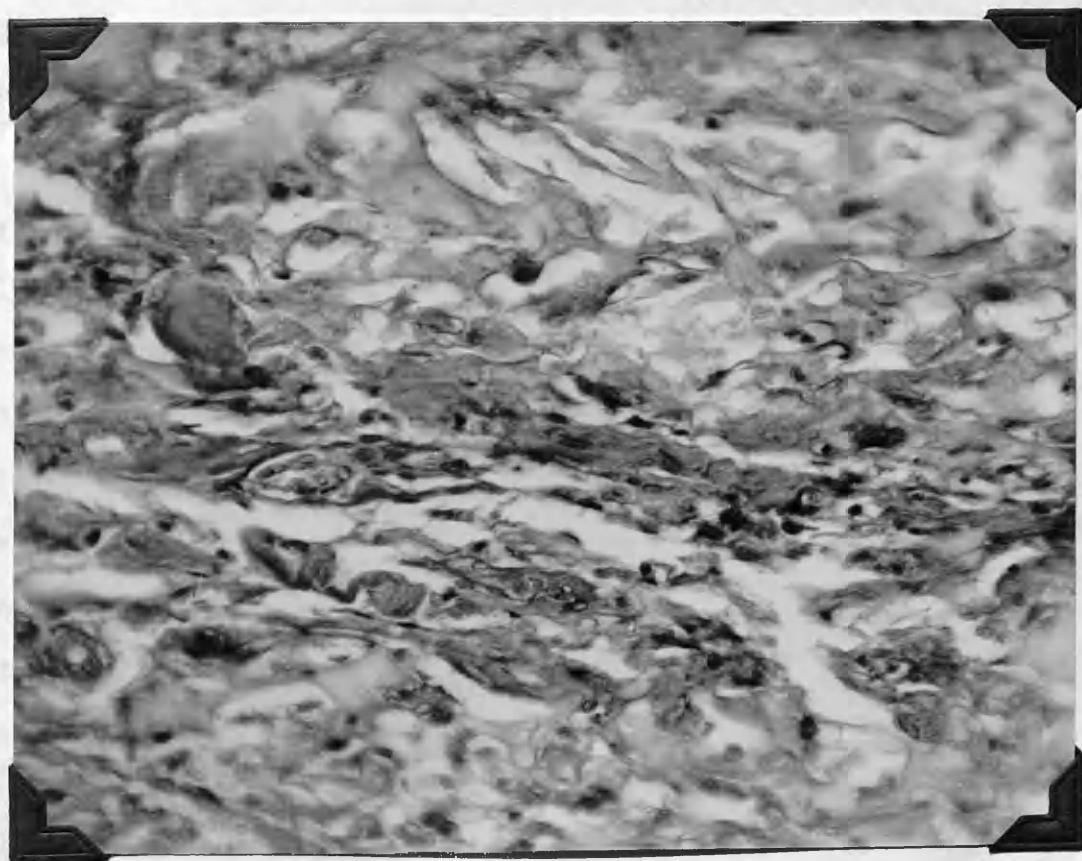
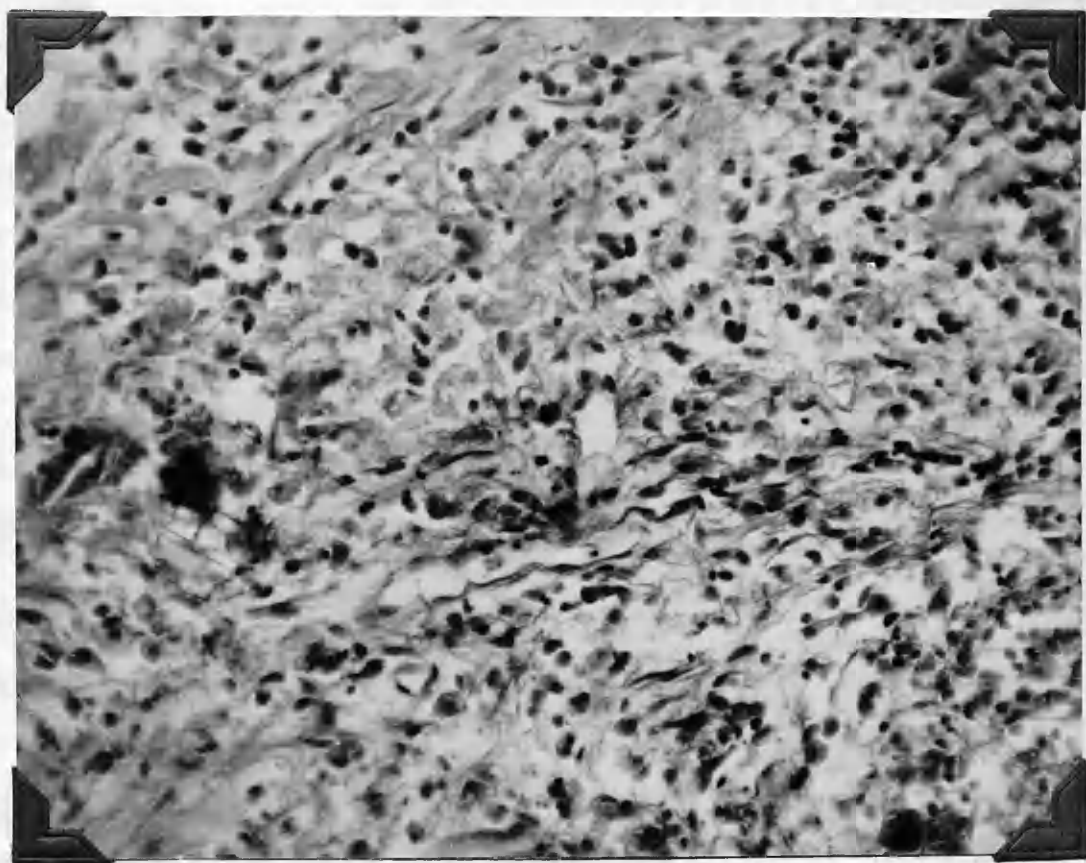
Fig. 9.

Cat 34.51

43 day intra musc. cortisone inj.

This shows collagen fibres more homogeneous
and mature than in the control wound (above)

HVG. x 312.



An adhesion was present.

Microscopic. The cellular elements of brain are not clearly outlined due to the decalcifying process. However, collagen is plentiful and is well formed and condensed. The gelatin sponge is present and undergoing phagocytosis. Fibroblasts are present in number.

Cat P.22.51. Wt.3.25 kg. Control.

Survival time - 40 days.

Gross. Course was unremarkable, remained well during the whole period. Well established adhesions between entire extent of wound and the dura were found at sacrifice.

Microscopic. The meninges show minimal thickening. The wound is not too well demarcated from adjacent tissue. There is still a great deal of phagocytosis going on in the wound. There are numerous inflammatory cells, polymorphs and plasma cells, at one edge of the wound. There is evidence of remnants of the gelatin sponge, although this is slight. In the P.T.A. and gold stains the fibrils of the glia are orientated towards the wound quite markedly and in the gold stains the astrocytes can be seen showing this change at quite a distance from the wound (fig.10). Many capillaries are visible around the margins of the wound. There is abundant reticulin present. Collagen is very plentiful and is young looking, appearing very fibery and running in streams (fig.8).

This is to demonstrate the effect of the
 hyperemia of the wound and orientation
 of the wound towards the wound.
 Vascularization can occasionally be

seen.

Fig. 156.

Fig. 11.

A table giving a comparison of the
 histological features of the animals

treated with intra-muscular cortisone

with the controls.

Fig. 10.

Cat 22.51 40 day control

This is to demonstrate gliosis with
hypertrophy of astrocytes and orientation
of their processes towards the wound.
Vascular feet can occasionally be
seen.

GCS. x 156.

Fig. 11.

A table giving a comparison of the
histological features of the animals
treated with intra musc. cortisone
with the controls.

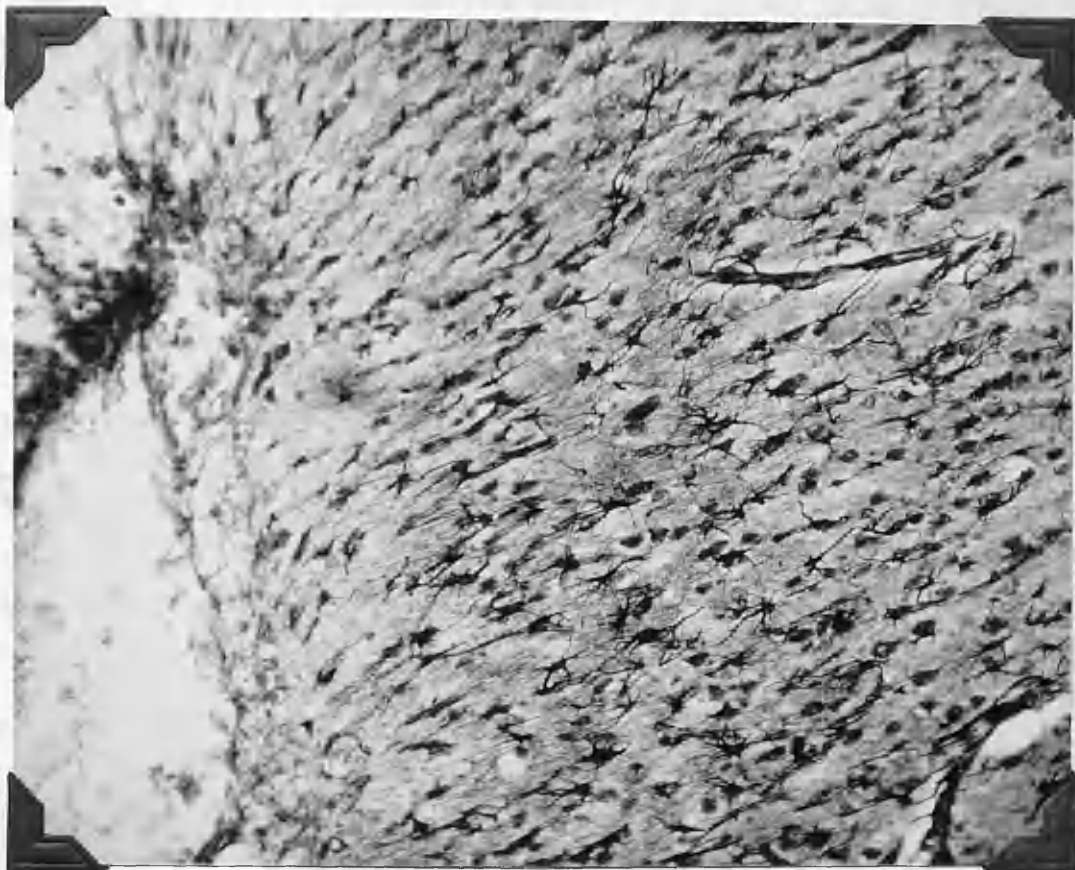


TABLE I
Histological Features of Cortisone and Control Animals

No. of cat	No. of days	Meningo-cerebral adhesion	Meningeal thickening	Zone of reaction & edema*	Phagocytosis	Gelatin sponge	Fibroblasts	Collagen	Reticulin	Vascularity	General effect of cortisone in brain
<u>Cortisone Animals</u>											
51.36	5	Present	None	Minimal	Marked	Intact	Scanty	None	None	Moderate	None
51.48	7	Present	None	Minimal	Marked	Phagocytosis beginning	Scanty	None	None	Moderate	None
51.46	15	Present	None	Minimal	Marked	Fragmented	Moderate number	Appearing	Appearing	Moderate	None
51.49	24	None	None	Very minimal	Moderate	Fragmented	Numerous	Present	Present	Very slight	None
51.52	25	None	None	Moderate	Moderate	Fragmented	Numerous	Present	Present	Slight	None
51.35	32	Present	None	Moderate	Moderate	Recognizable	Plentiful	Plentiful	Present	Moderate	None
51.51	37	Present	Minimal	Minimal	Still active	Recognizable	Plentiful	Heavy and thick	Present	Moderate	None
51.34	42	Present	Minimal	Very minimal	Still active	?Recognizable	Plentiful	Thick, mature looking	Present	Very slight	None
<u>Control Animals</u>											
51.44	8	Present	Considerable	Marked	Marked	Intact	Scanty	None	None	Quite marked	None
51.43	15	Present	Minimal	Minimal	Marked	Fragmenting	Moderate numbers	Appearing	None	Moderate	None
51.28	24	Present	Very minimal	Moderate	Moderate	Fragmenting	Numerous	Light-stained & wavy	None	Quite marked	None
51.29	31	Present	None	Moderate	Moderate	Recognizable	Plentiful	Plentiful	Plentiful	Very slight	None
51.22	40	Present	Minimal	Marked	Still active	Recognizable	Plentiful	Plentiful	Plentiful, thin, & light-staining	Moderate	None

* Minimal: width of less than one high power field. Moderate: two high power fields.

Cat. P. 34.51 Wt. 2.5 kg. Intra musc. cortisone.

Survival time - 43 days.

Gross. In removing the skull in this case the bone was nibbled right up to the edge of the wound to display the adhesions, which extended firmly right the way along the length of the wound.

Microscopic. The meninges are very slightly thickened at one side of the wound. The demarcation from the surrounding tissue is very good indeed and the wound appears to have contracted well. Gelatin sponge cannot be stated definitely to be present but there are crystals which probably represent elements of it. There is no orientation whatsoever of the glial fibrils towards the wound visible in P.T.A. or gold stains. The collagen which is quite plentiful looks darker, more compact and mature than in the control P.22.51 (fig.9). Few capillaries are noted around the margins of the wound. Occasional phagocytes can be seen. There is little reticulin. The cicatrix is sharply circumscribed and the adjacent architecture little disturbed. No general effect of cortisone on nerve cells and glia can be seen.

Cat. 120.51 Wt. 2.7 kg. Local cortisone acetate.

Survival 7 days.

Gross. No adhesion could be seen grossly when the animal was sacrificed. The wound edge looked slightly irregular when the preparation was cut after being fixed in 10% formalin.

Microscopic. There is no thickening of the meninges whatsoever. The wound edges have fallen together nicely and do not gape in the - - - - -

This is to illustrate a feature found
 almost constantly in the sections - a
 thickening of the epidermal lining in the
 areas nearest the wound with gradual
 attenuation.

CV. x 512.

Fig. 12. -
 illustrating the process of the
 cellular response.

CV. x 512.

Fig. 12.

Cat 43.51 15 day control.

This is to illustrate a feature found almost constantly in the sections - a thickening of the ependymal lining in the area nearest the wound with gradual attenuation.

CV. x 312.

Fig. 13.

Cat 48.51 7 day intra musc. inj. cortisone.

Illustrating phagocytosis of the gelatin sponge.

HVG. x 576.

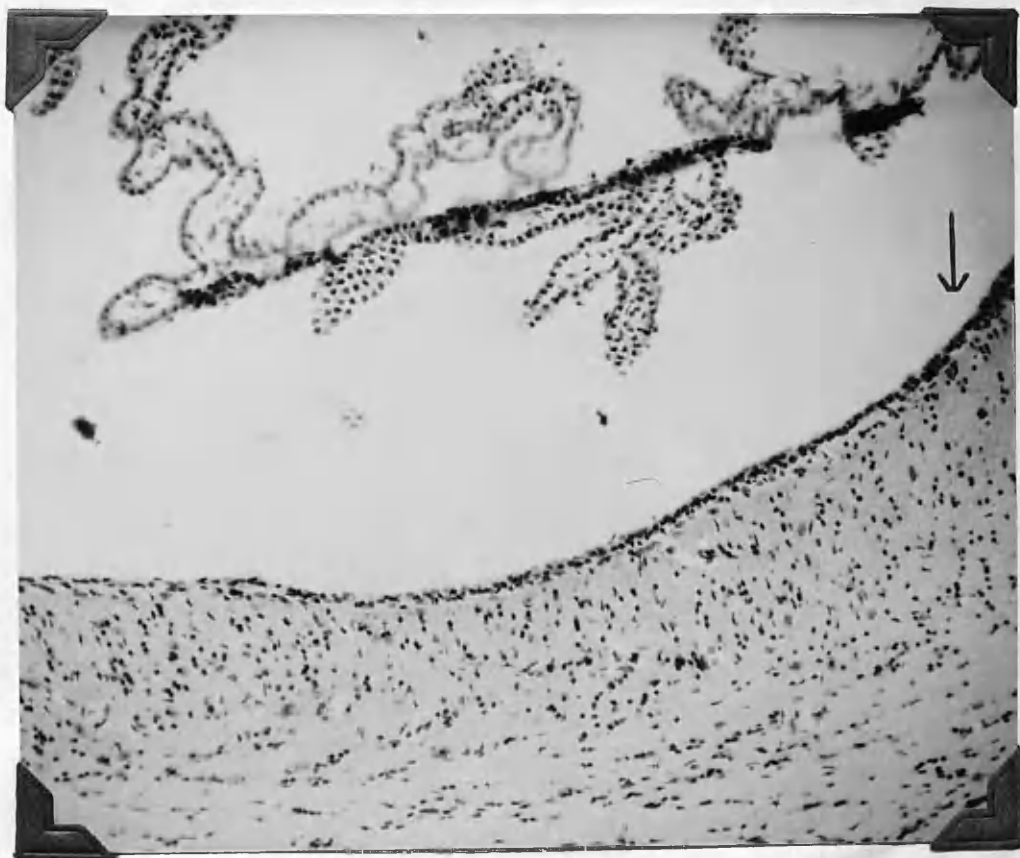


Fig. 11. 14 day local cortisone acetate
Oct 1955.51

This shows an adhesion right the

way along the surface.

Photo 51-1055.

Fig. 14.

Oct 1955.51 14 day local cortisone acetate
(saline suspension)

This shows a small filmy adhesion at

the edge of the wound. No adhesion was

noted in the case of the other two

animals treated by the local

application to gelatin sponge of the

saline suspension of cortisone acetate.

Photo 51-1055.

Fig. 16.

Cat 126.51 21 day local cortisone tablet powder.

This shows an adhesion right the way along the surface.

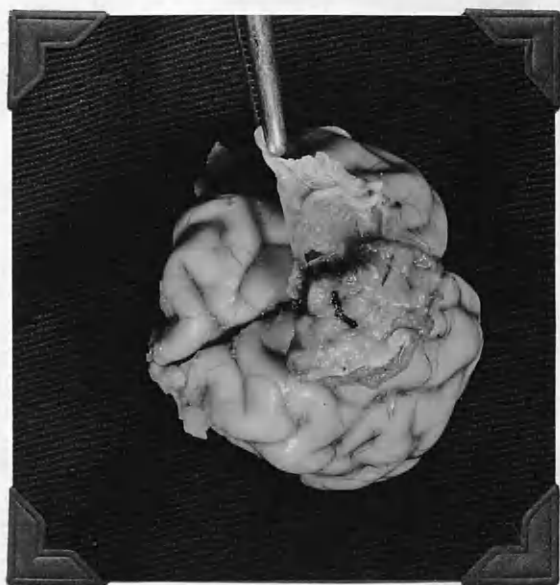
Photo 51-1359.

Fig. 17.

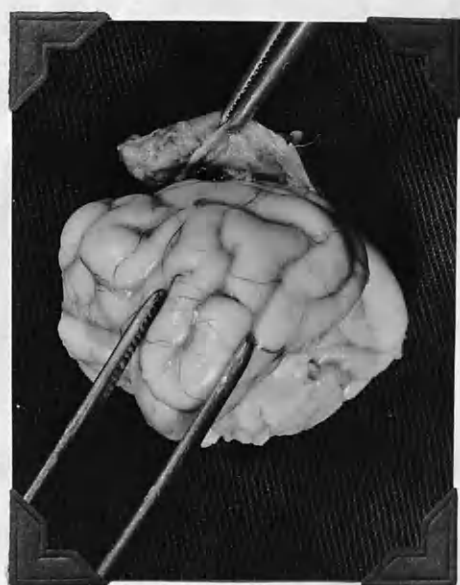
Cat 125.51 14 day local cortisone acetate
(saline suspension)

This shows a small filmy adhesion at the edge of the wound. No adhesion was noted in the case of the other two animals treated by the local application in gelatin sponge of the saline suspension of cortisone acetate.

Photo 51-1358.



16.



17.

Fig. 18.

Cat 120.51 7 day local cortisone acetate.
 (saline suspension)

Showing a low power, general view of the local cortisone acetate wound with falling together of the margins and quick disappearance of the gelatin sponge. Haemorrhage has been perfectly dealt with by the sponge before its disappearance.



HVG. x 15.

Fig. 19.

Cat 124.51 28 day local cortisone acetate
(saline suspension)

Low power view of the 28 day local
cortisone acetate to show good falling
together of the wound edges and no
thickening of the meninges .

HVG. x 15.



manner seen in other specimens. There is very good demarcation, the gelatin sponge has for the most part disappeared and the remaining appearance is that of a small cystic space. There is no evidence of an inflammatory reaction. Haemorrhage has been well controlled. Occasional small vessels can be seen and these do not seem to differ in size or number from the control series. There is no collagen or reticulin to be seen.

Cat 125.51 wt 3 kg Local cortisone acetate.

Survival 14 days

Gross

A very small thin filmy adhesion was present here and localised to the centre of the wound. The temporalis muscle was well bound down to the surrounding dura.

Microscopic.

Again there is a picture of a good wound with falling together of the wound edges, similar to that seen in 120.51. There is no thickening or inflammatory reaction of the meninges. The gelatin sponge has again largely disappeared only small fragments of it remain and the appearance of a small cyst persists. There is a very high degree of phagocytosis, right the way down into the base of the wound. There is no inflammatory reaction and haemorrhage has been

Fig. 20.

Cat 125.51 14 day local cortisone acetate
 (Saline Suspension)

General appearance of the wound with the gelatin sponge for the most part disappeared at 14 days.

HVG. x 15.

Fig. 21.

Cat 124.51 28 day local cortisone acetate
 (saline suspension)

This section shows excellent demarcation of the wound. This was a feature of the wounds treated by this method in contrast to the others.

HVG. x 120

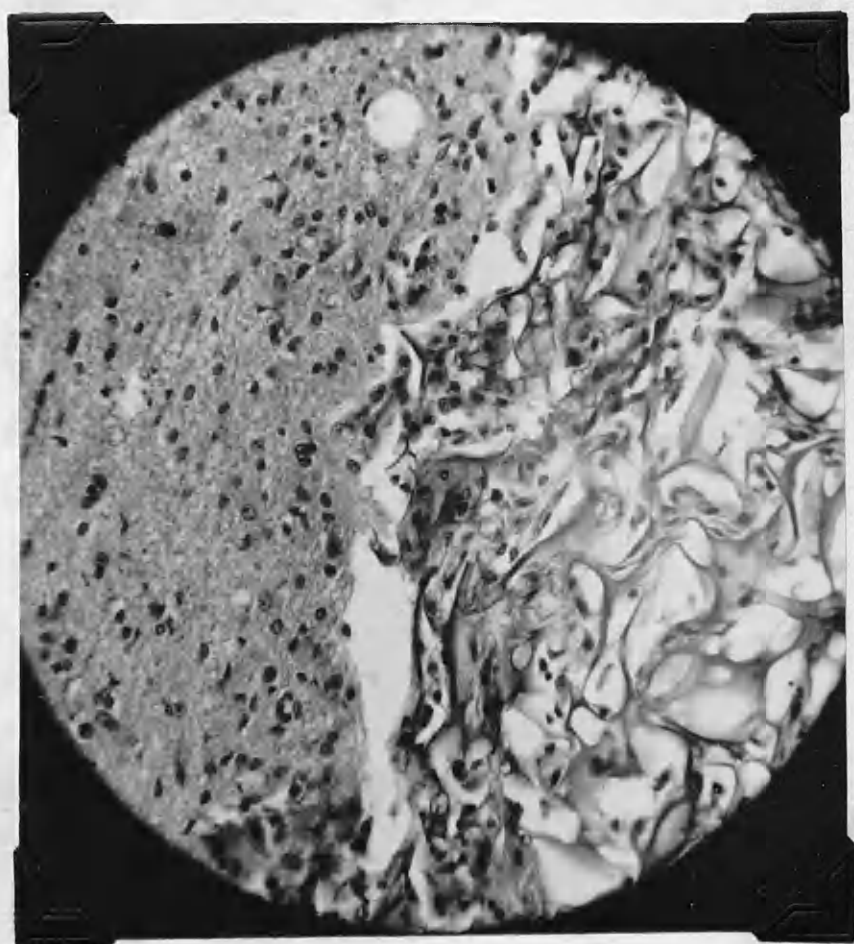
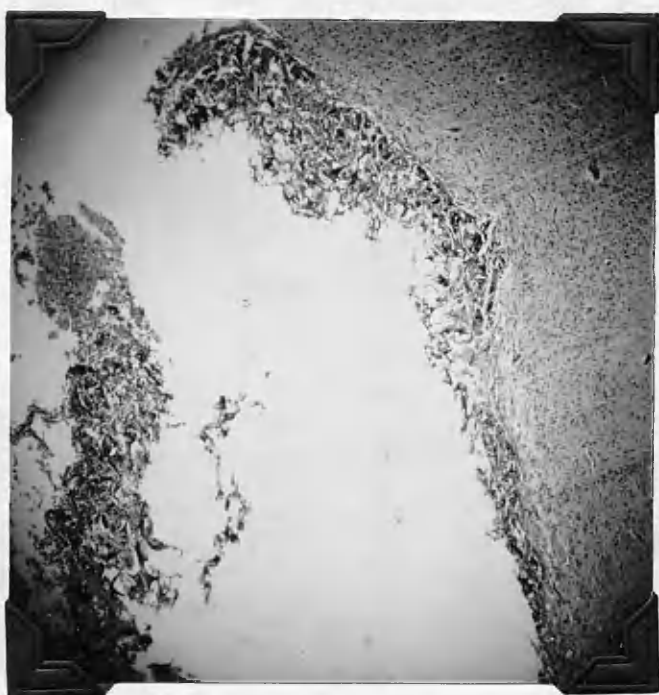

Fig. 32.

Fig. 32. The same as Fig. 31, but with the addition of the following text:

Showing the excellent photomicrographs of the

in the wound treated by the local

application of coumarin acetate (saline

suspension) in relation to the

Fig. 33.


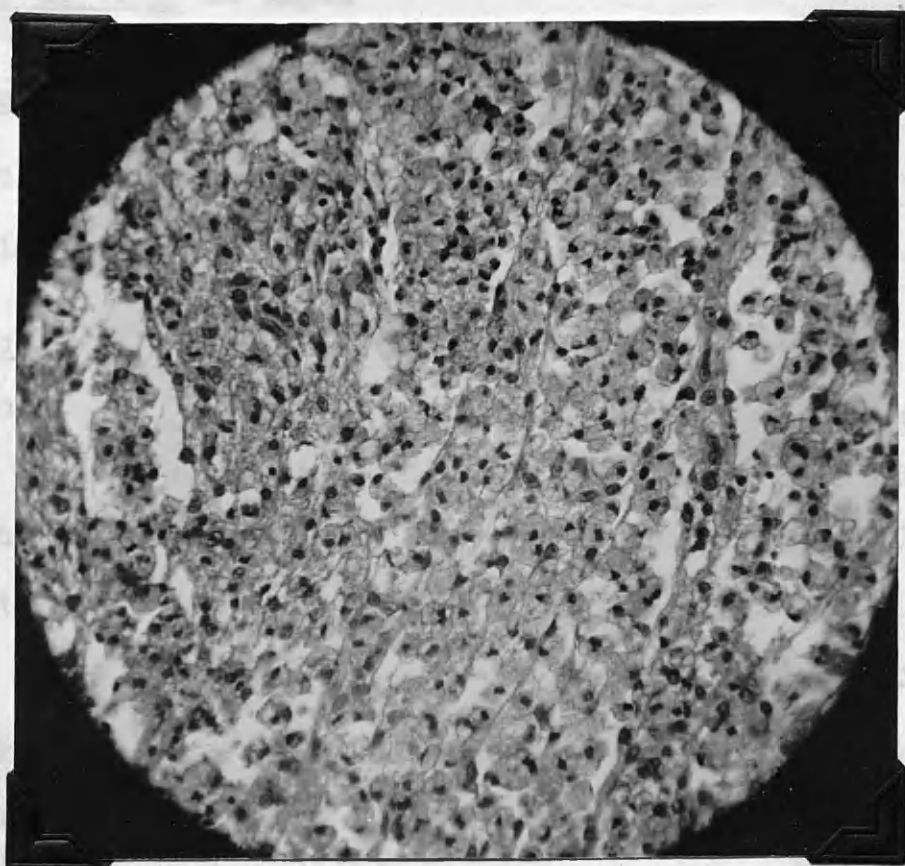


Fig. 22.

Cat 125.51 14 day local cortisone acetate.

Showing the excellent phagocytosis found
in the wounds treated by the local
application of cortisone acetate (saline
suspension) in gelatin sponge.

HVG. x 120.



well controlled. Some new vessels are present but they are not plentiful. There is a trace of collagen present; it is fine, homogeneous and light staining.

Cat 124.51 wt 3kg. Local cortisone acetate.

Survival time 28 days.

Gross.

There was no adhesion noted grossly when the animal was sacrificed. The wound margins were perfectly regular.

Microscopic.

As in 120.51 and 125.51 the wound edges have come together very well. There is no inflammatory reaction or thickening of the meninges. There is excellent demarcation of the wound from the surrounding brain tissue. Haemorrhage is well controlled. The gelatin sponge has again largely disappeared and only isolated fragments remain along the wound margins. There is no instreaming of collagen and fibrous tissue from the dura as seen in the control wounds. Collagen is present, however, but is definitely less than in the control sections. It is very light staining. Phagocytosis is still very obvious.

Cat 127.51 wt 3.4kg Local tablet application.

Survival time 14 days

Fig. 28.

Fig. 28. 21 day local carcinoma rabbit.

Showing circular at top of wound and

area of necrosis and inflammatory

material occupying wound.

Fig. 29. 21 day local carcinoma rabbit.

Fig. 29. 21 day local carcinoma rabbit.

Large area of necrosis and necrotic

debris in centre of wound.

Fig. 30. 21 day local carcinoma rabbit.

Fig. 23.

Cat 126.51 21 day local cortisone tablet.

Showing cicatrix at top, of wound and
mass of necrotic and inflammatory
material occupying wound.

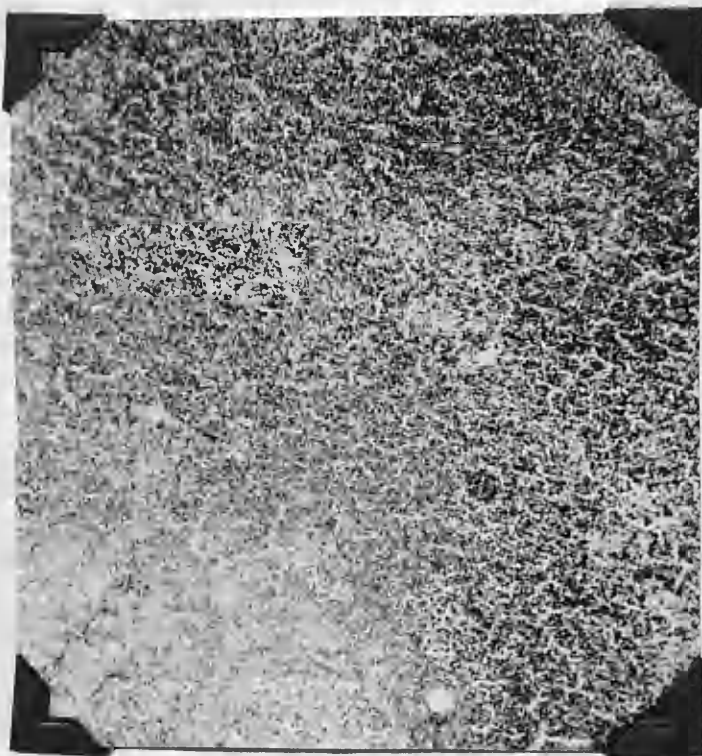
HVG. x 15.

Fig. 24.

Cat 126.51 21 day local cortisone tablet.

Large area of necrosis and necrotic
debris in centre of wound.

HVG. x 60.



Gross

There was an adhesion present at sacrifice. It extended right the way along the wound. No pus or exudate present.

Microscopic.

The wound edges are widely separated. There is minimal thickening of the meninges. There is a marked inflammatory response around the margins of the wound. Many cell types can be seen. The centre of the wound is occupied by necrotic debris. The gelatin sponge is largely in place and is invaded by inflammatory cells.

Cat 126.51 wt 2.6kg.

Local tablet application.

Survival time 21 days.

Gross

An adhesion was found along the entire extent of the wound.

Microscopic.

Again the wound margins are widely open and separated.

There is no inflammatory reaction and no thickening of the meninges. Phagocytosis is evident but this is to a large extent masked by the intense inflammatory reaction. There is an area of necrosis in the centre of the wound. The gelatin sponge is in place, largely unchanged but invaded by inflammatory cells. The adhesion to the dura is well seen

Oct 1961 21 day local correlative target.

showing well exposed strands of
reticulate branching along wound

edge.

100 x 60

Oct 1961 21 day local correlative target.

Connective tissue has achieved line
of demarcation from normal brain tissue.
Inflammatory cell reaction is extensive.

100 x 60

Fig. 25.

Cat 126.51 21 day local cortisone tablet.

Showing well marked strands of
reticulin streaming along wound
edge.

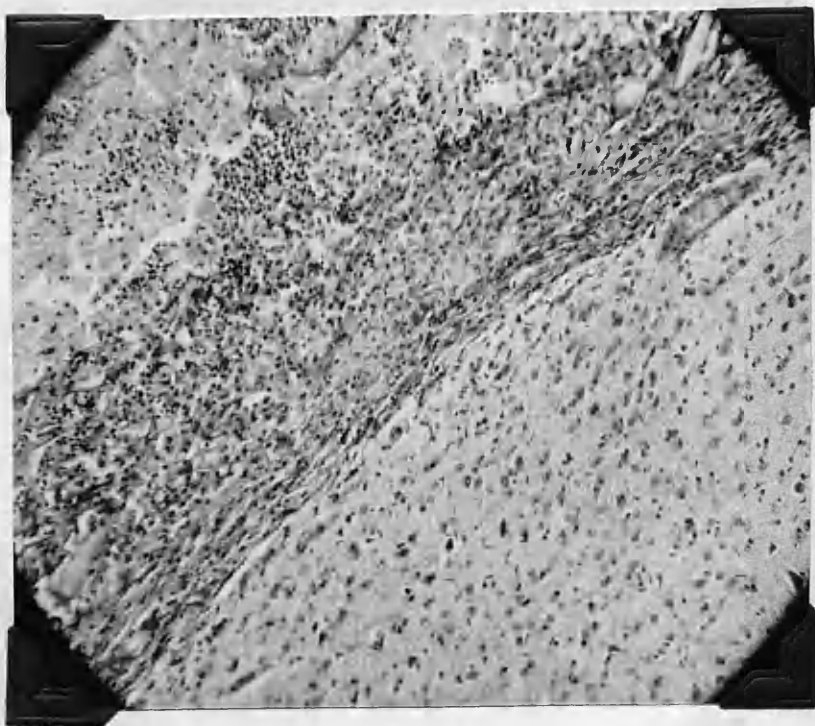
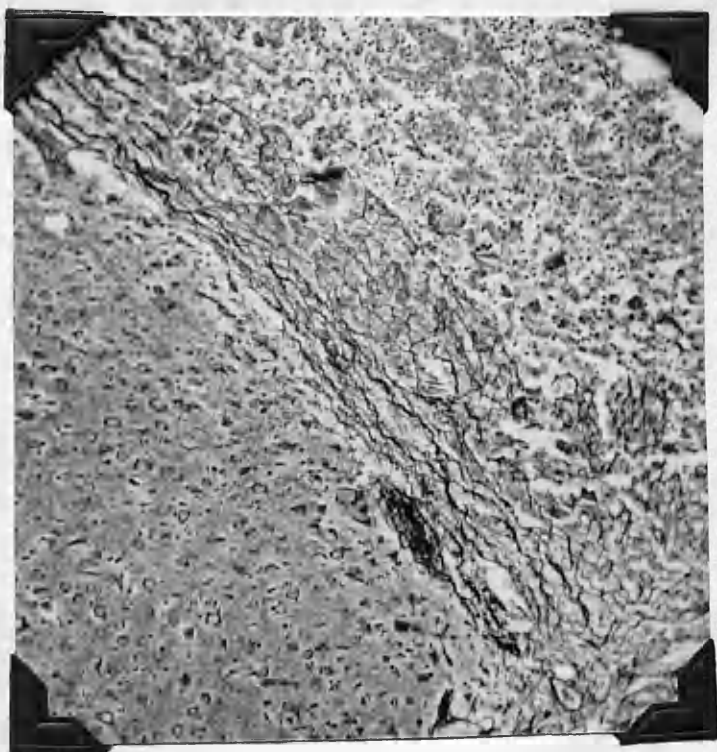
LCT. x 60.

Fig. 26.

Cat 126.51 21 day local cortisone tablet.

Connective tissue has achieved line
of demarcation from normal brain tissue.
Inflammatory cells much in evidence.

HVG. x 60.



Oct 1981. 21 day local continuous exhibit.

A composite picture showing the various

inflammatory cells found in this wound

where continuous local power was used

locally.

HVE. x 150.

Oct 1981. 21 day local continuous exhibit.

This also shows the inflammatory cells

response in the 14 day period in which

continuous local power was used locally.

HVE. x 150.

Fig. 27.

Cat 126.51 21 day local cortisone tablet.

A composite picture showing the various inflammatory cells found in this wound where cortisone tablet powder was used locally.

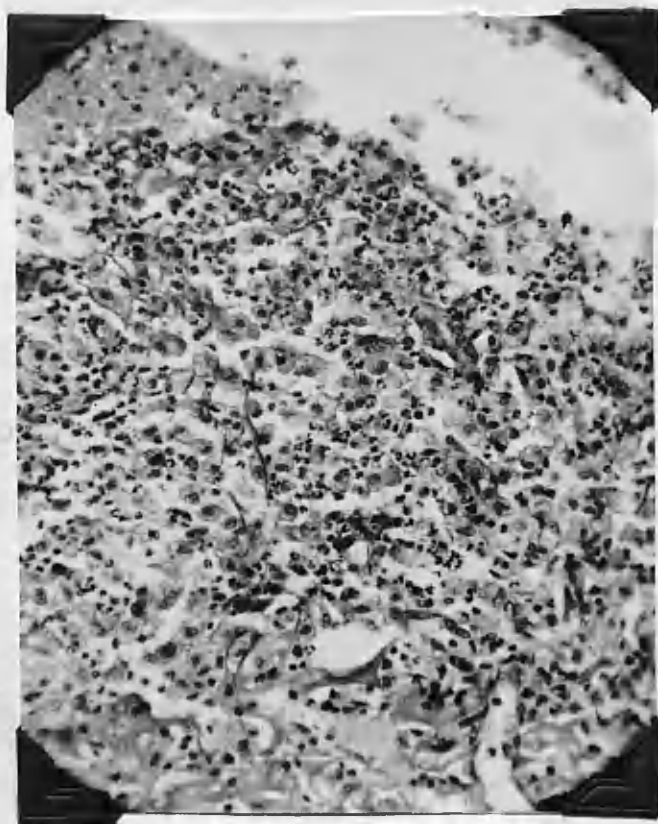
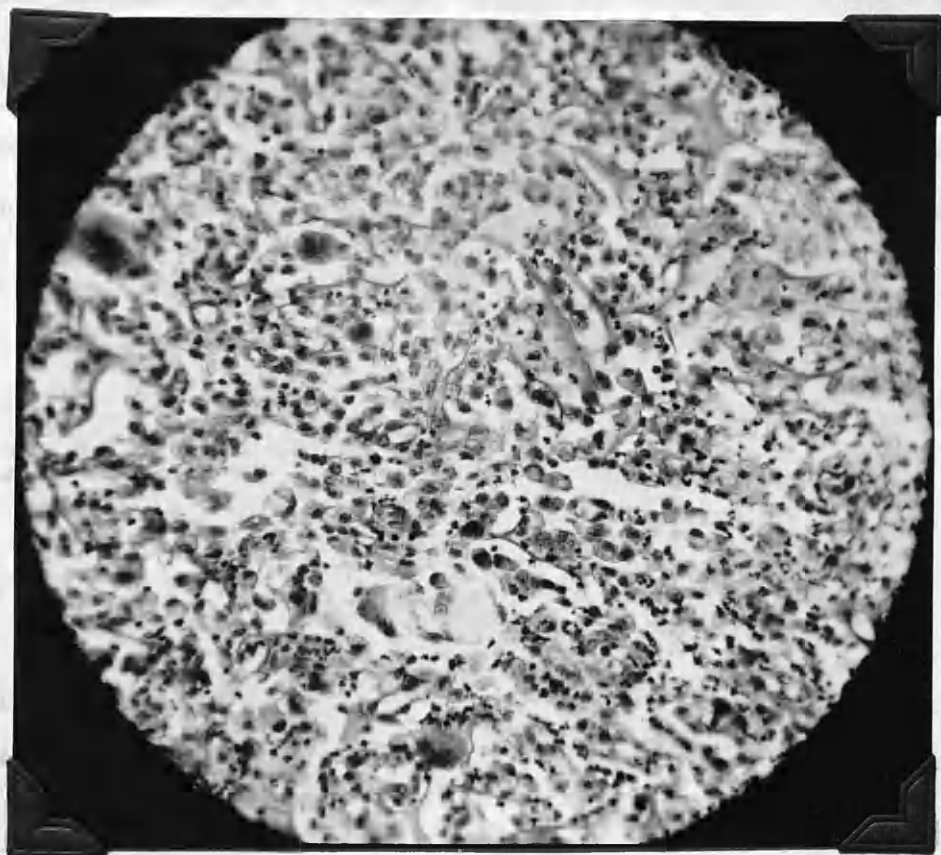
HVG. x 120.

Fig. 28.

Cat 127.51 14 day local cortisone tablet.

This also shows the inflammatory cell response in the 14 day animal in which cortisone tablet powder was used locally.

HVG. x 120.



in the microscopic section. There is much well stained collagen throughout the section. There is a pool of haemorrhage at the base of the wound. Demarcation of the wound however is good and this seems to have been achieved by a rim of collagen and connective tissue.

Cat 132.51 wt2.7kg

Cortisone by mouth.

Survival time 8 days.

Gross

An adhesion was found at sacrifice.

Microscopic.

There is no thickening or inflammatory reaction of the meninges. The gelatin sponge is for the most part still completely intact. Phagocytosis is very marked indeed.

Haemorrhage is well controlled. Demarcation not too good.

Collagen is present in the wound and although slight in amount is quite heavily stained. Many new vessels are

prominent in the base of the wound. Laidlaw's connective tissue stain shows plentiful reticulin at the base of the wound.

1948
1948-1949

Showing the well known
admission found to be correct.

Photo 11-1441

1948
1948-1949

These sections were taken in 1948
of the same in 1948-1949
and the same in 1948-1949

1948-1949

Fig. 29.

Cat 133.51 22 day Cortisone by mouth.

Showing the well marked though soft
adhesion found at sacrifice.

Photo 51-1491.

Fig. 30.

Cats 133.51 and 136.51 Cortisone by mouth.
22 days and 14 days

These sections made following fixation
of the brain in 10% formalin show the
adhesions with the overlying dura and
muscle adherent to the scar.

Photo 51-1492.

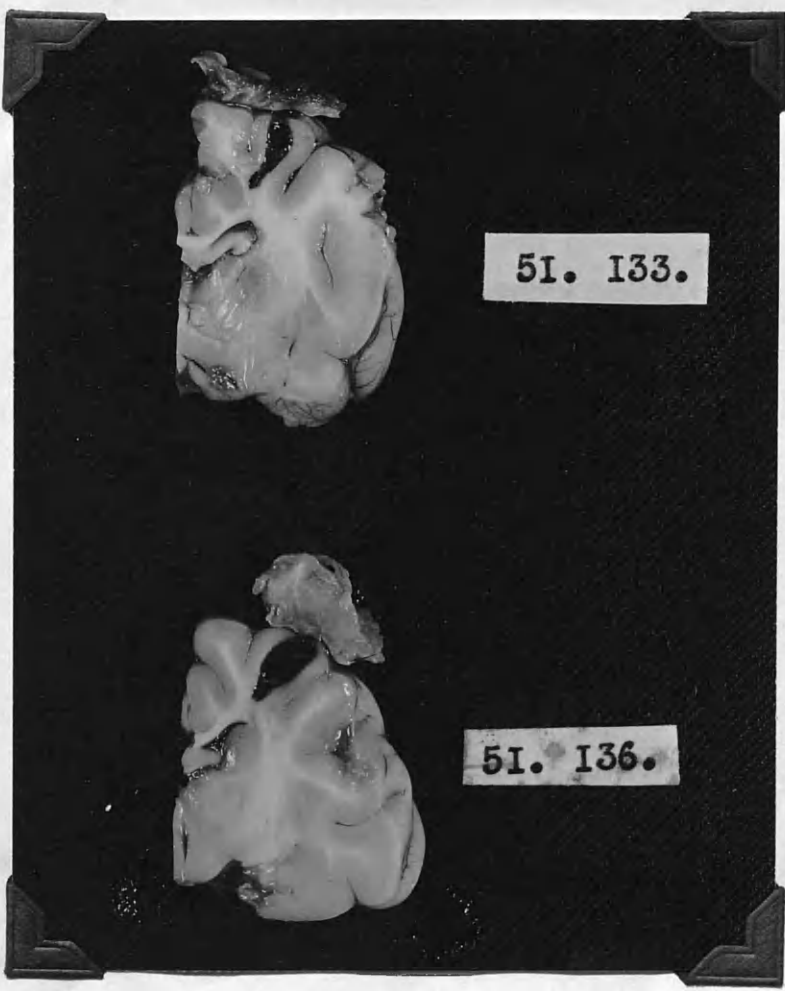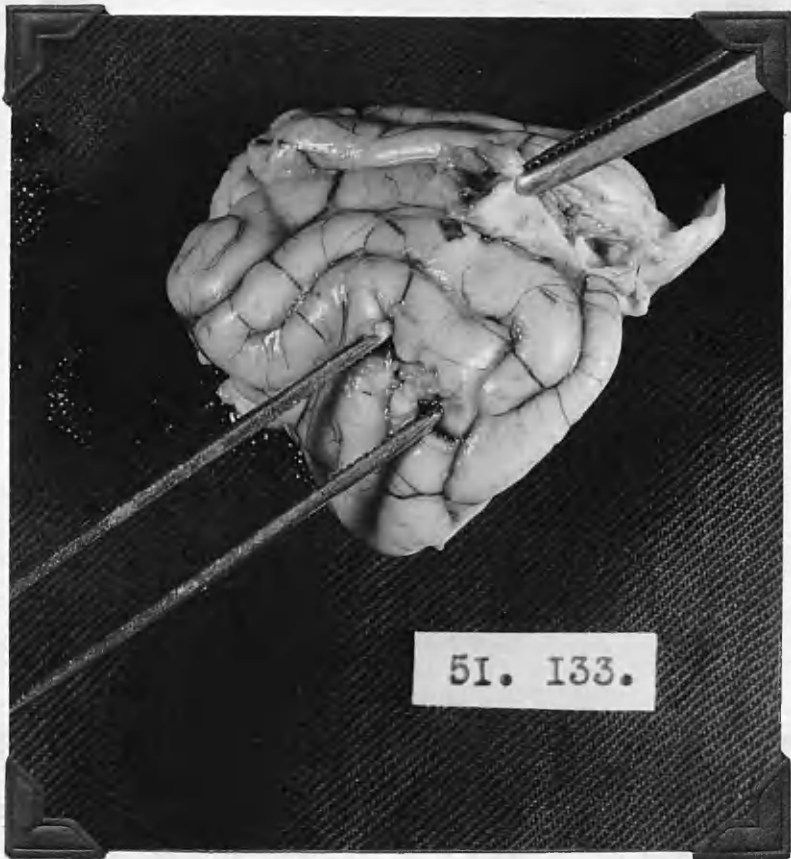


Fig. 31.

Cat 132.51 8 day Cortisone by mouth.

To show the well marked cicatrix at edge of
wound. The histological processing has
slightly separated the edges of the wound.

HVG. x 60.

Fig. 32.

Cat 136.51 14 day Cortisone by mouth.

Showing the cicatrix.

HVG. x 60.

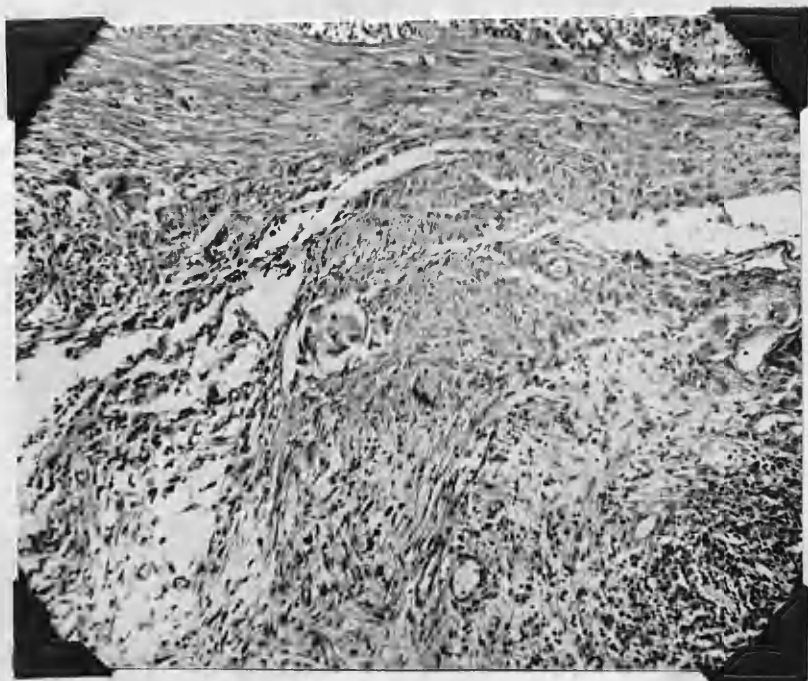
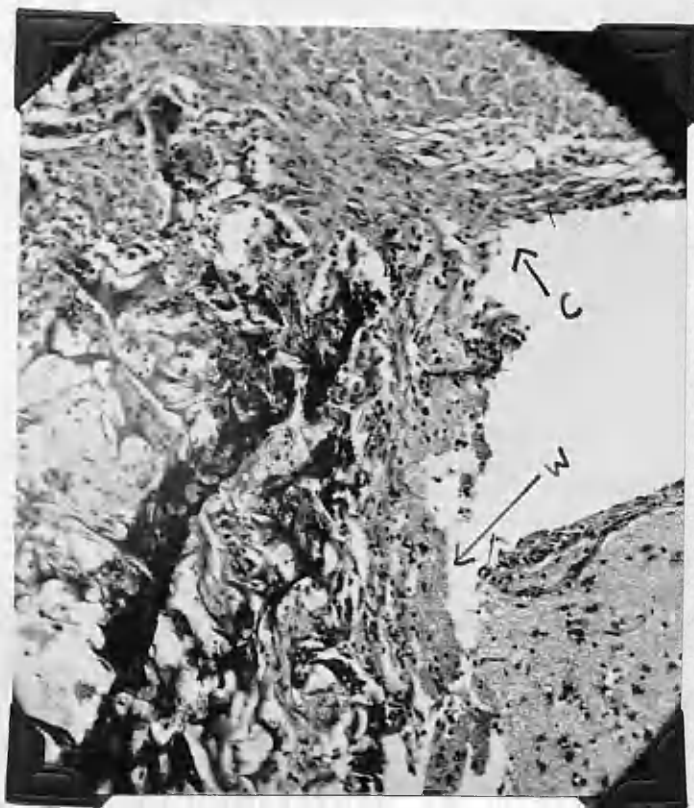


Fig. 1. 100x. 100x. 100x.

100x. 100x. 100x. 100x. 100x. 100x. 100x. 100x. 100x. 100x.

These sections show the marked separation

of reticulin in and around the wound

found in this animal treated for 8 days

with cortisone by mouth.

100x. 100x. 100x.

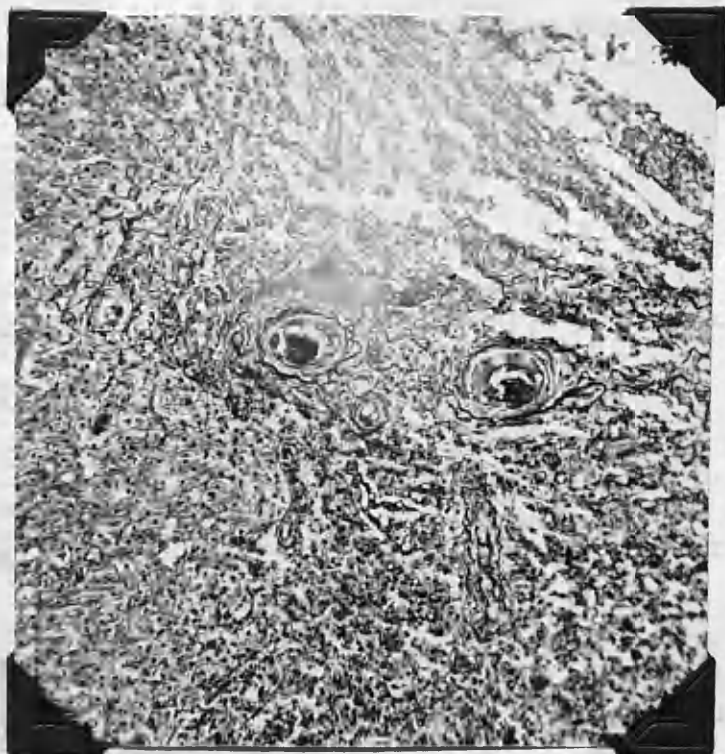

Figs. 33 and 34.

Cat 132.51

8 days Cortisone by mouth.

**These sections show the marked deposition
of reticulin in and around the wound
found in this animal treated for 8 days
with cortisone by mouth.**

LCT. x 60.



Cat 136.5l. wt 4.2kg.

Cortisone by mouth.

Survival time 14 days.

Gross.

There was an adhesion present grossly. The temporalis muscle was well bound down to the dura. No pus or exudate.

Microscopic.

There is no inflammation or thickening of the meninges. The gelatin sponge is still completely in place and a good number of red blood cells can be seen trapped in it. Collagen is present in the wound though not plentiful and it is light staining. There is a ring of fibroblasts and connective tissue around the edges of the wound. The wound is not too well demarcated. Laidlaws connective tissue stain shows lots of fine wavy reticulin in the base of the wound.

Cat 133.5l wt 3.3kg.

Cortisone by mouth.

Survival time 22 days.

Gross.

A soft adhesion was found at sacrifice. No pus or exudate.

Microscopic.

The wound margins are widely separated. There is no inflammation or thickening of the meninges. Phagocytosis

is marked especially in the base of the wound. The wound is well demarcated. The gelatin sponge is still intact and is invaded with phagocytes. There is much collagen present; it is homogeneous but well stained. Laidlaw's connective tissue stain shows much reticulin. It is fine and wavy around the edges but in quite definite streams at the base.

Cat 134.51 wt 2.3 kg.

Cortisone by mouth.

Survival time. 28 days.

Gross

No real adhesion was noted although when the removal was completed the dura was seen to be attached to the wound in a filmy fashion.

Microscopic.

The wound margins are not separated but it could not be said that they are in good apposition. There is very minimal thickening of the meninges. There is still large numbers of phagocytes present. The gelatin sponge is still present. There is a lot of collagen present and there is a stream of fibroblasts and collagen along each side of the wound.

Cat 137.51 wt 2.5 kg.

Cortisone by mouth.

Survival time 36 days.

Gross

A small adhesion was found along the entire extent of the wound.

Microscopic.

There is no inflammation or thickening of the meninges. The gelatin sponge although fragmented, is still easily recognised. The wound is not too well demarcated. Collagen is plentiful. It is homogeneous but distinctly stained. Many new vessels can be seen on scrutiny of the sections but are seen mostly in the base of the wound.

Cat 7.51 wt 3 kg.

Large lacerated wound and
intra muscular cortisone.

Survival time 8 days.

Gross.

In this case a lacerated wound had been made. Some of the damaged brain had been removed by the sucker and the remainder allowed to remain. Overlying the skull defect there was a dense adhesion of muscle and fascia. On further dissection it was seen that muscle and dura were

adherent to the brain wound.

Cat 8.51. wt 3.3 kg

Lacerated wound and
intra muscular cortisone.

Survival time 15 days.

Gross

As above a dense adhesion of muscle and dura to the wound site was found.

Cat 21.51. wt 3.35 kg

Lacerated wound and
intra muscular cortisone.

Survival time 28 days.

Gross.

The animal had pursued an uneventful course and had received a full series of intra muscular cortisone injections, 10mgm/kg body weight. At sacrifice a dense tough adhesion was found between the brain and the overlying structures.

Cat 442.50 wt 2.5 kg.

Lacerated wound with cortisone
inj. locally through scalp.

Survival time 9 days.

Gross

On incising the scalp at sacrifice a large amount of yellowish fluid escaped which was taken to be unabsorbed cortisone acetate. There was no adhesion encountered.

Cat 459.50 wt4.5 kg.

Lacerated wound with
cortisone inj. locally
Through scalp.

Survival time 14 days.

Gross.

In this case also, a large amount of yellowish serous fluid escaped when the skin of the scalp was incised at sacrifice. No adhesion was found but the cortex in the region of the wound was soft and lacked the normal texture and lustre.

Cat 443.50 wt 2.65 kg.

Lacerated wound with
cortisone inj. locally
through scalp.

Survival time 20 days.

Gross

On 12/12/50, the following information was received from the Bureau of Investigation, Washington, D.C.:

Re: Evidence of activities of the Communist Party, U.S.A., in the State of New York.

by name of the investigation.

On 12/12/50, the following information was received from the Bureau of Investigation, Washington, D.C.:

Re: Evidence of the activities of the Communist Party, U.S.A., in the State of New York.

be seen from the

Fig. 35.

Cats 247.51 and 249.51 polythene film and
14 days 33 days. intra musc. cortisone

No evidence of adhesion found at sacrifice
by naked eye inspection.

Fig. 36.

Cats 247.51 and 249.51 polythene film and
14 days 33 days intra musc. cortisone.

Sections of the brains following fixation
in 10% formalin. There are no adhesions to
be seen grossly.

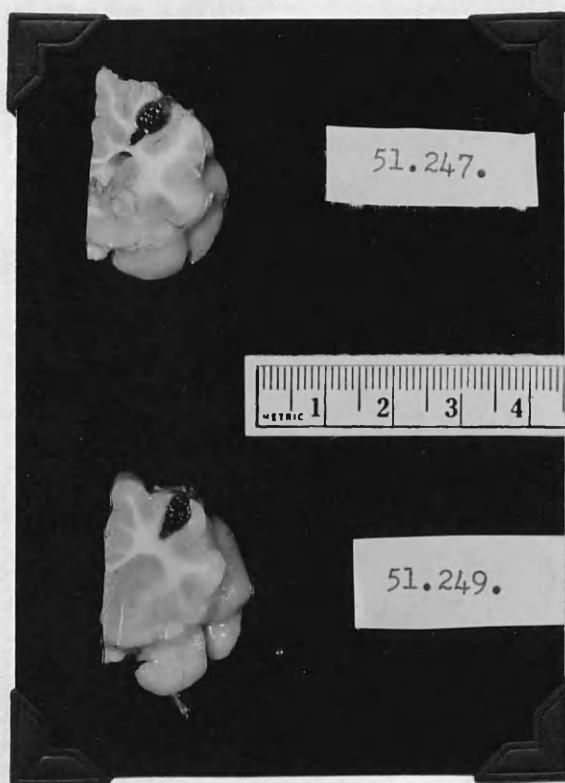
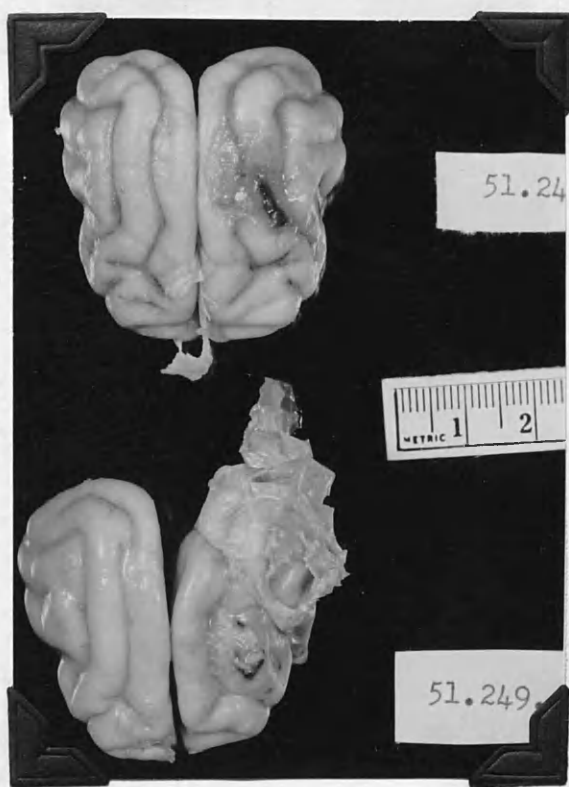

Fig. 1. 15.08.51
 The left and right sides of the brain are shown in the following sections.

This shows the brain of section 15.08.51
 there is no evidence of an abnormality.

Fig. 2. 15.08.51
 The left and right sides of the brain are shown in the following sections.

Fig. 3. 15.08.51
 The left and right sides of the brain are shown in the following sections.

Sections of brain fixed in 10% formalin

to examine the following conditions:

1. Abnormalities

Fig. 37.

Cat 250.51

45 day Polythene film and
intra musc. cortisone

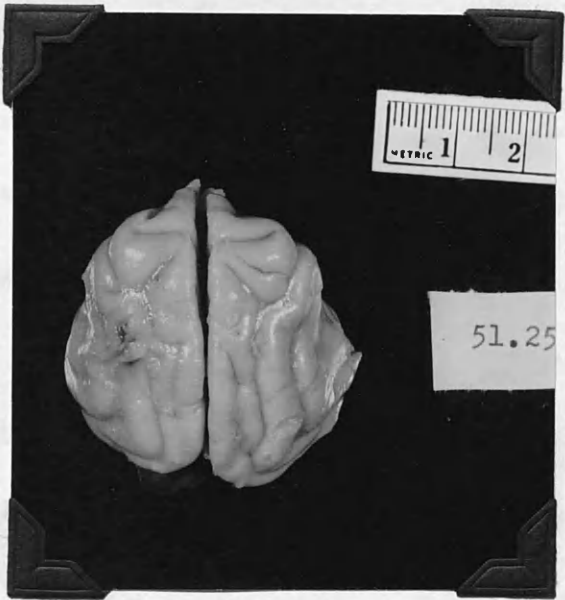
This shows the brain at sacrifice and
there is no evidence of an adhesion.

Fig. 38.

Cats 150.51 and 250.51
5 days and 45 days

polythene film and
intra musc. cortisone.

Sections of brains fixed in 10% formalin
following sacrifice with no evidence of
adhesions.



Gross

The animal resisted the local injections vigorously. The day prior to sacrifice a small amount of yellow fluid was expressed from the wound. At sacrifice this same type of fluid was present and escaped under slight pressure when the scalp was incised. Occupying the burr hole was a firm mass of what appeared to be cortisone crystals and fibrinous material. This was firmly tucked around by adhesions and was in its turn connected firmly to the wound.

Cat 149.51 wt 3.6kg.

Polythene film and
intra musc. cortisone.

Survival time 3 days

Gross At sacrifice the polythene film looked new and fresh. There was no adhesion and the film was easily removed. There was no evidence of haemorrhage or sepsis.

Microscopic. A definite inflammatory reaction with marked thickening of the meninges.

Cat 150.51 wt 3.3 kg.

Polythene film and
intra musc cortisone.

Survival time 5 days.

15 day polyethylene film and
 15 day polyethylene film and

15 day polyethylene film and

This shows some surface looking like
 the surface of a metallic film as was
 seen in the control and in 848.51 in which
 the polyethylene had slipped from the original

position

848.51 x 100

848.51 x 100

15 day polyethylene film and
 15 day polyethylene film and

15 day polyethylene film and
 15 day polyethylene film and

15 day polyethylene film and

Showing the relative position
 of the polyethylene film and

Showing the relative position
 of the polyethylene film and

and showing of the surface

in glass - many places

labeled but no evidence of

848.51 x 100

phosphorescence

848.51 x 100

Fig. 41.

Cat 247.51

14 day polythene film and
intra musc. cortisone.

This shows some mature looking collagen but no
instreaming of connective tissue such as was
seen in the controls and in 248.51 in which
the polythene had slipped from its original
position.

HVG. x 120.

Fig. 42.

Cat 247.51 14 day polythene film
intra musc. cortis.

Showing inflammatory cell reaction
and thickening of the meninges.

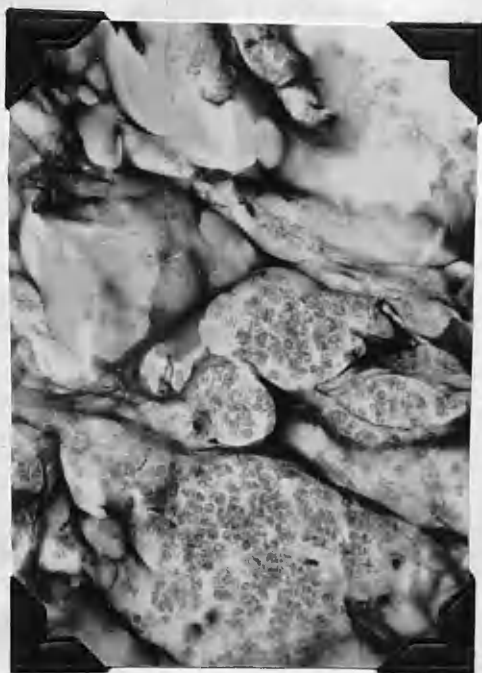
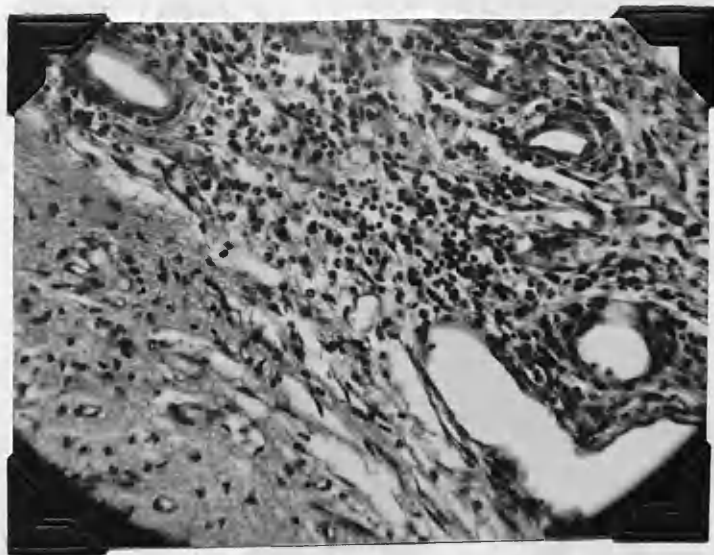
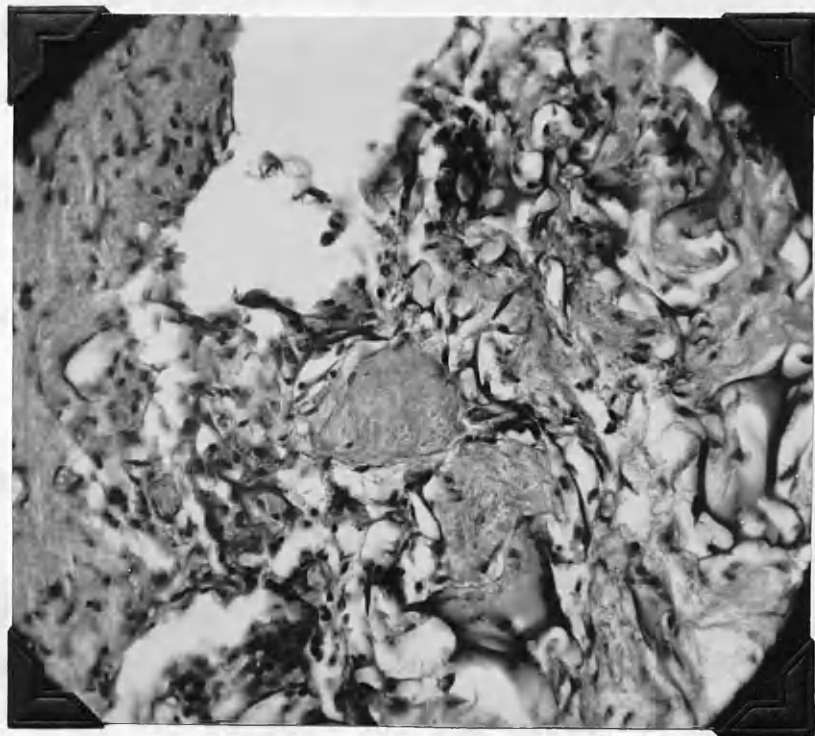HVG. x 120.

Fig. 43.

Cat 247.51 14 day polythene
intra musc
cortisone.

Showing the gelatin sponge
in place - many blood corpusc
laked but no evidence of
phagocytosis.

HVG. x 120.



Gross. No adhesion was found. The polythene film looked fresh and was cleanly and freely removed. No evidence of haemorrhage.

Microscopic. The microscopic picture was almost identical to that of 149.51 (above) showing inflammatory reaction and thickening of the meninges.

Cat 247.51 wt 4 kg.

Polythene film and
intra musc. cortisone.

Survival 14 days.

Gross No adhesion was found at sacrifice. The polythene film had a mucoid surface but was easily removed.

Microscopic. There was a marked inflammatory reaction and thickening of the meninges (fig 42). There is a lack of phagocytosis and in some areas lakes of what may be taken to be red blood corpuscles can be seen in the gelatin sponge without evidence of phagocytes. (fig 43)

Cat 248.51 wt 3.4kg.

Polythene film and
intra musc. cortisone.

Survival 21 days.

Gross On sacrifice it was found that the film had slipped a little from its original position over the wound and at that point a small gelatinous adhesion was present.

Microscopic. There is again inflammation and thickening of the meninges. (fig 39) Also, where the polythene film

cat 248.21 21 day polythene film and
intra-muscular conditions.

Showing the persistent thickening and
inflammatory reaction of the meninges
adjacent to the wound.

HVG. 2. 100.

248.21 21 day polythene film and

Fig. 40.

cat 248.21 21 day polythene film and
intra-muscular conditions.

Showing the well marked inflammatory reaction
extending into the surrounding tissue
inflammatory reaction of the meninges.
In this case the polythene film was applied
from the original position over the wound.

HVG. 2. 100.

Fig. 39.

Cat 248.51

21 day polythene film and
intra musc. cortisone.

Showing the persisting thickening and
inflammatory reaction of the meninges
adjacent to the wound.

HVG. x 120.

Fig. 40.

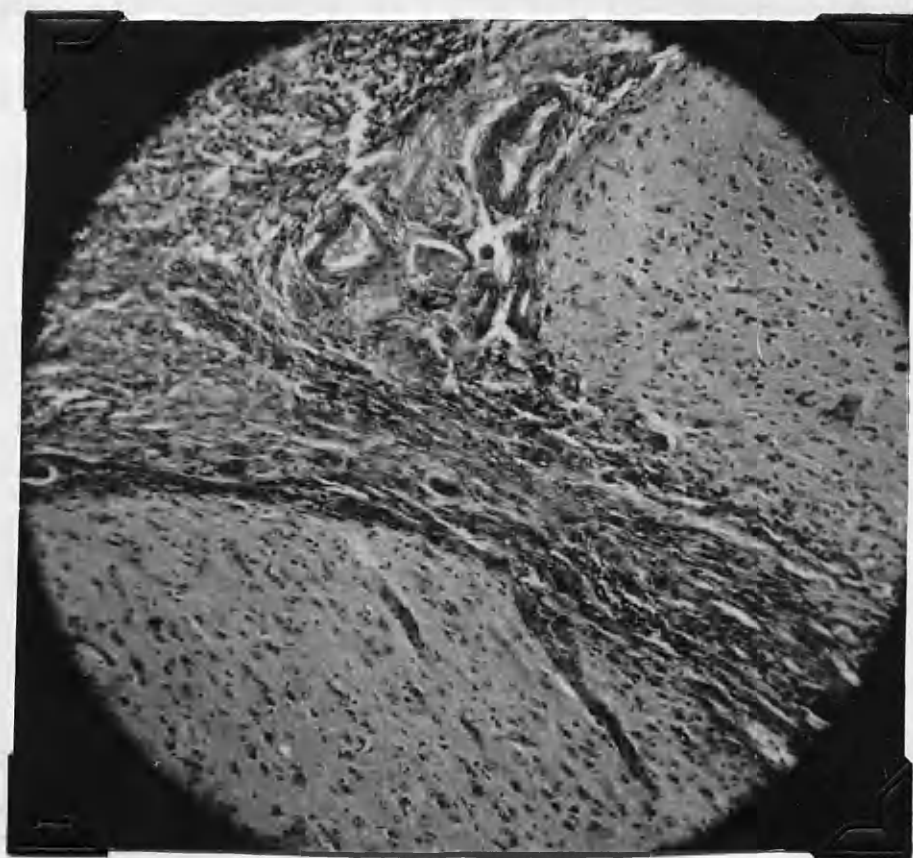
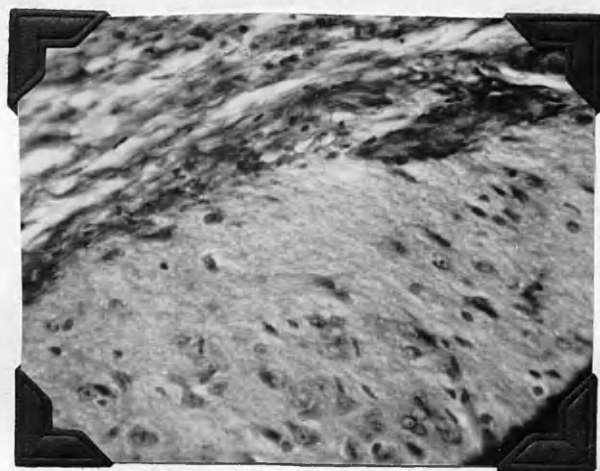
Cat 248.51

21 day polythene film and
intra musc. cortisone.

Showing the well marked connective tissue cicatrix
extending into the wound and thickening and
inflammatory reaction of the meninges.

In this case the polythene film had slipped
from its original position over the wound.

HVG. x 60.



COPIES OF THE INFORMATION REPORT TO THE
COMMITTEE ON ASSASSINATIONS, 1964-1965

...the ... of the ...

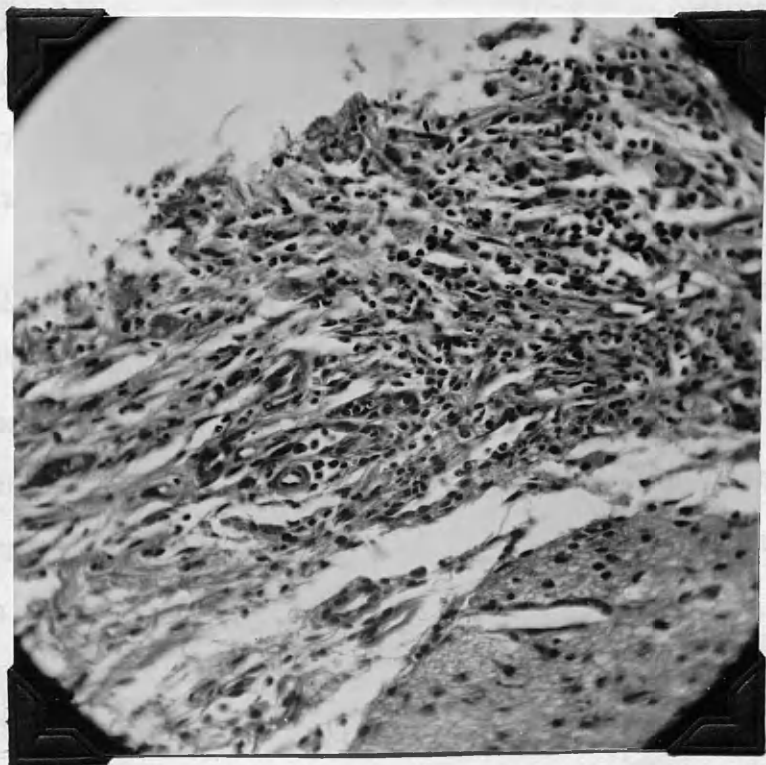
MAJ. X. OSI

Fig. 44.

Cat 250.51 45 day polythene film and
intra musc. cortisone.

This shows again the marked inflammatory response and thickening of the meninges found in the animals treated as shown above.

HVG. x 120.



had slipped the cicatrix of connective tissue can be seen (fig 40). The film itself was enclosed in a mucoid looking capsule which was composed of fibroblasts and inflammatory cells.

Cat 250.51

3.3kg.

Polythene film and
intra musc. cortisone.

Survival 45 days.

Gross At sacrifice no adhesion was found (fig 38) but the polythene film was enclosed in a mucoid capsule which was separated from the brain and dura without much difficulty.

Microscopic. The picture is that associated with the previous animals described in this group. An inflammatory cell reaction associated with thickening of the meninges (fig 44). Even for 45 days the wound is not well organised and large areas of the homogeneous gelatin sponge are still present.

SUMMARY OF EXPERIMENTAL EVIDENCE.

Examination of the cellular elements throughout all the cortisone treated sections confirmed the view obtained from previous work, that there is no recognisable general effect of cortisone on the glial and neuronal elements.

It appears that the wounds in the animal treated with intra muscular cortisone and local acetate application are well demarcated from the surrounding brain and the architecture of the adjacent cerebral tissue showed less disturbance than in the control series. The wounds treated with local application of cortisone acetate in gelatin sponge in particular showed little derangement of adjacent tissue.

Moderate thickening and inflammatory reaction of the meninges was seen in some of the control series. It was particularly well marked in the animals where polythene film had been inserted and intra muscular injection of cortisone given as well. The membranes were greatly thickened and oedematous, and contained a great variety of inflammatory cells. In the case of the local application of powdered cortisone tablet marked thickening of the meninges and inflammatory reaction was noted. The animals treated with cortisone by mouth showed a complete series without reaction or thickening of the membranes.

Early in the study it was found that the gelatin sponge was invaded by phagocytes in the 7 day intra muscular cortisone, whereas this was not the case in the 8 day control. The sponge was clearly visible undergoing various degrees of disintegration up to 35 days in the control and intra muscular cortisone preparations ; by 40 days no definite outline of the sponge could be seen but various homogeneous crystals, presumably representing its end

stages, could be recognised. As far as the controls were concerned, this was in agreement with previous writing on the subject and it was thought that the sponge did not disappear earlier under cortisone therapy. Later in the study it became apparent that wounds treated by the local application of cortisone acetate (saline suspension) in gelatin sponge presented a totally different picture. Here it was found that the gelatin sponge had mostly disappeared by 8 days and by 21 days only odd fragments of it still persisted around the edge of the wound. Haemorrhage was excellently controlled. Grossly the wounds looked well and microscopically the appearance remaining was that of a small cyst.

Phagocytosis was evident in all the sections irrespective of the mode of treatment. As was to be expected it was most marked in the early stages. It was difficult to appreciate differences in the relative degree of phagocytosis in the different groups but it was clear that in the animals treated by the local application of cortisone acetate in gelatin sponge phagocytosis was very marked (fig 22)

Well marked meningo cerebral adhesions were found in all the control animals and in all but two treated with intra muscular cortisone. All those treated with cortisone by mouth presented adhesions. Local powdered cortisone tablet presented well marked adhesions. Where irregular lacerations had been made the cicatrices were marked and firmly attached. Where polythene film had been placed over the defect and intra muscular cortisone used in addition it was found, as might be expected, that there were no adhesions. However, the polythene film was in most cases encased in a thin mucoid membrane. In addition the presence of the film was associated with an intense inflammatory

reaction and thickening of the meninges. In one instance (248.51) the polythene film had slipped from its original position and a meningo cerebral cicatrix was present. Where cortisone acetate had been used locally in gelatin sponge no adhesions were found in two cases and in the third a small, soft gelatinous looking adhesion presented.

The question of the relative amount of connective tissue found in the wounds, and its maturity is a difficult problem. Fibroblasts appear in number in the cortisone as well as the control animals. No difference in size structure or staining could be determined with certainty. The amount of collagen is interesting and important. In the control, intra muscular cortisone and cortisone by mouth group the amount of collagen in the early stages appeared equal. At any rate there was no diminution of it in the cortisone treated animals. However there would appear to be an appreciable difference in the texture or consistancy of the collagen in the later animals. The collagen of the control animals was loose, fibery, wavy in outline and stained lightly. That of the animal treated by intra muscular cortisone was thicker more condensed and appeared more mature. (figs 8 & 9). In the animals treated by the local application of cortisone acetate in gelatin sponge there was definately much less connective tissue to be seen than in the control animals (fig 21)

Attention was paid to the relative number of blood vessels and capillaries in and about the wound. The best sections in this connection were those done in celloidin and stained with cresyl violet. By this means the endothelial cells lining the capillaries were clearly outlined. Observations in this

regard were not constant and over all it appeared that there was little difference in the number of new capillaries in control and treated groups.

The animals were weighed daily. They were found almost without exception, even those under prolonged cortisone therapy, to gain weight. This increase was no doubt due to the regular and better feeding which most of the animals received in the laboratory.

CONCLUSIONS.

The injection of intra muscular cortisone in the dose of 10mgm/kg. body wt. did not prevent meningo-cerebral adhesions nor materially influence the healing of incised or lacerated wounds of the brain in cats. This is a fairly large dose representing something of the order of 700mgm. per day in the human. There was no increase in the rate of absorption of the gelatin sponge.

The oral administration of cortisone in the dose of 10mgm/kg. body wt. did not prevent meningo-cerebral adhesions nor materially influence the healing of the wounds of the brain. There was no increase in the rate of disappearance of the gelatin sponge. Demarcation of the wound from the surrounding brain tissue was no better than in the controls.

The local application of powdered cortisone tablet in gelatin sponge caused marked inflammatory response and thickening of the meninges. There was definite meningo-cerebral cicatrix formation. The centre of the wound was occupied by a mass of inflammatory and necrotic debris. Wound healing was delayed. Demarcation from surrounding brain tissue was poor.

The local application of the saline suspension of cortisone acetate in gelatin sponge proved most successful. Two of the three animals in which this was used had no meningo-cerebral

adhesions, the remaining one had a small soft looking adhesion. The gelatin sponge achieved haemostasis in the normal fashion but disappeared from the wound much earlier. The 14 day animal and the 7 day animal showed little evidence at all of the sponge microscopically. The wound margins had fallen together well. There was no thickening of the meninges. No inflammatory reaction. Phagocytosis was well marked. Demarcation of the wound from the surrounding brain tissue was very good. There was definitely less connective tissue to be seen in relation to that seen in the other groups and in the controls. Only one dose of cortisone was required to treat these animals (about $1\frac{1}{2}$ cc. = 40 mgm) in contrast to the average dose of 30 mgm per day over varying periods in the other animals.

Polythene film has been reported by several investigators as a suitable material for duroplasty and the prevention of meningo-cerebral adhesions (p27). In this study intramuscular cortisone was used in conjunction with the film in an attempt to prevent the encapsulation of the film in the thin membrane of connective tissue. The injection of 10mgm./kg body wt. failed to prevent this. As was to be expected from previous writing (p27) the presence of the film prevented the formation of a distinct meningo cerebral adhesion. However, there was invariably associated an inflammatory reaction and thickening of the meninges. The healing process in the wound, notably phagocytosis, was delayed and connective tissue was plentiful throughout.

This work bears relationship to that of Baker and Whitaker (1949 and 1950: pp 69) who demonstrated that adrenocortical steroids inhibited growth of hair and epidermis by local action and that the application of hog adrenal extract dissolved in 25% alcohol to cutaneous wounds in the rat interfered with the formation of granulation tissue. It does not confirm the work of Howes et al (1950) who found that intra muscular cortisone prevented the formation of granulation tissue in the rabbit and rat. In this present work it must be remembered that the part played by the "blood brain barrier" is not known.

It remains to be seen whether or not the local administration of cortisone acetate in wounds of the brain in the human subject will substantiate the promise suggested.

ACKNOWLEDGEMENTS.

I wish to express my gratitude to Prof. Wilder Penfield who afforded me laboratory facilities for the conduct of this problem.

My thanks are due Mr. Charles Stevens for the after care of the animals; Mrs Harriet Margolese of the dept. of Neuropathology; Mr. Ronald Harem of the dept. of Photography.

I am grateful to the National Research Council of Canada and Dr. Donald McEachern of Montreal for making available the supplies of cortisone.

I owe much to my sister, Miss Rosemary C. Gibson, for help in the final preparation of the manuscript.

This work was commenced while the writer held the Glasgow - McGill Exchange Fellowship 1950-51.

BIBLIOGRAPHY.

pp. a - u.

- ADIE W.J. 1918 656 cases of gunshot wounds of the head.
WAGSTAFFE W.W. Medical Research committee. Statistical
Report no.1. London.
- AITA J.A. 1948 Follow up study of men with penetrating
injury to the brain.
Arch.Neur.Psychiat. 59;511,1948.
- ALSTROM C.H. 1950 A study of epilepsy, in its clinical,
social and genetic aspects.
Acta Psychiat. et Neurol. Supplementum 63
Stockholm.
- ASCROFT P.B. 1941 Traumatic epilepsy after gunshot wounds
of the head.
Brit.Med.J. 1;739,1941.
- ASCROFT P.B. 1943 Treatment of head wounds due to missiles.
Lancet 2;211,1943.
- BAGGINSTOS et al 1944 The healing process in wounds of the
brain.
Proc.Mayo Clin. 19;419,1944.
- BAILEY O.T.
INGRAHAM F.D. 1947 Fibrin film in neurosurgery; further
Studies.
J.Neoursurg.4;465,1947.
- BAUM F. 1894 How to avoid adhesions in abdominal
sections.
J.Amer.Med.Ass. 23;242,1894.
- BEACH H.H.A. 1897 Gold foil in cerebral surgery.
Boston M.& S.J. 136;281,1897.
- BECK D.J.K. 1945 Implantation of acrylic resin discs in
RUSSEL D.S. rabbit's skulls.
Brit.J.Surg 33;83,1945.
- BUNE J.M. 1933 Ueber duroplastik.
Beitr.z.Klin.Chir. 157;9,1933.
- BROWN M.H. 1948 The use of polythene film as a dural
GRINDLAY J.H. substitute.An experimental and clinical
CRAIG W.McK. study.
Surg.Gyn.Obst.86;663,1948
- BROWN M.H. et al 1947 The use of polythene film as a dural
substitute.
J.Neurosurg. 4;505,1947.
- BURKE G.L. 1940 The corrosion of metals in tissues; and
an introduction to tantalum.
Canad.Med.Ass.J. 43;125,1940.

- BUSCH E. 1948 Gelatin and polythene film as dura substitute in cranial defects. Nord.Med. 40;1814,1948.
- BING J.
- HANSEN E.H.
- CAIRNS H. 1940 Treatment of gunshot wounds of peripheral nerves. Lancet 2;123,1940.
- YOUNG J.Z.
- CAIRNS H. 1944 Gunshot wounds of the head in the acute stage. Brit.Med.J. 1;33,1944.
- CAIRNS H. 1942 Head injuries in war, with especial reference to gunshot wounds. War Med. 2;772,1942.
- CAMPAILLA G. 1946 Alterazioni neuro-leptomeningee dopo un nmica introduzione di sostanze eterogenee negli spazi subaracnoidei. Dal Bol.Soc.Italiana di Biol.Sperimentale, 22;1,1946.
- CAMPBELL E. et al 1942 Studies on the use of metals in Surgery. Ann.Surg 116;763,1942.
- CAPORALE L.
- de BERNARDIS M. 1936 Sur les heteroplasties dures avec le catgut lamine. Rev.de Chir.Paris 74;10,1936.
- CARMICHAEL F.A. 1939 Histopathogenesis of cerebral abscess. Arch.Neur.& Psychat. 42;1001,1939.
- et al
- CHAO Y.C. 1940 A new method of preventing adhesions -- the use of amnioplastin after craniotomy. Brit.Med.J.1;517,1940
- HUMPHREYS S.
- PENFIELD W.
- CONE W.V. 1928 Acute pathologic changes in Neuroglia and Microglia. Arch.Neur.Psychat. 20;34,1928
- CORREL J.T. 1945 Certain properties of a new physiologically absorbable sponge. Proc.Soc.EXP.Biol.58; 233,1945.
- WISE E.C.
- CREDNER L. 1930 Klinische und sociale Auswirkungen von Hirnhadigungen. Ztschr.F.D.Ges.Neur.U.Psychiat 126;721, 1930.
- CUTTER I.S. 1930 Benjamin W. Dudley and the surgical relief of traumatic epilepsy. Int.Abst.Surg. p 189, March 1930.
- DAVIS L. 1937 An experimental study upon the preventaon of adhesions about repaired nerves and tendons. Surgery 2;877,1937.
- ARIES L.J.

- DELARUE N.C.
LINELL E.A.
McKENZIE K.G. 1944 An experimental study on the use of tantalum in the subdural space.
J.Neurosurg. 1;239,1944.
- DENNY-BROWN D. 1944 The clinical aspects of traumatic epilepsy.
Am.J.Psychiat. 100;585,1944.
- DENNY-BROWN D. 1942 The sequelae of war head injuries.
New England J.Med. 227; 771,1942.
- EAGLETON W.P. 1922 Brain abscess;Its surgical pathology and operative technique.
New York: McMillan Co. 1922.
- ELVIDGE A.R. 1940 The post traumatic convulsive and allied states.
Williams and Wilkins, Baltimore, 1940.
- EVANS W. 1931 The pathology and etiology of brain abscess.
Lancet 1; 1231 and 1289, 1931.
- FEINBERG P. 1934 Epilepsie und trauma.
Uznach 1934. published by Oberholzer.
- FERRARO A.
DAVIDOFF L.M. 1928 The reaction of the oligodendroglia to injury of the brain.
Arch.Path. 6;1030,1928.
- FERRY J.D.
MORRISON P.R. 1944 Chemical, clinical and immunological studies on the products of human plasma fractionation.
J.Clin.Invest. 23;566,1944.
- FINSTERER H. 1918 Die bedeutung der duraplastik beider Behandlung der Epilepsie nach geheilten Schadelsschussen.
Deutscha Ztschr.f.Chir. 146;145,1918.
- FOERSTER O.
PENFIELD W. 1930 Traumatic epilepsy.
Ztschr.f.d.ges.Neurol.u.Psychiat.125, 475,1930.
- FOERSTER O.
PENFIELD W. 1930 The structural basis of traumatic epilepsy and results of radical operation.
Brain 53;99,1930

- FORD F.R. 1927 Cerebral birth injuries.
Medicine monograph, Baltimore 1927.
- FRANTZ V.K. 1943 Absorbable cotton, paper and gauze.
Ann.Surg. 118;116,1943.
- FREEMAN L. 1898 Use of egg membrane in trephining operations
upon the skull.
Ann.Surg. 28;455,1898.
- FULCHER O.H. 1943 Tissue reactions to metallic implants.
MAXWELL M.M. Nav.Med.Bull. 41;845,1943.
- GAGE L. 1951 A headholder for experimental animals.
J.Neuropath.& Clin.Neurol.1;103,1951.
- GARLAND H.G. 1942 Discussion on traumatic epilepsy.
Proc.Roy.Soc.Med. London. 35;773,1942.
- GLASER M.A. 1938 Dural defects.
THIENEB C.H. Calif.and West.Med.J. 48;163,1938.
- GLIDDEN W. 1943 Gunshot woundws of the head.
Can.Med.Ass.J.49;373,1943.
- GLOBUS J.H. 1928 Glia response in chronic vascular disease
of the brain.
Arch.Neur.Psychiat.20;14,1928.
- GRINDLAY J.H. 1948 Surgical uses of polothene.
MANN F.C. Arch.Surg. 56;794,1948.
- HARVEY S.C. 1926 The development of the meninges.
BURR H.S. Arch.Neur.Psychiat. 15;545,1926.
- HARVEY S.C. Development of the meninges.
BURR H.S. Arch.Neur.Psychiat. 29;683,1933.
VanCAMPENHOUT 1933
- HASSIN G.B. 1918 Histopathological studies on brain
abscess.
M.Rec. 93;91,1918.

- HAYNES W.G. 1943 The use of sterile rubber glove as covering for dural defect resulting from removal of spinal cord tumor. Am.J.Surg. 59;133,1943.
- HICKS J.D. 1942 Experimental studies in use of amnioplastin. et al Austral.& New Zealand J.Surg. 11;268,1942.
- HICKS S.P. 1948 Brain repair. Some practical chronological aspects. Southern Med.J. 41;581,1948.
- HORSLEY V. 1890 Remarks on the surgery of the central nervous system. Brit.Med.J.2;1286,1890.
- INGRAHAM F.D. 1947 Synthetic plastic materials in surgery. et al New Eng.J.Med.236;362 & 402, 1947.
- INGRAHAM F.D. 1947 Polythene. A new synthetic plastic for use in et al surgery. J.Amer.Med.Ass. 135; 82,1947.
- INGRAHAM F.D. 1945 The use of polythene film as a dural et al substitute and in the prevention of meningo cerebral adhesions. J.Amer.Med.Ass. 128;1088,1945.
- KOBAC M.W. 1947 The relation of protein deficiency to et al experimental wound healing. Surg.Gyn.Obst. 85;751,1947.
- LEAR M. 1924 The regeneration of the meninges. The HARVEY S.C. pia arachnoid. Ann.Surg. 80;536,1924.
- LEARY T. 1933 The subdural space and its linings. EDWARDS E.A. Arch.Neur.Psychiat. 29;691,1933.
- LINELL E.A. 1929 The histology of neuroglial changes following cerebral trauma. Arch.Neur.Psychiat. 22;926,1929.
- MacEwen W. 1893 Pyogenic infective diseases of the brain and spinal cord. New York, Macmillan & Co. 1893.

- MALTBY G.L. 1946 Penetrating craaiocerebral injuries.
J.Neurosurg. 3;239,1946.
- NEUHOF H. 1920 The treatment of craniocerebral wounds
and its results.
Ann.Surg. 72;556,1920.
- NEY K.W. 1939 The repair of cranial defects with
celluloid.
Amer.J.Surg.44;394,1939.
- NONIDEZ J.F.
WINDLE W.F. - Connective tissue. in Textbook of
Histology. p67. McGraw Hill New York.
- OCHNER A. 1932 Peritoneal adhesions. Their prevention
GARSIDE E. by the use of digestive ferments.
Surg.Gyn.Obst.54;338,1932.
- OLIVECRONA H. 1941 Corticomeningeal scars in traumatic
epilepsy.
Arch.Neur.Psychiat. 45;666,1941.
- PENFIELD W. 1927 The mechanism of cicatricial contraction
on the brain.
Brain 50,499,1927.
- PENFIELD W. 1924 Meningo cerebral adhesions.
Surg.Gyn,Obst. 39;803,1924.
- PENFIELD W. 1936 Epilepsy and surgical therapy.
Arch.Neur.Psychiat. 36;499,1936.
- PENFIELD W. 1925 Phagocytic activity of microglia in the
central nervous system.
Proc.New York Path.Soc.25;71,1925.
- PENFIELD W. 1925 Microglia and the process of phagocytosis
in gliomas.
Amer.J.Path. 1;77,1925.
- PENFIELD W. 1928 A method of staining oligodendroglia and
microglia.
Amer.J.Path. 4;153,1928.
- PENFIELD W. 1932 Neuroglia and microglia. in Cowdry:
Special Cytology. Hoeber, New York.

- PENFIELD W.
BUCKLEY R.C. 1928 Punctures of the brain. The factors concerned in gliosis and cicatricial contraction.
Arch.Neur.Psychiat.20;1,1928.
- PENFIELD W.
CONE W.V. 1926 Acute swelling of oligodendroglia.
Arch.Neur.Psychiat. 16;131,1926.
- PENFIELD W.
STEELMAN H. 1947 The treatment of focal epilepsy by cortical excision.
Ann.Surg. 126,740,1947.
- PENFIELD W. 1944 Posttraumatic epilepsy.
Amer.J.Psychiat. 100;750,1944.
- PENFIELD W. Focal epilepsy.
In British Surgical Practice, vol4 pl14.
- PENFIELD W.
LIVINGSTON S. 1949 Birth injury, focal epilepsy and cortical excision.
Paediatrics, 4;157,1949.
- PENFIELD W.
SHAVER M. 1945 The incidence of traumatic epilepsy and headache after head injury in civil practice.
A.R.N.M.D. 24;620,1945.
- PENFIELD W.
HUMPHREYS S. 1940 Epileptogenic lesions of the brain.
Arch.Neur.Psychiat.43;240,1940.
- PENFIELD W. 1940 Amnioplastin - a warning.
Brit.Med.J. 2;668,1940.
- PINKERTON M.C. 1942 Amnioplastin for adherent digital flexor tendons.
Lancet 1;70,1942.
- PUDENZ R.H.
ODOM G.L. 1942 Meningo cerebral adhesions.
Surgery 12;318,1942.
- RAND C.W.
COURVILLE C.B. 1932 Reaction of the classic neuroglia.
Arch.Neur.Psychiat. 27;1342,1932.

- RAND C.W.
COURVILLE C.B. 1936. Cytoarchitectonic alterations.
Arch.neur.Psychiat. 36;1277,1936.
- RAND C.W.
COURVILLE C.B. 1932 The reaction of microglia and
oligodendroglia.
Arch.Neur.Psychiat. 27;605,1932.
- RAWLING L.B. 1922 The remote effects of gunshot wounds of
the head.
Brit.J.Surg.10;93,1922.
- RICHARDSON E.H. 1911 Studies on peritoneal adhesions.
Ann.Surg.54;758,1911.
- del RIO HORTEGA 1939 The microglia.
Lancet 1;1023,1939.
- del RIO HORTEGA 1927 Cerebral cicatrix. The reaction of neur
oglia and microglia to brain wounds.
PENFIELD W. Bull.Johns Hopkins Hosp. 41;278,1927.
- ROBERTSON R.C.L. 1945 The use of tantalum foil in the
PEACHER W.G. subdural space.
J.Neurosurg. 2;281,1945.
- ROGERS L. 1941 Experiences in treatment of peripheral
nerve injuries with amnioplastin.
Brit.Med.J. 1;587,1941.
- RUSSEL W.R. 1932 Cerebral involvement in head injury:
study based on examination of 200 cases.
Brain 55;549,1932.
- RUSSEL W.R. 1947 The anatomy of traumatic epilepsy.
Brain 70;225,1947.
- RUSSEL W.R. 1951 Disability caused by brain wounds. A
review of 1,166 cases.
J.Neur.Neurosurg. Psychiat. 14;35,1951.
- RUSSEL W.R. 1934 The after effects of head injury.
Edinburgh Med.J.41;129,1934.

- SACHS E. 1945 Two important post war problems in Neurological surgery. J.Nerv.& Ment.Dis. 101;460,1945.
- SARGENT P. 1921 Some observations on epilepsy. Brain 44;312,1921.
- SAYAD W.Y.
HARVEY S.C. 1923 The regeneration of the meninges. The dura mater. Ann.Surg. 77;129,1923.
- SCARFF J.E.
STOOKEY B. 1949 The use of dry oxidised cellulose as a primary haemostatic agent in Neurosurgery. J.Neurosurg. 6; 304,1949.
- SCHOU H.I. 1933 Trauma capitis and epilepsy. Acta Psychiat.et Neurol...8;75,1933.
- SHATALOVA G.S. 1950 Use of fibrin films in neurosurgery. Voprosy Neurokhirurgii 14;23,1950.
- SPURLING R.G. 1943 The use of tantalum wire and foil in the repair of peripheral nerves. Surg.Clin.N.Amer..23;1491,1943.
- STEELMAN H. 1949 The technique of cortical excision. An experimental study of postoperative cicatrisation. Arch.Neur.Psychiat.,62;479,1949.
- STEINTHAL K.
NAGEL H. 1926 Die Leistungsfähigkeit im Bürgerlichen Beruf nach Hirnchüssen mit besonderer Berücksichtigung der traumatischen Epilepsie. Bruns.Beit.Klin.Chir.137;361,1926.
- STEVENSON W.E. 1931 Epilepsy and gunshot wounds of the head. Brain 54;214,1931.
- SYMONDS C.P. 1935 Traumatic epilepsy. Lancet 2;1217,1935.
- SYMONDS C.P.
RUSSEL W.R. 1943 Accidental head injuries. Prognosis in service patients. Lancet 1;7,1943.

- TURNER W.A. 1923 Epilepsy and gunshot wounds of the head.
J.Neurol.& Psychopath..3;309,1923.
- Le Vann L.J. 1941 Amniotic membrane for cerebral adhesions.
Brit.Med.J. 1;213,1941.
- VENABLE C.S. 1943 A general consideration of metals for
STUCK W.G. buried appliances in surgery.
Int.Abstr.Surg.76;297,1943.
- WAGSTAFFE W. 1928 The incidence of traumatic epilepsy after
gunshot wounds of the head.
Lancet 2;861,1928.
- WALKER A.E. 1942 Treatment of penetrating wounds of the
head.
War Med. 2;454,1942.
- WATSON C.W. 1947 The incidence of epilepsy following
craniocerebral injury.
Proc.A.R.N.M.Dis. 26;516,1947.
- WILSON R.B. 1926 Brain repair.
Arch.Neur.Psychiat..15;75,1926.

- ADDIS T. et al 1950 Adrenalectomy and proteinuria in the rat.
Fed.Proc.:9,3,1950.
- ALBRIGHT F. 1943 Cushings syndrome.Its pathological
physiology.
Harvey Lectures 38;123,1943.
- ANTOPOL W. 1950 Anatomic changes produced in mice treated
with excessive doses of cortisone.
Proc.Soc.Exp,Biol.& Med.73;262,1950.
- BAKER B.L. 1950 Modification of body structure by adreno-
cortical secretions with special reference
to the regulation of growth.
A.A.S. symposium on the adrenal cortex,1950.
- BAKER B.L. 1950 Cutaneous atrophy induced by local treatment
CASTOR C.W. with adrenocortical steroids.
Anat.Rec. 106;173,1950.
- BAKER B.L. 1950 Interference with wound healing by the
WHITAKER W.L. local action of adrenocortical steroids.
Endocrinology 46; 544,1950.
- BAKER B.L.et al 1948 Growth inhibition in the skin induced by
parenteral administration of adrenocorti-
cotropin.
Anat.Rec. 102;313,1948.
- BAKER B.L. 1949 Influence of cortisone on chronically
WHITAKER W.L. induced carcinoma.
Univ.Mich.Hosp.Bull. 15;4,1949.
- BING M. 1950 Growth inhibiting properties of steroids.
Brit.Med.J. 1;846,1950.
- BISHOP C. 1950 Effect of colchicine and cortisone on
GARNER W. uric acid metabolism in gout.
TALBOTT J.H. Fed.Proc. 9;151,1950.
- BOGOMOLETS A.A. 1943 Anti reticular cytotoxic serum as a
means of pathogenic therapy.
Amer.Rev.Sov.Med. 1;101,1943.

- CARLISLE J.M. 1950 Cortisone- summary of its clinical uses.
Brit.Med.J. 2;590,1950.
- CHENG C.P. 1949 Quoted from Amer.J.Physiol. 159;426,1949.
SAYERS G.
- CLARK I. 1950 Effect of cortisone on protein metabolism
in the rat as studied with isotopic
glycine.
Fed.Proc. 9;161,1950.
- CONN J.W. 1950 1st conference on the adrenal cortex.
Josiah Macy Jr. Foundation 1950, pp95-96.
- CORI C.F. 1945 Enzymatic reactions in carbohydrate
metabolism.
Harvey Lectures p 253, 1945-46.
- CUTHBERTSON D.P. 1941 Anterior pituitary gland and protein
metabolism.
SHAW G.B. J.Endocrinology 2;475,1941.
- DEANE H.W. 1946 Quoted from Amer.J.Anat.79;117,1946.
GREEP R.O.
- DOUGHERTY T.F. 1945 Functional alterations in lymphoid
WHITE A. tissue induced by adrenal cortical
secretion.
Amer.J.Anat. 77;116,1945.
- DOUGHERTY T.F. 1944 Relationship of the effects of adrenal
et al cortical secretion on lymphoid tissue and
on antibody titre.
Proc.Soc.Exp.Biol& Med. 56;28,1944.
- DUCOMMUN P. 1950 L'action de l'ACTH sur les adherences
MACH R.S. dues a l'injection de talc dans la cavite
peritoneale des rats.
Semaine d'hop. de Paris 26;1,1950.
- ELIEL L.P. et al 1950 The comparative metabolic effects of
ACTH, cortisone acetate, and compound F
acetate in a patient with chronic
lymphatic leukaemia.
J.Clin.Investigation 29;811,1950

- EMERSON G.A. 1950 Regression of lymphosarcoma transplants
WURTZ E. following the administration of cortisone
ZANETTI M.E. to riboflavine deficient mice.
Fed.Proc. 9;357,1950.
- FORSHAM P.H. et al 1949 Quoted from J.Clin.Investigation 9;660.
- FORSHAM P.H. 1948 Clinical studies with pituitary
adrenocorticotropin.
J.Clin.Endocrin. 8;15,1948.
- FORTIER C. 1951 Influence of adrenaline and insulin
SKELTON F.R. on adrenal cortical response to ACTH.
Proc.Soc.Exp.Biol.& Med 76;77,1951.
- FRAENKEL*CONRAT H. 1943 Influence of adrenalectomy and of
adrenocortical steroids on liver
arginase.
J.Biol.Chem. 147;99,1943.
- GERMUTH F.G. 1951 Anatomic and histological changes in
NEDZELG.A. rabbits with experimental hypersensitivity
treated with coumpound E and ACTH.
Proc.Soc.Exp.Biol & Med 76;177,1951.
- GORDON A.S. 1949 RELation of adrenal cortex to structure
KATSH G.F. and phagocytic activity of macrophagic
system.
Ann.N.Y.Acad.Science. 52;1,1949.
- GREEP R.O. 1947 Quoted from Endocrinology 40; 417,1947.
DEANE H.W.
- HECTER O. 1949 In vitro effect of adrenal cortical extract
JOHNSON S. upon lymphocytolysis.
Endocrinology 45;351,1949.
- HEILMAN D.H. 1945 Effect of cortisone and 11-dehydro cort-
icosterone on the migration of macrophages
in tissue culture.
Proc.Staff. Meet.Mayo Clin. 20;318,1945.
- HEILMAN D.H. 1945 Effect of cortisone and 11-dehydrocort-
icosterone on lymphocytes in tissue culture.
Proc.Staff Meet.Mayo Clin. 20;310,1945.

- HEILMAN F.R.
KENDALL E.C. 1944 The influence of compound E on the growth of a malignant tumour in the mouse. Endocrinology 34;416,1944.
- HENDH P.S.
KENDALL E.C. 1950 Effects of cortisone acetate and pituitary ACTH on rheumatoid arthritis, rheumatic fever and certain other conditions. Arch.Int.Med. 85;545,1950.
- HIGGINS G.M.
et al 1950 The influence of cortisone upon the growth of a transplanted rhabdomyosarcoma in C3H mice. Cancer Research 10;203,1950.
- HILLS A.G.
et al 1948 Changes in circulating leukocytes induced by administration of ACTH in man. Blood 7;755,1948.
- HOBERMAN H.D. 1950 Endocrine regulation of amino acid and protein metabolism during fasting. Yale J.Biol. & Med. 22;341,1950.
- HOWES E.L.
PLOTZ C.M.
et al 1950 Retardation of wound healing by cortisone. Surgery 28; 177,1950.
- HYMAN C.
CHAMBERS R. 1943 Effect of adrenal cortical compounds on oedema formation of frogs hind limbs. Endocrinology 32;310,1943.
- INGLE D.J. 1943 Relationship of the adrenal cortex to the metabolism of fat. J.Clin. Endocrin. 3;603,1943.
- INGLE D.J. 1940 The effect of two cortin like compounds upon the body weight and work performance of adrenalectomised rats. Endocrinology 27;297,1940.
- INGLE D.J. 1941 Work performance of adrenalectomised rats treated with 11-desoxycorticosterone sodium phosphate and cortisone. Amer.J.Physiol. 133;676,1941.
- INGLE D.J.
MASON H.L. 1938 Subcutaneous administration of cortin compounds in solid form to the rat. Proc.Soc.Exper.Biol & Med. 39; 154, 1938.

- INGLE D.J.
et al 1945 A comparison of adrenal steroid diabetes and pancreatic diabetes in the rat. Endocrinology 37;341,1945.
- INGLE D.J.
KENDALL E.C. 1940 Influence of amorphous fraction from adrenal cortex on efficiency of muscle. Proc.Soc.Exp.Biol & med. 45;602,1940.
- INGLE D.J.
THORN G.W. 1941 A comparison of the effects of 11- desoxy corticosterone and cortisone in partially depancreatized rats. Amer.J.Physiol. 132,670,1941.
- INGLE D.J. 1938 Quoted from Amer.J.Physiol. 124;627,1938.
- INGLE D.J.
KENDALL E.C. 1938 Quoted from Amer.J.Physiol. 122;585,1938.
- JONES I.S.
MEYER K. 1950 Inhibition of vascularisation of the rabbit cornea by local application of cortisone. Proc.Soc.Exp.Biol & Med. 74;102,1950.
- KARNOFSKY d a
et al 1950 The effect of adrenal steroids on the growth of chick embryo. Fed. Proc. 9;290,1950.
- KENDALL E C 1950 Chemistry of the adrenal cortex. Science 111; 457,1950.
- KENDALL E C 1950 Studies related to the adrenal cortex. Fed. Proc. 9;501, 1950.
- KNOLTON A I
et al 1949 The development of hypertension and nephritis in normal and adrenalectomized rats treated with cortisone. Proc Soc Exper Biol Med. 72;722,1949.
- KOCHAKIAN C D . 1944 Conference on metabolic aspects of convalescence. Josiah Macy Foundation 1944 pp 13-35.

- KOCHAKIAN C.D. 1950 Effect of adrenal cortical steroids on arginase activity.
Fed Proc. 9;191,1950.
- KUIZENGA M.H.
et al 1943 The effect of cortisone on the growth of young adrenalectomised rats.
Am.J.Physiol. 139;403, 1943.
- LI C.H. 1943 from the J.Biol.Chem. 149;413,1943.
- LONG C.N.H. 1940 The adrenal cortex and carbohydrate metabolism.
Endocrinology 26;309,1940.
- LONG C N H. 1947 Recent studies on the function of the adrenal cortex.
Bull.NEW YORK Acad. Med. 23;260,1947.
- MEANS J.H. 1949 from the Lancet 257;543,1949.
- MENKIN V. 1942 Further studies on effect of adrenal cortex extract on capillary permeability.
ProcSocExperBiolMed. 51;39,1942.
- MIRICK G.S. 1950 The effect of adrenocorticotrophic hormone and cortisone on antibody production in human beings.
J.Clin.Invest. 29;836.
- MOLUMET N. et al 1950 The effect of cortisone on the spleen of mice.
ProcSocExperBiolMed.73;416.
- OPSAHL J.C. 1949 Influence of hormones from the adrenal cortex on the dermal spread of india ink with and without hyaluronodase.
Yale J.Biol et Med. 21;255,1949.

- OPSAHL J.C. 1949 Dermal spread of India ink with and without hyaluronidase as influenced by hormones from the adrenal cortex. Yale J.Biol&Med 21;487,1949.
- PERERA G.A. et al 1949 Clinical and metabolism study of compound E in hypertension, addisons disease, and diabetes mellitus. Am.J.Med. 7;56,.
- PERERA G A. 1951 Cortisone and Blood pressure. ProcSocExperBiolMed,76;585.
- PLOTZ C M. 1950 Action of cortisone on mesenchymal tissues. Arch.Derm & Syph. 61;919.
HOWES E L.
- PRICE W H. et al 1946 Effect of adrenal cortex extract on the hexokinase reaction. Fed.Proc. 5;150.
- RAGAN C. 1949 Effect of cortisone on the production of granulation tissue in the rabbit. ProcSocExperBiolMed. 72,718.
HOWES E L. et al
- RAGAN C. 1950 The effect of ACTH and cortisone on connective tissue. Bull N.Y.Acad Med. 26;251.
HOWES E L. et al
- RIFKINSON N. 1950 Negative results of trials to influence the healing of incised cerebral wounds by ACS serum J.Neuropath.&Exper Neurol. 9;198.
- SAYERS G. 1947 from Endocrinology 40; 265.
SAYERS M.A. 1943 from J.Biol.Chem. 149;425.
1948 from Recent progress in hormone research 2;81.
- SCHAFFENBURG G. 1950 Interrelationships in the genesis of mesenchymal lesions. ProcSocExperBiolMed. 74;358.
et al

- SCHNEEBELI G.L. 1950 Specific alterations in fibroblasts of loose connective tissue following cortisone administration. Anat.Record. 106;244.
- SCHREK R. 1949 Cytotoxic actions of hormones of the adrenal cortex according to the method of unstained cell counts. Endocrinology 45;317.
- SEIFTER J.
BAEDER D H. 1949 Alteration in permeability of some membranes by hyaluronidase and inhibition of this effect by steroids. ProcSocExperBiolMed. 72;136.
- SEIFTER J.
BAEDER D.H. 1949 Influence of hyaluronidase and steroids on permeability of synovial membrane. ProcSocExperBiolMed.72;277.
- SELYE H. 1942 Correlations between the chemical structure and the pharmacological actions of the steroids. Endocrinology 30;437.
- SELYE H. 1949 Further studies concerning the participation of the adrenal cortex in the pathogenesis of arthritis. B.M.J. 2;1129.
- SELYE H. 1950 'STRESS' Acta inc. Publishers. Montreal
- SELYE H. 1936 Syndrome produced by diverse nocuous agents. Nature 138,32.
- SELYE H. 1937 Studies on adaaptation. Endocrinology 21; 169.
- SELYE H. 1944 Role of hypophysis in pathogenesis of diseases of adaptation. CanMedAssJ. 50;426.

- SELYE H. 1946 General adaptation syndrome and diseases of adaptation.
J.Clin.Endocrin. 6;117.
- SHIPLEY R A. 1942 The effect of adrenal cortical compounds in ketosis.
Am.J.Physiol. 135;460.
- SMITH P E. 1933 from ProcSocExpBiolMed.30;1252.
- SPEIRS R S. 1949 The effect of stress, adrenal and adrenocorticotrophic hormones on the circulating eosinophils of mice.
Endocrinology 45;403.
- SPRAGUE R G. 1950 Observations on the physiologic effects of cortisone and ACTH in man.
Arch Int Med. 85;199.
- STOERK H.C. 1950 Adrenal cortical activity in relation to lymphoid tissue and to immune bodies.
Am.J.Path. 26;708.
- STRAUS R. 1946 Effect of anti reticular cytotoxic serum on
HOROWITZ M. healing of experimentally produced fractures in rabbits.
J.Immun. 54;163.
- SUGIURA K et al 1950 The effect of cortisone and other steroids on experimental tumors.
Cancer Res. 10;244.
- TAUBENHAUS M. 1950 The effects of the hypophysis, thyroid, sex steroids and the adrenal cortex upon
AMROMIN G D. granulation tissue.
J.Lab.Clin.Med. 36;7.
- TEPPERMAN J et al 1943 from the Endocrinology 32;373.

- THORN G.W. 1940 Carbohydrate metabolism in Addison's disease.
J.Clin.Invest. 19;813.
- THORN G W. 1949 Metabolic changes in man following adrenal and
FORSHAM P H. pituitary hormone administration.
'Recent progress hormone research' vol 4,229.
- Timiras P S. 1949 On participation of the reticulo-endothelial
Selye H. system in the alarm reaction.
Science 110;560.
- TOPPING N H. 1950 The present status and probable future
development of cortisone ACTH and related
compounds.
J.AMER. PHARM.A. 11;410.
- VOGT M.T. 1944 from Physiol. 103;317.
hormones.
B.M.J. 2;1242.
- VOGT M. 1950 Regulation of secretion of cortical
hormones.
B.M.J. 2;1242.
- WELLS B.B. 1940 The influence of corticosterone and
KENDALL E C. cortisone on somatic growth.
ProcStaffMeetMayoClin. 15;324.
- WELLS B.B. 1941 The influence of the hormones of the
adrenal cortex on ketonuria in rats treated
with phlorizin.
ProcStaffMeetMayoClin. 16;113.
- WERTHEIMER E. 1948 The physiology of adipose tissue.
Physiol Rev. 28;451.
- WHITAKER W.L. 1949 Relationship of the adrenal cortex
to inhibition of growth of hair by
oestrogen.
Am.J.Physiol. 159;118.

- WHITAKER W.L.
BAKER B.L. 1948 Inhibition of hair growth by the
percutaneous application of certain
cortical preparations
Science 108;207.
- WILLIAMS H.L. 1941 Influence of hormones upon
phosphatase content of rat femurs
Endocrinology 29;250.