

THE
ELECTROCARDIOGRAPH

IN
THYROTOXICOSIS.

by
A. L. McAdam

[Handwritten notes]

ProQuest Number: 13849778

All rights reserved

INFORMATION TO ALL USERS

The quality of this reproduction is dependent upon the quality of the copy submitted.

In the unlikely event that the author did not send a complete manuscript and there are missing pages, these will be noted. Also, if material had to be removed, a note will indicate the deletion.



ProQuest 13849778

Published by ProQuest LLC (2019). Copyright of the Dissertation is held by the Author.

All rights reserved.

This work is protected against unauthorized copying under Title 17, United States Code
Microform Edition © ProQuest LLC.

ProQuest LLC.
789 East Eisenhower Parkway
P.O. Box 1346
Ann Arbor, MI 48106 – 1346

THE ELECTROCARDIOGRAPH IN THYROTOXICOSIS.

That the extent and severity of the involvement of the cardio-vascular system by thyrotoxicosis is the most important feature of the disease has long been recognised. Factors which are known to affect greatly the seriousness of the cardio-vascular manifestations are chiefly, (a) the age of the patient, (b) the type of hyperthyroidism, (c) the intensity and duration of the toxæmia and (d) the pre-existing state of the heart.

There are, however, many aspects of the circulatory disturbances resulting upon thyrotoxicosis which have been, and still are, the subject of much controversy. Vastly different reasons have been expounded to account for the heart affection, although to-day the toxæmic theory is the generally accepted one. But agreement is not yet reached upon the features of the blood-pressure in thyrotoxicosis, nor upon the specific lesions (if any) produced in the myocardium, nor upon the electrocardiographic changes which result upon the toxæmia.

It is with the features of the electrocardiogram in toxic goitre that this thesis is especially concerned. The characteristics of the electrocardiogram before and after operative treatment will be noted, and discussed in the light of the findings of others. The significance of any electrocardiographic changes will be considered,

and an attempt made to draw clinical conclusions therefrom.
HISTORICAL SURVEY.

Parry (1) in 1786 was the first to describe accurately the features of toxic goitre, and Flajani (2) in 1802 recorded heart disturbances in a disease characterised by a tumour in the anterior part of the neck.

Graves (3) gave an excellent description of exophthalmic goitre in 1836, and his name is used in this country and in America to denote the primary type of hyperthyroidism. In continental countries the exophthalmic variety of toxic goitre is named after Von Basedow who described its features in 1840. Sir Henry Marsh (4) in 1841 described two cases with enlargement of the thyroid, exophthalmos, and heart disease. Irregularity of the heart was noted in the first case, with dilatation of the cavities.

MacDonnel (5) also described two cases of "a peculiar form of disease of the heart, attended with enlargement of the thyroid gland and eyeballs".

The risk of cardiac lesion in hyperthyroidism did not escape any of the original writers upon the disease. Prominence to heart symptoms was given in the original papers by Parry, Flajani, Adelman (6), Von Basedow (7) and Graves. Charcot (8), writing in the latter part of the nineteenth century, pointed out that heart affections frequently appeared in patients in whom one or more of the

signs of the disease were lacking, and he named the condition "formes frustes" of Basedow's disease.

A number of theories have been advanced by different writers to explain the mechanism of production of the heart symptoms. Rose (9) in 1877 was the first to expound the mechanical theory. He maintained that tracheal stenosis, due to the enlarged thyroid, changed the pressure relations in the thorax, so that there was an over-filling of the right heart during inspiration which later led to secondary hypertrophy and dilatation. Kocher (10) believed that "goitre heart" was due to congestion of the great veins of the neck by continued pressure of the thyroid gland.

Wolfler (11) thought that the enlarged thyroid hindered expiration, and began the first stage of cardiac damage by overloading the right side of the heart.

Boas (12) advanced the view that increased metabolism caused the heart to work more, and thus gradually wore it out.

The toxic theory was first put forth by Kraus (13) in 1899. He began the lengthy dispute as to whether the thyroid excess was qualitative or quantitative. The toxæmic theory was supported by Bircher (14), who held that the toxin arose through degeneration of the thyroid itself, whereas Kraus' view was that a quantitatively changed secretion explained the source of the toxæmia.

Most writers now adhere to the toxæmic theory, and Dameshek (15) says "it is a toxæmia of some sort, probably

closely related to an abnormal secretion, quantitative or qualitative, of the thyroid gland".

The status of exophthalmic goitre in his day, was given by Murray (16) in the Bradshaw lecture of 1905. It is interesting to note the revolutionary change which has occurred in our views upon operative treatment of toxic goitre since Murray's address. He said "The risks of surgical treatment are unfortunately so great that I do not consider partial thyroidectomy is advisable in exophthalmic goitre. I have only seen this operation performed in two cases, but both died within an hour or so. If operative treatment is undertaken, a local anaesthetic only should be employed, as much of the risk appears to be due to the use of general anaesthesia".

BLOOD PRESSURE.

The features of the blood-pressure in thyrotoxicosis have been the subject of many varying observations.

Goodall (17) expressed the following views upon this matter:-

- (a) the systolic B.P. in the ordinary typical case is low, about 10-2% below the physiological E.P. of the individual.
- (b) the diastolic B.P. is about normal.
- (c) pulse pressure is low.

He further stated that the blood-pressure in Graves' disease passes through three stages - (1) a stage of primary hypertension, (2) a stage of hypotension, (3) a

stage of secondary hypertension.

Kraus, Plummer (18) Krumbhaar (19) White and Aub (20) and others maintain that the systolic pressure is usually high, and that there is, in most cases, a high pulse pressure. Barr (21) states that the systolic pressure is usually fairly high, and the diastolic pressure lower than normal. This disparity in pressure causes longitudinal straining of the large arteries, and marked recoil of the heart, and it is this recoil which causes the thumping of the heart against the chest in hyperthyroidism.

Essential hypertension has been thought to be a sequela of thyrotoxicosis. Bach and Bourne (22) and Fishberg (41) believed that essential hypertension is more common in middle-aged persons who suffer or have suffered from toxic goitre ~~more~~ than in the rest of the population, but that this is more probably due to a constitutional proneness to hypertension than directly to thyrotoxicosis.

Thyrotoxic hypertension was described by Parkinson and Hoyle (42) as rare under 40, usually present in women between 45 and 65, two-thirds of whom have had a goitre for some years, though it may be small and overlooked, with tachycardia, nervousness, a systolic pressure of 170 - 240, and a low diastolic pressure. They considered that chronic thyrotoxicosis may be one of the

causes of hypertension, and that thyroidectomy may bring about a fall in the blood pressure in some cases.

MORBID CHANGES IN THE HEART.

Whether thyroid toxæmia can alone initiate gross myocardial changes has also provoked a great deal of controversy, and divergent views have been expressed. Each and Bourne (22) consider that thyrotoxicosis does not produce permanent changes in the normal heart, but may produce an additional myocardial change in hearts affected by some other cause of myocarditis or predisposed to arteriosclerosis.

Read's (23) view is that hyperthyroidism will only cause permanent organic cardiac damage if some other deleterious process, such as age, arteriosclerosis, and rheumatism is also at work. A similar view is expressed by Andrus (24).

Menne et al (25), however, claim that a heart exposed to hyperthyroidism, will exhaust its nutrition. Such exhaustion can be seen in the heart muscle in the form of parenchymatous and fatty degeneration, histiocyte invasion, fraying of the muscle bundles, and early fibrosis. Two cases of hyperthyroidism in both of which auricular fibrillation had been present before death, were studied by Goodpasture (26). In each case the cause of death was myocardial exhaustion. Acute necrosis of the myocardium was found in both hearts, in one so extensive as to involve a large part of the left ventricular muscle.

In estimating the degree of cardiac damage which results upon thyrotoxicosis, the electrocardiogram is of great value. Don and Langley (27) described three types of cardiac damage as revealed electrocardiographically:-

- (a) toxic, transient and recoverable;
- (b) toxic and stationary;
- (c) toxic and incurably progressive.

If the toxaemia is severe, or of low-grade virulence over a long period, the myocardium suffers a certain amount of injury which varies greatly in different subjects according to the degree of integrity of their cardiac neuro-muscular mechanism. Brenner (28) has pointed out that the higher incidence of failure in middle-aged and elderly patients is due to the associated degenerative cardio-vascular changes, particularly coronary sclerosis and hypertension.

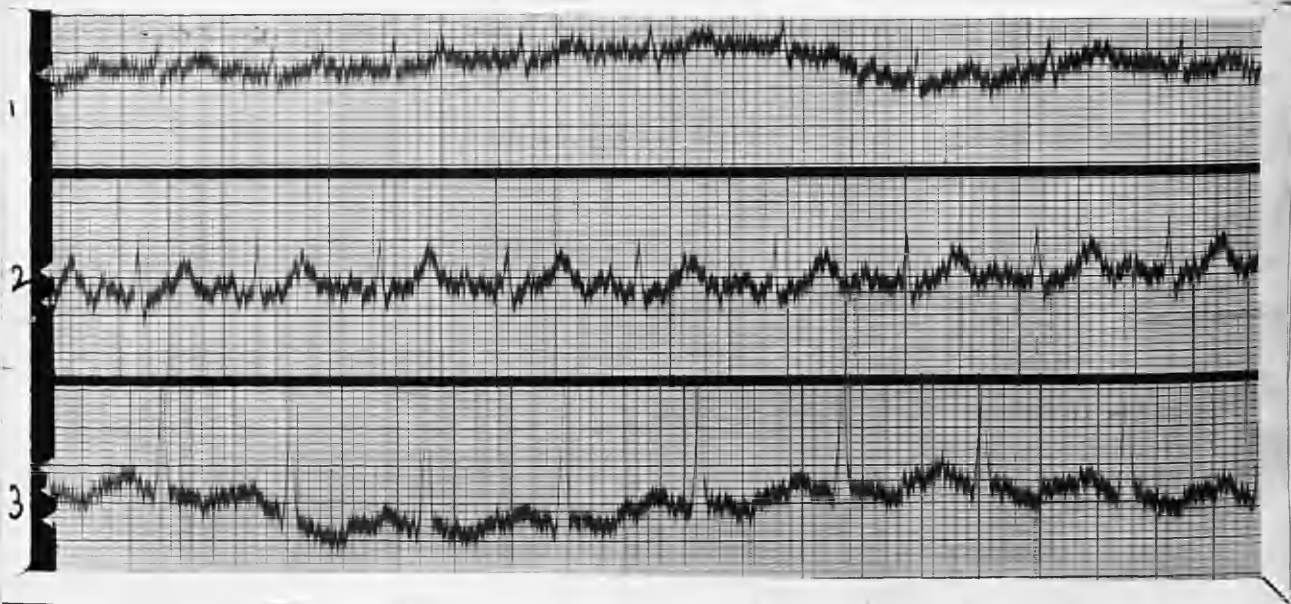
So widely divergent have been the views expressed upon the question whether there occur in thyrotoxicosis any electrocardiographic changes which may be said to be characteristic of the disease that there is justification for any investigation which may help to throw some light upon the problem.

The case-records which follow are of patients examined both before and following operation in the out-patient department of the Blackburn and East Lancashire Royal Infirmary during the past five years. The patients were

all of the working class type. Most of the women patients were employed in cotton weaving or cotton spinning mills, or were the wives of cotton operatives. Three were shop assistants, and one was a nurse. Of the two male patients one was a coal-miner, and the other one an errand boy. All were able to enjoy the period of rest so essential after operation for toxic goitre and a minimum of three months, - in some cases considerably longer - was insisted upon before they were permitted to resume work.

CASE 1. NURSE B. Single. aged 36 years.

Fifteen months' history of toxic goitre. She showed fine tremor of the hands, moistness of the skin, a slight uniform enlargement of the thyroid, and some loss of weight. (7 to 10 lbs.) Pulse rate (resting) was 140. B.P. 205/90, and B.M.R. +96 per cent. She had a past history of "lung trouble" with haemoptysis at 22, and radiological examination revealed many dense small shadows in the upper lobe of the left lung, indicative of healed T.B. lesions. Both apices appeared hazy - probably due to pleural thickening and retraction. Sputum and urine were negative. The blood sedimentation-rate was not increased. Partial thyroidectomy was carried out on 20th February 1936.



E.C.G. 10/2/1936. (PRE-OPERATIVE).

Rate: 134

Rhythm: Regular sinus rhythm.

P Waves: Upright in all Leads.

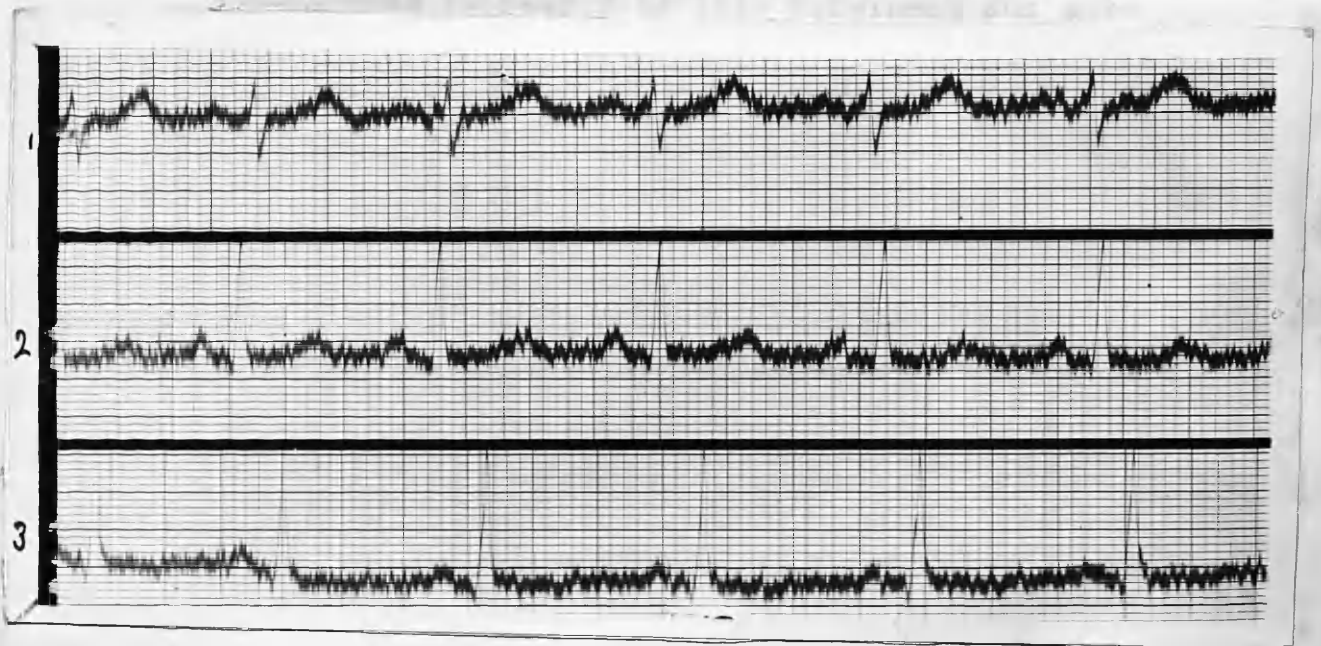
PR Interval: .12 seconds.

Axis Deviation: Normal.

QRS Complexes: No notching or slurring. Voltage low in Lead 1.

T Waves: In Lead 2, T wave is very prominent and sharply pointed, and in Lead 3, T wave is inverted.

Summary: Sinus tachycardia, with normal axis deviation and no conduction defects. T wave very prominent and pointed in Lead 2.



E.C.G. 7/4/1936. (POST-OPERATIVE).

Rate: 94.

Rhythm: Regular sinus rhythm.

P Waves: Upright in all Leads.

PR Interval: .14 seconds.

Axis Deviation: Tendency to right axis deviation.

QRS Complexes: S Lead 1 is much deeper than before operation. QRS in Lead 2 is of higher voltage.

T Waves: T wave in Lead 2 is less prominent and more blunted. There is diminished inversion of the T wave in Lead 3.

Summary: The cardiac rate is much slower than in the pre-operative E.C.G.

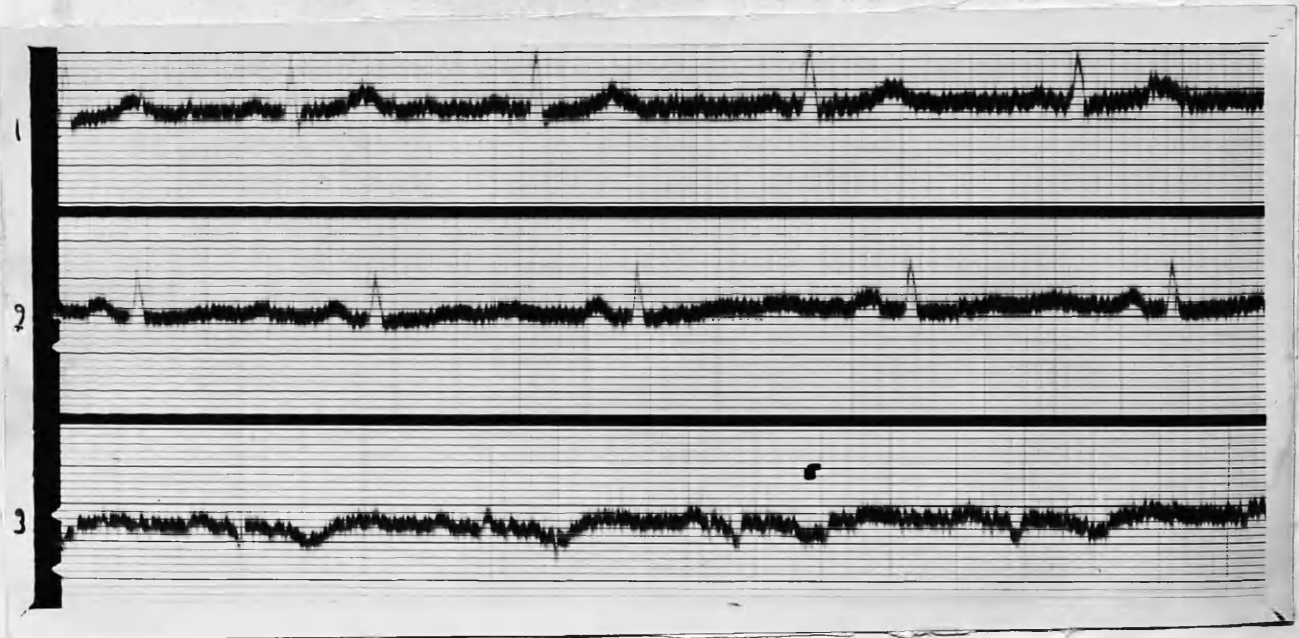
The tendency to right axis deviation now noticeable indicates that the anatomic axis has shifted towards the right.

The T wave in Lead 2 is less prominent and more blunted, and there is less inversion of T in Lead 3.

CASE 2. Miss B. H. : aged 38 years.

History. Thyroid gland became enlarged at 15 but there were no thyrotoxic symptoms till early in 1934. when she began to suffer from palpitation, nervousness, and excessive perspiration. She has lost a little weight. There is no exophthalmos. The thyroid shows a slight diffuse swelling affecting both lobes, with no palpable nodules.

P.R. 108: BMR. + 42 per cent. ; partial thyroidectomy was performed on 29/7/1935. *M. (?)*



E.C.G. 6/6/1935. (PRE-OPERATIVE).

Rate: 75.

Rhythm: Regular sinus mechanism.

P Waves: Upright in all Leads.

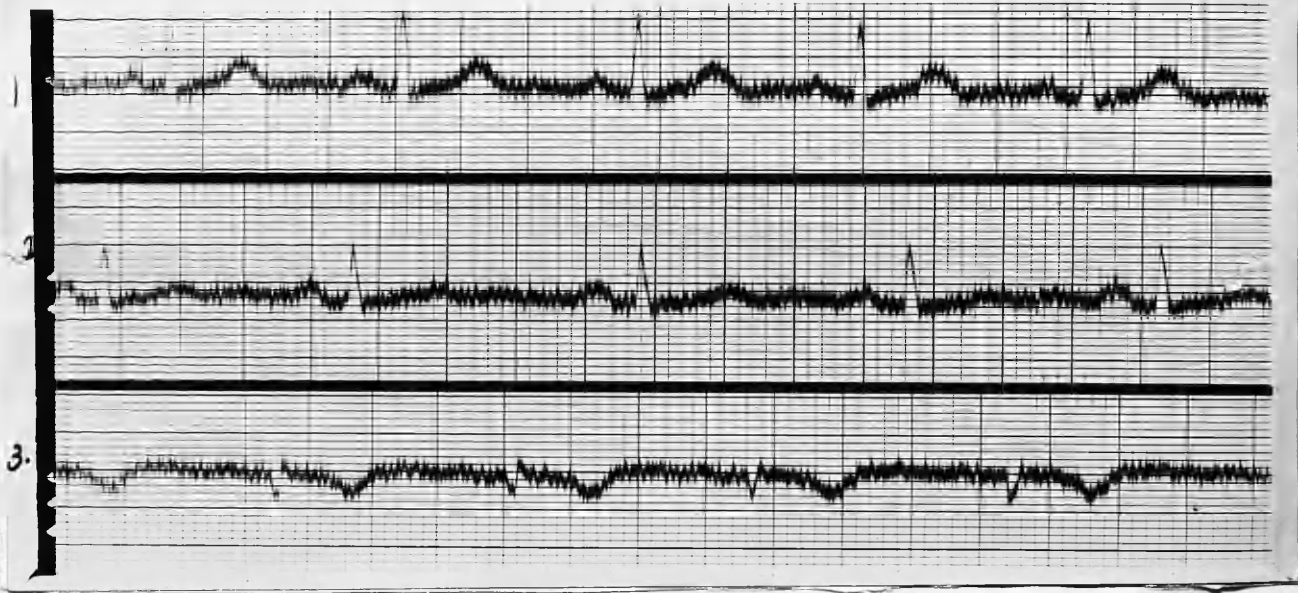
PR Interval: .12 seconds.

Axis deviation: Mild left axis deviation.

QRS Complexes: Normal in Leads 1 and 2. In Lead 3 they are directed downwards and are slightly notched.

T Waves: Upright in Lead 1; flattened in Lead 2;
Inverted in Lead 3.

Summary: Rate and Rhythm are normal. There is a
slight left axis deviation. The
inversion of T in Lead 3 is probably of
no significance, nor is the slight
notching of the QRS in the same Lead.



E.C.G. 10/10/1935. (POST-OPERATIVE).

Rate: 90.

Rhythm: Regular rhythm of sinus origin.

P Waves: Upright in Leads 1 and 2; unidentifiable
in Lead 3.

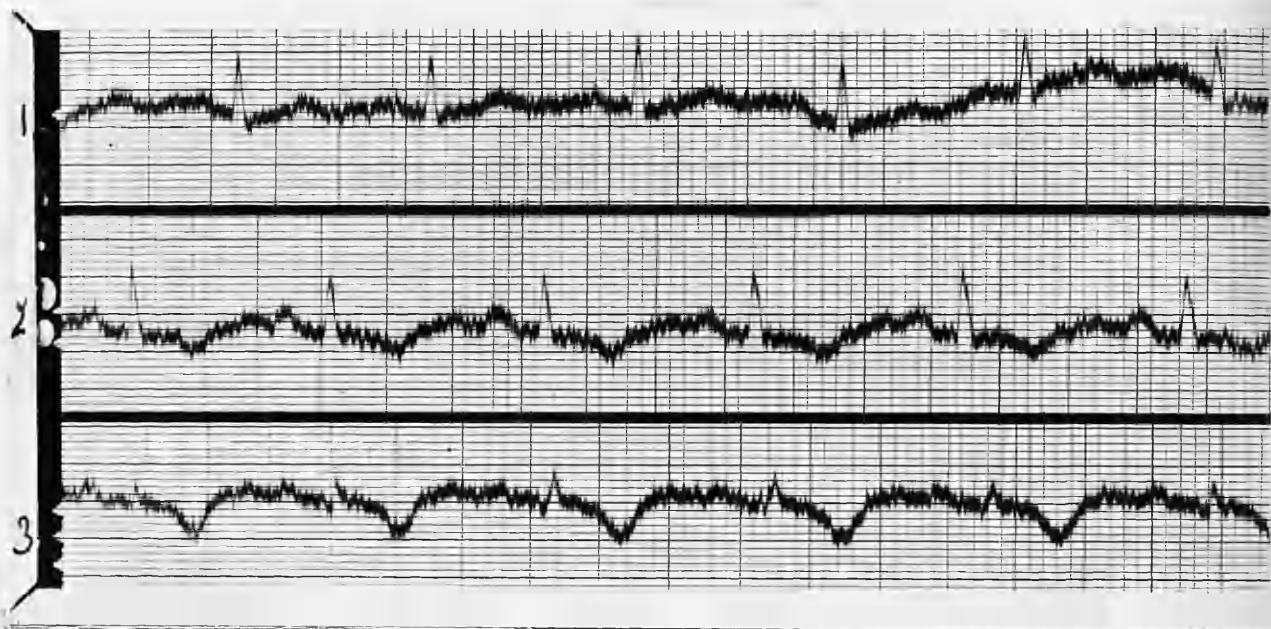
PR Interval: .13 seconds.

Axis deviation: Mild left axis deviation.

QRS Complexes: Normal in Leads 1 and 2; downward
and slightly notched in Lead 3.

T Waves: Directed upwards in Leads 1 and 2;
inverted in Lead 3.

Summary: The Rate is rather faster than in the previous E.C.G. but is not exceptionable. T wave in Lead 2 is now a blunt summit. and T wave in Lead 1 is rather more prominent.



E.C.G. 16/6/36. (POST-OPERATIVE)

Rate: 100.

Rhythm: Regular sinus rhythm.

P waves: Upright in all Leads.

PR Interval: .14 seconds.

Axis deviation: Normal.

QRS Complexes: Normal in all Leads.

T. Waves: T is a blunt summit in Lead 1; inverted in Lead 2, and markedly inverted in Lead 3.

Summary: The Rate is rather faster, but the axis deviation has now reverted to normal. There is no conduction defect, but the lowering of T in Lead 1, and the inversion of T in Lead 2, and the increased inversion of T in

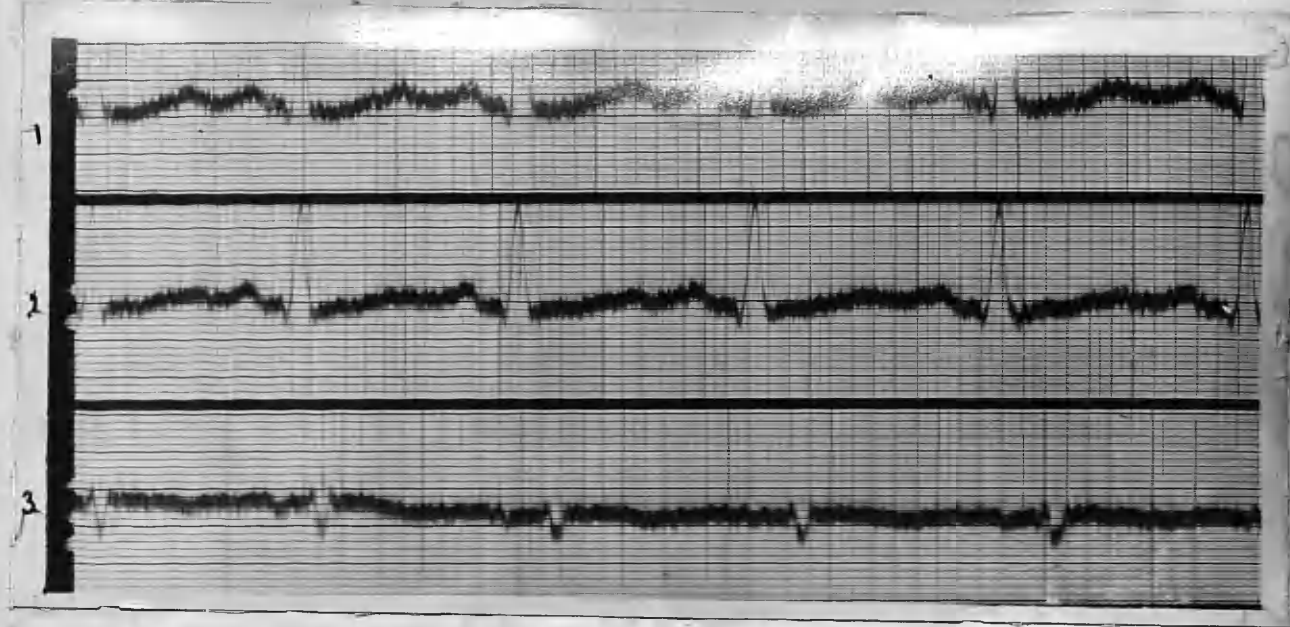
in Lead 3 indicate myocardial damage. B.M.R. remained + 25 per cent., and the patient still complained of perspiration and palpitation. The indications, both clinical and electro-cardiographic, were that insufficient thyroid tissue had been removed. The patient declined further operation.

CASE 3. Miss J. T. : aged 42 years.

She gave a history of hyperthyroid symptoms for two years prior to first observation in June, 1935. A curious symptom which she noticed at the beginning of her illness was a "neuralgia" in the gums of the upper jaw. Dental extractions did not afford much relief.

There was no palpable thyroid enlargement, and no obvious cardiac lesion. There was a fine tremor of the hands, but the main presenting symptom was persistent, troublesome tachycardia. None of the other usual evidences of thyrotoxicosis were present (apart from a raised B.M.R. of 43 per cent.) and a diagnosis was made of "masked" hyperthyroidism.

Sub-total thyroidectomy was performed on 18/11/1935 following four months' X-ray therapy which had effected no improvement in her condition.



E.C.G. 13/6/1935. (PRE-OPERATIVE).

Rate: 130.

Rhythm: Sinus arrhythmia.

P waves: Upright in Leads 1 and 2; isoelectric in Lead 3

PR Interval: .12 seconds. 1 and 2; isoelectric in Lead 3.

Axis Deviation: Mild left axis deviation.

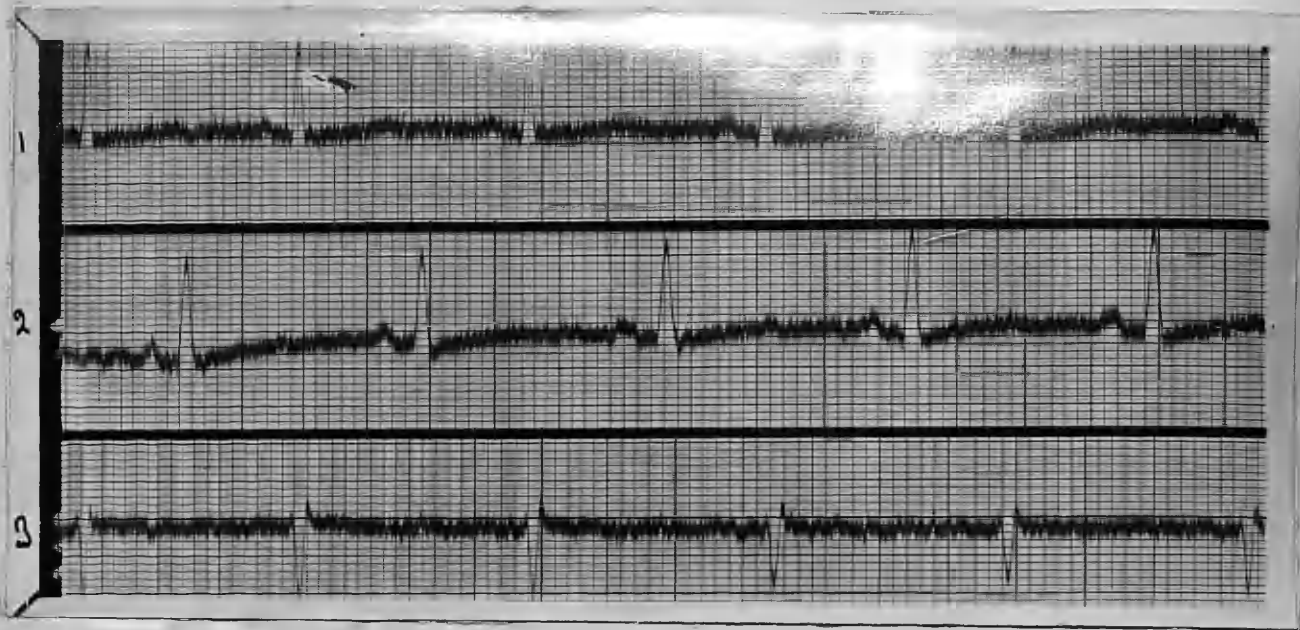
QRS Complexes: Slightly notched in Lead 3, but otherwise normal.

T waves: Upright in Leads 1 and 2; slightly inverted in Lead 3.

Summary: Mild sinus arrhythmia, and mild left axis deviation.

is now much slower, and the sinus arrhythmia less marked. There is a more pronounced deviation of the electrical axis to the left.

The T waves are less prominent in Leads 1 and 2 than in the pre-operative E.C.G.



E.C.G. 12/2/36. (POST-OPERATIVE).

Rate: 85.

Rhythm: Very mild sinus arrhythmia.

P waves: Upright in Leads 1 and 2; isoelectric in Lead 3.

PR Interval: 12 seconds.

Axis deviation: Marked left axis deviation.

QRD Complexes: Directed upwards in Leads 1 and 2, and downward in Lead 3.

T waves: Flattened in all Leads.

Summary: The rate is now much slower, and the sinus arrhythmia less marked. There is a more pronounced deviation of the electrical axis to the left.

The T waves are less prominent in Leads 1 and 2 than in the pre-operative E.C.G.

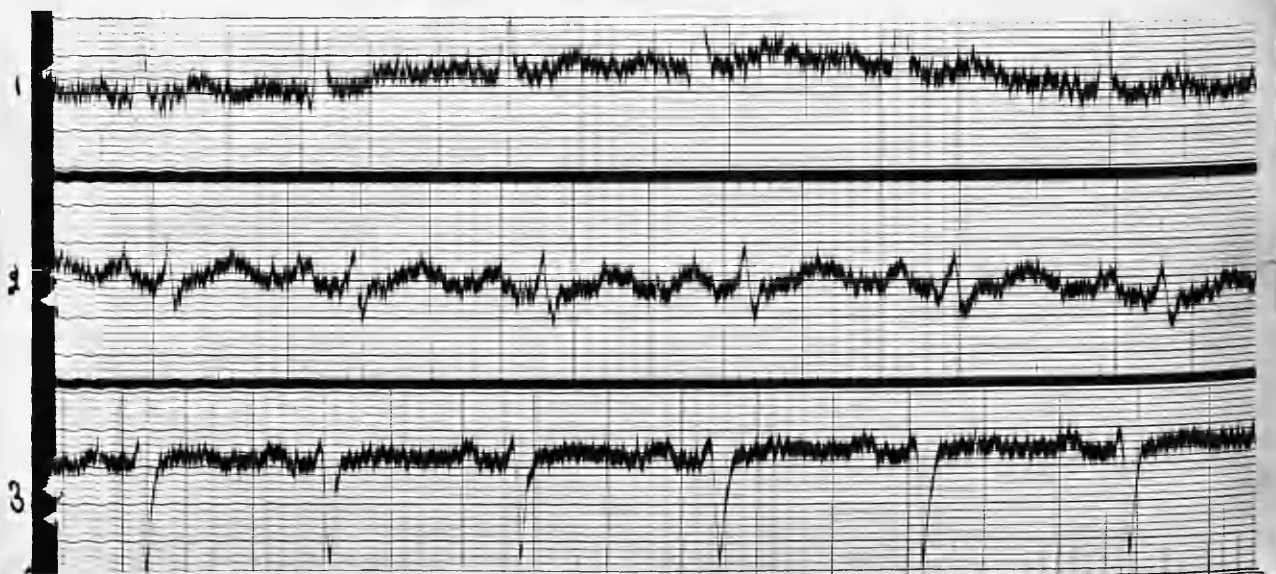
CASE 4. Mrs. M. L. : aged 49 years.

Early in 1933 she began to lose weight and strength, and she noticed that her eyes were becoming prominent. Her neck became enlarged and she was nervous and excitable.

When first seen in February, 1934, she had marked evidences of thyrotoxicosis, and was emaciated. The thyroid was considerably enlarged, both lobes being equally involved. P.R. 120; B.M.R. +52 per cent. *BP*

In adolescence, she had Rheumatic Fever and endocarditis and she now has a well-marked presystolic thrill and murmur in the apex area. The apex beat is in the nipple line in the fifth space. The first sound at the apex possesses a slapping character.

Partial thyroidectomy and ligature of the Jugular Veins was carried out on March 28th, 1935. (Operation was delayed in order that a complete prolapsus uteri could be surgically attended to in the interim).



E.C.G. 3/1/1935. (PRE-OPERATIVE)

Rate: 115.

Rhythm: Mild sinus arrhythmia.

P waves: Upright in all Leads.

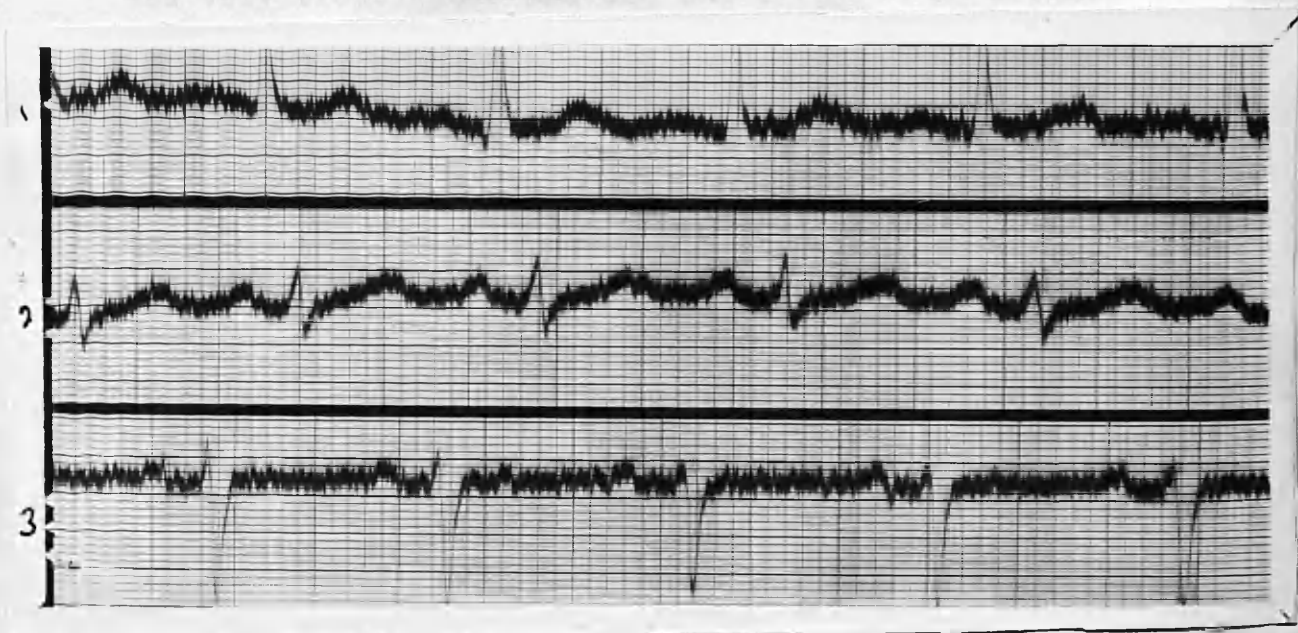
Axis deviation: Marked left axis deviation.

QRS Complexes: Rather broadened and notched in Lead 2.

T waves: Upright in Leads 1 and 2. flattened in Lead 3

Summary: Mitral Stenosis is usually associated with right axis deviation. but E.C.G. here shows marked deviation of the axis to the left.

The broadening and notching of the QRS in Lead 2 indicate mild conduction defect in the ventricular phase of the excitation wave. i.e., damage to the Bundle of His or its main branches.



E.C.G. 16/7/1935. (POST-OPERATIVE).

Rate: 108

Rhythm: Mild sinus arrhythmia.

P Waves: Upright in all Leads.

PR Interval: .12 seconds.

Axis deviation: Marked left axis deviation.

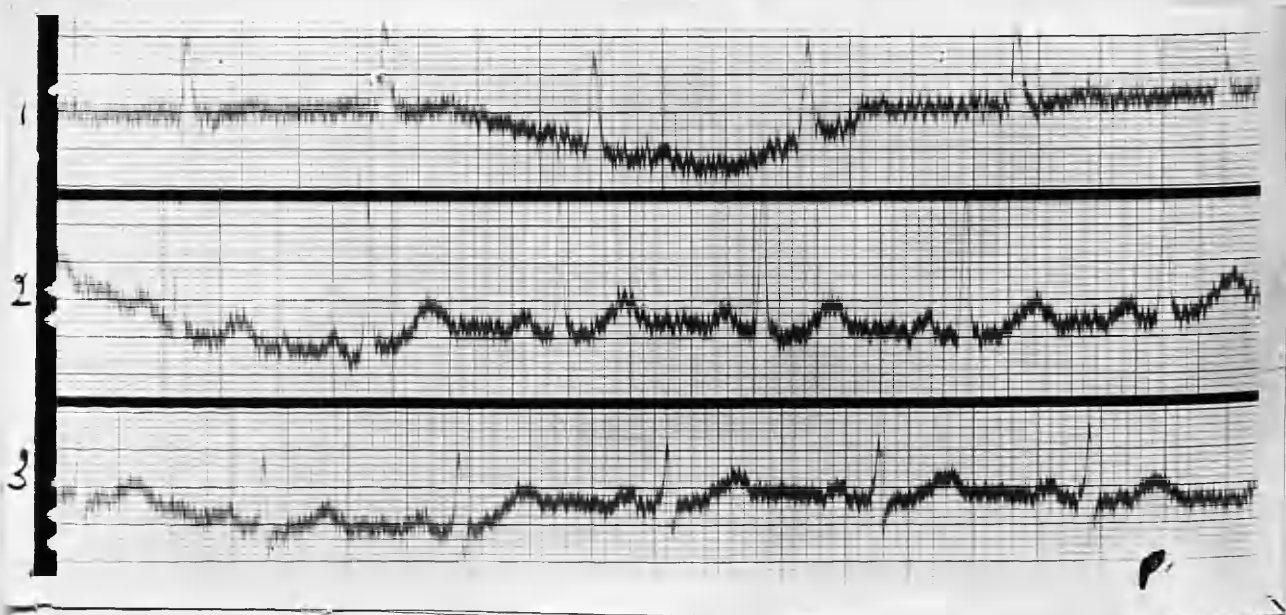
QRS Complexes: Slightly less broadened in Lead 2.

T waves: Upright in Leads 1 and 2; flattened in Lead 3.

Summary: The E.C.G. Changes are very slight compared with the pre-operative tracing.

CASE 5. Miss H. M. : aged 55 years.

History of simple goitre for 21 years. About two years ago the goitre became toxic, and she began to lose weight. She became nervous and easily tired; palpitation was very troublesome and she had dyspnoea on slight exertion. There were no urinary symptoms. The thyroid was moderately enlarged, and nodules were palpable in the isthmus and left lobe. P.R. 100; B.P. 152/78; B.M.R. +41.5 per cent. Partial thyroidectomy was performed on 21/11/1935.



E.C.G. 19/11/1935. (PRE-OPERATIVE).

Rate: 88.

Rhythm: Mild sinus arrhythmia.

P waves: Unidentifiable in Lead 1, but prominent in Lead 2.

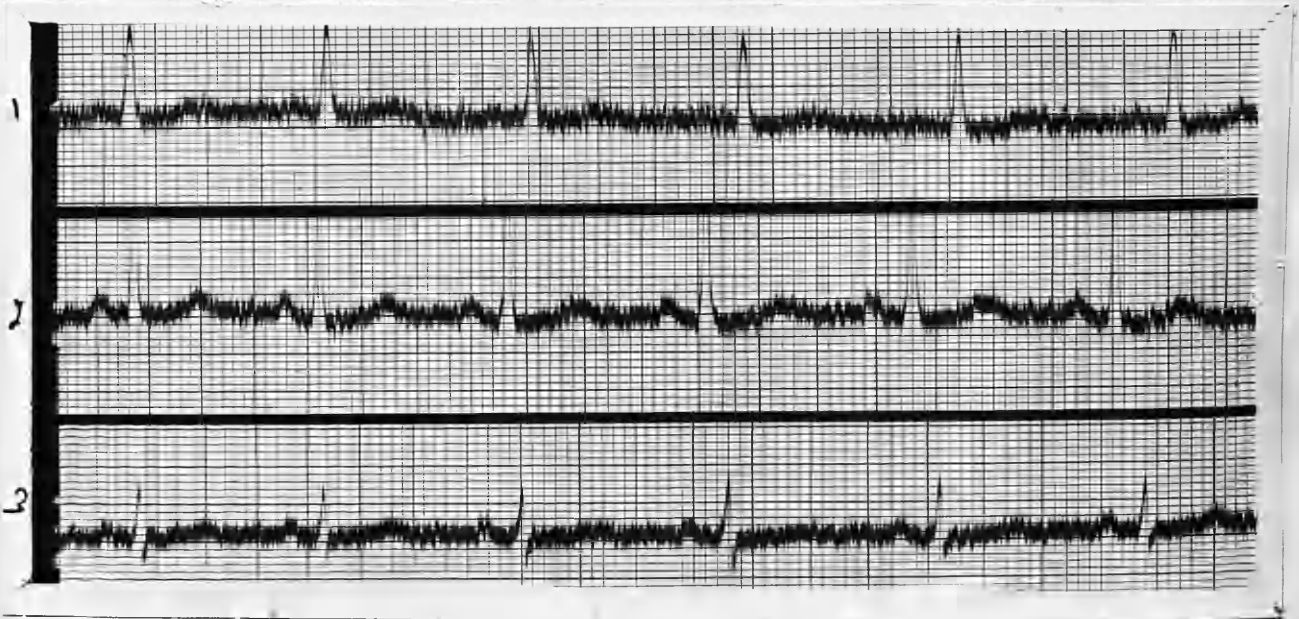
PR Interval: .16 seconds.

Axis deviation: Normal.

QRS Complexes: Upright in all Leads. Slight notching of the downward stroke in Lead 1.

T waves: Upright in all Leads; sharply pointed and prominent in Lead 2.

Summary: The E.C.G. may be considered physiological. When the tracing was taken, the patient had been for some days on digitalis and Lugol's iodine.



E.C.G. 29/2/1936. (POST-OPERATIVE).

Rate: 82.

Rhythm: Regular sinus rhythm.

P waves: Flattened in Lead 1; upright in Leads 2 and 3.

PR Interval: .16 seconds.

Axis deviation: Normal.

QRS Complexes: Normal and upright in all Leads.

T waves: Upright in all Leads.

Summary: The rate is slightly slower. The slight notching of the downward stroke in the QRS of Lead 1 has disappeared. The T waves are not so prominent in Leads 2 and 3 as in the pre-operative E.C.G.

CASE 6. Mr. T. G. : aged 38 years.

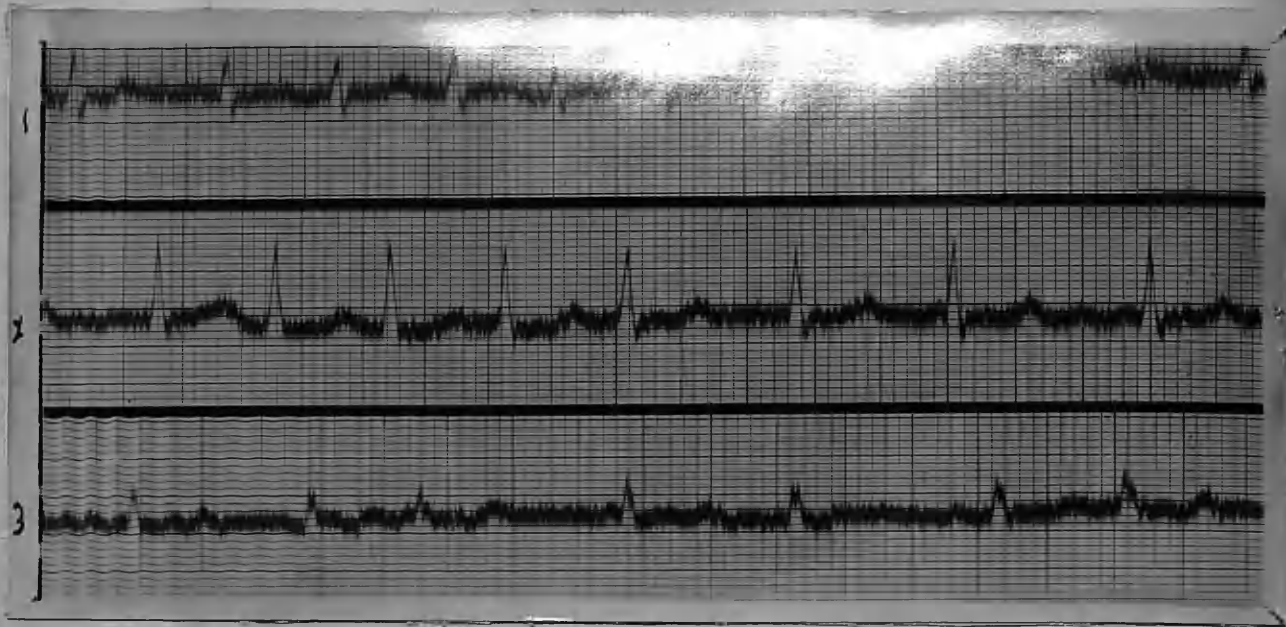
A healthy man till 18 months prior to first examination in September, 1935. During that period he has lost about 14 lbs. in weight, and has been troubled with palpitation, excessive perspiration and nervousness. Recently he has had slight difficulty in swallowing and occasional hoarseness. Examination (September, 1935), revealed a moderate bi-lateral enlargement of the thyroid and slight exophthalmos. There was a fine tremor noticeable in his hands.

The cardiac apex beat was rather diffuse, in the fifth space, about $\frac{1}{2}$ " - 1" within the nipple line.

Auricular fibrillation was present.

P.R. 88? B.P. 180/85. B.M.R. +66 per cent.

Partial thyroidectomy was performed on 12/2/1936.



E.C.G. 26/9/1935. (PRE-OPERATIVE)

Rate: 150.

Rhythm: Auricular fibrillation.

P waves: Represented by "f" oscillations.

PR Interval: Not identifiable.

Axis deviation: Normal.

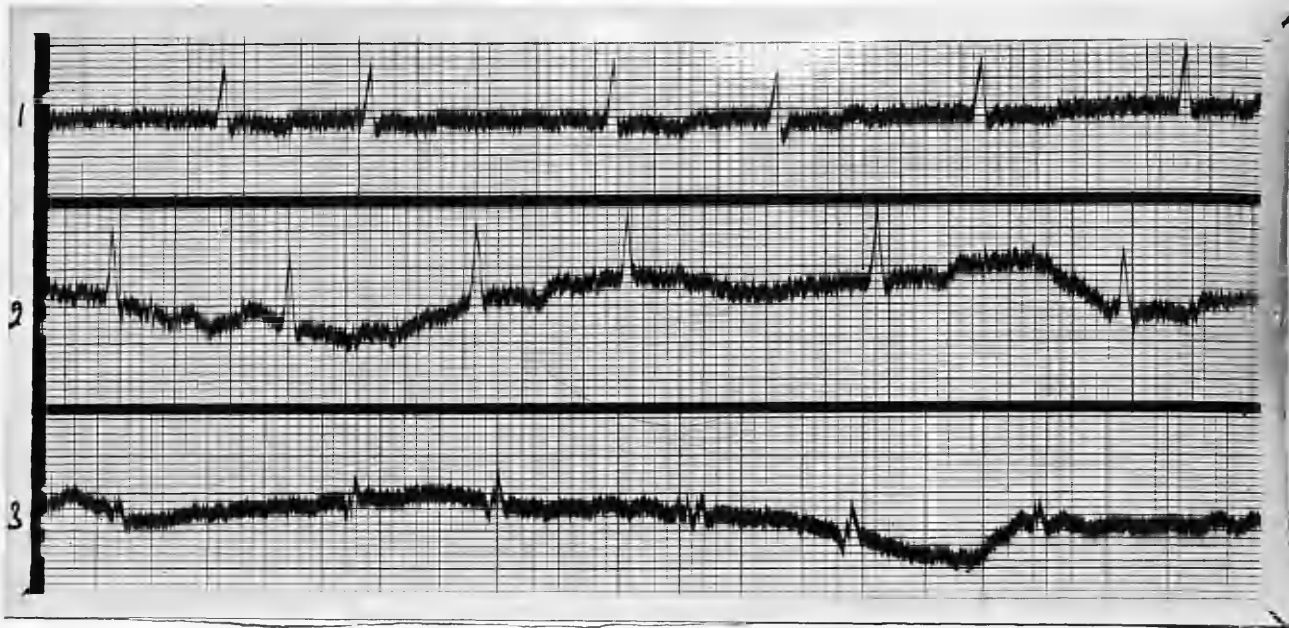
QRS Complexes: Notching present in the QRS complexes of Lead 3.

T waves: Upright in all Leads.

Summary: A rapidly acting heart, with well marked auricular fibrillation.

Notes: The rate is considerably slower than in the previous E.C.G. but auricular fibrillation still persists.

The T waves are now inverted in Leads 1 and 2.



E.C.G. 24/2/1936. (12 DAYS POST-OPERATIVE)

Rate: 100

Rhythm: Auricular fibrillation.

P waves: Represented by "f" oscillations.

PR Interval: Unidentifiable.

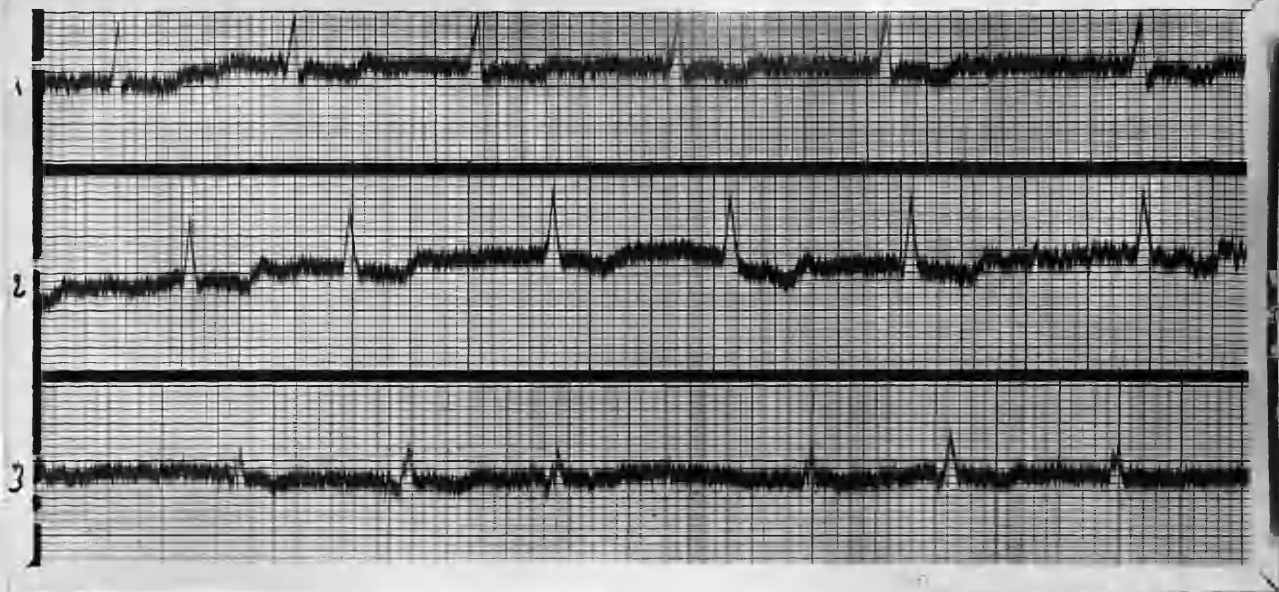
Axis deviation: Normal.

QRS Complexes: Definite notching of the upstroke in Lead 3.

T Waves: Inverted in Leads 1 and 2; Flattened to isoelectric line in Lead 3.

Summary: The rate is considerably slower than in the previous E.C.G. but auricular fibrillation still persists.

The T waves are now inverted in Leads 1 and 2.



E.C.G. 9/4/1936. (56 DAYS POST-OPERATIVE)

Rate: 112.

Rhythm: Auricular fibrillation.

P Waves: Represented by "f" oscillations.

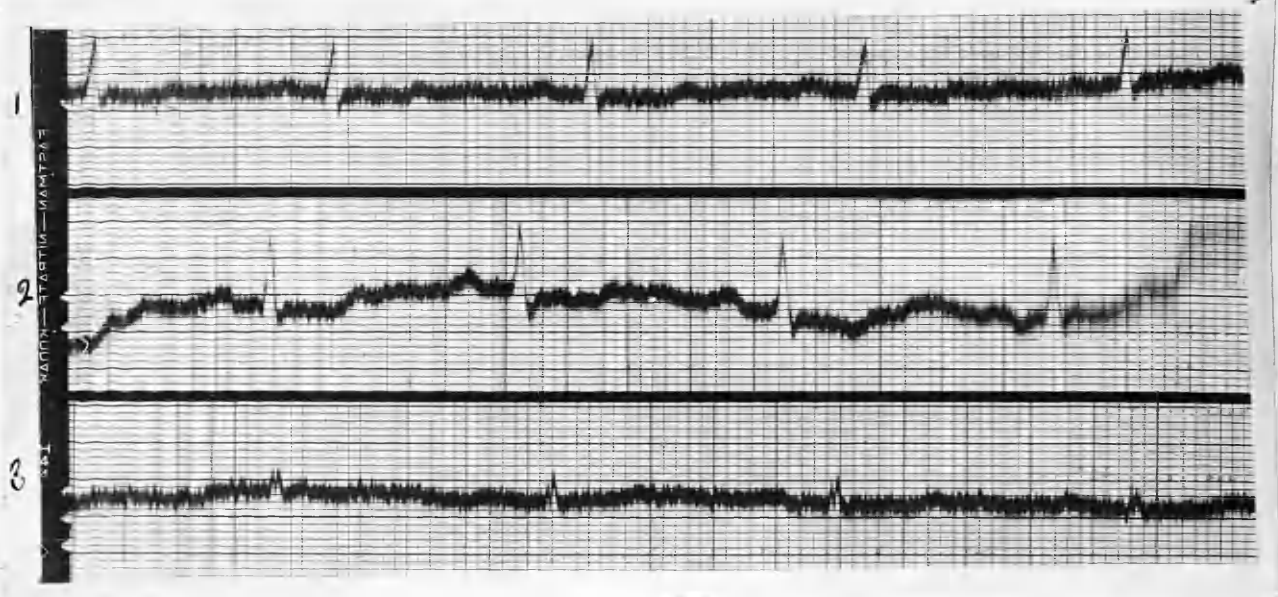
PR Interval: Unidentifiable.

Axis deviation: Normal.

QRS Complexes: Notching still present in upstroke
of R in Lead 3.

T Waves: Inverted in all Leads.

Summary: Auricular fibrillation still persisted, although the patient felt better, had gained weight, and B.M.R. was down to + 20 per cent. The RT segment depression was due to the administration of large doses of digitalis.



E.C.G. 23/4/1936. (70 DAYS POST-OPERATIVE).

In the 14 days since the last E.C.G., the patient has had Quinidine therapy - Tab. Quinidine gr. 5 t.d.s. for three days.

Rate: 86.

Rhythm: Normal sinus rhythm.

P Waves: Upright in all Leads.

PR Interval: .16 seconds.

Axis deviation: Normal.

QRS Complexes: Notching still present in R upstroke of Lead 3.

T waves: Upright in Leads 1 and 3; biphasic in Lead 2.

Summary: The rate is much slower, and the normal rhythm has been regained. Cessation of Digitalis therapy has restored the T waves to a summitt in Leads 1 and 3, and nearer to the isoelectric line in Lead 2.

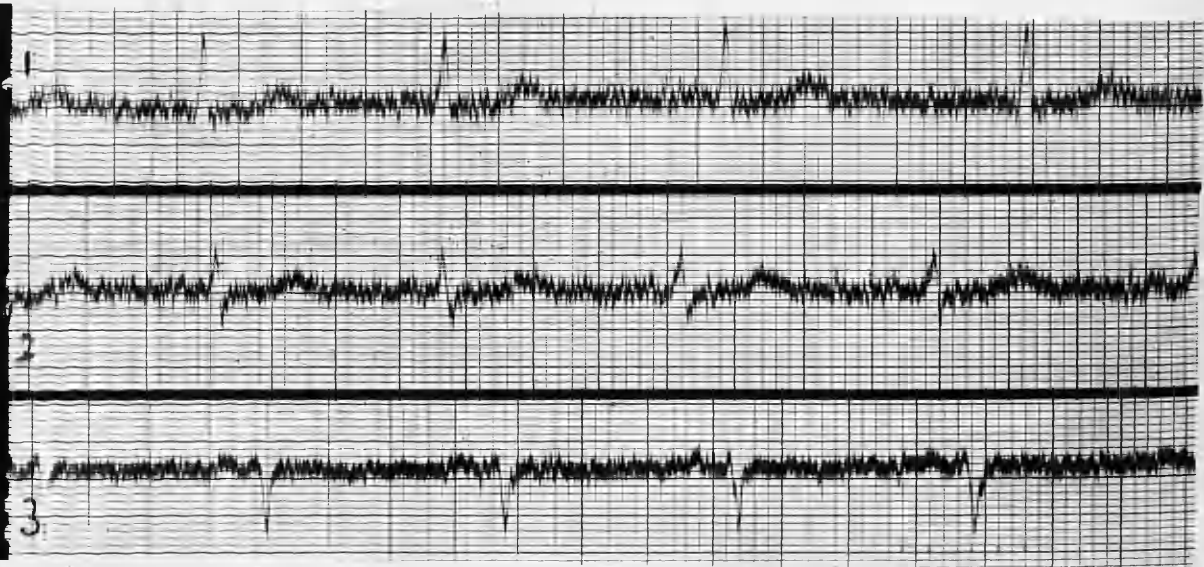
The E.C.G. may now be considered fairly normal; the patient felt quite well, and was able to resume his occupation as a coal miner.

CASE 7. Miss P. M. : aged 26 years.

In July, 1934, she had acute tonsillitis, and shortly afterwards she noticed that her neck was somewhat enlarged. Tremor, nervousness, and tachycardia developed, and she began to lose weight.

She had definite signs of hyperthyroidism when she first came for examination in September, 1935. The cardiac apex beat was four inches from the mid-sternum in the fifth space. The right border was at the right sternal margin, and the upper border was at the upper border of the third rib. Sinus arrhythmia was present.

The patient underwent partial thyroidectomy on 2/12/1935.



E.C.G. 29/9/35. (PRE-OPERATIVE)

Rate: 84.

Rhythm: Regular sinus rhythm.

P waves: Difficult to identify in Leads 1 and 2 on account of somatic tremor; upright in Lead 3.

PR Interval: .10 seconds. (2)

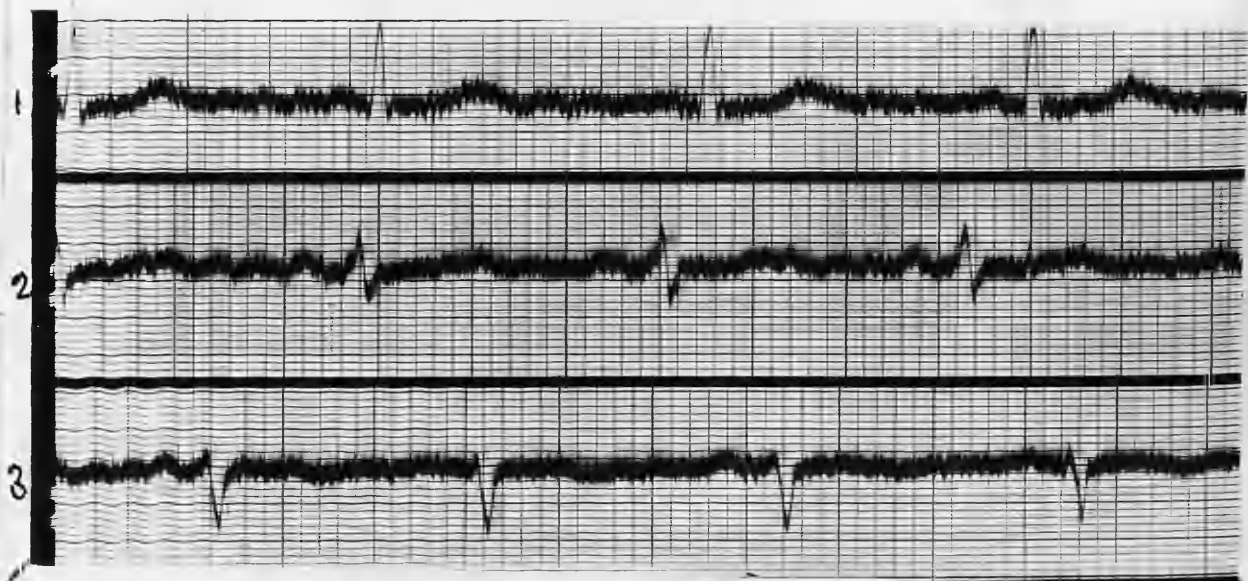
Axis deviation: Marked left axis deviation.

QRS Complexes: Upright in Leads 1 and 2; downward in Lead 3. Some notching of the upstroke in Lead 2.

T waves: Prominent and upright in Leads 1 and 2; Diphasic in Lead 3.

Summary: Moderate tachycardia and sinus arrhythmia. Well-marked deviation of the electrical axis to the left.

No conduction defects.



E.C.G. 20/1/1936. (POST-OPERATIVE)

Rate: 90.

Rhythm: Regular sinus rhythm.

P waves: Upright in all Leads.

PR Interval: .12 seconds.

Axis deviation: Well-marked left axis deviation.

QRS Complexes: Upright in Leads 1 and 2; downward
in Lead 3.

T waves: Less prominently upright in Leads 1 and
2; unchanged in Lead 3.

Summary: The rate is slightly faster, but the axis
deviation unaltered. The T waves are less
prominent in Leads 1 and 2. Somatic tremor
is less, and renders identification of the
P waves easier in Lead 1.

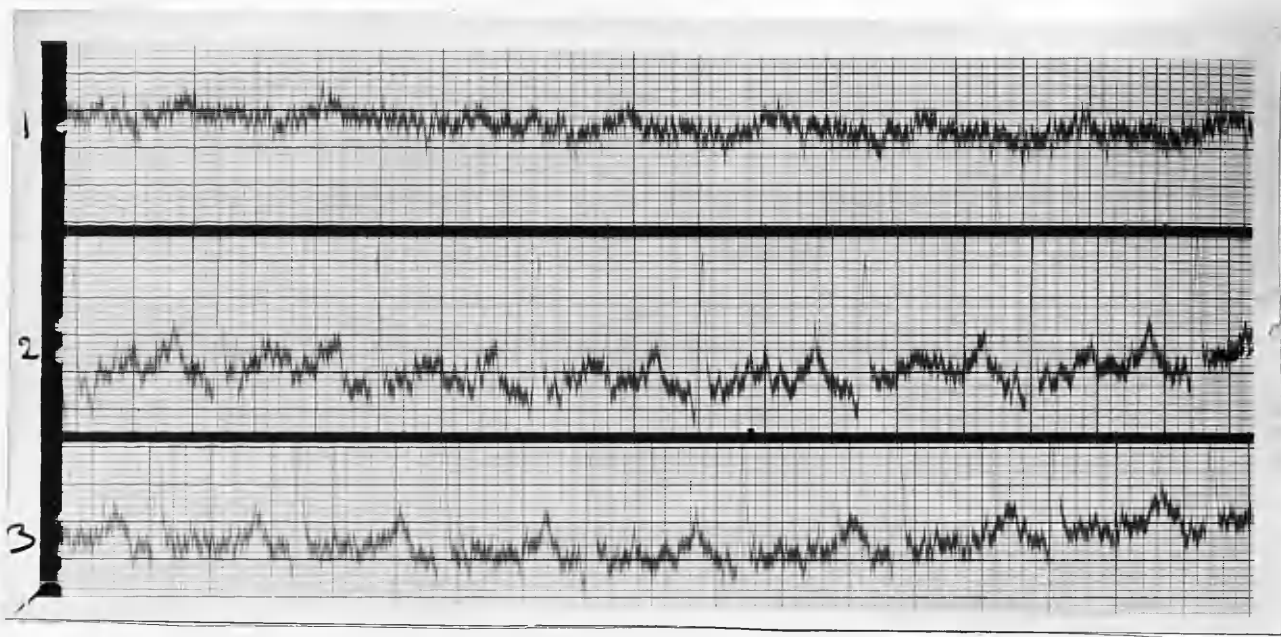
CASE 8. Mrs. M. P. : aged 36 years.

First seen in November, 1935. For 20 years she has had a large goitre which gave her no trouble until 12 months ago, when the swelling became smaller and firmer in consistency. This change was accompanied by symptoms of thyrotoxicosis, and she has lost about 2 stones in weight. No urinary symptoms, but menstruation irregular.

Examination reveals a moderately enlarged thyroid, both lobes about equally enlarged. No palpable nodules.

P.R. 88. B.P. 126/72. B.M.R. +23 per cent.

Partial thyroidectomy 12/12/1935.



E.C.G. 14/11/1935. (PRE-OPERATIVE).

Rate: 120.

Rhythm: Regular sinus rhythm.

P waves: Upright in all Leads; very prominent and sharply pointed in Leads 2 and 3.

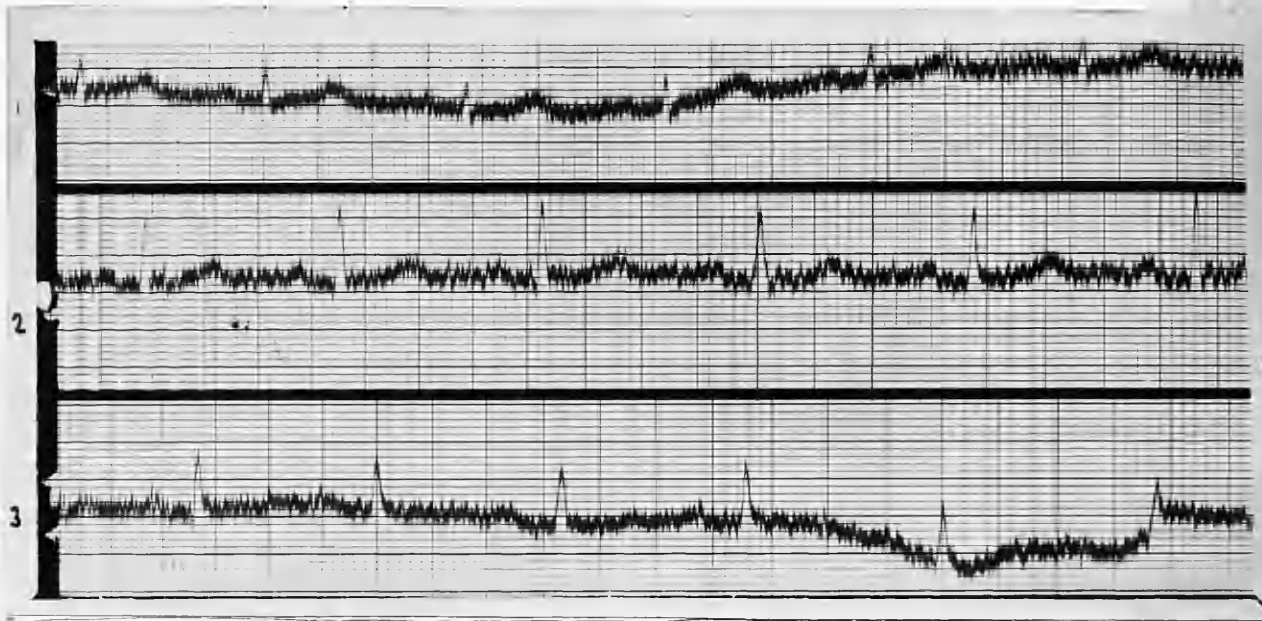
PR Interval. .16 seconds.

Axis deviation: Mild right axis deviation.

QRS Complexes: Directed downwards in Lead 1, where they are of low voltage: upright and of good amplitude in Leads 2 and 3.

T waves: Upright in all Leads; very prominent in Leads 2 and 3.

Summary: Sinus tachycardia with mild ^{right} axis deviation
Marked prominence of P waves in Leads 2
and 3.



E.C.G. 27/2/1936. (POST-OPERATIVE)

Rate: 80.

Rhythm: Regular sinus rhythm.

P waves: Upright in all Leads; much less prominent
in Leads 2 and 3.

PR Interval: .16 seconds.

Axis deviation: Normal.

QRS Complexes: Upright in all Leads. R is more
prominent now in Lead 1, and S less
prominent.

T waves: Upright in Leads 1 and 2; diphasic in Lead
3. The T waves in Lead 2 are rather less
prominent.

Summary: The cardiac rate is now approximately normal
P waves are considerably less pronounced in
Leads 2 and 3, and the T waves in Lead 2 are
slightly less pronounced.

The electrical axis has reverted from right deviation to normal.

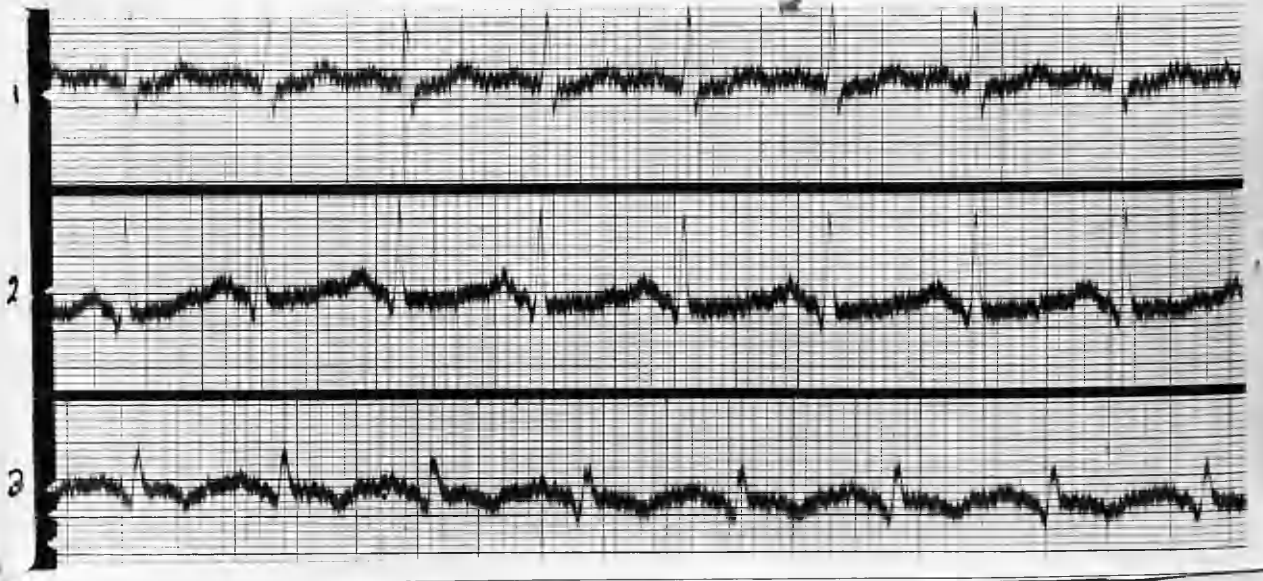
CASE 9. Mrs. M. E. P. : aged 32 years.

Referred for examination August, 1935. History given was that her neck began to enlarge about midsummer, 1933, and this was accompanied by nervousness, irritability, palpitation, and loss of strength. There has not been any appreciable loss of weight, however.

Examination reveals no exophthalmos, but a fine tremor present in the hands. The cardiac apex beat was in the fifth space within the mid-clavicular line, and the sounds pure and closed at all areas. Chest and urine negative.

B.P. 138/95. PR124. B.M.R. +39½ per cent.

Partial thyroidectomy 17/11/1935.



E.C.G. 4/9/1935. (PRE-OPERATIVE).

Rate: 128.

Rhythm: Regular sinus mechanism.

P waves: Upright in all Leads.

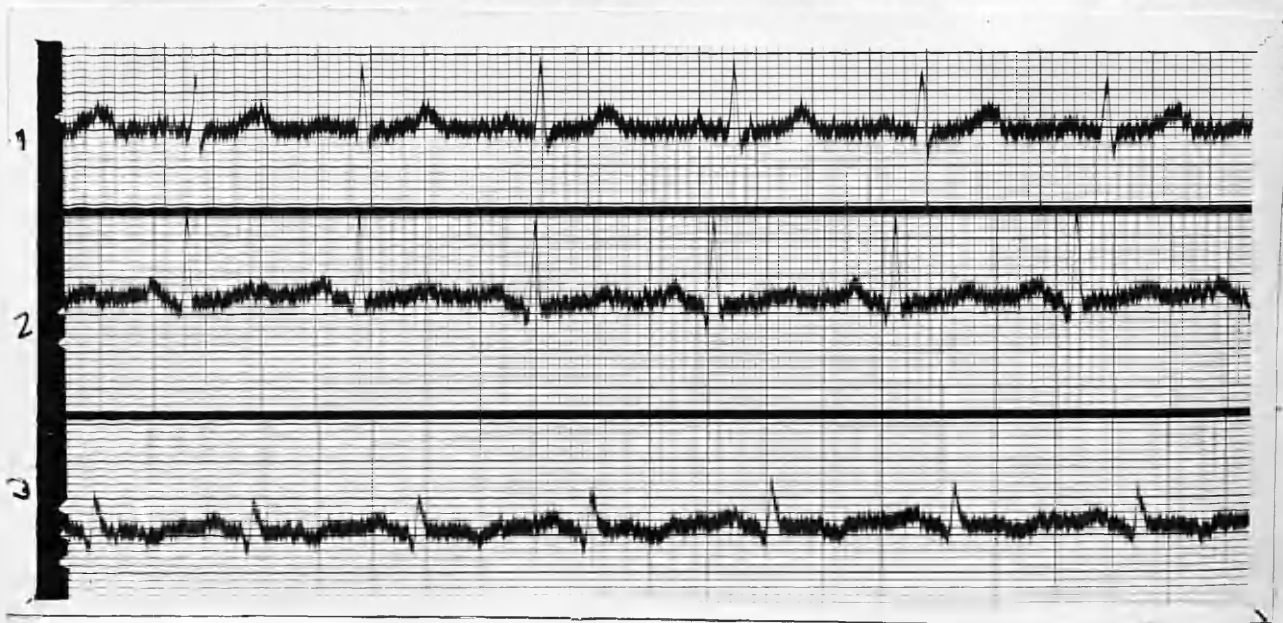
PR Interval: .14 seconds.

Axis deviation: Normal.

QRS Complexes: Upright in all Leads; slurred at the apex of R in Lead 3.

T waves: Upright in Lead 1; diphasic in Lead 2; Inverted in Lead 3.

Summary: Sinus tachycardia with depression of the RT segment in Leads 2 and 3 (? digitalis effect)



E.C.G. 24/2/1936. (POST-OPERATIVE).

Rate: 95.

Rhythm: Regular sinus rhythm.

P waves: Upright in all Leads.

PR Interval: .14 seconds.

Axis deviation: Normal.

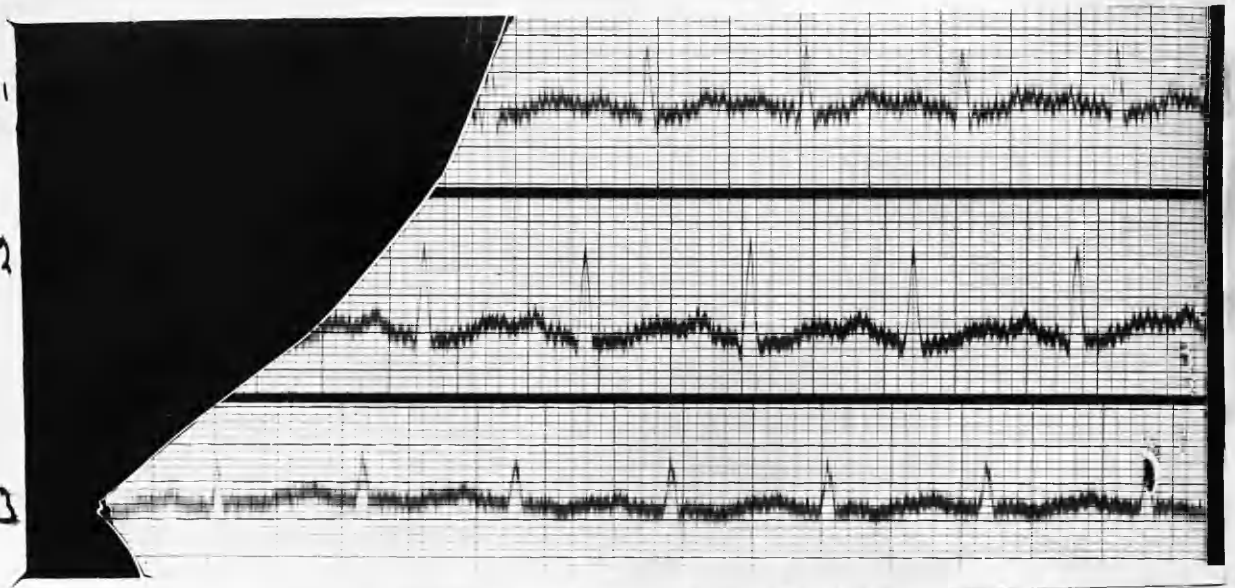
QRS Complexes: Upright in all Leads; downstroke of R in Lead 3 mildly slurred.

T waves: Upright in Leads 1 and 2; less inversion of T waves in Lead 3.

Summary: Heart rate now greatly reduced and less defect of the RT segment (probably due to cessation of Digitalis).

CASE 10. Mrs. M. A. W. : aged 59 years.

History of goitre for many years, but no toxic symptoms till several months prior to examination in October 1935. During the past few weeks she has lost 8 lbs in weight, and she has severe palpitation and tremor. No obvious cardiac disease and the heart is normal in size. Apex beat in fifth space, $4\frac{1}{4}$ " from mid-sternum. 1st mitral sound accentuated. Urine normal. PR 120. B.P. 200/100. B.M.R. +70 per cent. Sub-total thyroidectomy was performed on 29/10/1935 for toxic adenoma.



E.C.G. 16/10/1935. (PRE-OPERATIVE)

Rate: 132.

Rhythm: Regular sinus rhythm.

P waves: Upright in all Leads.

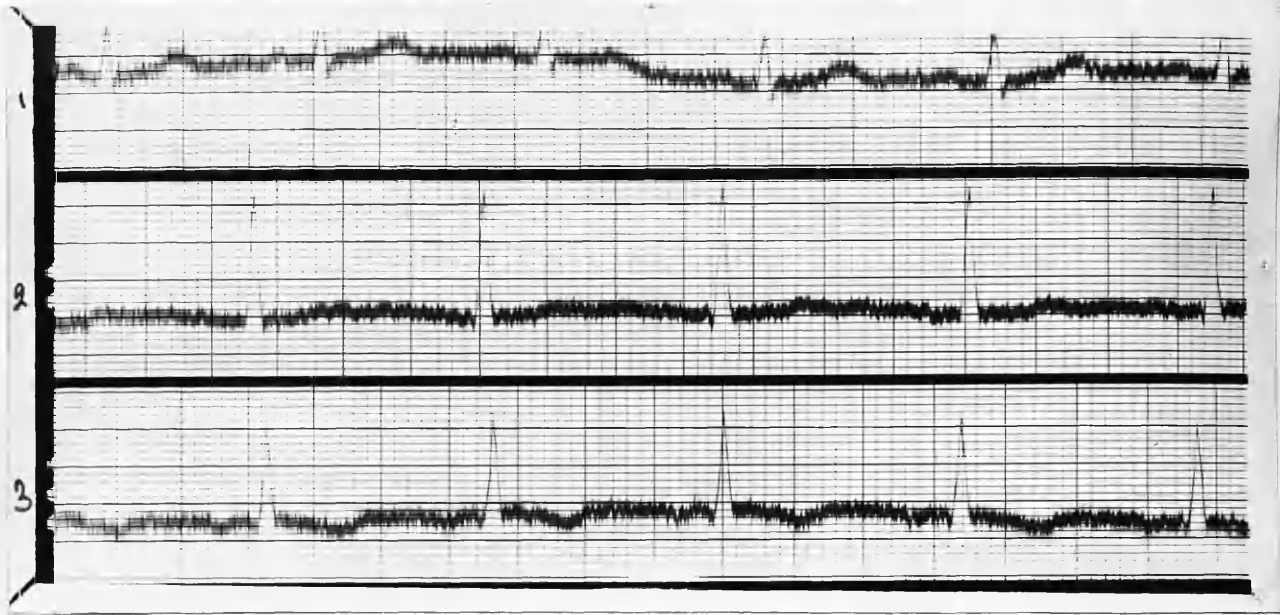PR Interval: .14 seconds.

Axis deviation: Normal.

QRS Complexes: Upright in all Leads. Slight slurring of the downstroke in Lead 3.

T waves: Upright and broad in Leads 1 and 2; inverted in Lead 3.

Summary: Sinus tachycardia without conduction defect or deviation of the electrical axis.



E.C.G. 3/11/1935. (POST-OPERATIVE)

Rate: 86.

Rhythm: Regular sinus mechanism.

P waves: Upright in Leads 1 and 2 inverted in Lead 3.

Axis deviation: Normal.

QRS Complexes: Upright and of normal contour in all Leads. The voltage of the QRS in Leads 2 and 3 is now greater.

T waves: Upright in Leads 1 and 2; inverted in Lead 3. The T wave in Lead 2 is less prominent than in the pre-operative E.C.G.

Summary: The rate is much slower. The P wave in Lead 3 is now inverted, and there is increased excursion of the QRS complex in Leads 2 and 3. T waves in Lead 2 are already slightly less prominent.

CASE 11. Mrs. M. C. : aged 57 years.

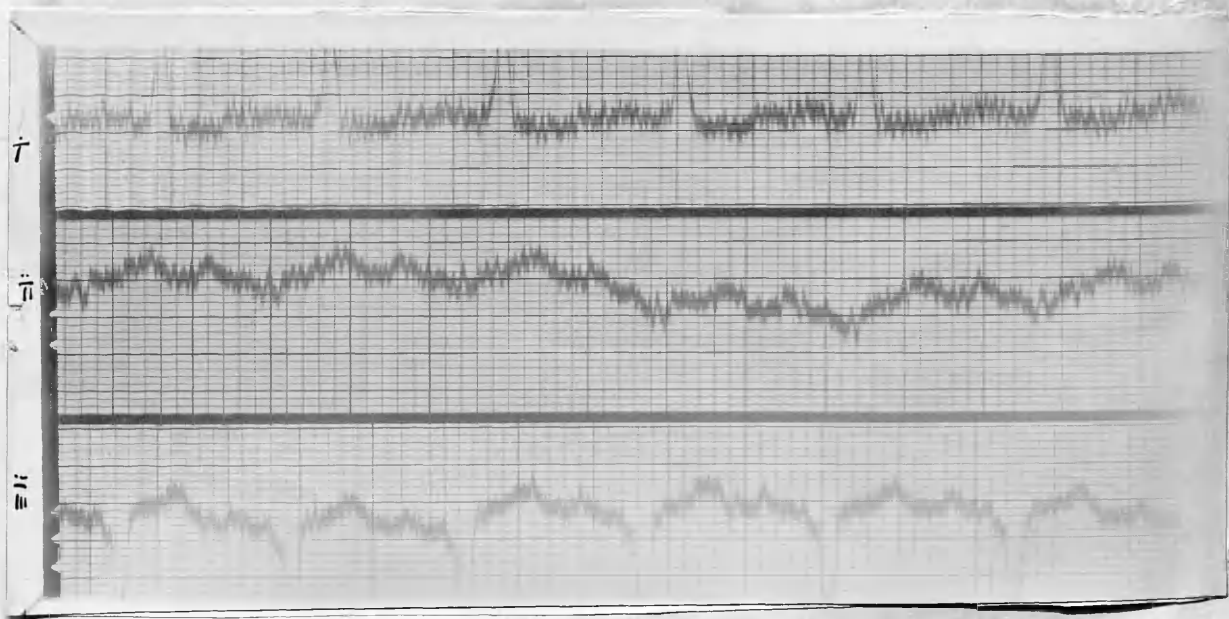
Began to feel ill about Christmas, 1934, but did not seek advice till July, 1935. Her neck has been enlarged since childhood, and this enlargement became noticeably greater during July, 1935. Thyrotoxic symptoms were markedly apparent when she first came for examination and she looked thin and worn. The thyroid shewed a uniform swelling of right and left lobes, and also of the isthmus. It had a nodular feel. In the isthmus was an adenoma about the size of a hen's egg.

P.R. 102. E.M.R. +71 per cent

(2 BP) left deviation
Calc bundle

Cardiac apex beat was $4\frac{1}{2}$ " from mid-sternum in the 5th space; it was localised, and there was no thrill. The 1st sound was loud, and accompanied by a soft systolic bruit conducted toward the base.

Subtotal thyroidectomy 10/10/1935.



E.C.G. 8/10/1935. (PRE-OPERATIVE)

Rate: 120.

Rhythm: Sinus rhythm.

P waves: Upright in all Leads.

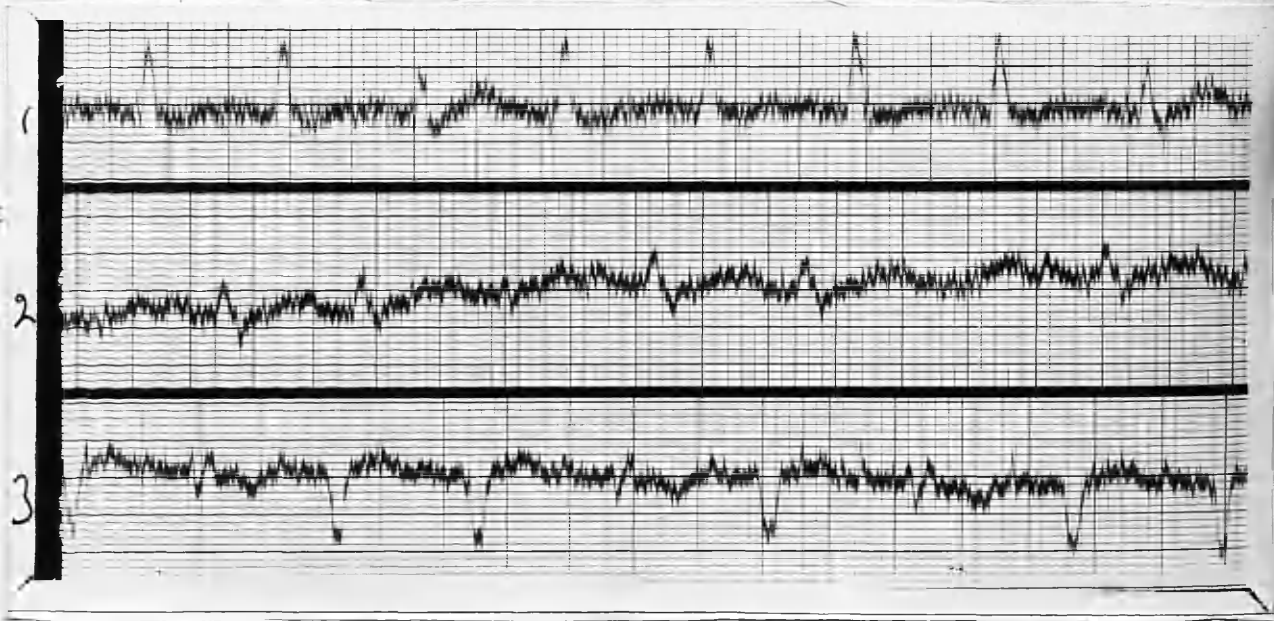
PR Interval: .16 seconds.

Axis deviation: Marked left axis deviation.

QRS Complexes: Of low voltage in Lead 2; some widening of the complexes in Leads 1 and 3.

T waves: Upright in all Leads; very prominent in Lead 3; opposite in direction to the QRS deflections.

Summary: Sinus tachycardia with marked left deviation of the electrical axis. Left bundle branch block.



E.C.G. 18/10/1935. (8 DAYS POST-OPERATIVE)

Rate: 132.

Rhythm: Sinus origin; ventricular extrasystoles - 3rd and 8th beats in Lead 1. 3rd and 6th beats in

Lead 2. 1st. 4th and 6th beats in Lead 3.

P waves: Upright in all Leads.

PR Interval: .18 seconds.

Axis deviation: Left axis deviation.

QRS Complexes: Notched and slurred in all Leads.
particularly marked in Lead 2, where the
complex is now of greater amplitude.

T waves: Isoelectric in Lead 1, except following
the extra systoles where it is prominently
upright.

Upright in Leads 2 and 3; in Lead 3 the T
of the extra systoles is inverted.

Summary: The rate is faster than in the pre-operative
E.C.G., and the rhythm is now interrupted
by ventricular extra-systoles. indicating a
focus of irritation in the ventricular system
probably in proximity to the main Bundle. 7X

(7) There is well-marked left bundle-branch block.

There is less deviation of the electrical axis
to the left in the post-operative E.C.G.

The T waves in Lead 3 are less prominent in
the post-operative E.C.G.

CASE 12. Miss A. F. : aged 30 years.

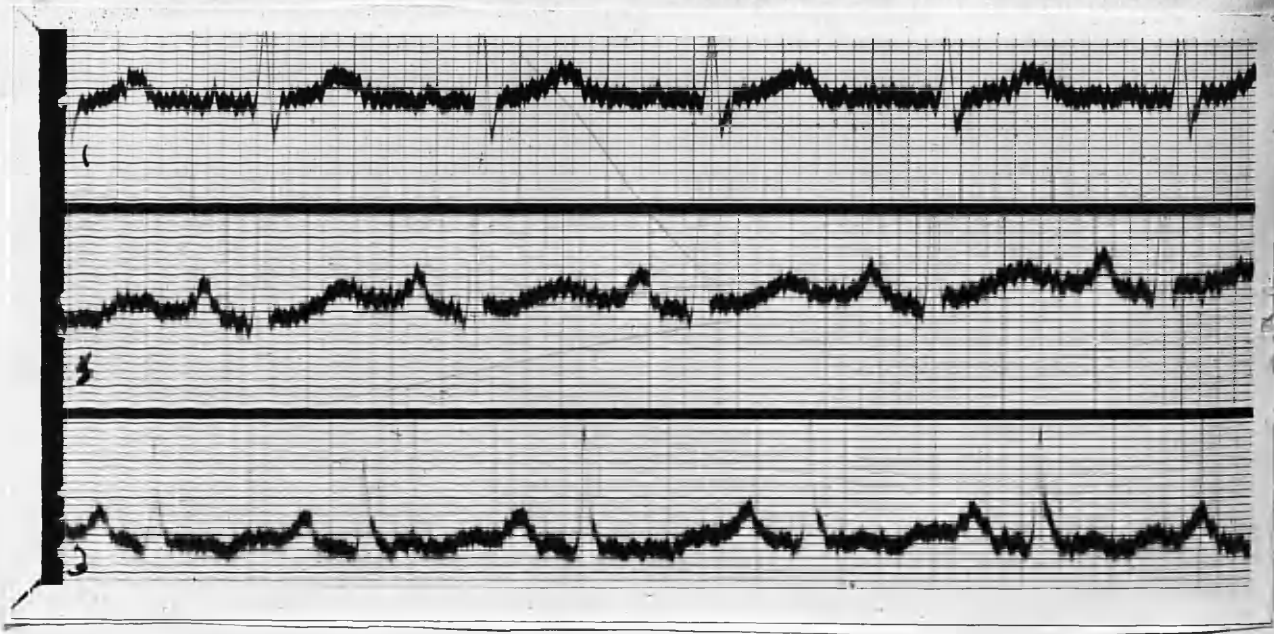
In January, 1935, began to feel nervous and easily
tired. She was breathless on exertion. There was at
that time no noticeable thyroid enlargement, but she was
diagnosed by her doctor as a case of hyperthyroidism and
sent to B.R.I. for X-Ray treatment. She had this treatment
from February 1935 till June, 1935. When seen on 25/6/1935.

she still complained of tiredness and palpitation. Her weight was 8 st. 2 lbs., her best weight having been 9 st. 4 lbs. She has gained 2 lbs. whilst on X-Ray therapy.

There was slight exophthalmos, and Van Graefe's sign was present. Her hands shewed fine tremor when outstretched.

Cardiac apex beat was 4" from mid-sternum in 5th space. The first sound at the apex was forcible, and accompanied by a soft systolic murmur. B.P. 140/75. P.R. 108. E.M.R. +43.5 per cent.

Operation (S.T.T.) 15/7/1935.



E.C.G. 25/6/1935. (PRE-OPERATIVE)

Rate: 118

Rhythm: Mild sinus arrhythmia.

P waves: Upright in all Leads: very prominent and

sharply pointed in Leads 2 and 3.

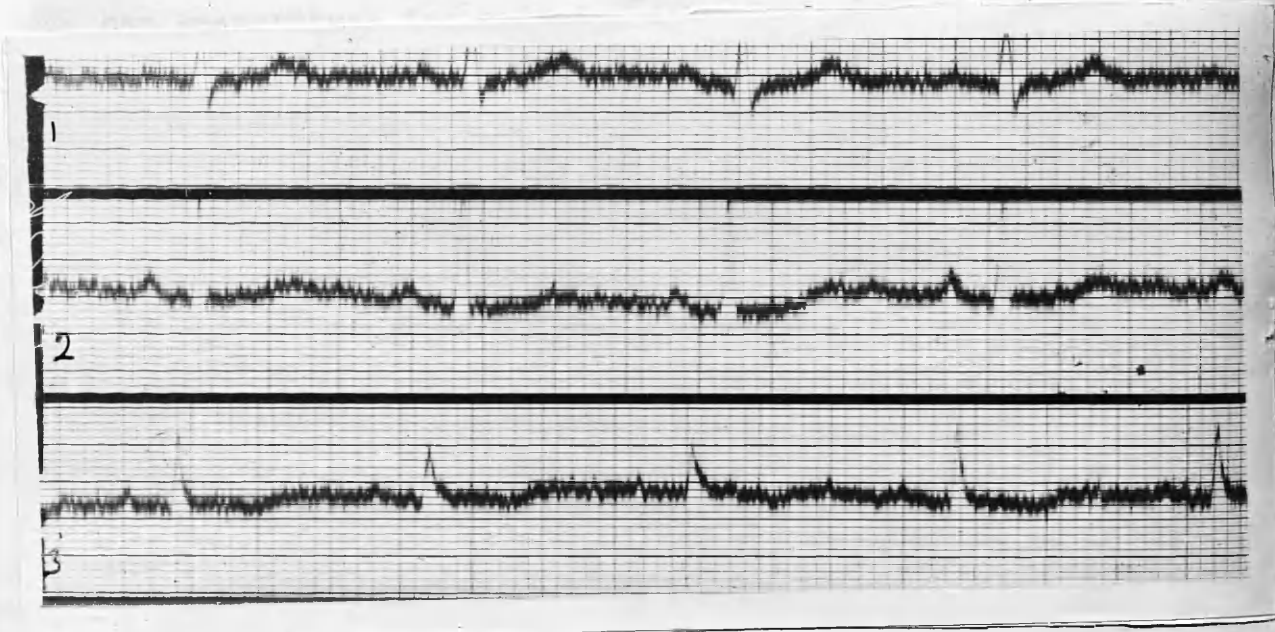
PR Interval: .14 seconds.

Axis deviation: Normal.

QRS Complexes: Upright and of normal contour
in all Leads.

T waves: Prominent, broad and upright in Lead 1.
Upright and broad in Lead 2. Inverted in
Lead 3.

Summary: Sinus tachycardia with no conduction
deformity, and normal axis deviation. Marked
prominence of P waves in Leads 2 and 3, ~~and of~~
and of the T waves in Lead 1.



E.C.G. 20/7/36. (POST OPERATIVE).

Rate: 82.

Rhythm: Regular sinus rhythm.

P waves: Upright in all Leads.

PR Interval: .14 seconds.

Axis deviation: Normal.

QRS Complexes: Normal and upright in all Leads.

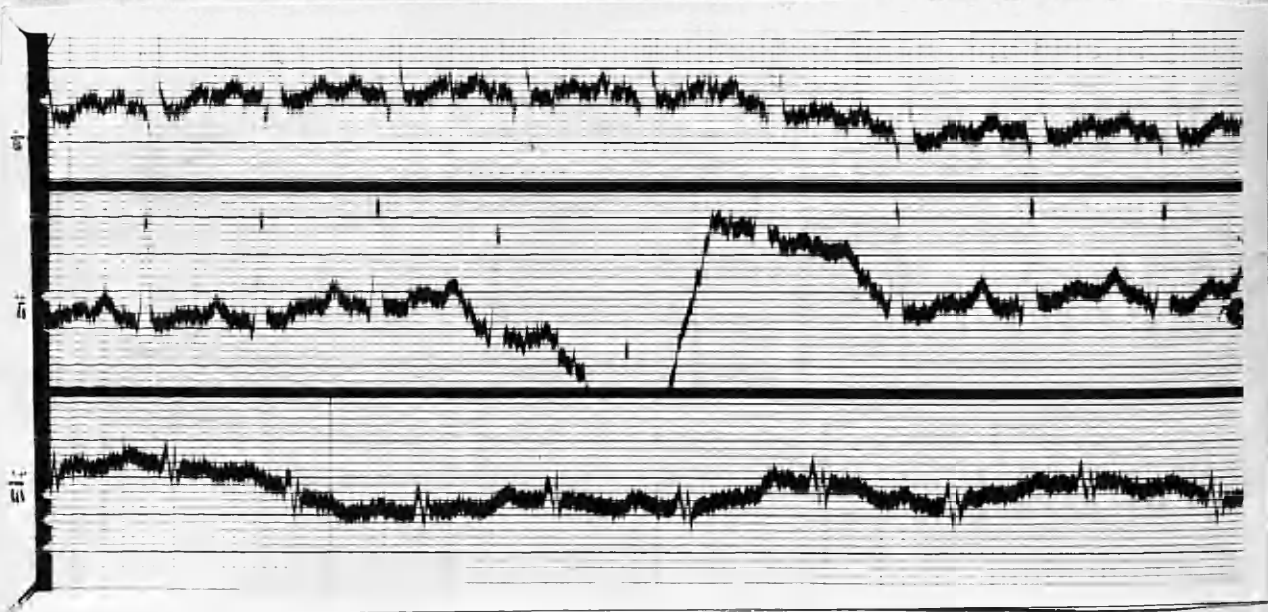
T waves: Upright in Leads 1 and 2; mildly inverted in Lead 3.

Summary: The rate is now much slower, and the rhythm regular. The P waves in Leads 2 and 3 are less prominent, particularly in Lead 3. The T waves also shew less prominence in Leads 1 and 2

CASE 13. Miss J. W. : aged 41 years.

Shortness of breath, choking sensation in throat, and palpitation - 9 months' history. Has lost weight, and has had amenorrhoea for past 4 months. Thyroid enlarged.

Heart: Apex-beat $3\frac{1}{2}$ " from mid-sternum; localised systolic murmur at apex: pulmonary 2nd sound +. Operation : 7/7/1937



E.C.G. 27/6/1937. (PRE-OPERATIVE)

Rate: 125.

Rhythm: Regular sinus rhythm; no rest time.

P waves: Upright in all Leads. Fairly prominent in Lead 2.

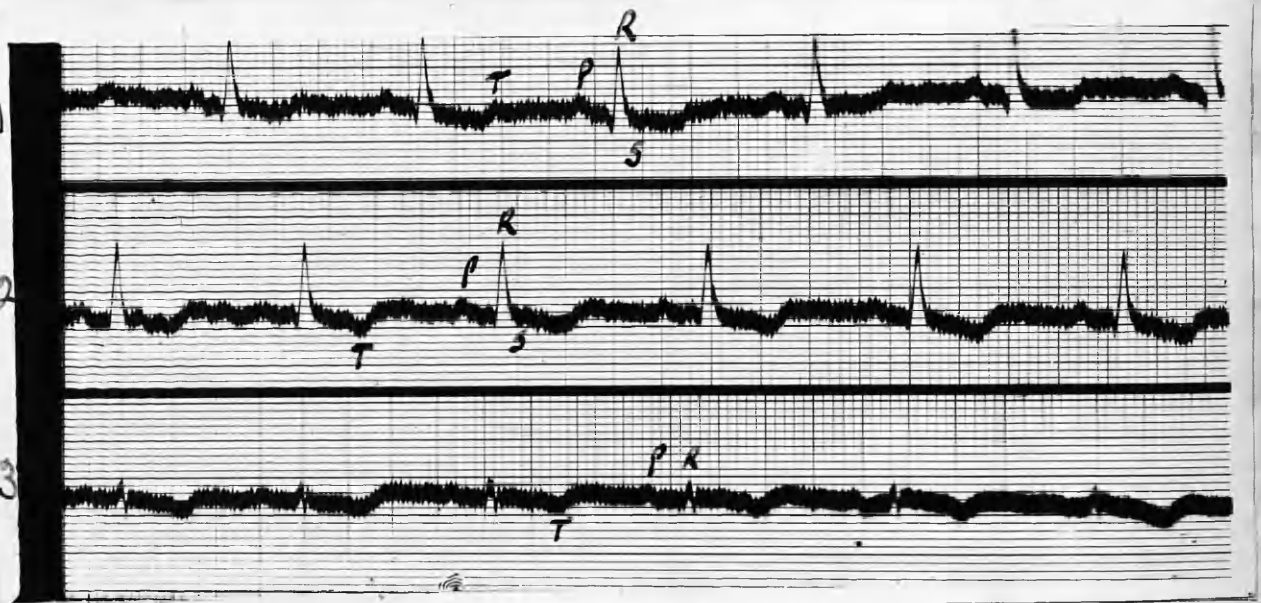
PR Interval: .18 seconds.

QRS Complexes: Directed upwards in all Leads. In Lead 3 the complex is of low voltage and is notched.

T waves: Upright in Lead 1: diphasic in Leads 2 and 3.

Axis: Normal deviation.

Summary: Sinus tachycardia. P 2 fairly prominent. T waves diphasic in Leads 2 and 3.



E.C.G. 28/7/1937. (POST-OPERATIVE).

Rate: 70.

Rhythm: Regular sinus rhythm.

P waves: Upright in all Leads: amplitude small.

PR Interval: .18 seconds.

QRS. Complexes: Directed upwards in all Leads: low voltage and notched in Lead 3.

T waves: Inverted in Leads 2 and 3; diphasic in Lead 1.

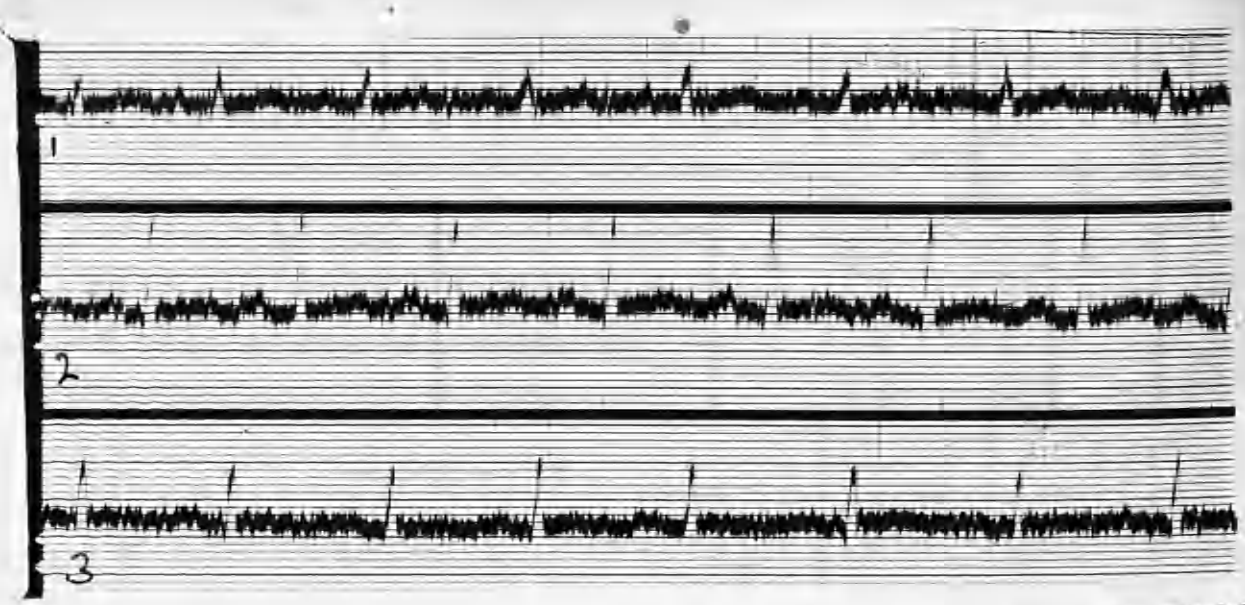
Axis: Normal.

Summary: Regular sinus rhythm. Rate much slower than in pre-operative E.C.G. P.2. is of lower amplitude, also T.2. and T.3. are now inverted.

QRS Complexes: Directed upwards in all leads. Some notching in Lead 1, and slurring

CASE 14. Mrs. S. B. : aged 63 years.

Thyroid enlarged for 20 years. About 12 months ago she began to lose weight and complained of being easily tired, shortness of breath, and nervousness. Exophthalmos commenced shortly afterwards. Altogether lost about 20 lbs. Exophthalmos and marked fine tremor. Gross bilateral enlargement of the thyroid ^{and} of isthmus, right lobe slightly the larger. Heart negative. Operation: 23/7/1937.



E.C.G. 5/7/1937. (PRE-OPERATIVE).

Rate: 104.

Rhythm: Regular sinus rhythm.

P waves: Upright and of low voltage in all Leads.

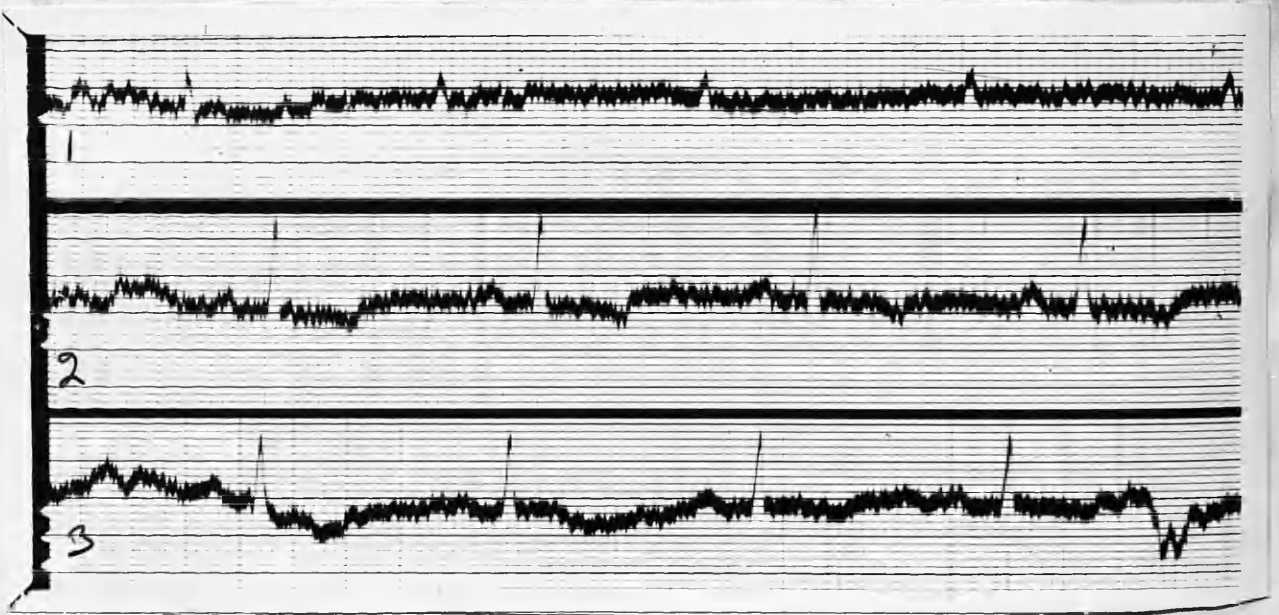
PR Interval: .16 seconds.

QRS Complexes: Directed upwards in all Leads.
Some notching in Lead 1, and slurring
in Lead 3.

T waves: Upright and rather flattened in Leads 1
and 2; isoelectric in Lead 3.

Axis: Normal.

Summary: Sinus tachycardia. No conduction defects.
T and P waves of small amplitude in all Leads.



E.C.G. 6/8/1937. (POST-OPERATIVE)

Rate: 60.

Rhythm: Sinus rhythm with a ventricular extra-
systole at the end of Lead 3.

P waves: Upright and of small amplitude in all Leads.

PR Interval: .16.

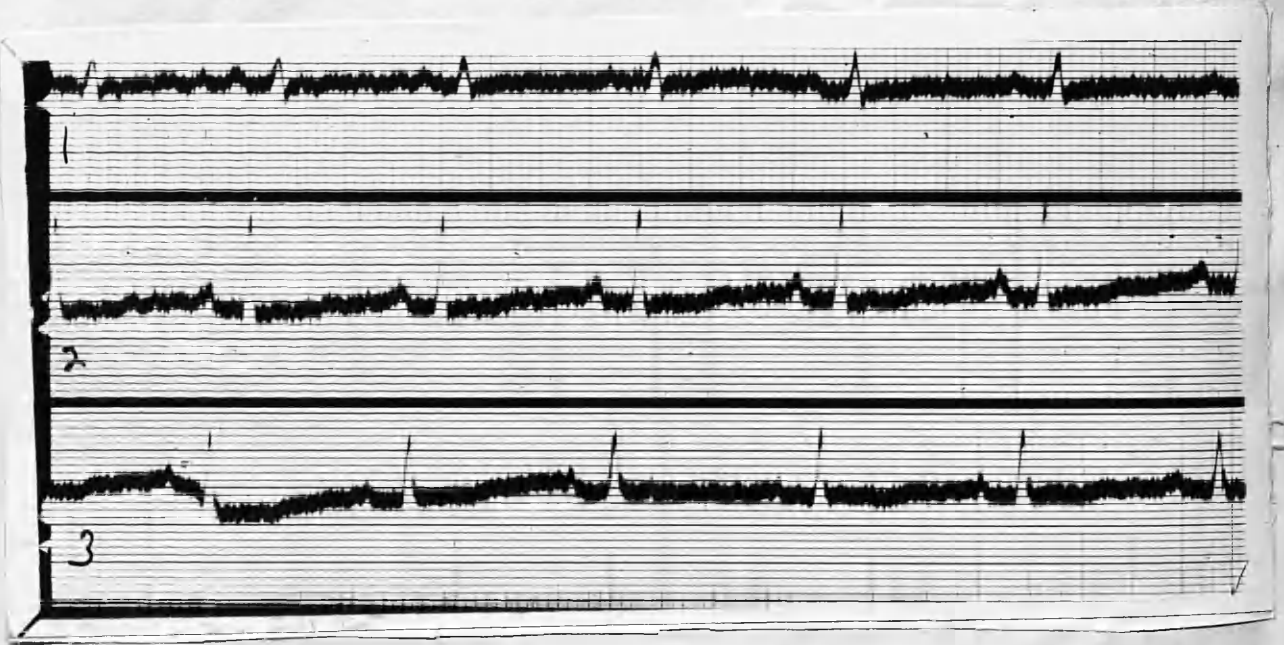
QRS Complexes: Upright in all Leads; low voltage
in Lead 1.

T waves: Diphasic in Lead 1; inverted in Leads
2 and 3.

Axis: Normal.

Summary: Sinus bradycardia. T waves are now
inverted in Leads 2 and 3, and are diphasic
in Lead 1.

One ventricular extra-systole interrupts
the sinus rhythm.



E.C.G. 26/8/37. (POST-OPERATIVE)

Rate: 75.

Rhythm: Regular sinus rhythm.

P waves: Upright in all Leads.

PR Interval. .16 seconds.

QRS Complexes: Directed upwards in all Leads.

T waves: Flattened in all Leads.

Electrical Axis: Normal.

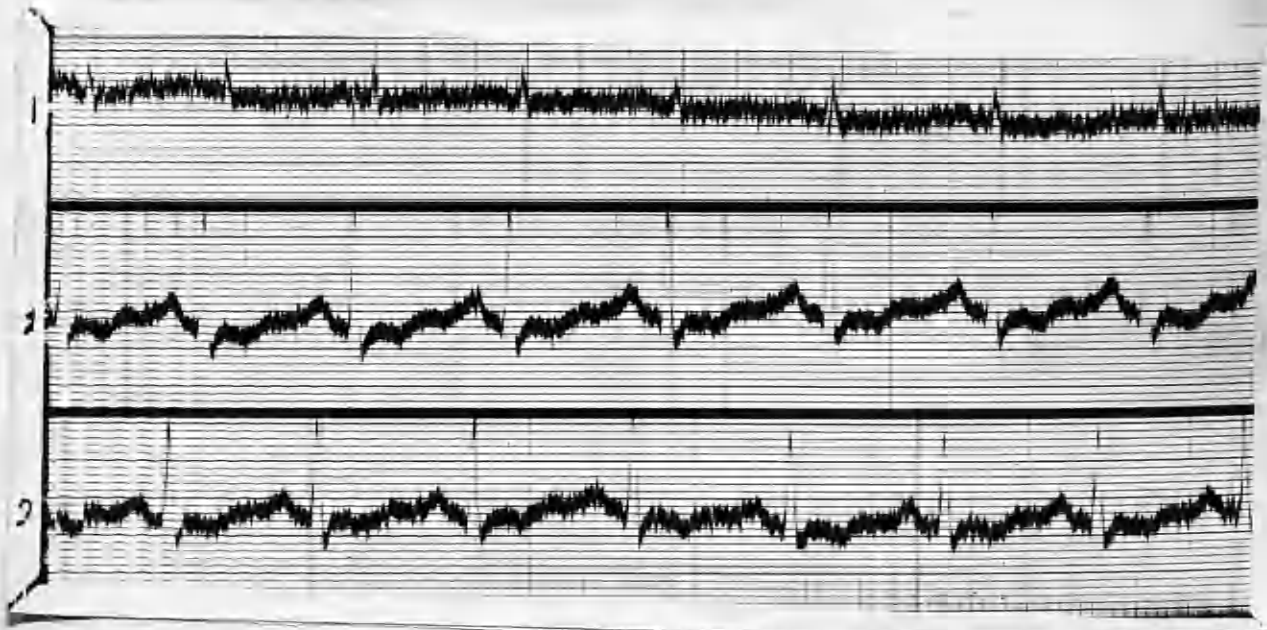
Summary: Rate is now normal and rhythm regular. QRS complexes in Lead 1 are of slightly higher voltage.

The T waves in Lead 3 are no longer inverted.

CASE 15. Mrs. A. W. : aged 34.

Two months history of praecordial distress on exertion, associated with constant langour and tachycardia. Fine tremor of hands, and slight bilateral enlargement of thyroid. Apex beat in 6th space, within nipple line; 1st. sound at apex sharp and accentuated. No bruits or arrhythmia.

Operation 25/5/1936.



E.C.G. 15/5/1936. (PRE-OPERATIVE)

Rate: 100.

Rhythm: Regular sinus rhythm.

P waves: Upright in all Leads. Prominent particularly in Lead 2.

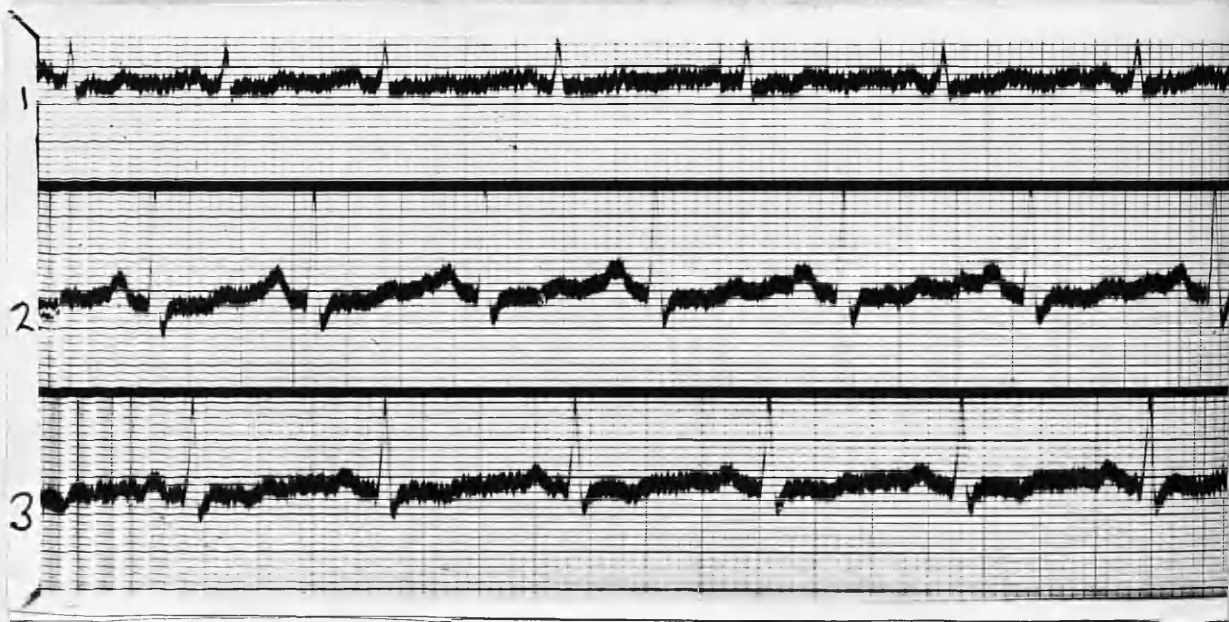
PR Interval: .14 seconds.

QRS Complexes: Directed upwards in all Leads.

T WAVES: RT interval flattened (? digitalis effect) in all Leads.

Axis: Normal.

Summary: Sinus tachycardia. RT segment depression.



E.C.G. 3/1/1937. (POST OPERATIVE).

Rate: 92.

Rhythm: Regular sinus rhythm.

P waves: Upright in all Leads. Rather prominent in Lead 2.

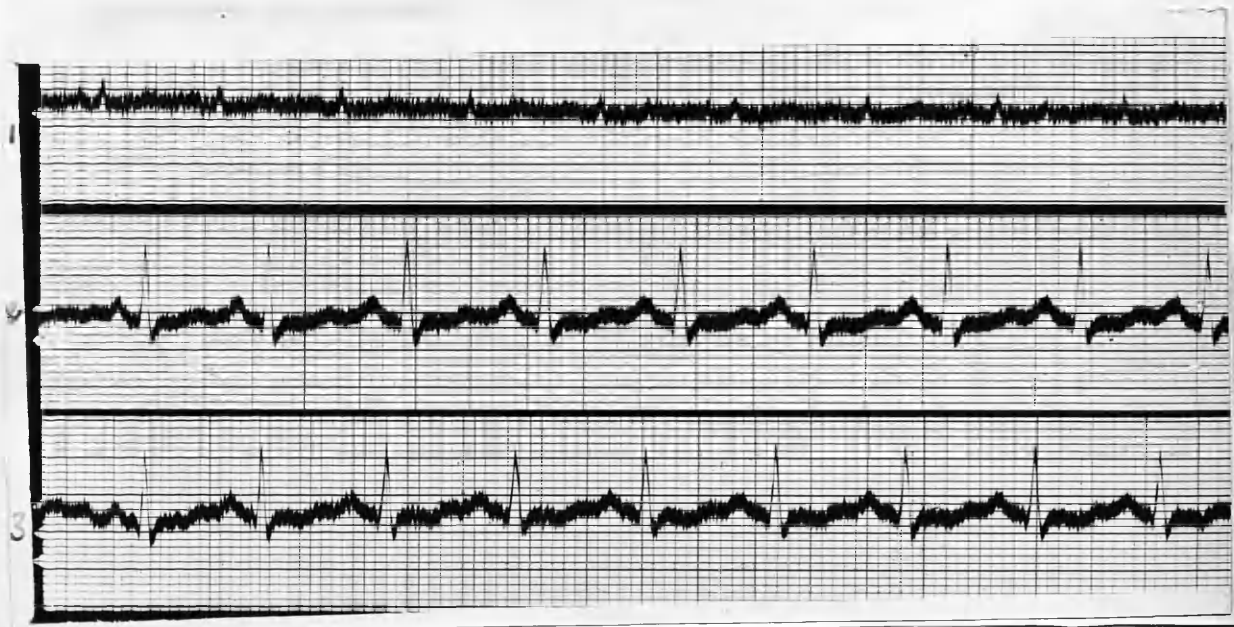
PR Interval: .14 seconds.

QRS Complexes: Directed upwards in all Leads.

T waves: Diphasic in Leads 1 and 2; inverted in Lead 3. RT segment still flattened.

Axis: Normal deviation.

Summary: Sinus tachycardia: regular rhythm. P.2. remains prominent. Rate slightly slower.



E.C.G. 19/6/1937. (POST OPERATIVE)

Rate: 120.

Rhythm: Regular sinus rhythm.

P waves: Upright in all Leads; less prominent in Lead 2.

PR Interval: .14 seconds.

QRS Complexes: Upright in all Leads. Voltage low in Lead 1.

T waves: RT segment still shows depression.

Electrical Axis: Normal.

Summary: Rate is faster despite clinical improvement?
(? emotional). P 2 is now less prominent
following her operation.

CASE 16. Miss D. Y. : aged 17 years.

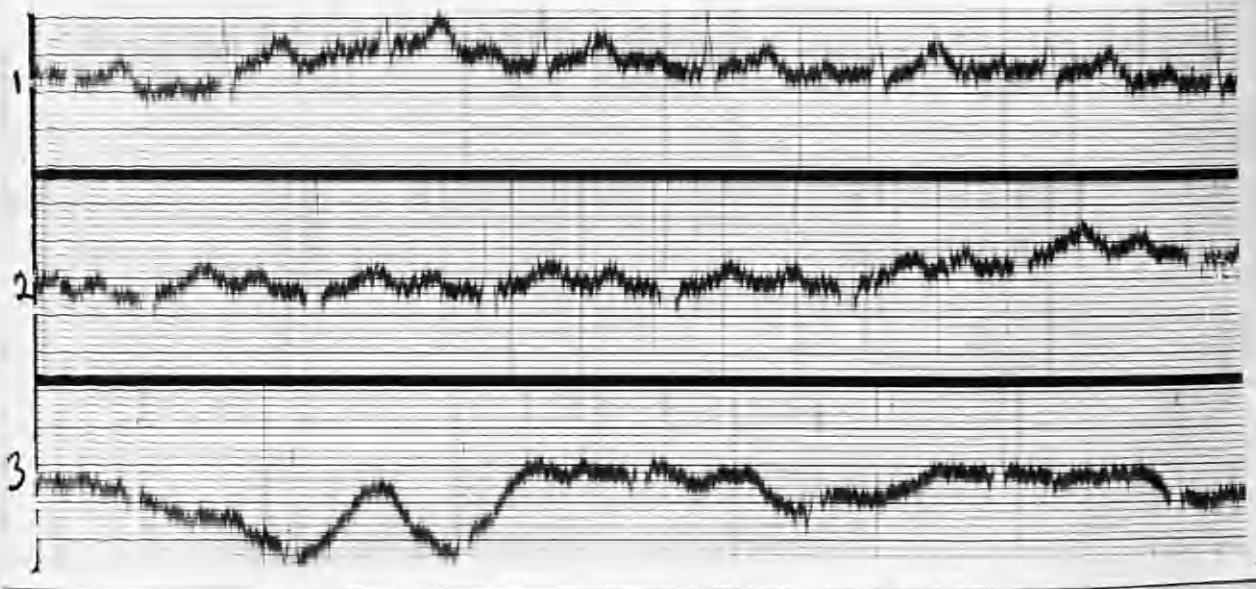
Three months' history of swelling in neck with symptoms
of hyperthyroid activity. Exophthalmos prominent, with
dyspnoea and tremor.

Systolic bruit at apex. not conducted. Aortic 2nd
sound +. Slight pericardial rub audible over 2nd left
space near sternum.

Apex-beat $3\frac{1}{2}$ " from mid-sternum.

B.P. 150/72. B.M.R. +40 per cent.

Partial thyroidectomy 15/2/1937.



E.C.G. 31/12/1936. (PRE-OPERATIVE).

Rate: 104.

Rhythm: Regular sinus rhythm.

P waves: Upright in all Leads.

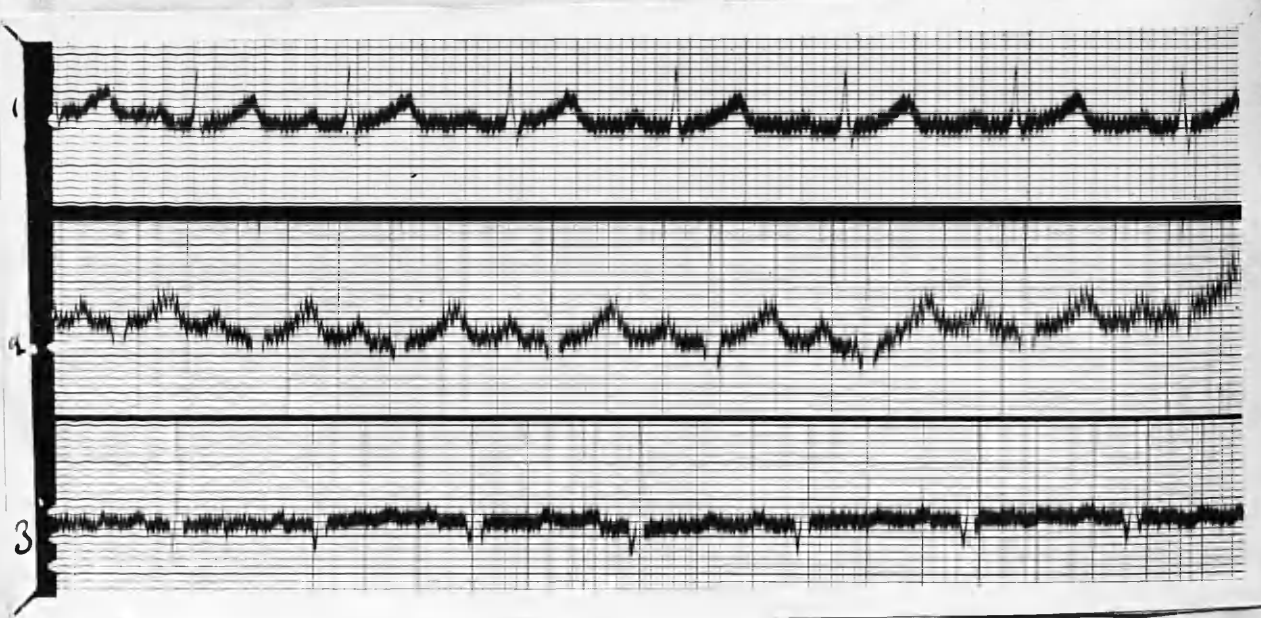
PR Interval: .13 seconds.

QRS Complexes: Upwards. and of normal contour in all Leads.

T waves: Upright and markedly prominent in Lead 1;
Upright in Lead 2; inverted in Lead 3.

Axis deviation: Normal.

Summary: Sinus tachycardia; marked prominence of T.1.



E.C.G. 4/2/1937. (PRE-OPERATIVE).

Rate: 104.

Rhythm: Regular sinus rhythm.

P waves: Upright in all Leads. No undue prominence.

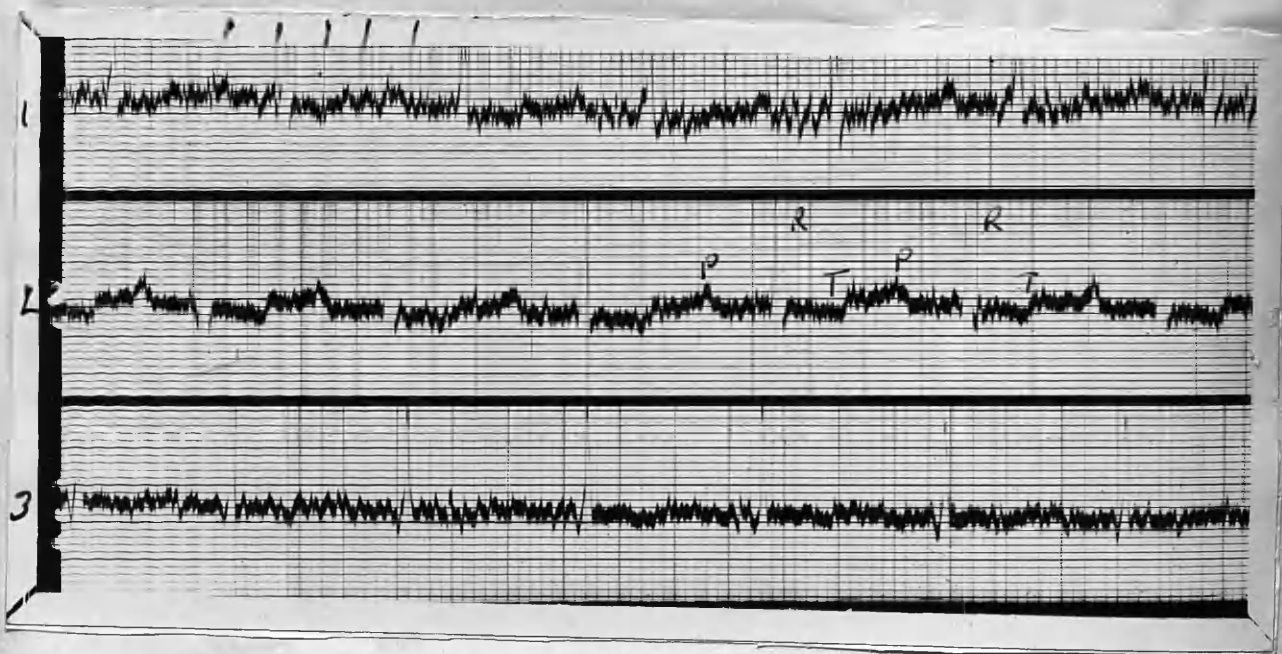
PR Interval: .16 seconds.

QRS Complexes: Directed upwards in all Leads.

T waves: Directed upwards, and prominent in Leads 1 and 2; diphasic in Lead 3.

Axis deviation: Normal.

Summary: Sinus tachycardia; prominent T waves in Leads 1 and 2.



E.C.G. 24/2/1937. (POST-OPERATIVE).

Rate: 96.

Rhythm: Regular sinus rhythm.

P waves: Upright in Leads 1 and 2; unrecognisable in Lead 3.

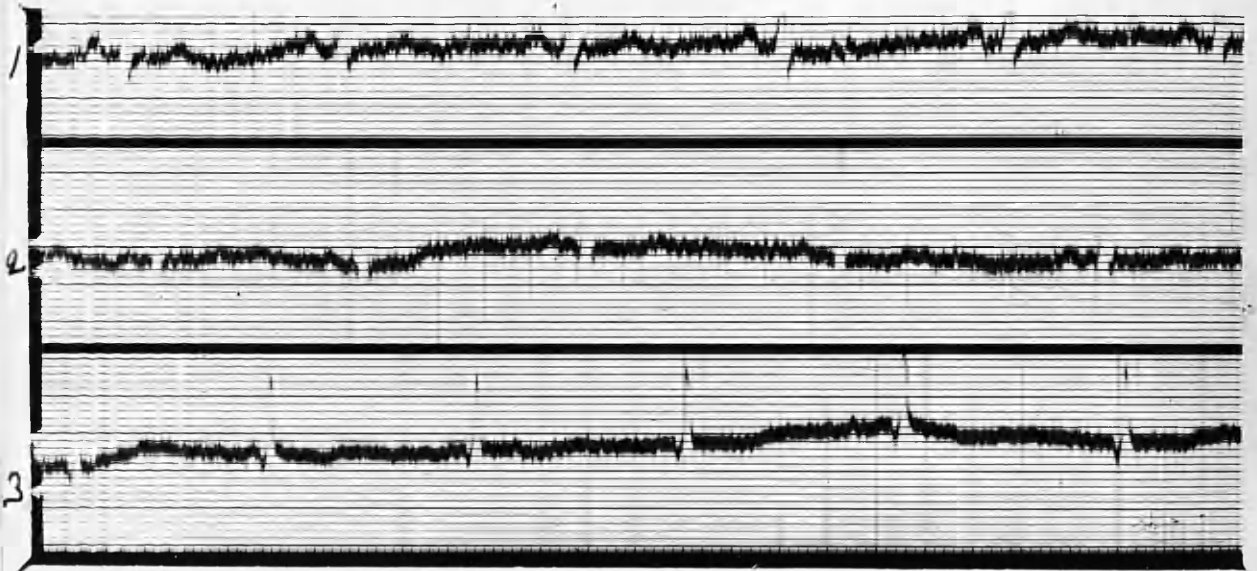
PR Interval: .24 seconds.

QRS Complexes: Directed upwards in all Leads.

T waves: Diphasic in Lead 2; unrecognisable in Lead 1. mildly inverted in Lead 3.

Axis deviation: Normal.

Summary: Sinus tachycardia less marked than in pre-operative E.C.G. Partial heart block now present. T waves less prominent in Leads 1 and 2, and now inverted in Lead 3.



E.C.G. 18/3/1937. (POST-OPERATIVE)

Rate: 66.

Rhythm: Mild sinus arrhythmia.

P waves: Directed upwards in Leads 1 and 2;
flattened in Lead 3.

PR Interval: .16 seconds.

QRS Complexes: Directed upwards in all Leads.

T waves: Directed upwards in Leads 1 and 2;
mildly inverted in Lead 3.

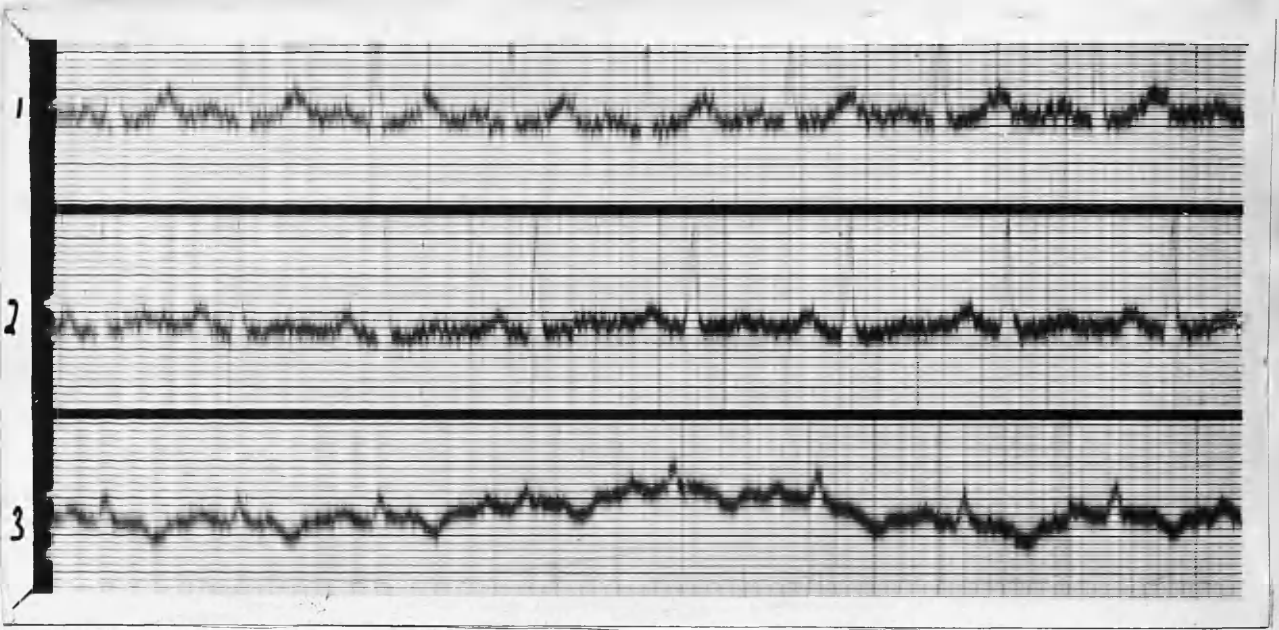
Axis deviation: Normal.

Summary: Mild sinus arrhythmia. Tachycardia now disappeared, and no evidence of partial heart-block. The T waves are less prominent than in the pre-operative E.C.G.

CASE 17. Mrs. E. J. : aged 25 years.

Primary toxic goitre. Tachycardia; exophthalmos marked; soft bilateral thyroid enlargement - 12 months' history.

Has lost about 18 lbs. since symptoms began. Operation 18/2/1937



E.C.G. 3/2/1937. (PRE-OPERATIVE)

Rate: 120.

Rhythm: Regular sinus mechanism.

P waves: Upright in all Leads.

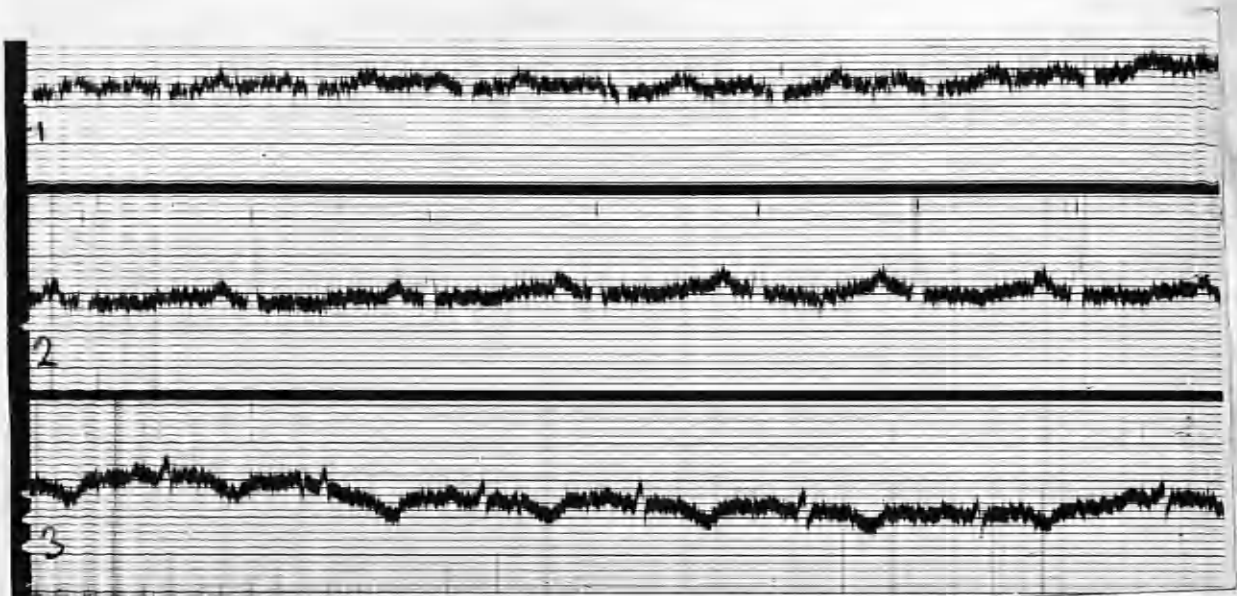
PR Interval: .12 seconds.

QRS Complexes: Directed upwards in all Leads:
amplitude small in Lead 3, and complex mildly
slurred.

T waves: Very prominent in Lead 1; upright in Lead
2; inverted in Lead 3.

Axis deviation: Normal.

Summary: Sinus tachycardia; no conduction defects;
T.1. prominent.



E.C.G. 1/4/1937. (POST OPERATIVE)

Rate: 94.

Rhythm: Regular sinus rhythm.

P waves: Upright in all Leads.

PR Interval: .16 seconds.

QRS Complexes: Directed upwards in all Leads; low amplitude in Lead 3.

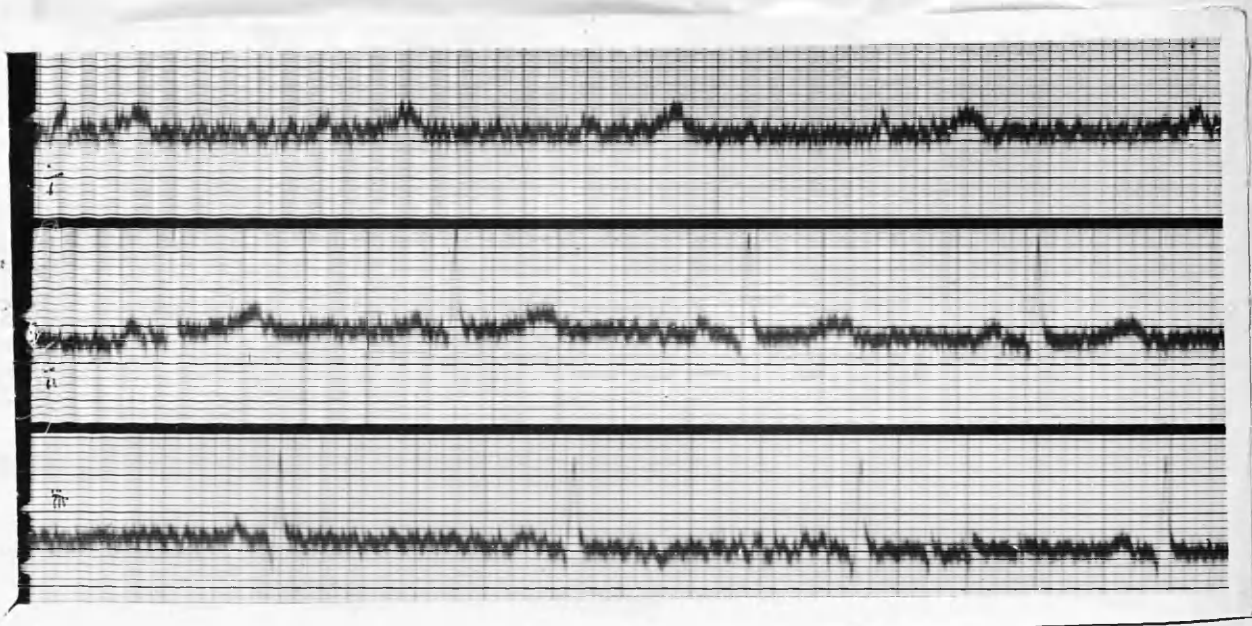
x T waves: Upwards in Lead 1; diphasic in Lead 2; inverted in Lead 3.

Axis deviation; Normal.

Summary: There is considerably less prominence in T.1, and the rate is slower.

CASE 18. Mrs. E. T. : aged 27 years.

Goitre of 7 years' duration; during last few months it has become bigger, with toxic symptoms. (Toxic Adenoma).
Operation : 8/1/1937. (Taken whilst patient was having pre-operative therapy with Lugol's Iodine and Digitalis).



E.C.G. 5/1/1937. (PRE-OPERATIVE)

Rate: 70.

Rhythm: Regular sinus rhythm.

P waves: Isoelectric in Lead 1; upright and of normal amplitude in Leads 2 and 3.

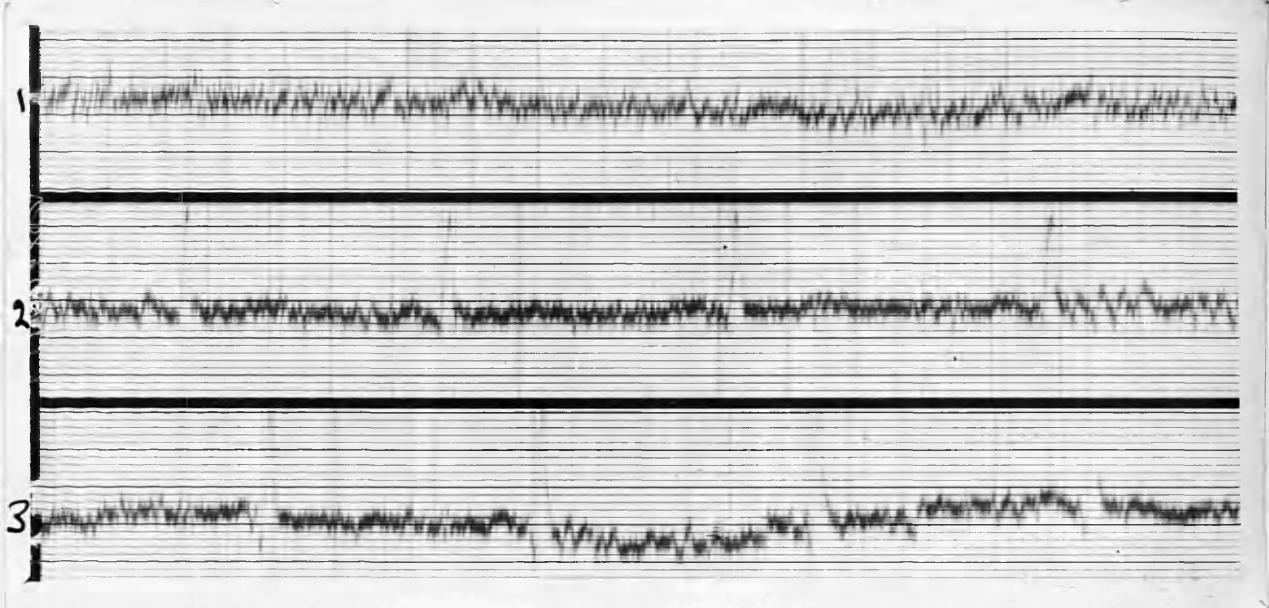
PR Interval: .15 seconds.

QRS Complexes: Directed upwards in all Leads; of low voltage and notched in Lead 1.

T waves: Very prominent in Lead 1; upright in Lead 2; diphasic in Lead 3.

Electrical axis: Normal deviation.

Summary: Regular sinus rhythm: QRS in Lead 1 indicates some inefficiency of the right ventricle. T.1. prominent.



E.C.G. 18/1/1937. (POST-OPERATIVE).

Rate: 70.

Rhythm: Sinus arrhythmia.

P waves: Isoelectric in Lead 1.

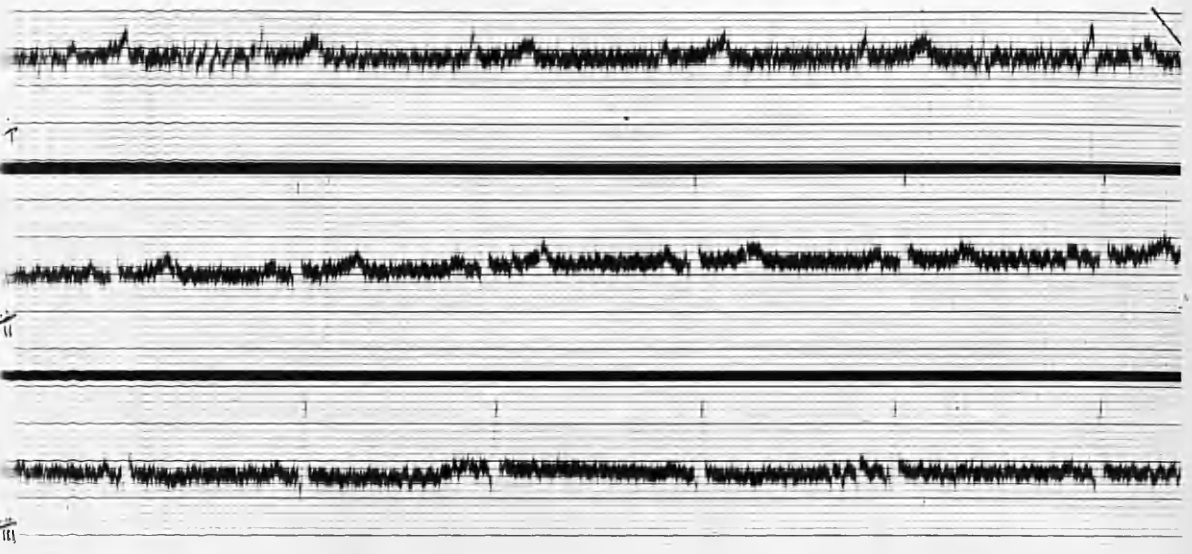
PR Interval: .14 seconds.

QRS complexes: Directed upwards in all Leads. R 3 shows a greater excursion than in the pre-operative E.C.G. QRS complexes difficult to identify in Lead 1 on account of somatic tremor.

T waves: Less prominent in Leads 1 and 2.

Axis: Probably normal deviation.

Summary: T.1. and T.2. less prominent.



E.C.G. 31/8/1937. (POST-OPERATIVE).

Rate: 62.

Rhythm: Mild sinus arrhythmia.

P waves: Flat in Lead 1.

PR interval: .14 seconds.

QRS complexes: R 3 now shows less amplitude than in last E.C.G.

T waves: Of normal amplitude in Leads 1 and 2; diphasic in Lead 3.

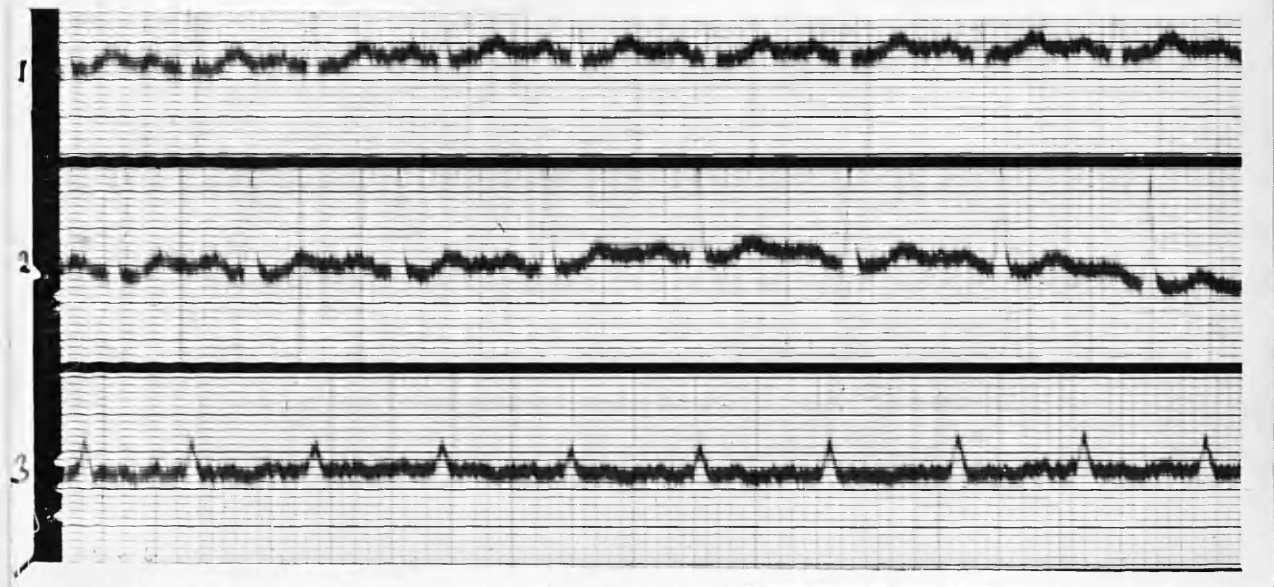
Electrical axis: Normal.

Summary: Sinus bradycardia and arrhythmia.

CASE 19. Miss E. B. : aged 55 years.

Well in health until two years ago, when she began to complain of fatigue, loss of weight and palpitation. She has lost two stones. Thyroid is moderately enlarged and

exophthalmos is present. She has had X-Ray therapy for three months, but though there has been some gain in weight. her general condition is not much better. Partial thyroidectomy 9/10/1936.



E.C.G. 28/9/1936. (PRE-OPERATIVE)

Rate: 120.

Rhythm: Regular sinus rhythm.

P waves: Upright and of low amplitude in all Leads.

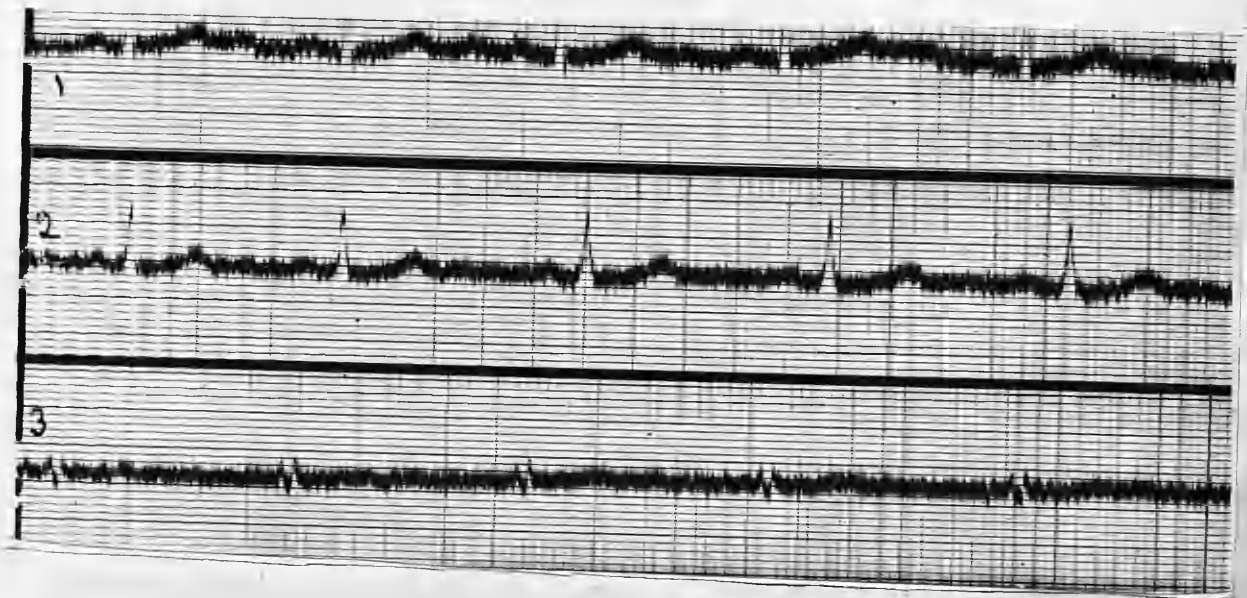
PR Interval: .12 seconds.

QRS Complexes: Directed upwards in all Leads; low voltage in Lead 3.

T waves: Upright and prominent in Lead 1; upright in Lead 2; diphasic in Lead 3.

Axis deviation: Normal.

Summary: Sinus tachycardia: prominent T.1.



E.C.G. 31/3/1937. (POST-OPERATIVE).

Rate: 62.

Rhythm: Sinus arrhythmia.

P waves: Upwards: low amplitude in Leads 1 and 2; *diphasic Lead 3.

PR interval: .14 seconds.

QRS Complexes: Directed upwards in all Leads; low amplitude in Lead 3.

T waves: Upwards in all Leads.

Axis deviation: Normal.

Summary: Sinus arrhythmia and bradycardia.

T.1. slightly flatter than in pre-operative E.C.G

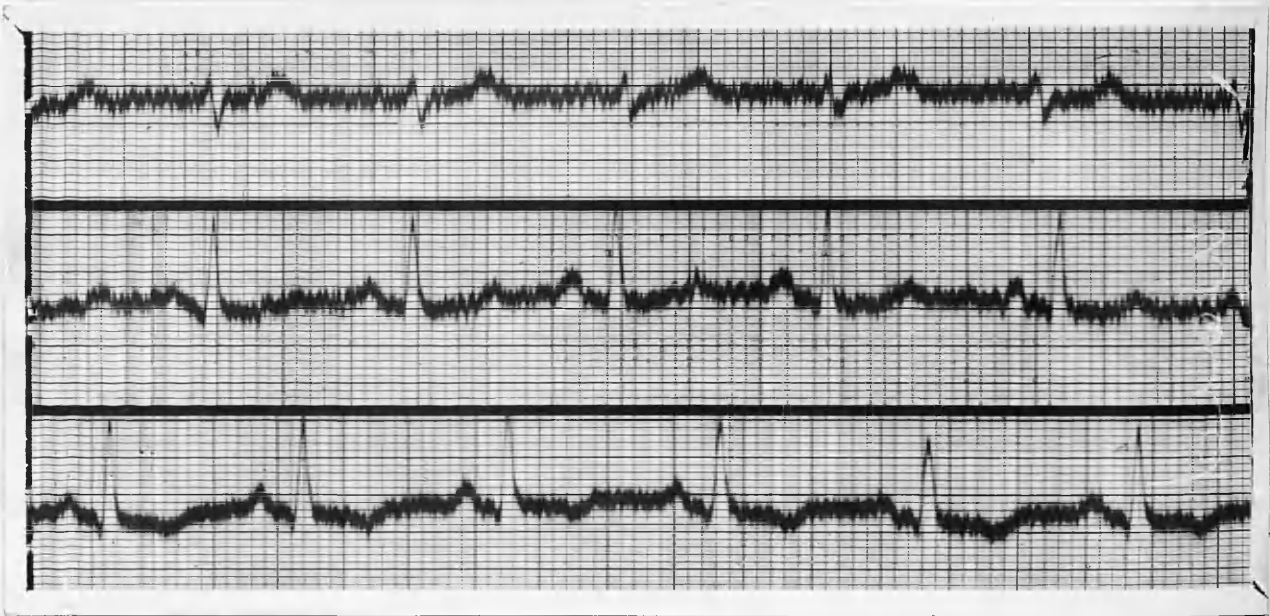
QRS in Lead 3 of lower amplitude and notched.

CASE 20. Miss E. M. W. : aged 34 years.

History of enlarged thyroid since puberty. At 33 she began to experience palpitation and dyspnoea on exertion, and she noticed a further enlargement of her goitre.

Adenoma present in right lobe size of pigeon's egg.

No exophthalmos, but tremor present, and she ^{has} lost weight. Systolic bruit at apex, which is in 5th space. 4" from mid-sternum. Partial thyroidectomy 15/9/1936.



E.C.G. 6/7/1936. (PRE OPERATIVE).

Rate: 102.

Rhythm: Sinus arrhythmia.

P waves: Diphasic in Lead 1; upright and prominent in Lead 2; upright in Lead 3.

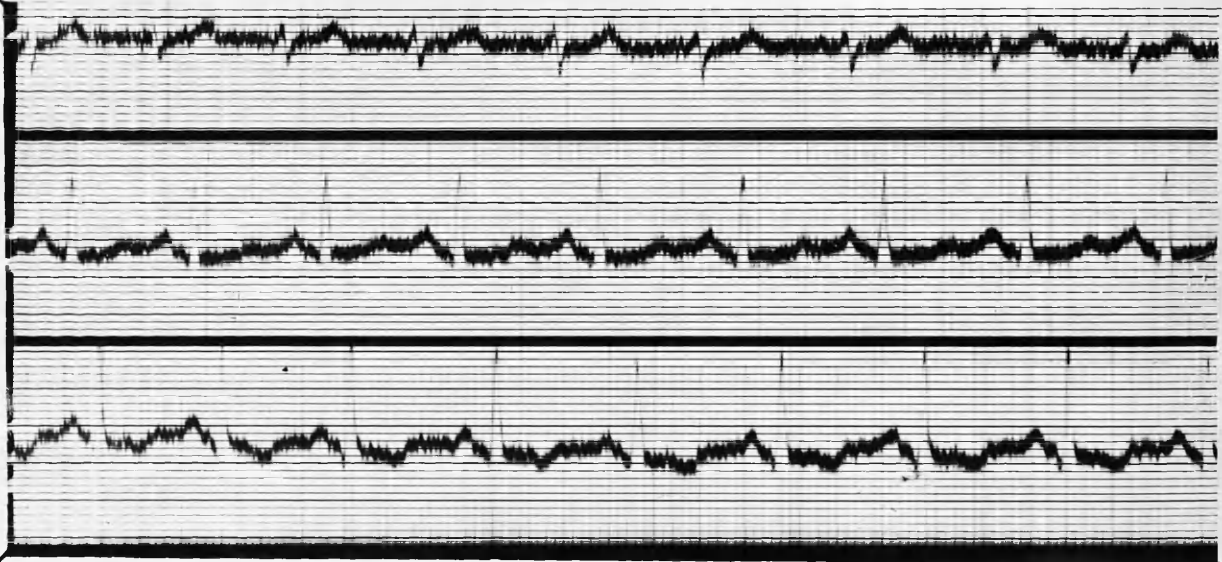
PR Interval: .13 seconds.

QRS Complexes: Directed downwards in Lead 1; upwards in Leads 2 and 3; low voltage in Lead 1.

T waves: Upright and prominent in Lead 1, upright in Lead 2; inverted in Lead 3.

Axis deviation: Right axis deviation.

Summary: Sinus arrhythmia and tachycardia. with right axis deviation.



E.C.G. 18/3/1937. (POST OPERATIVE).

Rate: 100.

Rhythm: Regular sinus rhythm.

P waves: Isoelectric in Lead 1; upright in Leads 2 and 3.

PR interval: .14 seconds.

QRS Complexes: Directed downwards in Lead 1; upwards and of good amplitude in Leads 2 and 3.

T waves: Upright in Leads 1 and 2; inverted in Lead 3.

Axis deviation: Mild right axis deviation.

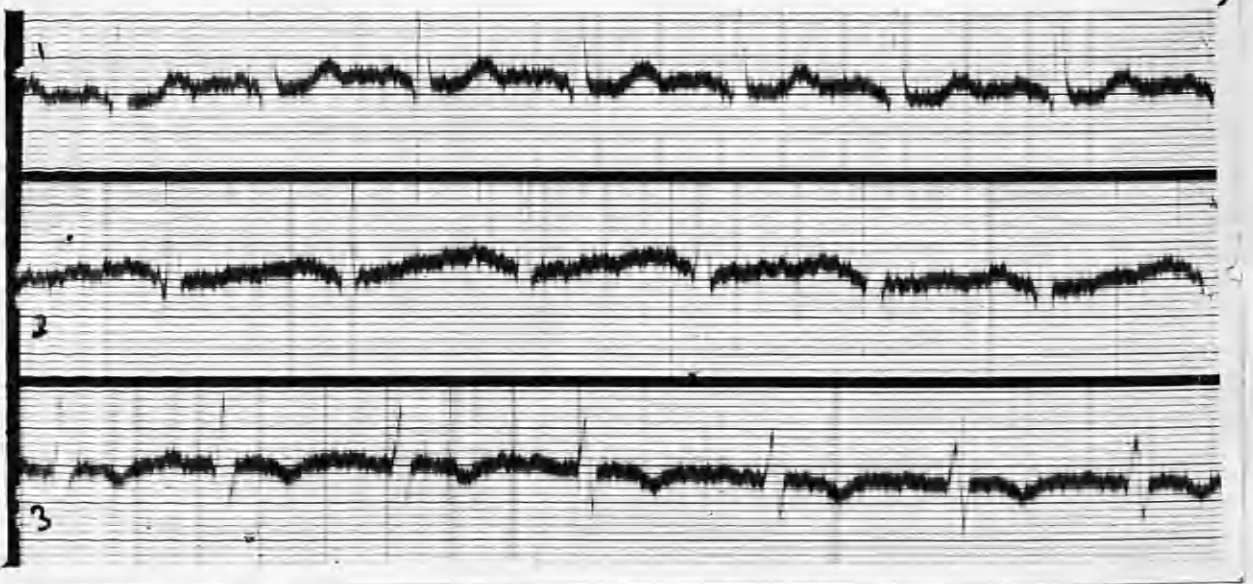
Summary: Sinus tachycardia is still present. There is little change from the pre-operative E.C.G.

CASE 21. Mrs. F. W. : aged 32 years.

Toxic adenoma.

Enlarged thyroid since 15. Recently it has become larger, and now shews toxic symptoms.

Generalised nodular goitre. Sub-total thyroidectomy performed 21/12/1936. *No details re heart, pulse or BP. or B.M.R.*



E.C.G. 10/12/1936.

(PRE-OPERATIVE)

Rate: 108.

Rhythm: Regular sinus rhythm.

P waves: Upright in all Leads.

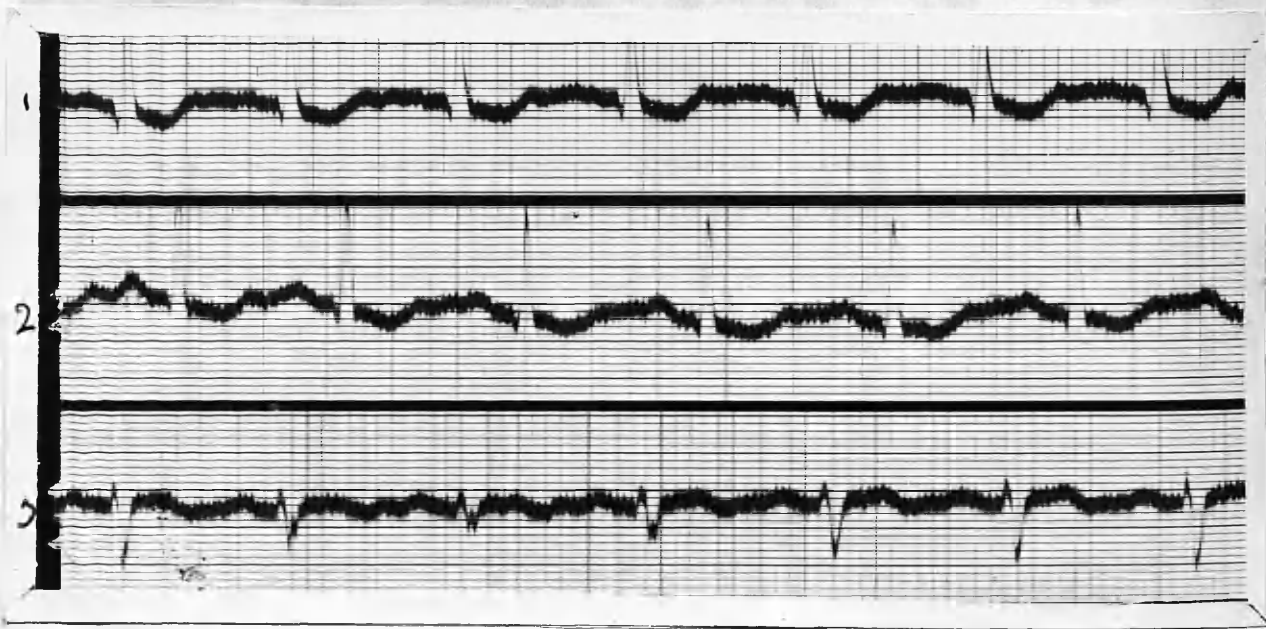
PR interval: .13 seconds.

QRS Complexes: Directed upwards in all Leads.
S prominent in Lead 3.

T waves: Upright and prominent in Lead 1;
inverted in Lead 3.

Axis deviation: Tendency to left deviation.

Summary: Sinus tachycardia; T prominent in Lead 3.



E. C. G. 28/12/1936.

(POST-OPERATIVE).

Rate: 108.

Rhythm: Regular sinus mechanism.

P waves: Upright and of low amplitude in all Leads.

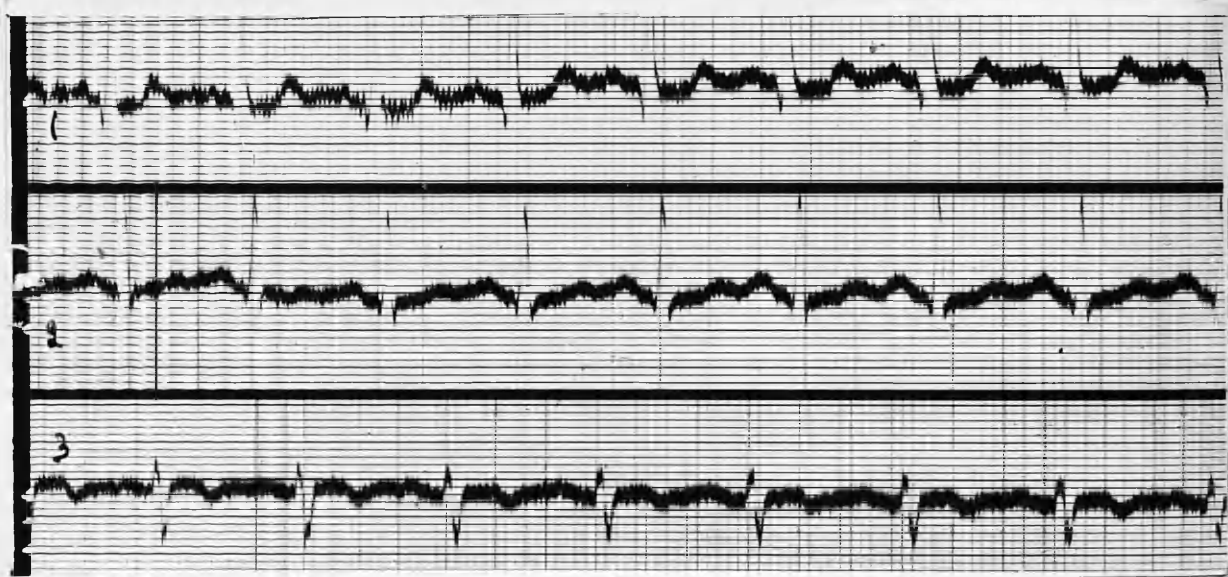
PR interval: .13 seconds.

QRS Complexes: Directed upwards in Leads 1 and 2;
downwards in Lead 3: some notching of
2nd 3rd and 4th complexes in Lead 3.

T waves: RT segment depressed in Leads 1 and 2.
T diphasic in Lead 3.

Axis deviation: Well marked left axis deviation.

Summary: Sinus tachycardia with left axis deviation
T has become depressed in Leads 1 and 2, but
is now diphasic in Lead 3.



E.C.G. 31/3/1937. (POST-OPERATIVE)

Rate: 102.

Rhythm: Regular sinus mechanism.

P waves: Upwards in all Leads.

PR interval: .16 seconds.

QRS Complexes: Directed upwards in Leads 1 and 2, and downwards in Lead 3.

T waves: Upwards and prominent in Lead 1; upwards and flattened in Lead 2; mildly inverted in Lead 3.

Axis deviation: Well marked left preponderance.

Summary: Rate only slightly slower. T.1 more prominent in Lead 2; T.2 now a summit.

CASE 22. Mrs. J. K. : aged 33 years.

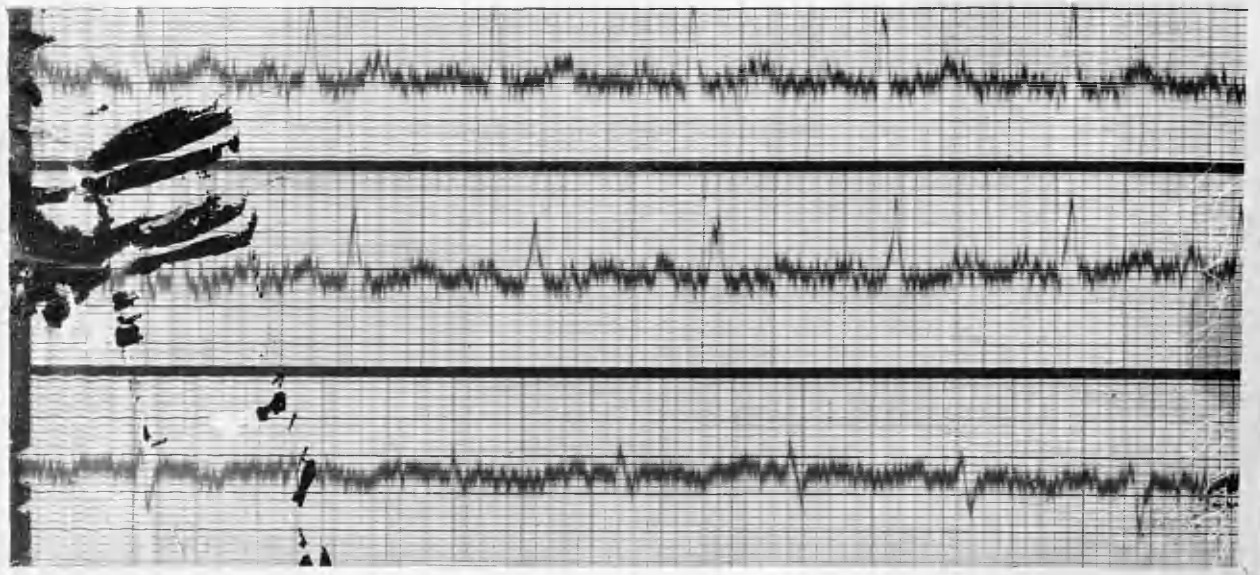
For past nine months has noticed exophthalmos, and increasing nervousness, with attacks of palpitation from time to time. Recently neck has become slightly enlarged. No urinary or menstrual disturbances. No previous illnesses. Slight bilateral enlargement of the thyroid. Eye signs present. Tremor of hands and tongue.

Heart: N.A.D. Has lost weight (about 12 lbs).

Partial thyroidectomy 12/8/1936.

Heart: Apex-beat in 5th space $\frac{1}{2}$ " within mid-clavicular line. 1st. apical sound and Pulmonary 2nd sound +. No murmurs.

B.P. 136/92. B.M.R. +34 per cent.



E.C.G. 9/7/1936. (PRE-OPERATIVE).

Rate: 104.

Rhythm: Regular sinus rhythm.

P waves: Upright in all Leads.

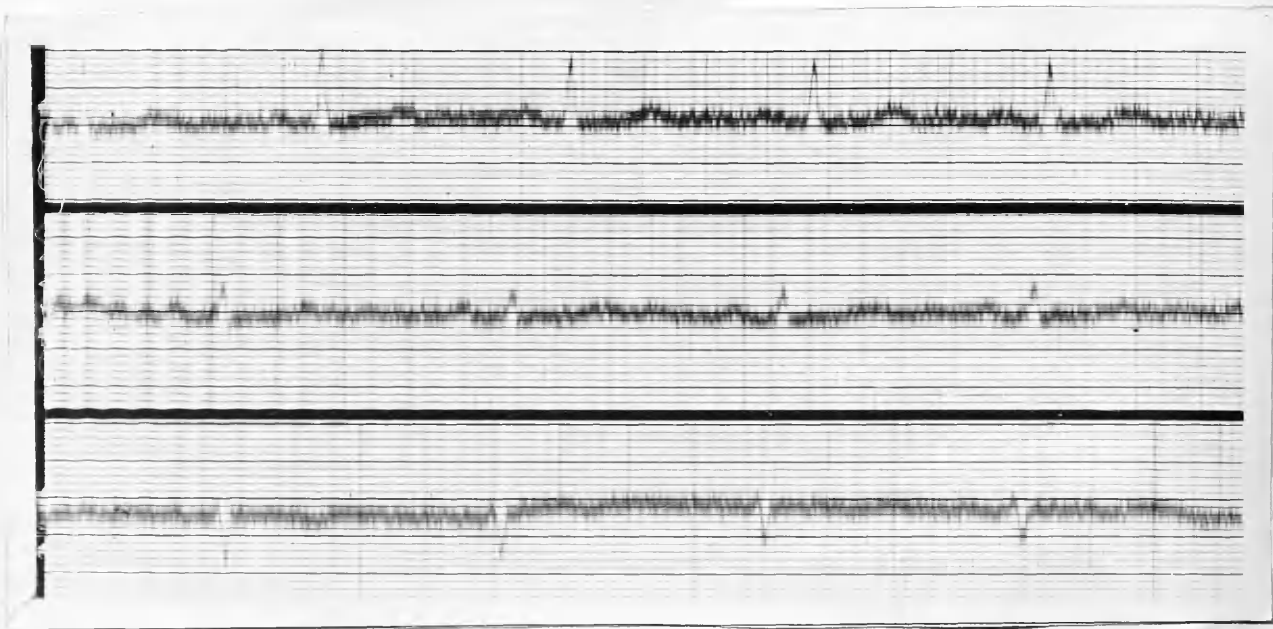
PR interval: .16 seconds.

QRS complexes: Directed upwards in Leads 1 and 2.
Some notching in Leads 1 and 2. Down-
wards in Lead 3.

T waves: Upright and prominent in Lead 1, and
upright also in Lead 2. Mildly inverted
in Lead 3.

Electrical axis: Left deviation.

Summary: Sinus tachycardia, with left axis deviation.
No conduction defects.



E.C.G. 17/12/1936. (POST OPERATIVE)

Rate: 75.

Rhythm: Mild sinus arrhythmia.

P waves: Upright in Leads 1 and 2; isoelectric in
Lead 3.

PR interval: .16 seconds.

QRS complexes: Directed upwards in Leads 1 and 2;
downwards in Lead 3; amplitude less.

T waves: Upright in Leads 1 and 2; mildly
inverted in Lead 3.

Axis : *Left deviation.*

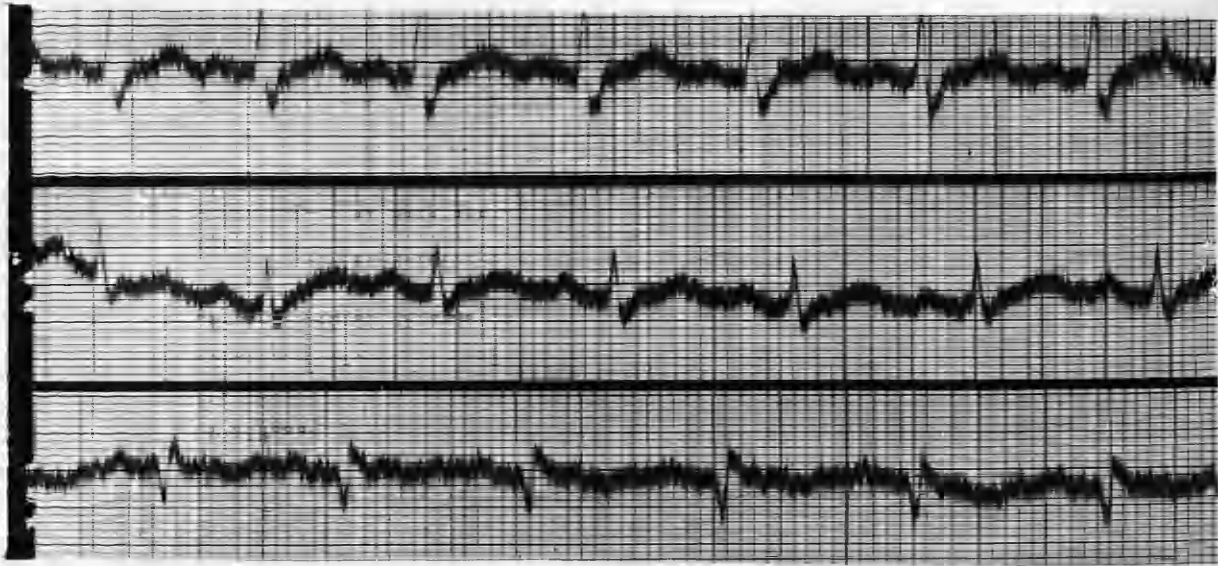
Summary: The rate is now normal, but there is sinus arrhythmia. P 3 is slightly less prominent, and the QRS complexes in Lead 2 are of smaller amplitude. T.2 is more flattened than in the pre-operative E.C.G.

CASE 23. Mrs. C. B. : aged 52 years.

No evidence of thyroid enlargement until two years ago, when she began to complain of increasing languor and general lassitude. Progressive loss of weight and loss of appetite followed. B.P. 150/85. Marked leucodermia all over body - most marked on hands. Obvious loss of flesh; marked tremor; rather pale. Weight; 7 st. 9 lbs. Thyroid now moderately enlarged in both lobes.

Heart: Systolic murmur at base - functional. No clinical evidence of enlargement.

Partial thryoidectomy - 21/4/1937.



E.C.G. 5/9/1936. (PRE-OPERATIVE).

Rate: 108.

Rhythm: Regular sinus rhythm.

P waves: Upright in all Leads.

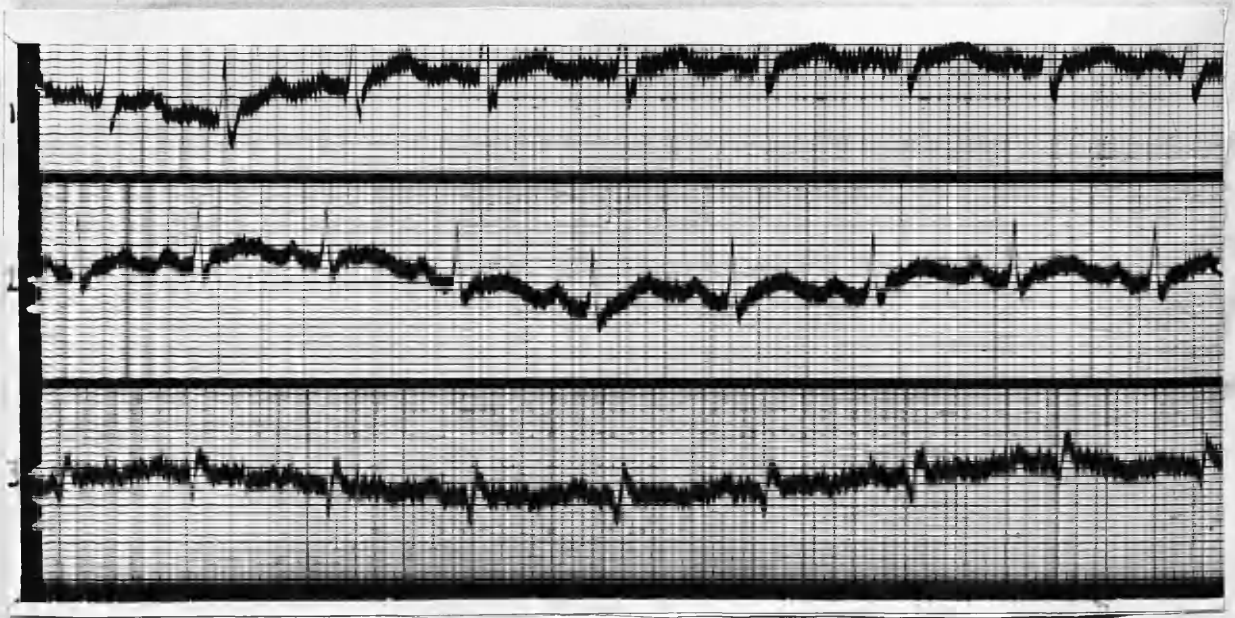
PR interval: .16 seconds.

QRS complexes: Directed upwards in Leads 1 and 2. S.1 prominent and slurred. Directed downwards in Lead 3; slight widening of complexes present

T waves: Upright in Leads 1 and 2; mildly inverted in Lead 3.

Axis: Left deviation.

Summary: Sinus tachycardia with some widening of QRS complexes.



E.C.G. 6/4/1937. (PRE OPERATIVE).

Rate: 100.

Rhythm: Regular sinus rhythm.

P waves: Upright in all Leads.

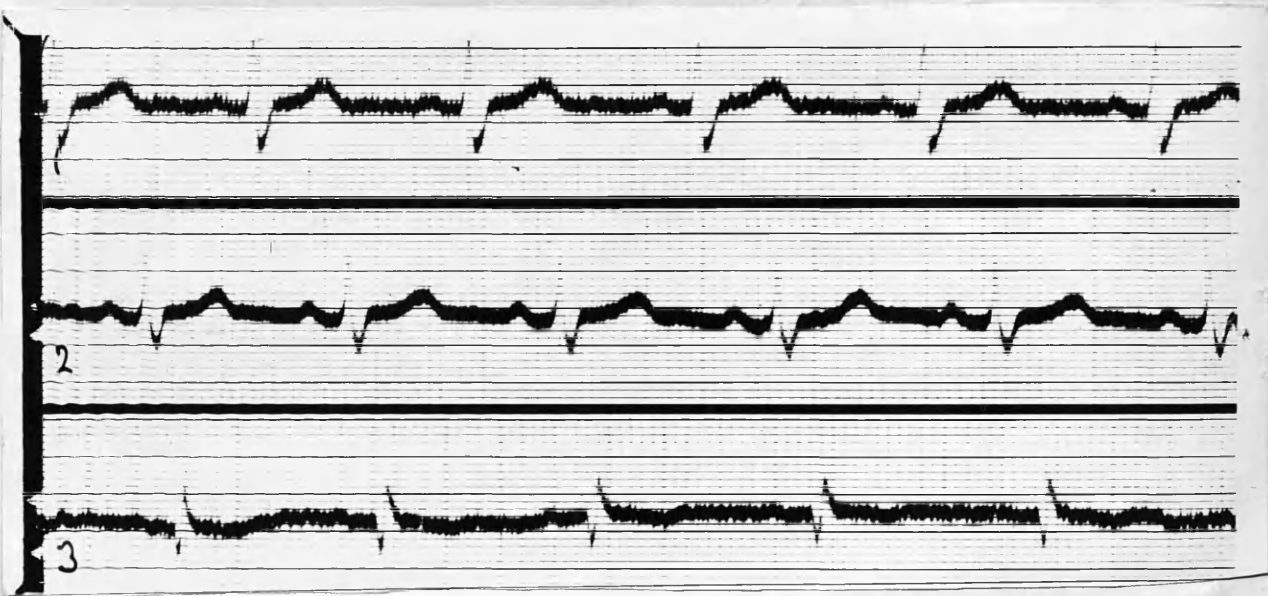
PR interval: .16.

QRS complexes: Directed upwards in Leads 1 and 2,
downwards in Lead 3. S.1 prominent and
notched.

T waves: Upright in Leads 1 and 2; mildly
inverted in Lead 3.

Axis: Tendency to left deviation.

Summary: Sinus tachycardia; mild left axis deviation
No conduction defects.



E.C.G. 7/6/1937. (POST-OPERATIVE)

Rate: 75.

Rhythm: Regular sinus rhythm.

P waves: Upright and of low amplitude in all Leads.

PR interval: .16 seconds.

QRS complexes: Directed upwards in all Leads. S.1 and
2 deep and slurred. Widened QRS complexes.

R in Lead 3 is now more pronounced.

T waves: Upright in Leads 1 and 2; mildly inverted in Lead 3.

Axis: Normal deviation.

Summary: Regular sinus rhythm. The mild left axis deviation has now reverted to normal since operation. Rate much slower. Marked clinical improvement. (weight 8 st. 10 lbs).

CASE 24. Mrs. M. J. : aged 26 years.

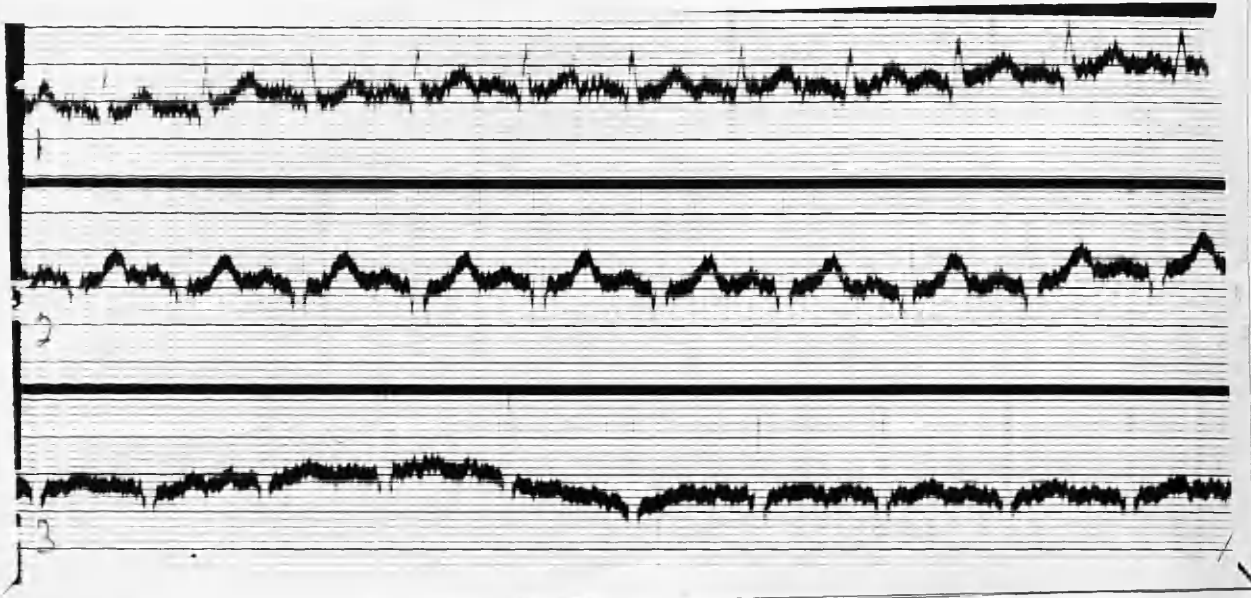
Dyspepsia for about three years, which was attributed following X-Ray examination two months ago to visceroptosis. About 7 - 8 weeks ago noticed some enlargement of her neck accompanied by dyspnoea and moist skin. Always very nervous, and more so recently. Tremor + . No menses during past nine weeks.

Family History: Sister had thyroidectomy for goitre two years ago. One aunt died of thyrotoxicosis.

Mild degree of exophthalmos present, with slight sagging of upper lids.

P.R. 116. B.P. 135/75. Thyroid slightly increased in size bilaterally. Nil abnormal in heart.

Operation: 23/6/1937.



E.C.G. 27/5/1937. (PRE-OPERATIVE)

Rate: 144.

Rhythm: Regular sinus rhythm; no resting period.

P waves: Upwards in all Leads.

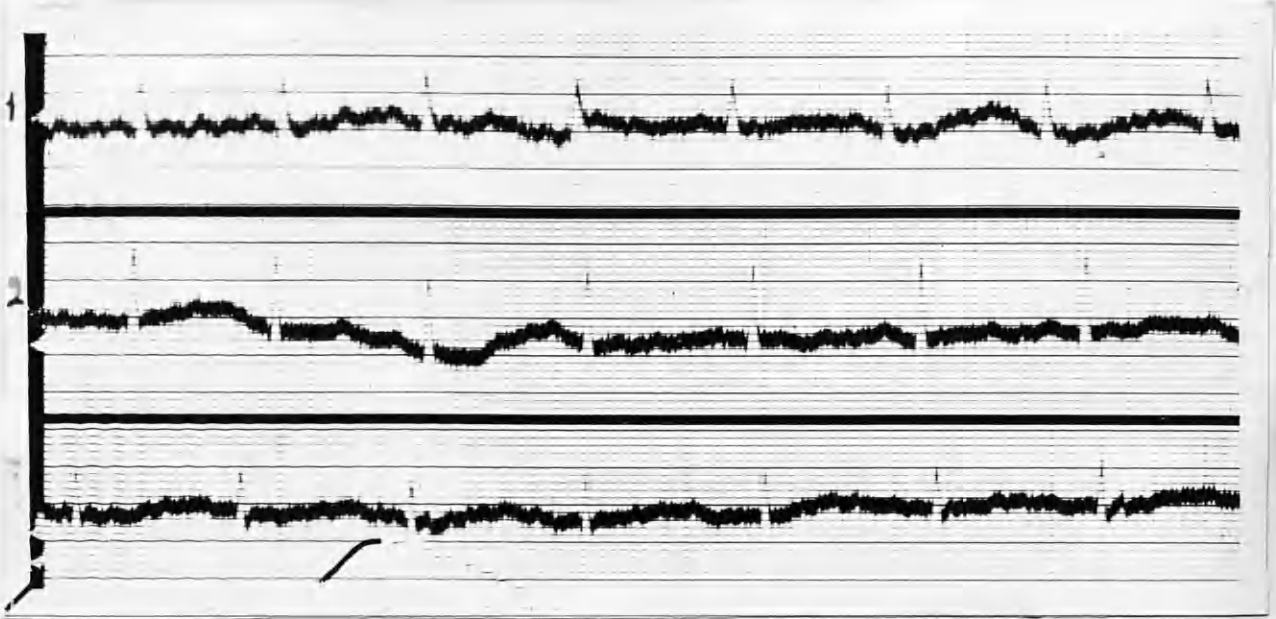
PR Interval: .12 seconds.

QRS complexes: Directed upwards and of good amplitude in all Leads.

T waves: Very prominent in Leads 1 and 2; less prominent in Lead 3.

Axis: Normal.

Summary: Sinus tachycardia; no conduction defects. Prominent T.1 and T.2.



E.C.G. 26/7/1937. (POST-OPERATIVE).

Rate: 96.

Rhythm: Regular sinus rhythm.

P waves: Upwards in all Leads.

PR interval: .14 seconds.

QRS complexes: Directed upwards in all Leads.

T waves: RT interval shows a depression in all Leads.

Axis: Normal.

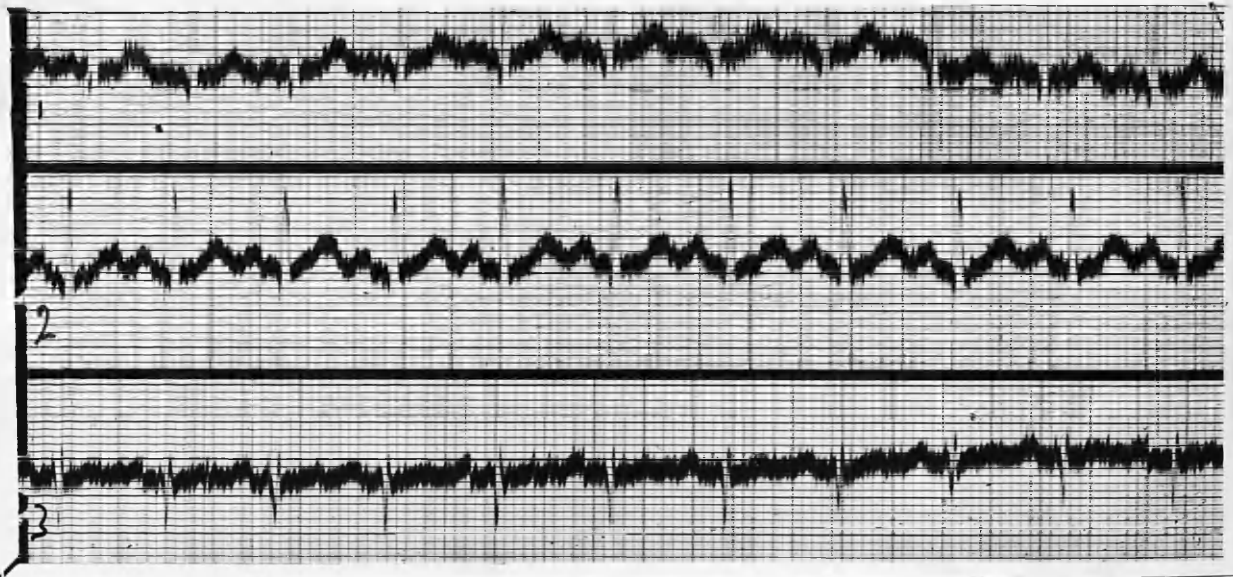
Summary: Rate much slower than in pre-operative E.C.G., and the T waves are now more flattened. QRS SHOWS LESSENED AMPLITUDE in Leads 2 and 3.

CASE 25. Mrs. G. H. : aged 49 years.

History of goitre for 15 years; recently toxic symptoms have arisen. Toxic adenoma.

Apex-beat in 6th space 4" from mid-sternum.

Operation: 15/10/1937.



E.C.G. 2/9/1937. (PRE-OPERATIVE).

Rate: 140.

Rhythm: Regular sinus rhythm; no rest time.

P waves: Upright in all Leads.

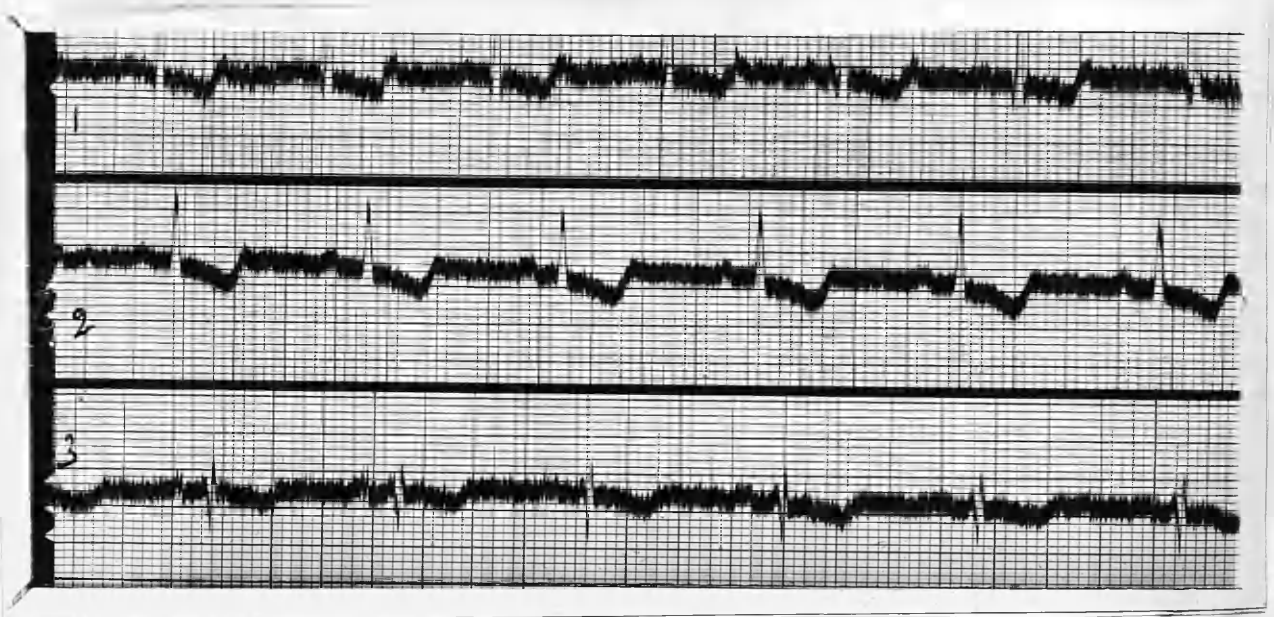
PR interval: .12 seconds.

QRS complexes: Directed upwards in Leads 1 and 2;
downwards in Lead 3.

T waves: Upright in all Leads.

Electric axis: Left deviation.

Summary: Sinus tachycardia with left axis deviation.



E.C.G. 25/10/1937. (POST-OPERATIVE)

Rate: 72.

Rhythm: Regular sinus rhythm.

P waves: Upright in all Leads.

PR interval: .12 seconds.

QRS Complexes: Directed upwards in Leads 1 and 2;
downwards in Lead 3.

T waves: RT interval is depressed in all Leads.
Digitalis effect.

Electric Axis: Left deviation.

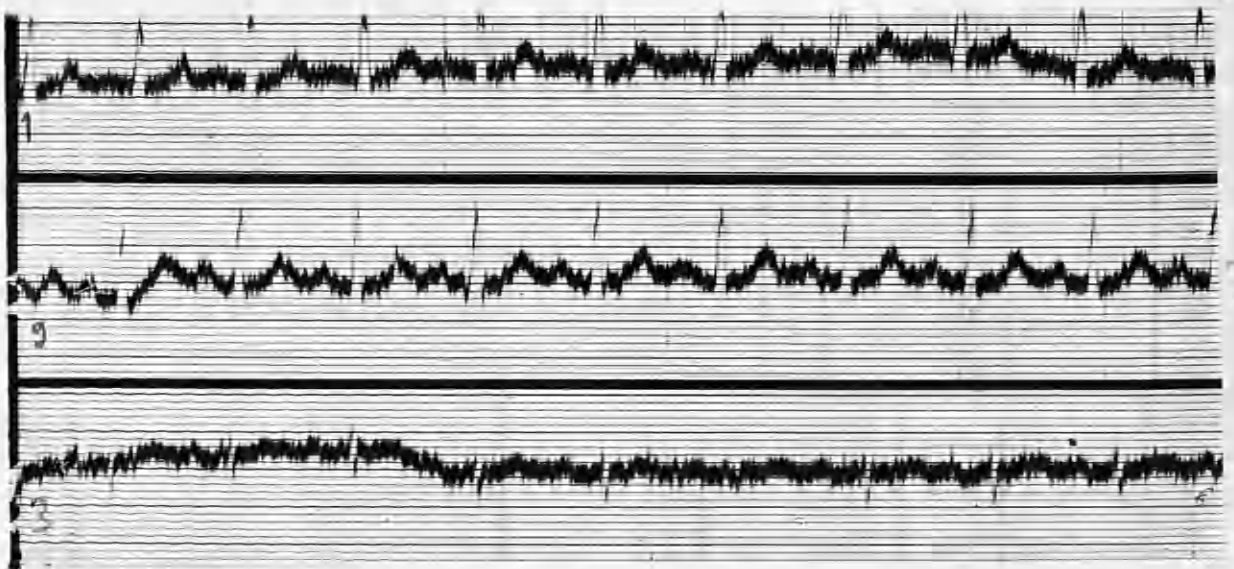
Summary: Rate is now normal; P waves show a definite lowering in amplitude in Lead 2. RT interval depression is now present, the result of intensive digitalisation before operation.

CASE 26. Mrs. M. A. K. : aged 43 years.

Six years' history of thyroid enlargement. Some months ago toxic symptoms arose, and she has now marked exophthalmos and tremor. There is a soft bilateral enlargement of the thyroid and isthmus.

Apart from accentuation of 1st mitral sound, heart is normal.

Operation: 7/6/1937.



E.C.G. 22/4/1937. (PRE-OPERATIVE).

Rate: 124.

Rhythm: Regular sinus rhythm.

P waves: Upright in Lead 2; unidentifiable in Leads 1 and 3.

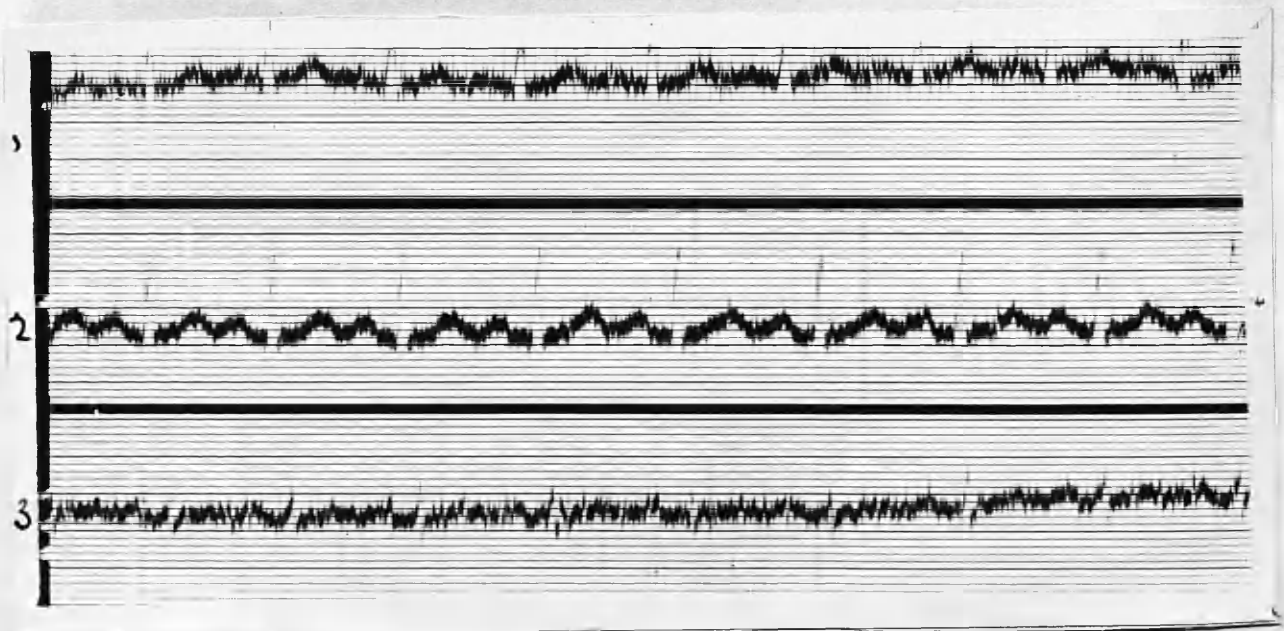
PR Interval: .14 seconds.

QRS Complexes: Directed upwards in all Leads. Amplitude low in Lead 2.

T waves: Upright in Leads 1 and 2; diphasic Lead 3.

Axis: Normal.

Summary: Sinus tachycardia; no resting time. Low voltage QRS in Lead 3.



E.C.G. 2/9/1937. (POST-OPERATIVE)

Rate: 124.

Rhythm: Regular sinus rhythm.

P waves: Upright in all Leads.

PR interval: .16 seconds.

QRS Complexes: Upright in Leads 1 and 2; S.3
Directed downwards.

T waves: Upright in all Leads.

Axis: Tendency to left deviation.

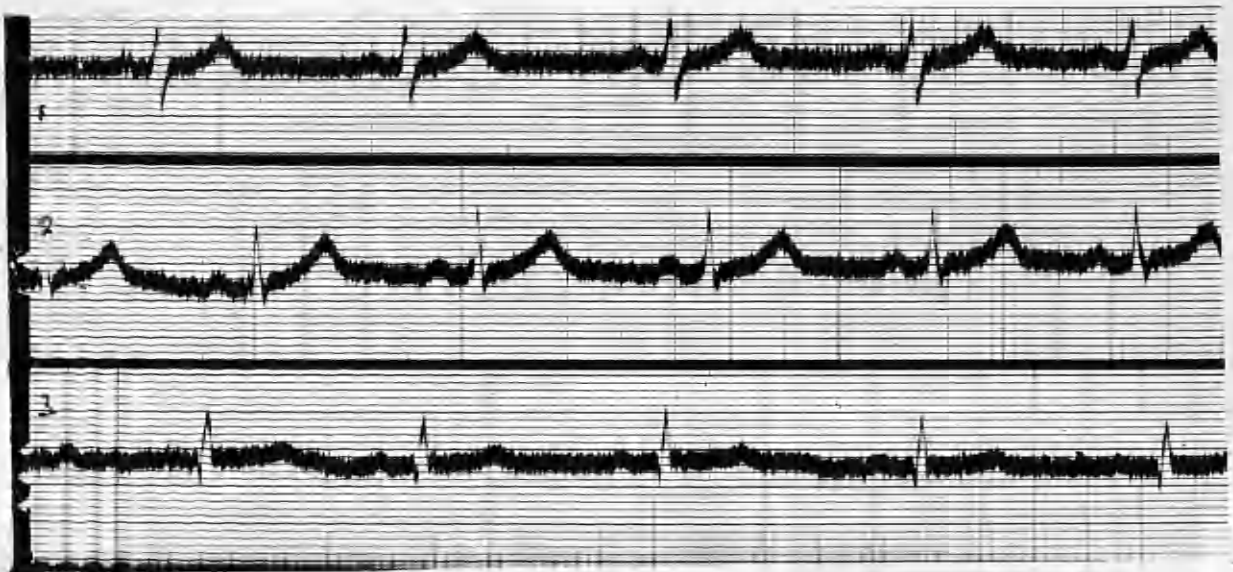Summary: Rate still rapid; there is now a tendency
to left deviation.

CASE 27. R. B. : aged 17.

Thyroid has been enlarged for several years, but has increased considerably in size during past six months. Now has gross diffuse colloid goitre with pressure symptoms:-
dysphagia. dyspnoea. and stridor.

Heart normal; fine tremor of hands noticeable.

Operation: 1/9/1937.



E.C.G. 12/8/1937. (PRE-OPERATIVE)

Rate: 68.

Rhythm: Regular sinus rhythm.

P waves: Upright in all Leads.

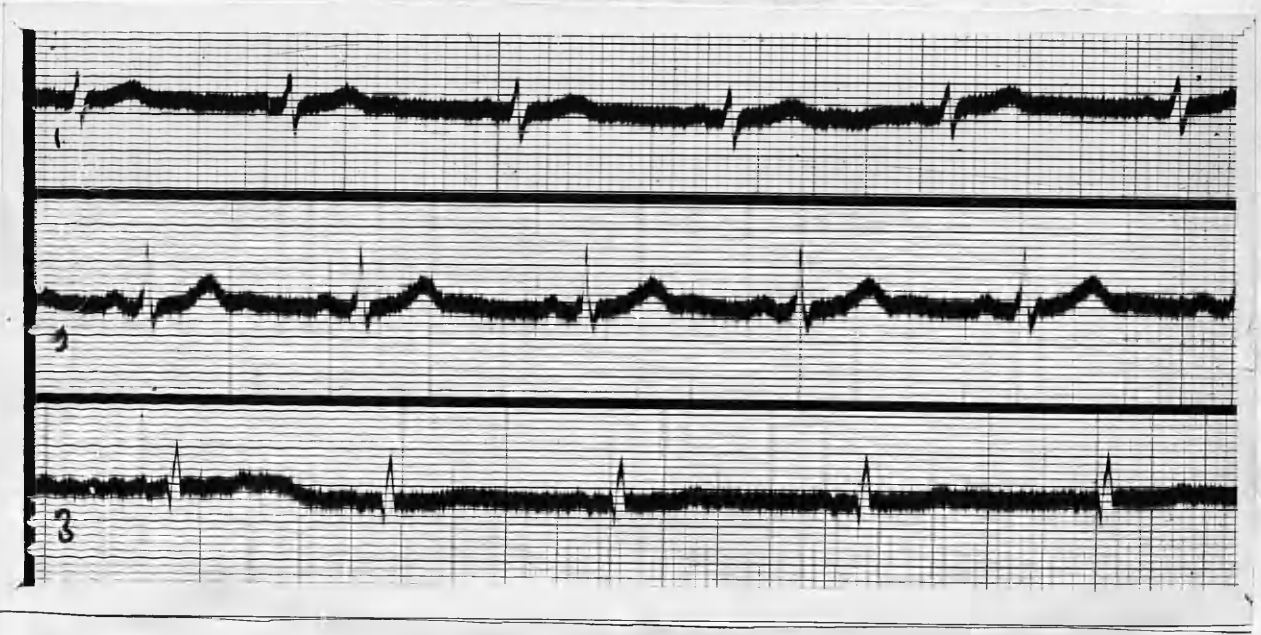
PR interval: .14 seconds.

QRS complexes: Upright in all Leads. S.1 prominent

T waves: Prominent in Leads 1 and 2.

Axis: Tendency to right deviation.

Summary: T.1 and T.2. prominent. Rate slow.



E.C.G. 7/10/1937. (POST-OPERATIVE).

Rate: 70.

Rhythm: Regular sinus rhythm.

P waves: Upright in all Leads.

PR interval: .14 seconds.

QRS complexes: Upright in all Leads; S.1
slightly less prominent.

T waves: Much less prominent in Lead 1, and slightly
less prominent in Lead 2.

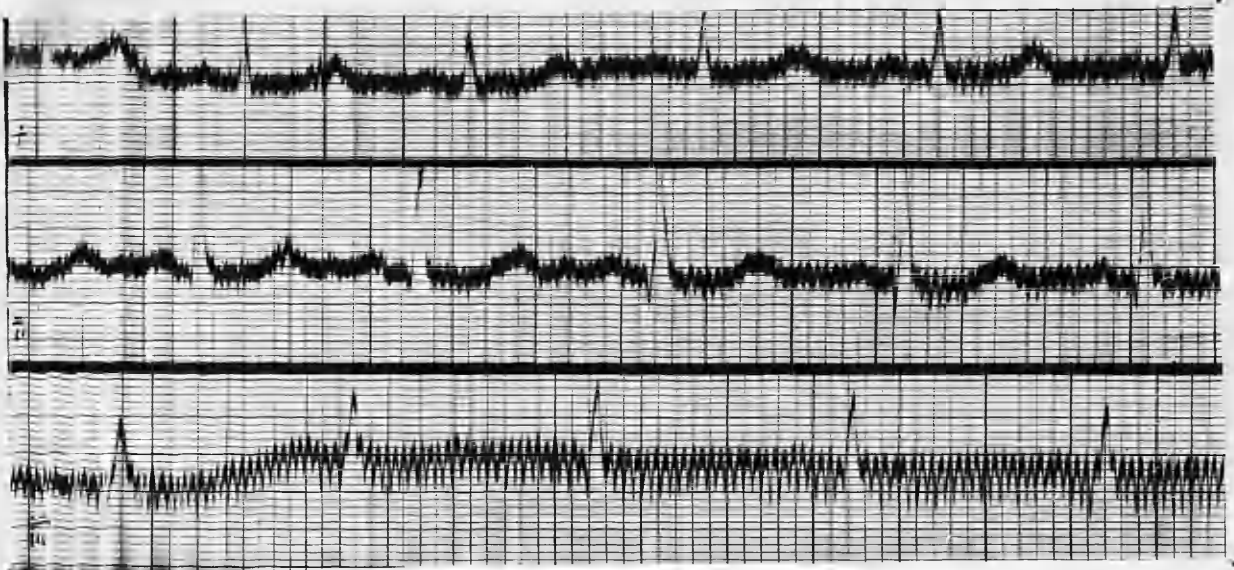Axis: Tendency to right deviation.

Summary: There is less prominence of the T waves in
Leads 1 and 2, and S.1 is not so deep.

CASE 28. Miss C. E. : aged 41 years.

Health was good until twelve months ago, when she
first noticed enlargement of the neck, and palpitation
She has lost weight and energy, and exophthalmos is now
present.

Partial thyroidectomy was performed on August 4th, 1938.



E.C.G. 17/7/1938. (PRE OPERATIVE).

Rate: 104.

Rhythm: Regular sinus rhythm.

P waves: Upright and normal in Leads 1 and 2;
unrecognisable in Lead 3 through somatic tremor.

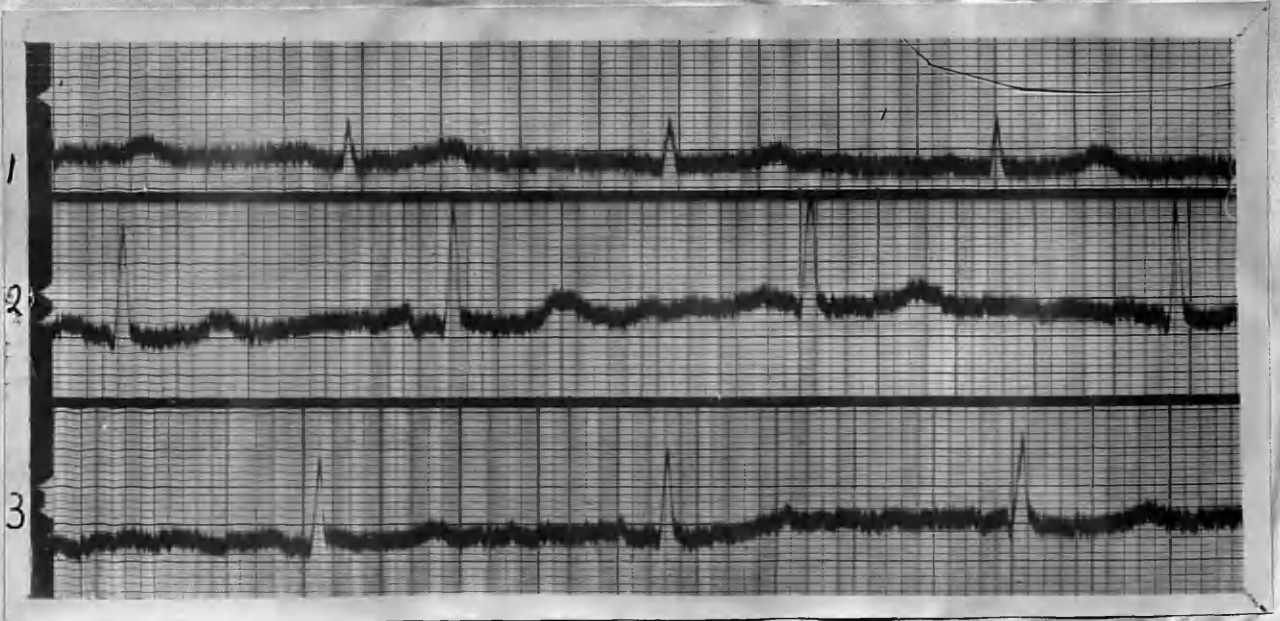
PR interval: .12 seconds.

Axis deviation: Normal.

QRS complexes: Normal.

T waves: Upright and of normal size in Leads 1 and 2;
not recognisable in Lead 3.

Summary: Sinus tachycardia, with normal axis deviation
and normal P & T waves in Leads 1 and 2.



E.C.G. 6/11/40. (POST-OPERATIVE).

Rate: 64.

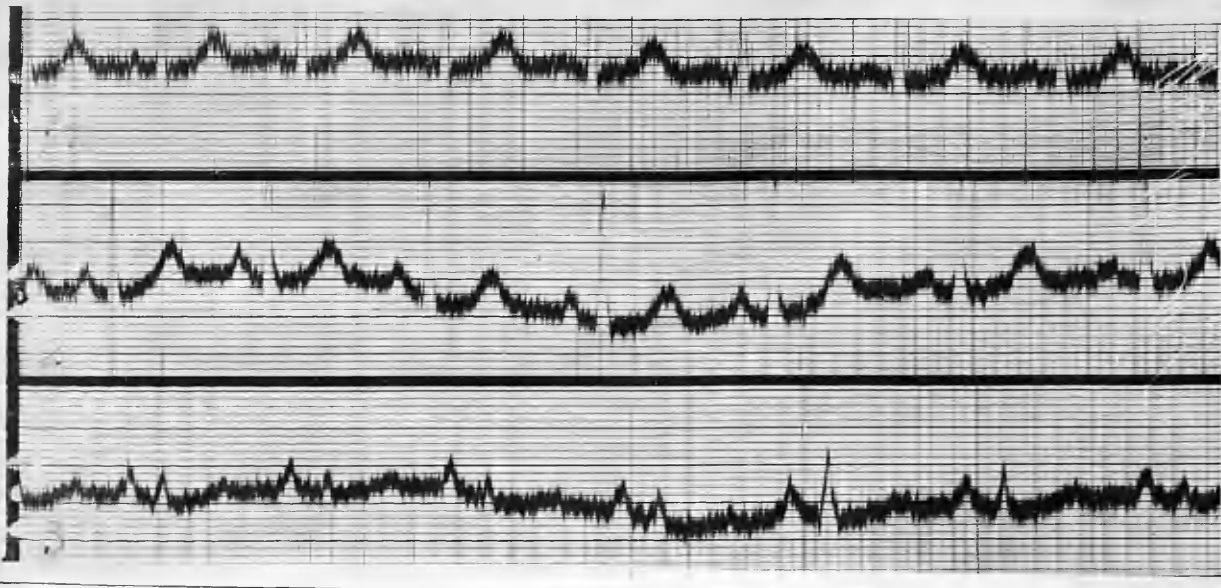
Rhythm: Regular sinus rhythm.

P waves: flattened in all Leads.

PR interval: .10 seconds.
Axis deviation: Normal.
QRS complexes: Normal.
T waves: Normal summits in all Leads.
Summary: The rate is much slower than before operation. but there is little other change.

CASE 29. Mrs. M. G. aged 55 years.

Her thyroid has been enlarged since a pregnancy at 30, but it gave her no trouble till two years ago. when she began to suffer from dyspnoea and palpitation. Of recent months excessive perspiration and lassitude have developed. A slight adenoma is palpable in the enlarged left lobe. Partial thyroidectomy was carried out on 19th January 1939.



E.C.G. 6/1/1939. (PRE-OPERATIVE)

Rate: 100.

Rhythm: Regular sinus rhythm.

P waves: Markedly prominent in Lead 3.

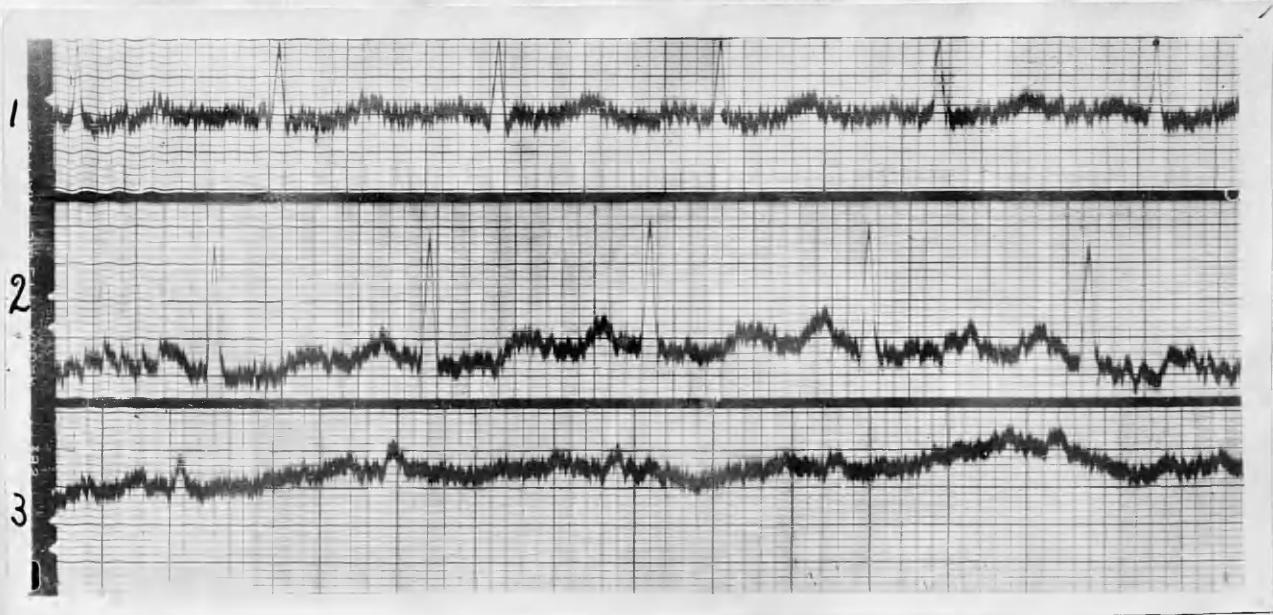
PR interval: .14 seconds.

Axis deviation: Normal.

QRS complexes: Voltage rather low in Lead 3.

T waves: Large and broad in Leads 1 and 2.

Summary: Sinus tachycardia with prominent P waves in Lead 3, and prominent T waves in Leads 1 and 2.



E.C.G. 6/11/40. (POST-OPERATIVE).

Rate: 100.

Rhythm: Regular sinus rhythm.

P waves: Less prominent in Lead 3.

PR interval: .12 seconds.

Axis deviation: Normal.

QRS complexes: Broadened and notched and of low amplitude in Lead 3.

T waves: Less prominent in Leads 1 and 2.

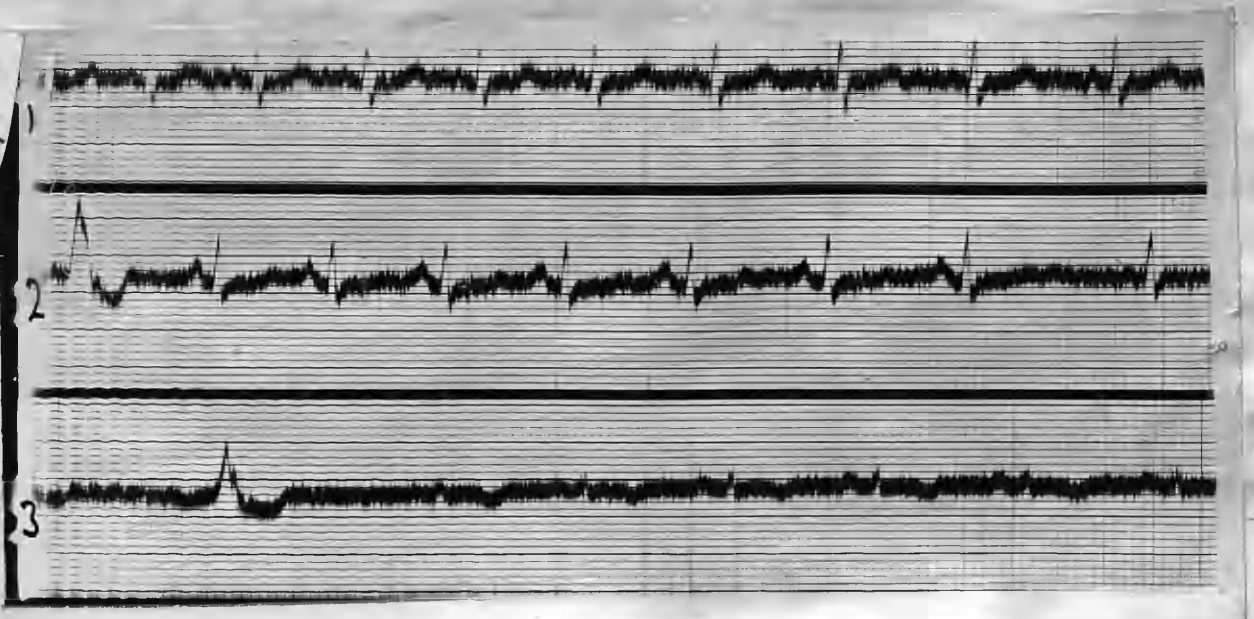
Summary: The rate is still rapid, but there is less prominence of P and T waves. There is increased deformity of the QRS complexes in Lead 3.

T waves: Upright in Leads 1 and 2; inverted in Lead 3.

Summary: Sinus tachycardia with ventricular extrasystoles.

CASE 30. Mrs. I. G. : aged 39 years.

Three months history of enlargement of the thyroid with palpitation, tremor, exophthalmos, and loss of weight. Heart negative. Resting P.R. 132. B.P. 180/85. Subtotal thyroidectomy performed on March 16th, 1938.



E.C.G. 21/12/37. (PRE-OPERATIVE)

Rate: 100.

Rhythm: Sinus rhythm with a ventricular extra-systole in Lead 2 and Lead 3.

P waves: Normal.

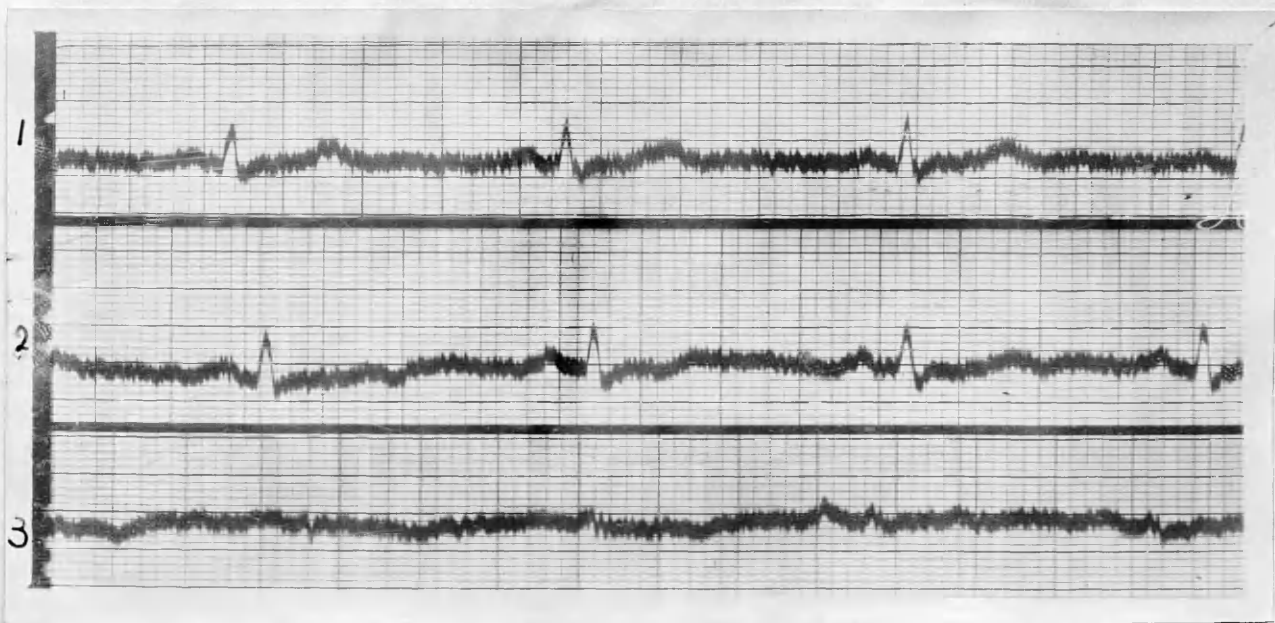
PR interval: .12 seconds.

Axis deviation: Normal.

QRS complexes: Low voltage in Lead 3.

T waves: Upright in Leads 1 and 2; inverted in Lead 3.

Summary: Sinus tachycardia with ventricular extra-systoles.



E.C.G. 6/11/40. (POST-OPERATIVE).

Rate: 75.

Rhythm: Regular sinus rhythm.

P waves: Normal.

PR interval: .12 seconds.

Axis deviation: Normal.

QRS complexes: Low voltage in Lead 3.

T waves: Upright in Leads 1 and 2; isoelectric
Lead 3.

Summary: Rate is now normal, and there are no
extra-systoles. QRS complexes in Lead 3
are unchanged.

QRS complexes: Normal.

T waves: Upright in Leads 1 and 2; inverted in Lead 3.

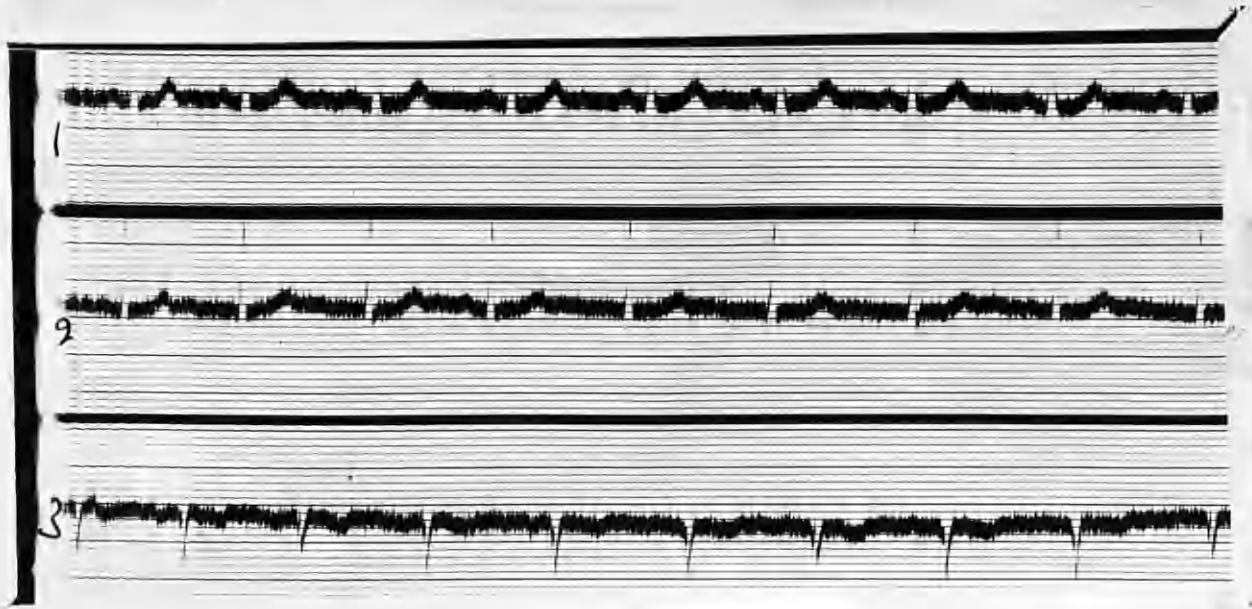
Summary: Sinus tachycardia and left axis deviation.

CASE 31. Mrs. A.F. aged 33 years.

Thyroid became enlarged when she was 21, but no toxic symptoms arose till several weeks ago. Palpitation and dyspnoea are troublesome and she has lost weight. There is bilateral enlargement of the thyroid, with a small nodule in each lobe.

Mitral 1st. sound is sharp and accentuated.

Operation was carried out on April 25th. 1938.



E.C.G. 17/3/38. (PRE-OPERATIVE)

Rate: 86.

Rhythm: Regular sinus rhythm.

P waves: Flattened in all Leads.

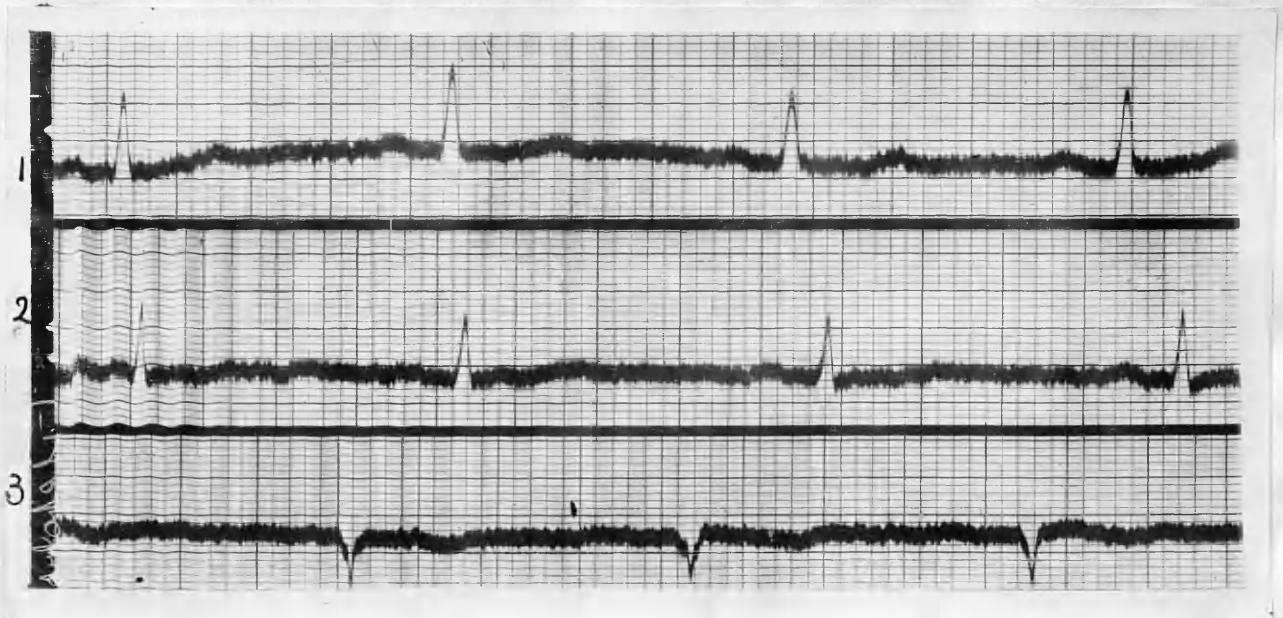PR interval: .12 seconds.

Axis deviation: Marked left axis deviation.

QRS complexes: Normal.

T waves: Upright in Leads 1 and 2; inverted in Lead 3.

Summary: Sinus tachycardia, and left axis deviation.



E.C.G. 6/11/40. (POST-OPERATIVE).

Rate: 70.

Rhythm: Regular sinus rhythm.

P waves: Flattened in all Leads.

PR interval: .14 seconds.

Axis deviation: Left deviation.

QRS complexes: Normal.

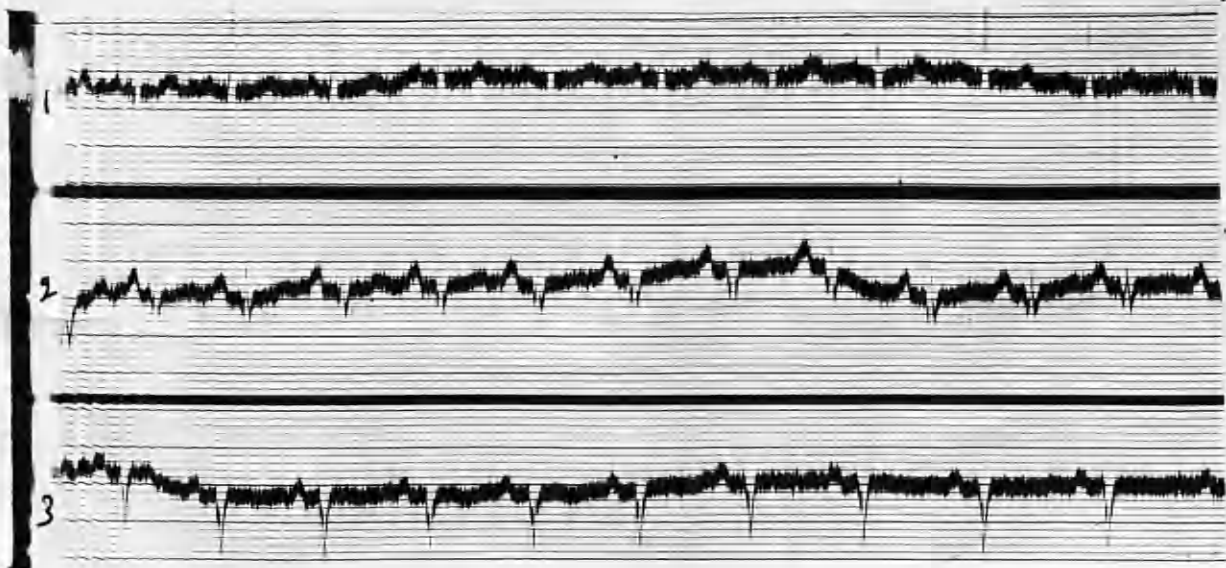
T waves: Less prominent in Lead 1 and Lead 2.

Summary: The rate is now normal, and the left axis deviation persists, but T waves in Leads 1 and 2 are less prominent.

CASE 32. Mrs. E. P. : aged 28 years.

Since puberty at 14 her thyroid has been enlarged. The enlargement increased three months ago, with an accompanying loss of weight and strength. Palpitation and tremor are present. In the isthmus of the thyroid there is a small round nodule, and the left lobe is markedly enlarged.

Partial thyroidectomy was carried out on February 23rd. 1938.



E.C.G. 15/2/1938. (PRE-OPERATIVE).

Rate: 100.

Rhythm: Regular sinus rhythm.

P waves: Upright all Leads, and prominent in Lead 2.

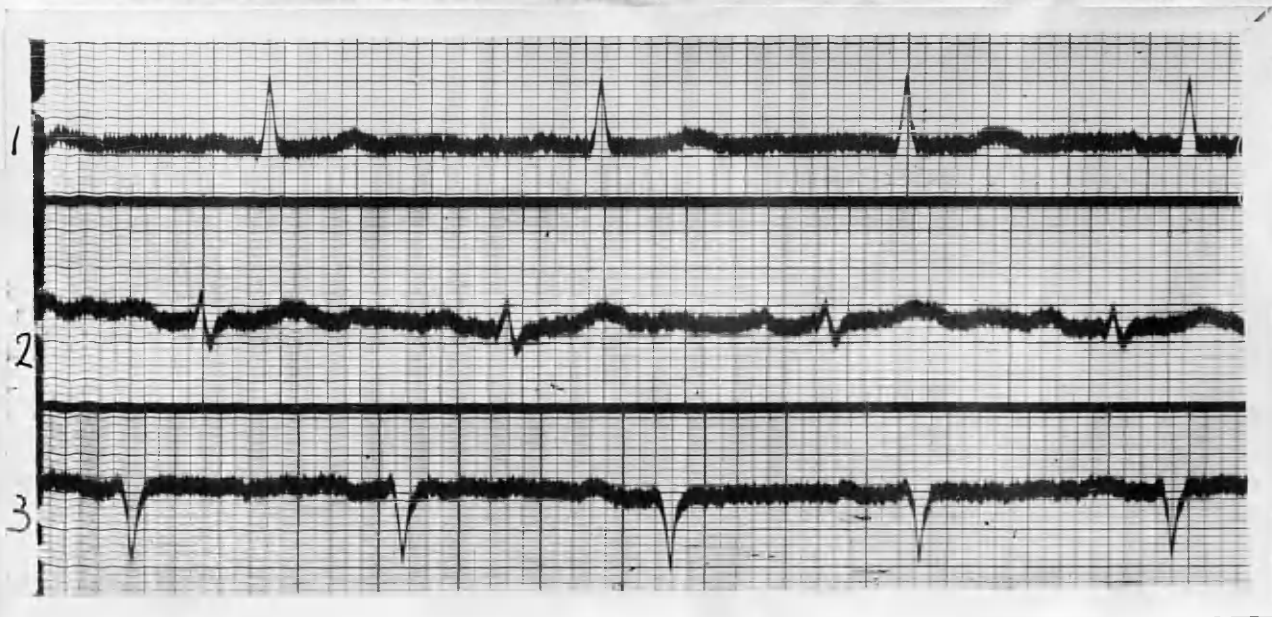PR interval: .12 seconds.

Axis deviation: Marked left axis deviation.

QRS complexes: Normal.

T waves: Isoelectric in Lead 3.

Summary: Sinus tachycardia, and marked left axis deviation. Prominent P.2.



E.C.G. 6/11/40. (POST-OPERATIVE).

Rate: 76.

2 Strains Rhythm: Mild axis arrhythmia.

P waves: Flat in Leads 1 and 3, and of lowered amplitude in Lead 2.

PR interval: .14 seconds.

Axis deviation: Marked left axis deviation.

QRS Complexes: Normal.

T waves: Isoelectric Lead 3.

Summary: The rate is now normal, and there is sinus arrhythmia. P.2. is of lower amplitude.

CASE 33. Mrs. M. W. : aged 49 years.

The thyroid first enlarged 6 months ago, and now is large enough to cause dysphagia .

She has lost thirty pounds in weight, and has severe dyspnoea on exertion and palpitation even when resting.

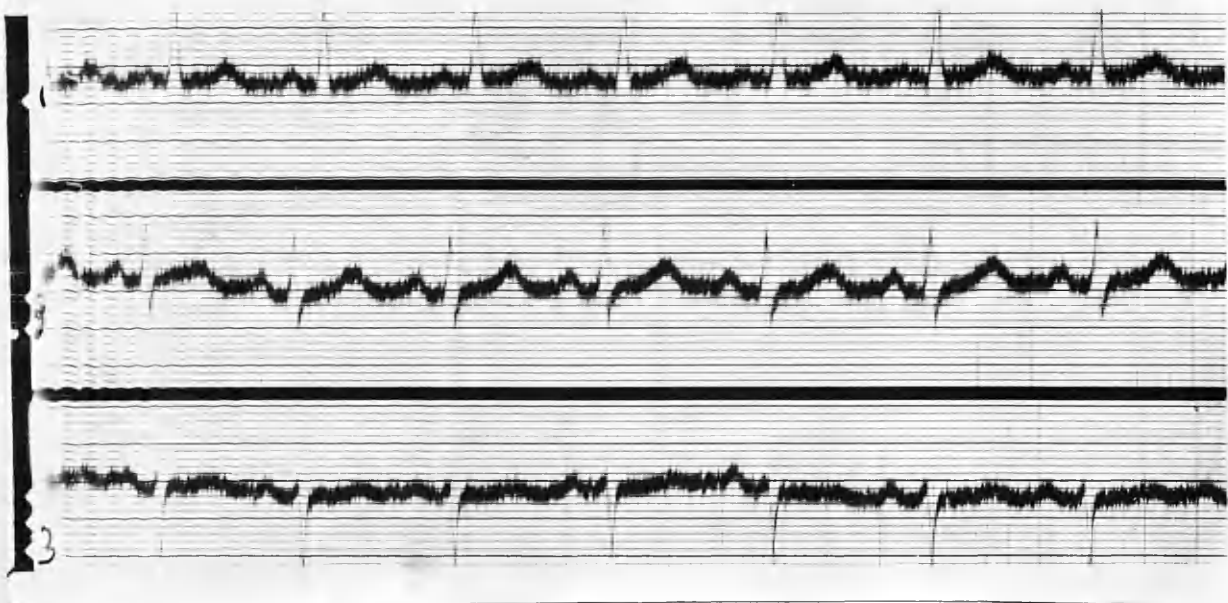
There is slight prominence of the eyes.

There is a generalised fullness of the isthmus and of the lower poles of the lobes.

Resting P.R. is 85. B.P. 144/88.

The cardiac sounds are pure and forcible. The Aortic 2nd sound is accentuated.

Partial thyroidectomy was performed on Jan. 14th 1938.



E.C.G. 2/12/1937. (PRE-OPERATIVE).

Rate: 96.

Rhythm: Regular sinus rhythm.

P waves: Normal.

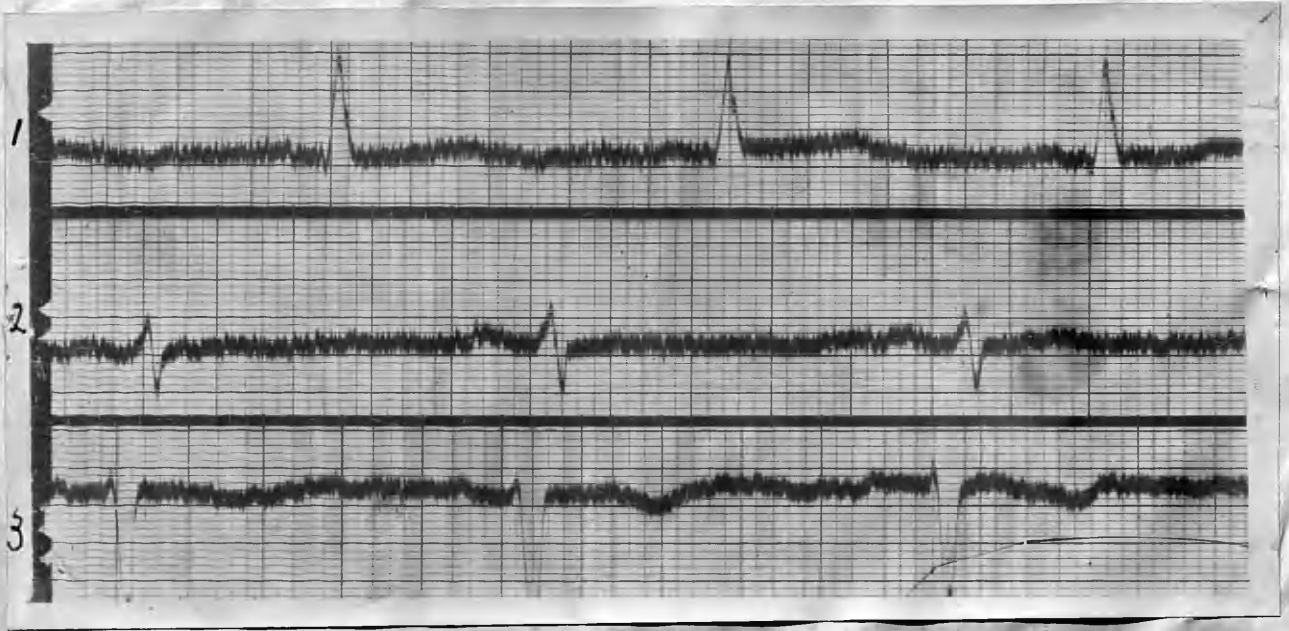PR interval: .14 seconds.

Axis deviation: Marked left axis deviation.

QRS complexes: Normal.

T waves: Upright in all Leads.

Summary: Sinus tachycardia, and left ventricular preponderance.



E.C.G. 6/11/40. (POST-OPERATIVE).

Rate: 62.

Rhythm: Regular sinus rhythm.

P waves: Flat in all Leads.

PR interval: .14 seconds.

Axis deviation: Marked left axis deviation.

QRS Complexes: Slightly widened in all Leads, and downstroke of R, notched.

T waves: Considerably less prominent in Lead 1 and Lead 2, now inverted in Lead 3.

Summary: The rate is now slow, and T waves are lowered in amplitude in all Leads. There is now some delay in conduction in the QRS complexes.

Rate: 62

QRS complexes: Slightly widened in all Leads, and downstroke of R, notched.

T waves: Considerably less prominent in Lead 1 and Lead 2, now inverted in Lead 3.

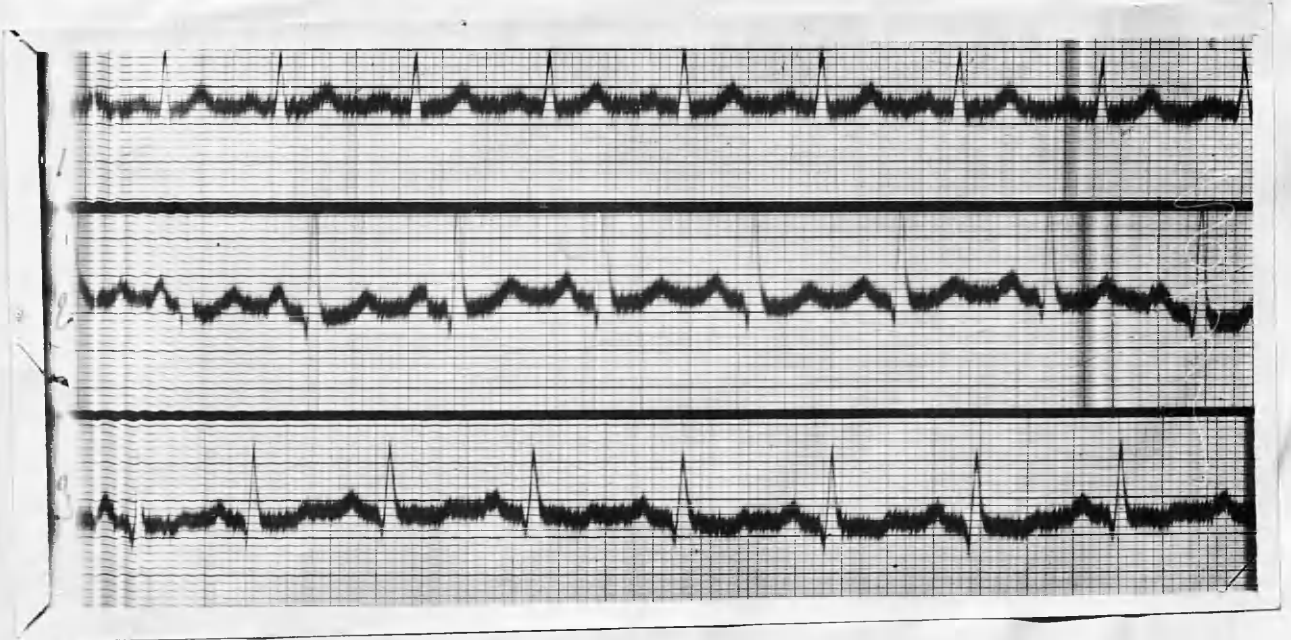
CASE 34. MRS. E. A. : aged 46 years.

History of palpitation, tremor and loss of weight since a shock 4 months ago.

There is now well-marked exophthalmos, with
^{and.}
Mobius, Van Graefe signs present.

Soft bilateral enlargement of both lobes of thyroid.

Systolic murmur at apex. conducted towards the base.



E.C.G. 25/10/1939. (PRE-OPERATIVE)

Rate: 96.

Rhythm: Regular sinus rhythm.

P waves: Upright in all Leads; prominent in Lead 2.

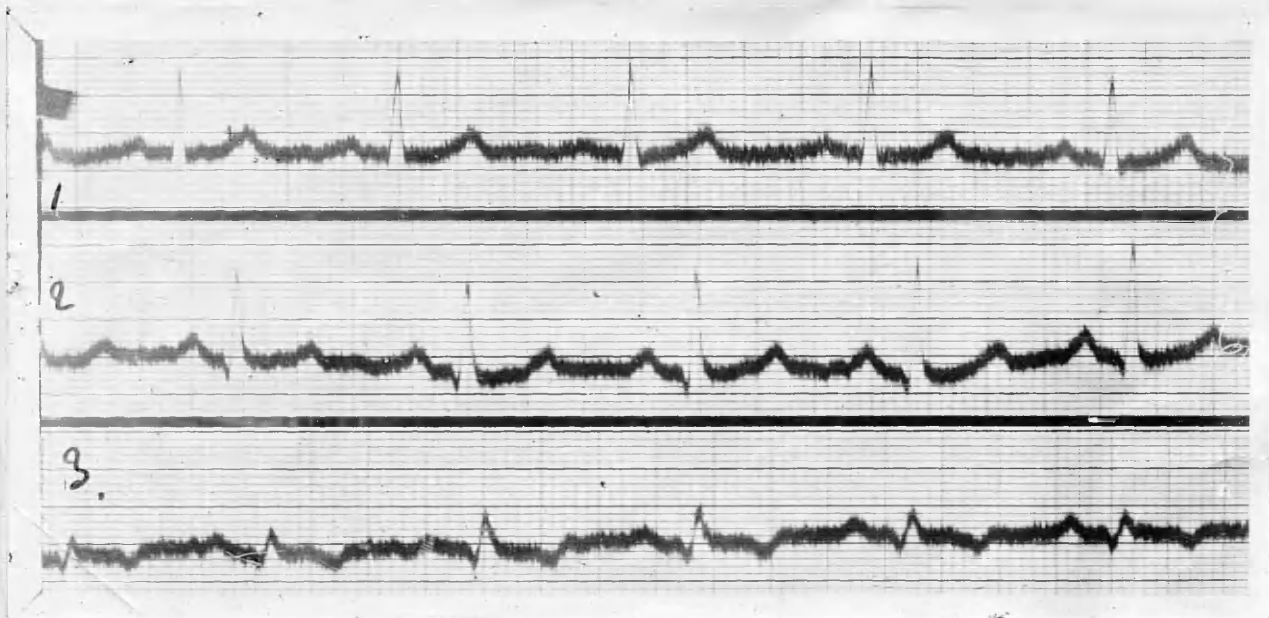
PR interval: .16 seconds.

QRS complexes: Of normal contour and duration in all Leads.

T waves: Upright in Leads 1 and 2; diphasic in Lead 3.

Electrical Axis: Normal.

Summary: Sinus tachycardia, with P.2. prominent.



E.C.G. 25/7/1940. (POST-OPERATIVE).

Rate: 72.

Rhythm: Regular sinus rhythm.

P waves: Less prominent in Lead 2.

PR interval: .16 seconds.

QRS complexes: Some widening and notching in Lead 3.

T waves: Inverted in Lead 3.

Electrical Axis: Normal.

Summary: Rate is now normal, and P.2 is less prominent. There is some defect and delayed conduction in the QRS complexes of Lead 3, and T.3 is now inverted.

GENERAL SUMMARY.

Thirty-four cases of thyrotoxicosis have been investigated all of whom underwent operative measures. An analysis of the cases, and of their pre-operative and post-operative electrocardiograms is now reviewed.

A. AGE AND SEX INCIDENCE.

Included in the series are 19 cases (55.8%) of Primary or Exophthalmic Goitre - Nos. 1, 3, 4, 6, 7, 9, 12, 13, 15, 17, 19, 22, 23, 24, 28, 30, 33, 34, and 15 cases of Secondary or Toxic Adenoma - Nos. 2, 5, 8, 10, 11, 14, 18, 20, 21, 25, 26, 27, 29, 31, 32.

Thirty-two of the patients were females, of whom 23 (71.8%) were married, and 11 (28.2%) unmarried.

TABLE I (age-incidence)

	Under 20.	21-30	31-40	41-50	51-60	61-70
Primary	1	4	6	6	2	0
Toxic Adenoma.	1	2	5	2	4	1

The analysis reveals that of the 19 Primary cases 12 were between the ages of 31 and 50, 6 in each age period. The two oldest patients in this group were each 55 years. The average age was 37.4 years.

The incidence of Toxic Adenoma was highest in the age period 31-40 (33.3%) and the next highest in the 6th decade (26.6%). The oldest patient in this group was aged 63 years and the average age 43 years.

B. RHYTHM.

Regular sinus rhythm was present in 25 cases (73.5%), and sinus arrhythmia in 6 (17.6%). Case 30 showed ventricular extra-systoles, which disappeared after operation. Only one case (No.6) had auricular fibrillation before operation, and this persisted when all ^{other} over evidence of thyrotoxicosis had gone. Quinidine therapy, however, quickly restored normal rhythm.

C. P. WAVES:

Cases 5, 15, 20, 32, and 54 showed prominence of the P Waves in Lead II, Cases 8 and 12 in Leads II and III, and case 29 in Lead III only. Operation resulted in a lowering of the amplitude of the P wave in all cases.

Case 12 and 15 were in the Primary Group and the others were in the Toxic Adenoma group.

D. P-R INTERVAL.

The average duration of the P-T Interval before operation was .13 seconds and this became .14 seconds following surgical measures. In case 16 it became prolonged to .24 seconds post-operatively, but one month later was within normal limits.

E. HEIGHT OF R WAVE.

Lead II showed the greater amplitude of R in 24 pre-operative electrocardiograms, and Lead I in 12 (a number of cases revealed equal excursion of R1 and R2). After operation changes occurred in the height of the

R wave as follows:-

R1 became greater in Case 33.
R2 " " " " I
R3 " " " " 10 and Case 21.

R1 became lowered in Case 27.
R2 " " " " 13, 15, 22, 25, 31.
R3 " " " " 12.
R2 and R3 " " " " 8, 19, 24.

The tendency, therefore, was for a lowered amplitude of the R wave after operation.

F. T WAVES.

The pre-operative electrocardiogram of the following cases revealed some prominence of the T waves in one or more leads:-

Cases 1 and 5 in Lead II.
" 7, 12, 16, 17, 18, 20, 21 and 22 in Lead I.
Case II in Lead III.
Cases 24, 27, and 29 in Leads I and II.
Case 8 in Leads II and III.

Thus prominent T waves were a feature of Lead I in eleven of the thirty-four cases (32.4%). Six were cases of Primary goitre and five of Toxic Adenoma.

Inversion of a previously positive T wave was noted in a number of cases, and diminished amplitude of T, following operation, was frequent throughout the series.

G. ELECTRICAL AXIS.

Left deviation of the electrical axis was present in 12 (35.3%) pre-operative electrocardiograms. The deviation was of mild degree in Cases 2, 3, and 21 and was well marked in Cases 4, 7, 11, 22, 23, 25, 31, 32, and 33.

Right vertical preponderance was noted in the pre-operative tracings of cases 8, 26 and 27 (8.8%), being of slight degree in Case 8.

Operation restored left deviation to normal in Cases 2 and 23, and right deviation to normal in Cases 8 and 27. Deviation was unchanged in the remainder, but a normal axis showed a tendency to left deviation in Cases 1 and 26. Left ventricular preponderance was present in 6 cases of Primary Goitre and in 6 of Toxic adenoma. All the instances of right preponderance were in patients with Toxic Adenoma.

TABLE II (Axis deviation)

	No Deviation.	Left Deviation.	Right Deviation
Primary.	13	6	0
Toxic Adenoma.	6	6	3

COMPARATIVE DISCUSSION.

It is not admitted by every observer that the features of the electrocardiogram in thyrotoxicosis possess any real significance. Towers (29), for example, says that apart from recording the type of arrhythmia which may be present, the electrocardiogram has not proved of much value. On the other hand, Jenner Hoskin (30) claims that the electrocardiogram shews definite changes from the normal, which in many cases are pathognomic of the disease.

Certainly the behaviour of the electrocardiogram in thyrotoxicosis has stimulated many investigations, the results of which have varied to a surprising degree. A review of these electrocardiographic findings induces one to support the view expressed by Cookson (31) that the features of hyperthyroidism probably vary in different parts of the country, and still more in different countries.

AGE AND SEX INCIDENCE.

No less than 26 out of the 34 patients in the thesis were over 30 years old when first examined, and 15 were above 40. The average age of the Primary group was 37.4 years, and of the Toxic Adenoma patients it was 43 years. Hay (32) has declared the onset of Primary toxic goitre as most frequent between the ages of 15 and 37, and of Toxic Adenoma at any time between 30 and 70.

In a series of 400 patients suffering from Toxic goitre, Cookson found only 37% were under 40 years and 63% over this age; 42% were over 50 years old. He claimed

that there is now evidence that toxic goitre is commoner in women over 40 than below this age. whereas formerly it was considered an affection of girls and young women.

The preponderance in the thesis of patients over the age of 30 supports the view that the disease is commoner somewhat later in life than was formally held. Cookson also found the sex-ratio to be 8.5 females to 1 male, and this appears to be about the usual sex-incidence according to other writers.

In the thesis, females predominated to the extent of 32 to 2. Such an excess of female over male subjects indicates that in the area whence the patients came (East Lancashire and the Ribble valley) the disease affects the former sex to an unusual degree.

DISTURBANCES OF RHYTHM.

An interesting feature of the thesis cases is the remarkable infrequency of abnormal rhythms. Six patients had sinus arrhythmia, one had sinus rhythm with ventricular extra-systoles, and only one presented a rhythm not of sinus origin - auricular fibrillation.

A review of the abnormal rhythms noted in other series reveals a great difference from the thesis findings.

White and Aub found paroxysmal auricular fibrillation in 3 of 47 patients, and continuous auricular fibrillation in 3 more. One patient showed paroxysms of auricular flutter.

and extra systoles were seen in the tracings of a number of others.

Goodall and Rogers (33) reported 15% of cases with auricular fibrillation. the arrhythmia being present before operation in 10%, and developing as a post operative complication in the remainder. They stated that, generally speaking, auricular fibrillation develops after the disease has been in progress for some years, and must be regarded as indicating that the myocardium is profoundly poisoned, or that degeneration has definitely commenced.

Krumbhaar's series of 51 cases revealed the following arrhythmias:-

Sinus arrhythmia.....	4
Ventricular extra systoles..	3
Auricular fibrillation.....	3 (2 continuous, 1 post-operative and transient)
Auricular flutter.....	1
Delayed conductivity.....	2

Magee and Smith (34) observed that the exact incidence of auricular fibrillation in hyperthyroidism varies considerably in different localities. They found the maximum incidence in the 8th decade. and that its occurrence in toxic adenoma was commoner in every decade. In their opinion. advanced age is a much more important factor than the duration or the intensity of symptoms in determining the incidence of auricular fibrillation and myocardial insufficiency in patients with hyperthyroidism.

In a follow up of 36 patients who had undergone operation

for thyrotoxicosis. Don and Langley noted auricular fibrillation in 4, in one of whom it had developed post-operatively. Brenner stated that auricular fibrillation supervenes in 10% of all cases of thyrotoxicosis, is twice as common in males, and its incidence increases with age and the duration of toxæmia. Ernstene (35) in a large series of 1000 cases of thyrotoxicosis reported auricular fibrillation in 207; in 96 the arrhythmia was present before operation, either in its continuous form or in paroxysms of long or short duration, while in 111 it developed for the first time post-operatively. Auricular flutter was found only twice, auricular paroxysmal tachycardia five times, and auricular paroxysmal tachycardia twice. Premature beats were also encountered, but he considered their incidence not appreciably greater than in the general run of patients seeking advice for conditions other than thyrotoxicosis. Ernstene found no apparent relationship between the duration of the toxæmia and the incidence of auricular fibrillation when all patients were considered together. But individuals in the age-group 46-65 (who showed the highest incidence of auricular fibrillation) developed the arrhythmia much more frequently when the thyrotoxicosis had been present for three years or more.

No patient in the thesis had had toxic symptoms for

three years. and in the majority the toxaemia had lasted less than twelve months. This appears to be the most logical explanation for the low incidence of abnormal rhythms, though possible as Magee and Smith stated, the locality from which the patients were derived may have been a factor of some importance. The one patient with auricular fibrillation, it should be noted, was a male.

P WAVES AND P-R INTERVAL.

Eight patients in the thesis had prominent P waves before operation, and thyroidectomy resulted in a reduced amplitude in every case. Six of these patients were suffering from Toxic Adenoma.

This P wave feature in thyrotoxicosis is confirmed by a number of writers.

Rose, Wood and Margolies stated that large P waves are common in hyperthyroidism. and are usually reduced after a successful thyroidectomy.

Don and Langley noted tall P waves before operation in 5 of 18 patients, and well developed P waves in 9. At the follow up P had decreased in 7, increased in 4.

Jenner Hoskin's view was that P waves show a definitely increased amplitude in Leads II and III.

Goddall and Rogers stated that in thyroid tachycardia the P wave is enlarged, and tends to equal the T wave in amplitude.

In the opinion of Brenner, tall P and T waves occur in 25% of all cases of thyrotoxicosis, and operation reduces the size of the T waves.

The P-R interval was within normal limits in all the thesis cases except for a short period following operation in case 16. After thyroidectomy there was a slight lengthening of the interval (from .13 to .14 sec)

Jenner Hoskin noted .16 sec. as the average PR interval in his cases and said that .13 sec. was quoted by other observers. Don and Langley instanced no cases with prolonged PR interval in their follow-up report.

Goodall and Rogers, however, maintained that the continued action of the toxin produces distinct evidence of myocardial damage, the conducting system being especially picked out, so that there is impaired conduction in the Bundle of His, the PR interval being increased in some cases to as much as .3 seconds; in other cases the right main bundle is picked out producing definite right-bundle branch block with consequent impaired efficiency of the pulmonary circuit. They further claimed that this is particularly liable to occur in the pneumo-mechanical heart of Toxic Adenoma.

No evidence was forthcoming in the thesis to support these statements. One is induced to believe that when these changes do occur, they are a late manifestation, and indicate an advanced degree of myocardial damage.

HEIGHT OF R.

Eleven patients in the thesis showed a lowered excursion of R after operation, and an increased excursion was noted in 4.

Jenner Hoskin observed that, in thyrotoxicosis, the height of R is increased, but slightly only in most cases, and that where ventricular preponderance is absent, R₂ is usually the greatest.

Don and Langley also found R tall before operation, and considerably diminished at the follow-up three years later. Only one case then showed an increased excursion of R.

Removal of the intoxication which follows successful operative measures puts a stop to the prolonged overaction of the ventricles, and accounts for the reduction in the size of R.

T WAVES.

More observations have been made upon the T wave than upon any other feature of the electrocardiogram in thyrotoxicosis. Fifteen tracings in the thesis revealed some prominence of T in one or more leads. Lead I exhibited this phenomenon most frequently, and Lead II next. In both types of the disease, prominent T waves were encountered.

Almost invariably there was a reduction in the amplitude of T, whether previously prominent or not,

following operation, and in a few cases this reduction proceeded to inversion.

Hoffman (37) in 1914 appears to have been the first to describe the high T waves in exophthalmic goitre. He considered the height of the T wave proportional to some extent to the rapidity of the heart-beat.

Four years later, Krumbhaar remarked upon the unusually large T waves in most cases of toxic goitre, which in about half the cases were markedly and persistently diminished after operation. In his view flattening or inversion of T in Leads I and II indicated a bad prognosis.

Hamburger et al (38) in their series of 32 hyperthyroid patients noted increased height of T in a few, and that thyroidectomy reduced the amplitude, in 2 cases the reduction progressing to inversion. They explained the variations in the height and form of the T waves as due to variations in the tone of the cardiac regulatory nerves as well as ^{to} ~~by~~ alterations in the muscular state of the heart.

Coello (39) reported enlarged P and T waves in 22 of 39 patients examined, the enlargement being most frequent in Leads I and II. Thyroidectomy reduced the voltage in all cases exhibiting this feature.

Don and Langley in their follow-up of 42 cases of thyroid toxæmia remarked upon the large number in which

T was inverted in Lead II. Nine of 36 showed this inversion and in 4 it was a post-operative development. Inversion was found in Leads II and III in 2 cases, here again of post-operative origin. Tall T waves were noted in Lead I in 4 patients, and well developed T waves in Lead II in 12. Operation reduced the size of T in 8, increased it in 4. They concluded that the size of T bore no constant relationship to the metabolic or clinical condition of the patient.

In the view of Rose, Wood and Margolies, marked T wave changes occur before and after thyroidectomy in hyperthyroidism, but they follow no apparent pattern, and their occurrence is unpredictable. T wave inversion, they held, does not necessarily indicate the presence of chronic myocardial disease; it is, in fact, frequently a transient phenomenon.

Mc.Guire and Foulger (40) described a "thyroid" T wave of large amplitude and rolling contour, and noted a similar form of wave in 25 cases of neuro-circulatory asthenia, in all of whom the pulse-rate was 90 or less. They concluded that "thyroid" T waves bear no relation to the pulse rate or to the basal metabolic rate, and, furthermore, that there is no constancy in their occurrence.

The significance of the size of the T waves in thyrotoxicosis was explained as follows by Jenner Hoskin. A large T_I he said indicates a powerfully acting right

ventricle. A sub-normal or negative T1. points to a fatigued right ventricle, and is a warning that pulmonary complications would be ill-borne. Flat or negative T2 indicates an impaired state of the left ventricle with the risk of cardiac failure.

In the thesis five patients (Nos. 5, 8, 12, 20, 29) showed prominence of both P and T waves in their pre-operative tracings. On the whole series the behaviour of the P and T waves did not support the statements of Goodall and Goodall and Rogers that in thyrotoxicosis these waves tend to be equally enlarged, as P was frequently of normal size when T was enlarged.

Post-operative inversion of T did not appear to have any prognostic significance.

ELECTRICAL AXIS.

The present series reveals left axis deviation in 12 cases, and right axis deviation in 3. Operation restored a normal axis in 2 of each variety.

That left ventricular preponderance is more common than right is confirmed by most observers. Goodall stated that left preponderance is frequent, indicating excessive action of the left ventricle, and that right preponderance is distinctly rare. Dameshek noted left axis deviation frequently in 141 cases, but White and Aub found it only three times in 27 patients. Jenner

Hoskin's figures were:-

	<u>Exoththalmic goitre.</u>	<u>Toxic Adenoma.</u>
No preponderance.....	64%	64%
Left " 	20%	24%
Right " 	16%	12%

Left axis deviation was thus commoner than right in both types.

Don and Langley found 10 of 36 cases followed up presenting left ventricular preponderance, and in 2 the dominance had increased following operation. Right deviation was only seen once.

Why some electrocardiograms show a return from deviation to a normal axis may be explained by the fact that ventricular dilatation precedes hypertrophy, as Goodall has stated. Removal of the toxæmia which follows successful thyroidectomy will permit the ventricular muscle to regain its tone if dilatation only is present. When hypertrophy has supervened, with preponderance of one or other ventricle the axis deviation will persist after operation.

CONCLUSIONS.

The following observations are suggested from a review of the records of the patients whose histories and electrocardiograms have been analysed:-

- (1) The age incidence of thyrotoxicosis is commonest above 30, and is frequent above 40, higher ages than was formerly considered usual.
- (2) The disease predominates to an unusual degree amongst females in the area from which the patients came.
- (3) The low incidence of abnormal rhythms is attributable to the comparatively short duration of toxic symptoms before operative measures were instituted. Locality is another possible factor.
- (4) Enlarged P waves occur in a minority of cases, and operation invariably reduces their size. The PR interval is unaffected unless toxæmia is severe and of long duration.
- (5) Ventricular over-action produces some heightening of R, and operation frequently reduces the amplitude.
- (6) Prominence of T waves is fairly common in thyrotoxicosis more so than of P waves, and this prominence is reduced by operation. T inversion may follow thyroidectomy, but is not of clinical importance.
- (7) T and P waves do not tend, when enlarged in thyrotoxicosis, to approximate in size.
- (8) Left axis deviation is much commoner than right and thyroidectomy may restore a normal axis in a small

percentage of cases.

- (9) The clinical improvement which follows successful thyroidectomy is paralleled by changes in the electrocardiogram, which showed throughout the series little or no evidence of gross myocardial damage.

1. ...
2. ...
3. ...
4. ...
5. ...
6. ...
7. ...
8. ...
9. ...
10. ...
11. ...
12. ...
13. ...
14. ...
15. ...
16. ...
17. ...
18. ...
19. ...
20. ...
21. ...
22. ...
23. ...
24. ...
25. ...
26. ...
27. ...
28. ...
29. ...
30. ...
31. ...
32. ...
33. ...
34. ...
35. ...
36. ...
37. ...
38. ...
39. ...
40. ...
41. ...
42. ...
43. ...
44. ...
45. ...
46. ...
47. ...
48. ...
49. ...
50. ...
51. ...
52. ...
53. ...
54. ...
55. ...
56. ...
57. ...
58. ...
59. ...
60. ...
61. ...
62. ...
63. ...
64. ...
65. ...
66. ...
67. ...
68. ...
69. ...
70. ...
71. ...
72. ...
73. ...
74. ...
75. ...
76. ...
77. ...
78. ...
79. ...
80. ...
81. ...
82. ...
83. ...
84. ...
85. ...
86. ...
87. ...
88. ...
89. ...
90. ...
91. ...
92. ...
93. ...
94. ...
95. ...
96. ...
97. ...
98. ...
99. ...
100. ...

REFERENCES.

1. Parry quoted by Dameshek.
2. Flajani " " "
3. Graves. London Medical and Surgical Journal 1835.
4. Marsh: Sir Henry. quoted by Dameshek.
5. Mc. Donnel R.L. " " "
6. Adelman " " "
7. Von Basedow(1840) Wshnschr, f.d. ges. Hlilk; 197, 1840.
8. Charcot T M. Gazette des Hôpit. 62:135:1888.
9. Rose E. Archiv. J. Klin. Chir. 22:1:1878.
10. Kocher quoted by Dameshek.
11. Wolfler " " "
12. Boas Journ. Amer. Med. Assocn. 80:1683:1923.
13. Kraus. quoted by Dameshek.
14. Bircher E. Med.Klinik : 6 : 391 : 1910.
15. Dameshek W.E. Boston Med. and Surg.Journ.190:487:1924
16. Murray Brit. Med J. 11 : 1245 : 1905.
17. Good~~ra~~al^b. J. S. Pract. 105 : 37 : 1920.
18. Plummer H. S. Trans. Assoc. Amer. Phys. 30: 450: 1915.
19. Krumbhaar E.B. Amer Journ. Med. Sci.155 : 175 : 1918.
20. White P D and Aub J C. Arch. Int. Med. 22 : 76 : 1918.
21. Barr Sir T. Brit. Med J. T. 544 : 1916.
22. Bach F. and Bourne. J. Quart. J. Med. 1. 579. 1932.
23. Read Amer Heart Journ. 8 : 84 : 1932.
24. Andrus " " " 8 : 66 : 1932.
25. Menne et al " " " 8 : 75 : 1932.
26. Goodpasture. Journ. Amer. Med. Assoc. 76 : 1545 : 1921.
27. Don & Langley Quart Journ Med. 50 : 9 : 1932.
28. Brenner Brit. Med. J. 2 : 199 : 1935.
29. Towers. Lancet : 1 : 67 : 1933.
30. Hoskin J. Diseases of the Thyroid : Joll. C.A.1932.
31. Cookson H. Lancet. 1363: 1939.
32. Hay Lancet 2: 1377 : 1936.
33. Goodall J.S and Rogers L. Brit. Med. J. 1: 1141: 1927.
34. Magee H R and Smith H L. Am. J. Med. Sci. 189: 683 : 1935.
35. Ernestene A.C. Am. J. Med. Sci. 11 : 195 : 1938.
36. Rose Wood and Margolies J. Clin. Invest. 14 : 497 : 1935.
37. Hoffman : quoted by Mc.Guire. J. and Foulger M.
38. Hamburger et al : Arch. Int. Med. 43 : 35 : 1929.
39. Coello E. Ann. de med. 30 : 272 : 1931.
40. Mc.Guire J and Foulger M. Amer. Heart Journ. 8:114: 1932.
41. Fishberg A. M. Hypertension and Nephritis. 1934.
42. Parkinson J and Hoyle J C. Lancet. 1 : 912 : 1934.