THE INFLUENCE
OF THE AUTONOMIC NERVOUS SYSTEM
IN PSORIASIS

By

George Leslie, M. B., Ch. B.

With 92 Photographic Illustrations.

September 1948

CONTENTS

INTRODUCTION

The object of this thesis will be to show that the Autonomic Nervous System plays an active part in Psoriasis.

A series of cases will be presented in which roentgen-rays were applied to the spine, the applicator being centred over the Cervical and Lumbar Sympathetic Enlargements.

A further series of cases will be presented in which one of the chemical intermediaries of the autonomic nervous system, viz., Acetylcholine, in the form of Carbachol, was administered orally.

Some of the case histories will be given throughout the text to illustrate the usual sequence of events and also any interesting or unusual features observed. A synopsis of all the case histories will be incorporated in an appendix at the end.

Photographic illustrations will also be given. It is hoped that they will demonstrate better than any word-picture the results obtained by the methods about to be described. The photographs were all taken and processed by the author.

Chapter 1

CLINICAL ASPECTS OF PSORIASIS

Psoriasis is an inflammatory disease of the skin. The primary lesion is a small papule which very soon becomes covered by a whitish, dry scale. The papule tends to spread peripherally and to join up with neighbouring papules to form larger lesions. These, in turn, may coalesce until, in some cases, very large, irregular lesions are formed. The lesions are always well demarcated and are usually covered by layers of silvery scales. In many lesions, however, the scales form into tough, whitish, laminated, adherent crusts. When the undermost layer of scales is removed, small bleeding points, due to the abrading of inflamed and hypertrophied papillae, are seen. This is one of the characteristics of the disease. In lesions which do not show the characteristic scaling, a silvery streak can be produced when the surface of the lesion is scratched.

The extensor surfaces are usually the sites of election but in extensive involvement of the body, the flexural surfaces are also affected, and in some cases lesions only appear on the flexural surface. In most cases the scalp is affected to a greater or less extent. There may

Fig. 1. Psoriasis of the scalp.

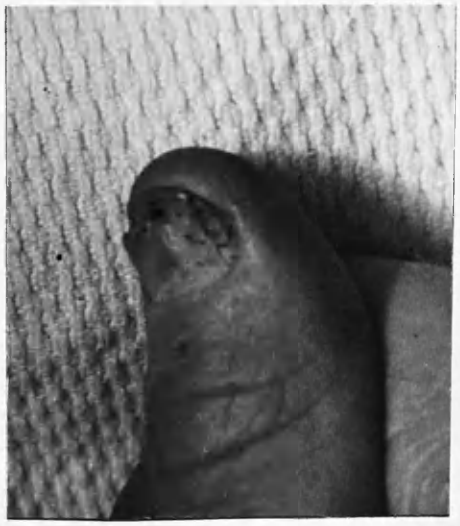

Fig. 2. Psoriasis of the nail.

Fig. 3. Psoriasis of the palm.

Fig. 4. Psoriasis of the eyelids.

only be a few, scattered, scaling papules or the whole scalp may be covered by a massive, infiltrated crust (fig.1). Psoriasis appears on the nails as pin-point pitting with an accumulation of scales heaped up underneath the nails (fig.2). On the scrotum scaling is often absent and the skin is red, thickened and indurated. On the palms and soles the condition is usually a hyperkeratosis with numerous fissures, giving a dirty greyish appearance and a coarse, harsh feeling (fig.3). It is not common to get involvement of the face and the eyelids are rarely affected (fig.4). Irritation is a variable symptom. Some patients complain of extreme discomfort, while others are free from itching.

The character of the eruption varies. The individual lesions may remain small, giving the appearance of drops of grease scattered on the body. This is referred to as a Guttate eruption (fig.5). Due to a few guttate lesions joining together, larger nummular and discoid lesions are produced. The term Psoriasis geographica is applied to the type of eruption in which the lesions are extensive and irregular in outline (fig.6). In some cases the central part of a lesion may heal spontaneously while still spreading peripherally giving ringed and annular appearances (fig.7). These in turn may coalesce to form gyrate configurations

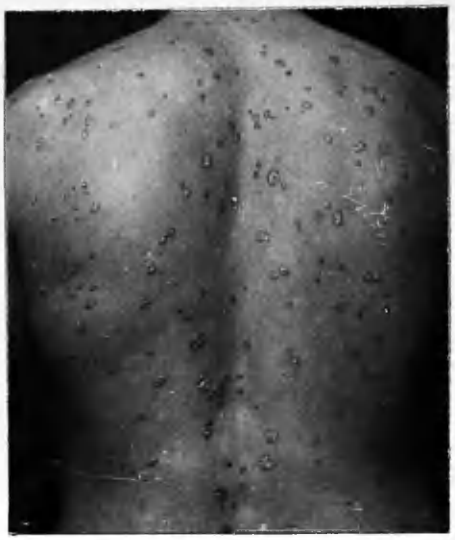

Fig. 5. Guttate psoriasis.

Fig. 6. Psoriasis geographica.

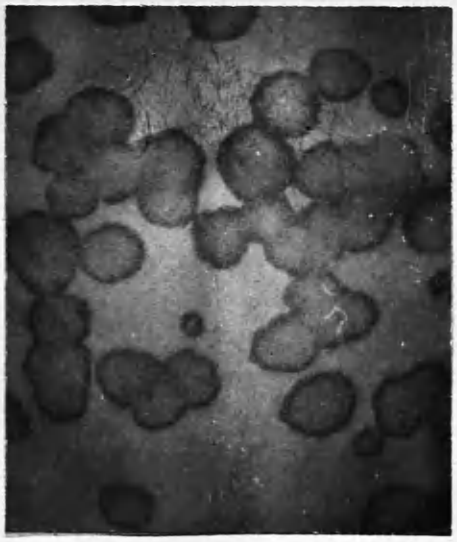

Fig. 7. Annular psoriasis.

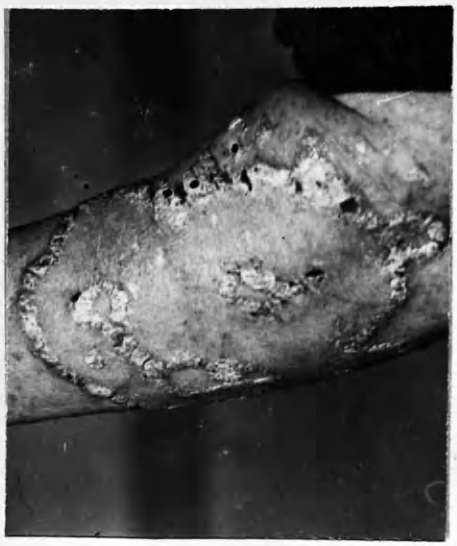

Fig. 8. Gyrate psoriasis.

(fig.8). All varieties of lesions may be seen in the one patient. A rare variety is Pustular psoriasis in which small pin-head sized pustules appear, usually on the hands and feet. Neither bacteria nor fungi can be demonstrated in the pus which is sterile. This type is very resistant to treatment (fig.9).

The condition is chronic and remissions after healing are frequent. Some cases may remain clear for years, others may relapse as soon as treatment is stopped.

HISTOPATHOLOGY. The following description is according to McLeod and Muende (1).

Psoriasis is a classical example of a mild degree of oedema of the epidermis with imperfect keratinisation or parakeratosis.

A marked feature in the histopathology is ACANTHOSIS with proliferation of the prickle-cell layer resulting in lengthening and broadening of the interpapillary processes, except immediately above the papillae, where the prickle-cell layer may be only one or two cells thick. Few mitotic figures may be seen in the prickle-cell layer, and Lipschutz has described the presence of eosinophilic nuclear bodies in very early lesions. These inclusion bodies, which are eventually

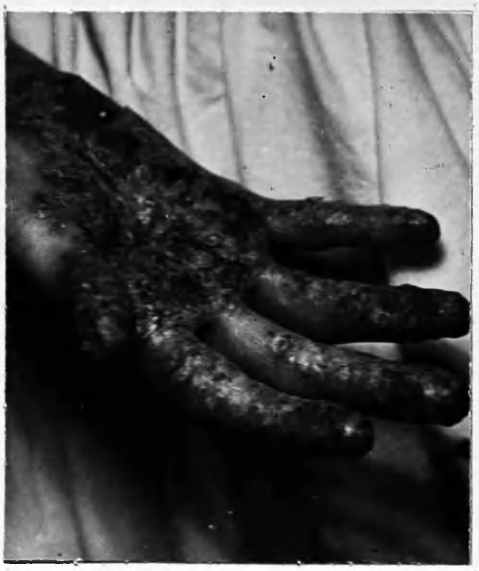

Fig. 9. Pustular psoriasis.

Fig. 10. Psoriasis of the axilla.

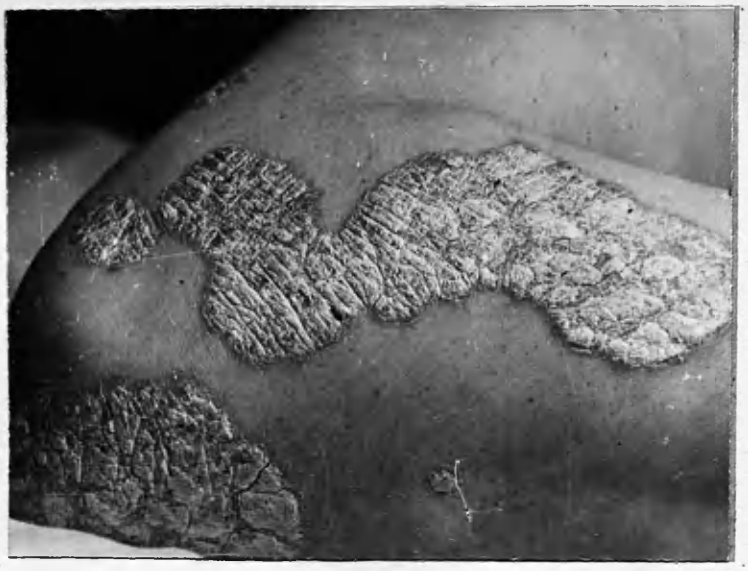

Fig. 11. A typical plaque of psoriasis on the forearm.

extruded into the cytoplasm, have been likened to the Gaurneri bodies of variola and have given support to the contention that psoriasis is due to a virus infection.

There is pronounced intercellular oedema and migration of polymorphonuclear leucocytes into the epidermis from the underlying corium, giving rise to the formation of the PSEUDO-ABSCESSES OF MUNRO. Owing to the development of parakeratotic cells beneath the pseudo-abscesses the latter may be found present between the superficial lamellae of the imperfect horny layer.

The Stratum granulosum is absent and the Stratum corneum replaced by several layers of parakeratotic horn cells.

The blood vessels of the papillary and sub-papillary layers are dilated and surrounded by a leucocytic and a lymphocytic cellular infiltration.

The above pathological changes account for the peculiarity of the psoriatic lesions. As the parakeratotic cells are soft and plastic they adhere together in lamellae or squames which cannot be rubbed off singly like the dry horn cells of perfect keratinisation. Again, when these lamellae become partially dried, air makes its way into the cellular debris and gives to the scales their characteristic

silvery appearance.

As the presence of the keratohyalin granules of the granular layer gives the skin its whitish opacity, the absence of this layer accounts to some extent for the vivid redness of the pellicle on the removal of the scale and, as the prickle-cell layer is thin over the papillae, even slight scarification of the red pellicle is sufficient to expose the delicate dilated capillary vessels which on rupture give rise to minute bleeding points.

AETIOLOGY. The cause of Psoriasis is unknown.

Chapter 2

PREVIOUS WORK DONE IN THE USE OF INDIRECT X-RADIATION

The idea of irradiating one part of the body surface to produce healing of a skin eruption at a distance from it is not new. Brock (2) in 1920 advocated the use of roentgen-rays, directed over the thymus gland, as a method of treating psoriasis.

His formulation of this method followed an observation that a child with psoriasis, who received roentgen-rays for a local effect, the rays being directed to the head and chest, developed an extensive and severe generalised eruption. Later observations revealed that, in adults receiving local treatment on the neck and upper chest, a disappearance of a generalised eruption resulted. He immediately started an investigation as to the cause of this phenomenon.

It was at first thought that the thyroid gland was responsible. Experiments were done in which the thyroid, para-thyroid and thymus glands were irradiated, singly and in combination. Improvement or deterioration in the skin condition resulted only when the region topographically related to the thymus gland was included in the irradiated area.

In a series of twenty-two cases of all age groups in which a definite field of entry over the thymus gland for the rays was selected, fourteen cases were successfully treated, four cases were improved and four were failures. The failures were attributed to giving a second treatment too early in two cases and in the other two, to the dosage being too big in young subjects. The portal of entry for the x-rays recommended by Brock is bound above by the lower border of the larynx and upper border of the clavicle; at the sides by the parasternal lines; below by the fifth intercostal space.

In order to explain his results, Brock stated that psoriasis is due to hypofunction of the thymus gland. He draws attention to the fact that psoriasis is rare in early childhood, at a time when thymus activity is at its maximum, that it never occurs in subjects with a true thymus hyperplasia and that psoriasis often developes during puberty, when the thymus undergoes involution. By stimulating the gland with roentgen-rays, this hypofunction can be overcome. This statement assumes that the thymus gland functions at all ages. To support this assumption, Brock points out that it has been histologically shown that the thymus functions even in old age - new formation of Hassall corpuscles, mitotic increase of lymphocytes and reaction to nutritional disorders.

Because of the large amount of lymphoid tissue in the thymus it is very radio-sensitive, and undergoes rapid regression, followed by regeneration after moderate doses of x-rays and a constant finding, noted by various observers who have studied the changes in the thymus following irradiation, is the enlargement of the Hassall corpuscles. Hassall corpuscles are formed by a coalescing of the branching stellate cells of the reticulum and are epithelial in origin. They continue to be formed as long as the thymus reticulum continues to exist.

The fact that Hassall corpuscles were increased following irradiation caused Brock to think that the therapeutic effect in psoriasis was to be sought in the Hassall corpuscles as they formed an index of the degree of functional activity of the thymus gland. He explained the deterioration of the condition which occurred in some patients as being due to overdosage which instead of stimulating the thymus gland, temporarily paralysed it, so impairing its functional activity still further.

Following the publication by Brock of his results, many other workers tried his method. Foerster and Foerster (3) published observations on Brock's method in 1921. Their results compared with those of Brock, thirteen cases out of a

series of twenty-three being markedly improved and they concluded that it was worthy of consideration as a practical procedure in the treatment of psoriasis. Schneider (4), on the other hand in 1922, came to the conclusion, following unfavourable results that a pathological relation between the thymus and psoriasis could not be assumed. This conclusion was also arrived at by Kumer (5) after he had unsuccessfully treated several cases by Brock's method.

Gawalowski (6) reported success in 65.8% of cases treated by means of thymus irradiation. He used a larger dose at shorter intervals. Rummo (7), in a series of twelve cases, reported five completely cured, three almost entirely cured, two improved and two whose condition was unchanged.

Other workers administered extracts of thymus gland tissue to patients suffering from psoriasis. Samberger (8) reported improvement following subcutaneous administration of thymus extract. He did not agree that the thymus was always at fault in cases of psoriasis, but thought administration of thymus substance good symptomatic treatment, as it seemed to increase the vitality of the skin. Gross (9) recorded two cases of psoriasis of many years duration which were cured following 15 injections of thymus extract (1cc. corresponding to 2 gm. of thymus gland).

Spillman and Carillon (10) noted improvement in a case of psoriasis in a patient with disturbance of the vagosympathetic equilibrium, following thymus gland administration. Hanney (11) did not think that any improvement had occurred in his cases following the administration of thymus gland extract.

Jamieson (12) treated fifty patients by Brock's method of irradiation of the thymus gland. 10% were improved, 34% showed temporary improvement and 56% were considered unimproved. His observations showed that the most beneficial result seemed to be in lessening the severity of recurrences in many inveterate cases.

Gorl and Voigt (13) in 1921 reported a case of generalised psoriasis in which a temporary, but complete, disappearance of all lesions followed a full erythema dose of x-rays to one hand only. They thought they were dealing with a general and not a local reaction of the body and believed it does not matter which part of the body is selected for x-ray treatment.

Pautrier (14) at the Dermatological Reunion in Strasbourg in March 1924 published the result of the first case of a generalised skin eruption cured by medullary radiotherapy. It was a case of Lichen planus in a woman and,

without any other external or internal treatment, a complete cure was effected within a month. The spine, from the first dorsal to the fifth lumbar vertebrae, was divided into five fields, each field receiving IsB through 5 mm. Al. filtration. He was led to this method of treatment, as he says in a later publication (15), by purely theoretical reasons. For a long time there had been a tendency to ascribe to the nervous system an important role in the etiology of this complaint. Nervousness and irritability in the patient suffering from it, pruritus, often severe, which accompanied the eruption and sometimes preceded it, manifest zosteriform distribution of certain eruptions and the favourable results from the withdrawal of a few c.cs. of cerebro-spinal fluid by lumbar puncture, were facts which seemed to point to the incrimination of the nervous system.

Two other dermatologists, working independantly to each other and to Pautrier, also in 1924, published results of patients treated by irradiation of the spine, Hufschmidt (16) and Gouin (17).

Hufschmidt also irradiated the spine with filtered radiation, the dosage being 3/5sB. His first patient showed no response after 15 days and a further treatment was given. This produced a rise in temperature, headache and vomiting

(ray sickness). On the sixth day, following the second treatment, the lesions rapidly subsided and the pruritus disappeared. His second patient had an exacerbation of the condition following therapy. This soon settled and a complete cure was obtained.

Gouin's experiments in medullary radiation date back to 1919, although his results were not published until September 1924. His method differed from the others in that he used unfiltered radiation and treated the interscapular, and sometimes the lumbo-sacral, region only. The majority of his patients received treatment to the interscapular region alone, the lumbar region being irradiated only when there were lesions on the lower extremities. He noted a reaction of two kinds; an immediate and a late. In an immediate reaction there was an exacerbation of the condition within 24 hours. In a late reaction, after 2 - 3 days, the itching disappeared and the eruption subsided.

Pautrier, following the treatment of his first three cases by his original method, altered the technique and obtained better results. He divided the spine into eight fields, four on either side of the vertebral column. He inclined the tube at an angle of 45° and gave 4/5sB through 3 mm. Al. filter. This semi-deep, cross-fire method was

employed on two patients who had resisted the first method and a complete cure was obtained in both cases. Out of 35 patients treated by the semi-deep, cross-fire method, 13 were cured after a single treatment, 9 after two treatments, 8 were failures and in 5 follow up did not take place. Pautrier records one recurrence almost three years after being cured by medullary radiation. He noted two facts, one, the lesions were not in the same situation, and, two, the eruption this time proved radio-resistant.

Payeuneville and Billiard (18) reported six cases of lichen planus treated by medullary radiation, four by Pautrier's method and two by Gouin's method. According to them Pautrier's method gave quicker and more satisfactory results. Two members of one family, a brother and sister, both with a generalised lichen planus, were treated by the different methods. The brother, treated by Pautrier's method, improved very quickly; the sister, treated by Gouin's method improved much more slowly.

Prieto (19) introduced yet another method of indirect x-radiation for the treatment of lichen planus. He estimated that by Pautrier's method 800 sq.cms. of the skin's surface was irradiated. His method consisted of irradiating a similar area of the skin surface over the abdomen. The dosage

was between 3/5 and 4/5sB and the target skin distance was 15 cms. with no filtration. He observed 5 cases treated in this way and reported failure in only one. In addition he mentioned 3 cases similarly treated by Covisa, two of which were successful.

Hudelo, Laporte and Kourilsky (2) reported on a case of lichen planus treated by irradiation of the interscapular and lumbar regions with 3/5sB through 10 mm. Al. filtration, the rays being directed to each side of the vertebral column in both regions. Itching disappeared in four days, but, following a second irradiation 18 days later, there developed violent itching and an outbreak of a generalised scaling erythrodermia, which, on close examination, was seen to be made up of coalescing lichen planus papules. Within a month the itching had gone entirely and the eruption had almost cleared. Like Pautrier and Hufschmidt, who also had cases which flared up following irradiation, they considered this to be a Herxheimer reaction.

Neumark and Krynski (21) recommended small doses at monthly intervals to the interscapular and lumbar regions. After observations on 8 cases, they came to the conclusion that irradiation of the spine is most effective in generalised subacute cases, less effective in cases where

lesions are localised to the lower part of the body and has no effect on the verrucose type situated on the lower leg.

Gawalowski (22), carefully stating that he was not introducing a new method but only giving an experimental one, reported on three cases of lichen planus. He irradiated the great vessels of the upper and lower limbs (armpits and the anterior aspect of the thighs). In two cases he obtained results comparable with medullary radiation. The third case failed to show any improvement.

Irradiation of the spine was tried as a therapeutic measure in other dermatoses, especially where itching was a prominent symptom. Kriser (23) applying 2/5sB through 0.3 mm. Zn. to the lumbar area, treated cases of senile pruritus, generalised eczema, psoriasis and lichenification of the skin and obtained satisfactory results in that the pruritus disappeared and some improvement was noted in the cutaneous lesions.

Gouin (24) described a case of erythema multiforme successfully treated by his method of medullary radiation. He followed this with a report on 150 cases of various dermatoses treated similarly (25). He divided them into 7 groups. In the first group there was a disappearance of the pruritus and the

cutaneous lesions. Included in this group were 14 cases of lichen planus, 9 cases of erythema multiforme, 2 cases of parapsoriasis, 3 cases of diffuse neurodermatitis, 10 cases of prurigo of Hebra without asthma, 5 cases of urticaria and 14 cases of eczema. In the second group, where the pruritus disappeared but no improvement was noted in the cutaneous lesions, were placed 24 cases of psoriasis. Chronic lichen simplex, 2 cases, came into the third group, in which neither the pruritus nor the cutaneous lesions improved. 6 cases of herpes zoster were included in the fourth group. Here the cutaneous lesions disappeared but the pruritus was uninfluenced. In the fifth group were placed dermatoses in which there was no pruritus. These included two cases of common warts, 1 case of plane warts, 2 cases of xanthoma, 1 case of congenital ichthiosis, 4 cases of vitiligo, 2 cases of von Recklinghausen's disease, 1 case of Darier's disease, 3 cases of naevus, 1 case of palmar hyperhydrosis and 1 case of lupus erythematosus. No positive result was obtained in any of them. The sixth group contained cases of pruritus without any cutaneous lesion. Of 3 cases treated 2 were successful. In the seventh group 6 cases of asthma with cutaneous lesions were treated and in all the cutaneous lesions disappeared and in five the asthma

was very much improved; 1 case of asthma with vitiligo was treated with no improvement in either condition; 2 cases of true asthma were treated without result and 9 cases of alopecia also failed to improve.

Rosh (26), in the American Journal of Roentgenology, published a series of cases of psoriasis treated by irradiation of the cervical and lumbar areas of the spine. He used deep x-ray therapy in 24 cases during the period 1924 - 1933. In most cases, following treatment, patients noticed, at first, an increase of itching which was soon followed by a complete cessation of this symptom. About three weeks after treatment it was noted that the colour faded from the centre of the affected area, the scales became loosened, and the surrounding infiltration of the skin was diminished. In most cases a second treatment was given after a period of six to eight weeks, during which time a majority of the areas were replaced by a brownish pigmentation. Complete disappearance of the lesions occurred only in three to six months after the administration of the last treatment. In some persistent cases a year elapsed before the body was freed from psoriasis.

Hellier (27), in 1943, published results of a series of cases of lichen planus, 60 treated by spinal radiation, 31 treated by irradiation of the chest and abdomen, and 67

treated by intramuscular injections of ½ gr. Enesol (a preparation containing mercury and salicylarsonate). In the cases treated by roentgen-rays the dosage was 1sB at 100 Kv through 2 mm. Al. filter. An area of 160 sq.cms. of skin over the lumbar and cervical areas of the spine, in the one series of cases, and a similar area of skin over the chest and abdomen, in the other, were irradiated. He classified the results into four groups, the table of which is reproduced.

Table 1

Treatment	Group 1 Dramatic improvement followed by cure	Group 2 Definite improvement but no immediate cure	Group 3 No change	Group 4 Worse
X-rays to spine (60 cases)	12 (20%)	29 (48%)	16 (27%)	3 (5%)
X-rays to chest and abdomen (31 cases)	14 (45%)	8 (26%)	8 (26%)	1 (3%)
Enesol (67 cases)	24 (36%)	28 (42%)	15 (22%)	0

It is seen that the comparison, though slight, between spinal radiation and radiation of similar sized areas of the chest and abdomen, favours the latter. From these results Hellier drew the conclusion that there was no greater benefit from exposing the skin over the spine than from over other parts of the body.

The various views put forward as to the mode of action of this method of treatment will be given later in a general discussion.

Chapter 3

SERIES 1. SPINAL RADIATION

In the series of cases under review in this section two regions of the spine were irradiated. In the cervical area the applicator was centred over the 7th cervical spinous process and in the lumbar area the applicator was centred over the 1st lumbar spinous process. In some cases, indicated later, the popliteal fossae were also irradiated. Small doses at weekly intervals were preferred to one large dose at one treatment, 600 r ('r' being 1 roentgen unit) being given as a full course. At first only one area was irradiated weekly, either the cervical or the lumbar, but later both areas were treated each week. 200 r were given to both areas weekly in adults, for children (patients under 12 years) the weekly dosage was 100 r to each area.

It will be seen, on reading the case histories in the appendix, that the technical factors vary slightly. Owing to necessity, and not with the intention of altering factors for the purpose of obtaining varied results, two machines were used in the course of the series. It was observed that there was no difference in the results achieved. The kilovoltage, 100 Kv, and the diameter of the applicator,

10 cms. for adults and 7.5 cms. for children, were constant with both machines. Variation took place in the milliamperage, 5 Ma in the one case, 4 Ma in the other, in the skin target distance (f.s.d.) 20 cms. in the one and 25 cms. in the other, and in the thickness of the filter, 1.5 mm. Al. and 2 mm. Al. The factors used for each case are given in the synopsis of the case histories.

All types of psoriasis were treated from mild papular eruptions to severe geographic types in which most of the body surface was involved. The youngest patient was 6 years of age, the oldest 82. There was no selection of cases and no other form of treatment, either external or internal, was administered.

100 cases were treated. Of these a few will be presented as typical examples of the usual sequence of events which took place following irradiation. Unusual features will be illustrated by the case histories of the patients in which they occurred.

Case 3.

R.S.L., aged 19, male, was first seen on 8 Aug.46 with psoriasis on the forearms and on the legs, below the knees, the rest of the body being clear. The eruption was papular

and small guttate. It had first appeared 6 years before and had cleared completely with ointment therapy, but had reappeared a year before examination and had remained unchanged since in spite of treatment. 600 r in weekly doses of 200 r spread over six weeks was given. The cervical area was irradiated first and within a week changes in the lesions round the elbows were observed. The scales became finer and less adherent, and the guttae flattened. This improvement gradually extended down the forearms. No change was noted on the legs following cervical radiation, and it was not until the lumbar area was treated that the lesions on the legs began to clear. Healing was similar to that on the arms and gradually extended down the legs. By 8 Nov.46, six weeks after the last treatment, all the lesions had disappeared.

Case 12.

R.M., aged 35, male, was first seen on 7 Oct.46. with wide-spread psoriasis. There were small, irregular, heavily scaling plaques on the arms, legs and trunk (fig.12), as well as multiple guttate lesions. The scalp was covered by a massive, infiltrated crust. The lumbar area was irradiated first and an immediate response was noted. The scaling on the abdomen and thighs was greatly reduced, and, within three

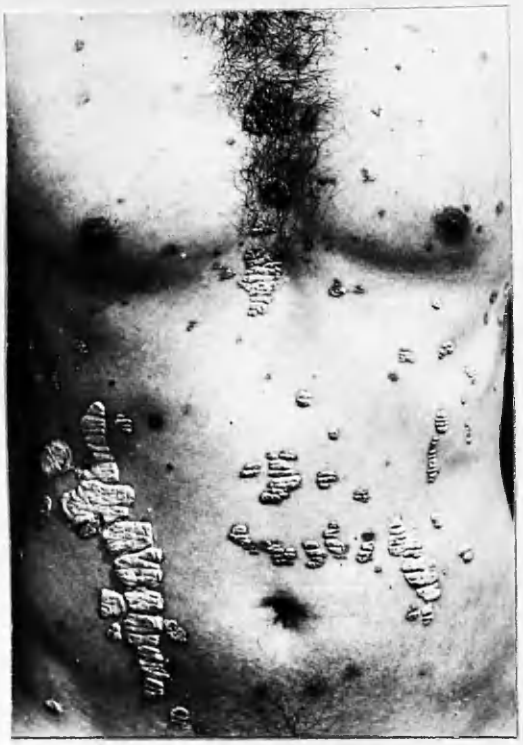

Fig. 12.

Case 12.

Chest and abdomen on 7 Oct. 46.

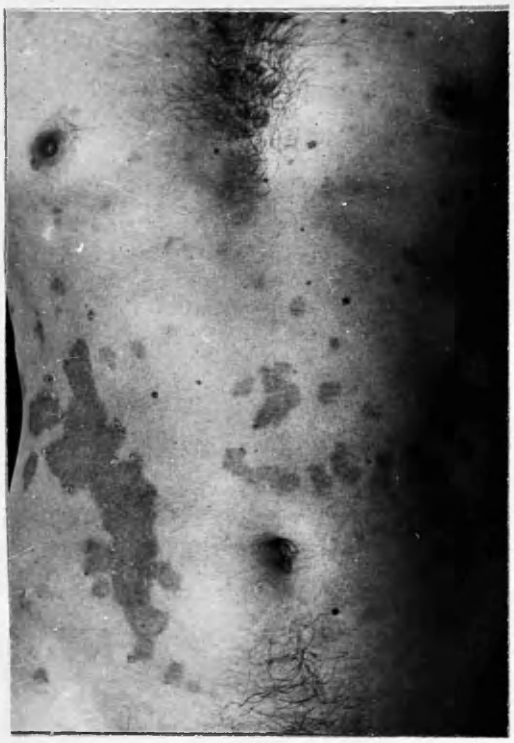

Fig. 13.

Case 12.

The same areas, 11 weeks later, showing only the residual brown pigmentation.

weeks, was to be seen only at the periphery of the plaques, the skin in the central part of which was of normal texture but showed a brownish pigmentation. Little difference was noted in the lesions on the upper part of the body following lumbar irradiation. The scaling on some of the guttae was reduced but nothing more. Response on the upper part of the body was observed after the first treatment to the cervical area. By 24 Dec.46 the patient was clear of psoriasis except for a faint brownish pigmentation (fig.13). By 8 Feb.47 this residual pigmentation had faded completely.

Case 16.

N.B., aged 18, male, was seen on 4 Nov.46. The legs and the scalp were mainly involved. The scalp was covered by numerous, large, circular, heavily scaling lesions, and on both shins, extending almost from the knees to the ankles, there was a large, irregular, infiltrated, heavily scaling plaque. Round the elbows were amassed many small, shiny, scaling papules. The patient complained of severe irritation on the legs. Treatment was applied to the lumbar area first and following the first 200 r the irritation disappeared from the legs. The plaques responded quickly, healing taking place in the centre. Healing gradually extended until only a narrow

edge with some 'stuck on' scales remained. There was no change noted on the scalp or round the elbows until the cervical area was irradiated. Only two treatments were needed to this area and by 16 Dec.46, six weeks after treatment began, there was no evidence of the previous psoriasis.

Case 26.

M.McF., aged 13, female, was seen for the first time on 25 Jan.47. The whole body was involved in a severe eruption in which all types of lesions, from small, scaling papules to fairly large, infiltrated plaques were represented. The plaque formation was mainly on the arms, buttocks and thighs (figs.14 & 16). The scalp was very heavily crusted. Itching was intense and there were numerous excoriations and a degree of secondary infection in some of the lesions. The excoriations showed a typical Koebner reaction - small psoriatic papules appearing along the scratch marks. The lumbar and cervical areas were irradiated on the same day. Although the patient was over 12, as she was small for her years and undernourished, it was decided only to give 100 r weekly to each area. There was a marked lessening of the irritation following the first treatment, and some of the smaller lesions had gone. Central healing then became evident

Fig. 14. Case 26. The arms as they appeared at the first examination.

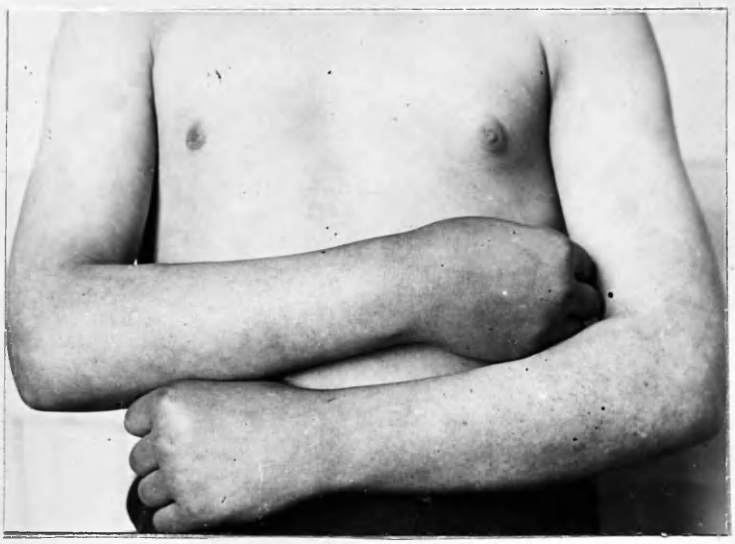

Fig. 15. Case 26. The arms completely clear 3 months later.

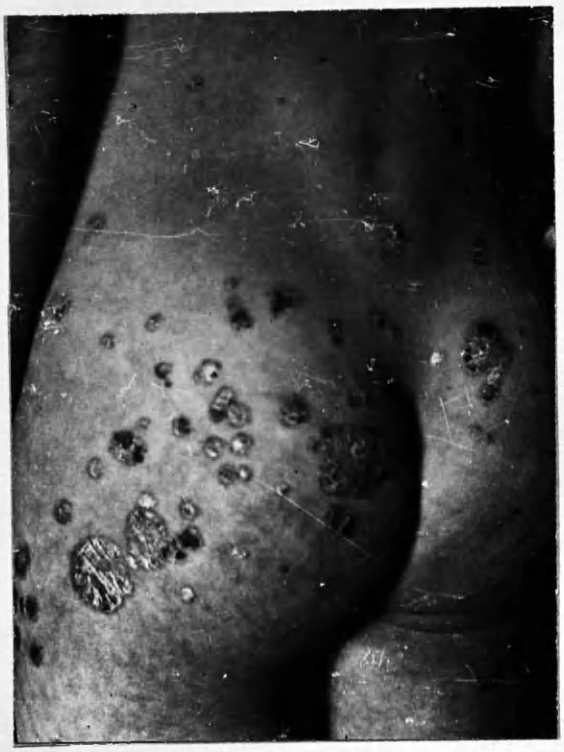

Fig. 16.

Case 26.

The buttocks as they appeared at the first examination.

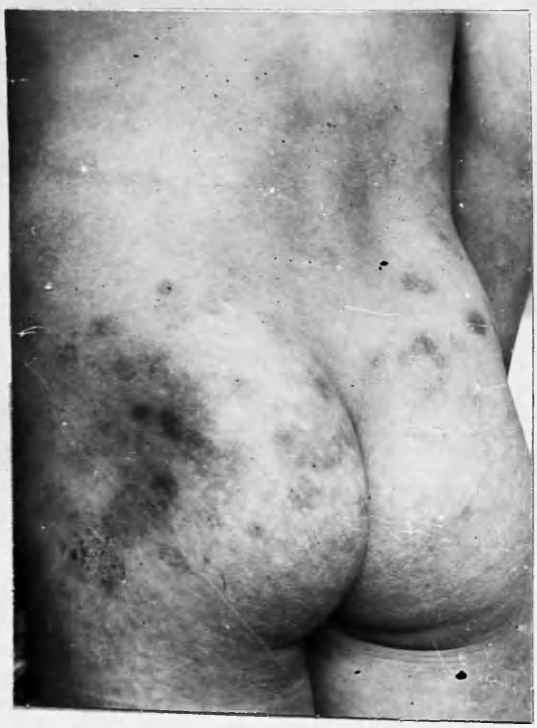

Fig. 17.

Case 26.

The buttocks, 3 months later, showing a faint pigmentation. This disappeared within a month.

in the plaques. After the third treatment the secondary infection became much worse, but this was controlled within a week with Penicillin cream 1,000 units/gm. The improvement in the psoriasis was steadily maintained and by 19 Apr.47 all that remained was a faint brownish pigmentation (figs.15 & 17). This had faded completely by 31 May 47, 4½ months after treatment was started.

Case 32.

I.H.D., aged 13, female was seen on 22 Feb.47 with a generalised eruption. On the legs, from the buttocks to the ankles, there were large, roughly circular, infiltrated plaques covered by thick scales. Plaque formation on the arms was confined to the elbows but a guttate eruption extended from the shoulders to the wrists. The scalp was covered by hard, raised, crusted lesions which spread round the hair margin and extended on to the forehead. On the trunk the eruption was papular with here and there small plaques. One area, only, was irradiated at each treatment. The response to therapy was immediate, many of the smaller papular and guttate lesions clearing up after one treatment, leaving just a faint reddish colouration. Healing in the plaques above and below the knees was from the centre, but in those round the knees

and elbows healing was from the periphery, causing the plaques to shrink gradually. The papular and guttate eruptions were the first to clear completely. In the plaques, except those round the knees and elbows, the central area of healing gradually enlarged, until only a narrow scaling border remained. This, in turn, broke up and disintegrated. A deep brown pigmentation persisted for some time at the site of the plaques, but by 21 Jun.47, four months after the commencement of treatment, this too had completely faded and the skin was clear of any abnormality.

Case 36.

C.H.F., aged 15, female, was seen on 15 Mar.47 with Psoriasis, which had first made its appearance 6 months before. There was a generalised involvement of the skin, the lesions varying from papules to small plaques. Scaling was moderately heavy (fig.18). Both the lumbar and cervical areas received 200 r at weekly intervals for three weeks. Improvement was noted following the first treatment, healing changes appearing first in the central part of the lesion. A steady improvement was maintained and all areas were clear of lesions by 21 Jun. 47, 3 months after the first treatment (fig.19). The scalp, in this case, was slow to respond at first, but once healing

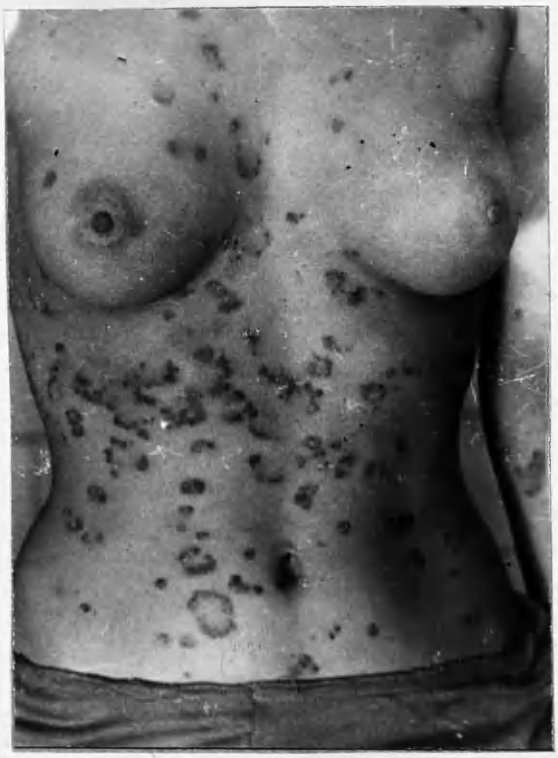

Fig. 18.

Case 36.

The chest and abdomen as seen at the first examination.

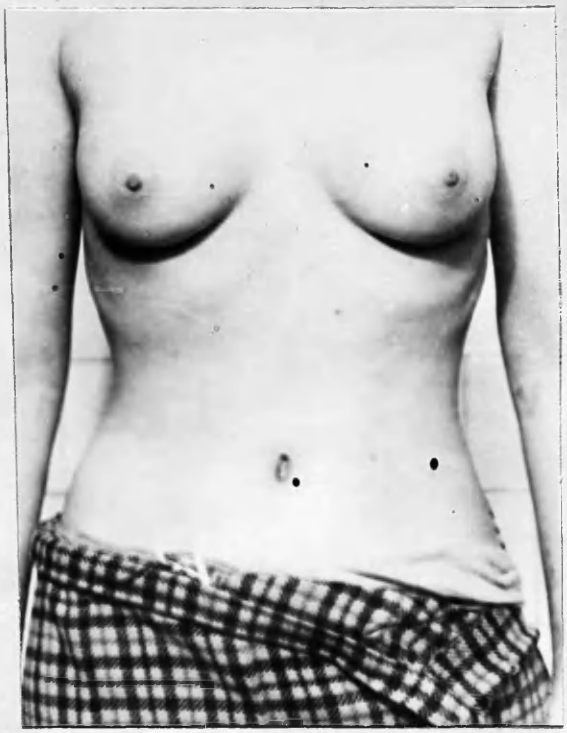

Fig. 19.

Case 36.

The same areas, 3 months later.

had started it cleared rapidly.

Case 43.

J.B., aged 22, male, was seen on 5 Apr.47. There was a strong family history, the patient's mother, two brothers and one sister also having psoriasis. It was first noticed three years before, when the patient was 19, and he had never been clear since. There was widespread involvement of the whole body, including the face, the eruption being mainly papular and guttate with, however, numerous small, circular and ovoid plaques (fig.20). The scaling on the smaller lesions was fine and silvery, while that on the plaques was tough and heaped up. The scalp was extensively involved. 200 r weekly, for three weeks, were given to the lumbar and cervical areas. The lesions on the face began to clear after one treatment and following the second treatment, overall improvement was noted. The plaques healed in the usual way, from the centre. It was observed that some of the guttae were slower to respond. A rapid improvement was maintained and two months after first being seen, only a faint, reddish brown, mottling of the skin was apparent (fig.21). Six weeks later this, too, had cleared and the entire skin surface was normal and healthy.

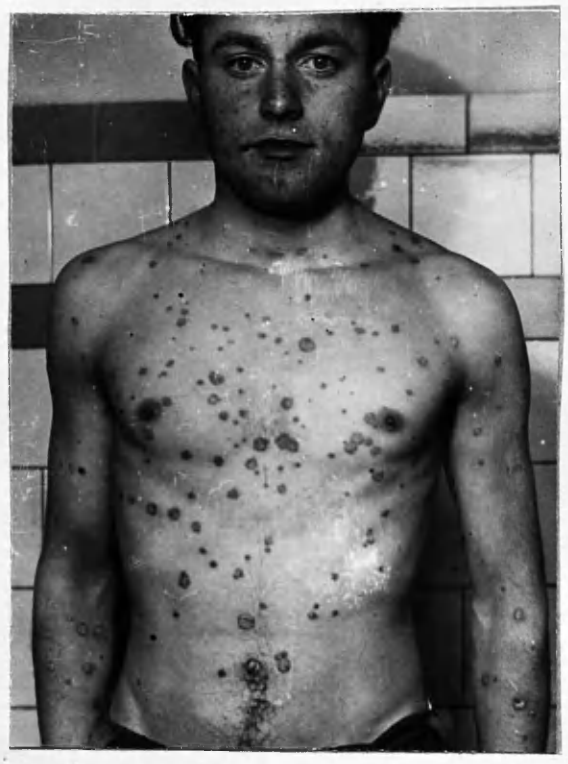

Fig. 20.

Case 43.

Showing the involvement of the face, chest and abdomen.

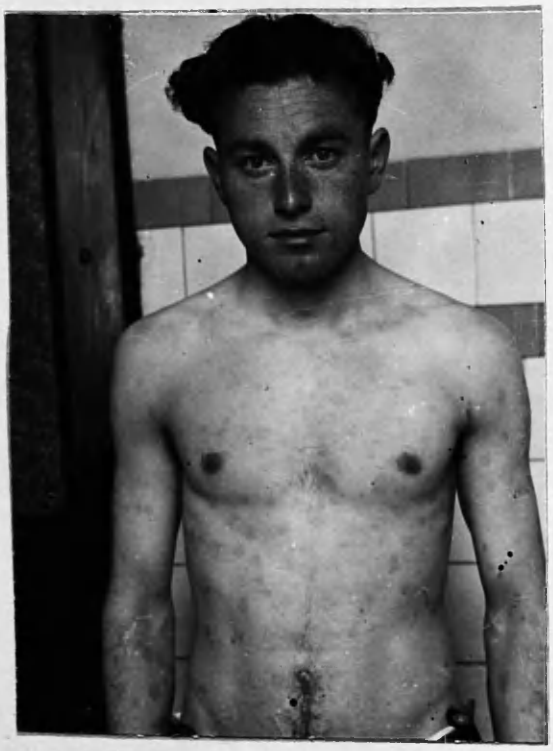

Fig. 21.

Case 43.

2 months later. The faint mottling can be seen. This cleared within 6 weeks.

Case 44.

R.B., aged 28, male, was the brother of the previous case. Psoriasis appeared for the first time 9 months before examination on 5 Apr.47. The eruption was generalised, but, in this case, the face was not affected. The lesions were mainly small, infiltrated plaques with larger and more irregular plaque formations on the arms and legs. The scalp was extensively involved, being covered by a thick, infiltrated crust. 200 r were given weekly, for three weeks to the lumbar and cervical areas. The response to treatment was immediate, the scaling being reduced, central healing started and the crust on the scalp broken up following the first treatment. The eruption cleared rapidly and six weeks after the start of treatment only a reddish-brown pigmentation remained and by 14 Jun.47, 10 weeks after the first treatment, all trace of the psoriasis had disappeared.

Case 53.

D.McC., aged 11, male, was seen on 18 Oct.47. There was a family history, the mother and a sister also having psoriasis. A widespread, bright fiery red eruption involved practically the whole of the body surface. The neck and the upper part of the chest were the least involved (fig.22). The face was

Fig. 22.

Case 53.

Showing the extensive and severe nature of the eruption when seen on 18 Oct. 47.

Fig. 23.

Case 53.

The same areas, 3 months later, showing complete recovery.

affected, as was the scalp. Irritation was troublesome. 100 r were given weekly, for four weeks, to the lumbar and cervical areas. Following the first treatment the colour had faded and the eruption assumed the appearance of a pink, scaling erythema, and the irritation had almost completely gone. There was a slight exacerbation of dull red, scaling papules on the face, after the second treatment, which soon subsided. There was a rapid improvement, so much so, indeed, that treatment was stopped after only 400 r had been administered to each area. Nine weeks after the start of treatment only a few scattered areas of faint erythema remained, and even those had cleared by the end of the third month (fig.23).

Case 55.

B.McK., aged 17, female, was seen on 25 Oct. 47 with psoriasis of 4 months duration. The whole body surface, except the face, was involved. On the legs there were large, irregular, infiltrated, erythematous plaques, covered by brittle, whitish, silvery scales (fig.24). On the arms and trunk the plaques were nummular and the scaling was heavier. The scalp was covered by numerous, heavily scaling, infiltrated lesions. 200 r at weekly intervals, for 3 weeks,

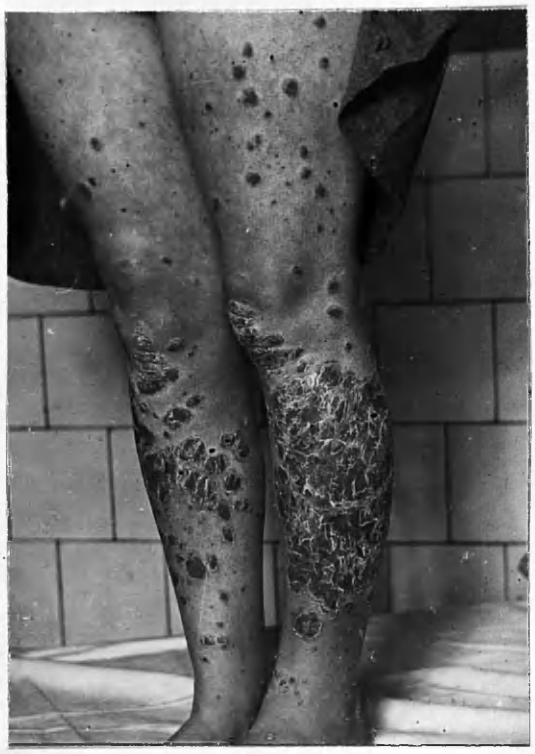

Fig. 24.

Case 55.

Shows the extensive involvement of the lower part of the legs.

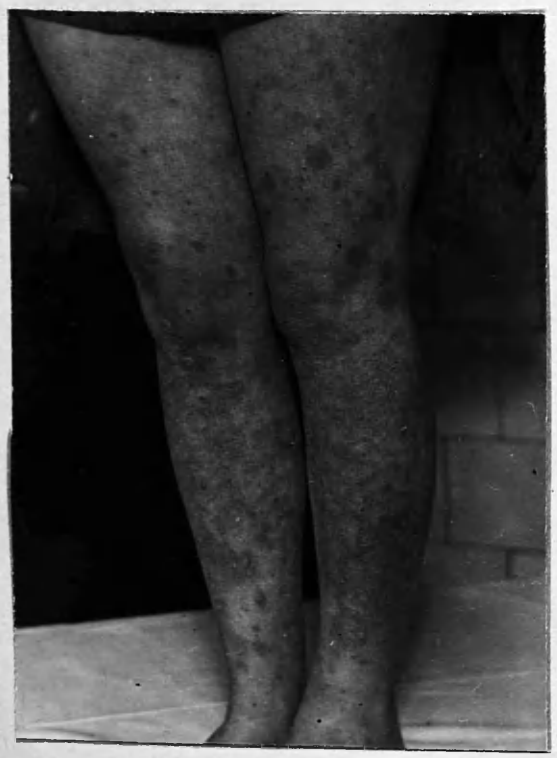

Fig. 25.

Case 55.

Four months later. The mottling, not unlike an erythema ab igne, can be seen. This pigmentation had cleared a month later.

were given to the lumbar and cervical areas. Following the first treatment some of the plaques on the upper parts of the body and arms showed a central depression. Scaling was much less and of a finer texture following the second treatment and the colour of the lesions had paled considerably. Many of the smaller lesions had disappeared, leaving a very faint pinkish stain. Central healing took place in the plaques on the trunk, but on the arms and legs the psoriatic tissue gradually changed its character and assumed the appearance of a finely scaling erythema, which, in turn, was replaced by normal tissue which grew in from the periphery, causing a gradual shrinking of the original lesions. The legs responded much slower and there were still numerous active lesions there when the scalp, trunk, and arms were clear. These, however, gradually healed and four months after the start of treatment the only abnormality was a reddish mottling of the skin on the legs, not unlike an erythema ab igne (fig.25). This, too, had gone when the patient was seen a month later.

Case 57.

H.R.McK., aged 18, female, was seen on 1 Nov.47 with psoriasis which had started two years before. The whole body

was extensively involved (figs. 26, 28, 30, 32). The back was one mass of raised, infiltrated, crusted tissue which stopped abruptly across the buttocks. There were large, irregular geographic plaques on the legs, back and front, and the whole extent of the arms, from the shoulders to the wrists, was covered by a mass of infiltrated, heavily scaling tissue which extended on to the backs of the hands. Across the breasts and on the chest and lower abdomen there was a moist, finely scaling erythema. The scalp was completely covered by a massive infiltrated crust. Irritation was severe. 200 r were given weekly for three weeks to the lumbar and cervical areas. Following the first treatment, the patient complained of increased irritation, but a clinical improvement was noted, scaling being reduced and the lesions on the breasts, chest and abdomen being dry and covered by fine brittle scales. After the second treatment the irritation had practically gone and there was a good clinical improvement. Scaling, especially on the arms, back, chest, abdomen and thighs, was greatly reduced and the infiltration was much less marked. A rapid improvement took place and, three weeks after treatment was started, large areas of new skin had replaced much of the psoriatic tissue. The rate of progress on the legs, from the knees down, was slower and there were still

Fig. 26.

Case 57.

The back as seen on 1 Nov. 47. The sharp line of demarcation between normal and abnormal tissue is well demonstrated.

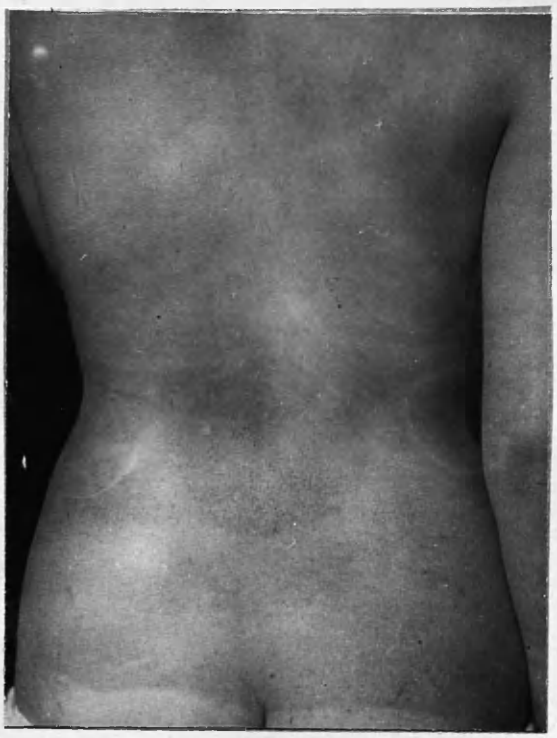

Fig. 27.

Case 57.

Three months later. A faint trace of the line of demarcation can still be seen.

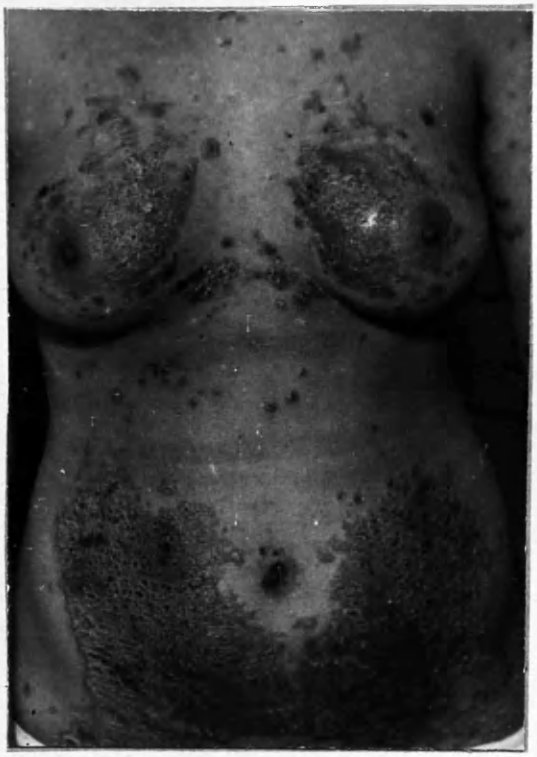

Fig. 28.

Case 57.

The breasts and abdomen. The moist, almost eczematoid, nature of the eruption in these situations can be seen.

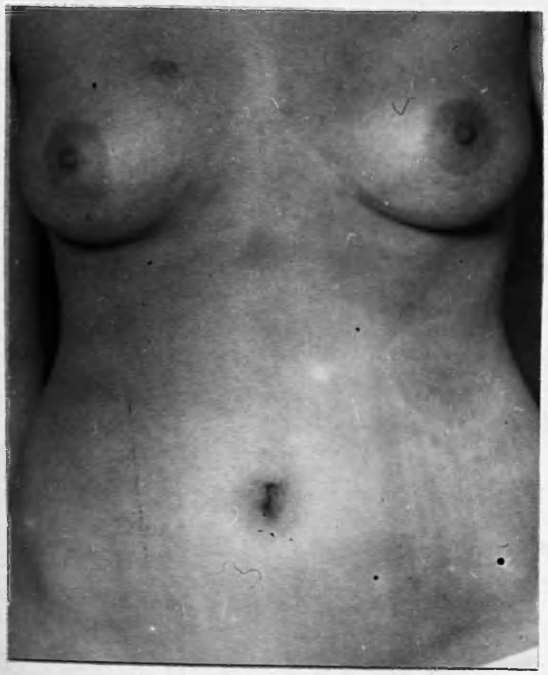

Fig. 29.

Case 57.

Three months later. The skin shows complete recovery.

Fig. 30. Case 57. The arms as seen at the first examination.

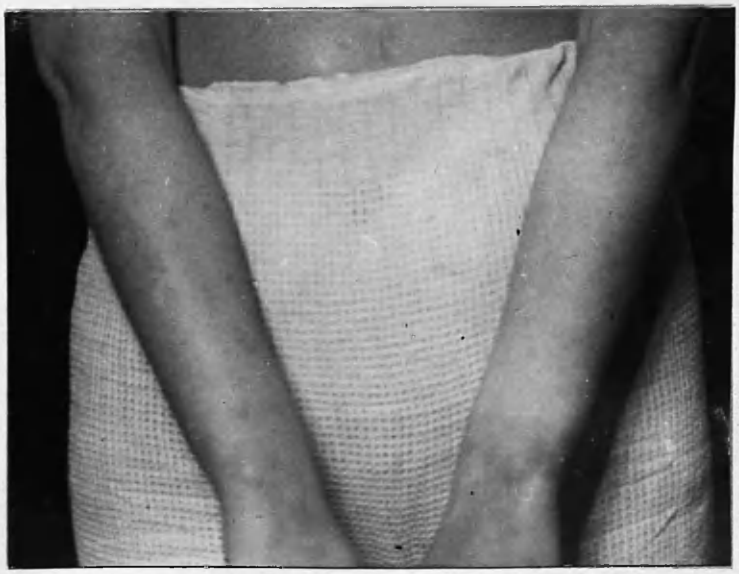

Fig. 31. Case 57. Three months later. Recovery is complete.

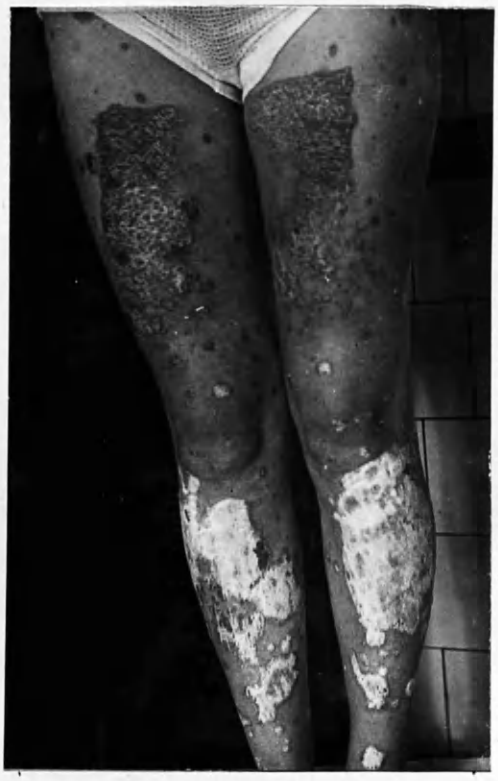

Fig. 32.

Case 57.

The legs as seen on first examination.

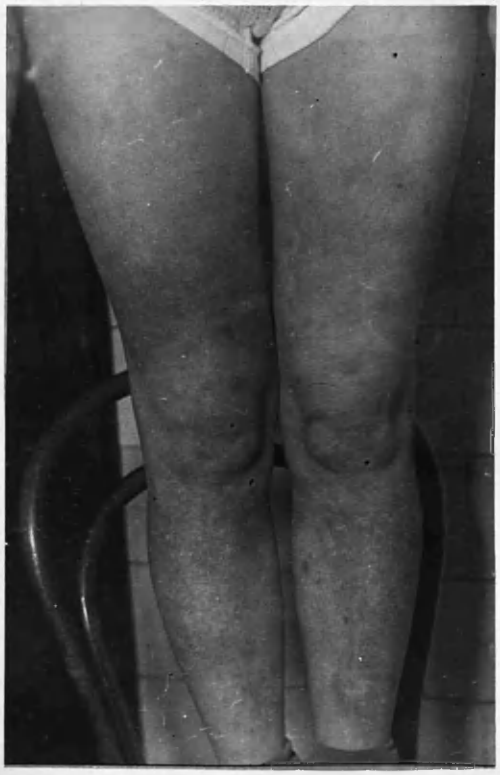

Fig. 33.

Case 57.

Three months later. A very faint pigmentation can still be seen.

active lesions present when the rest of the body was clear. Seven weeks after the start of treatment, only the legs below the knees showed any active psoriasis. All other areas were clear. In order to try and hasten recovery on the legs, 100 r were given to the popliteal fossae at weekly intervals, for three weeks, the technical factors being the same as for the spinal irradiation. The response was immediate and within a month all that remained on the legs were a few scattered, small, white scales, which, when removed, showed normal skin underneath. On 24 Jan.48, 12 weeks after the start of treatment, there was no trace of the previous widespread and severe psoriasis (figs. 27, 29, 31, 33).

Case 73.

I.W., aged 61, female, was seen for the first time on 5 Dec.47, with psoriasis which had started a month before. This was the first time the patient had had psoriasis and it followed a very severe Herpes zoster. There was an acute, widespread eruption involving the abdomen, pubis, groins, genitalia, the lumbo-sacral region, buttocks and thighs. The tissue over these areas was dull red and infiltrated and was covered by dull white scales (fig.34). The irritation was

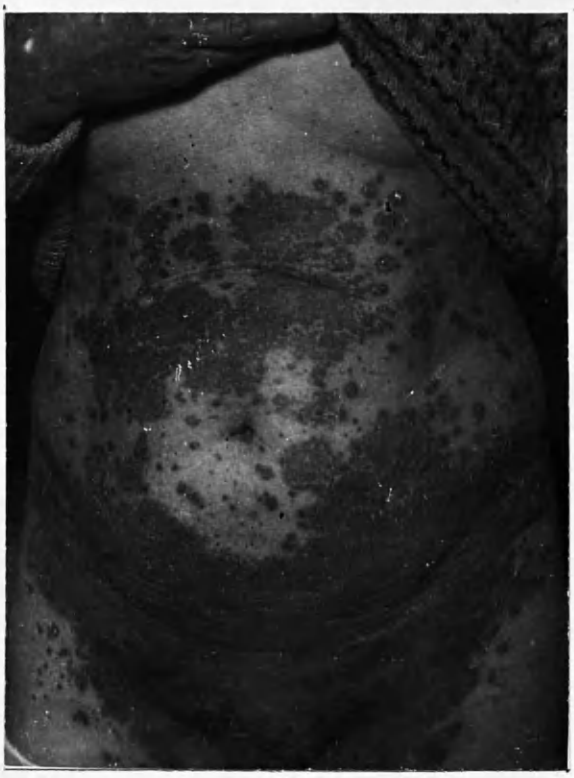

Fig. 34.

Case 73.

As seen on 5 Dec. 47.

Following the first treatment the isolated patches coalesced to form one complete mass.

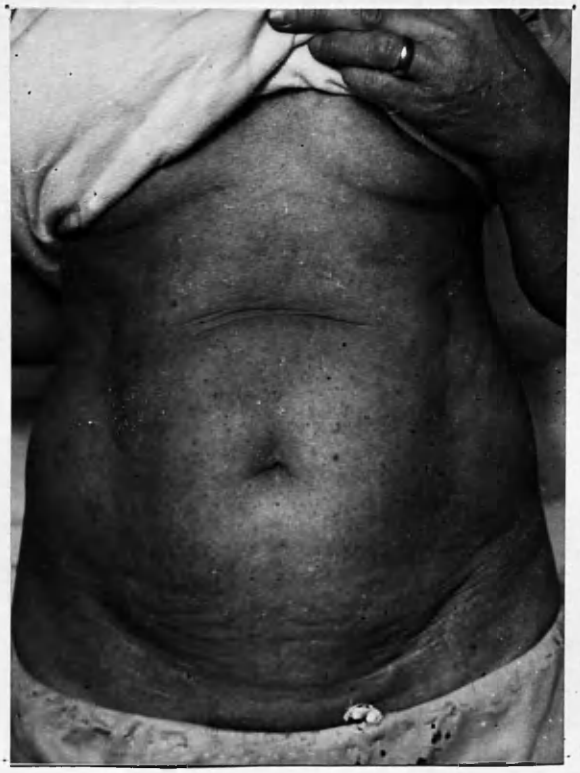

Fig. 35.

Case 73.

The same area six weeks later.

intense. 200 r at weekly intervals for three weeks were given to the lumbar and the cervical areas. Following the first treatment some outlying guttae and small plaques coalesced with each other and with the main area of abnormal tissue, so that the area of involvement was more extensive. The irritation in the original area was less, but in the spreading part it was very intense. After the second treatment there was no further spread and the irritation all over was very much less. The colour, too, had faded and the scales were drier and more brittle. A remarkable difference was noted after the third treatment, all the scaling had gone, the colour was much paler, being more a pinkish erythema, there was no longer any irritation. By 13 Jan.48, six weeks after the start of treatment, all that remained were a few scattered, circular areas of redness on the inner aspect of the thighs. Three weeks later these had cleared and all areas of the skin surface were healthy and the skin was of normal texture (fig.35).

One case in the series was given a massive dose to each area instead of the usual fractional doses. At the end of two months a very slight response only was noted. Fractional therapy was then given and an uninterrupted

recovery resulted.

Case 27.

R.J.M., aged 20, male was seen on 27 Jan.47 suffering from psoriasis. The whole body was involved, including the face. On the limbs, which were the most severely affected there were numerous large, heavily crusted, infiltrated, geographic plaques. On the trunk the lesions were mainly guttate with some scattered small, nummular, crusted plaques and the scalp was covered by a massive, infiltrated crust. 500 r were administered to the lumbar area followed, a week later, by a similar dose to the cervical area. Three weeks after treatment the irritation, which had been severe, had gone but, beyond a reduction in the scaling, little change was seen in any of the lesions. No further change was noted by 27 Mar.47, two months after the treatment. It was then decided to give a further course of fractional doses, 200 r weekly to each area. Improvement was noted following the second treatment, scaling almost entirely disappearing leaving the lesions as red, raised blotches on the skin. New tissue gradually appeared in the lesions and enlarged until, by 6 Jun.47, ten weeks after the start of the second course, only a dull reddish pigmentation remained with some fine

scaling at the periphery.

Further review in the case just described was not possible. The patient was a serving soldier and was posted to another area shortly after the last review. The response to a massive dose was not encouraging and real benefit was not obtained until a course of fractional dosage was given. From then on improvement was steadily maintained and at the final review all that remained of the previous extensive psoriasis were areas of dull red pigmentation with a few fine scales at the periphery.

A severe exacerbation of the condition following therapy was observed in some cases in the series.

Case 8.

C.P., aged 21, male, was seen on 26 Aug.46 suffering from psoriasis of 3 years duration. The back and the thighs were the areas mainly affected, the lesions being small, circular and ovoid in shape, and covered by shining translucent scales. The limbs were practically clear. 200 r were given to the lumbar and cervical areas at weekly intervals, only one area being irradiated at a time, till a total of 600 r had been given to the cervical area and 400 r

to the lumbar area. Following the second treatment a worsening of the condition was observed. Many fresh lesions appeared on the face, trunk and arms, areas which, before, had been practically clear. The new lesions were small, irregular areas of finely scaling erythema. On the trunk and arms they tended to remain discrete, but on the face they coalesced to form larger patches. The irritation was intense. This state of affairs persisted for two months without any change for the better being apparent. Then suddenly, without further treatment of any kind, a rapid improvement started and within six weeks all that could be seen were some small, dull red blotches on the forehead and a few widely scattered small areas of finely scaling, faint erythema on the trunk and limbs. The patient was not seen again until 6 Feb.47 when a complete and minute examination of the skin revealed only two small, flat-topped, non-scaling papules on the right elbow and one on the left elbow.

Case 33.

A.D.B., aged 32, female, was seen on 7 Mar.47 suffering from psoriasis of 7 years duration. Only the limbs and scalp were affected. On the legs the lesions consisted mainly of small irregular plaques which were most numerous between the

knees and the ankles. The arms, between the elbows and the wrists, were covered by a mass of small circular guttae about the size of a small pea. On the scalp there were a few scattered, heavily scaled papules. The trunk and face were clear. 200 r at weekly intervals, for three weeks, were given to the lumbar and cervical areas. Following the second treatment the central areas of the plaques on the legs were paler in colour and after the third treatment definite signs of healing could be seen in the plaques. There was absolutely no change on the arms or on the scalp. A month after the third treatment had been given a severe exacerbation of the condition developed on the upper part of the body. A generalised, extremely itchy, papular, eruption appeared on areas previously unaffected - at the hair margin, on the forehead, chest, back, abdomen and upper parts of the arms. It was noted that the eruption had a peculiar coppery colour and that the papules were grouped together in a way not unlike the vesicles in Herpes zoster. Meanwhile, healing in the plaques on the legs continued. Within three weeks the coppery colour faded and the generalised papular eruption became more erythematous. By the end of May 1947, about 12 weeks after treatment was started, there was very little to be seen either of the original lesions or of the papular exacerbation.

On the legs some faint brownish pigmentation persisted with here and there minute scaling papules and round the knees there was a collection of small non-scaling papules. The arms were clear, except for some flat-topped papules round the elbows. On the scalp there was a fine dandruff-like scurf. This latter cleared away but a few small papules, just discernable, persisted and still persist round the knees and elbows.

In the last case two points of interest were noted. Firstly, the lesions on the legs responded almost at once while those on the arms showed no improvement at all and even when the condition became much worse on the upper part of the body the lesions on the legs still maintained a steady improvement. Improvement on the arms did not take place until the secondary eruption had begun to subside. The second point of interest was the zosteriform appearance of the papules and the coppery colour of the base upon which they were set.

An exacerbation of the condition developed in one case five months after the start of treatment and after a slow but satisfactory improvement had been established. This persisted for six weeks before it began to subside, no further treatment having been given in the meantime. The interesting

feature, however, was the rapidity with which the condition cleared after this. Before the worsening of the condition the response to treatment had been slow but now the psoriatic tissue was rapidly replaced by good, sound, healthy skin.

Case 9.

Mrs.A., aged 62, female, was seen on 2 Sept.46 with an extensive and severe psoriasis. It had developed over 9 years before, after the patient had recovered from a severe nervous breakdown following the very sudden death of her husband. With the exception of the face, the palms of the hands and the soles of the feet, the entire body was involved. There was one mass of dull red, shiny, beefy looking, raised, infiltrated tissue. The backs of the hands and the neck were not so extensively involved, but here there were numerous, round, raised lesions similar in appearance to the main mass. The junction of the abnormal tissue with the very small areas of skin not involved was well defined. There was no scaling but when the surface of the abnormal tissue was scratched fine, small, silvery scales were produced and a silvery streak was left behind. The patient complained of intense irritation generally, with extreme discomfort in the groins and

genitalia. 600 r, in weekly doses of 200 r, were given to the lumbar and cervical areas, each area being irradiated at different times. A general paling of the colour of the psoriatic tissue was noted after the fourth treatment and scaling became more pronounced, the scales being fairly large and translucent. Seven weeks after the start of treatment the condition had the appearance of an extensive exfoliating dermatitis. During this time the irritation was variable, one time it was less, the next as bad as ever. Minute areas of normal skin then made their appearance in the midst of the abnormal tissue and slowly united to form larger areas. Improvement continued slowly until 6 Feb.47 when a worsening of the condition was observed. This increased and a week later a severe exacerbation of the condition had developed. The irritation became almost intolerable and the abnormal tissue reverted to its original appearance. To ease the irritation Tab. Phenobarb. gr. ii, nocte were given, but no other treatment. This continued for six weeks. At the end of this time the irritation eased considerably and although there was no improvement in the skin the patient was much happier. Two weeks later the appearance was once again that of an exfoliating dermatitis and improvement then became rapid. Large areas of healthy

skin replaced the abnormal tissue, the new tissue growing both in the midst of the abnormal tissue and growing in from the periphery, so that the psoriatic tissue became broken up into smaller units and gradually diminished in size. Ten weeks after the exacerbation had subsided the only abnormality to be seen was a small circular area of finely scaling erythema in the lumbo-sacral region. This persisted for a further three months and then suddenly disappeared. In this case almost a year elapsed before the psoriasis finally cleared.

Another unusual feature noted in some cases, was, what appeared to be a latent phase. Improvement continued so far and then remained static for a varying period. Then, suddenly, without further treatment, the condition began to clear and usually did so fairly quickly. This is well illustrated in the following case.

Case 42.

E.M., aged 29, female, was seen on 5 Apr.47. She was suffering from psoriasis of 18 years duration. A brother also suffered from psoriasis. There was a widespread eruption involving all parts of the body. On the trunk the eruption

was mainly guttate with some small plaque formations, especially on the back. On the limbs there was mostly plaque formation with scattered guttae and papules. There were a few papules on the face and the scalp was extensively involved. Scaling was pronounced on all the lesions. 200 r at weekly intervals, for three weeks were given to the lumbar and cervical areas. The colour of the smaller lesions was paler following the second treatment and the scaling was reduced. After the third treatment most of the guttate lesions had cleared and the plaques on the trunk and arms were healing centrally. Beyond a reduction in the scaling little change was noted on the plaques on the legs. Improvement continued slowly till 14 Jun.47, ten weeks after the start of treatment. Then the condition remained static and no change either for the better or for the worse was observed. This latent phase persisted for almost five months and it was not until 28 Oct.47 that definite signs of further improvement were noted. During this period no further treatment was given. Within two months the trunk, arms, buttocks, thighs and scalp were clear except for a few isolated collection of scales. On the legs, below the knees, there were large patches of dull red staining, corresponding to the plaques, with some isolated scaling papules at the

peripheral parts. This staining on the legs persisted for some time gradually becoming paler, until there was just a very faint reddish marling on the shins. Ten months elapsed, in this case, from the beginning of treatment until the psoriasis finally cleared.

Another feature worthy of note was that, in some cases, new lesions developed but they healed spontaneously, sometimes within 48 hours. In the case about to be described, complete recovery was followed by a severe, generalised relapse, which responded to a modified course of therapy, and a second relapse cleared spontaneously without any further treatment being given. In this case, also, the condition became worse during the course of the first treatment.

Case 23.

E.P.L., aged 8, female, was seen on 18 Jan.47 suffering from psoriasis which had started two years before following an injury to her arm. There was a widespread guttate eruption involving the trunk and limbs and the scalp had numerous scaling papules. 100 r weekly were given to the lumbar and cervical areas to a total of 600 r. Scaling was reduced

following the first treatment. After the third treatment the lesions on the scalp became more numerous and heavily crusted and on the body many fresh papules appeared. Treatment was continued and the psoriasis became worse. The exacerbation continued for three weeks before it stopped and a general improvement became apparent once more. Healing continued satisfactorily and by 14 Jun.47, six months after the start of treatment all areas were clear, except the lower part of the legs where some guttae persisted. The patient was not seen again for two months when she reported with a relapse. This was widespread, the legs, arms, trunk and scalp being involved. The eruption was made up of papules, guttae and plaques, the latter being confined to the legs. A second, modified, course was started, the total dosage being 300 r in weekly doses of 100 r. Improvement was apparent following the second treatment, the lesions being paler in colour and scaling reduced. Improvement was maintained and no worsening of the condition took place this time. Within two and a half months of the start of the second course of therapy, recovery was complete. A month later there was a further relapse, again widespread. This time, however, the eruption remained papular, the papules being covered by fine, white, translucent scales. On the scalp thick crusting

developed. No further treatment was given and at the end of two months the eruption began to clear. At the end of a further two months recovery was complete, except for a few papules on the forehead.

Not all the cases responded to treatment satisfactorily as the following case illustrates.

Case 15.

J.W., aged 37, male was seen on 30 Oct.46. He looked undernourished and of poor physique and gave a history of chronic bronchitis and chronic dyspepsia. He had suffered from psoriasis for 9 years. There was a widespread eruption involving all areas of the body. The chest, abdomen, sides and back were covered with large, heavily crusted, infiltrated, geographic plaques and gyrate configurations (fig.36). On the arms and legs the lesions were more nummular. The face was covered with numerous erythematous, scaling lesions and the scalp was covered by a thick, infiltrated crust. 200 r were given weekly to the lumbar and cervical areas, each region being treated alternately, a total dosage of 600 r being given. The patient was very irregular in his attendances for treatment and as long as five weeks elapsed in one

Fig. 36.

Case 15.

The back showing the extensive involvement when seen at first.

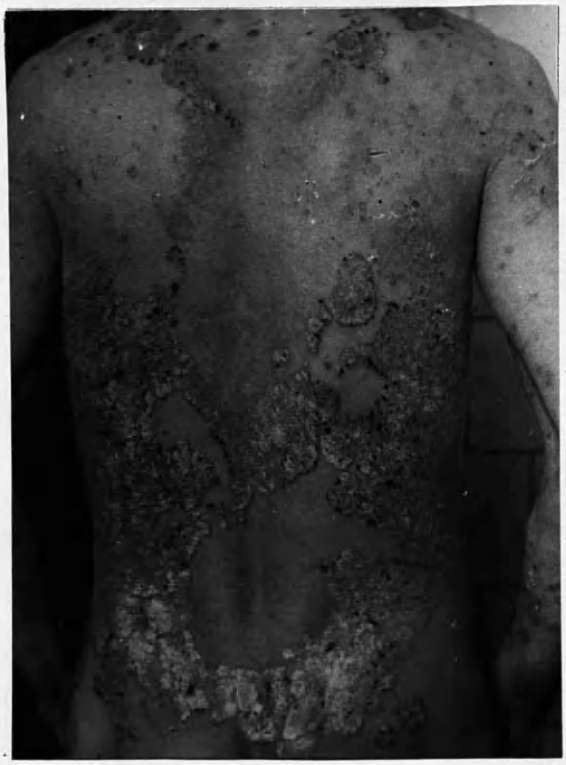

Fig. 37.

Case 15.

A year later. Very little change is seen in the condition.

instance between two treatments. An improvement was noted at first but by 15 Mar.47, five months after the start of treatment, there was little change from the original condition to be seen. A second course of therapy was then started, both areas being treated on the same day. The patient attended better this time and 600 r were given within three weeks. Following treatment, however, eight weeks elapsed before he was seen again. During this time there had been an improvement. The lesions on the limbs were clearing and on the trunk new skin had replaced some of the psoriatic tissue, especially at the periphery of the plaques, the centre remaining as heavily crusted as before. A further four months elapsed before he again presented himself for review. The scalp and face were completely clear and on the limbs most of the plaques had cleared leaving faintly pigmented skin with, here and there, small serpiginous and papular, scaling lesions. On the trunk, however, the heavily scaling plaques persisted, not as massive as at first, but still covering large areas (fig.37). By this time a year had elapsed since the patient was first seen. A review three months later showed no further change. The patient has not been seen since.

When the first course of treatment failed to produce

much change in the condition it was thought that this was due to the irregular and sometimes lengthy intervals between treatments. With the second course, however, this could not be blamed for the indifferent response, as the treatment this time was given at the proper times. An interesting point was the way in which what little healing there was on the trunk took place. Instead of the usual central healing, new tissue grew in from the periphery causing the plaques to shrink, the central part remaining heavily crusted and infiltrated.

It was noted that when the lumbar area was irradiated improvement was seen only on the lower limbs and on the lower part of the trunk. Cervical irradiation was necessary before improvement took place in lesions on the upper limbs, on the upper part of the trunk, the face and the scalp.

Healing in the plaques and large guttae, in the large majority of cases, began in the centre. The sequence of events was; scaling became finer and a depression appeared in the centre of the lesion (fig.38); new tissue then appeared, at first very minute, but gradually enlarging until only a thin rim of active, scaling psoriasis remained (fig.39); this, in turn, became broken up by bands of new skin cutting across

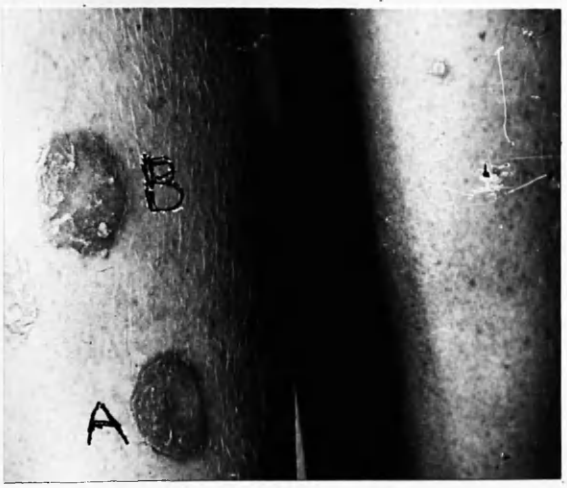

Fig. 38.

A. The initial stage of healing. A depression has appeared in the lesion.

B. The next stage. A minute area of normal tissue has appeared in the centre.

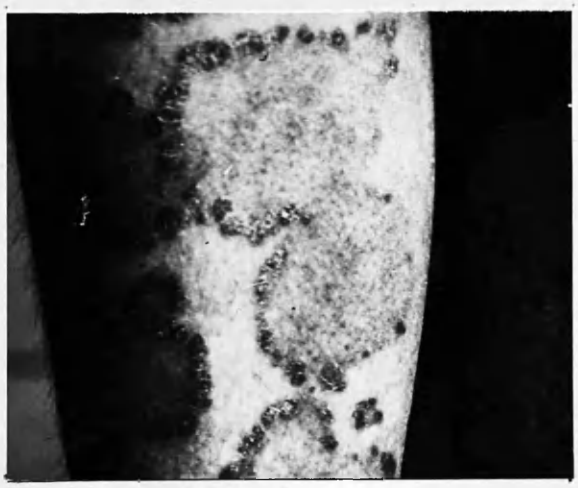

Fig. 39.

The narrow active border left when the centre of a plaque has healed. The next stage in which this becomes broken across is also shown.

it, leaving isolated, crescent-shaped lesions which became smaller in size and finally disappeared. Pigmentation was observed in nearly all cases which varied from a deep brown to a faint reddish brown. This pigmentation did not persist for long.

In some cases healing began at the periphery of the plaques which gradually decreased in size. When the heavy scaling which usually persisted in the centre dropped off, the skin underneath was of normal texture. Pigmentation, in these cases, was very faint and was of short duration.

Yet another healing process was observed. Lines of healthy tissue appeared within the plaques and by lengthening and joining together gradually broke the plaques up into small units. At this stage the plaques had a honeycomb appearance. The lines of normal tissue broadened and the abnormal tissue gradually shrunk until it was completely replaced by healthy skin. This method of healing was observed most frequently in plaques round the knees and elbows.

Smaller lesions, such as papules and small guttae became flattened and paler in colour and when the scale, which was dry and brittle, dropped off healed tissue was found underneath. A very faint stain, which disappeared quickly, was left behind.

In a few cases the psoriatic lesions changed their appearance to that of patches of exfoliating dermatitis which later became a finely scaling erythrodermia. The colour then gradually faded and scaling disappeared, healthy skin taking its place. When this happened there was no residual pigmentation.

In general the lesions on the lower part of the legs, below the knees, were slower to respond to treatment than were lesions on other parts of the body. Lesions in this situation often persisted when all other areas were clear. This is illustrated in figs.40 - 43. Figs. 40 and 41 show the appearance of the arms and the legs when seen at first. Figs.42 and 43 show the same parts seven weeks later. The skin on the arms had almost completely recovered but little change was noted on the legs below the knees. On the thighs, too, marked improvement had taken place. In cases where recovery below the knees was unduly slow, the popliteal fossae were irradiated. 100 r were given weekly to both fossae, using the same technical factors as for spinal irradiation, to a total of 300 r. In most cases healing on the lower part of the legs was hastened in this way. In the main lesions nearest to the sites of irradiation were the first to show response, although this was not a constant feature.

Fig. 40.

Case 57.

The arms and legs as seen at the first examination.

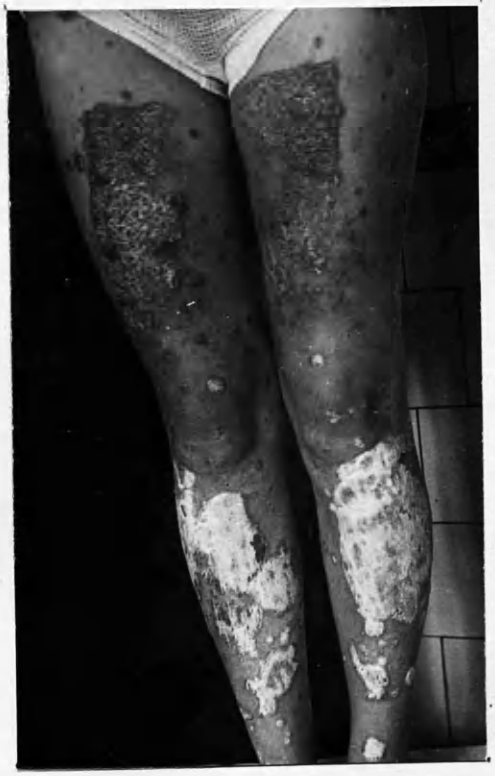

Fig. 41.

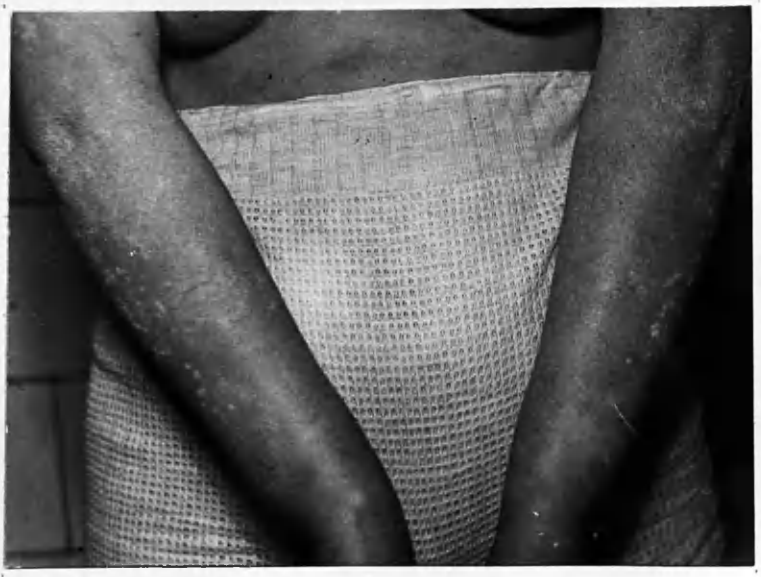

Fig. 42.

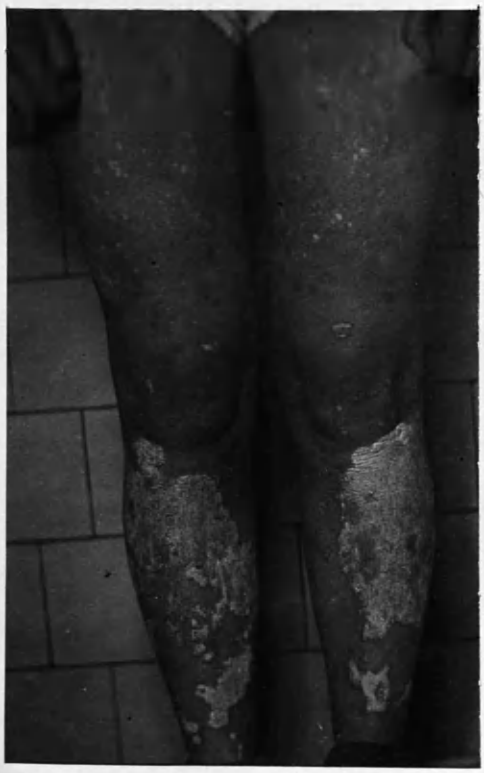

Fig. 43.

Case 57.

Seven weeks later. The arms have almost completely healed but there is little change below the knees.

Within three months from the start of spinal radiation all areas affected had recovered completely.

Lesions present on the areas irradiated, i.e. those receiving direct radiation healed quickly as a rule, but this was by no means a constant finding, lesions in these situations sometimes persisting when neighbouring ones had cleared. In a few cases an eruption appeared over the lumbar and cervical areas only after irradiation and it was often slow to heal.

In cases where pruritus was a predominant symptom relief often followed the first treatment and the irritation was the first thing to completely disappear. When there was an exacerbation of the condition itching became intense, even in cases where before it had not been troublesome, and relief from itching was the first indication that the exacerbation was subsiding. In most instances the fresh eruption was papular in appearance and the original lesions became swollen and relapsed to an acute phase. Following such an exacerbation a quick recovery was usually effected. In one case, described earlier (Case 33), an exacerbation of the condition developed on the upper part of the body while the lesions on the lower part of the body maintained a steady improvement. No improvement was noted in the lesions on the upper part of the body before the exacerbation, but, as soon as it had subsided, they also began to heal and

did so quickly.

Reference has been made to 'evanescent spots', small lesions, usually papules, which appeared suddenly, either on parts previously unaffected or on parts from which an eruption had cleared. These, for the most part, disappeared within three days but some remained for as long as a fortnight before going. The patient usually complained of slight irritation in them.

The time taken for complete clearing of an eruption, including the disappearance of any residual pigmentation, varied from six weeks to a year from the time treatment was started, but in the majority of cases it was from three to six months.

Table 2 sets out the details of the results. It has been divided into four age groups, 6 - 12, 12 - 30, 30 - 45, 45 upwards. The observation was made during the survey that the response was better in the younger age groups. Up to 30 years of age the percentage of cases in which an eruption cleared completely or was markedly improved was high. Over 30, the percentage of cases responding satisfactorily to spinal radiation fell sharply. This could be accounted for by the fact that in many patients in the higher age groups the condition was of many years duration. It should be noted

Table 2

Age group	Number of cases treated	The eruption cleared or improved	Unimproved
6 - 12	16	15 (93.8%)	1 (6.2%)
12 - 30	44	40 (90.9%)	4 (9.1%)
30 - 45	26	20 (76.9%)	6 (23.1%)
45 upwards	14	8 (57.1%)	6 (42.9%)
	100	83 (83%)	17 (17%)

Table 3

Number of cases treated	Cleared or improved with one treatment	Relapsed	Treated a second time	Cleared or improved a second time	Relapsed again
76	65	15	9	9	5

that in all cases some measure of response was observed but, where any gross amount of abnormal tissue persisted, the case was regarded as unimproved.

Spinal radiation as a therapeutic measure will be discussed later and it is for this reason that Table 3 has been included. In it the number of cases relapsing is given. Cases observed for six months or less are not included. This accounts for the difference in the figures in the column headed "Treated" in the two tables. It was noted that in the majority of cases the relapse was not as severe as the original condition. A noteworthy feature was that the cases treated a second time all responded to the second course of therapy. In those cases relapsing a second time no further x-radiation was given.

This review of 100 cases shows that roentgen-rays applied to the spine over the lumbar and cervical sympathetic enlargements produces a beneficial effect in a high percentage of patients suffering from a generalised psoriasis eruption.

A suggestion as to the mechanism producing this effect will be discussed following a review of a second series of cases in which Carbachol, a drug which reproduces the reactions of acetylcholine in the body, was administered.

Chapter 4

ACETYLCHOLINE

CHOLINE is a vasodilator and as a constituent of lecithin and sphingomyelin has a wide distribution in the body.

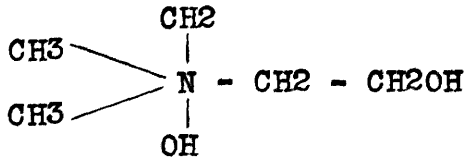

Choline

ACETYLCHOLINE is the only ester of choline found in animal tissues and more is known about its physiological significance than of any of the other vasodilator substances.

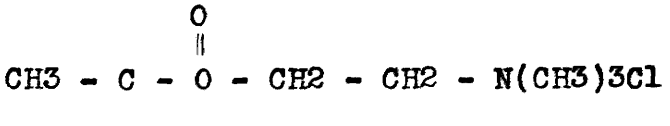

Acetylcholine chloride

The activity of choline is increased by at least one thousand times after acetylation. There appears to be very little free choline in the body, and the amount of

acetylcholine, rather than choline, appears to vary under physiological conditions. Nerve fibres which liberate acetylcholine are called Cholinergic.

The liberation of acetylcholine at cholinergic nerve endings is the result of stimulation of the corresponding nerve cells. The fact that it does not continue to act indefinitely after production is due to the fact that it is rapidly inactivated by hydrolysis to choline and acetic acid by means of an enzyme, cholinesterase, contained in blood and other body fluids. Thompson and Whittaker (29) have shown that rat and human skin contains a specific cholinesterase. This cholinesterase was found to be highly sensitive to inhibition by eserine, and to be distinct from a non-specific esterase also present, capable of splitting simple esters and fats such as methyl butyrate and tributyrin.

In the resting phase acetylcholine does not exist as such but is stored as choline. By acetylation, on nerve stimulation, it is transformed into acetylcholine. Potassium is liberated after nerve stimulation and therefore it is reasonable to suppose that this is the mechanism whereby nerve stimulation releases acetylcholine from nerve endings. Brown and Feldberg (30) suggest that the liberation of acetylcholine under normal circumstances is dependant upon

the movement of K ions accompanying the preganglionic impulse and that the appearance of K ions at the synapse also conditions the actions of acetylcholine upon the ganglion cell. Mann et al (31) found that the effect of the K ion was to increase the permeability of the nerve cell so that acetylcholine diffuses through the cell membrane at a greater rate than in the absence of potassium.

von Muralt (32) in discussing the relationship between the functions of acetylcholine and vit BI, states that 'bound' and 'free' acetylcholine exist together in nerve tissue. He also states that the K ion probably has a direct influence on the equilibrium between 'bound' and 'free' acetylcholine. The presence of pyruvate and vit BI co-carboxylase appears to be necessary for the formation of an acetylcholine reserve upon which the nerve can draw in the event of prolonged stimulation (such stimulation might result from chronic focal sepsis or prolonged nervous tension). The vit BI and co-carboxylase have been shown to exist in the myelin sheath, as also does cholinesterase. The myelin sheath should therefore be regarded as a storage battery in which acetylcholine synthesis takes place from phosphatide and glucose pyruvate breakdown. During this synthesis phosphate is set free from the phosphatide with the liberation of

choline. The phosphate is taken up by acceptor systems, such as creatin or vit BI, which play an important part in the maintainance of the resting potential of nerve. Vit BI as a phosphate donator and receptor, with its co-carboxylase activity in the diphosoxylated state is an essential factor in the excitation process of peripheral nerve. Acetylcholine formation and mobilisation of energy seems to be connected with co-carboxylase activity during or shortly following excitation. The function of the system is most probably one of recharging. After stimulation the vit BI gives up its phosphate again to form further phosphatide with the choline resulting from hydrolysis of the acetylcholine by cholin-esterase.

Acetylcholine is liberated at all preganglionic nerve endings, at all parasympathetic post ganglionic nerve endings, at sympathetic postganglionic nerve endings to regions where there is no parasympathetic nerve supply and partially at motor nerve endings. The post ganglionic sympathetic nerve endings which are cholinergic are those ones concerned with vasodilatation and sweat gland stimulation.

Its actions are in two categories:-

1) "Muscarine" like in that it accurately imitates

stimulation of parasympathetic nerves.

2) "Nicotine" like in stimulating ganglion cells.

The former action is annulled by atropine but the latter is not.

CARBACHOL is carbamylcholine chloride and is closely related to acetylcholine, the reactions of which it reproduces in the body.

$$NH_2 - CO_2 - CH_2 - N(CH_3)_3Cl$$

Carbamylcholine chloride

Whereas the effects of acetylcholine are transitory, owing to its rapid breakdown in the body, those of carbachol are prolonged and are available for therapeutic purposes. It is administered either by hypodermic injection in doses of $\frac{1}{4}$ - $\frac{1}{2}$ mgm. or orally in doses of 1 - 4 mgms. Its actions of clinical importance depend on its producing the effects of stimulation of nerves which liberate acetylcholine at their terminals and to produce their effects by its liberation.

Chapter 5

SERIES 2. CARBACHOL ADMINISTRATION.

In the cases under review in this section treatment consisted of the oral administration of Carbachol. The dosage prescribed was the same in all cases. For the first two days 3 mgms. were given daily, on the next two days the daily dosage was 4 mgms. and after that 6 mgms. daily, the latter level being maintained until treatment was stopped. The reason for this gradual increase was to introduce the drug at a low level and gradually build it up to what was considered a safe and sufficient level. In this way the patients experienced no discomfort such as nausea, vomiting, abdominal pains or frequency of micturition due to intolerance to the drug, nor did any of these symptoms arise even when treatment was prolonged.

Carbachol was not prescribed to patients who gave a history of gastric ulceration or chronic dyspepsia and, in one case, where the patient also suffered from asthma, the drug had to be withdrawn because it made the attacks of asthma more frequent and more severe. Only patients over 12 were given Carbachol. Otherwise there was no selection of cases, which varied from mild eruptions to inveterate

conditions of long duration.

84 cases are included in this review. A few case histories will be given to show the usual sequence of events and any unusual features noted will be illustrated by the histories of the patients in whom they occurred.

Case 102.

D.D., aged 19, male, was seen on 23 Mar. 47, suffering from psoriasis of three years duration. The arms, from the elbows down, and the legs, from the knees down, were mainly involved. Down the forearms, back and front, and spreading over the backs of the hands and fingers there was a closely set papular and small guttate eruption. A similar type of eruption extended down the legs and across the dorsa of the feet. Round the knees and elbows the lesions had coalesced to form circular, heavily scaling plaques. The skin of the hands was tough, coarse and thickened and had numerous deep, linear fissures (fig. 44). The scalp was heavily crusted and on the outer aspect of each thigh, at the level of the great trochanter, there was a large irregular, infiltrated, scaling plaque Treatment with Carbachol was started. Improvement was noted within two weeks. The lesions round the wrists were clearing and those on the backs of the hands had flattened. Scaling was

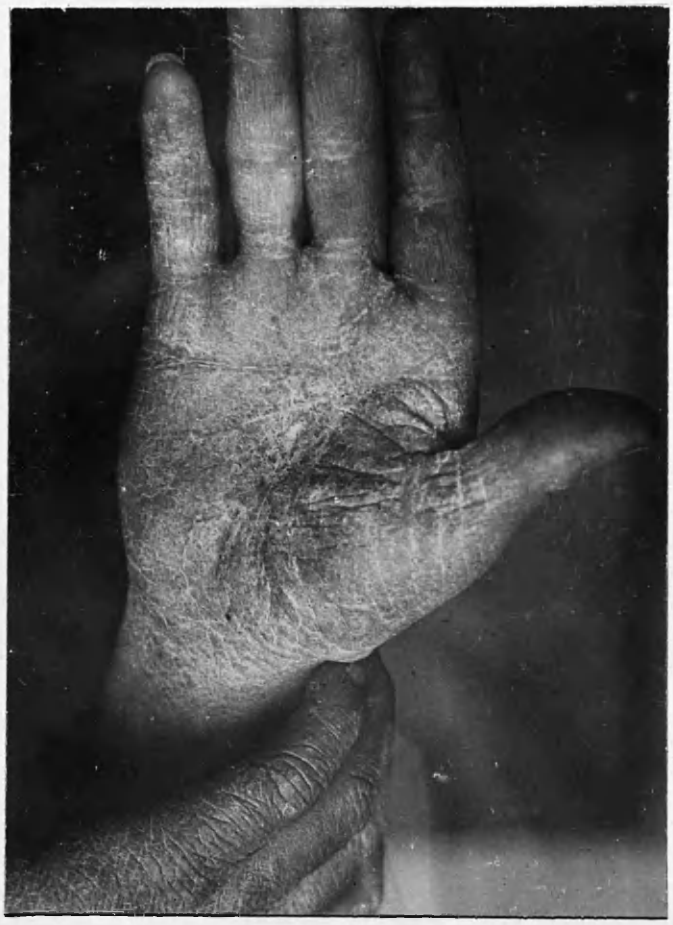

Fig. 44. Case 102.

The appearance of the palm on first examination.

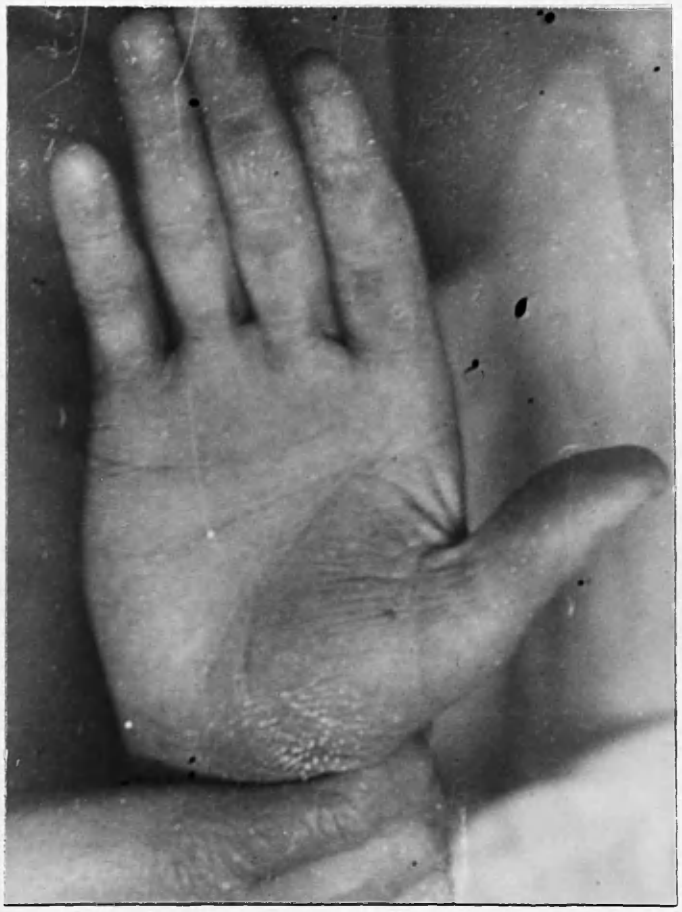

Fig. 45. Case 102.

The appearance of the palm
15 weeks later.

reduced and the lesions were paler. When seen ten days later the skin on the palms was not so thickened and all the fissures had healed. The papular and guttate eruption on the limbs had almost entirely cleared and the plaques round the knees and elbows had broken up into collections of individual papules. Scaling on the scalp was not so heavy and the plaques on the thighs had healed in the centre. On 2 Jun.47, ten weeks after treatment was started, all that remained was a small area of thickening in the centre of each palm and a few flat, non-scaling papules at the elbows. Five weeks later, on 9 Jul. 47, all trace of the psoriasis had gone (fig.45).

Case 106.

V.C.S., aged 19, female, was seen on 15 Apr.47 suffering from psoriasis which had appeared for the first time seven weeks before. The arms, backs of the hands and the backs of the fingers were covered by a bright red, scaling, infiltrated papular and small guttate eruption. There was a similar type of eruption on the legs and over the dorsa of the feet. The lesions were discrete, except round the ankles and over the dorsa of the feet, where they had coalesced to form infiltrated scaling plaques. There were numerous widely scattered guttate lesions on the trunk and the scalp was covered by a thick,

infiltrated crust. There was a response to treatment within a week, the lesions on the arms, hands and legs beginning to clear. On 2 May 47 the skin on the arms and legs, above the ankles was normal, the lesions had cleared from the trunk, the plaques round the ankles and across the top of the feet had lost their infiltration and were areas of pink erythema covered with fine, powdery scales and the massive crust on the scalp was beginning to break up. The erythema on the feet and ankles cleared more slowly but, fourteen weeks after treatment was started, the skin on these parts, although showing a reddish colouration, was of normal texture and the scalp was also clear. When seen again, after a lapse of two months, there was no trace of the previous psoriasis.

Case 108.

A.D., aged 15, female, was seen on 30 Sept. 47, suffering from a severe, widespread psoriasis of two months duration. On the trunk there were multiple, small, circular lesions covered by whitish, heaped-up, tough scales and on the arms there was a mass of coarse, tough, greyish scales set on a dull red erythema (fig 46). On the legs the lesions were nummular, dull red, infiltrated, heavily scaling plaques. The entire scalp was covered by a massive infiltrated crust. Irritation was a

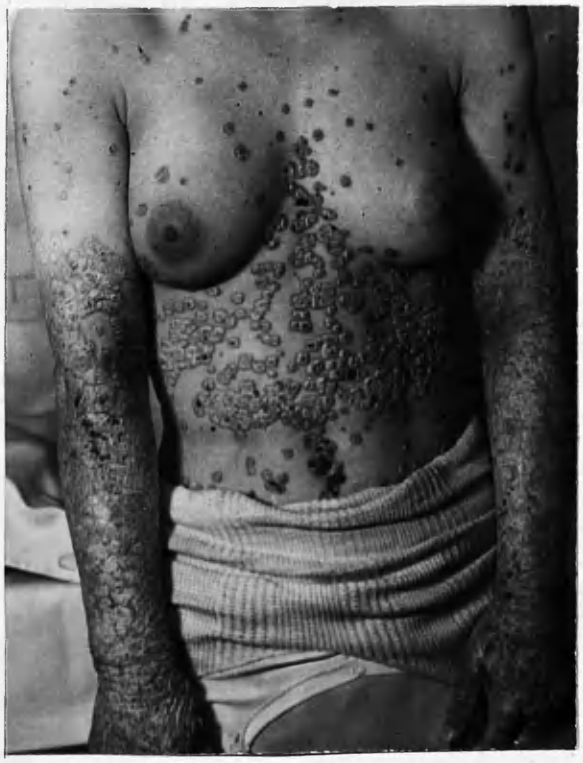

Fig. 46.

Case 108.

The chest, abdomen and arms, as seen on 30 Sept. 47.

Fig. 47.

Case 108.

Nine weeks later. The small collection of scales on the left side of the abdomen are shown. These had gone 2 weeks later.

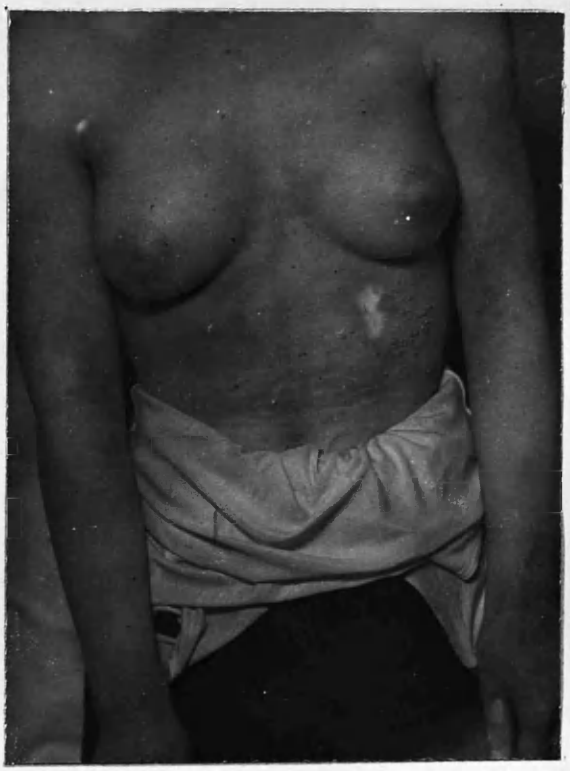

marked feature. A week after treatment was started the condition had worsened. The irritation was more intense and many fresh, bright red, non-scaling papules had appeared on the small areas of skin previously unaffected. This settled down, however, within a week. A general improvement was noted at the end of the third week. The erythema on the arms was paler, the infiltration less and tiny areas of new tissue were apparent, especially in the anticubital fossae. On the trunk, too, the erythema had faded and each individual lesion was surrounded by a narrow, pink aureola. A central depression had appeared in all the plaques on the legs. Scaling was still heavy, although on the scalp the massive crust was breaking up. The irritation had practically gone. Good improvement was maintained until, by 7 Dec.47, nine weeks after treatment was started, all that remained of the severe eruption was a collection of small, loose scales on the left side of the abdomen which left normal tissue underneath when removed (fig.47). These, too, had gone two weeks later.

Case 114.

A.G., aged 49, female, was seen on 7 Oct.47 suffering from psoriasis of 4½ years duration. The whole body, with the exception of the face, was covered by a dull red exfoliating

eruption. On the backs of the hands and on the top of the feet the lesions were small, dull red circles. The whole scalp was covered by a massive infiltrated crust. Irritation was marked. A week after treatment was started the acute stage was subsiding and the patient was more comfortable. By the end of the fourth week the arms had started to clear and the erythema generally was paler and all irritation had gone. There was little change on the scalp. Good improvement was maintained and at the end of the seventh week all areas of the skin were normal except the upper part of the chest and small areas on the thighs; the massive crust on the scalp had broken up and the scaling was finer. On 16 Dec.47, ten weeks after the start of treatment, the entire skin surface was completely clear.

Case 125.

H.F., aged 41, female, was seen on 26 Sept.47 suffering from an acute, bright red, exfoliating psoriasis covering the whole body, including the face (fig.48). There was a severe conjunctivitis of the left eye with photophobia and the scalp was thickly covered with small scales which also lay along the shaft of the hairs. Psoriasis had first begun 18 years before and each year there had been an acute flare-up necessitating,

Fig. 48. Case 125. The right thigh as seen at the first examination. This shows the exfoliating nature of the eruption.

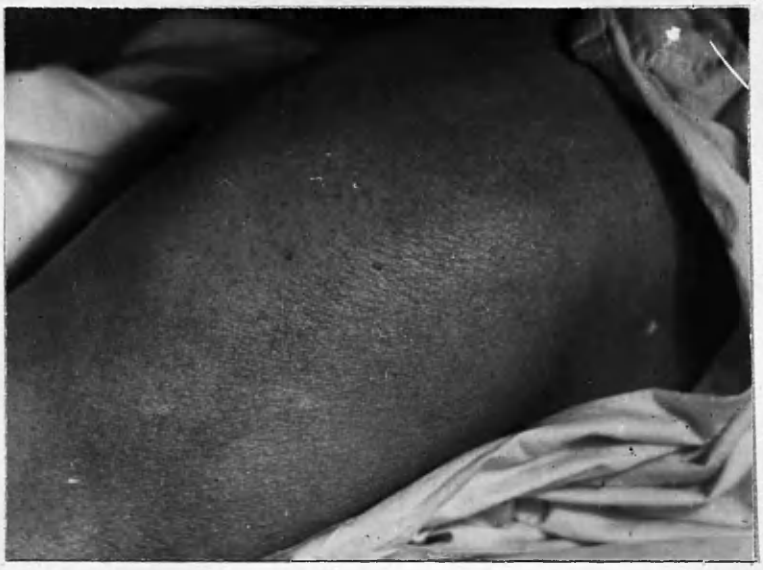

Fig. 49. Case 125. Eleven weeks later. All the psoriatic tissue has been replaced by normal skin.

on occasions, as long as nine months hospitilization. Within three days of the start of treatment with Carbachol the conjunctivitis was clearing and the patient was able to open her left eye. At the end of a week, small, pin-point areas of new skin were appearing on the shoulders. The colour of the eruption on the face and neck was much paler and the left eye was completely healed. The patient was feeling very much more comfortable. The small areas of new skin became bigger and coalesced with each other and in this way new skin gradually spread down both arms. The face and neck assumed a normal colour. By 24 Oct.47, a month after the start of treatment, the upper arms were entirely clear and large patches of new skin had appeared on the chest and upper part of the back, while on the scalp only a fine dandruff-like scurf remained. Although there was so much improvement on the upper part of the body, the lower part of the body and the legs remained unaltered. New, healthy skin gradually extended down the chest, abdomen and back. Small areas of normal tissue then appeared on the buttocks and thighs and by coalescing and spreading downwards gradually replaced the psoriatic tissue on the legs (fig.49). By 5 Dec.47, eleven weeks after the start of treatment, all that remained of the previous severe eruption was a little scaling on both shins and a slightly eczematoid

eruption on the top of both feet near the toes. This latter persisted and on 23 Dec.47, 100 r at 100 Kv at 5 Ma at 20 cms. f.s.d. with no added filter was given directly to the top of the feet. This was repeated three times at weekly intervals. The patient was discharged from hospital at the end of January 1948 completely recovered. A noteworthy feature was that previously in all such acute attacks the hair and the nails had been completely shed. On this occasion there was only a slight loss of hair and the nails were not cast off. New nail grew in without any pitting or striation, the deformed part gradually travelling upwards.

Case 129.

M.C., aged 36, female, was seen on 15 Oct.47 suffering from psoriasis of two years duration. Only the lower parts of the legs were affected. There were multiple, erythematous, heavily scaled guttate lesions between the knees and the ankles. On the left leg, there were two circular, crusted plaques on the inner aspect just above the ankle. The response to Carbachol was dramatic. When seen a fortnight after treatment was started the two plaques had cleared completely, leaving no trace and the guttate eruption had almost cleared all that remained being a few scattered small, circular areas of

reddish staining. A week later there was no trace of the eruption.

Case 139.

M.McG., aged 17, female, was seen on 3 Nov.47 suffering from psoriasis which had been present for a year. Only the legs and the scalp were affected. On the legs the lesions varied from small guttae to fairly extensive geographic plaques. The lesions were infiltrated and covered by thick, white scales (fig.50). On the scalp there were numerous infiltrated, heavily crusted areas. Improvement was noted within a week. Scaling was reduced, the erythema was paler and the scalp was clearing. A fortnight later large areas of new skin had replaced the abnormal tissue on the legs, and the scalp was clear except for a circular area of scaling on the crown. Improvement continued and on 8 Jan.48, nine weeks after the start of treatment, all that could be seen were small areas of fine desquamation and a bluish marling on the legs (fig.51). This, too, had disappeared three weeks later.

Case 141.

J.B.S., aged 35, male, was seen on 22 Oct.47 suffering from psoriasis of 1½ years duration. The eruption varied from

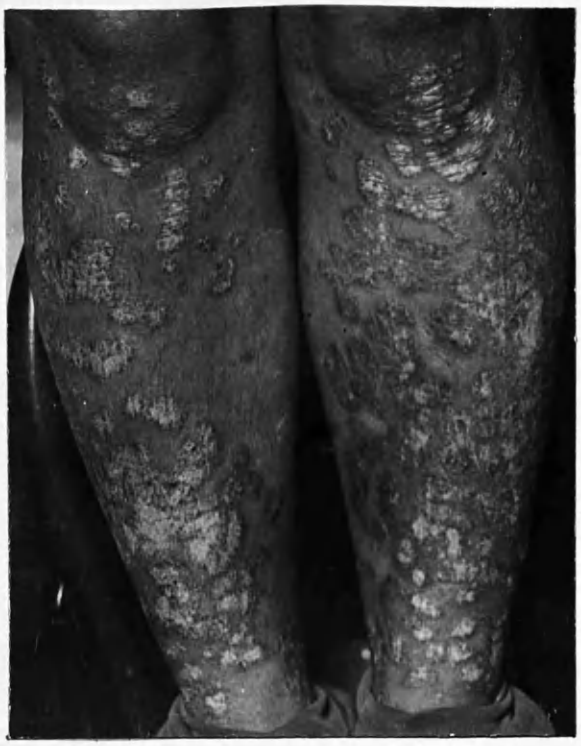

Fig. 50.

Case 139.

As seen on first examination.

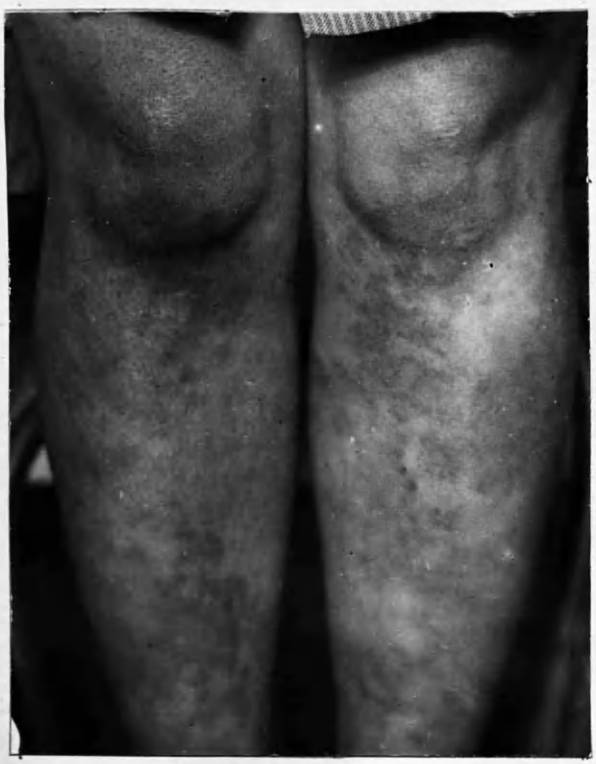

Fig. 51.

Case 139.

Nine weeks later.

scaling papules to large irregular plaques (fig.52). The scalp was heavily crusted and the patient complained of severe irritation. A fortnight after treatment was started the irritation had gone and scaling and infiltration was reduced. Healing continued, the larger lesions clearing in the centre first, the smaller ones becoming paler in colour, losing their scaling and gradually being replaced by normal skin. This improvement was maintained and on 20 Dec.47, nine weeks after the start of treatment only the shoulders, forearms and thighs, at the level of the great trochanter had any active lesions. Those areas were constantly being subjected to friction at his work as a miner. On 7 Feb.48, fifteen weeks after the start of treatment only some areas of faint, reddish brown pigmentation remained of the previous severe eruption (fig.53). This pigmentation had faded six weeks later.

Case 148.

J.G., aged 60, female, was seen on 10 Nov.47 suffering from psoriasis of seven months duration. The perianal region, perineum, vulva, groins, upper and inner aspect of the thighs, and the pubic region were covered by bright red, raised, infiltrated tissue. Scaling was not marked and what there was was whitish and macerated. Small circular lesions, similar in

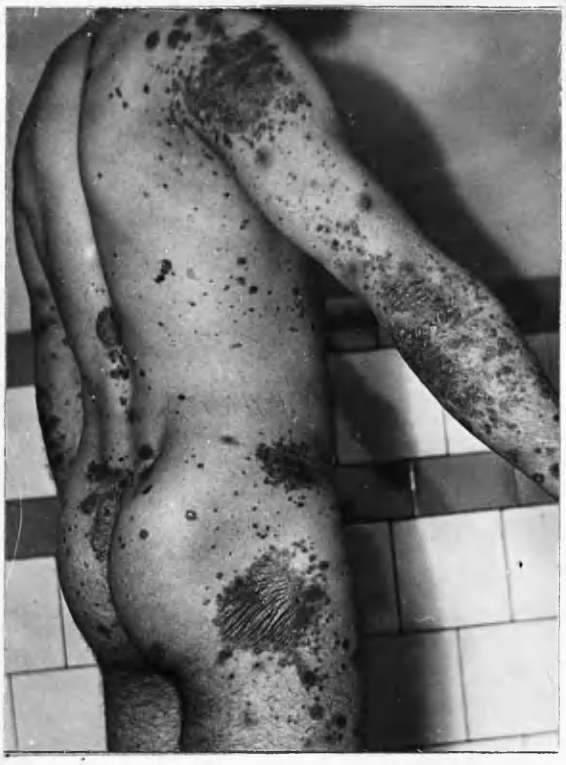

Fig. 52

Case 141.

As seen on 22 Oct. 47.

The varied and wide-spread nature of the eruption can be seen.

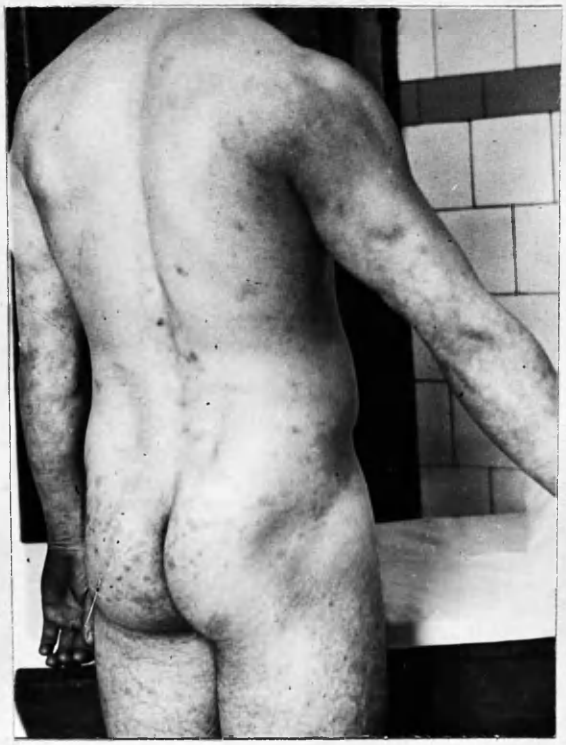

Fig. 53.

Case 141.

Fifteen weeks later.

Faint pigmentation can just be seen.

appearance to the main plaque, extended down the inner aspect of the thighs. The irritation was severe. Improvement was observed within a fortnight. The abnormal tissue was not so raised and the infiltration was less. What little scaling there had been had disappeared and the outlying lesions on the thighs were clearing. The irritation was still considerable. The main plaque then broke up into smaller units and by 9 Dec.47, the pubic and the perianal regions were clear. The irritation, although becoming less severe, did not finally cease until eight weeks after the start of treatment by which time all that could be seen of the previous eruption were some small circular areas of faint reddish staining in the groins. Two weeks later these, too, had disappeared.

Case 155.

J.McC., aged 16, female was seen on 10 Dec.47 suffering from psoriasis of two years duration. There was a widespread bright red, scaling guttate eruption involving all areas of the body (fig.54). The scalp was covered by a massive infiltrated crust. Response to treatment was good and within a fortnight the eruption had started to clear from all areas and the massive crust on the scalp was breaking up. The

Fig. 54.

Case 155.

As seen on 10 Dec. 47.

The legs and back were similarly involved.

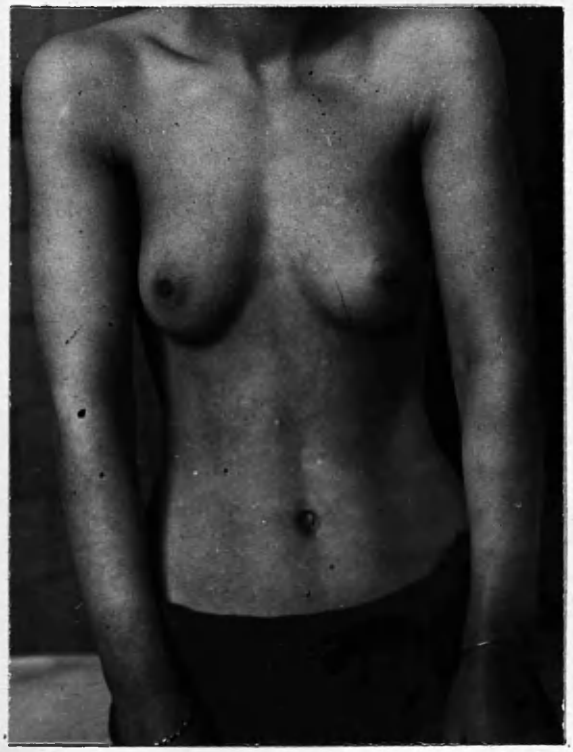

Fig. 55.

Case 155.

Ten weeks later.

The eruption has completely cleared.

improvement continued and by 14 Feb.48, ten weeks after treatment was started all evidence of the psoriasis had disappeared (fig.55).

Two patients in the series gave an unusual response. Carbachol was prescribed in the usual way and both patients responded well, the lesions improving rapidly. When the original lesions had almost healed an irritible, papular eruption developed. This steadily became worse and still persisted undiminished both in appearance and in the intensity of the irritation when the original lesions had entirely cleared. Thinking that this might be an exacerbation similar to that seen with spinal radiation, treatment was continued. Instead of improving the eruption became worse and Carbachol had to be stopped. One case was given spinal radiation, but the eruption has proved very resistant and two courses have been given with only slight beneficial results. The other was given Tab. Thiamin hydrochlor.(Vit B1) mgm. 25 daily and a more marked improvement has been apparent. In the latter the irritation has gone and the lesions are slowly clearing.

Case 121.

S.W., aged 48, female was seen on 14 Oct.47 suffering from psoriasis of 18 years duration. There was widespread involvement with large plaques on the trunk and limbs. The plaques were bright red in colour and covered by shining translucent scales (fig.56). There were also some papular and guttate lesions present. Improvement was apparent within a fortnight. Particularly on the arms much of the psoriatic tissue had been replaced by new skin and on the trunk there were numerous ringed lesions where the plaques had healed in the centre. The legs showed hardly any change at this time. Most of the papules and guttae had disappeared. By 11 Nov.47, a month after the start of treatment, there was practically nothing to be seen of the original eruption on the upper part of the body, but a few fresh irritable papules had made their appearance. On 2 Dec.47 all that remained of the original eruption were some patches of dull red staining on the right thigh. The papular eruption was, however, worse (fig.57). Treatment with Carbachol was continued until 30 Dec.47 but, as the patient was suffering extreme discomfort from irritation, Carbachol was stopped and spinal radiation substituted. The eruption had by this time assumed the appearance of a guttate psoriasis.

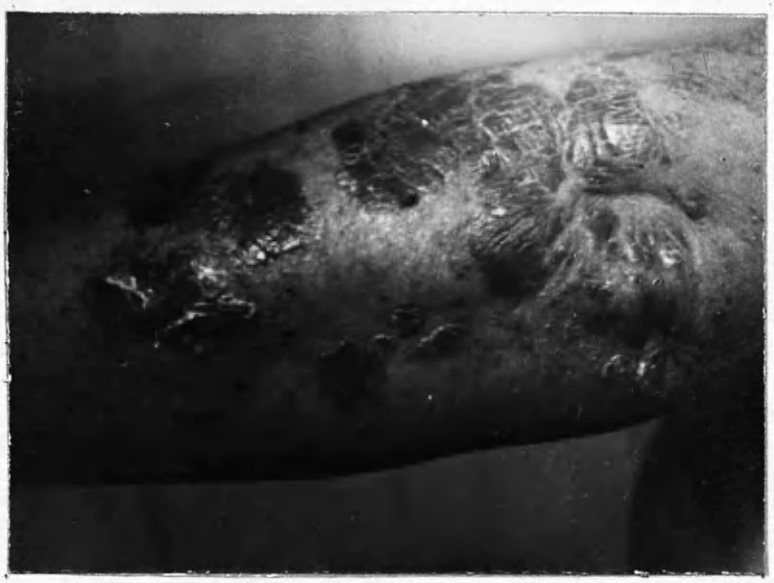

Fig. 56. Case 121. The left forearm as seen on 14 Oct. 47, showing the plaque formation.

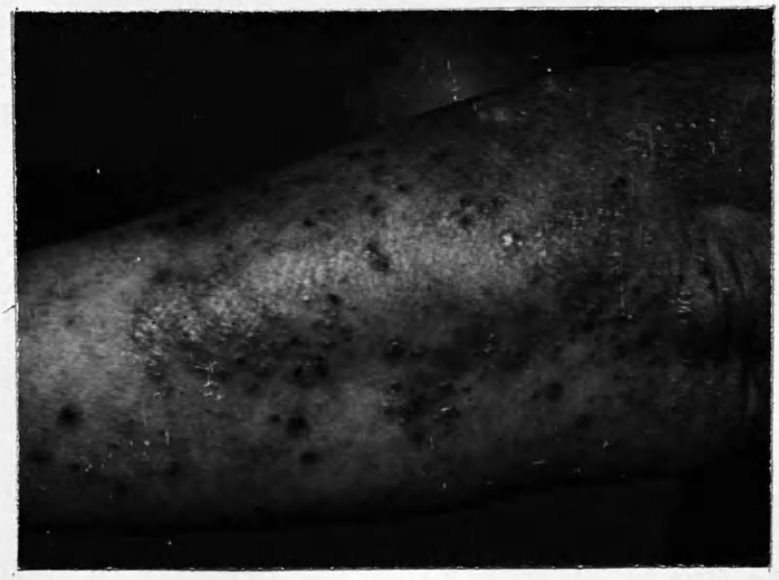

Fig. 57. Case 121. The left forearm on 2 Dec. 47. The plaques have cleared and the papular eruption which developed is shown.

Case 133.

E.F., aged 45, female, was seen on 16 Oct.47 suffering from psoriasis of 33 years duration. The arms were mainly affected the eruption being plaque and guttate. On the trunk and legs the lesions were guttate with no tendency to form plaques. The lesions responded quickly to Carbachol many of the guttae having cleared and the plaques having healed centrally, three weeks after treatment had been started. At this time, however, a papular eruption began to make its appearance. The original lesions continued to improve and when seen on 9 Dec.47, eight weeks after treatment was started, had cleared entirely. The fresh papular eruption had got worse, however, and was very troublesome to the patient because of the irritation. Treatment with Carbachol was stopped. The patient was not seen again until 16 Mar.48 when no change, either for the better or worse, could be seen except that the eruption now had the appearance of a guttate psoriasis. It was decided to prescribe Thiamin hydrochlor. mgm 25, daily. Within three weeks the irritation had ceased and a slight improvement was apparent in the lesions. A slow improvement was maintained and at the present time the lesions are healing, but so far only a few have disappeared.

In one case in the series the psoriasis cleared entirely from the upper part of the body but remained unchanged from the buttocks downwards. After prolonged treatment with Carbachol, with no effect, an ointment containing Cignolin had to be used before the lower limbs cleared.

Case 126.

J.S., aged 20, female, was seen on 3 Oct.47 suffering from psoriasis of five years duration. There were large areas of dull red, scaling erythema with marked infiltration and a well defined, raised edge. The scalp, forehead, side of the face and neck, shoulders, chest and upper part of the back, arms and hands were covered by one continuous patch (fig.58). The lower abdomen, lower part of the back, groins, buttocks and upper part of the thighs were covered by another continuous patch. There were large irregular patches down both legs, round the ankles and across the dorsa of the feet. The palms and soles were clear. Within a week small areas of paler tissue were seen on the face. These gradually extended and coalesced and others appeared on the neck, chest, back, shoulders, and down the arms. By enlargement of these areas the skin on the upper part of the body gradually became normal in appearance, texture and colour (fig.59). The upper

Fig. 58.

Case 126.

The face, neck, shoulder and hand, showing the severe nature of the eruption.

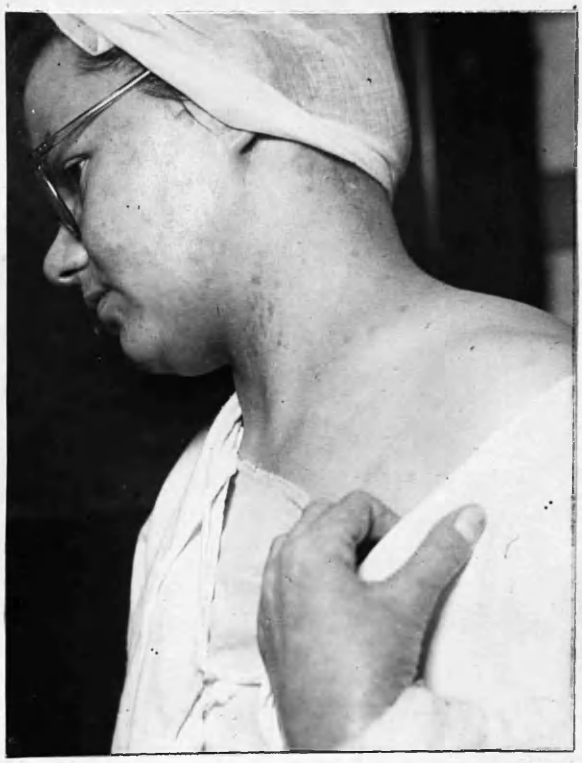

Fig. 59.

Case 126.

The same areas, seven weeks later.

part of the body was clear seven weeks after treatment was started. During this time the abnormal tissue had been clearing from the lower abdomen and back, although slower than in the case of the upper part of the body. By 12 Dec.47, ten weeks after the start of treatment only the buttocks and lower limbs were affected and here the appearance was much the same as when seen originally. Treatment was continued and spinal radiation was applied to the lumbar area with little or no response. After a further two months with still no appreciable change in the appearance of the lower limbs a 1% Cignolin ointment was applied. Following this the condition improved and by the middle of March 1948 all areas were clear and the patient was discharged from hospital.

The detrimental effect of a sudden shock was well illustrated in one case. Good response to Carbachol therapy was taking place when the patient's daughter met with a serious accident, witnessed by the patient. An acute relapse developed practically overnight.

Case 130.

Mrs.G., aged 48, female, was seen on 23 Oct.47 suffering from psoriasis affecting the limbs mainly. Down the extensor

surface of both forearms there was a broad, elongated area of raised erythema covered by fine, white scales. On the right knee there was a large infiltrated plaque with tough, thick, heaped-up scales with a linear extension down the right shin. As well, there were numerous small, circular, scaling lesions. There was a smaller plaque on the left knee with scattered heavily scaled lesions extending down the left leg. The scalp was moderately affected and there were a few small, reddish, scaling lesions behind the ears. The arms responded quickly to treatment, small islands of new tissue being seen in the midst of the abnormal tissue within a week. Improvement continued satisfactorily, new tissue rapidly replacing psoriatic tissue on the arms. The lesions on the legs broke up into smaller units and the scaling became finer and more easily removed. The scalp and behind the ears were clear. This was the state of affairs on 20 Jan. 48, three months after treatment was started. When seen again three weeks later the condition was as bad as ever, indeed on the arms it was worse than when seen originally. The patient's daughter had met with an accident, which the patient had witnessed, and the relapse had developed suddenly following this. Carbachol was stopped and massive doses of Bromides and Phenobarbitone were prescribed for three weeks. There was

no change in the clinical picture at the end of this time. Carbachol was then restarted and the eruption again began to clear.

Not all of the cases in the series responded to treatment. Some showed no change either one way or the other, a few became worse and others, after improving well initially, suffered a sudden acute relapse. As spinal radiation was substituted in all of these cases they will be reviewed more fully in the next chapter which deals with those cases treated by both Carbachol and X-ray therapy.

In the cases which responded to treatment with Carbachol the changes which took place were almost identical to those which took place in the cases treated by spinal radiation. In plaques and large guttate lesions, healing began in the centre, in the majority of cases. Scaling became finer and less marked and either one small area of normal tissue appeared and gradually enlarged or numerous pin-point areas appeared scattered in the body of the plaque and by enlarging and coalescing formed one large area of normal skin surrounded by a narrow rim of raised, finely scaling tissue. This rim became broken across in places and small isolated, scaling papules were left which in turn disappeared. In some

cases the large lesions were broken up into smaller units by ingrowths of new skin. These units gradually decreased in size until they were completely replaced by normal tissue. When this happened scaling persisted as fine desquamation until recovery was complete.

Small guttae and papules lost their typical scales and became flat areas of pale erythema with fine powdery desquamation at the periphery. The erythema gradually faded, the slight exaggeration of the normal skin markings disappeared and normal skin took its place. Fig.60 - 62 show the usual sequence of events which took place during the process of healing.

In none of the cases treated by Carbachol did a typical psoriasis eruption change its character and assume the appearance of an exfoliating dermatitis.

Lesions on the upper part of the body responded quicker than did those on the lower part and often when an extensive eruption had cleared everywhere else traces of it persisted on the legs below the knees and in one case already described (Case 126) no impression was made on the lesions from the buttocks down although all traces of psoriasis had cleared from the upper part of the body.

Irritation, in cases in which it had been a predominant

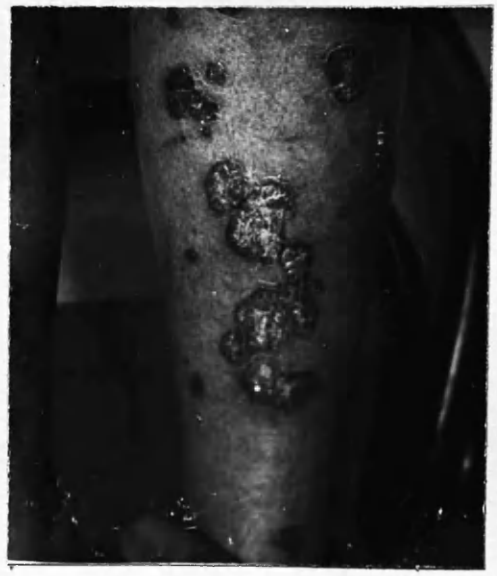

Fig. 60.
The original lesion.

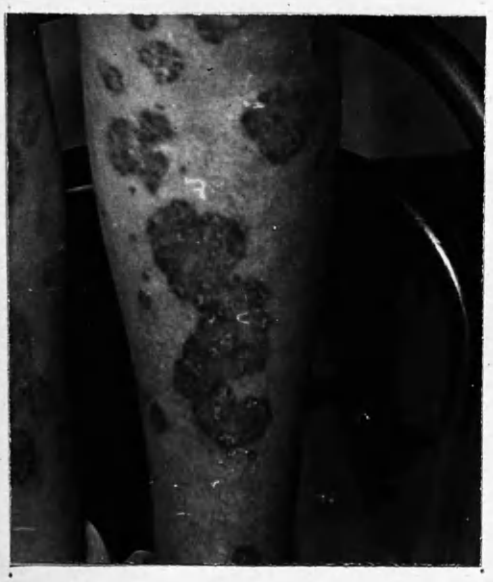

Fig. 61.
Scaling is reduced and healing is beginning in the centre of the plaque.

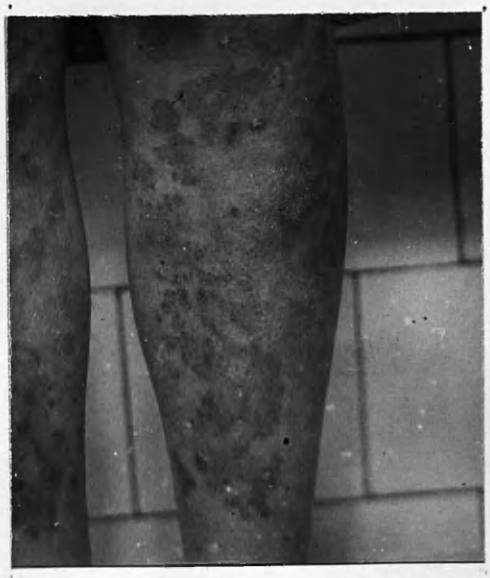

Fig. 62.
Healing is almost complete, a broken papular border being all that remains.

symptom, was quickly relieved when Carbachol was effective, but in cases which relapsed after an initial improvement, irritation became more intense. Where Carbachol failed to produce any objective improvement in the lesions there was no lessening of the irritation either.

Some degree of pigmentation was left when the eruption had cleared. This varied from brown to reddish staining. It did not persist for long and in most cases had cleared within a month.

In cases responding to Carbachol therapy improvement was evident within a fortnight and the average time taken for the complete disappearance of an eruption was three months, although, in one case, an eruption of two years duration had entirely disappeared in three weeks.

One case of pustular psoriasis is included in the series but after prolonged therapy no improvement has been noted.

Table 4 sets out the details of the results. It has been divided into three age groups, 12 - 30, 30 - 45, 45 upwards.

As with spinal radiation the results obtained were better in patients under 30 years of age, but with Carbachol the difference between those patients and patients over 30

Table 4

Age group	Number of cases treated	The eruption cleared or improved	Unimproved
12 - 30	41	33 (80.5%)	8 (19.5%)
30 - 45	25	18 (72%)	7 (28%)
45 upwards	18	13 (72.2%)	5 (27.8%)
	84	64 (76.2%)	20 (23.8%)

Table 5

	Spinal Radiation		Carbachol	
Age group	Cases treated	Cleared or improved	Cases treated	Cleared or improved
12 - 30	44	40 (90.9%)	41	33 (80.5%)
30 - 45	26	20 (76.9%)	25	18 (72%)
45 upwards	14	8 (57.1%)	18	13 (72.2%)
	84	68 (80.9%)	84	64 (76.2%)

was not so marked. With spinal radiation, too, there was less chance of producing a satisfactory result as the age increased, whereas with Carbachol there was no difference between the percentage of patients responding in the age groups 30 - 45 and 45 upwards. The comparative figures are set out in Table 5.

In order to try to determine if Carbachol acted at skin level, some lesions were infiltrated with 1 c.c. of a solution containing 0.25 mgm. Carbachol. The result of this was very indefinite. In one patient who had three small guttate lesions so treated, two of the lesions cleared and the other remained as it was. Another case in which two lesions about the size of a shilling were infiltrated showed no improvement in either. In yet another in which a small guttate lesion was infiltrated, the lesion disappeared completely. An area about the size of a shilling in a large plaque was infiltrated and an improvement was noted in this area but, within a week, it had reverted to its original appearance and could not be distinguished from the rest of the plaque. One patient who had cleared with spinal radiation developed a scaling papule on the back of the hand. This was infiltrated and disappeared within a week but, as this had

happened in other cases treated with spinal radiation, the lesions disappearing spontaneously without Carbachol infiltration, no significance could be attached to it.

Two patients were given intramuscular injections of Carbachol 0.25 mgm. per c.c., ½ c.c. being given twice daily for three days, then 1 c.c. twice daily thereafter. At the end of ten days mild signs of intolerance began to develope and as there was no appreciable difference in the psoriasis this method of administration was discontinued. It is regretted that in both these cases there was no opportunity to try the effect of spinal radiation or the oral administration of Carbachol.

This review of 84 cases shows that Carbachol produces a beneficial effect in a high percentage of patients suffering from psoriasis. The results, too, compare closely with those in series 1.

Chapter 6

TREATMENT WITH CARBACHOL AND SPINAL RADIATION

The 20 cases which did not benefit by the oral administration of Carbachol are dealt with in this section. In these cases, following treatment with Carbachol, one of three things happened: a) There was some improvement but a gross amount of abnormal tissue still persisted even when therapy was prolonged: b) A good initial improvement took place, then while still undergoing treatment, a sudden acute relapse developed: c) There was an immediate worsening of the condition. One case showed no change either way after prolonged treatment. In all of these cases spinal radiation was substituted. The results, from the point of view of producing a beneficial effect in the patients, were disappointing. Only two of the cases showed any marked improvement and, in one of these, two courses of spinal radiation were given before improvement took place.

Case 109.

I.H., aged 32, female, was seen on 30 Sept.47 suffering from psoriasis of a year's duration. The eruption was confined mainly to the knees and elbows. In these situations there

were large, infiltrated, heavily scaling plaques. Extending down the right shin there was an elongated plaque. Some guttae were scattered on the arms and legs. A fortnight after treatment with Carbachol was started some improvement was noted in the plaques. Scaling was reduced, infiltration was less and signs of healing were evident in the centre of all the lesions. However, when seen a fortnight later there was a severe relapse. The plaques were swollen and congested and the scaling was heavier than when seen originally. The guttate lesions had enlarged and now appeared as nummular, heavily scaled plaques. Carbachol was stopped and spinal radiation started. 600 r, in doses of 200 r weekly were given to the lumbar and cervical areas. There was an improvement in the condition almost immediately, scaling was reduced, the lesions were no longer swollen and were level with the surrounding skin and areas of healing appeared centrally. The narrow scaling border of the plaques persisted, however, and at the end of a further two months a second course of spinal radiation was given. Improvement followed this and the peripheral border became broken across leaving scattered, isolated, finely scaling papules. These have persisted for some time now but so far no further therapy of any kind has been prescribed.

Except for those two cases little was achieved in the others, even in those given two courses of spinal therapy. The following two cases are illustrative of what usually happened.

Case 120.

J.P., aged 27, male, was seen on 7 Oct.47 suffering from psoriasis of six years duration. There was a dull red, finely scaling, infiltrated plaque on the front of the right leg, extending almost from the knee to the ankle. At both elbows and extending down the forearms there were small plaques covered by tough, whitish, heaped-up scales. Scattered on the chest, back and upper part of the abdomen were numerous small, red discoidal lesions covered by fine, greasy, yellowish scales. The scalp had a few scaling papules and was covered by a heavy dandruff-like scurf. Treatment with Carbachol was prescribed but at the end of two months there was no difference whatever in the condition. Spinal radiation was then substituted, 600 r, in weekly doses of 200 r, being given to the lumbar and cervical areas. A few fresh lesions appeared but beyond this there was no response to treatment. At the end of a further three months a second course of spinal therapy was given. Again there was no change noted in

the eruption and now at the end of another four months, and nine months from the time of the first examination, there is no difference at all in the condition.

Case 116.

M.T., aged 44, female, was seen on 7 Oct.47 suffering from psoriasis of 5 years duration. Covering almost the entire extensor surfaces of both forearms, from the elbows to the wrists were massive, infiltrated, heavily scaling plaques (fig.63). On both knees there were irregular, infiltrated plaques with tough, white, adherent scales. There were a few scattered nummular lesions on the trunk and the scalp was moderately affected. Treatment with Carbachol was started and at the end of three weeks the scaling on the plaques on the forearms was greatly reduced, the infiltration was less, and linear areas of new tissue had appeared in the body of the plaques. On the knees scaling and infiltration was less but no new tissue could be seen. On the trunk the nummular plaques had started to heal in the centre. A slow improvement continued for another month but after that the condition remained stationary. Spinal radiation was started on 10 Jan.48, 600 r, in weekly doses of 200 r, being given to the lumbar and cervical areas. Following this, further improvement was noted

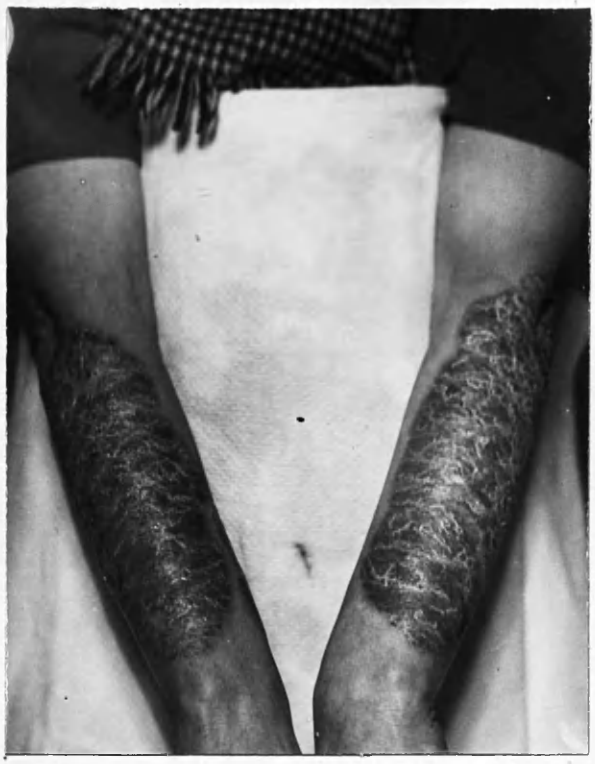

Fig. 63.

Case 116.

The forearms as seen on 7 Oct. 47.

Fig. 64.

Case 116.

8 months later.

After improving the eruption reverted to its original appearance.

but, after progressing for two months, the improvement stopped and a static phase again ensued. The first change noted after this was one of deterioration and the lesions on the forearms and knees slowly reverted to their original appearance (fig.64).

What was the significance of the fact that cases which failed to respond to Carbachol were also resistant to spinal radiation?

Six cases were selected and each was given Thiamin hydrochloride (Vit. B1) in doses of 25 mgm. daily, by mouth. The cases were divided into the following categories:-

A. Two of the cases had responded in some measure to both Carbachol and spinal radiation but had relapsed, the condition becoming worse than when seen originally.

B. One of the cases had become worse with Carbachol and spinal radiation aggravated the condition still further.

C. One of the cases had almost cleared completely with Carbachol but relapsed. Instead of repeating Carbachol therapy spinal radiation was given. An acute exacerbation developed almost immediately.

D. One case had developed an irritable papular eruption after the original condition had been cleared by Carbachol.

E. One of the cases had responded on two occasions to spinal radiation but had twice relapsed before recovering completely. This case did not have any Carbachol therapy.

A.

Case 131.

H.C., aged 16, female, was seen on 8 Oct. suffering from psoriasis of 3 years duration. There was a large, infiltrated, heavily crusted plaque on the chest and between the breasts shaped like the ace of clubs. On both temples there was a large oval plaque, heavily crusted and infiltrated and round the hair margin there was a continuous, broad, heavily scaling, erythematous eruption. There were numerous areas of thick crusting on the scalp. Carbachol therapy was started. When seen three weeks later the plaque on the chest was healing in the centre, and there was a raised scaling border surrounding an area of scaling erythema. At the hair margin small areas of normal skin had appeared in the midst of the abnormal tissue and the scaling all over this area was greatly reduced. There was little difference to be seen in the plaques on the temples and no difference at all on the scalp. When seen a fortnight later only slight further improvement was noted and little or no change took place in the following month. With a static phase having been reached it was decided

to implement treatment with spinal radiation to the cervical area only. Within a month the plaque on the chest healed entirely in the centre leaving a narrow raised border, the plaques on the temple broke up into small circular areas of scaling set on an erythematous base and the eruption at the hair margin had also healed in the centre. On the scalp the crusted lesions were improving the scales being finer and more easily removed. Some fresh guttate lesions had, however, appeared on the upper part of the abdomen. Suddenly the plaque on the chest and the fresh guttae on the upper abdomen flared up and coalesced to form one large irregular, acutely inflamed, swollen oedematous lesion. This acute stage subsided without further treatment but there was no further improvement. This state of affairs lasted for two months when there was another flare-up, this time the temples and hair margin being affected as well. A second course of spinal radiation similar to the first was given. The acute condition again subsided but after a further nine weeks no marked improvement had taken place. It was then decided to prescribe Thiamin hydrochloride (Vit B1) mgm 25 daily. At the end of a fortnight a slight improvement was noted in all areas affected and two weeks later the change in the condition was very marked. The large plaque on the chest and upper abdomen

was healing centrally although the edge was still raised and scaling, the lesions round the hair margin had cleared entirely and the plaques on the temples had once again broken up into small units, still with a certain amount of scaling. A rapid improvement continued and a fortnight later the lesions on the temple had cleared completely for the first time, and of the large plaque on the chest and abdomen all that remained was a very narrow, slightly raised border with some small dry scales, the skin enclosed by it being normal and healthy. When seen on 22 Jun.48, five weeks later, all trace of the eruption had cleared.

Case 137.

R.T., aged 32, male, was seen on 29 Oct.47 suffering from psoriasis of four years duration. The eruption was confined almost entirely to the pubic region, groins, shaft of the penis and the scrotum and to a lesser extent over the coccyx. The skin was raised, bright red and inflammed, there was no scaling and on the scrotum the skin was thickened and had lost its elasticity. The irritation was intense. Treatment with Carbachol was started and within a fortnight there was a remarkable improvement. All the irritation had gone and on the pubis, groins and over the coccyx the bright red, swollen

tissue had given place to a pinkish erythema with some dry powdery scaling and the abnormal tissue was no longer raised above the level of the surrounding skin. Unfortunately this improvement was only of short duration and a deterioration was evident when seen two weeks later. The irritation had returned and a large new plaque had appeared in the left axilla. Carbachol was continued for a further month, with no improvement, indeed the irritation became progressively worse and on 16 Dec.47, it was decided to give spinal radiation. 600 r in weekly doses of 200 r were given to the lumbar and cervical areas. Following this a steady improvement took place and by 2 Mar.48, three months later, except for a small area of red staining over the coccyx, all evidence of the psoriasis had disappeared. Three weeks later the patient reported with a severe relapse which had developed practically overnight. The pubis, groins, scrotum and over the coccyx were as bad as ever, the plaque had reappeared in the left axilla and numerous small, scaling plaques had appeared on the trunk, the limbs, backs of the hands and the scalp. The irritation was once more very severe. A further course of spinal radiation was prescribed. Following the first 200 r there was a further deterioration and it was with some misgiving that further radiation was given. In an attempt to

minimise as far as possible the severity of any exacerbation that might develop Thiamin hydrochloride mgm 25 daily was prescribed. No further deterioration in the condition took place and four weeks after the start of the second course of radiation a slight general improvement was noted. On 22 May 48, four weeks later, still, there was a sudden and decided change for the better. All the irritation had gone, the pubis, groins, penis and scrotum were clear of psoriasis and all that could be seen in the left axilla was a circular area of reddish staining. The generalised eruption, particularly on the backs of the hands was very much improved and the scalp was practically clear, only a few scattered, scaling papules remaining.

B.

Case 158.

C.McI., aged 32, female, was seen on 13 Jan.48 suffering from psoriasis of four years duration. Only the arms were affected. There was a finely scaling erythema extending from the elbows to the wrists and some isolated, small guttate lesions as well. Carbachol was started and within three weeks the condition was very much worse. Many new lesions had developed all over the body and the original ones were worse. Carbachol was stopped and spinal radiation substituted.

Following this a generalised papular eruption developed which was extremely irritable. A gradual worsening of the condition took place and the whole body, including the face, was soon covered by an infiltrated, heavily scaling, guttate eruption. The scalp, too, became badly affected. The irritation became very intense and the patient looked and felt miserable. Eleven weeks after the start of spinal radiation the patient's condition was very much worse. Thiamin hydrochloride mgm.25 daily was prescribed and an almost immediate improvement was noted. The irritation became less and the lesions began to settle down. Within a month all the irritation had gone and healing changes were evident in most of the lesions. When seen at the end of a further six weeks most of the eruption had cleared.

C.

Case 110.

M.K., aged 27, female, was seen on 30 Sept.47 suffering from psoriasis of 13 years duration. There were scattered irregular plaque formations on both the legs and the arms. The lesions on the legs tended to be nummular although one or two had irregular outlines, they were dusky red in colour, with white adherent scales (fig.65). On the arms the lesions were paler in colour, more irregular in outline and the

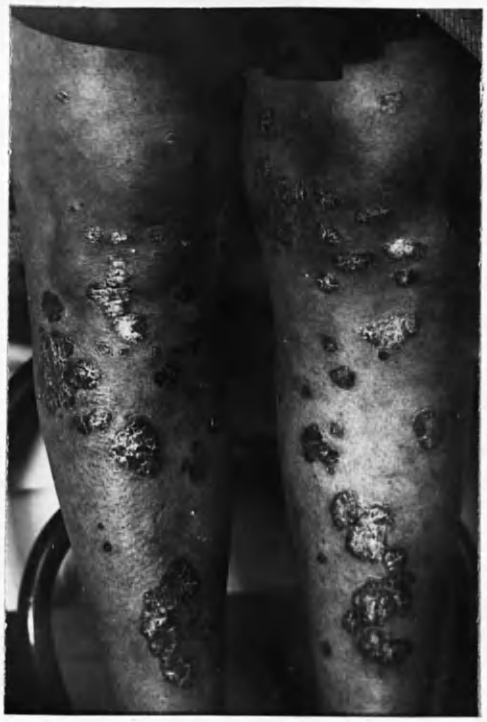

Fig. 65.

Case 110.

The appearance of the legs on first examination.

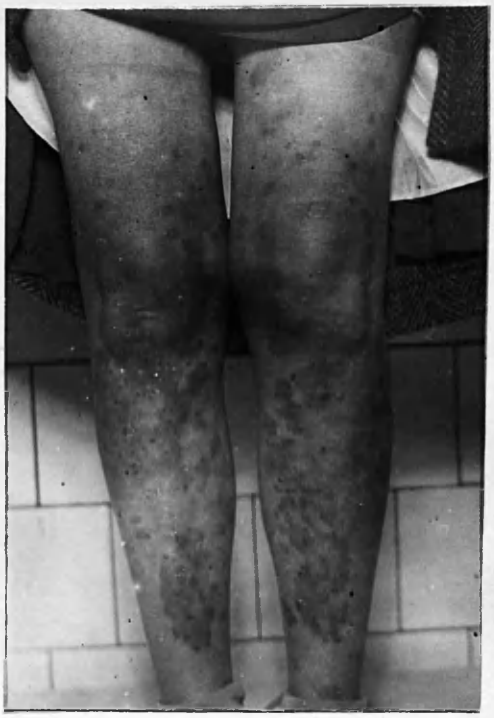

Fig. 66.

Case 110.

Four months later. Pigmentation, with scaling at the periphery can be seen.

scaling was finer and not so adherent. There was one nummular plaque on the trunk and the scalp was clear. Treatment with Carbachol was started. Improvement was noted within a fortnight, scaling was less on all the lesions and in many of the plaques, especially on the legs, central healing had started. A steady improvement was maintained and on 10 Feb.48 just over 4 months from the start of treatment all that remained were some areas of red staining on the legs with some small scales at the periphery (fig.66). The patient was not seen again for two months when she reported with a relapse, the condition on the arms and legs being as bad as ever and the trunk was extensively involved. Spinal radiation was started, 600 r in weekly doses of 200 r being given to the cervical and lumbar areas. When seen two weeks after the last treatment, the condition was very much worse, a severe exacerbation of the condition having developed. Thiamin hydrochloride was prescribed. Within a fortnight, not only had the acute exacerbation settled, but all the lesions were in an advanced stage of healing.

D.

Case 133.

This case has already been described on Page 100.

E.

Case 10.

A.McM., aged 45, male, was seen on 4 Sept. 46 suffering from a severe, widespread psoriasis of 15 years duration. On the front of the body there was a large, irregular, geographic plaque extending from the chest to the pubis. On the back, from the neck to the sacral region, there was a similar extensive mass of psoriatic tissue (figs. 67 & 68). The sides of the trunk and the chest were relatively clear, only a few scattered nummular plaques and guttae being evident. The lesions were infiltrated and the scaling was tough and very adherent. On the inner aspect of the thighs there were numerous small, circular, heavily crusted, infiltrated lesions. On the outer aspect and front of the thighs and lower part of the legs, stretching practically from the buttocks to the ankles, there was an almost continuous plaque covered by a thick, white, adherent, crust. On the extensor surface of the arms a similar type of plaque extended from above the elbows down to the wrists. The scalp was covered by a heavy, thick, white crust and round the hair margin and on the face there were numerous small, circular, scaled lesions. The irritation was intense. Spinal radiation was given, 600 r, inweekly doses of 200 r, to the lumbar and

cervical areas. Following the first treatment the patient complained of increased irritation, but a week after the last treatment had been given the irritation had completely gone. Within a month of the start of treatment there was a marked improvement. The plaques on the front and back of the trunk had almost entirely cleared, only a broken, papular edge remaining and the smaller lesions on the trunk had a similar appearance (figs. 69 & 70). The new skin had a brown colour. The scalp, hair margin and face were clear. On the inner aspect of the thighs the small nummular plaques had healed in the centre but the narrow, raised edge of each was still intact. The plaques on the legs and arms, although not so infiltrated were still covered by a massive crust. By 18 Oct. 46 the trunk was completely clear and some of the ringed lesions on the inner aspect of the thighs had become broken up. Little change was noted on the arms and legs. The patient then developed a severe attack of influenza and bronchitis and was confined to bed. When seen two months later there were numerous circular, scaling lesions about the size of a shilling on the sides of the trunk, areas previously little affected. No new lesions appeared on any part previously involved. There was also a deterioration in the lesions on the inner aspect of the thighs. The scalp and face still

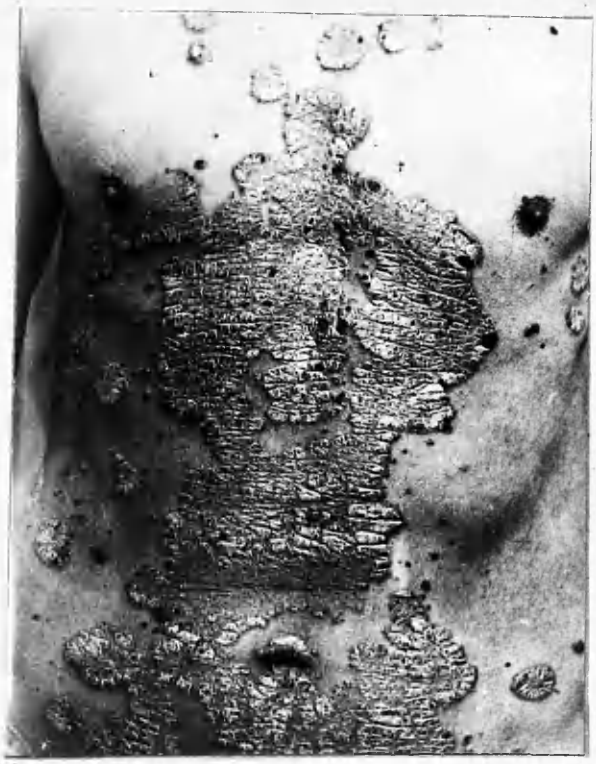

Fig. 67.

Case 10.

The chest and abdomen as seen on 4 Sept. 46.

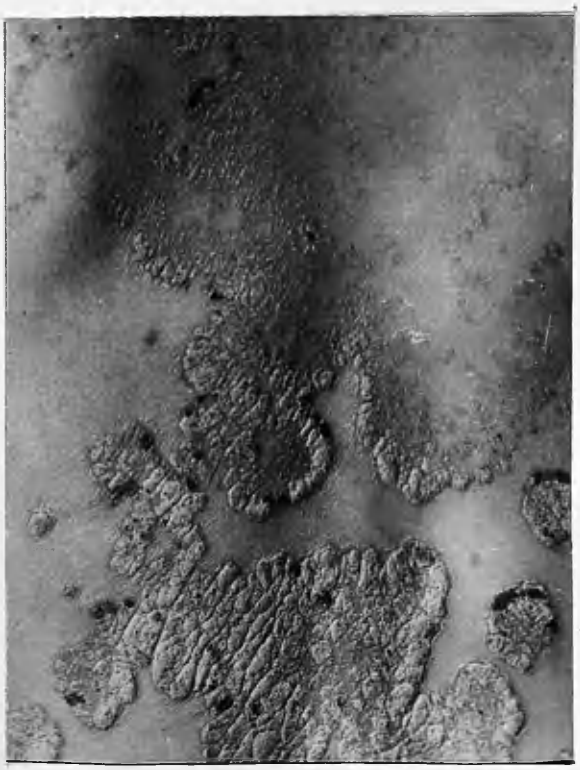

Fig. 68.

Case 10.

Showing the typical geographic plaques on the back.

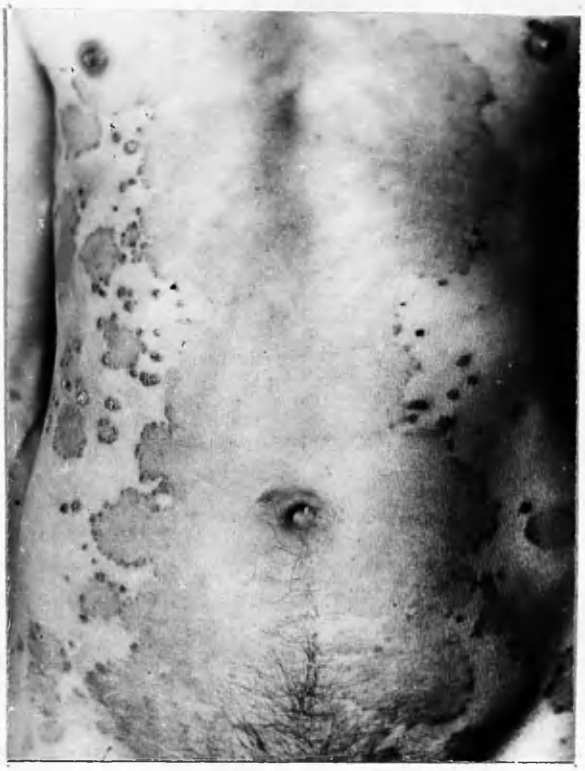

Fig. 69.

Case 10.

The chest and abdomen a month later. All that remains of the eruption is a broken, papular border enclosing an area of brownish pigmentation.

Fig. 70.

Case 10.

The back a month later. Brown staining with a few scattered papules are all that remain of the eruption.

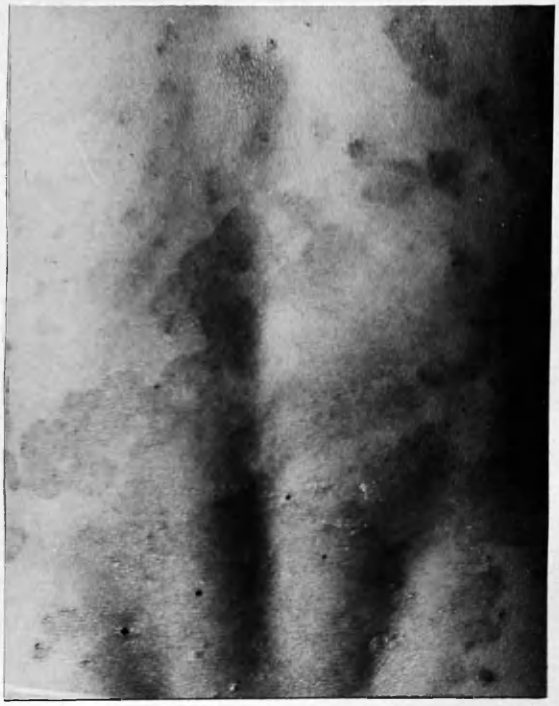

remained clear. Slight irritation was complained of. No further treatment was given at this time and the lesions on the sides of the trunk healed in the centre but no further improvement took place. A second course of spinal radiation was started on 22 Mar.47. There was an immediate deterioration in the condition. The severe irritation returned, the lesions on the sides of the trunk coalesced to form geographic plaques, some small guttae appeared on the front and back of the trunk and an infiltrated plaque developed round the umbilicus. The face and scalp still remained clear. Within a month, however, there was a lessening of the irritation and signs of healing in the plaques on the trunk became evident. There was no change on the legs or arms. A slow improvement then ensued and by 24 Jan.48, ten months after the start of the second course of radiation the trunk was again clear; on the inner aspect of the thighs there were areas of brownish pigmentation with a few scattered scaling papules only; on the outer aspect and front of the thighs the skin was normal and the original extensive plaque was confined to the outer aspect of the calves and to a small area on the shins and on the arms plaque formation was confined to the middle third of the forearms. Three months later the patient reported with a further relapse. This had again followed an

attack of bronchitis which had kept the patient in bed for five weeks. The lower abdomen and lower part of the back had some small, irregular plaques, some nummular plaques had developed on the inner aspect of the thighs and the plaques on the legs and arms had become very much worse. Irritation on the legs only was severe and for the first time the patient complained of pain when bending his knees. This pain was not in the knee-joint. Thiamin hydrochloride mgm. 25 daily was prescribed and within three weeks there was a marked improvement. The irritation had eased considerably, there was no pain on bending the knees, the trunk and inner aspect of the thighs were clearing well and the legs and arms had also improved. At the end of another month the eruption was again mainly confined to the outer aspects of the calves and the middle third of the forearm.

Apart from the possible beneficial effect of Thiamin in the last case described, other features are noteworthy. In this case psoriasis first appeared when the patient was convalescing following a serious illness with pneumonia and the two relapses noted each followed a severe attack of bronchitis. Recovery following the first course of spinal radiation was quick but, after the second course, ten months elapsed before

the eruption was cleared except from the legs and arms, where it has never completely gone. On the trunk, the first relapse did not affect the front or back, areas originally severely affected and, during the second relapse, the sides of the trunk, involved in the first relapse, remained clear and the lesions developed on the front and back. The face and scalp did not become affected during any of the relapses. Each relapse, too, was less severe. Irritation was variable but in each instance was the first symptom to be relieved when treatment was having a beneficial effect.

It would be unwise to assess the value of Thiamin in the cases just described. In the first three cases it could be argued that the improvement would have taken place anyway as it could have been due to the effect of spinal radiation. However, in the light of the histories of these cases, the evidence is in favour of Thiamin playing an active part in the improvement.

In the last three cases the evidence is strongly in favour of Thiamin having a direct beneficial effect.

It is obvious that more work must be done over a longer period before any true assessment of the value of Thiamin in psoriasis can be made and the author is at present pursuing

this subject further.

From the point of view of the present work, it is interesting to note that another chemical intermediary of the autonomic nervous system may beneficially influence psoriasis and so further support the hypothesis that the autonomic nervous system plays some part in this disease of the skin.

THIAMIN (ANEURIN, VIT B1). Leichti et al (33) found that on nerve stimulation aneurin was liberated at nerve endings as well as acetylcholine. Kuhn et al (34) showed that the concentration liberated was 80 times as great as that existing in resting nerve. These workers experimentally showed that aneurin itself did not act as a chemical transmitter but that acetylaneurin did so act. They also suggested that the effect of choline as an intermediary chemical agent was in fact due to the acetlyaneurin being in the solution in sufficient quantity to produce the desired effect. v Muralt (35) claims that the action of acetylcholine at nerve endings is augmented by aneurin because the latter inhibits the formation of cholinesterase, the enzyme that inactivates acetylcholine.

Lissak et al (36) suggest that aneurin may be an

alternative to acetylcholine in the transmission of nerve impulses and that in effect there is a certain interdependance between aneurin on the one hand and the acetylcholine cholinesterase on the other. They also showed in support of this that the acetylcholine content in vit B1 deficient rat's heart was considerably raised and this might therefore be due either to inhibition of cholinesterase activity in breaking down acetylcholine, or else to an increase in the synthesis of the latter. The fact that there is apparently no difference in the acetylcholine destruction in B1 deficient and normal heart extract is evidence in favour of increased synthesis. In a series of estimations of acetylcholine and cholinesterase content in various organs in normal and B1 deficient animals, these workers found a great variation in normal contents between different individuals. On an average, however, they found the acetylcholine content raised in B1 deficient hearts, striped muscle and smooth muscle, unchanged in the sciatic nerve and lowered in the brain and spinal cord. There was also a definite fall in the serum cholinesterase in B1 deficient animals.

Most of the vit B1 of nerve tissue is in the myelin sheath and this is the storage battery in which acetylcholine synthesis takes place - v Muralt (32).

It can be said that

1) Both acetylcholine and vit B1 are liberated at nerve endings on nerve stimulation.

2) Both are essential as intermediary chemical agents in the transmission of nerve impulses.

3) It is the acetyl ester of both choline and aneurin that produces the effect on nerve stimulation.

4) Vit B1 in nerve tissue is stored in the myelin sheath and this is also where acetylcholine formation takes place.

5) Vit B1 enhances the action of acetylcholine, either by destroying cholinesterase, the enzyme that hydrolysis and inactivates acetylcholine, or by increasing the synthesis of acetylcholine.

6) The acetylcholine content of nerve tissue is lowered in vit B1 deficiency, except in the sciatic nerve where it is unchanged.

Chapter 7

DISCUSSION

Brock (2), who was the first to describe a method of irradiating, with roentgen-rays, one specified area of the body to produce an effect on lesions of psoriasis remote from it, considered that this effect was produced by stimulation of the thymus gland, hypofunction of which, he believed, was associated with psoriasis. He gave various reasons in support of his theory. First, a response was only produced when an area of skin topographically related to the thymus was included in the field of entry of the rays. Second, the fact that an increase in Hassall corpuscles was a constant finding following irradiation of the thymus gland, and these Hassall corpuscles predominate in the thymic remnant of adults, which would account for the response to this method of treatment in adult patients suffering from psoriasis. Third, the rarity of the disease in early childhood when the thymus gland is most active, the aggravation of psoriasis during pregnancy when the thymus undergoes involution, and the frequent development of psoriasis during puberty when involution of the thymus occurs.

Most of the work in the field of medullary radiation has

been done in connection with Lichen planus.

Pautrier (14 & 15), who published the first case of lichen planus treated by this method, was led to it because of the tendency to ascribe to the nervous system an important role in the etiology of this complaint and the beneficial results obtained by the withdrawal of a few c.cs. of cerebrospinal fluid by lumbar puncture. He saw in his results a selective action on the nervous system. By his method he felt certain that there was an action on all the medullary centres, on the posterior roots and on the spinal ganglia and, as there was no doubt but that the sympathetic medullary cells were influenced, some effect must be produced on the ganglion chains of the sympathetic nervous system. As to the mechanism he was not prepared to make any pronouncement as the precise point at which the rays acted could not be defined.

Gouin (37), who favoured unfiltered radiation, considered the site of action was more superficial and believed that his method acted on the neurovegetative system by producing a sensitisation of the entire sympathetic system.

Neumark and Krynski (21) found it difficult to imagine that, by Gouin's unfiltered method, the sympathetic ganglia received a large amount of rays of such mild quality and weak intensity, as they were probably absorbed for the most part

by the skin, subcutaneous tissue and bone tissue. They considered that, in both superficial and deep therapy, the rays acted intensively on the end branches of the sympathetic and sensory nerves and exerted a reflex action on the spinal cord and sympathetic ganglia.

Gawalowski (22) in discussing the problem thought that it was not possible to say whether the action was on the medullary centres, on the ganglia, or on the sympathetic fibres. He carried out his experiment of irradiating the great vessels of the upper and lower limbs in three cases of lichen planus with a view to trying to supply the answer. He chose the armpits and the anterior aspect of the thighs in order to avoid action on the medullary centres and on the sympathetic ganglia. Two of the cases recovered and the same changes were noted in them as were noted in cases recovering after spinal radiation. He therefore considered that it was a question of direct action on the sympathetic fibres. He was not sure whether it was a suppression of function or an x-ray action which could restore normal function to sympathetic fibres functioning abnormally.

Prieto (19) believed that the skin itself plays an important part in the healing mechanism of lichen planus by radio-therapy, by undergoing a certain biological modification

capable of influencing the evolution of lichen planus. In the majority of cases this modification determined the cure.

Hellier (27) thought that his results suggested that the action of the x-rays was on the skin and not on the underlying nervous tissue of the spinal column, but that it was possible that they produced some kind of reflex action through the nerves of the skin. However, it seemed more probable that the action was more in the nature of shock therapy, possibly due to the liberation of some substance in the exposed area.

Medullary radiation in psoriasis, as reported by Gouin (25), Kriser (23), and Gawalowski (22) was not very effective.

Gouin included 24 cases of psoriasis in his review of 150 cases of various dermatoses treated by medullary radiation. Twenty were given unfiltered radiation and four were given filtered radiation. In all the pruritus disappeared but there was no response in the cutaneous lesions. Kriser also produced a response in that the pruritus disappeared and there was a slight objective improvement in the cutaneous lesions. Gawalowski, on the other hand, produced no effect whatever, either in the pruritus or in the cutaneous lesions, using Gouin's method of unfiltered radiation.

The first successful use of medullary radiation as a

therapeutic measure in psoriasis was reported by Rosh (26). He had been impressed by the results obtained in irradiation of the thymus gland and, although he irradiated the sympathetic nervous system, he thought the results were due to the effect this had on thymus tissue.

The theory that the nervous system plays some part in the aetiology of psoriasis is not new and, if this had any substance, it seemed more than likely that medullary radiation would produce results comparable to those achieved in the treatment of lichen planus by this method, provided the action of the rays, in the latter instance, was on the nervous system, proof of which had so far not been advanced.

In was in order to prove whether or not the sympathetic nervous system had any influence in psoriasis that the series under review was started.

First it had to be demonstrated that roentgen rays directed to the cervical and lumbar sympathetic enlargements produced a beneficial effect on a generalised psoriasis eruption. That this was done has already been shown but, this in itself was not sufficient to localise the effect to the sympathetic nervous system. As Prieto suggested in the case of lichen planus, it may have been due simply to a certain biological modification of the skin capable of influencing

the evolution of psoriasis or, again, as Hellier suggested, it may have been shock therapy, due to the liberation of some substance in the exposed areas. The mere choosing of the sympathetic enlargements as the sites of irradiation did not necessarily incriminate the sympathetic nervous system. Nor could it be shown at what level the rays acted. The depth dose graph of the machine used for the majority of the cases is given (Table 6).

Some observations made in the spinal radiation series suggested that the effect of the roentgen-rays was on the sympathetic nervous system. Lesions in the area supplied by the cervical sympathetic nerves did not respond when the lumbar area was irradiated and vice versa, and that the two probably work independently of each other was suggested by the observation, in one case, of an exacerbation of the condition in the area supplied by the cervical sympathetic nerves while a steady improvement was maintained in the area supplied by the lumbar sympathetic nerves. The possible influence of the nervous system was demonstrated in this case also by the zosteriform appearance of the fresh eruption.

In order to arrive at a more definite conclusion, it was necessary to administer some substance which was known to produce the effects of stimulation of the autonomic nervous

Percentage Depth Dose

100 Kv 5 Ma Filter 1.5 mm. Al.

20 cms. f.s.d. 10 cms. Applicator.

Masonite Phantom. Victoreen Dosemeter (100r chamber)

Depth (cm.)	% Depth dose
0	100
1	84
2	61
3	47
4	37
5	29
6	22

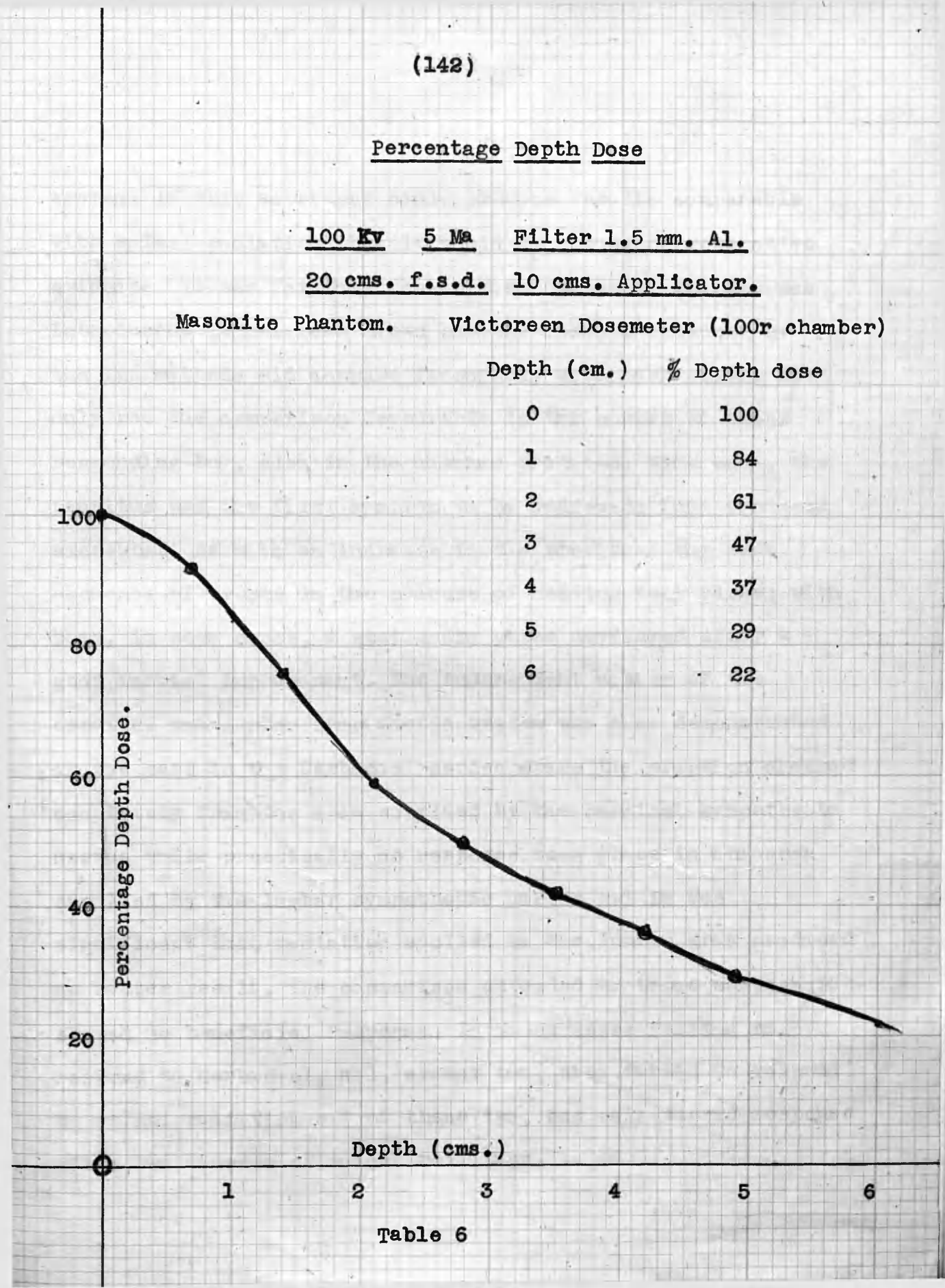

Table 6

system. If this substance could produce results comparable with spinal radiation then it would be strong corroborative evidence. It was for this reason that Carbachol therapy was introduced. It has been shown how the results obtained by the two methods did compare favourably with each other. Not only was the comparison favourable in the number of cases responding but, also in the changes produced. With both, the pruritus was the first symptom to be relieved; both produced exacerbations with an increase in the pruritus; the same sequence of events in the process of healing took place; with both, in some cases, a stationary phase developed after a good initial improvement. The independant action of the cervical and lumbar sympathetic system was also demonstrated in one case in the Carbachol series where the eruption cleared completely from the area supplied by the cervical sympathetic nerves while practically no response took place in the area supplied by the lumbar sympathetic nerves and it was significant that radiation applied to the lumbar area produced no better result. The comparison extended to those cases which showed no beneficial response. In those cases failing to respond to Carbachol, all, except two, also failed to respond to spinal radiation and of these two, one only showed response after two courses of spinal radiation.

In the cases failing to respond to spinal radiation and Carbachol was some other factor necessary to produce an effect? The beneficial results shown by the administration of Thiamin would suggest that this is so. Thiamin is also liberated on nerve stimulation and is also one of the intermediary chemical agents of the autonomic nervous system. It is known that Thiamin enhances the action of acetylcholine and it may well be that this was its action in the six cases described. The real value of Thiamin cannot be judged from the results it produced in these cases and in order to get more information a new series has been started. Up to the present 30 cases of psoriasis have been given Thiamin, either alone or in combination with Carbachol or spinal radiation. It is too soon yet to say whether or not any positive result will be obtained, but it is hoped to publish more about this subject at a future date.

The results obtained by the administration of Carbachol show that the autonomic nervous system has an active role in psoriasis, and the comparable results obtained with spinal radiation strongly support the theory that the action of medullary radiation is due to the effect of the roentgen-rays on the sympathetic nervous system. As can be seen from Table 6, a sufficient percentage of the dose can penetrate to

the spinal cord and medullary centres to produce an effect and even the spinal ganglia, which lie deeper, receive a certain amount of radiation but it is doubtful if this is sufficient to produce an effect. However, as the greatest effect of the rays is at a more superficial level it seems more likely that the action is on the sympathetic nerve terminals in the skin and on the blood vessels which in turn produces a reflex action on the sympathetic ganglia. The postganglionic fibres of the sympathetic nervous system to the smooth muscle of the skin, to the blood vessels and to the sweat glands are cholinergic, i.e., on stimulation acetylcholine is liberated. If this is so then it may well be that the results reported by Brock in 1920 were not due to the effect of the roentgen-rays on the tissue of the thymus gland but were in fact due to the effect of the rays on the sympathetic nerve terminals in the cutaneous tissue. This, too, would explain the results obtained by Prieto and Hellier when they irradiated the chest and abdomen in patients suffering from lichen planus.

What has been said in the foregoing in no way clarifies the position as regards the aetiology of psoriasis, as a chronic focus of infection, prolonged nervous stimulation and imperfect carbohydrate metabolism, to mention only three

of the suspected causes of psoriasis, can all cause impairment in the synthesis of acetylcholine. It is possible that the many and varied causes claimed, by numerous workers, as being responsible for psoriasis, all have the common factor of, either directly or indirectly, having the power to upset acetylcholine synthesis to such an extent as to start the chain of events which eventually leads to the appearance on the skin of the typical lesions of psoriasis.

Although no stress has so far been placed on either method as a means of treating psoriasis, the results show that both may be used as such with good effect. Many of the cases of long duration, who had failed to benefit from any previous form of therapy were improved for the first time with spinal radiation or Carbachol. Psoriasis is a chronic, relapsing skin condition and it is not possible to claim any one remedy as a specific cure, as a recurrence may develope many years after the disease has been apparently cured. If, however, a remedy brings a good measure of relief to the long suffering patient when other means have failed, and, moreover, if after such treatment the relapses tend to be less severe, then that remedy is worthy of consideration when the question of suitable therapy for psoriasis arises. The two methods discussed both fulfil these precepts to a large extent. The

great majority of the patients treated by both methods responded well and some who were treated by spinal radiation two years ago have remained free from psoriasis since. Carbachol was introduced over a year ago and of the patients who have been under review for nine months or more and who recovered completely, only two have so far shown any recurrence and the response to a second course of Carbachol has been as satisfactory as the response to the first course was.

Both spinal radiation and Carbachol are easy to administer and no inconvenience is caused to the patient. There is no need for the patient to be smeared from head to foot with messy ointments and the possible psychological effect of this should not be ignored. So far no bad effects have been observed with either. The producing of an exacerbation was not considered to be an ill effect, especially as, with spinal radiation this was nearly always followed by a complete recovery. This was probably a so-called Herxheimer reaction. When Carbachol produced an exacerbation it was found that spinal radiation had the same effect in the same patient.

Lewis (38) has described an urticarial reaction in women following the ionisation of Carbachol in to the skin. It is possible that the papular eruption which developed in

cases 121 & 133, when the original psoriasis eruption had cleared, was of this nature. At first the papules were not like those of psoriasis but, as no flare was produced when the skin was stroked, it could not be definitely stated that the reaction was urticarial. That the papules later became guttate lesions of psoriasis is still no guide to the nature of the eruption at the beginning, as this could be a natural development in a psoriasis patient.

The drawback to spinal radiation as a therapeutic measure is that it cannot be repeated too often and with patients relapsing quickly is of no real value. In the series reviewed no more than two treatments to the spine were given. No matter how beneficial the results at the time, the repeated application of roentgen-rays is to be deprecated. This does not condemn it as a therapeutic measure, however, as some cases in the present review have remained free of symptoms for almost two years and Rosh (26) reported cases still clear four and a half years after spinal radiation.

Some fatal accidents have been reported following the accidental administration of an overdose of Carbachol by the intramuscular route. However, where the patient is under regular surveillance and where the dose is within safe limits, as it was in the series reviewed, it can be given over long

periods and can be repeated if any relapse occurs, without causing the patient any harm. The use of Carbachol intramuscularly is not advised. In the two patients in which this was tried mild signs of intolerance developed before any appreciable difference had been made on the psoriasis. In any case, oral administration gives a more prolonged action and is much easier to administer where a large number of ambulatory patients are being dealt with. A history of gastric ulceration or chronic dyspepsia are contra-indications for the use of Carbachol and in one patient, who also suffered from asthma, treatment had to be discontinued because the attacks of asthma became more frequent and more severe.

The only specific cure in any illness is one which will remove the cause. A glance through the literature on psoriasis will be sufficient to show the number of causes suggested are legion. A suggestion that an upsetting influence on the autonomic nervous system may be common to most of them has been made during the course of this survey. To aim at righting this disorder in the autonomic nervous system either by the use of spinal radiation or Carbachol may give satisfactory results, but a complete answer to the problem cannot be arrived at until the factor primarily causing the upset has been found and has been eliminated.

Chapter 8

SUMMARY

1). A review of 186 cases of Psoriasis is given.

2). 100 cases had roentgen-rays applied to the Lumbar and Cervical Sympathetic Enlargements.

83 cases (83%) responded (the eruption cleared or improved); 17 cases (17%) were unimproved.

3). 84 cases had Carbachol administered by mouth.

64 cases (76.2%) responded (the eruption cleared or improved); 20 cases (23.8%) were unimproved.

4). 2 cases had Carbachol administered by intramuscular injection.

There was no response before the onset of mild signs of intolerance to the drug.

5). 6 cases failing to respond to Carbachol orally and to Spinal Radiation were given Thiamin hydrochloride by mouth.

1 case cleared completely and the others were improved.

6). The results in the series of cases given Carbachol, a substance which reproduces the effects of stimulation of the Autonomic Nervous System, show that this System plays an active role in Psoriasis.

7). The almost identical results observed in the Spinal Radiation series is evidence that the action of the roentgen-rays is on the Autonomic Nervous System.

8). It has been suggested that this action is on the sympathetic end branches to the skin, which in turn produces a reflex action on the sympathetic ganglia.

9). It has been shown that Thiamin, another chemical intermediary of the Autonomic Nervous System, may also have a beneficial influence in Psoriasis.

BIBLIOGRAPHY

1). McLeod, J. M. H. & Muende, J. (1946). Practical Handbook of the Pathology of the Skin. (Lewis).

2). Brock, W. (1920). Strahlentherap., 11, 2.

3). Foerster, O. H. & Foerster, H. R. (1921). Arch. Derm. & Syph., 4, 639.

4). Schneider, P. (1922). Wien. klin. Wchnschr., 35, 565.

5). Kumer, L. (1924). Wien. klin. Wchnschr., 37, 1870.

6). Gawalowski, K. (1923). Ceska dermat., 5, 1.

7). Rummo, R. (1924). Gior. ital. di mal. ven., 65, 578.

8). Samberger (1921). Acta derm. venereol., 2, 359.

9). Gross, B. G. (1922). Deutche med. Wchnschr., 48, 1211.

10). Spillman, L. & Carillon, L. (1925). Bull. Soc. franc de dermat. et syph., 32, 63.

11). Hanney (1923 - 24). Proc. Soc. M. & Chir., 17, 92. (discussion).

12). Jamieson, R. C. (1928). Arch. Derm. & Syph., 18, 109.

13). Gorl & Voigt (1921). Munchen. med. Wchnschr., 68, 1423.

14). Pautrier, L. M. (1924). Bull. Soc. franc de dermat. et syph., 31.

15). Pautrier, L. M. (1927). Bull. Soc. franc de dermat. et syph., 34, 602.

16). Hufschmidt (1924). Bull. Soc. franc de dermat. et syph., 31, 71.

17). Gouin, J. (Sept. 1924). Bull. Med.

18). Payeuneville & Billiard (1927). Bull. Soc. franc de dermat. et syph., 34, 598.

19). Prieto, J. G. (1927). Bull. Soc. franc de dermat et syph., 34, 599.

20). Hudelo, Laporte & Kourilsky (1925). Bull. Soc. Derm. Syph., 32, 6.

21). Neumark, S. & Krynski, A. (1927). Strahlentherap. 25, 427 - 442.

22). Gawalowski, K. (1927). Bull. Soc. franc de dermat. et syph., 34, 594.

23). Kriser, A. (1925). Wien. klin. Wchnschr., 21, 569.

24). Gouin, J. (1926). Bull. de la soc. de derm., 8.

25). Gouin, J., Bienvenue, A. & Dewing, W. (1927). Bull. Soc. franc de dermat. et syph., 34, 124.

26). Rosh, J. (1934). The American Journal of Roentgenology, 82, 32.

27). Hellier, F. F. (1934). Brit. Jour. of Derm. & Syph., 55, 11.

28). Loewi, O. (1945). J. Mt. Sinai Hosp., 12, 803.

29). Thompson, R. H. S. & Whittaker, V. P. (1944). Biochem. J., 38, 295. Quoted in Modern Trends in Dermatology. McKenna. (Butterworth). 1948.

30). Brown, G. L. & Feldberg, W. (1936). Jour. Physiol. 88, 265.

31). Mann, P. J. G., Tennenbaum, M. & Quastel, J. H. (1939). Biochem. Jour., 33, 822.

32). von Muralt, A. (1943). Nature, 152, 188.

33). Leichti, A., von Muralt, A. & Reinest, M. (1943). Helv. Physiol. Acta, 1, 79.

34). Kuhn, R., Wieland, T. & Huebschmann, H. (1939). Zeitschr. f. physiol. Chem., 259, 48.

35). von Muralt, A. (1939). Naturwis, 17, 265.

36). Lissak, K., Kovacs, T. & Nagg, E. K. (1943). Pflugers Arch. f. ges. Physiol., 247, 124.

37). Gouin, J. (1925). Bull. Soc. franc de dermat. et syph., 32, 80.

38). Lewis, T. (1944). Clin. Sci., 5, 5.

APPENDIX

SERIES 1.

SPINAL RADIATION

Case 1.

H. L. Age 24 Male

Family History The patient's mother also suffers from psoriasis.

Personal History The patient has always been healthy. The first appearance of psoriasis was at the age of 12. This was cleared with ointments but recurred 4 years ago. Since then there has been no improvement from any form of therapy.

On Examination (2 Aug. 46) There was gross and widespread involvement of the trunk and limbs. On the trunk there were large geographic plaques with, here and there, scattered guttae. On the limbs the lesions were more nummular with geographic formations round the knees and elbows. The scalp was covered by a massive, infiltrated crust.

Treatment 600 r to the lumbar and cervical areas, in weekly doses of 200 r, each area being treated on alternate weeks.

Technical Factors

Kv	Ma	f.s.d.	Diam. of appl.	Filter
100	4	25 cms.	10 cms.	2 mm. Al.

Result All trace of the eruption had cleared by 26 Nov. 46, 4 months later.

Case 2.

M.A. Age 20 Female.

Family History Nil.

Personal History The patient has always been well. Psoriasis first appeared on the ankles 13 years ago. She has never been completely clear of the eruption since.

On Examination (7 Aug. 46) There was a widespread guttate eruption involving the scalp, trunk and limbs. The

guttae were infiltrated and covered by tough, white scales. There was a marked degree of irritation.

Treatment 600 r to the lumbar and cervical areas, in weekly doses of 200 r, each area being treated on alternate weeks.

Technical Factors

Kv	Ma	f.s.d.	Diam. of appl.	Filter
100	4	25 cms.	10 cms.	2 mm. Al.

Result All trace of the eruption had cleared by 23 Nov. 46, 4 months later.

Case 3.

R. S. L. Age 19 Male

Family History Nil.

Personal History The only illness reported was Pneumonia at 17. Psoriasis first appeared 6 years ago. Only the elbows were affected and ointment cleared the eruption. Reappeared a year ago. Has not been improved by any treatment since.

On Examination (8 Aug. 46) There were multiple, discrete, heavily scaling guttate lesions on the arms, from the elbows down, and on the legs, from the knees down. As well as the guttate lesions there were numerous papules. The upper part of the arms and legs, the trunk and the scalp were clear.

Treatment. 6 00 r to the lumbar and cervical areas, in weekly doses of 200 r. The cervical area had a complete course before the lumbar area was treated.

Technical Factors

Kv	Ma	f.s.d.	Diam. of appl.	Filter
100	4	25cms.	10 cms.	2 mm. Al.

Result All lesions had cleared by 8 Nov. 46, six weeks after the last treatment.

Case 4.

L.R.C. Age 22 Male

Family History: Nil.

Personal History: The patient has always been well. Psoriasis first began at the age of 16. Since then there have been yearly relapses.

On Examination. (8 Aug. 46): There was a severe, generalised eruption involving all areas of the body. The lesions range from papules to large, geographic plaques. Scaling was heavy. The scalp was extensively involved.

Treatment: 600 r to the lumbar and cervical areas, in weekly doses of 200 r, each area being treated alternately.

Technical Factors:

Kv	Ma	f.s.d.	Diam. of appl.	Filter
100	4	25 cms.	10 cms.	2 mm. Al.

Result: At the end of 9 months there was no appreciable improvement.
Unimproved.

Case 5.

E. S. Age 24 Female

Family History: Nil

Personal History: The patient has always been healthy. She first noticed the psoriasis a year before examination. There have been no remissions since.

On Examination (9 Aug. 46): There were multiple guttate lesions on the arms, legs and trunk, covered by tough, crusted scales. On the right shin there was a raised, tough scaling, infiltrated plaque. The scalp was extensively involved.

Treatment: 600 r to the lumbar and cervical areas, in

weekly doses of 200 r. The lumbar area had a complete course before the cervical area was treated.

Technical Factors	Kv	Ma	f.s.d.	Diam. of appl.	Filter
	100	4	25 cms.	10 cms.	2 mm. Al.

Result All trace of the eruption had cleared by 29 Nov. 46, 4 months later.

Case 6.

T. W. Age 41 Male

Family History Nil

Personal History There was no history of any previous illnesses. Psoriasis first appeared a year before examination. There have been no remissions since the onset.

On Examination (12 Aug. 46) There were typical, heavily scaling, infiltrated plaques on both elbows. In the pubic region there was a raised, dull red, infiltrated plaque covered by a thick, yellowish crust. There was fine dandruff-like scaling on the scalp.

Treatment 600 r to the lumbar and cervical areas, in weekly doses of 200 r. The lumbar area was treated first.

Technical Factors	Kv	Ma	f.s.d.	Diam. of appl.	Filter
	100	4	25 cms.	10 cms.	2 mm. Al.

Result All trace of the eruption had cleared by 6 Nov. 46, 12 weeks later.

Case 7.

J. Y. Age 19 Female

Family History Nil.

Personal History

The patient has always been healthy. Psoriasis first began at the age of 8. There was a period of freedom from the eruption for 3 months 7 years ago. Since then there have been no remissions.

On Examination

(16 Aug. 46)

The legs were particularly heavily affected. There were numerous small, round, infiltrated plaques and very little normal tissue. There was a similar eruption on the arms. On the trunk there was a widely scattered guttate eruption. Irritation, particularly on the legs was very troublesome.

Treatment.

600 r to the lumbar and cervical areas, in weekly doses of 200 r, each area being treated alternately.

Technical Factors

Kv	Ma	f.s.d.	Diam. of appl.	Filter
100	4	25 cms.	10 cms.	2 mm. Al.

Result.

All traces of the eruption had cleared by 10 May 47, 9 months later.

Case 8.

C. P. Age 21 Male.

Family History

Nil.

Personal History

No history of any previous illness. First noticed psoriasis at the age of 18. There have been no remissions since.

On Examination

(21 Aug. 46)

The back and thighs were the areas most affected. On these areas there were numerous circular and ovoid, red, infiltarted lesions covered by shining translucent scales. The limbs are practically clear, some shining, non-scaling papules round the knees and elbows being the only abnormality. The scalp was also affected.

Treatment

600 r in weekly doses of 200 r to the lumbar and cervical areas, each area being treated alternately.

Technical Factors	Kv	Ma	f.s.d.	Diam. of appl.	Filter
	100	4	25 cms.	10 cms.	2 mm. Al.

Result All trace of the eruption had cleared by 6 Feb. 47, 6 months later.

Case 9.

Mrs. A Age 62 Female

Family History Nil.

Personal History The patient never had any serious illness until 9 years ago, when her husband died very suddenly. She had a severe nervous breakdown at that time, and 10 months later an acute generalised psoriasis developed. There have been no remissions since, nor any response to numerous and various treatments.

On Examination (2 Sept. 46) With the exception of the face, palms and the soles of the feet, the whole body surface was involved. From the wrists, up the arms to the shoulders, spreading about 1 inch up the neck, across the chest and back, down the abdomen and the bottom of the back, over the buttocks, genitalia, groins, down the thighs and legs on to the dorsa of the feet, there was one contiuous sheet of dull red, shining, beefy looking, infiltrated tissue. The skin markings were greatly exaggerated. On scratching the surface a white streak, composed of fine powdery scales was produced. The junction of normal tissue with abnormal was well defined. The patient complained of intense irritation generally, with extreme discomfort in the groins and genitalia.

Treatment 600 r to the lumbar and cervical areas, in weekly doses of 200 r, each area being treated on alternate weeks.

Technical Factors	Kv	Ma	f.s.d.	Diam. of appl.	Filter
	100	4	25 cms.	10 cms.	2 mm. Al.

Result All trace of the eruption had cleared by 6 Aug. 47, 11 months later.

Case 10.

A. McM. Age 45 Male

Family History Nil.

Personal History Fifteen years ago the patient had Pneumonia and following this psoriasis developed for the first time. It started on the ankle but soon spread until the whole body was extensively involved. There have been no remissions since.

On Examination (4 Sept. 46) The trunk and the limbs were covered by large, infiltrated, geographic plaques. The sides of the trunk, however, were relatively clear, as was the chest, only a few nummular plaques and guttae being evident. The lesions were covered by tough, adherent scales. The scalp was extensively involved, the lesions extending on to the face. The patient complained of severe irritation.

Treatment Two courses of 600 r to the lumbar and cervical areas.
Later, Thiamin hydrochloride mgm. 25, daily

Technical Factors	Kv	Ma	f.s.d.	Diam. of appl.	Filter
	100	4	25 cms.	10 cms.	2 mm. Al.

Result Improved after 1st. course. Relapsed.
Improved after 2nd. course. Relapsed.
Improvement also followed Thiamin therapy.

Case 11.

T. C. G. Age 34 Male

Family History Nil.

Personal History

The patient has always been well. Psoriasis first began 9 months prior to examination. It appeared on the right shin following an injury. Various treatments, including direct x-radiation, produced no improvement.

On Examination (25 Sept. 46)

There were two large, circular, infiltrated plaques on the right shin and one on the left shin. They were covered by heaped-up, dull white crusts. On the glans penis there were four, small, non-scaling papules.

Treatment

600 r to the lumbar area, in weekly doses of 200 r.

Technical Factors

Kv	Ma	f.s.d.	Diam. of appl.	Filter
100	4	25 cms.	10 cms.	2 mm. Al

Result

All trace of the eruption had cleared by 3 Dec. 46, 3½ months later.

Case 12.

R. M. Age 35 Male

Family History

Nil.

Personal History

The patient has always been well. Psoriasis began 2½ years prior to examination. It has never cleared since.

On Examination (7 Oct. 46)

There were heavily scaled plaques on the legs, arms and trunk. As well as the plaques there were numerous, scattered, heavily crusted guttate lesions. The scalp was severely affected.

Treatment

600 r to the lumbar and cervical areas, in weekly doses of 200 r. The lumbar area was treated first.

Technical Factors

Kv	Ma	f.s.d.	Diam. of appl.	Filter
100	4	25 cms.	10 cms.	2 mm. Al

Result

All trace of the eruption had cleared by 8 Feb. 47, 4 months later.

Case 13.

J. W. Age 14 Female

Family History Nil.

Personal History The patient gave no history of any illness. Psoriasis began 10 years before examination and has been severe and intractible since. Although the eruption has always been generalised, the legs have always been the most severely affected.

On Examination (19 Oct. 46) The legs from the buttocks to the ankles were covered by a mass of small circular plaques (fig. 71). On the arms the plaques were larger and more irregular in outline. There were plaque and guttate formations on the trunk. All the lesions were covered by thick, white crusts. The scalp was covered by a massive crust. Round the hair margin and on the temples there were numerous, crusted lesions. Irritation, particularly on the legs was severe.

Treatment Two courses of 600 r to the lumbar and cervical areas.

Technical Factors

Kv	Ma	Diam. of appl.	f.s.d.	Filter
100	4	10 cms.	25 cms.	2 mm. Al.

Result Cleared after 1st. course. Relapsed.
Cleared after 2nd. course. Relapsed.

Case 14.

W. S. D. Age 34 Male

Family History Nil.

Personal History The patient has always been healthy. First noticed psoriasis at the age of 14. He has never been clear since.

On Examination (30 Oct. 46) The whole body was involved. Generalised small guttate lesions, infiltrated and covered by small, white, adherent scales.

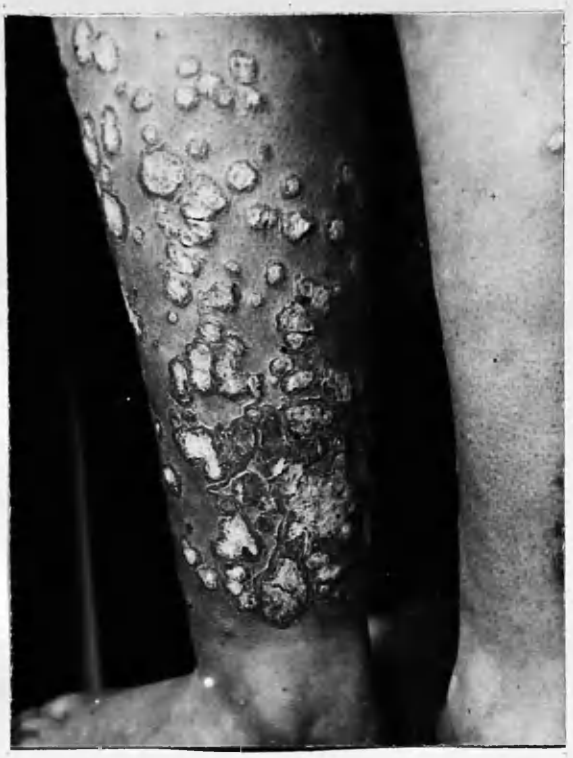

Fig. 71.

Case 13.

The legs as seen at first examination.

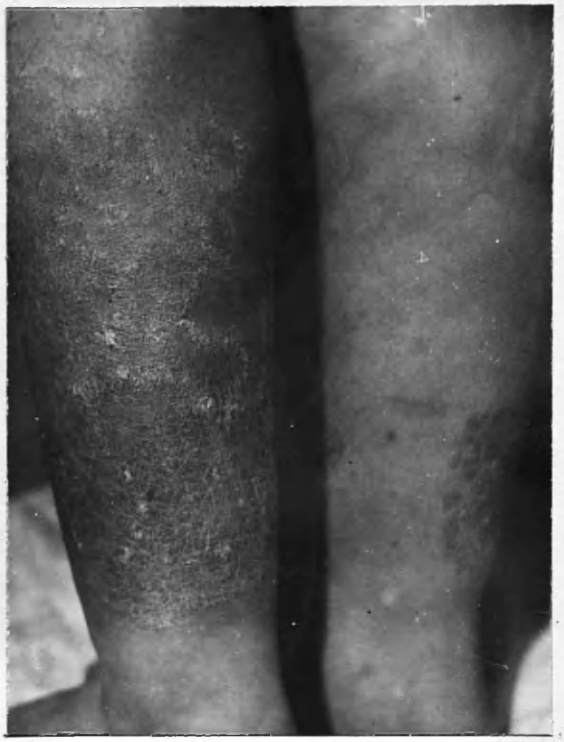

Fig. 72.

Case 13.

6 months later.

There were heavily crusted plaque formations round the knees and elbows and numerous scaling lesions on the scalp.

Treatment

Two courses of 600 r to the lumbar and cervical areas, in weekly doses of 200 r. 4 months elapsed between the courses.

Technical Factors

Kv	Ma	f.s.d.	Diam. of appl.	Filter
100	4	25 cms.	10 cms.	2 mm. Al.

Result

Unimproved.

Case 15.

J. W. Age 37 Male

Family History

Nil.

Personal History

The patient gave a history of chronic bronchitis and chronic dyspepsia. Psoriasis first began 9 years before examination. No remissions since.

On Examination

(30 Oct. 46)

The patient looked undernourished and of poor physique. There was a widespread eruption involving all areas of the body. The trunk was covered by crusted, infiltrated plaques and gyrate lesions. On the limbs the lesions were more nummular. The scalp was covered by a massive, infiltrated crust and there were numerous small, erythematous, scaling lesions on the face.

Treatment

Two courses of 600 r to the lumbar and cervical areas, in doses of 200 r. During the first course the patient attended very irregularly.

Technical Factors

Kv	Ma	f.s.d.	Diam. of appl.	Filter
100	4	25 cms.	10 cms.	2 mm. Al.

Result

Unimproved.

Case 16.

N. B. Age 18 Male

Family History Nil.

Personal History There was no history of any previous illness. Psoriasis first began 5 years before examination. Since then there have been no remissions.

On Examination (4 Nov. 46) The legs and scalp were most severely affected. On both legs, extending almost from the knees to the ankles, there was a large, irregular, infiltrated, heavily scaling plaque. On the scalp there were numerous, circular, scaling lesions. On the arms only the elbows were affected. The trunk was clear. There was marked irritation on the legs.

Treatment 600 r to the lumbar area, in weekly doses of 200 r. This area was treated first.
400 r to the cervical area, in weekly doses of 200 r.

Technical Factors

Kv	Ma	f.s.d.	Diam. of appl.	Filter
100	4	25 cms.	10 cms.	2 mm. Al.

Result All trace of the eruption had cleared by 16 Dec. 46, 6 weeks later.

Case 17.

L. M. Age 19 Male

Family History Nil.

Personal History With the exception of a query pneumonia as a child, there was no history of any previous illness. Psoriasis began 4 months before examination. No remissions since.

On Examination (6 Nov. 46) On the legs, from the thighs to the ankles, there were multiple lesions, varying from

non-scaling papules to small, irregular, heavily crusted plaques. On the trunk and arms the lesions were small and circular and were covered by fine, white, adherent scales. A massive crusted plaque covered the entire scalp. There was marked irritation.

Treatment 600 r to the lumbar and cervical areas, in weekly doses of 200 r, each area being treated alternately.

Technical Factors

Kv	Ma	f.s.d.	Diam. of appl.	Filter
100	4	25 cms.	10 cms.	2 mm. Al.

Result All trace of the eruption had cleared by 29 May 47, 6½ months later.

Case 18.

E. W. Age 15 Female

Family History Nil.

Personal History The patient had pleurisy at 1½ years of age. Since then she has always been healthy. Psoriasis first began 7 years before examination. Has never cleared since.

On Examination (7 Dec. 46) There was a widespread eruption involving all areas of the body. The lesions were mainly guttate with plaque formation between the shoulders, between the breasts and in the sacral region. All the lesions were covered by tough, adherent scales. On the scalp there was a massive, infiltrated crust.

Treatment 600 r to the lumbar and cervical areas, in weekly doses of 200 r, each area being treated alternately

Technical Factors

Kv	Ma	f.s.d.	Diam of appl.	Filter
100	5	20 cms.	10 cms.	1.5 mm Al.

Result All trace of the eruption had cleared by 8 Mar. 47, 4 months later.

Case 19.

C. K. Age 13 Female

Family History: Nil.

Personal History: The patient has always been healthy and the skin was clear until 1½ years before examination. There have been no remissions since.

On Examination (14 Dec. 46): There was a widespread eruption involving all areas of the body. On the trunk there were annular and gyrate configurations, with scattered guttate lesions as well. On the arms the lesions were guttate, but on the legs large, irregular plaques had formed. All were covered by tough, adherent scales. There were numerous erythematous, finely scaling lesions on the face and the scalp was covered by a thick, greyish white crust.

Treatment: 600 r to the lumbar and cervical areas, in weekly doses of 200 r, each area being treated alternately.

Technical Factors:

KV	Ma	f.s.d.	Diam. of appl.	Filter
100	5	20 cms.	10 cms.	1.5 mm. Al.

Result: A few scaling papules persisted on the legs.
Improved.

Case 20.

L. W. Age 42 Male.

Family History: Nil.

Personal History: The patient had Pneumonia in 1930, but otherwise has always been well. Psoriasis first began 7 years before examination. Has never been clear since.

On Examination (14 Dec. 46): Mainly knee-elbow involvement. Round the elbows and on the left knee there were

infiltrated, circular, heavily scaling plaques. On the left leg, below the knee, there were two crusted plaques and on the left thigh, at the level of the great trochanter there was another plaque. The trunk, face and scalp were clear.

Treatment

600 r to the lumbar and cervical areas, in weekly doses of 200 r.
300 r to the left popliteal fossa, in weekly doses of 100 r.
Course to lumbar and cervical areas repeated.

Technical Factors

Kv	Ma	f.s.d.	Diam. of appl.	Filter
100	5	20 cms.	10 cms.	1.5 mm Al.

Result

Cleared after 1st. course. Relapsed.
Cleared after 2nd. course.

Case 21.

J. T. Age 22 Male

Family History

Nil.

Personal History

The patient has always been healthy. He first noticed a patch of psoriasis on the left leg 10 years previously following an injury. A second patch appeared 8 years later after a gunshot wound. The condition became generalised 6 months before examination

On Examination

(6 Jan. 47)

The arms and the legs were the most severely affected. On them there were large, heavily scaling plaque formations. There were scattered nummular plaques on the trunk. On the scalp there were numerous scaling papules.

Treatment

600 r to the lumbar and cervical areas, in weekly doses of 200 r, each area being treated alternately.

Technical Factors

Kv	Ma	f.s.d.	Diam. of appl.	Filter
100	4	25 cms.	10 cms.	2 mm. Al.

Result

All trace of the eruption had cleared by 25 Apr. 47, 4½ months later.

Case 22.

D. J. McC. Age 20 Male

Family History The patient's sister also has psoriasis. (Case 42).

Personal History From time to time the patient suffers from Rheumatism, but otherwise he is healthy. Psoriasis first appeared 6 years before examination.

On Examination (7 Jan. 47) There was an acute generalised eruption involving all areas of the body. There was an almost continuous, bright red, heavily crusted sheet of psoriatic tissue, covering the trunk and limbs. On the palms and soles there were numerous scaling papules, The face had a blotchy red appearance and a massive crust covered the scalp. Irritation was intense.

Treatment 600 r to the lumbar and cervical areas, in weekly doses of 200 r.

Technical Factors

Kv	Ma	Diam. of appl.	f.s.d.	Filter
100	4	10.cms.	25 cms.	2 mm. Al.

Result All trace of the psoriasis had cleared by 13 Jun. 47, 6 months later.

Case 23.

E. P. L. Age 8 Female

Family History Nil.

Personal History No history of any previous illness. Two years before examination the patient broke her wrist. Psoriasis developed soon after.

On Examination (18 Jan. 47) There was a generalised guttate eruption involving the trunk and limbs. The greatest concentration of lesions was round the knees and on the lower part of the legs. There were numerous scaling papules on the scalp. All the lesions were heavily scaled.

Treatment

600 r to the lumbar and cervical areas, in weekly doses of 100 r. 1st. course.
300 r to the lumbar and cervical areas. in weekly doses of 100 r. 2nd. course.

Technical Factors

Kv	Ma	f.s.d.	Diam. of appl.	Filter
100	5	20 cms.	7.5 cms.	2 mm. Al.

Result

Cleared after 1st. course. Relapsed.
Cleared after 2nd. course. Relapsed.
Cleared spontaneously.

Case 24.

H. H. Age 7 Male

Family History

There is a strong family history of psoriasis.

Personal History

The patient has had Bronchitis and Rheumatism. Psoriasis first began 7 months before examination.

On Examination (25 Jan. 47)

There were numerous small, circular, crusted plaques on both the arms and the legs. Round the elbows and knees the plaques were larger and more irregular in outline. The rest of the body was clear.

Treatment

4 00 r to the lumbar and cervical areas, in weekly doses of 100 r. 1st. course.
600 r to the lumbar and cervical areas, in weekly doses of 100 r . 2nd. course.

Technical Factors

Kv	Ma	f.s.d.	Diam. of appl.	Filter
100	5	20 cms.	7.5 cms.	2 mm Al.

Result

Cleared after 1st. course. Relapsed.
Cleared after 2nd. course.

Case 25.

G. S. Age 13 Female

Family History

The patient's father and grandfather had psoriasis.

Personal History — There is no history of any previous illness. Psoriasis first appeared 2 years before examination.

On Examination (25 Jan. 47) — On the trunk there were numerous, small, silvery, scaling papules. There were irregular areas of erythema covered by fine, white scales, on the arms and legs. There were scattered, scaling papules on the scalp.

Treatment — 600 r to the lumbar and cervical areas, in weekly doses of 100 r.

Technical Factors

Kv	Ma	f.s.d.	Diam. of appl.	Filter
100	5	20 cms.	7.5 cms.	1.5 mm. Al

Result — All trace of the eruption had cleared by 9 Sept. 47, 8 months later.

Case 26.

M. McF. Age 13 Female

Family History — Nil.

Personal History — The patient gave a history of Pneumonia, Bronchitis and Rickets. Psoriasis was first noticed 9 years before examination.

On Examination (25 Jan. 47) — All areas of the body were involved in a severe eruption in which all types of lesions, from small, scaling papules to large, infiltrated plaques, were present. The largest plaque formations were mainly on the arms, buttocks and thighs. The scalp was heavily crusted. Itching was intense, especially at night, and there were numerous excoriations. Many of the lesions were impetiginised.

Treatment — 600 r to the lumbar and cervical areas, in weekly doses of 100 r.

Technical Factors

Kv	Ma	f.s.d.	Diam. of appl.	Filter
100	5	20 cms.	10 cms.	1.5 mm. Al

Result — All trace of the eruption had cleared by 31 May 47, 4½ months later. Relapsed.

Case 27.

R.J.M. Age 20 Male

Family History Nil.

Personal History No history of any serious illness. First noticed psoriasis 8 years before examination. There have been no remissions since the onset.

On Examination (27 Jan. 47) There was widespread involvement. On the trunk the lesions were mainly guttate and were covered by tough, white, adherent scales. On the limbs there were massive geographic plaques, heavily crusted and deeply infiltrated. The scalp, especially at the frontal hair margin, was heavily crusted and there were numerous, finely scaling, guttate lesions on the face. The patient complained of severe irritation.

Treatment 500 r to the lumbar area, followed, a week later by a similar dose to the cervical area.
600 r to the lumbar and cervical areas, in weekly doses of 200 r, two months later.

Technical Factors

Kv	Ma	f.s.d.	Diam. of appl.	Filter
100	4	25 cms.	10 cms.	2 mm. Al.

Result Unimproved after 1st. course.
Marked improvement after 2nd. course.
Further review not possible.
Improved.

Case 28.

M. S. Age 14 Female

Family History There is no history of psoriasis in the patient's immediate family, but two cousins suffer from it.

Personal History The only serious illness was Pneumonia as a child. Psoriasis first developed 7 years before examination. Since its onset there have been no remissions.

On Examination (1 Feb. 47)

There was a generalised papular, guttate and small plaque eruptioninvolving all areas of the body. Scaling varied from fine, white scales to heavy crusts. The scalp was mainly involved at the hair margin.

Treatment

600 r to the lumbar and cervical areas, in weekly doses of 200 r. 1st. course.
600 r to the lumbar and cervical areas, in weekly doses of 200 r. 2nd course.

Technical Factors

Kv	Ma	f.s.d.	Diam. of appl.	Filter
100	5	20 cms.	10 cms.	1.5 mm. Al

Result

Unimproved after 1st.course.
Unimproved after 2nd. course.

Case 29.

G. K. Age 6 Female.

Family History

Nil.

Personal History

No history of any serious illness. Psoriasis first developed 6 months prior to examination.

On Examination (8 Feb. 47)

There was a bright erythematous, finely scaling eruption in the lumgo-sacral region, on the buttocks and on the thighs. There was also an infected, eczematised condition superimposed. On the extensor surface of the right forearm there was a similar type of eruption.

Treatment

300 r to the lumbar and cervical areas,in weekly doses of 100 r, each area being treated alternately.

Technical Factors

Kv	Ma	f.s.d.	Diam. of appl.	Filter
100	5	20 cms	7.5 cms.	1.5 mm. Al

Result

All trace of the eruption had cleared by 9 Aug. 47, 6 months later.

Case 30.

E. M. M. Age 30 Female

Family History Nil.

Personal History The patient has always been healthy. First noticed psoriasis 1½ years before examination. Has never been clear since.

On Examination (11 Feb. 47) There was one large, scaling, infiltrated plaque on the outer aspect of the left calf and a smaller, circular one on the left thigh. There was also plaque formation on the left shoulder. All were covered by large, white, adherent scales.

Treatment 600 r to the lumbar and cervical areas, in weekly doses of 200 r.

Technical Factors

Kv	Ma	f.s.d.	Diam. of appl.	Filter
100	5	20 cms.	10 cms.	1.5 mm. Al

Result Unimproved.

Case 31.

M. L. Age 19 Female

Family History A brother also suffers from psoriasis (Case 34).

Personal History The patient gave a history of Pneumonia and Empyema. Psoriasis first appeared 9 years prior to examination.

On Examination (22 Feb. 47) The condition was very mild. There were scaling papules round the elbows and knees and one small guttate lesion on the back. The rest of the body surface was clear.

Treatment 600 r to the lumbar and cervical areas, in weekly doses of 200 r.

Technical Factors

Kv	Ma	f.s.d.	Diam. of appl.	Filter
100	5	20 cms.	10 cms.	1.5 mm. Al

Result All trace of the eruption had cleared by 5 Apr. 47, 6 weeks later.

Case 32.

I. H. D. Age 13 Female

Family History The patient's paternal grandmother suffered from psoriasis.

Personal History No history of any illness. Just before the onset of psoriasis, 3 years prior to examination, the patient sustained an injury to the left leg. Since the onset there have been no remissions.

On Examination (22 Feb. 47) On the legs, from the buttocks down to the ankles, there were numerous, large, roughly circular, infiltrated plaques. On the arms there was plaque formation round the elbows with guttae from the shoulders to the wrists. The scalp was covered by raised, crusted lesions, which spread round the hair margin and on to the forehead. On the trunk the eruption was papular with here and there small plaque formations.

Treatment 600 r to the lumbar and cervical areas, in weekly doses of 200 r.

Technical Factors

Kv	Ma	f.s.d.	Diam. of appl.	Filter
100	5	20 cms.	10 cms.	1.5 mm. Al

Result All trace of the eruption had cleared by 21 Jun. 47, 4 months later.

Case 33.

A. D. B. Age 32 Female

Family History Nil.

Personal History With the exception of ringworm at the age of 9, the patient has never had any skin trouble or serious illness. Psoriasis began 7 years prior to examination and has never cleared since.

On Examination (7 Mar. 47)

On both legs, between the knees and the ankles, there were numerous, small, irregular plaques, dull red in coluor and covered by shiny, semi-translucent, adherent scales. Round the knees, the plaques were more infiltrated and covered by a heaped-up crust. On the thighs the lesions were more widely scattered, but were similar in appearance to those below the knees. The arms, between the elbows and the wrists, were covered by a mass of small circular guttae about the size of a small pea. On the scalp there were a few scattered, heavily scaled papules. The face and trunk were clear.

Treatment

600 r to the lumbar and cervical areas, in weekly doses of 200 r.

Technical Factors

Kv	Ma	f.s.d.	Diam. of appl.	Filter
100	4	25 cms.	10 cms.	2 mm. Al.

Result

All trace of the eruption had cleared by 30 Jun. 47, 4 months later, except for a few flat papules at the knees and elbows.

Case 34.

P. L. Age 28 Male

Family History

The patient's sister also suffers from psoriasis (Case 31).

Personal History

The patient gave a history of Bronchitis, Pneumonia and Pleurisy. Psoriasis first began 18 years prior to examination. There have been no remissions since.

On Examination (8 Mar. 47)

The trunk was chiefly involved, the lesions varying from small scaling papules to heavily crusted, nummular plaques. There were plaques round the knees and elbows and papules and guttate lesions scattered on both the upper and lower limbs. The scalp was covered by a fine, dandruff-like scaling.

Treatment

600 r to the lumbar and cervical areas, in weekly doses of 200 r. 1st. course.

600 r to the lumbar and cervical areas, in weekly doses of 200 r. 2nd. course.

Technical Factors	Kv	Ma	f.s.d.	Diam. of appl.	Filter
	100	5	20 cms.	10 cms.	1.5 mm. Al

Result Improved after the first course. Relapsed.
Cleared after the second course. Relapsed.

Case 35.

S. McC. Age 10 Female

Family History The patient's mother also has psoriasis.

Personal History The patient has always been well. Psoriasis began 3 years prior to examination. There have been no remissions since.

On Examination (8 Mar. 47) There was a widespread papular and guttate eruption, the latter being confined mainly to the legs, below the knees. The lesions were erythematous and covered by white, brittle scales. There was a large, infiltrated plaque on each knee. On the scalp there were numerous scaling papules.

Treatment 400 r to the lumbar and cervical areas, in weekly doses of 100 r.

Technical Factors	Kv	Ma	f.s.d.	Diam. of appl.	Filter
	100	5	20 cms.	7.5 cms.	1.5 mm. Al

Result All trace of the eruption had cleared by 17 May 47, 2½ months later.

Case 36.

C. H. F. Age 15 Female

Family History Nil.

Personal History The patient has always been well. Psoriasis began 6 months prior to examination. No response to any treatment so far.

On Examination (15 Mar. 47)

There was a generalised involvement of the skin, the lesions varying from papules to small plaques. The abdomen, round the waist and the arms were the areas most affected. The legs were relatively clear, the lesions being few in number and widely scattered. On the scalp there were numerous, patchy, heavily crusted, infiltrated lesions. On the face there were patches of faint erythema, covered by small, greasy scales.

Treatment

600 r to the lumbar and cervical areas, in weekly doses of 200 r.

Technical Factors

Kv	Ma	f.s.d.	Diam. of appl.	Filter
100	5	20 cms.	10 cms.	1.5 mm. Al

Result

All trace of the eruption had cleared by 21 Jun. 47, 3 months later.

Case 37.

C. McG. Age 29 Female

Family History

Nil.

Personal History

The patient gave a history of Bronchitis. Psoriasis began for the first time 6 months prior to examination.

On Examination. (15 Mar. 47)

There was widespread involvement, the eruption varying from small papules to large plaques. On the trunk the lesions were guttate with plaque formation at the small of the back. Plaques were most numerous on the legs while on the arms there was a mixture of plaques and guttae. There were small, scaling papules on the scalp.

Treatment

600 r to the lumbar and cervical areas, in weekly doses of 200 r.

Technical Factors

Kv.	Ma	f.s.d.	Diam. of appl.	Filter
100	5	20 cms.	10 cms.	1.5 mm. Al

Result

Improved.

Case 38.

M. A. Age 52 Female

Family History: Nil.

Personal History: The patient has always been healthy. First noticed psoriasis 15 years prior to examination. There have been a few short periods of remission.

On Examination (15 Mar. 47): There were scattered guttate lesions on the body and a large, heavily scaling geographic plaque in the lumbo-sacral region. On the left side of the abdomen there was a similar, though smaller plaque. There was a large patch of infiltrated scaling on the front of the scalp. Irritation troublesome.

Treatment: 600 r to the lumbar and cervical areas, in weekly doses of 200 r. 1st. course.
600 r to the lumbar and cervical areas, in weekly doses of 200 r. 2nd. course.

Technical Factors:

Kv	Ma	f.s.d.	Diam. of appl.	Filter
100	5	20 cms.	10 cms.	1.5 mm. Al

Result: Unimproved.

Case 39.

M. S. Age 44 Female

Family History: Nil.

Personal History: No history of any previous illness. First noticed psoriasis 1½ years prior to examination. No remission since.

On Examination (22 Mar. 47): Typical scaling, infiltrated, circular plaques on the legs, between the knees and the ankles. There was a full tree of varicose veins on both legs and the psoriasis lesions followed the distribution of the veins. On the scalp there was moderately heavy scaling. all other areas were clear.

Treatment 600 r to the lumbar and cervical areas, in weekly doses of 200 r.

Technical Factors

Kv	Ma	f.s.d.	Diam. of appl.	Filter
100	5	20 cms.	10 cms.	1.5 mm. Al

Result Improved.

Case 40.

C. McA. Age 39 Female

Family History The patient's mother also had psoriasis.

Personal History At the age of 9½ the patient had Meningitis and "Spinal trouble" which left her deaf. Psoriasis began when she was 11 years of age. Since then she has never been clear.

On Examination (29 Mar. 47) There was widespread involvement of the whole body. The lesions were mostly large, irregular plaques, in such close apposition to each other that very little normal skin could be seen. Scaling was slight and was only produced when when the surface of the lesions was scraped. The scalp was covered by a thick, infiltrated crust. The patient complained of extreme irritation.

Treatment 600 r to the lumbar and cervical areas, in weekly doses of 200 r.

Technical Factors

Kv	Ma	f.s.d.	Diam. of appl.	Filter
100	5	20 cms.	10 cms.	1.5 mm. Al

Result All trace of the eruption had cleared by 6 Mar 48, 12 months later. Relapsed.

Case 41.

M. C. Age 42 Female

Family History Nil.

Personal History The patient has always been healthy. First noticed psoriasis 12 years before examination.

On Examination (29 Mar. 47)

There was a patch of thick, infiltrated scaling on the front of the scalp. All other areas of the body were clear.

Treatment

600 r to the cervical area, in weekly doses of 200 r.

Technical Factors

Kv	Ma	f.s.d.	Diam. of appl.	Filter
100	5	20 cms.	10 cms.	1.5 mm. Al

Result

All trace of the lesion cleared.

Case 42.

E. M. Age 29 Female

Family History

The patient's brother also suffers from psoriasis (Case 22).

Personal History

There was no history of any previous illness. Psoriasis appeared for the first time 18 years prior to examination. On one occasion the eruption cleared for two years.

On Examination (5 Apr. 47)

There was a widespread eruption involving all parts of the body. On the trunk the eruption was mainly guttate, with some small plaque formations, especially on the back. On the limbs the lesions were mostly plaques with scattered guttae and papules. There were a few scaling papules on the face and the scalp was extensively involved. All the lesion were covered by tough, adherent scales.

Treatment

600 r to the lumbar and cervical areas, in weekly doses of 200 r.

Technical Factors

Kv	Ma	f.s.d.	Diam. of appl.	Filter
100	5	20 cms.	10 cms.	1.5 mm. Al

Result

All trace of the eruption had cleared by 14 Feb. 48, 10 months later. Relapsed.

Case 43.

J. B. Age 22 Male

Family History There was a strong family history. The patient's mother, one sister, two brothers (one included in this series - Case 44) and two cousins (Cases 160 & 163), all suffer from psoriasis.

Personal History No history of any serious illness. The skin was clear until 3 years prior to examination, when psoriasis first began. Since then all treatments have failed to give any beneficial result.

On Examination (5 Apr. 47.) There was widespread involvement of the whole body. The eruption was mainly papular and guttate with numerous small, circular and ovoid plaques. Scaling was variable. On the scalp there was a massive crust. The irritation was troublesome.

Treatment 600 r to the lumbar and cervical areas, in weekly doses of 200r.

Technical Factors

Kv	Ma	f.s.d.	Diam. of appl.	Filter
100	5	20 cms.	10 cms.	1.5 mm. Al

Result All trace of the eruption had cleared by 26 Jul. 47, 3½ months later.

Case 44.

R. B. Age 28 Male

Family History As for Case 43.

Personal History The patient has always been well and, until 9 months prior to examination, when psoriasis first started, had no previous skin trouble.

On Examination (5 Apr. 48) There was a generalised eruption, the lesions being mainly small, infiltrated plaques with, however, larger and more irregular plaques on the arms and legs. The scalp was covered by an infiltrated crust. There were no lesions on the face.

Treatment 600 r to the lumbar and cervical areas, in weekly doses of 200 r.

Technical Factors

Kv	Ma	f.s.d.	Diam. of appl.	Filter
100	5	20 cms.	10 cms.	1.5 mm. Al

Result All trace of the eruption had cleared by 14 Jun. 47, 10 weeks later.

Case 45.

A. McM. Age 21 Male

Family History An aunt also has psoriasis.

Personal History The patient has always been healthy. Six years prior to examination he was involved in a car smash. He was uninjured but suffered from shock. Soon after this psoriasis began and the skin has never been clear since.

On Examination (13 May 47) The legs, arms and trunk were covered by an erythematous, heavily scaling, guttate eruption. The scalp was also involved, being covered by a heavy, whitish, infiltrated crust. The patient complained of severe irritation.

Treatment 600 r to the lumbar and cervical areas, in weekly doses of 200 r.

Technical Factors

Kv	Ma	f.s.d.	Diam. of appl.	Filter
100	5	20 cms.	10 cms.	1.5 mm. Al

Result All trace of the eruption had cleared by 9 Aug. 47, 3 months later.

Case 46.

N. McG. Age 29 Female

Family History Nil.

Personal History No history of any previous illnesses. Psoriasis first appeared 5 years prior to

examination. Since then there have been no remissions but has gradually got worse.

On Examination (24 May 47)

There was a widespread distribution. On the arms and legs there were numerous, circular, infiltrated, heavily scaled plaques. Similar plaques, few in number, were widely scattered on the trunk. The skin in the pubic region, groins and on the vulva is acutely inflammed and covered by yellowish, macerated scales. There was extreme discomfort in this area.

Treatment

600 r to the lumbar and cervical areas, in weekly doses of 200 r.

Technical Factors

Kv	Ma	f.s.d.	Diam. of appl.	Filter
100	5	20 cms.	10 cms.	1.5 mm. Al

Result

All trace of the eruption had cleared by 23 Aug. 47, 3 months later.

Case 47.

I. T. Age 15 Male

Family History

Nil.

Personal History

The patient has always been healthy. First noticed psoriasis 3 months prior to examination

On Examination (24 May 47)

There was a large oval plaque on each forearm, involving the elbow and two thirds of the extensor aspect. The plaques were infiltrated and covered by a tough crust. A massive crust covered the scalp. There were a few guttate lesions on the trunk.

Treatment

600 r to the lumbar and cervical areas, in weekly doses of 200 r.

Technical Factors

Kv	Ma	f.s.d.	Diam. of appl.	Filter
100	5	20 cms.	10 cms.	1.5 mm. Al

Result

All trace of the eruption had cleared by 25 Oct. 47, 5 months later.

Case 48.

T. G. P. R. Age 23 Male

Family History Nil.

Personal History The patient had an operation for a tubercular gland in the neck but, otherwise, he has always been healthy. Psoriasis began 3 years prior to examination. There have been no remissions since.

On Examination (28 May 47) There was a generalised eruption involving the trunk and limbs, the lesions varying from papules to small plaques. Scaling was scanty and fine. On the scalp there were small areas of scaling.

Treatment 600 r to the lumbar and cervical areas, in weekly doses of 200 r.

Technical Factors

Kv	Ma	f.s.d.	Diam. of appl.	Filter
100	5	20 cms.	10 cms.	1.5 mm. Al

Result All trace of the eruption had cleared by 11 Oct. 47, 5 months later.

Case 49.

M. C. Age 31 Female

Family History A brother of the patient also suffered from psoriasis.

Personal History The patient has always been well. Psoriasis first started 4 years prior to examination. There have been no remissions since.

On Examination (7 Jun. 47) There was one large, circular, scaling plaque on the outer aspect of each thigh, just above the knee joint. On both knee caps there were numerous, small, non-scaling, papules.

Treatment 600 r to the lumbar area, in weekly doses of 200 r.

Technical Factors	Kv	Ma	f.s.d.	Diam. of appl.	Filter
	100	5	20 cms.	10 cms.	1.5 mm. Al

Result All trace of the eruption had cleared by 23 Aug. 47, 2½ months later.

Case 50.

E. B. Age 40 Female

Family History The patient's sister (Case 52) and an aunt of the patient's mother suffer from psoriasis.

Personal History The patient has always been well. Psoriasis first began 24 years prior to examination. It has remained much the same all the time.

On Examination (13 Sept. 47) On the left arm there were two circular, raised, erythematous, infiltrated, scaling plaques, one on the elbow and the other just above it. There was a similar plaque on the right elbow, and on the right knee. Over the coccyx there was a similar lesion.

Treatment 600 r to the lumbar and cervical areas, in weekly doses of 200 r.

Technical Factors	Kv	Ma	f.s.d.	Diam. of appl.	Filter
	100	5	20 cms.	10 cms.	1.5 mm. Al

Result All trace of the eruption had cleared by 24 Jan. 48, 4½ months later. Relapsed.

Case 51.

I. R. Age 9 Female

Family History The patient's father also suffers from psoriasis (Case 70).

Personal History The patient has always been well. Psoriasis first began 9 months prior to examination.

On Examination (4 Oct. 47) There was a widespread eruption. On the scalp there were numerous heavily crusted papules. The eyelids were affected, being covered by fine wafer scales. In each axilla there was a large, irregular, scaling plaque

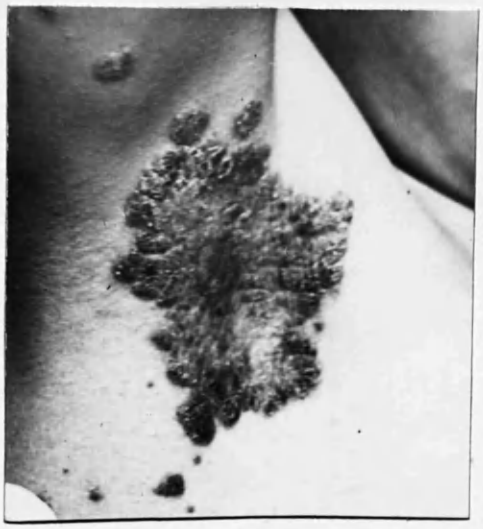

Fig. 73.

Case 51.

The axilla as seen at first examination.

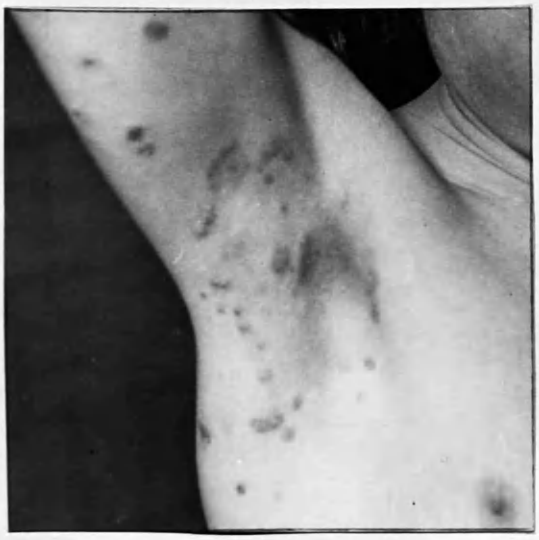

Fig. 74.

Case 51.

2 months later.

made up of closely set papules (Fig. 73). On the elbows there were typical plaques with fissuring on the surface. From the shoulders to the wrists there were many nummular lesions. The trunk was relatively clear. The pubis, vulva, perineum and inner aspect of the thighs were covered by a continuous plaque. The legs, like the trunk, were relatively clear.

Treatment 600 r to the lumbar and cervical areas, in weekly doses of 100 r. Repeated.

Technical Factors

Kv.	Ma	f.s.d.	Diam. of appl.	Filter
100	5	20 cms.	7.5 cms.	1.5 mm. Al

Result Improved after 1st. course. Relapsed.
Unimproved, so far, after 2nd. course.

Case 52.

M.N. Age 47 Female

Family History The patient's sister (Case 50) and an aunt of her mother suffer from psoriasis.

Personal History The patient has suffered on and off for many years from Rheumatism. Psoriasis first began 14 years prior to examination. It cleared with treatment but recurred 7 years later since when there have been no remissions.

On Examination (11 Oct. 47) There were irregular, infiltrated, finely scaling, erythematous plaques on the arms from the elbows to the wrists and on the legs from the knees to the ankles. The scalp, face and trunk were clear.

Treatment 600 r to the lumbar and cervical areas, in weekly doses of 200 r. Repeated.

Technical Factors

Kv	Ma	f.s.d.	Diam. of appl.	Filter
100	5	20 cms.	10 cms.	1.5 mm. Al

Result Cleared after 1st. course. Relapsed.
Cleared after 2nd. course. Relapsed.

Case 53.

D. McC. Age 11 Male

Family History The patient's mother and younger sister also have psoriasis.

Personal History The patient has always been well. Psoriasis first began 5 years prior to examination. On one occasion it cleared for a year but, since its reappearance a year later, there have been no remissions.

On Examination (18 Oct. 47) There was a generalised, acutely inflamed eruption involving practically the whole body surface. The neck and the upper part of the chest were the clearest areas. The skin was rough and covered by a mass of fine powdery scales. The face was affected and there were many infiltrated, crusted lesions on the scalp. Irritation was troublesome.

Treatment 400 r to the lumbar and cervical areas, in weekly doses of 100 r.

Technical Factors

Kv.	Ma	f.s.d.	Diam. of appl.	Filter
100	5	20 cms.	7.5 cms.	1.5 mm. Al

Result All trace of the eruption had cleared by 17 Jan. 48, 3 months later.

Case 54.

J. S. Age 40 Female.

Family History Nil.

Personal History There was a history of Scarlet fever, immediately following which psoriasis began, 27 years prior to examination. The patient also suffers from anaemia.

On Examination (18 Oct. 47) The eruption was almost entirely papular. All areas of the body were involved. Round the knees and in a few scattered areas there was a tendency towards plaque formation. The occipital region of the scalp was heavily crusted.

Treatment 600 r to the lumbar and cervical areas, in weekly doses of 200 r.

Technical Factors

Kv	Ma	f.s.d.	Diam. of appl.	Filter
100	5	20 cms.	10 cms.	1.5 mm. Al

Result Improved.

Case 55.

B. McK. Age 17 Female

Family History A cousin of the patient also suffers from psoriasis.

Personal History The patient has always been well. Psoriasis appeared for the first time 4 months prior to examination.

On Examination (25 Oct. 47) On the legs there were large, irregular, infiltrated, erythematous plaques, covered by brittle, whitish, silvery scales. On the arms and trunk the plaques were nummular and the scaling was thicker. As well as the plaques there was a papular and guttate eruption. The scalp was covered by numerous, heavily scaling, infiltrated lesions.

Treatment 600 r to the lumbar and cervical areas, in weekly doses of 200 r.

Technical Factors

Kv	Ma	f.s.d.	Diam. of appl.	Filter
100	5	20 cms.	10 cms.	1.5 mm. Al

Result All trace of the eruption had cleared by 13 Mar. 48, 5 months later.

Case 56.

F. B. Age 27 Male

Family History Nil.

Personal History The patient has always been well. Psoriasis first began 2 years prior to examination. There have been no remissions.

On Examination (29 Oct. 47)

There were multiple, nummular plaques on the legs and arms with a massive geographic formation round the left elbow. Scaling varied from small, white flakes to large heaped-up crusts. On the back there were numerous, scattered, circular, dull red lesions with soft, yellowish scales. On the scalp there were numerous, circular, heavily crusted lesions. Irritation was troublesome.

Treatment

600 r to the lumbar and cervical areas, in weekly doses of 200 r.

300 r to the popliteal fossae, in weekly doses of 100 r.

Technical Factors

Kv	Ma	f.s.d.	Diam. of appl.	Filter
100	5	20 cms.	10 cms.	1.5 mm. Al

Result

All trace of the eruption had cleared by 24 Apr. 48, 6 months later.

Case 57.

H. R. McK. Age 18 Female

Family History

Nil.

Personal History

The patient has always been healthy and gave no history of any previous illness. She first noticed psoriasis 2 years prior to examination. There have been no remissions and it has steadily got worse.

On Examination (1Nov. 47)

The whole body surface was extensively involved. The back was one mass of raised, infiltrated, crusted tissue which stopped abruptly across the buttocks. On the legs, back and front, there were large, irregular, geographic plaques, covered by thick, white, adherent scales. The whole extent of the arms was covered by a mass of infiltrated, scaling tissue. Across the breasts and to a certain extent on the chest and lower abdomen there was a moist, scaling erythema. Scattered on the abdomen and chest, as well, were some guttate lesions. The scalp was completely covered by a massive, infiltrated crust. The irritation was severe.

Treatment 600 r to the lumbar and cervical areas, in weekly doses of 200 r.
300 r to the popliteal fossae, in weekly doses of 100 r.

Technical Factors

Kv.	Ma	f.s.d.	Diam. of appl.	Filter
100	5	20 cms.	10 cms.	1.5 mm. Al

Result All trace of the eruption had cleared by 24 Jan. 48, 3 months later.

Case 58.

M. K. Age 60 Female

Family History Nil.

Personal History The patient was always well until 10 years prior to examination, when Rheumatoid arthritis developed. Very soon after this she noticed the psoriasis.

On Examination (4 Nov. 47) The patient was almost crippled with arthritis and looked much older than her years. The legs were the only part of the body affected by psoriasis. There were many small plaque and guttate lesions from the buttocks down to the ankles. The lesions were infiltrated and covered by heavy scales.

Treatment 600 r to the lumbar area, in weekly doses of 200 r.

Technical Factors

Kv	Ma	f.s.d.	Diam. of appl.	Filter
100	5	20 cms.	10 cms.	1.5 mm. Al

Result All trace of the eruption had cleared by 5 Feb. 48, 3 months later.

Case 59.

M. M. Age 23 Female

Family History Nil.

Personal History The patient has always been well. Psoriasis first began 3 years prior to examination.

Fig. 75. Case 59. The forehead on first examination.

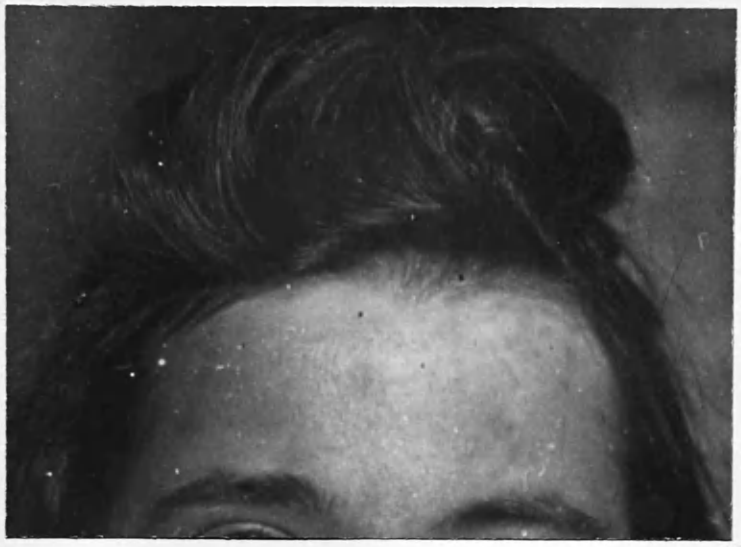

Fig. 76. Case 59. 3 months later.

There have been no remissions.

On Examination (8 Nov. 47)

Round the elbows and extending down the extensor aspect of the forearms there were large, elongated, heavily scaled, infiltrated plaques. On the legs, between the knees and the ankles, the lesions were nummular and heavily scaled. On the forehead and extending into and involving the whole scalp there were numerous, infiltrated, white scaling plaques (fig. 75). The trunk was clear.

Treatment

600 r to the lumbar and cervical areas, in weekly doses of 200 r.
300 r to the popliteal fossae, in weekly doses of 100 r.

Technical Factors

Kv	Ma	f.s.d.	Diam. of appl.	Filter
100	5	20 cms.	10 cms.	1.5 mm. Al

Result

All trace of the eruption had cleared by 19 Jun. 48, 7 months later.

Case 60.

E. R. Age 13 Female

Family History

The patient's grandfather suffered from psoriasis.

Personal History

The patient has always been well. Psoriasis first began just over a year prior to examination. It cleared with treatment but recurred almost immediately.

On Examination (8 Nov. 47)

There was a papular and guttate eruption on the arms and legs. The lesions were erythematous and finely scaled. On the calves and shins there were plaque formations. The rest of the body was clear.

Treatment

600 r to the lumbar and cervical areas, in weekly doses of 200 r.

Technical Factors

Kv	Ma	f.s.d.	Diam. of appl.	Filter
100	5	20 cms.	10 cms.	1.5 mm. Al

Result

Cleared by 24 Jan. 48, 2½ months later.

Case 61.

A. A. Age 7 Male

Family History: Nil.

Personal History: The patient has always been well. Psoriasis began a year prior to examination.

On Examination (8 Nov. 47): There were numerous large, roughly circular plaques on the abdomen, pubic region, lower part of the back and the legs. The plaques were infiltrated and covered by thick crusts.

Treatment: 600 r to the lumbar and cervical areas, in weekly doses of 100 r.

Technical Factors:

Kv	Ma	f.s.d.	Diam. of appl.	Filter
100	5	20 cms.	10 cms.	1.5 mm. Al

Result: Improved.

Case 62.

A. T. Age 12 Female

Family History: An aunt of the patient also suffers from psoriasis (Case 71).

Personal History: The patient gave a history of having had Pneumonia. Psoriasis began 5 months prior to examination.

On Examination (15 Nov. 47): The legs were extensively involved, the lesions varying from small scaling papules to circular, infiltrated, crusted plaques. On the arms the eruption was mainly papular. A widespread guttate eruption covered the trunk and the scalp was grossly affected.

Treatment: 600 r to the lumbar area and 200 r to the cervical area in doses of 100 r weekly.

Technical Factors:

Kv	Ma	f.s.d.	Diam. of appl.	Filter
100	5	20 cms.	7.5 cms.	1.5 mm. Al

Result: All trace of the eruption had cleared by 10 Jan. 48, 2 months later.

Case 63.

L. A. Age 11 Male

Family History: The patient's father also suffers from psoriasis (Case 151).

Personal History: The only serious illness recorded was Pneumonia. Psoriasis first began 4 months prior to examination.

On Examination (22 Nov. 47): Round both elbows and both knees there were large, infiltrated, erythematous, scaling plaques. There was a widely scattered papular eruption on the trunk.

Treatment: 500 r to the lumbar and cervical areas, in weekly doses of 100 r.

Technical Factors:

Kv	Ma	f.s.d.	Diam. of appl.	Filter
100	5	20 cms.	7.5 cms.	1.5 mm. Al

Result: All trace of the eruption had cleared by 31 Jan. 48, 2 months later.

Case 64.

S. W. Age 9 Female

Family History: Nil.

Personal History: The patient has always been well. Psoriasis first began 6 months prior to examination.

On Examination (25 Nov. 47): There was a generalised, scaling, papular and small guttate eruption, most pronounced on the limbs. There were heavily scaling plaque formations at the knees, ankles and heels.

Treatment: 600 r to the lumbar and cervical areas, in weekly doses of 100 r.

Technical Factors:

Kv	Ma	f.s.d.	Diam. of appl.	Filter
100	5	20 cms.	7.5 cms.	1.5 mm. Al

Result: All trace of the eruption had cleared by 22 Mar. 48, 3 months later. Relapsed.

Case 65.

J. C. McK. Age 59 Female

Family History: Nil.

Personal History: Except for muscular Rheumatism from time to time, the patient has always been well. Psoriasis first began 14 years prior to examination. Since it began there have been no remissions.

On Examination (22 Nov. 47): There was a generalised, guttate and plaque eruption on the trunk and limbs. The lesions were covered by tough, adherent scales. On the scalp there were numerous scaling papules.

Treatment: 600 r to the lumbar and cervical areas, in weekly doses of 200 r.

Technical Factors:

Kv	Ma	f.s.d.	Diam. of appl.	Filter
100	5	20 cms.	10 cms.	1.5 mm. Al

Result: Unimproved.

Case 66.

C. T. Age 8 Female

Family History: Nil.

Personal History: Except for occasional attacks of Bronchitis the patient has always been well. Psoriasis began 4 years prior to examination.

On Examination (29 Nov. 47): There were large, irregular plaques round the knees and extending down the legs. The plaques were infiltrated and covered by thick, adherent scales (fig. 77). On the arms there was a similar distribution, round the elbows and extending down the arms, but the plaques were smaller and more nummular. There were scaling guttate lesions scattered on the rest of the body. A fine dandruff-like scaling covered the scalp.

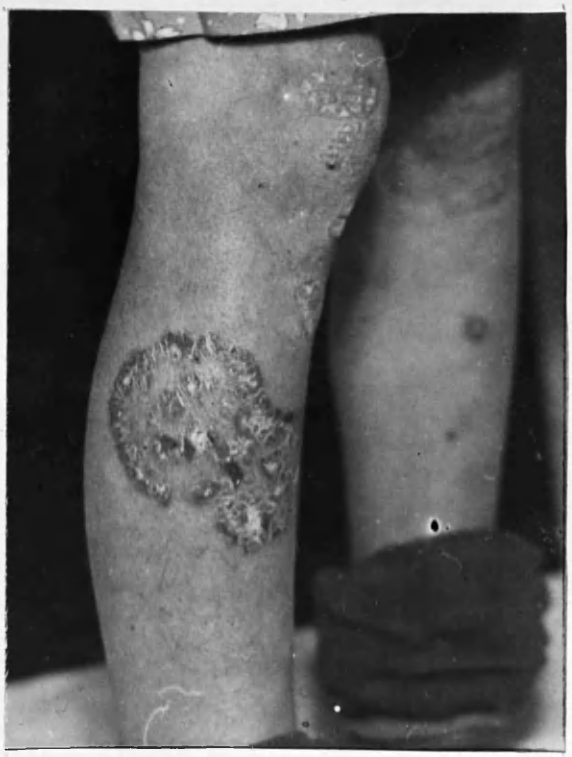

Fig. 77.

Case 66.

Plaque formation on the leg.

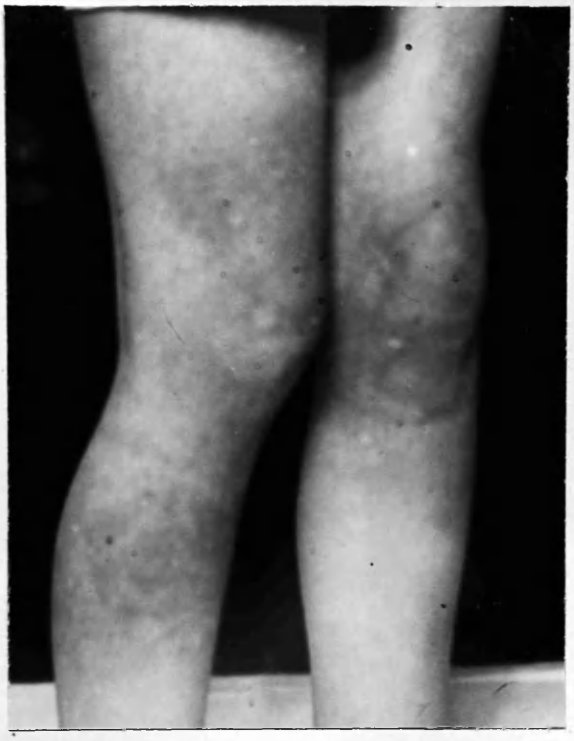

Fig. 78.

Case 66.

The same area, 2 months later.

Treatment — 600 r to the lumbar and cervical areas, in weekly doses of 100 r.

Technical Factors

Kv	Ma	f.s.d.	Diam. of appl.	Filter
100	5	20 cms.	7.5 cms.	1.5 mm. Al

Result — All trace of the eruption had cleared by 31 Jan. 48, 2 months later.

Case 67.

W. P. — Age 59 — Male

Family History — Nil.

Personal History — The patient has always been well. Psoriasis first began 21 years prior to examination. It has never cleared since.

On Examination (29 Nov, 47) — There were multiple, large, geographic plaques on the trunk and limbs. The plaques were infiltrated and heavily crusted. There were also scattered guttate lesions. The scalp was clear.

Treatment — 600 r to the lumbar and cervical area, in weekly doses of 200 r.

Technical Factors

Kv	Ma	f.s.d.	Diam. of appl.	Filter
100	5	20 cms.	10 cms.	1.5 mm. Al

Result — Unimproved.

Case 68.

D. R. — Age 43 — Male

Family History — The patient's mother had psoriasis.

Personal History — The patient has suffered for years from Arthritis and has been operated on for a perforated Gastric ulcer. Psoriasis began 17 years prior to examination. There have been no remissions and on two occasions after having had plaster of paris applied to the hands a severe eruption developed on the hands.

On Examination (29 Nov. 47)

There were large, infiltrated, heavily scaled plaques on the elbows, and a guttate eruption on the trunk. The skin of the scrotum was thickened and indurated and in the pubic region the skin was raised and infiltrated. Irritation, especially in the pubic region was severe.

Treatment

600 r to the lumbar and cervical areas, in weekly doses of 200 r.

Technical Factors

Kv	Ma	f.s.d.	Diam. of appl.	Filter
100	5	20 cms.	10 cms.	1.5 mm. Al

Result

Improved.

Case 69.

J. B. Age 34 Male

Family History

Nil.

Personal History

The patient gave a history of Pleurisy but otherwise has always been well. Psoriasis began 5 years prior to examination. There have been no remissions since.

On Examination (2 Dec. 47)

There was a widespread plaque and guttate eruption involving the trunk and the limbs. All the lesions were infiltrated and covered by thick crusted scales. The scalp was also extensively involved. Irritation was severe.

Treatment

600 r to the lumbar and cervical areas, in weekly doses of 200 r. Repeated.

Technical Factors

Kv	Ma	f.s.d.	Diam. of appl.	Filter
100	5	20 cms.	10 cms.	1.5 mm. Al

Result

Unimproved

Case 70.

A. R. Age 48 Male

Family History

The patient's daughter also suffers from psoriasis (Case 51).

Personal History

The patient has always been well. Psoriasis began 40 years prior to examination. It has never cleared since. Recently it had become worse than ever before.

On Examination

(6 Dec. 47)

On the legs, especially below the knees, there was a mixed eruption of nummular plaques, guttae and papules. On each elbow, and extending down the forearms, there was a large oval plaque. There was a large plaque on each buttock and scattered nummular plaques on the back. All the lesions were infiltrated and heavily scaled. There was irritation, particularly on the legs.

Treatment

600 r to the lumbar and cervical areas, in weekly doses of 200 r.

Technical Factors

Kv	Ma	f.s.d.	Diam. of appl.	Filter
100	5	20 cms	10 cms.	1.5 mm. Al

Result

All trace of the eruption had cleared by 5 Jun. 48, 6 months later.

Case 71.

E. D. Age 42 Female

Family History

A neice of the patient also suffers from psoriasis (Case 62).

Personal History

The patient gave a previous history of Bronchitis. Psoriasis first began 17 years prior to examination. There was a period of 2 years when it cleared completely. Since it recurred there have been no further remissions.

On Examination

(6Dec. 47)

There was a severe, generalised, guttate, eruption involving the entire body surface, including the face. The lesions were very closely set together but there was no plaque formation. The guttae were covered by silvery, brittle scales. The scalp was covered by a massive crust and there was some hair loss.

Treatment

600 r to the lumbar and cervical areas, in weekly doses of 200 r. Repeated.

Technical Factors	Kv	Ma	f.s.d.	Diam. of appl.	Filter
	100	5	20 cms.	10 cms.	1.5 mm. Al

Result Improved.

Case 72.

J. I. Age 60 Female

Family History Nil.

Personal History The patient gave a history of Rheumatism and Bronchitis. Psoriasis first began 2 years prior to examination.

On Examination (6 Dec. 47) There was a heavily crusted, infiltrated lesion involving the whole occipital region of the scalp. There were scattered guttae on the legs. Irritation on the scalp was severe.

Treatment 600 r to the cervical area, in weekly doses of 200 r.

Technical Factors	Kv	Ma	f.s.d.	Diam. of appl.	Filter
	100	5	20 cms.	10 cms.	1.5 mm. Al

Result Unimproved.

Case 73.

I. W. Age 61 Female

Family History Nil.

Personal History There was a history of Pneumonia three times. Just before the onset of psoriasis, a month prior to examination, she had a severe attack of Herpes zoster. No history of psoriasis previous to this.

On Examination (5 Dec. 47) There was an acute, widespread psoriasis involving the abdomen, pubis, groins, genitalia, lumbo-sacral region, buttocks and thighs. The skin on these areas was dull red, infiltrated and covered by dull white scales. There were numerous outlying guttae and small

plaques. Irritation was intense.

Treatment — 600 r to the lumbar and cervical areas, in weekly doses of 200 r.

Technical Factors

Kv	Ma	f.s.d.	Diam. of appl.	Filter
100	5	20 cms.	10 cms.	1.5 mm. Al

Result — All trace of the eruption had cleared by 3 Feb. 48, 9 weeks later.

Case 74.

I. K. — Age 19 — Female

Family History — The patient's brother also has psoriasis.

Personal History — The patient has always been well. Psoriasis first began a year prior to examination.

On Examination (13 Dec. 47) — The eruption was mainly guttate and involved the back and the limbs mostly. Round the knees and elbows there were small plaque formations. The scalp was moderately affected.

Treatment — 600 r to the lumbar and cervical areas, in weekly doses of 200 r.

Technical Factors

Kv	Ma	f.s.d.	Diam. of appl.	Filter
100	5	20 cms.	10 cms.	1.5 mm. Al

Result — All trace of the eruption had cleared by 28 Feb. 48, 2½ months later.

Case 75.

M. G. — Age 44 — Male.

Family History — Nil.

Personal History — The patient has always been well. Psoriasis began 14 years prior to examination. On one occasion it cleared for 6 months.

On Examination (20 Dec. 47)

There were large, scaling, infiltrated plaques on the shoulders, elbows and forearms There were nummular plaques, particularly heavily ammassed on the buttocks and extending down the legs to the ankles. On the sides of the trunk there were also many nummular plaque formations. Scaling was fine and brittle. On the scalp there were numerous scaling papules.

Treatment

600 r to the lumbar and cervical areas, in weekly doses of 200 r. Repeated.

Technical Factors

Kv	Ma	f.s.d.	Diam. of appl.	Filter
100	5	20 cms.	10 cms.	1.5 mm. Al

Result

All trace of the eruption had cleared by 26 Jun. 48, 6 months later.

Case 76.

M. B. Age 9 Female

Family History

Nil.

Personal History

There was a history of Bronchitis but otherwise the patient has always been well. Psoriasis began 6 months before examination.

On Examination (20 Dec. 47)

There was a large, infiltrated plaque on the outer aspect of the right thigh covered by large, white, wafer-like scales. As well as this plaque there were numerous nummular plaques. On the right shoulder there were two, heavily crusted, circular plaques.

Treatment

500 r to the lumbar and cervical areas, in weekly doses of 100 r.

Technical Factors

Kv	Ma	f.s.d.	Diam. of appl.	Filter
100	5	20 cms.	7.5 cms.	1.5 mm. Al

Result

All trace of the eruption had cleared by 6 Mar. 48, 2½ months later.

Case 77.

M. H. Age 39 Male

Family History Nil.

Personal History The patient has always been well. Psoriasis first appeared 4 years prior to examination. It has remained the same since.

On Examination (3 Jan. 48) There were large, erythematous, slightly infiltrated plaques on the trunk, shoulders and upper part of the arms. Scattered over the body there were numerous, heavily scaling guttate lesions, with here and there some follicular parakeratosis..The face, post-auricular folds and the neck were also affected.

Treatment 600 r to the lumbar and cervical areas, in weekly doses of 200 r.

Technical Factors

Kv	Ma	f.s.d.	Diam. of appl.	Filter
100	5	20 cms.	10 cms.	1.5 mm. Al

Result Unimproved.

Case 78.

M. J. S. Age 16 Female

Family History The patient's sister also has psoriasis (Case 147).

Personal History The patient has always been well. Psoriasis first began a year prior to examination.

On Examination (3 Jan. 48) Only the scalp was affected. In this area there were numerous circular lesions covered by thick, heaped-up crusts. All the rest of the body was clear.

Treatment 600 r to the cervical area, in weekly doses of 200 r.

Technical Factors

Kv	Ma	f.s.d.	Diam. of appl.	Filter
100	5	20 cms.	10 cms.	1.5 mm. Al

Result — All trace of the eruption had cleared by 3 Jul. 48, 7 months later.

Case 79.

F. C. — Age 40 — Female

Family History — Nil.

Personal History — The patient gave a history of Rheumatism. Psoriasis first began 24 years prior to examination. It has remained about the same all the time.

On Examination (10 Jan. 48) — There were numerous, large, geographic plaques scattered over all areas of the body. The plaques were infiltrated and covered by thick scales. The scalp was also involved.

Treatment — 600 r to the lumbar and cervical areas, in weekly doses of 200 r. Repeated.

Technical Factors

Kv	Ma	f.s.d.	Diam. of appl.	Filter
100	5	20 cms.	10 cms	1.5 mm. Al

Result — Unimproved.

Case 80.

E. F. — Age 82 — Female

Family History — Nil.

Personal History — The patient gave a history of Rheumatism and Pneumonia. As well, she gave a history of Herpes zoster and erysipelas. Psoriasis first appeared 10 years prior to examination.

On Examination (31 Jan. 48) — The scalp was mainly affected. On it there were small, irregular, scaling, infiltrated plaques. The hair was very scanty. Widely scattered, small lesions only on the rest of the body. The patient complained of severe irritation on the scalp.

Treatment — 600 r to the cervical area, in weekly doses of 200 r.

Technical Factors

Kv	Ma	f.s.d.	Diam. of appl.	Filter
100	5	20 cms.	10 cms.	1.5 mm. Al

Result — Unimproved.

Case 81.

D. D. — Age 43 — Male

Family History — Nil.

Personal History — The patient has always been well. Psoriasis began 30 years prior to examination. There have been no remissions since.

On Examination (31 Jan. 48) — There were infiltrated, silvery scaling plaques round the knees and elbows with scattered guttate lesions down the legs and forearms. On the trunk there were some widely scattered guttae. There was a papular eruption on the face.

Treatment — 600 r to the lumbar and cervical areas, in weekly doses of 200 r. Repeated.

Technical Factors

Kv	Ma	f.s.d.	Diam. of appl.	Filter
100	5	20 cms.	10 cms.	1.5 mm. Al

Result — All trace of the eruption had cleared by 10 Jul. 48, 6½ months later.

Case 82.

E. L. — Age 11. — Female

Family History — Nil.

Personal History — The patient gave a history of Pneumonia. Psoriasis began 7 years prior to examination. It has remained about the same all the time since and has never cleared,

On Examination (7 Feb. 48)

The whole trunk was covered by small, raised, erythematous, finely scaled, ringed lesions. On the arms and legs there were a few, scaling papules. The scalp was not affected.

Treatment

300 r to the lumbar and cervical areas, in weekly doses of 100 r.

Technical Factors

Kv	Ma	f.s.d.	Diam. of appl.	Filter
100	5	20 cms.	7.5 cms.	1.5 mm. Al

Result

All trace of the eruption had cleared by 28 Feb. 48, 3 weeks later.

Case 83.

W. B. Age 48 Male

Family History

Nil.

Personal History

The patient has always been well. Psoriasis began 9 years prior to examination. He has never been clear since.

On Examination (7 Feb. 48)

All areas of the body were covered by massive plaques of psoriasis. They were infiltrated and covered by large, tough scales. The scalp was covered by a thick crust. (figs. 79 & 80).

Treatment

600 r to the lumbar and cervical areas, in weekly doses of 200 r.

Technical Factors

Kv	Ma	f.s.d.	Diam. of appl.	Filter
100	5	20 cms.	10 cms.	1.5 mm. Al

Result

Improved.

Case 84.

J. S. Age 72 Male

Family History

Nil.

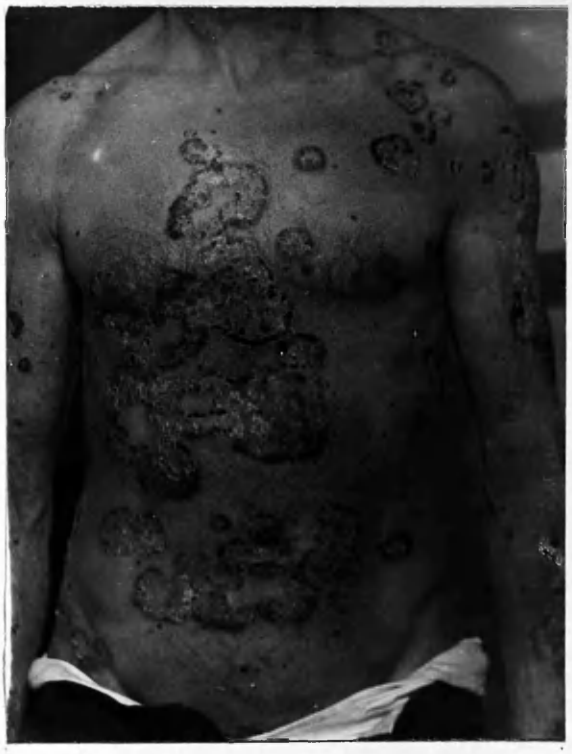

Fig. 79.

Case 83.

The chest and abdomen on first examination.

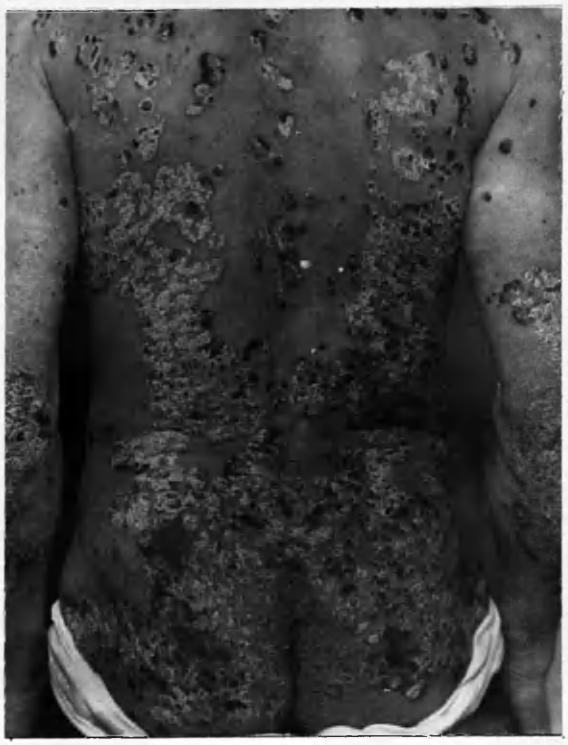

Fig. 80.

Case 83.

The back on first examination.

Fig. 81 (a).

Case 83.

$2\frac{1}{2}$ months later. The original lesions have cleared, but a fresh eruption has appeared on the upper part of the chest and on the neck.

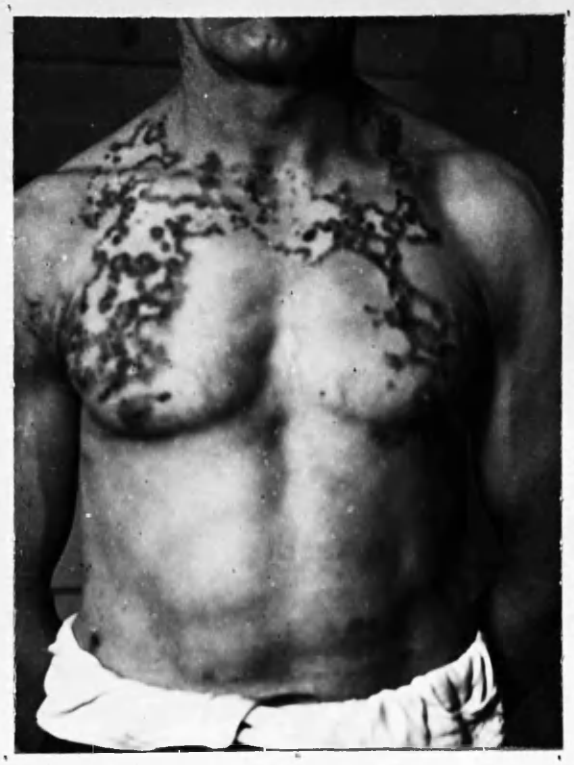

Fig. 81 (b).

Case 83.

After a further 2 months. The eruption on the upper part of the chest and on the neck has almost completely gone. No further treatment was given.

Personal History — The patient has always been well. Psoriasis began 18 years prior to examination. Since then there have been no remissions.

On Examination (7 Feb. 48) — The skin round the buttocks, anus, perineum, groins and pubis was red, raised and infiltrated. There were a few small, circular lesions between the shoulders and a few scaling papules on the ears and scalp.

Treatment — 600 r to the lumbar and cervical areas, in weekly doses of 200 r.

Technical Factors

Kv	Ma	f.s.d.	Diam. of appl.	Filter
100	5	20 cms.	10 cms.	1.5 mm. Al

Result — All trace of the eruption had cleared by 26 Jun. 48, 5 months later.

Case 85.

H. McS. — Age 32 — Female

Family History — Nil.

Personal History — The patient has always been well. Psoriasis began 20 years prior to examination. There was one period of 2 years when it cleared.

On Examination (7 Feb. 48) — There was a generalised, papular, scaling eruption involving the scalp, face, arms and legs. The trunk was relatively clear. The patient complained of irritation.

Treatment — 600 r to the lumbar and cervical areas, in weekly doses of 200 r.

Technical Factors

Kv	Ma	f.s.d.	Diam. of appl.	Filter
100	5	20 cms.	10 cms.	1.5 mm. Al

Result — Improved.

Case 86.

T. D. H. — Age 45 — Male

Family History — The patient's father suffered from psoriasis.

Personal History

The patient has always been well. Psoriasis began 10 years prior to examination. It tends to be worse in the Summer and has not cleared at any time since the onset.

On Examination (10 Feb. 48)

There was ageneralised plaque and guttate eruption. The trunk, limbs and scalp were involved. The largest plaques were round the knee and elbow joints and there was a very large one in the sacral region which extended down between the cheeks of the buttocks.

Treatment

600 r to the lumbar and cervical areas, in weekly doses of 200 r.

Technical Factors

Kv	Ma	f.s.d.	Diam. of appl.	Filter
100	5	20 cms.	10 cms.	1.5 mm. Al

Result

Unimproved.

Case 87.

J. McI. T. Age 9 Male

Family History

Nil.

Personal History

The patient gave a history of having had Pneumonia. Psoriasis began 3 years prior to examination. It cleared on one occasion after ointment therapy.

On Examination (14 Feb. 48)

The lesions were mainly plaque formations and were widely scattered. There were three small ones at each elbow and one large one on the outer aspect of the right thigh. On the legs they were nummular. All the lesions were heavily scaled. There were a few scaling papules on the scalp.

Treatment

600 r to the lumbar and cervical areas, in weekly doses of 100 r.

Technical Factors

Kv	Ma	f.s.d.	Diam. of appl.	Filter
100	5	20 cms.	7.5 cms.	1.5 mm. Al

Result

All trace of the eruption had cleared by 3 Jul. 48, 4½ months later.

Case 88.

J. P. Age 24 Male

Family History Nil.

Personal History The patient has always been well. Psoriasis began 1½ years prior to examination. It has never cleared since.

On Examination (14 Feb. 48) There were scattered guttate lesions on the trunk and limbs, with one large plaque extending almost the whole length of the right shin. The lesions were red, heavily scaling and infiltrated. On the scalp there were many scaling papules and these extended round the hair margin and on to the face. The patient complained of irritation especially at night.

Treatment 600 r to the lumbar and cervical areas, in weekly doses of 200 r.

Technical Factors

Kv	Ma	f.s.d.	Diam. of appl.	Filter
100	5	20 cms.	10 cms.	1.5 mm. Al

Result The patient became very much worse after treatment, but all trace of the eruption had cleared by 10 Jul. 48, 5 months later.

Case 89.

C. McC. Age 29 Female

Family History Nil.

Personal History The patient has always been well. Psoriasis began 3 months prior to examination.

On Examination (2 Mar. 48) There were multiple, small, scaling guttae on the buttocks, thighs and legs. There was a similar eruption on the shoulders and arms but the lesions were not so numereus. The lesions were slightly infiltrated and covered by small, white, brittle scales. The patient complained of some irritation.

Treatment 600 r to the lumbar and cervical areas, in weekly doses of 200 r.

Technical Factors

Kv	Ma	f.s.d.	Diam. of appl.	Filter
100	5	20 cms.	10 cms.	1.5 mm. Al

Result All trace of the eruption had cleared by 1 May 48, 2 months later.

Case 90.

E. O'N. Age 58 Female

Family History Nil.

Personal History The patient has always been well. Psoriasis began 7 years prior to examination. It has been much the same all the time.

On Examination (10 Feb. 48) There were small circular plaques round the knees and elbows and a guttate eruption on the shoulders, arms and thighs. There were areas of thick crusting on the scalp.

Treatment 600 r to the lumbar and cervical areas, in weekly doses of 200 r.

Technical Factors

Kv	Ma	f.s.d.	Diam. of appl.	Filter
100	5	20 cms.	10 cms.	1.5 mm. Al

Result All trace of the eruption had cleared by 1 Jun. 48, 3½ months later.

Case 91.

E. T. Age 16 Female

Family History Nil.

Personal History The patient has always been well. Psoriasis began a year prior to examination.

On Examination (6 Mar. 48) There were infiltrated and heavily scaling plaque formations round the elbows. On the trunk there were a few scattered nummular plaques. A few papules on the legs.

Treatment — 600 r to the lumbar and cervical areas, in weekly doses of 200 r.

Technical Factors

Kv	Ma	f.s.d.	Diam. of appl.	Filter
100	5	20 cms.	10 cms.	1.5 mm. Al

Result — Improved.

Case 92.

M. McG. — Age 26 — Male

Family History — The patient's mother also suffers from psoriasis.

Personal History — The patient has always been well. Psoriasis began 9 years prior to examination. On one occasion it cleared for 6 months.

On Examination (18 Mar. 48) — There were discoidal and oval plaques on the legs, below the knees. On the trunk there was a large plaque between the shoulders and numerous nummular plaques and guttate lesions. The arms were clear except for one guttate lesion on the right forearm. All the lesions were infiltrated and covered by a thick crust. The scalp was grossly involved.

Treatment — 600 r to the lumbar and cervical areas, in weekly doses of 200 r.

Technical Factors

Kv	Ma	f.s.d.	Diam. of appl.	Filter
100	5	20 cms.	10 cms.	1.5 mm. Al

Result — Improved.

Case 93.

E. T. — Age 35 — Female

Family History — There was a strong family history.

Personal History — The patient gave a history of Bronchitis but otherwise she has always been well. Psoriasis began 2 years prior to examination.

On Examination (12 Feb. 48)

There was a generalised, scaling, papular eruption involving all areas of the body - scalp, face, trunk, arms and legs. On the trunk as well there were a few larger, guttate lesions as well.

Treatment

600 r to the lumbar and cervical areas, in weekly doses of 200 r.

Technical Factors

Kv	Ma	f.s.d.	Diam. of appl.	Filter
100	5	20 cms.	10 cms.	1.5 mm. Al

Result

Improved.

Case 94.

A. R. Age 28 Female

Family History

There was a strong family history. Her father, two sisters and a brother suffer from psoriasis.

Personal History

The patient gave a history of Rheumatism. Psoriasis began 21 years prior to examination and during that time there has only been 2 months when it completely cleared.

On Examination (30 Mar. 48)

There was widespread involvement of the body. The limbs were the most severely affected, large, geographic plaques involving almost their full extent. On the trunk there was a mixture of geographic, annular and guttate lesions. On the face there were numerous guttae. All the lesions were heavily crusted and infiltrated. The scalp was severely affected.

Treatment

600 r to the lumbar and cervical areas, in doses of 200 r weekly.

Technical Factors

Kv	Ma	f.s.d.	Diam. of appl.	Filter
100	5	20 cms.	10 cms.	1.5 mm. Al

Result

Improved.

Case 95.

J. D. Age 54 Male

Family History Nil.

Personal History The patient gave a history of Rheumatism and Bronchitis. Psoriasis began 7 months prior to examination.

On Examination (10 Apr. 48) There was a widely scattered, guttate and small, nummular plaque eruption on the trunk and limbs. The lesions were infiltrated and heavily scaling. The eruption was closely ammassed on the front of the scalp and forehead.

Treatment 600 r to the lumbar and cervical areas, in weekly doses of 200 r.

Technical Factors

Kv	Ma	f.s.d.	Diam.of appl.	Filter
100	5	20 cms..	10 cms.	1.5 mm. Al

Result Improved.

Case 96.

M. McC. Age 44 Female

Family History The patient's daughter also suffers from psoriasis (Case 35).

Personal History The patient has always been well. Psoriasis began 17 years prior to examination. It has never completely gone since.

On Examination (13 Apr. 48) There were multiple, small, scaling guttae on the lower part of the back, buttocks and upper part of the thighs. On the rest of the trunk and legs and on the arms the lesions were more widely scattered. The back of the scalp only was affected. Scaling in this part was very thick.

Treatment 600 r to the lumbar and cervical areas, in weekly doses of 200 r.

Technical Factors	Kv	Ma	f.s.d.	Diam. of appl.	Filter
	100	5	20 cms.	10 cms.	1.5 mm. Al

Result Unimproved.

Case 97.

E. McA. Age 33 Female

Family History The patient's mother and brother suffer from psoriasis.

Personal History The patient also suffers from Rheumatism. Psoriasis began 7 years prior to examination. It has never cleared since.

On Examination (20 Apr. 48) There were numerous, large, geographic plaques on the trunk and limbs (fig. 82). All the lesions were infiltrated but scaling varied. On the face there were numerous, finely scaling, erythematous lesions.

Treatment 600 r to the lumbar and cervical areas, in weekly doses of 200 r.

Technical Factors	Kv	Ma	f.s.d.	Diam. of appl.	Filter
	100	5	20 cms.	10 cms.	1.5.mm. Al

Result Except for a reddish pigmentation and a few scattered, scaling papules, remnants of the edge of the plaques, all trace of the eruption had cleared by 13 Jul. 48, 3 months later.

Case 98.

T. McL. Age 12 Male

Family History Nil.

Personal History The patient has always been well. Psoriasis began 5 years prior to examination. It has never been clear since.

Fig. 82.

Case 97.

Showing the plaque-like nature of the eruption.

Fig. 83.

Case 97.

3 months later. There is now only reddish pigmentation and scattered, scaling papules.

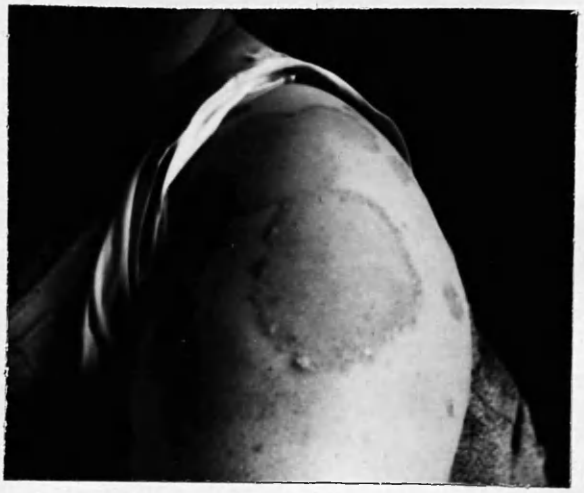

On Examination (8 May 48)

There was a severe, generalised papular and guttate eruption involving all areas of the body - trunk, limbs, face and scalp. The lesions were covered by small, brittle, whitish scales. Irritation was troublesome.

Treatment

600 r to the lumbar and cervical areas, in weekly doses of 100 r.

Technical Factors

Kv	Ma	f.s.d.	Diam. of appl.	Filter
100	5	20 cms.	7.5 cms.	1.5 mm. Al

Result

Unimproved at the end of 2 months.

Case 99.

A. B. Age 5 Female

Family History

Nil.

Personal History

The patient had Diphtheria almost a year prior to examination and following this psoriasis started. Has not cleared since.

On Examination (13 May 48)

There was a severe and widespread involvement of the body - scalp, face, trunk and limbs. The lesions vary from small papules to fairly large geographic plaques. All the lesions were infiltrated and covered by thick scales. There was severe irritation.

Treatment

400 r to the lumbar and cervical areas, in weekly doses of 100 r.

Technical Factors

Kv	Ma	f.s.d.	Diam. of appl.	Filter
100	5	20 cms.	7.5 cms.	1.5 mm. Al

Result

Improved.

Case 100.

I. R. Age 29 Female

Family History

A brother and sister of the patient also suffer from psoriasis.

Personal History

The patient has always been well. Psoriasis began 20 years prior to examination. It has never cleared since.

On Examination

(12 Jun. 48)

There was widespread involvement of the body. There were scattered, gyrate, annular and serpiginous configurations. The lesions were infiltrated and covered by heavy crusts.

Treatment

600 r to the lumbar and cervical areas, in weekly doses of 200 r.

Technical Factors

Kv	Ma	f.s.d.	Diam. of appl.	Filter
100	5	20 cms.	10 cms.	1.5 mm. Al

Result

Improved.

Series 2.

CARBACHOL

Case 101.

A. McC. Age 32 Male

Family History: Nil.

Personal History: The patient has always been well. Psoriasis began 5 years prior to examination. It appeared as one lesion over the site of a previous tropical ulcer. It gradually spread and has never cleared since.

On Examination (19 Mar. 47): There was an elongated, tough scaling, infiltrated plaque on the right shin. Round the knees and elbows there were heavily scaling plaques (fig. 84). In the pubic region the skin was erythematous and covered by fine, powdery scales. On the glans penis there were some small, scaling papules.

Treatment: Tab. Carbachol mgm. 3, daily, for 2 days.
mgm. 4, daily, for 2 days.
mgm. 6, daily, thereafter.

Result: All trace of the eruption cleared by 28 May 47, 2½ months later.

Case 102.

D. D. Age 19 Male

Family History: Nil.

Personal History: The patient has always been well. Psoriasis began 3 years prior to examination. It has not cleared since.

On Examination (23 Mar. 47): The arms, below the elbows and the legs, below the knees were mainly involved. Down the forearms, back and front, and spreading over the backs of the hands and fingers there was a closely set papular and small guttate eruption. A similar type of eruption extended down the legs and across the dorsa of the feet. Round the knees and elbows the lesions had coalesced to form circular, heavily scaling

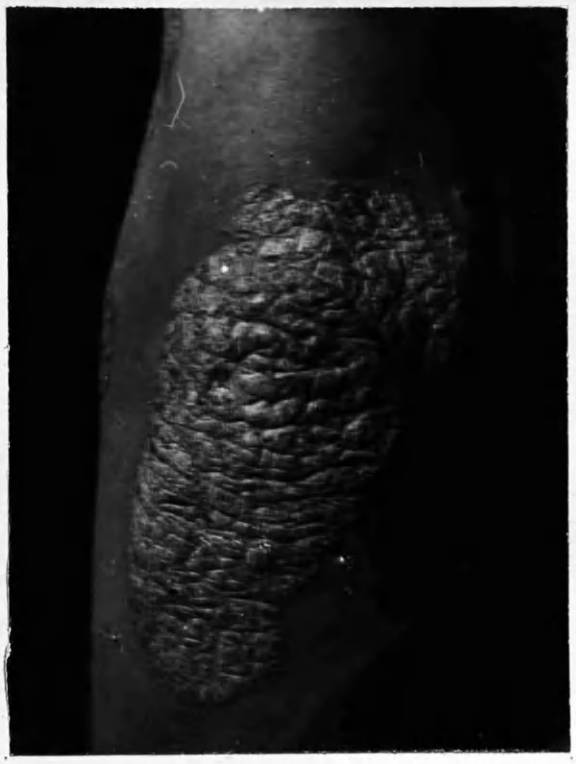

Fig. 84.

Case 101.

Plaque formation round the elbow.

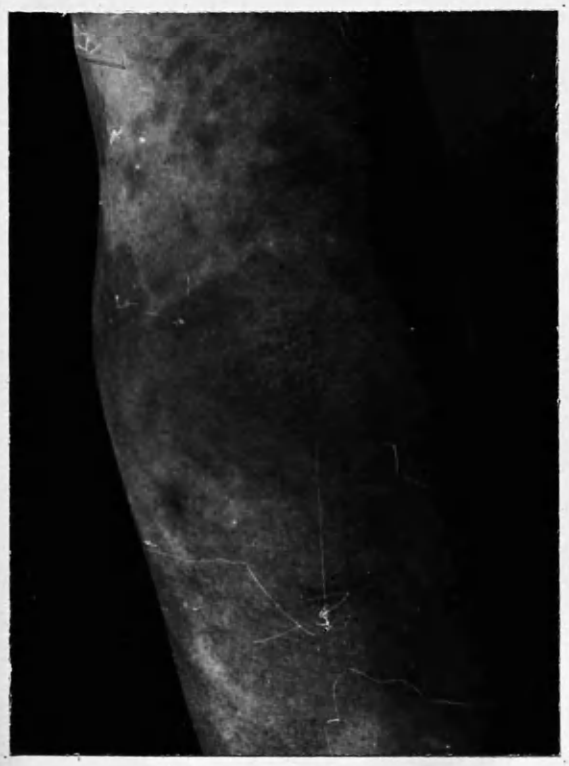

Fig. 85.

Case 101.

2 months later.

plaques. The skin on the hands was tough, coarse and thickened and had numerous, deep, linear fissures. The scalp was heavily crusted and on the outer aspect of each thigh, at the level of the great trochanter, there was a large, irregular, infiltrated, scaling plaque.

Treatment — Tab. Carbachol mgm. 3, daily, for 2 days.
mgm. 4, daily, for 2 days.
mgm. 6, daily, thereafter.

Result — All trace of the eruption had cleared by 9 Jul. 47, 4 months later.

Case 103.

D. W. L. Age 35 Male

Family History — A brother also has psoriasis.

Personal History — The patient has always been well. Psoriasis began 20 years prior to examination. Has never cleared since.

On Examination (24 Mar. 47) — Typical, tough scaling plaques round both elbows and on the right knee. On the legs, between the knees and the ankles, there were some circular, infiltrated, heavily scaled plaques.

Treatment — Tab. Carbachol mgm. 3, daily, for 2 days.
mgm. 4, daily, for 2 days.
mgm. 6, daily, thereafter.

Result — All trace of the eruption had cleared by 30 May 47,2 months later.

Case 104.

R. R. W. Age 15 Male

Family History — Nil.

Personal History — The patient gave a history of Pneumonia and Bronchitis. Psoriasis began for the first

time a few days prior to examination. It followed upon a severe attack of Tonsillitis.

On Examination (31 Mar. 47)

The arms and legs were covered by multiple lesions varying from pin-head sized papules to small, circular guttae, about the size of a sixpence. The scales were silvery and adherent. The skin on the backs of the hands was dry with a tendency to fissuring and there were numerous, red papules which extended on to the fingers.

Treatment

Tab. Carbachol mgm. 3, daily, for 2 days.
mgm. 4, daily, for 2 days.
mgm. 6, daily, thereafter.

Result

All trace of the eruption had cleared by 2 Jun. 47, 2 months later.

Case 105.

A. McD. M. Age 20 Male

Family History

Nil.

Personal History

The patient gave a history of Rheumatism. Psoriasis began a year prior to examination.

On Examination (9 Apr. 47)

There were numerous, circular, infiltrated, scaling lesions on the arms and legs (fig. 86). As well there was a widespread, papular eruption. On the scalp there were numerous, heavily scaled papules.

Treatment

Tab. Carbachol mgm. 3, daily, for 2 days.
mgm. 4, daily, for 2 days.
mgm. 6, daily, thereafter.

Result

All trace of the eruption had cleared by 23 Jul. 47, 3½ months later.

Case 106.

V. C. S. Age 19 Female

Family History

Nil.

Fig. 86.

Case 105.

Showing the plaque formation. This was similar on the arms.

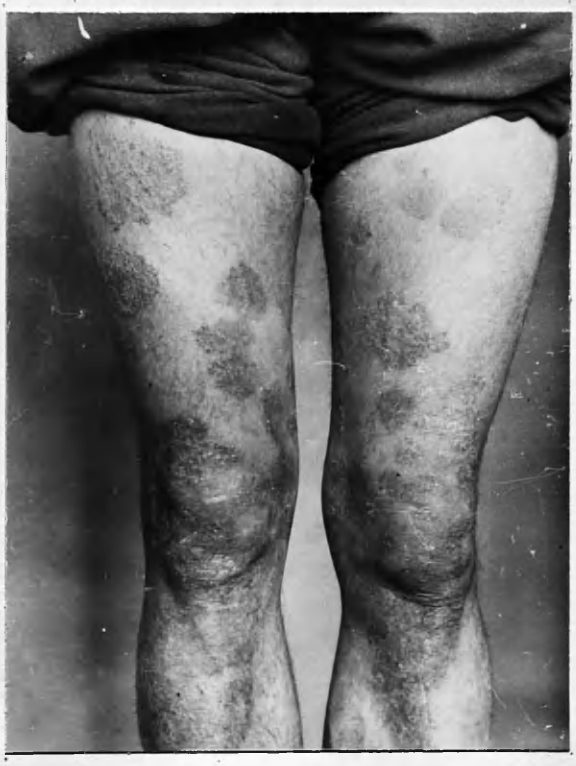

Fig. 87.

Case 105.

2 months later. Some pigmentation and fine scaling still be seen on the thighs.

Personal History — The patient has always been well. Psoriasis began 7 weeks prior to examination.

On Examination (15 Apr. 47) — The arms, backs of the hands and backs of the fingers were covered by a bright red, scaling, infiltrated, papular and small guttate eruption. There was a similar type of eruption on the legs and over the tops of the feet. The lesions were discrete, except round the ankles and on the dorsa of the feet where they had coalesced to form infiltrated, scaling plaques. There were numerous, widely scattered, guttae on the trunk, and the scalp was covered by a thick, infiltrated crust.

Treatment — Tab. Carbachol mgm. 3, daily, for 2 days.
mgm. 4, daily, for 2 days.
mgm. 6, daily, thereafter.

Result — All trace of the eruption had cleared by 2 Aug. 47, 3½ months later.

Case 107.

J. L. Age 28 Male

Family History — The patient has 3 brothers who also suffer from psoriasis.

Personal History — The patient gave a history of having had Pneumonia. Psoriasis began 2 years prior to examination. It has never cleared since.

On Examination (30 Sept. 47) — There was a widespread eruption involving the limbs, trunk and scalp. The lesions were mainly circular, raised, heavily scaling plaques of varying size. On the scalp there was a scaling, papular eruption.

Fig. 88 was taken 6 weeks after the start of treatment and shows the central areas of the plaques healed. The negative of the eruption as seen at examination was damaged accidentally.

Treatment — Tab. Carbachol mgm. 3, daily, for 2 days.
mgm. 4, daily, for 2 days.
mgm. 6, daily, thereafter.

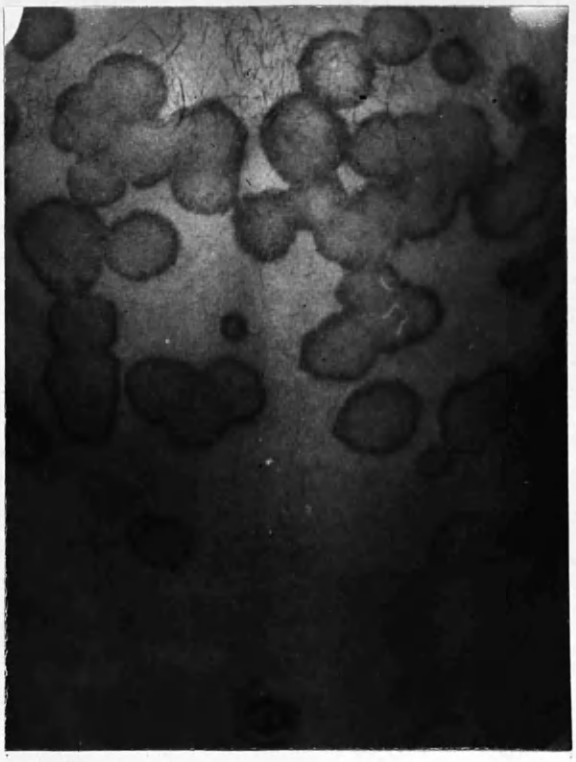

Fig. 88.

Case 107.

The chest and abdomen 6 weeks after the start of treatment. It shows the plaques healed in the centre.

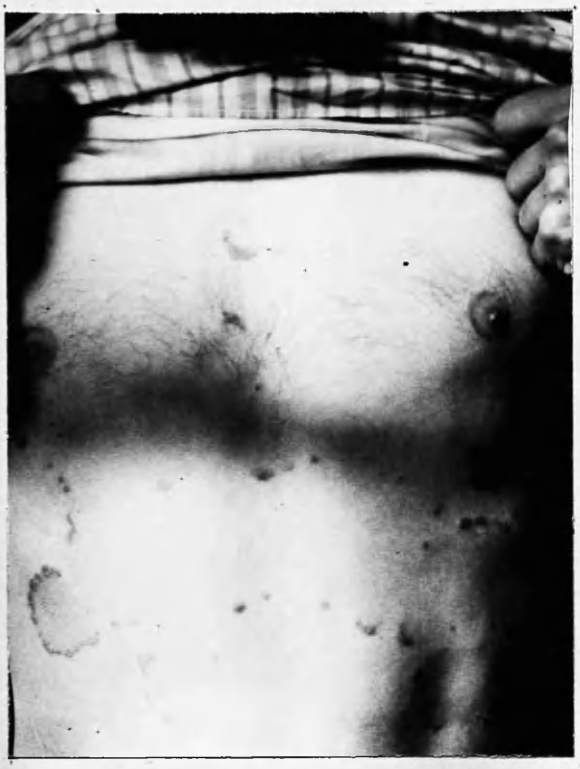

Fig. 89.

Case 107.

6 months later. A few serpiginous lesions and papules can still be seen.

Result — A few serpiginous lesions and papules persisted on the trunk for 6 months after the eruption had cleared from the limbs and scalp (fig. 89). All trace of the eruption, however, had cleared by 10 Jul. 48, 8½ months after the start of treatment.

Case 108.

A. D. — Age 15 — Female

Family History — Nil.

Personal History — The patient gave a history of having had Rheumatic fever. Psoriasis began 2 months prior to examination.

On Examination (30 Sept. 47) — On the trunk there were multiple, small, circular lesions covered by whitish, heaped up, tough scales and on the arms there was a mass of coarse, tough, greyish scales set on a dull red erythema. On the legs the lesions were nummular, dull red, infiltrated, heavily scaling plaques. The entire scalp was covered by a massive, infiltrated crust. The patient complained of severe irritation.

Treatment — Tab. Carbachol mgm. 3, daily, for 2 days.
mgm. 4, daily, for 2 days.
mgm. 6, daily, thereafter.

Result — All trace of the eruption had cleared by 21 Dec. 47, 2½ months later.

Case 109.

I. H. — Age 32 — Female

Family History — Nil.

Personal History — The patient has always been well. Psoriasis began a year prior to examination.

On Examination (30 Sept. 47)

Mainly knee - elbow distribution. On the right knee and spreading down the front of the right leg there was a thick, infiltrated plaque. There was also plaque formation at the left knee and round both elbows. There were also scattered guttate lesions.

Treatment

Tab. Carbachol mgm. 3, daily, for 2 days.
mgm. 4, daily, for 2 days.
mgm. 6, daily, thereafter.

600 r to the lumbar and cervical areas, in weekly doses of 200 r. Repeated.

Result

Unimproved with Carbachol.
Unimproved after 1st course of spinal radiation.
Improved after 2nd course of spinal radiation.

Case 110.

M. K. Age 27 Female

Family History

Nil.

Personal History

The patient has always been well. Psoriasis first began 13 years prior to examination. This first attack yielded to treatment and the skin was clear for 7 years. It then recurred as bad as ever. There have been no further remissions since.

On Examination (30 Sept. 47)

There were scattered, irregular plaque formations on both the legs and the arms. The lesions on the legs tended to be nummular, although one or two had irregular outlines, they were dusky red in colour, with white, adherent scales. On the arms the lesions were paler in colour, more irregular in outline and the scaling was finer and not so adherent. There was one nummular plaque on the trunk and the scalp was clear.

Treatment

Tab. Carbachol mgm. 3, daily, for 2 days.
mgm. 4, daily, for 2 days.
mgm. 6, daily, thereafter.

600 r to the lumbar and cervical areas, in weekly doses of 200 r.

Treatment (cont.) — Tab. Thiamin hydrochloride mgm. 25, daily.

Result — Improved with Carbachol. Relapsed.
Acute exacerbation following spinal radiation.
Improved with Thiamin hydrochloride.

Case 111.

E. R. — Age 26 — Female

Family History — The patient's father also has psoriasis.

Personal History — The patient has Goitre. Psoriasis began 10 years prior to examination. It cleared on one occasion for 4 years.

On Examination (30 Sept. 47) — The lesions were all on the upper part of the body. On the arms and trunk there were numerous gyrate and serpiginous configurations covered by fine, adherent scales.

Treatment — Tab. Carbachol mgm. 3, daily, for 2 days.
mgm. 4, daily, for 2 days.
mgm. 6, daily, thereafter.

Result — Improved.

Case 112.

T. D. — Age 32 — Female

Family History — The patient's mother also suffers from psoriasis.

Personal History — The patient gave a history of Rheumatism. Psoriasis began 24 years prior to examination and cleared on one occasion for over a year.

On Examination (7 Oct. 47) — There were multiple, widespread, circular lesions on the arms, legs, trunk, neck and scalp. The lesions were covered by tough, white, adherent scales.

Treatment — Tab. Carbachol mgm. 3, daily, for 2 days.
mgm. 4, daily, for 2 days.
mgm. 6, daily, thereafter.
600 r to the lumbar and cervical areas, in weekly doses of 200 r.

Result — Unimproved with Carbachol.
Unimproved after spinal radiation.

Case 113.

M. C. — Age 19 — Female

Family History — Nil.

Personal History — The patient has always been well. Psoriasis began 10 years prior to examination and on one occasion cleared for 9 months.

On Examination (7 Oct. 47) — There was plaque formation on the backs of the hands, arms, elbows, legs and knees. The lesions were erythematous, heavily scaled and infiltrated. The scalp and trunk were clear.

Treatment — Tab. Carbachol mgm. 3, daily, for 2 days.
mgm. 4, daily, for 2 days.
mgm. 6, daily, thereafter.

Result — All trace of the eruption had cleared by 25 Nov. 47, 7 weeks later.

Case 114.

A. G. — Age 49 — Female

Family History — Nil.

Personal History — The patient has been troubled for many years with Rheumatism and Bronchitis. The psoriasis began 4½ years prior to examination. It cleared on one occasion for 10 months.

On Examination (7 Oct. 47)

The whole body, with the exception of the face, was covered by a dull, red, exfoliating eruption. On the backs of the hands and on the tops of the feet the lesions were small, dull red circles. The whole scalp was covered by a massive, infiltrated crust. Irritation was marked.

Treatment

Tab. Carbachol mgm. 3, daily, for 2 days.
mgm. 4, daily, for 2 days.
mgm. 6, daily, thereafter.

Result

All trace of the eruption had cleared by 16 Dec. 47, 2½ months later.

Case 115.

J. P. V. R. Age 36 Male

Family History

A sister of the patient also suffers from psoriasis.

Personal History

The patient gave a history of Bronchitis and acute Dysentry. Psoriasis began 3 years prior to examination and has not been clear since, although it improves when the patient sun- bathes.

On Examination (7 Oct. 47)

The eruption was mild. Mainly papular and guttate with a tendency to plaque formation round the joints. Scaling is fine and powdery.

Treatment

Tab. Carbachol mgm. 3, daily, for 2 days.
mgm. 4, daily, for 2 days.
mgm. 6, daily, thereafter.

Result

All trace of the eruption had cleared by 25 Nov. 47, 7 weeks later.

Case 116.

M. T. Age 44 Female

Family History

Nil.

Personal History

The patient suffers from Rheumatism. Psoriasis began 5 years prior to examination. It has never cleared since.

On Examination

(7 Oct. 47)

Covering almost the entire extensor surfaces of both forearms, from the elbows to the wrists, were massive, infiltrated, heavily scaling plaques. On both knees there were irregular, infiltrated plaques with tough, white, adherent scales. There were a few scattered nummular lesions on the trunk and the scalp was moderately affected.

Treatment

Tab. Carbachol mgm. 3, daily, for 2 days.
mgm. 4, daily, for 2 days.
mgm. 6, daily, thereafter.
600 r to the spinal areas, in weekly doses of 200 r.

Result

Unimproved with Carbachol.
Unimproved after Spinal radiation.

Case 117.

S. O. Age 31 Female

Family History

Nil.

Personal History

The patient gave a history of having had Pleurisy. Psoriasis began 10 years prior to examination. It cleared on one occasion for a month.

On Examination

(7 Oct. 47)

There was a generalised, erythematous, scaling eruption on the trunk and limbs. On the back the lesions were circular and had a seborrhoeic appearance. The face and scalp were also affected

Treatment

Tab. Carbachol mgm. 3, daily, for 2 days.
mgm. 4, daily, for 2 days.
mgm. 6, daily, thereafter.
600 r to the lumbar and cervical areas, in weekly doses of 200 r.

Result

Unimproved with Carbachol.
Unimproved after Spinal radiation.

Case 118.

A..H. N. Age 22 Male

Family History: Nil.

Personal History: The patient has always been well. Psoriasis began 6 years prior to examination. It has never cleared since.

On Examination (7 Oct. 47): There were infiltrated, scaling plaques round the elbows and extending down the forearms and round the knees and extending down the legs. The rest of the body was clear.

Treatment: Tab. Carbachol mgm. 3, daily, for 2 days.
mgm. 4, daily, for 2 days.
mgm. 6, daily, thereafter.
600 r to the lumbar and cervical areas, in weekly doses of 200 r.

Result: Unimproved with Carbachol.
Improved after Spinal radiation.

Case 119.

A. McK. Age 27 Female

Family History: Nil.

Personal History: The patient has always been well. Psoriasis began 13 years prior to examination. It cleared on one occasion for 2 years.

On Examination (7 Oct. 47): There were dull red, finely scaling plaques on the backs of both hands. On the elbows and knees the plaques were circular, infiltrated and covered by massive crusts.

Treatment: Tab. Carbachol mgm. 3, daily, for 2 days.
mgm. 4, daily, for 2 days.
mgm. 6, daily, thereafter.

Result: Improved.

Case 120.

J. P. Age 27 Male

Family History: Nil.

Personal History: The patient has always been well. Psoriasis began 6 years prior to examination. It has never cleared since.

On Examination (7 Oct. 47): There was a dull red, finely scaling, infiltrated plaque on the front of the right leg, extending almost from the knee to the ankle. At both elbows and extending down the forearms there were small plaques covered by tough, whitish, heaped scales. Scattered on the chest, back and upper part of the abdomen were numerous red, discoidal lesions covered by fine, greasy, yellowish scales. The scalp had a few scaling papular lesions and was covered by a heavy dandruff-like scurf.

Treatment: Tab. Carbachol mgm. 3, daily, for 2 days.
mgm. 4, daily, for 2 days.
mgm. 6, daily, thereafter.
600 r to the lumbar and cervical areas, in weekly doses of 200 r. Repeated.

Result: Unimproved with Carbachol.
Unimproved after 2 courses of Spinal radiation.

Case 121.

S. W. Age 48 Female

Family History: The patient's father also suffered from psoriasis.

Personal History: The patient has always been well. Psoriasis began 18 years prior to examination. It has never cleared since.

On Examination (14 Oct. 47): There was widespread involvement with large plaques on the trunk and limbs. The plaques were bright red in colour and covered by shining translucent scales. There

were also some papular and guttate lesions present. The patient complained of irritation.

Treatment — Tab. Carbachol mgm. 3, daily, for 2 days.
mgm. 4, daily, for 2 days.
mgm. 6, daily, thereafter.
600 r to the lumbar and cervical areas, in weekly doses of 200 r.

Result — The original eruption cleared with Carbachol but a very irritable papular eruption developed. Spinal radiation has so far failed to relieve this.

Case 122.

P. McC. Age 14 Female

Family History — Nil.

Personal History — The patient has always been well. Psoriasis began 6 months prior to examination.

On Examination (8 Oct. 47) — There were multiple scaling papules on the arms and hands. On the legs, cheifly below the knees there were numerous irregular, scaling lesions (fig. 90). There were a few scaling papules in the scalp. The trunk was clear. Some irritation on the legs.

Treatment — Tab. Carbachol mgm. 3, daily, for 2 days.
mgm. 4, daily, for 2 days.
mgm. 6, daily, thereafter.

Result — Except for a very few papules on the legs all trace of the eruption had cleared by 7 Feb. 48, 4 months later.

Case 123.

E. McB. Age 55 Female

Family History — The patient's mother also suffered from psoriasis

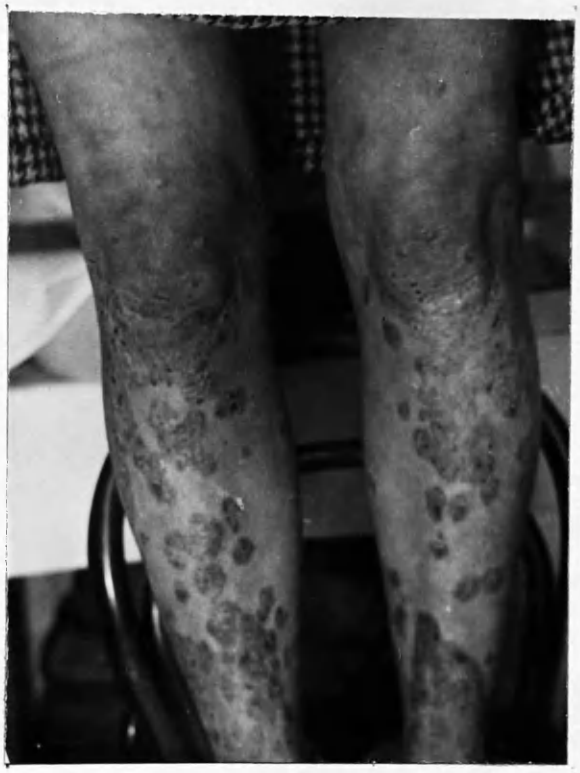

Fig. 90.

Case 122.

The legs as seen on first examination.

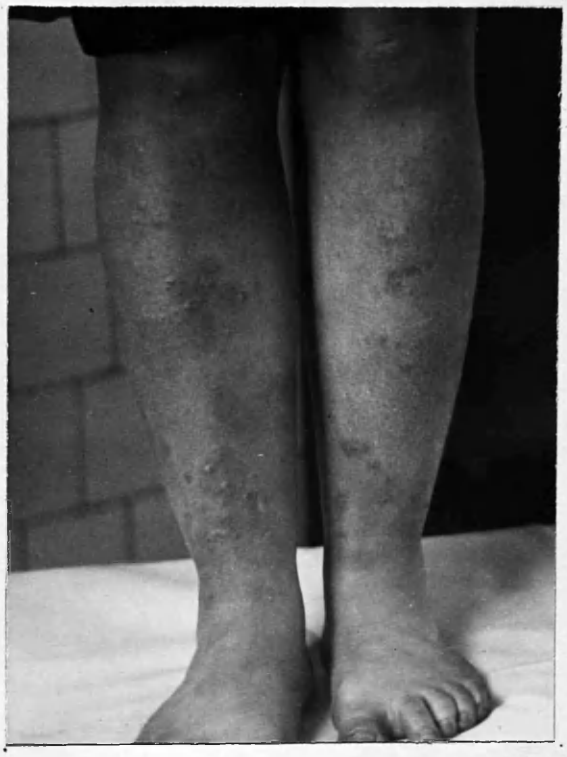

Fig. 91.

Case 122.

4 months later. A few scaling papules still persist.

Personal History

The patient gave a history of having Rheumatism. Psoriasis began 16 years prior to examination. It has never cleared since.

On Examination

(8 Oct. 47)

There was a large, infiltrated plaque on antero- lateral aspect of the right leg, extending from the ankle to the junction of the upper and middle third of the tibia. On the outer aspect of the left thigh there was another infiltrated plaque. Scaling on both was heavy. Irritation was troublesome.

Treatment

Tab. Carbachol mgm. 3, daily, for 2 days.
mgm. 4, daily, for 2 days.
mgm. 6, daily, thereafter.

Result

All trace of the psoriasis had cleared by 16 Mar. 48, 5½ months later.

Case 124.

J. M. J. Age 54 Male

Family History

Nil.

Personal History

The patient has always been well. Psoriasis began 22 years prior to examination. It has not cleared since.

On Examination

(21 Oct. 47)

There were numerous large plaques scattered over the body, but more concentrated on the buttocks, thighs, front and inner aspect of the knees, down the front of the legs and round the ankles. All the plaques were alike, being roughly circular, infiltrated, bright red and covered by small, silvery scales.

Treatment

Tab. Carbachol mgm. 3, daily, for 2 days.
mgm. 4, daily, for 2 days.
mgm. 6, daily, thereafter.

Result

With the exception of a faint reddish staining at the knees all trace of the eruption had cleared by 6 Jul. 48, 9 months later.

Case 125.

H. F. Age 41 Female

Family History: Nil.

Personal History: The patient gave no history of any serious illness. Psoriasis first began 18 years prior to examination. Since then there have been yearly acute flare-ups necessitating long periods of hospitilization. The longest time the eruption has been clear since it started has been 6 months. In all those attacks the hair fell out and the nails were shed.

On Examination (26 Sept. 47): The whole body, from the scalp down, was involved. The skin was acutely inflammed, almost scarlet in colour, and was covered by a mass of whitish, flake- like scales which showered off when the skin was rubbed. The texture of the skin was rough and the markings were exaggerated. The scalp was thickly covered by small scales which lay along the shaft of the hair. There was severe conjunctivitis of the left eye with photophobia. The patient was extremely uncomfortable.

Treatment: Tab. Carbachol mgm. 3, daily, for 2 days.
mgm. 4, daily, for 2 days.
mgm. 6, daily, thereafter.

Result: All trace of the eruption had cleared by 13 Jan. 48, 4 months later. On this occasion the nails were not shed and there was only a slight loss of hair.

Case 126.

J. S. Age 20 Female

Family History: Nil.

Personal History: The patient has always been well. Psoriasis began 5 years prior to examination. On one occasion it cleared for 4 months.

On Examination (3 Oct. 47)

There were large areas of dull red, scaling erythema with marked infiltration and a well defined, raised edge. The scalp, forehead, side of the face and neck, shoulders, chest and upper part of the back, arms and hands were covered by one continuous patch. The lower abdomen, lower part of the back, groins, buttocks and upper part of the thighs were covered by another continuous patch. There were large, irregular patches down both legs, round the ankles and across the dorsa of the feet. The palms and soles were clear.

Treatment

Tab. Carbachol mgm. 3, daily, for 2 days.
mgm. 4, daily, for 2 days.
mgm. 6, daily, thereafter.

600 r to the lumbar area, in weekly doses of 200 r.

Result

All trace of the eruption cleared from the upper part of the body with Carbachol.

The eruption on the lower part of the body was unimproved with both Carbachol and Spinal radiation.

Case 127.

E. G. Age 17 Female

Family History

Nil.

Personal History

The patient has always been well. Psoriasis began 6 months prior to examination.

On Examination (15 Oct. 47)

The arms and the legs were the only parts of the body affected. The lesions were raised, irregular, infiltrated plaques with large, white, adherent scales. As well as the plaques there were numerous guttate lesions. Irritation especially on the legs.

Treatment

Tab. Carbachol mgm. 3, daily, for 2 days.
mgm. 4, daily, for 2 days.
mgm. 6, daily, thereafter.

Result — All trace of the eruption had cleared by 3 Feb. 48, 4 months later. Relapsed.

Case 128.

C. B. — Age 23 — Female

Family History — Nil.

Personal History — The patient gave a history of having had Pneumonia and Bronchitis. Psoriasis began 7 months prior to examination.

On Examination (16 Oct. 47) — The legs only were affected. There were numerous, bright red, infiltrated, guttate lesions covered by whitish, adherent scales. There was irritation, especially at night.

Treatment — Tab. Carbachol mgm. 3, daily, for 2 days.
mgm. 4, daily, for 2 days.
mgm. 6, daily, thereafter.

Result — Improved. Relapsed.

Case 129.

M. C. — Age 36 — Female

Family History — Nil.

Personal History — The patient had an operation for an abscess at the foot of the spine in 1933. Psoriasis began 2 years prior to examination. It has not cleared since.

On Examination (15 Oct. 47) — Only the lower parts of the legs were affected. There were multiple, erythematous, heavily scaled, guttate lesions between the knees and the ankles. On the left leg, as well, there were two circular, crusted plaques on the inner aspect, just above the ankle.

Treatment — Tab. Carbachol mgm. 3, daily, for 2 days.
mgm. 4, daily, for 2 days.
mgm. 6, daily, thereafter.

Result — All trace of the eruption had cleared by 4 Nov. 47, 3 weeks later.

Case 130.

Mrs. G. — Age 48 — Female

Family History — The patient's son also suffers from psoriasis.

Personal History — The patient has always been well. Psoriasis began 18 years prior to examination.

On Examination (23 Oct 47) — Down the extensor surface of both forearms there was a broad, elongated area of raised erythema covered by fine, white scales. On the right knee there was a large, infiltrated plaque with tough, thick, heaped-up scales with a linear extension down the right shin. As well, there were numerous, small, circular, scaling lesions. There was a smaller plaque on the left knee with scattered, heavily scaled lesions extending down the left leg. The scalp was moderately affected and there were a few, small, reddish, scaling lesions behind the ears.

Treatment — Tab. Carbachol mgm. 3, daily, for 2 days.
mgm. 4, daily, for 2 days.
mgm. 6, daily, thereafter.

Result — Improved.

Case 131.

H. C. — Age 16 — Female

Family History — Nil.

Personal History — The patient gave a history of Rheumatism. Psoriasis began 3 years prior to examination. It has never cleared since.

On Examination (8 Oct. 47) — There was a large, infiltrated, heavily crusted plaque on the chest and between the breasts shaped like the ace of clubs. On both temples there was a large, oval plaque,

heavily crusted and infiltrated and round the hair margin there was a continuous, broad, heavily scaling, erythematous eruption. There were numerous areas of thick crusting on the scalp.

Treatment — Tab. Carbachol mgm. 3, daily, for 2 days.
mgm. 4, daily, for 2 days.
mgm. 6, daily, thereafter.
600 r to the cervical area, in weekly doses of 200 r. Repeated.
Tab. Thiamin hydrochloride mgm. 25, daily.

Result — Improved but relapsed with Carbachol.
Improved but relapsed with Spinal radiation
The eruption cleared entirely after Thiamin had been given.

Case 132.

S. F. — Age 13 — Female

Family History — Nil.

Personal History — The patient has always been well. Psoriasis began 6 weeks prior to examination.

On Examination (29 Oct. 47) — There was an acute, generalised, papular eruption affecting the whole body. The papules were dull red in colour and were covered by small, brittle, silvery scales. Round the elbows, knees and ankles and in the sacral region there was plaque formation.

Treatment — Tab. Carbachol mgm. 3, daily, for 2 days.
mgm. 4, daily, for 2 days.
mgm. 6, daily, thereafter.

Result — All trace of the eruption had cleared by 18 May 48, 7 months later.

Case 133.

E. F. — Age 45 — Female

Family History — A brother of the patient also suffers from psoriasis.

Personal History

The patient gave a history of Rheumatism. Psoriasis began 33 years prior to examination. It cleared on 3 occasions after treatment in hospital but soon re-appeared. The present attack has been the worst so far.

On Examination (16 Oct. 47)

There was a generalised, guttate eruption involving all areas of the body. On the arms there were also plaque formations. Scaling was heavy and the patient complained of severe irritation.

Treatment

Tab. Carbachol mgm. 3, daily, for 2 days.
mgm. 4, daily, for 2 days.
mgm. 6, daily, thereafter.
Tab. Thiamin hydrochloride mgm. 25, daily.

Result

All trace of the eruption cleared with Carbachol.
An irritable papular eruption developed immediately afterwards. This was improved improved with Thiamin.

Case 134.

M. C. Age 50 Female

Family History

Nil.

Personal History

The patient has always been well. Psoriasis began 4 years prior to examination. It has cleared on 2 occasions.

On Examination (6 Oct. 47)

On both forearms there were thickly crusted, rupoid lesions, the one on the left arm extending almost from the elbow to the wrist. The crust was about $\frac{1}{4}$ inch thick. On the back of the left hand there was a circular, heavily crusted, infiltrated lesion. The rest of the body was clear.

Treatment

Tab. Carbachol mgm. 3, daily, for 2 days.
mgm. 4, daily, for 2 days.
mgm. 6, daily, thereafter.

Result

All trace of the eruption had cleared by 23 Dec. 47, 3 months later.

Case 135.

J. G. M. Age 41 Male

Family History Nil.

Personal History The patient has always been well. Psoriasis began 2 years prior to examination. It has not cleared since.

On Examination (23 Oct. 47) The hair margin and scalp were the areas mainly affected. All round the hair margin and extending on to the scalp there were raised, red, infiltrated lesions covered by yellowish, greasy scales. There was a large area of baldness on the top of the head which was free from lesions. On the right elbow there were two small, circular, infiltrated plaques covered by white scales. All other areas were clear.

Treatment Tab. Carbachol mgm. 3, daily, for 2 days.
mgm. 4, daily, for 2 days.
mgm. 6, daily, thereafter.
600 r to the cervical area, in weekly doses of 200 r.

Result Unimproved with Carbachol.
Unimproved after Spinal radiation.

Case 136.

J. R. Age 24 Female

Family History Nil.

Personal History The patient gave a history of having had Pneumonia and Meningitis. Psoriasis began 23 years prior to examination. On one occasion it cleared for 6 years.

On Examination (28 Oct. 47) There was a severe pustular psoriasis involving the hands and fingers and the feet and toes. The hands and fingers were the most severely affected. There was deep fissuring and the hands were drawn up into a half shut position.

Treatment — Tab. Carbachol mgm. 3, daily, for 2 days.
mgm. 4, daily, for 2 days.
mgm. 6, daily, thereafter.

Result — Unimproved.

Case 137.

R. T. — Age 32 — Male

Family History — Nil.

Personal History — The patient has always been well. Psoriasis began 4 years prior to examination. It has not cleared since.

On Examination (29 Oct. 47) — The eruption was confined almost entirely to the pubic region, groins, shaft of the penis and the scrotum and to a lesser extent over the coccyx. The skin was raised, bright red and inflammed, there was no scaling and on the scrotum the skin was thickened and had lost its elasticity. Irritation was intense.

Treatment — Tab. Carbachol mgm. 3, daily, for 2 days.
mgm. 4, daily, for 2 days.
mgm. 6, daily, thereafter.
600 r to the lumbar and cervical areas, in weekly doses of 200 r. Repeated.
Tab Thiamin Hydrochloride mgm 25, daily.

Result — Improved but relapsed with Carbachol.
Improved but relapsed after Spinal radiation (1st. course).
Acute exacerbation during 2nd. course of Spinal radiation.
Improved with Thiamin.

Case 138.

A. G. — Age 65 — Female

Family History — Nil.

Personal History — The patient has always been well. Psoriasis began 7 years prior to examination.

On Examination (16 Oct. 47)

There were infiltrated, raw, beefy looking lesions under and between the breasts, covered by soft, white, macerated scales. On the left side of the abdomen there were two, large, heavily crusted, circular plaques and a similar plaque on the left thigh about the level of the great trochanter. There was also plaque formation round both elbows and in the sacral region. In both axillae there were collections of scaling papules. On the scalp there were numerous, small, infiltrated, crusted areas.

Treatment

Tab. Carbachol mgm. 3, daily, for 2 days.
mgm. 4, daily, for 2 days.
mgm. 6, daily, thereafter.

Result

All trace of the eruption had cleared by 23 Dec. 47, 2 months later.

Case 139.

M. McG. Age 17 Female

Family History

Nil.

Personal History

The patient has always been healthy. Psoriasis began a year prior to examination. It has not cleared since.

On Examination (3 Nov. 47)

Only the legs and the scalp were affected. On the legs the lesions varied from small guttae to fairly extensive geographic plaques. The lesions were infiltrated and covered by thick, white scales. On the scalp there were numerous, infiltrated, crusted areas.

Treatment

Tab. Carbachol mgm. 3, daily, for 2 days.
mgm. 4, daily, for 2 days.
mgm. 6, daily, thereafter.

Result

All trace of the eruption had cleared by 29 Jan. 48, 3 months later.

Case 140.

R. McA. Age 31 Female

Family History: Nil.

Personal History: The patient has always been well. Psoriasis began 5 years prior to examination. It has never cleared.

On Examination (3 Nov. 47): The arms and legs were extensively involved. The lesions, of varying size and shape, were bright red, raised, infiltrated and covered by soft, yellowish scales. There was a heavy scarf on the scalp.

Treatment: Tab. Carbachol mgm. 3, daily, for 2 days.
mgm. 4, daily, for 2 days.
mgm. 6, daily, thereafter.

Result: Improved.

Case 141.

J. B. S. Age 35 Male

Family History: Nil.

Personal History: The patient has always been well. Psoriasis began 1½ years prior to examination. It has remained the same since.

On Examination (22 Oct. 47): There were large, heavily scaled plaques widely scattered on the body. There was also a papular and guttate eruption. The scalp was heavily crusted and the patient complained of severe irritation.

Treatment: Tab. Carbachol mgm. 3, daily, for 2 days.
mgm. 4, daily, for 2 days.
mgm. 6, daily, thereafter.

Result: All trace of the eruption had cleared by 20 Mar. 48, 5 months later.

Case 142.

S. J. McG. Age 25 Male

Family History	Nil.
Personal History	The patient gave a history of having had Bronchitis and Rheumatism. Psoriasis began 9 years prior to examination. It was clear for 5 years at one time.
On Examination (5 Nov. 47)	There were numerous, serpiginous and gyrate configurations on the trunk - mostly on the back. There were multiple papules scattered on the arms and legs. The scalp was clear.
Treatment	Tab. Carbachol mgm. 3, daily, for 2 days. mgm. 4, daily, for 2 days. mgm. 6, daily, thereafter.
Result	Improved.

Case 143.

A. F. Age 18 Female

Family History	Nil.
Personal History	The patient has always been well. Psoriasis began 8 years prior to examination. It has never cleared since.
On Examination (5 Nov. 47)	The arms, below the elbows and the legs, below the knees, were covered by erythematous, finely scaling, infiltrated lesions. On the scalp there were a few scaling papules.
Treatment	Tab. Carbachol mgm. 3, daily, for 2 days. mgm. 4, daily, for 2 days. mgm. 6, daily, thereafter.
Result	The eruption cleared but relapsed as soon as Carbachol was stopped.

Case 144.

H. M. Age 63 Male

Family History The patient's mother also suffered from psoriasis.

Personal History The patient gave a history of having had Pneumonia, Pleurisy and Arthritis. Psoriasis began 34 years prior to examination. It has varied but has never quite cleared.

On Examination (6 Nov. 47) There were erythematous, scaling plaques down the front and outer aspect of both legs. Round the elbows there were irregular, scaling plaques. On the backs of the hands there were numerous, red, non-scaling papules.

Treatment Tab. Carbachol mgm. 3, daily, for 2 days.
mgm. 4, daily, for 2 days.
mgm. 6, daily, thereafter.

Result Unimproved.

Case 145.

R. P. Age 26 Male

Family History Nil.

Personal History The patient has always been well. Psoriasis began 8 years prior to examination. It has never cleared since.

On Examination (6 Nov. 47) There was a papular, guttate and nummular plaque eruption on the arms and legs. Round the knees and elbows plaque formation was more massive and scaling heavier. Scattered guttae on the trunk with some gyrate configurations. There were some scaling papules on the scalp.

Treatment Tab. Carbachol mgm. 3, daily, for 2 days.
mgm. 4, daily, for 2 days.
mgm. 6, daily, thereafter.

Result All trace of the eruption had cleared by 17 Jan. 48, 2½ months later.

Case 146.

A. McK. Age 32 Male

Family History: Nil.

Personal History: The patient has always been well. Psoriasis began 5 years prior to examination. It has never cleared since.

On Examination (6 Nov. 47): There were widely scattered, small, dull red, raised, infiltrated guttae and small plaques covered by thick scales. On the left shin there was a large, infiltrated plaque. There was a heavy scurf on the scalp.

Treatment: Tab. Carbachol mgm. 3, daily, for 2 days.
mgm. 4, daily, for 2 days.
mgm. 6, daily, thereafter.

Result: All trace of the eruption had cleared by 23 Mar. 48, 4½ months later.

Case 147.

M. S. Age 20 Female

Family History: The patient's sister also has psoriasis (Case 78).

Personal History: The patient gave a history of having had Pleurisy. Psoriasis began 10 years prior to examination. It has never cleared.

On Examination (8 Nov. 47): There was plaque formation round both elbows and on the left knee. On the arms and legs there were some scattered guttate lesions. Round the hair margin there were numerous, small, circular, scaling lesions.

Treatment: Tab. Carbachol mgm. 3, daily, for 2 days.
mgm. 4, daily, for 2 days.
mgm. 6, daily, thereafter.

Result: All trace of the eruption had cleared by 17 Jan. 48, 2½ months later.

Case 148.

J. G. Age 60 Female

Family History Nil.

Personal History The patient gave a history of Bronchitis. Psoriasis began 7 months prior to examination.

On Examination (10 Nov. 47) The perianal region, perineum, vulva, groins, upper and inner aspect of the thighs and the pubic region were covered by bright red, raised, infiltrated tissue. Scaling was not marked and what there was was whitish and macerated. Small, circular lesions extended down the inner aspect of the thighs. The irritation was intense.

Treatment Tab. Carbachol mgm. 3, daily, for 2 days.
mgm. 4, daily, for 2 days.
mgm. 6, daily, thereafter.

Result All trace of the eruption had cleared by 20 Jan. 48, 2½ months later.

Case 149.

W. N. Age 66 Female

Family History Nil.

Personal History The patient has suffered for many years from Arthritis. Psoriasis began 20 years prior to examination. It has never quite cleared.

On Examination (10 Nov. 47) There were large, infiltrated plaques round the knees and the elbows and also between the knees and the ankles. There was hyperkeratosis on the heels and along the sides of the feet.

Treatment Tab. Carbachol mgm. 3, daily, for 2 days.
mgm. 4, daily, for 2 days.
mgm. 6, daily, thereafter.

Result All trace of the eruption had cleared by 30 Mar. 48, 4½ months later.

Case 150.

W. P. Age 46 Male

Family History The patient's father also suffers from psoriasis.

Personal History The patient has always been well. Psoriasis began 40 years prior to examination. It has never cleared since.

On Examination (13 Nov. 47) There was widespread involvement of the body. On the trunk there were erythematous, scaling gyrate configurations with one large, infiltrated plaque in the lumbar region. On the limbs the eruption was papular, guttate and small plaque. On the scalp there were many scaling papules. Irritation troublesome.

Treatment Tab. Carbachol mgm. 3, daily, for 2 days.
mgm. 4, daily, for 2 days.
mgm. 6, daily, thereafter.
600 r to the lumbar and cervical areas, in weekly doses of 200 r.

Result Unimproved with Carbachol.
Unimproved after spinal radiation.

Case 151.

F. W. A. Age 45 Male

Family History The patient's son also suffers from psoriasis.

Personal History The patient has always been well. Psoriasis began 30 years prior to examination. On one occasion it cleared for 8 months.

On Examination (17 Nov. 47) Round the knees and elbows there were numerous, small, scaling plaques and small plaques and guttae spreading down the arms and legs. All the lesions were covered by thick, tough scaling.

Treatment Tab. Carbachol mgm. 3, daily, for 2 days.
mgm. 4, daily, for 2 days.
mgm. 6, daily, thereafter.

Treatment (cont.) 600 r to the lumbar and cervical areas, in weekly doses of 200 r.

Result Unimproved with Carbachol.
Unimproved after Spinal radiation.

Case 152.

F. C. Age 55 Female

Family History Nil.

Personal History The patient gave a history of Rheumatism. Psoriasis began 2 years prior to examination. Has never cleared.

On Examination (26 Nov. 47) There were small plaques on both elbows and both knees. They were infiltrated and covered by coarse, white crusts. There was one circular lesion on the front of the scalp covered by a heaped- up, white crust. On the forehead, at the hair margin, there was a row of scaling papules.

Treatment Tab. Carbachol mgm. 3, daily, for 2 days.
mgm. 4, daily, for 2 days.
mgm. 6, daily, thereafter.

Result All trace of the eruption had cleared by 2 Mar. 48, 3½ months later.

Case 153.

M. R. Age 18 Female

Family History Nil.

Personal History The patient gave a history of Asthma. Psoriasis began a few days prior to examination.

On Examination (28 Nov. 47) There was a circular area about 8 cms in diameter in the lumbar region made up of very closely set, scaling papules and small guttae. There were no lesions anywhere else.

Treatment — Tab. Carbachol mgm. 3, daily, for 2 days.
mgm. 4, daily, for 2 days.
mgm. 6, daily, thereafter.

Result — All trace of the eruption had cleared by 27 Apr. 48, 5 months later.

Case 154.

A. S. — Age 45 — Female

Family History — Nil.

Personal History — The patient has always been well. Psoriasis began 26 years prior to examination. It cleared on one occasion for 8 years.

On Examination (2 Dec. 47) — There was a large, ovoid plaque on the right shin and, on the left leg, just above the internal malleolus, there was a large, circular plaque. The plaques were infiltrated and covered by a yellowish crust. There was also some stasis dermatitis and a degree of secondary infection. Irritation was severe.

Treatment — Tab. Carbachol mgm. 3, daily, for 2 days.
mgm. 4, daily, for 2 days.
mgm. 6, daily, thereafter.

Result — Improved.

Case 155.

J. McC. — Age 16 — Female

Family History — Nil.

Personal History — The patient gave a history of having had Pneumonia. Psoriasis began 2 years prior to examination.

On Examination (10 Dec 47) — There was a widespread, bright red, scaling guttate eruption involving all areas of the body. The scalp was covered by a massive, infiltrated crust.

Treatment — Tab. Carbachol mgm. 3, daily, for 2 days.
mgm. 4, daily, for 2 days.
mgm. 6, daily, thereafter.

Result — All trace of the eruption had cleared by 14 Feb. 48, 2½ months later.

Case 156.

M. A. S. — Age 44 — Female

Family History — Nil.

Personal History — The patient gave a history of Rheumatism following Diphtheria. She has had Erysipelas twice and 'Dermatitis' of the neck. There was also a history of Bronchitis. Psoriasis began 24 years prior to examination. It was clear for 19 years and only recurred 4 years prior to examination. It has not cleared since.

On Examination (2 Dec. 47) — There were raised, infiltrated, erythematous, scaling plaques round both elbows and extending down the extensor aspect of the forearms and round both knees and extending down the front and outer aspects of the legs.

Treatment — Tab. Carbachol mgm. 3, daily, for 2 days.
mgm. 4, daily, for 2 days.
mgm. 6, daily, thereafter.
600 r to the lumbar and cervical areas, in weekly doses of 200 r.

Result — Unimproved with Carbachol.
Unimproved after Spinal radiation.

Case 157.

A. McG. — Age 19 — Male

Family History — Nil.

Personal History — The patient has always been well. Psoriasis began 5 years prior to examination. It has never cleared since.

On Examination (22 Dec. 47)

There was widespread involvement of the trunk - mainly the front. Large, erythematous, infiltrated plaques. On the limbs the eruption was papular and guttate. The scalp was covered by multiple, scaling papules.

Treatment

Tab. Carbachol mgm. 3, daily, for 2 days.
mgm. 4, daily, for 2 days.
mgm. 6, daily, thereafter.
600 r to the lumbar and cervical areas, in weekly doses of 200 r.

Result

Unimproved with Carbachol.
Unimproved after Spinal radiation.

Case 158.

C. McI. Age 34 Female

Family History

Nil.

Personal History

The patient gave a history of having had Pneumonia and Pleurisy. Psoriasis began 4 years prior to examination. It cleared for 9 months during pregnancy.

On Examination (13 Jan. 48)

Only the arms were affected. There was a finely scaling erythema extending from the elbows to the wrists and some isolated, small, guttate lesions as well.

Treatment

Tab. Carbachol mgm. 3, daily, for 2 days.
mgm. 4, daily, for 2 days.
mgm. 6, daily, thereafter.
600 r to the lumbar and cervical areas, in weekly doses of 200 r.
Tab. Thiamin hydrochloride mgm. 25 daily.

Result

An acute exacerbation, all over the body, developed 3 weeks after Carbachol was started. This was made very much worse after the course of Spinal radiation.
An almost immediate improvement followed the administration of Thiamin. This improve- was maintained until at the present time very little abnormal tissue remains.

Case 159.

J. W. Age 15 Female

Family History: Nil.

Personal History: The patient gave a history of having had Pneumonia twice and Bronchial asthma. Psoriasis began 2 months prior to examination.

On Examination (13 Jan. 48): There was a generalised, papular eruption involving all areas of the body, including the face. The papules were dull red and finely scaling. Round the knees and elbows there were small, plaque formations. The scalp and the post auricular areas were also affected.

Treatment: Tab. Carbachol mgm. 3, daily, for 2 days.
mgm. 4, daily, for 2 days.
mgm. 6, daily, thereafter.

Result: All trace of the eruption had cleared by 13 Apr. 48, 3 months later.

Case 160.

H. B. Age 29 Male

Family History: The patient's sister (Case 163) and four cousins, two included in the series (Cases 43 & 44) and an aunt suffer from psoriasis.

Personal History: The patient gave a history of having had Malaria. Psoriasis began 6 weeks prior to examination.

On Examination (14 Jan. 48): There were scattered, guttate lesions on the arms and legs, with plaque formation round the knees and elbows. The lesions were infiltrated and scaling. The scalp was clear.

Treatment: Tab. Carbachol mgm. 3, daily, for 2 days.
mgm. 4, daily, for 2 days.
mgm. 6, daily, thereafter.

Result: All trace of the eruption had cleared by 30 Mar. 48, 2½ months later.

Case 161.

E. McC. Age 36 Female

Family History Nil.

Personal History The patient has always been well. Psoriasis began 8 years prior to examination. It has never quite cleared since.

On Examination (4 Feb. 48) There was a generalised, small circular plaque and gyrate eruption involving all areas of the body. There was a papular eruption on the face. The scalp was also affected.

Treatment Tab. Carbachol mgm. 3, daily, for 2 days.
mgm. 4, daily, for 2 days.
mgm. 6, daily, thereafter.

Result All trace of the eruption had cleared by 29 May 48, 4 months later.

Case 162.

F. D. Age 19 Male

Family History There was a strong family history. The patient's 3 sisters and 1 brother also suffer from psoriasis.

Personal History The patient gave a history of having had Rheumatism and Bronchitis. Psoriasis began 11 years prior to examination. It cleared for 3 months on one occasion following treatment in hospital.

On Examination (4 Feb. 48) All areas of the body were affected. Small, geographic plaques and gyrate patterns on the chest and abdomen. Guttate and papular eruption on the arms and back. Plaque, guttate and papular on the legs. The scalp and hair margin were severely affected. Irritation severe.

Treatment Tab. Carbachol mgm. 3, daily, for 2 days.
mgm. 4, daily, for 2 days.
mgm. 6, daily, thereafter.

Result All trace of the eruption had cleared by 5 Jun. 48, 5 months later.

Case 163.

A. M. Age 38 Female

Family History The patient's brother (Case 160), four cousins and an aunt suffer from psoriasis.

Personal History The patient has always been well. Psoriasis began 20 years prior to examination. It cleared on one occasion for a year.

On Examination (17 Feb. 48) The eruption was fairly mild. Round the wrists, on the abdomen and back and on the legs there were scattered, guttate lesions. The scalp was clear.

Treatment Tab, Carbachol mgm. 3, daily, for 2 days.
mgm. 4, daily, for 2 days.
mgm. 6, daily, thereafter.

Result All trace of the eruption had cleared by 18 May 48, 4 months later.

Case 164.

M. B. Age 32 Female

Family History Nil.

Personal History The patient has always been well. Psoriasis began 7 years prior to examination. It has remained much the same since.

On Examination (17 Feb. 48) The skin on the hands was thickened, rough and fissured. There was a large, irregular plaque on the back of each hand and a few guttae on the extensor aspect of the forearms. On the trunk, neck and legs there were more guttate lesions.

Treatment Tab. Carbachol mgm 3, daily, for 2 days.
mgm. 4, daily, for 2 days.
mgm. 6, daily, thereafter.

Result — All trace of the eruption had cleared by 15 Jun. 48, 4 months later.

Case 165.

G. McK. — Age 23 — Male

Family History — Nil.

Personal History — The patient has always been well. Psoriasis began 4 months prior to examination.

On Examination (3 Mar. 48) — There were small nummular plaques on the trunk. The plaques were raised, infiltrated and covered by white, brittle, adherent scales. The limbs and scalp were clear.

Treatment — Tab. Carbachol mgm. 3, daily, for 2 days.
mgm. 4, daily, for 2 days.
mgm. 6, daily, thereafter.

Result — Unimproved.

Case 166.

A. O'D. — Age 14 — Female

Family History — Nil.

Personal History — The patient has always been well. Psoriasis began 11 years prior to examination. It has never cleared since.

On Examination. (16 Mar. 48) — There was a generalised eruption. It was papular on the trunk and papular, guttate and small plaque on the limbs. The scalp and hair margin were also affected.

Treatment — Tab. Carbachol mgm. 3, daily, for 2 days.
mgm. 4, daily, for 2 days.
mgm. 6, daily, thereafter.

Result — Improved.

Case 167.

D. G. Age 33 Male

Family History: The patient's father and brother also suffer from psoriasis.

Personal History: The patient has always been well. Psoriasis began 12 years prior to examination. It has never cleared.

On Examination (17 Mar. 48): There were numerous, large, oval, infiltrated, heavily scaling plaques on the trunk. Round the elbows, on the forearms and round the knees there were smaller plaque formations.

Treatment: Tab. Carbachol mgm. 3, daily, for 2 days.
mgm. 4, daily, for 2 days.
mgm. 6, daily, thereafter.

Result: Improved.

Case 168.

B. G. Age 22 Male

Family History: The patient's father and brother suffer from psoriasis.

Personal History: The patient has always been well. Psoriasis began 8 years prior to examination. It has never cleared.

On Examination (17 Mar. 48): The limbs were mainly affected. The lesions were mostly papules and guttae but there was irregular plaque formation on the back of the hands and round the elbows and knees. There were guttae and small plaques scattered on the trunk. The scalp was affected.

Treatment: Tab. Carbachol mgm. 3, daily, for 2 days.
mgm. 4, daily, for 2 days.
mgm. 6, daily, thereafter.

Result: Unimproved.

Case 169.

J. M. Age 49 Female

Family History: The patient's brother suffers from psoriasis.

Personal History: The patient has always been well. Psoriasis began 30 years prior to examination. It has never cleared.

On Examination (22 Mar. 48): There was a generalised, guttate and small plaque eruption on the trunk, arms and buttocks On the face the eruption was papular and the scalp was grossly affected. The left breast was covered by a fiery red erythema with small, dry scales on the upper part but with macerated scales and some weeping under the breasts.

Treatment: Tab. Carbachol mgm. 3, daily, for 2 days.
mgm. 4, daily, for 2 days.
mgm. 6, daily, thereafter.

Result: Improved.

Case 170.

M. J. Age 44 Female

Family History: The patient's mother also suffers from psoriasis.

Personal History: The patient has always been well. Psoriasis began 8 years prior to examination. It has never cleared.

On Examination (24 Mar. 48): The vulva, groins, pubis, perineum, perianal region and the upper and inner aspect of the thighs were covered by bright red, raised tissue. The scales, few in number, were soft and macerated. The irritation was severe. On the knees and elbows there were large plaque formations and the scalp was badly affected.

Treatment: Tab. Carbachol mgm. 3, daily, for 2 days.
mgm. 4, daily, for 2 days.
mgm. 6, daily, thereafter.

Result — All trace of the eruption had cleared by 5 Jun. 48, 2½ months later.

Case 171.

J. C. — Age 13 — Male

Family History — Nil.

Personal History — The patient has always been well. Psoriasis began a year prior to examination. It has never cleared.

On Examination (31 Mar. 48) — Only the limbs were affected, the legs to a greater extent than the arms. The eruption was made up of guttae and small, nummular plaques. Scaling was heavy.

Treatment — Tab. Carbachol mgm. 3, daily, for 2 days.
mgm. 4, daily, for 2 days.
mgm. 6, daily, thereafter.

Result — Improved.

Case 172.

J. G. — Age 37 — Male

Family History — The patient's father also suffers from psoriasis.

Personal History — The patient gave a history of having had Rheumatism and Bronchitis. Psoriasis began 5 months prior to examination.

On Examination (6 Apr. 48) — There were large, irregular plaques on the legs, below the knees. On the arms the lesions were papular and guttate. A heavy scurf covered the scalp. The legs were irritible.

Treatment — Tab. Carbachol mgm. 3, daily, for 2 days.
mgm. 4, daily, for 2 days.
mgm. 6, daily, thereafter.

Result — Improved.

Case 173.

M. D. Age 17 Female

Family History: The patient's mother also suffers from psoriasis.

Personal History: The patient has always been well. Psoriasis began 2 weeks prior to examination.

On Examination (10 Apr. 48): The eruption was of a very mild nature, the arms only being affected. On the arms there were a few small areas of finely scaling erythema.

Treatment: Tab. Carbachol mgm. 3, daily, for 2 days.
mgm. 4, daily, for 2 days.
mgm. 6, daily, thereafter.

Result: All trace of the eruption had cleared by 25 May 48, 6 weeks later.

Case 174.

E. K. Age 38 Female

Family History: Nil.

Personal History: The patient gave a history of having had Bronchitis. Psoriasis began 6 months prior to examination. It has not cleared since.

On Examination (14 Apr. 48): Round the knees and the elbows there were heavily crusted, infiltrated plaques. On the arms and thighs there was a guttate and small plaque eruption. All other areas were clear.

Treatment: Tab. Carbachol mgm. 3, daily, for 2 days.
mgm. 4, daily, for 2 days.
mgm. 6, daily, thereafter.

Result: Improved.

Case 175.

E. T. Age 53 Female

Family History The patient's sister also suffers from psoriasis.

Personal History The patient gave a history of having had Bronchitis and Rheumatism. Psoriasis began 4 months prior to examination.

On Examination (14 Apr. 48) There were four, circular, infiltrated plaques on the left forearm and one large, heavily crusted plaque on the left knee. All other areas were clear.

Treatment Tab. Carbachol mgm. 3, daily, for 2 days.
mgm. 4, daily, for 2 days.
mgm. 6, daily, thereafter.

Result Improved.

Case 176.

M. C. Age 19 Female

Family History Nil.

Personal History The patient has always been well. Psoriasis began 5 years prior to examination. It has never cleared since.

On Examination (21 Apr. 48) There were large, irregular plaques round the knees and the elbows covered by small, hard scales. There were also papules and small guttae scattered on the legs, from the buttocks down and on the arms below the elbows. There was a ring of raised, infiltrated tissue round the hair margin and the scalp was covered by a heavy scurf.

Treatment Tab. Carbachol mgm. 3, daily, for 2 days.
mgm. 4, daily, for 2 days.
mgm. 6, daily, thereafter.

Result All trace of the eruption had cleared by 15 Jun. 48, 2 months later.

Case 177.

N. R. Age 20 Female

Family History Nil.

Personal History The patient has always been well. Psoriasis began 8 years prior to examination. It has never cleared.

On Examination (26 Apr. 48) There was a generalised eruption. It was made up of finely scaling, erythematous guttae and small plaques. There was a large area of scaling erythema on the outer aspect of each thigh at the level of the great trochanter. The scalp was clear.

Treatment Tab. Carbachol mgm. 3, daily, for 2 days.
mgm. 4, daily, for 2 days.
mgm. 6, daily, thereafter.

Result Improved.

Case 178.

J. S. Age 23 Male

Family History Nil.

Personal History The patient gave a history of having had Pneumonia. Psoriasis began 4½ years prior to examination. On one occasion it cleared for 6 months.

On Examination (28 Apr. 48) There were large, elongated plaques on the forearms, infiltrated and covered by heavy scaling. On the trunk and legs there were nummular plaques with a few larger formations. The scalp was moderately affected.

Treatment Tab. Carbachol mgm. 3, daily, for 2 days.
mgm. 4, daily, for 2 days.
mgm. 6, daily, thereafter.

Result Improved.

Case 179.

R. D. M. Age 70 Male

Family History: Nil.

Personal History: The patient has always been well. Psoriasis began 8 years prior to examination. It has never cleared since.

On Examination (5 May 48): There were large, elongated, infiltrated, heavily scaling plaques round both elbows and extending down the forearms. One large, irregular plaque on each leg, between the knees and the ankles. There was another large plaque in the lumbo-sacral region.

Treatment: Tab. Carbachol mgm. 3, daily, for 2 days.
mgm. 4, daily, for 2 days.
mgm. 6, daily, thereafter.

Result: Improved

Case 180.

L. L. Age 36 Female

Family History: Nil.

Personal History: The patient has always been well. Psoriasis began 12 years prior to examination. It has never cleared.

On Examination (12 May 48): There was a large, irregular, infiltrated, heavily scaling plaque on the right shin and one round the left elbow. All other areas were clear.

Treatment: Tab. Carbachol mgm. 3, daily, for 2 days.
mgm. 4, daily, for 2 days.
mgm. 6, daily, thereafter.

Result: Improved.

Case 181.

E. A. M. Age 18 Female

Family History: Nil.

Personal History: The patient has always been well. Psoriasis began 8 years prior to examination. It has never cleared.

On Examination (27 May 48): There was an annular eruption on the back. The lesions were raised, erythematous and had small, yellowish scales. There were three small lesions between the breasts and on the arms there was a papular eruption. All other areas, including the scalp, were clear.

Treatment: Tab. Carbachol mgm. 3, daily, for 2 days.
mgm. 4, daily, for 2 days.
mgm. 6, daily, thereafter.

Result: Improved.

Case 182.

E. F. Age 15 Female

Family History: Nil.

Personal History: The patient has always been well. Psoriasis began 4 years prior to examination. It has never cleared since.

On Examination (31 May 48): Only the arms and the legs were affected. The eruption was made up of numerous guttate lesions and small nummular plaques. The lesions were heavily scaling and infiltrated.

Treatment: Tab. Carbachol mgm. 3, daily, for 2 days.
mgm. 4, daily, for 2 days.
mgm. 6, daily, thereafter.

Result: Improved.

Case 183.

M. G. Age 30 Female

Family History Nil.

Personal History The patient has always been well. Psoriasis began 14 years prior to examination. It has improved several times but has never quite cleared.

On Examination (31 May 48) On the legs there were scattered, nummular, erythematous, scaling plaques. At the elbows there were collections of small, finely scaling papules. All other areas were clear.

Treatment Tab. Carbachol mgm. 3, daily, for 2 days.
mgm. 4, daily, for 2 days.
mgm. 6, thereafter, daily.

Result Improved

Case 184.

J. McC. Age 19 Female

Family History The patient's mother also suffers from psoriasis.

Personal History The patient gave a history of having had Bronchitis and Rheumatic Fever. Psoriasis began 13 years prior to examination. It has never cleared.

On Examination (2 Jun. 48) There was a large, geographic plaque on both shins, infiltrated and covered by large, white, opaque scales. Round the elbows there were a few scaling papules.

Treatment Tab. Carbachol mgm. 3, daily, for 2 days.
mgm. 4, daily, for 2 days.
mgm. 6, daily, thereafter.

Result Improved.

Case 185.

T. R. Age 19 Male

Family History The patient's father also suffers from psoriasis.

Personal History The patient has always been well. Psoriasis began 4 months prior to examination.

On Examination (2 May 47) There was a widespread eruption affecting all areas of the body. The lesions varied from small papules to large, infiltrated plaques, dull red in colour and covered by fine scales. On the forehead and scalp there were numerous, scaling papules. Irritation was severe.

Treatment Inj. Carbachol mgm. 0.125, b.d., for 3 days.
mgm. 0.25 , b.d., thereafter.

Result Psoriasis unimproved before the onset of mild toxic symptoms at the end of 10 days.

Case 186.

J. M. W. Age 20 Male

Family History Nil.

Personal History The patient gave a history of having had Pneumonia. Psoriasis began 3 years prior to examination. It has never cleared.

On Examination (14 May 47) There were widely scattered, nummular plaques on the arms and legs and on the trunk. The lesions were infiltrated and covered by thick crusts. The scalp was clear.

Treatment Inj. Carbachol mgm. 0.125, b.d., for 3 days.
mgm. 0.25 , b.d., thereafter.

Result Psoriasis unimproved before the onset of mild toxic symptoms at the end of 10 days.
