# A HISTOLOGICAL STUDY
# OF THE KIDNEY IN SCARLATINA.

Thesis presented to the University of Glasgow for the Degree of Doctor of Medicine, by,

E. Seymour Chapman M.B. Ch.B.

October, 1905.

ProQuest Number: 27626667

All rights reserved

INFORMATION TO ALL USERS
The quality of this reproduction is dependent upon the quality of the copy submitted.

In the unlikely event that the author did not send a complete manuscript
and there are missing pages, these will be noted. Also, if material had to be removed,
a note will indicate the deletion.

ProQuest 27626667

Published by ProQuest LLC (2019). Copyright of the Dissertation is held by the Author.

All rights reserved.
This work is protected against unauthorized copying under Title 17, United States Code
Microform Edition © ProQuest LLC.

ProQuest LLC.
789 East Eisenhower Parkway
P.O. Box 1346
Ann Arbor, MI 48106 – 1346

It is proposed in the following pages to describe the pathological changes found in the kidneys of patients, dying during an attack of Scarlet Fever, and to discuss the association existing between the clinical and pathological conditions exhibited by such cases. For many years acute renal disease has been recognised as a frequent complication of Scarlet Fever and it has been fully demonstrated that the kidney is often seriously damaged in cases, not showing any symptoms of acute nephritis during life. But notwithstanding the compilation of a large amount of literature, resulting from the descriptions of these conditions, it would seem there are still some pathological alterations of the kidney, which have not been fully described and which have certainly not received their warrantable amount of attention. Also on reviewing this literature it is interesting to note the disagreement, which exists between various authors, as to the relative frequency and importance of these changes, and, although the renal pathology of Scarlet Fever has been studied by many observers, only a very few have made any attenpt to associate together the clinical and pathological features of the cases described. In the present observations the majority of the changes found have been already studied but a few pathological alterations will be described that have not been previously noted. The relative frequency and importance of some of these conditions, which have been found to differ from the results given by previous observers, will also be discussed, and the establishment of a closer association between the clinical and pathological features of the cases will be attempted.

The kidneys examined number twenty-nine, and were obtained from patients dying of Scarlet Fever in the City of Glasgow Fever Hospital Belvidere. The specimens for examination were in all cases obtained/

obtained as soon after death as possible. Alcohol was the fixing agent most frequently used but some of the specimens were placed in Formaldehyde and in a few instances Zenker's Fluid was tried. Except for the demonstration of fat, alcohol was found to be the most satisfactory fixing agent. The tissues were embedded in paraffin and the sections were cut with the Cambridge Rocker Microtome. A large variety of stains were made use of, the most satisfactory being Alum Haematoxylin and Eosin. Van Gieson was used for the demonstration of hyaline degeneration. Polychrome Methylene Blue with Orcein and Ehrlich's tri-acid were found to give a good differentiating stain for the plasma cells. A few specimens, fixed in Form-aldehyde, were cut on the freezing microtome with a view to showing the amount and character of the fatty degeneration and for this purpose Soudan III and Scharlach R. were the stains employed. The whole work, with the exception of the illustrations, was done in the laboratory of Belvidere Hospital while the micro-photographs were taken, with the kind assistance of Mr J. Hume Paterson, assistant bacteriologist, by myself at the Glasgow Sanitary Office.

The classification of the cases has been based originally upon their clinical features and it will subsequently be shown that the chief pathological changes correspond with these sections. They are divided into three groups. The first class includes cases, which during life showed unequivocal signs of acute nephritis. Under the second head are found cases of very severe Scarlet Fever proving fatal within six days, while in the last division are described severe cases, which survived for a period of a week or longer. In the two latter classes the cases did not show any signs or symptoms suggestive of acute nephritis.

In view of the large number of observations that have already

been/

been made upon this subject it has been considered advisable to write a short summary of the literature. Following this the pathological changes found,together with the clinical characteristics of the cases will be described under the three heads given above and,in conclusion, the clinical histories, the post mortem reports where possible and the individual pathological features of the cases will be enumerated. This last section is included chiefly for the purpose of reference amd, with a view to simplifying the classification used, a table of the cases will be given at the end of each class.

# Literature.

The renal pathology of Scarlet Fever has of recent years attracted considerable attention and has given rise to a large amount of literature. A short resume of the chief papers and works upon the subject will be given, the chronological order of publication being retained as far as possible.

It was not until some years after the discovery of Bright that any attempt was made to differentiate between the morbid changes found in cases of ordinary acute catarrhal nephritis and in those consequent upon Scarlet Fever. One of the aarliest cases, belonging to the latter class, to be recorded was that of Dr. Bristowe[1]. On examination of the kidney he found that the chief lesion was situated in the Malpighian bodies and consisted of an exudation lying between the capsule and the glomerulus and giving rise to pressure upon the capillary tuft. Klebs[2] in 1869 was the first observer to describe and figure a condition in which there was a great increase in the number of nuclei in the glomerulus, and he considered that these cells were in all probability the result of proliferation of the capillary endothelium and that by their presence in the glomerular capsule the pressure upon the capillary tuft was increased and so the circulation through the Malpighian corpuscle was obstructed. Since then many pathologists have noted the same condition but there has been some diversity of opinion as to the origin of these cells. Rindfleisch[3] described these cells and consideredthat they were situated between the capillary vessels and were derived from the connective tissue. Kelsh and Keiner[4] considered that they were endothelial in origin while Cornil and Brault[5] concluded that they had the characters of connective tissue cells. Langhans[6] in 1885 described the same appearances more minutely and gave it/

it as his opinion that these cells, which he considered to be situated in the glomerular capillaries, were derived from the capillary endothelium. Welch[7] studied a similar condition, produced by cantharidin poisoning, in rabbits and mice and considered that the cells were leucocytes. He also noted the same increase of cells in human nephritis and especially in cases occuring during Scarlet Fever, and in these cases he agreed with Klebs and Langhans in ascribing their origin to proliferation of the capillary endothelium. This observer also demonstrated that many of the capsular spaces frequently contained masses of free granular matter and he showed that this material could originate from the degenerating cells situated at the commencement of the tubules. Ribbert[8] looked upon this accumulation of cells in the glomerular capillaries as a thrombus of white blood corpuscles and Councilman[9] in 1897 gave a very minute description of these cells. He considered that they were derived from the glomerular endothelium and pointed out that they could be quite easily distinguished both by their staining reaction and minute anatomy from the leucocytes, which in many cases were found lying among them, and also from the cells forming the epithelial covering of the glomerular tuft,

In 1875 Klein[10] published his paper "On the minute Anatomy of Scarlet Fever" in the Report of the Medical Officer of the Privy Council and two years later the same paper, synopsised, appeared in the Transactions of the Pathological Society of London.[11] In this paper he described the results of twenty three post-mortems upon patients dying during an attack of Scarlet Fever. The day of death varied from the second to the forty-fourth and, in his considerations of the pathological changes found in the kidneys, he divided the cases into two classes, namely those dying within the first week and those dying later during the course of the fever. In the first division he noted three chief changes:-

1. Increase of nuclei covering the glomerulus.
2. Hyaline degeneration in the minute arteries and especially in the afferent arterioles.
3. Multiplication of the nuclei in the muscular coat of small arteries and increase in the thickness of the vessel wall.

As regards the first change he did not find the increase in the cells of the glomerulus to be so marked a feature as Klebs described and he considered that the obstruction of the circulation through the Malpighian corpuscle depended more upon the hyaline change and muscular hypertrophy of the vessel wall than upon the pressure caused by the increased number of cells within the glomerular capsule. He noted that the hyaline degeneration was in the early stages limited to the interior of the vessel and only in the later cases did it affect the endothelium. He also observed that the capillaries of the glomeruli were implicated in this hyaline degeneration and that in some of the cases of longest standing the hyaline matter was replaced by fibrous masses. The multiplication of muscle nuclei was seen to be most conspicuous in the arterioles just at their entrance into the Malpighian corpuscles. He also found masses of granular material and blood in the capsular spaces. Parenchymatous changes were not very marked in the early cases and when present consisted of cloudy swelling of the epithelium in the convoluted tubules,"germination of nuclei" most marked in the ascending loop of Henle and some loss of cells in the collecting tubules.

In the second division the most marked change found was an infiltration of the interstitial tissue with small round cells, which he considered were in all probability lymphoid in origin. This infiltration appeared at first around the interlobular arteries and so was limited to the intermedullary rays. Subsequently it spread into the medullary rays and in some cases became converted into "a whitish, firm, bloodless/

less, cellular mass, in which the Malpighian Corpuscles and urinary tubules cannot be more than imperfectly recognised, having become more or less degenerated."

A case, showing this same infiltration of small cells, was described by Coats[12] about the same time. He considered that the cells were leucocytes and thought that their presence in the interstitial tissue in such large numbers was evidence of a septic process, originating in all probability in the ulcerated condition of the throat.

Kelsh[13] reported two similar cases in both of which there was a diffuse interstial infiltration together with some exudation around and degeneration of the Malpighian corpuscles, the latter change in his opinion being secondary to the interstitial change.

Thomas[14] also observed this interstitial infiltration and gave the following description "circumscribed inflammatory masses are found diffused throughout the stroma or only at certain points of the same, resembling abscesses and composed of small round cells". He also described a catarrhal condition, which occurred early in the course of the disease and was characterized by a disturbance of the epithelial elements of the medullary substance, whereby they were thrown off in large numbers and washed away.

Dickenson[15] noted the fact that it was possible to have a considerable variety in the pathological conditions of the tubules without any marked disturbance of the renal function. He considered that the chief changes in Scarlet Fever were situated in the tubules and consisted of the choking up of their interiors by epithelium. With the exception of some dilatation of the capsules he found that the Malpighian corpuscles were normal.

The importance of the pathological changes connected with Bowman's capsule was first fully recognized by Greenfield[16.17.] in 1875.

He emphasized the fact that proliferation of the cells of Bowman's Capsule with consequent adhesion between the endothelium lining the capsule and the endothelial covering of the glomerular capillaries resulted in a complete cessation of the important function of the Malpighian corpuscle and thus prevented the excretion of fluid and salts, and further that, owing to the obstruction of the circulation through the Malpighian capillaries, there was produced a local anaemia of the corresponding convoluted tubules and loops of Henle, which caused a diminution in the amount of nitrogenous matter eliminated from the blood through these structures. He also demonstrated that Bowman's capsule might be thickened in three ways, (1) by cell growth internal to the capsule, (2) by a pericapsular growth of cells and, (3) by hyaline swelling of the capsule itself. The first process he considered to be the commonest form, the cells being derived either from the endothelium of the capsule, from migrated leucocytes or from the endothelial covering of the capillary tuft. In the second case he thought that the cells were either migrated leucocytes or owed their origin to the proliferation of the connective tissue cells situated around the glomerulus and afferent arterioles. In addition to these glomerular changes he described an acute interstitial change, consisting of an infiltration of small cells into the interstitial tissue, combined with various degrees of epithelial degeneration.

Friedlander[18] made a distinction between those cases of nephritis occurring early in the course of the disease and those, which apparently commenced after the end of the second week. He considered that the commencement of the kidney changes in the former class coincided with the appearance of the exanthem and that they were only temporary and were later on replaced by the conditions found in the latter class. The most characteristic features of the first class were found to/

to be moderate hyperaemia with slight cloudy swelling of the epithelium in the convoluted tubules together with marked local proliferation and later a desquamation of the epithelial cells in the convoluted and collecting tubules. As a rule the glomerular vessels were found to be normal and any thickening of the capsule was very slight. Occasionally there was a deposit of albuminous matter between the capsule and the glomerulus, and hyaline and granular casts were rarely present in the convoluted and straight tubules. The most marked changes found in the later cases were situated in the Malpighian corpuscles and consisted of great degeneration of all the elements so that the original structure of the corpuscle could only be made out with difficulty, the entire picture consisting of a finely granular material, in which here and there fat globules and many polymorphonucleated leucocytes were seen. Only occasionally was there any marked proliferation of the capsular epithelium, and infiltration of the interstitial tissue with small cells, which, when present, were most marked around the larger branches of the vessels and were always localized, was extremely rare.

A complicated case of Scarlet Fever and Diphtheria, in which the kidney was found to be enlarged and flabby and on microscopical examination showed considerable infiltration of the interstitial tissue was classified by him as an Interstitial Septic Nephritis.

Wagner[19] has never seen the condition described by Klebs. He considered that the large white kidney of Bright was most often found in cases consequent upon Scarlet Fever and might occur either early or late in the course of the disease. Un-der the name of lymphomatous nephritis he described an infiltration of the kidney substances with small cells. He thought that this condition was rare and was generally of a septic origin. He further pointed out that it was most marked around some of the Malpighian corpuscles and that these in consequence showed signs of being compressed while other corpuscles, not similarly affected, showed a compensatory enlargement.

Crooke[20] found that this condition of infiltration was of common occurrence and was most evident in cases dying late in the course of the disease.

The question of the origin and nature of these infiltrating cells has lately been studied by Councilman[9.21.] of Boston. In a paper published in 1897 after giving an account of their appearances he gave it as his opinion that they were derived by proliferation of the fixed cells of the tissues, particularly from the endothelium of the blood-vessels. In the following year however he altered his opinion and then put forward the theory that they were mono-nucleated leucocytes, which had emigrated from the blood and were seen in the various stages of becoming converted into fixed cells, and under these circumstances he called them Plasma cells. This theory of their origin he based upon numerous observations both as regards their staining properties and their minute structure. With most nuclear stains used singly he found that the protoplasm was stained faintly but more intensely than the protoplasm of epithelial cells and also that with strongly alkaline methylene-blue the protoplasm stained deeply and retained the colour even after counter-staining with Eosin whereas the protoplasm of a cell of epithelial origin would become lilac in colour after this treatment. The fact that they were never found in the tubules and were constantly present in the blood vessels he considered as important in showing that they originated from the blood. He described them as varying much in size and shape but always being larger than a polymorphonucleated leucocyte, as having an eccentrically placed nucleus, which stained deeply and especially so at the periphery and which contained an intra-nuclear net-work of fine lines connecting deeply staining/

staining points. Some of the cells contained more than one nucleus and mitotic figures were often seen. They never showed any phagocytic characters themselves but were sometimes seen in the interior of desquamated epithelial cells surrounded by a clear Zone as if undergoing digestion. In addition to these plasma cells there were seen in the infiltrated areas three other classes of cells, namely desquamated epithelial cells, polymorpho-nucleated leucocytes and lymphocytes.

One of the latest monographs on the kidney is by Hoche[22] and this observer divides the lesions consequent upon Scarlet Fever into Two Classes, namely those that rapidly proved fatal and those of a longer duration. In the first class he found that the glomerular capillaries were dilated, that there was emigration of leucocytes through these structures, desquamation and proliferation of the cells in Bowman's capsule and albuminous and haemorrhagic exudates in the capsular spaces. He also observed that some of the tubular cells were swollen and granular and sometimes contained two nuclei. The tubules contained hyaline and colloid casts and there was frequently an interstitial oedema. In the cases of longer duration he found an increase in the number of nuclei in the glomeruli together with some obliteration of the glomerular capillary structure. There was also seen some proliferation of the capsular endothelium and some infiltration of leucocytes around the glomeruli. The cells of the tubules were found to be granular and in some instances desquamation and proliferation had taken place.

# Personal Observations.

The chief clinical features and pathological alterations found in the present specimens will now be described under the heads already mentioned.

The cases of Class I. number eight and during life shewed signs and symptoms of acute nephritis, and this complication was in every case the cause of death. Class II. contains ten cases of Scarlet Fever, which with three exceptioms proved fatal within six days. Under Class III. are discussed eleven cases, all of which survived for a longer period than six days. Although the pathological changes correspond in the main with this classification there are a few cases, which do not show all the characteristic features generally found under these heads and any exceptions will be noted at the end of each section.

## OBSERVATIONS UPON THE CASES OF CLASS I.

The cases of this class all presented the characteristic clinical features associated with acute nephritis occurring as a complication of Scarlet Fever. Five of the cases were admitted to hospital after the onset of the nephritis and died within two days of admission and within four days of the onset of any noticeable symptoms. These patients exhibited considerable oedema of the lax tissues and in every case was there fluid in the pleural sacs while in two there was marked ascites. Of these five cases only in two was the temperature febrile. The remaining three cases were admitted during the acute stage of the fever and developed acute nephritis while in hospital. Case No. 6 first shewed symptoms of nephritis about a month after the onset of the initial illness and cases No. 7 and 8 developed the disease on the 59th and 27th days of illness respectively. The onset of the nephritis in these three cases was sudden, the symptoms being headache, sickness and vomiting, elevation of temperature and subsequently oedema of the superficial tissues and lungs. Case No. 6 died on the 67th day of illness, that is, eight days after the onset of the nephritis while Case No. 7 lived forty-six days after the commencement of the nephritis, and died on the 73rd day from the onset of the fever.

The urine was obtained in all but two cases and in every instance it was scanty, high coloured and smoky in appearance and contained large quantities of albumen and some blood. Microscopically many casts were found, the granular variety being the most numerous while hyaline and epithelial casts were not so frequent. In two cases casts composed of red blood corpuscles were met with and in all the cases the sediment contained many blood cells mixed with a large quantity of epithelial detritus.

## PATHOLOGICAL ALTERATIONS OBSERVED IN THE KIDNEY.

With the exception of Case No. 8 the macroscopical appearances of the kidneys were consistent with acute nephritis. They were enlarged with non-adherent capsules. The pyramids were much congested and the cortices were swollen, pale in appearance and had lost much of their normal markings. In case No. 8, however, the conditions were more compatible with a sub-acute form of nephritis, the cortex being diminished in size and showing many small areas of fatty degeneration.

The most important alterations, however, are found upon microscopical examination. These changes affect both the Malpighian corpuscles and the tubular structures.

### Malpighian Corpuscles.

The most marked pathological changes are found in connection with the Malpighian corpuscles. These structures under normal conditions consist of a spherical mass of capillaries, which is surrounded by a double capsule. The space between this double capsule is known as the capsular/

capsular space and forms the commencement of a convoluted tubule. In a few instances the sections are so cut as to show the convoluted tubule commencing from this space. In the normal kidney this space is unoccupied except by urine. The two layers of the capsule are continuous with one another but the epithelia of which they are composed, is said to be of a different structure and origin in each (Herring[23]), the epithelium of the outer or Bowman's capsule being mesoblastic in origin, while that of the inner capsule is derived from the epiblast and is a much more highly specialised tissue. The origin and structure of these capsules is of importance from the pathological point of as will afterwards be shown. Bowman's capsule is composed of a fairly thick basement membrane, which is lined on its inner side by a single layer of clear flattened epithelium while the covering nearest to the glomerular tuft is formed of clear cubical epithelial cells without any visible basement membrane. This latter capsule is most evident in the embryo and in the adult kidney has to a large extent disappeared. It is in close apposition to the glomerular tuft and dips down between the lobes into which the tuft is normally divided.

The capillaries forming the glomerular tuft are held together by a very small amount of connective tissue. They derive their blood from the afferent arteries, which are branches from the interlobular arteries. These latter vessels arise from the arterial branches, situated between the cortical and medullary portions of the kidney and ascend through the cortex in the intermedullary spaces. The efferent glomerular vessel leaves the Malpighian corpuscle at the same place as the afferent vessel entered and immediately breaks up into a number of capillaries, which surround the tubule arising from that particular Malpighiam corpuscle, and thus the blood supply of the convoluted/

convoluted tubules is largely dependent upon the condition of the glomerular capillaries. The efferent vessels of some of the deepest placed glomeruli, however, break up into smaller straight veins, which pass directly downwards into the boundary zone and there supply the continuation downwards of the medullary rays into the pyramids.

The pathological alterations can now be described. Under the low power the Malpighian corpuscles stand out prominently and the glomeruli occupy nearly the whole space within Bowman's capsule. As already stated, a certain amount of lobulation of the glomerular capillaries is found in the normal kidney and many observers consider that this feature is increased, especially in the more chronic cases of Scarlatinal nephritis, but this has not been found to be the case in the present specimens.

Proliferation of the epithelium of Bowman's capsule occurs in some sections and constitutes one of the most important pathological changes found. This proliferation is, in the first instance, local, and appears to commence on the side furthest away from the entrance of the afferent artery and only in the later stages does it extend round the whole circumference of the capsule. The nuclei of the normal capsule are oblong in shape and stain deeply with the ordinary nuclear dyes. At first the newly formed cells are rounder in shape than those, from which they have originated,and it is not apparently until after they have been subjected to some pressure that they assume a more elongated and flattened appearance. In the early stages the divisions between the various cells can be distinguished but these are lost with the increase in the number of cells. This process of proliferation gradually extends round the circumference of the capsule, although it is always most evident at the site at which it started, and gradually/

ually the capsular space is filled up with newly formed cells and a junction effected between the capsule and the glomerular tuft of capillaries. Prior to this union, however, the cells have commenced to alter in appearance and have assumed a more flattened shape, the nuclei having become compressed laterally and all division between the cells being entirely lost. As this increase of cells continues, the glomerular capillaries are more and more subjected to pressure and in advanced cases the greater part of the space inside the capsule of Bowman is occupied by flattened epithelial cells, in the centre of which is seen a small tuft of compressed capillaries. This extreme degree of degeneration is, however, very rarely seen except in case No. 8 where it is of common occurrence.

In only one case reported, namely No. 8, and in this one there was a history of nephritis extending over a period of 50 days, is there any further change to be noted as regards these cells. In this case there has been a replacement of the proliferated cells by fibrous tissue. The nuclei become further flattened and elongated and the protoplasm of the cells loses its granular appearance and assumes a more striated form, and in a few instances this process has entended so far that only a very small amount of the original glomerular capillary tissue is left, the whole glomerular space being occupied by dense fibrous tissue. A detailed description of this condition has not been given here however, as it only occurred in one case, but it is to be found on page 84.

A condition of Bowman's capsule, less frequently met with, is slight hyaline swelling of the basement membrane without any proliferation of the lining epithelium. This change is entirely limited to the basement membrane, which becomes slightly increased in width and/

and of a more translucent homogenous appearance while the lining epithelium is seen in an apparently normal condition. The thickening is equal in all parts of the circumference and stains characteristically with Van Gieson's stain.

In two cases, namely No. 7 and 8 there is some leucocytic infiltration of the tissues immediately surrounding the Malpighian corpuscles and some increase in the amount of connective tissue at this part while in the latter case there is marked fibrosis throughout the section, which causes considerable separation of the tubules from one another.

Some of the capsular spaces contain small quantities of debris. This material, which is highly granular and generally free from nuclei, is seen lying loose in small masses and stains in the same way as the protoplasm of the tubular cells. In a few instances the section is so cut as to show that this debris is derived from the commencement of the convoluted tubule, the cells of which have become much degenerated and pushed up into the capsular space, and occasionally a tubular cell, which is only slightly degenerated, is seen lying free in the space. This condition occurs, however, in cases showing very slight degeneration of the tubular epithelium and under these circumstances the debris is in all probability derived from the coagulation of the serum-albumen, which has transuded through the walls of the glomerular capillaries. No appearances suggestive of the formation of fibrin in this situation are seen.

On account of the development of the epithelial covering of the glomerular tuft it would seem probable that this epithelium would take an important part in any pathological changes connected with the glomerulus, but this is not found to be the case. In a few glomeruli in kidneys obtained from young subjects it is still quite evident and especially/

especially so in glomeruli situated in the extreme cortex, and, although in most sections nuclei can be distinguished as belonging to this capsule, they are never seen to be in a state of proliferation or to be taking any active part in the pathological change in process.

The pathological changes in the circulatory system of the kidney are also well marked. Some of the afferent arteries are dilated and contain numerous blood cells and a few exhibit a slight degree of hyaline degeneration. This change is, however, more constant in the cases of class II and will be discussed in detail subsequently.

The changes found in the glomerular capillaries are very prominent and constant. They consist of an increase in the number of nuclei and of an obscuration of the capillary structure. The increase in the number of nuclei has been studied by a number of observers and their various opinions as to the origin of the cells have already been enumerated. The consensus of opinion, as expressed in recent literature, appears to be that they are mainly derived by proliferation of the capillary endothelium and this has been found to be the case in the present work, although many leucocytes, both of the polymorphonucleated and lymphoid variety are seen. The polymorpho-nucleated leucocyte can be easily distinguished by its nuclear form, and the lymphocyte by its deeply staining and dense nucleus, and both cells are usually found in the glomerular capillaries, the former variety being the most numerous. Regarding the origin of this increase in the number of nuclei in the glomerular capillaries, it is to be noted that in the foetal state there is a considerable amount of connective tissue throughout the kidney and one of the situations, in which it is abundant, is at the bases of the glomerulus, but with advancing age this tissue largely disappears and, although there is still a small amount present/

present in the fully developed kidney, any proliferation of it can only be a minor factor in the production of this increase of cells. The newly formed cells are situated inside the capillaries and, in cases where they are not very numerous and where degeneration of the capillaries has not become very marked, their out-line can be distinguished. In other cases, however, and these form a considerable majority, no division can be seen between the various cells or between the cells and the capillary wall and under these conditions the picture, that is presented, consists of a mass of protoplasm, in which are embedded numerous nuclei. The nuclei of these cells are mostly oval in shape although a few of them assume irregular forms. They appear to be granular and stain well, but not so deeply as the lymphocytes. The staining is most marked in the periphery and throughout the body many chromatin granules are visible. No evidence of mitotic or amitotic division has been seen.

The obscuration of the capillary structure is dependent upon various factors apart from the presence of the newly formed cells. Many of the capillary walls are swollen and this swelling in the majority of the cases takes on the characteristic hyaline stain with Van Gieson and has a homogenous translucent appearance. It is not distributed equally around the calibre of the vessels but is seen as a small spindle shaped unilateral mass projecting into the lumen of the capillary. In the interior of other capillaries small hyaline masses are seen lying free or at least in apposition to the vessel wall on one side only. These masses are to be regarded as hyaline thrombi. The explanation of their origin has been given by Von Recklinghausen[24], who considers that they originate by the transformation of coagulated white blood corpuscles into hyaline matter and although no evidence of/

of this has been observed in the specimens examined, it would seem to be the probable solution. Some of the capillary vessels contain masses of granular material, partly lying free and partly adherent to the vessel wall, and these are in all probability derived from degeneration of the cells of the capillary endothelium. In cases in which there is very marked obscuration of the capillary structure nothing definite can be made out, portions of the glomerulus appearing as a solid mass, granular in appearance and studded with nuclei and nuclear detritus. This extreme degree of degeneration, which is practically a necrosis of the capillaries, is rarely found and when present generally only affects a part of the glomerulus.

In some sections, and notably in these in which a congested condition of the blood vessels is seen and in which there is some dilatation of the afferent arteries, the capillaries have ruptured and have so given rise to abnormally large blood-containing spaces. It is to be noted, however, that as a rule very few red cells are to be seen in thecapillaries and no example of haemorrhage into the glomerular space as figured by Coats[25] has been found. This fact is of interest when it is considered that the external loops of the capillaries are to a large extent unsupported and so offer the line of least resistance to the increased blood pressure. Under these circumstances it would have been expected that they would have been the first to rupture, whereas, in the present specimens, this is found not to be the case. A possible explanation of the phenomenon is that as the kidneys were obtained from young subjects the epithelial covering of the capillary tuft would be still fairly well developed and would so support the outlying loops. This solution, however, presupposes the presence of a basement membrane in this epithelial capsule, which up to the present has not been demonstrated.

In a few instances a very slight amount of fatty degeneration is seen in the cells lining Bowman-s capsule, while the glomerular tuft is entirely free from this form of degeneration.

As regards the frequency of these changes in the Malpighian corpuscles it is found that the increase in the number of nuclei is present and that the glomerular capillary structure is more or less obscured in every case. There is capsular proliferation in five cases, while it is absent in No. 3, 6, and 7 and there is thickening of the capsule apart from proliferation in four cases, namely, Nos. 2, 4, 7 and 8. Hyaline degeneration in a slight degree occurs in all the cases and dilatation of the afferent vessels is seen in Nos 1, 2, 3, 5, and 6. Complete destruction of the glomerular capillaries is found in cases Nos 1, 2, 4, 6, and 8. In conclusion it is to be noted that these various changes are found in the Malpighian corpuscles irrespective of whether they are situated in the deep or superficial portion of the cortex.

These alterations in the Malpighian corpuscles are collectively known as glomerular nephritis and constitute the most important pathological conditions found in cases of Scarlatinal nephritis. Most of them if sufficiently advanced will compromise the functional activity of the Malpighian corpuscles. For by proliferation of the capsular epithelium the space into which the watery constituents of the urine are excreted is at first encroached upon and eventually obliterated while the partial or complete occlusion of the glomerular vessels by thrombi, hyaline swelling etc., prevents the circulation of the blood through the Malpighian corpuscles, either of which conditions will give rise to symptoms of urinary suppression. Also it is to be noted that in none of these cases was there any blood found in the capsular/

capsular spaces although, clinically, they all showed a marked degree of haematuria, and it will be subsequently shown that this symptom is dependent upon haemorrhage taking place into the tubules.

## TUBULES.

Prior to describing the pathological phenomena found associated with the tubules, it will be perhaps advisable to enumerate the varieties of tubules and to point out briefly the differences exhibited by their various epithelium in the normal state. Adopting the nomenclature of Schafer and Symington[26] each tubule is found to commence in a spherical dilatation, surrounding a glomerular capillary tuft. Extending from this it ramifies in a series of convolutions through the cortex thus forming the first convoluted tubule. The cells in this portion are granular in appearance with a spherical nucleus, which stains well with the ordinary nuclear dyes, the staining being most marked around the periphery and in numerous chromatin granules throughout its body. The portion of the cell next to the basement membrane is said to be made up of a series of rods or fibrils, placed vertically to the membrane, but around the nucleus and towards the lumen the protoplasm is granular and does not show any rod-formation. On approaching the medullary ray the tubule becomes nearly straight with a slight tendency to a spiral, thus forming the spiral tube of Schachowa and in this section the epithelium is like that of the former tubule excepting that its free border is broken up into numerous ridges. Passing through the medullary ray the tubule enters the medulla of the kidney and forms the descending limb of Henle, this portion being the narrowest variety of urinary tubule. Here the epithelium/

helium is quite low and flattened against the basement membrane, the protoplasm is clear and the nuclei are prominent. The same variety of epithelium is found in the loop of Henle. From this point it ascends again through the medulla and medullary ray, forming the ascending tubule of Henle. In the ascending limb the epithelium takes on the same characters as that found in the convoluted tubules but the cells are rather smaller with nuclei that stain more deeply, the lumen of the tubule is relatively larger and the rod-formation is not so fully developed. The ascending loop of Henle passes into a short section known as the irregular tube, which is said to lack a basement membrane and the cells of which are granular in appearance and unequal in size. Following this it becomes the second convoluted tubule, the cells exhibiting the same character as formerly, excepting that they are somewhat longer. The second convoluted tubule terminates in a junctional tube, which uniting with another junctional tube forms a collecting tubule and this again coalescing with a similar structure forms a duct of Bellini. The epithelium is the same throughout these latter structures, the cells being cubical in shape and having clear protoplasm with a round nucleus. It is of interest to notice the similarity in structure existing between the cells of the convoluted tubule and those of the ascending loop of Henle and that those structures perform similar functions has been proved by Heidenhain[27]. Both these considerations are of importance as it will be afterwards shown that the cells of each tubule undergo much the same pathological alterations

The morbid changes, which affect the different parts of the urinary tubules will now be described. Most of the cells in the first and second convoluted tubules show granular degeneration of varying degrees. The protoplasm takes on a more granular appearance with loss of all evidence of any rod formation and the divisions between the/

the cells, whenever this is at all marked is entirely lost. With high magnification the protoplasm is seen to be most granular and dense in that part of the cell adjoining the lumen of the tubule. In cells showing only a slight degree of the degeneration the lumen of the tube is not encroached upon and the nuclei seem to stain more deeply than normal. In more advanced cases, however, the cells are swollen and project into the interior of the lumen and the nuclear structure is partly obscured. In a few cases there is some disintergration of the peripheral protoplasm of the cells. Many of the tubules contain small masses of granular material, which stain in the same way as the cell protoplasm and these are undoubtedly derived from this disintegration of the cellular protoplasm. There is very rarely any separation of complete cells from the basement membrane and there is no evidence of any increase in the number of nuclei in these tubules. A few of the convoluted tubules together with some of the spiral tubes and ascending limbs of Henle exhibit cells, which have undergone hyaline degeneration. In these cells the protoplasm is broken up into small round globules, which appear to be distinct from one another. These globules are highly refractive, homogenous in appearance and in the majority of cases, stain characteristically with Eosin and Van Gieson. This latter condition is nearly always associated with complete loss of nuclear staining.

The cells of the ascending loop of Henle show the same granular degeneration and in addition they exhibit a considerable tendency to become separated from the basement membrane. In the medulla this separation takes place en masse, the cells being separated from the basement membrane all round and lying gathered together in the centre, thus partly or completely blocking up the lumen of the tubule. In the cortical portion the cells as well as being separated from the basement membrane/

membrane are separated from one another and are seen lying free in the tubule cavity. The cells of the irregular tubules show the same changes while those of the collecting tubules appear to be normal.

In sections stained with a view to demonstrating fatty degeneration, it is seen that the cells of the ascending loops of Henle and the convoluted tubules are the ones affected. The fat is in the form of minute globules, which appear to be distributed equally throughout the cells. The distribution is regular throughout the section but this form of degeneration is not very marked.

In some sections the tubules are separated from one another more than usual, the intervening spaces being occupied by dilated capillaries, swollen connective tissue or by an increase in the amount of the intertubular tissue. The last condition is only found in case No. 8 where it is very marked and where it forms part of the pathological condition associated with the sub-acute nephritis. This separation of the tubules is most frequently found and is always most marked in the cortex and there between the convoluted tubules. In most cases it is apparently due to a dilated condition of the intertubular vessels, which are filled with blood cells but in other cases the walls of the capillaries are seen to be normally placed and the small amount of connective tissue, which normally exists between the tubules, is much swollen and oedematous, the nuclei of the connective tissue cells being separated from one another but not increased in number. The former condition is associated with marked congestion of all the blood vessels, while the latter condition is a true oedema of the intertubular connective tissue. In specimens showing this separation in a marked degree it is found that the cells of the tubules and especially those of the convoluted tubules are flattened as if there had been/

been an increase of the normal pressure inside these structures as well as externally, a condition which suggests a higher osmotic tension on the part of the transuded fluid than the kidney cells themselves possess. This compression of the tubular cells together with separation of the tubules is frequently associated with a dilatation of Bowman's capsules. There is no difficulty in distinguishing the above described appearance from a somewhat similar condition occasionally seen and frequently due to faulty technique, producing a separation of the cells en masse from their basement membranes. No relation between this separation of the tubules and the degree of oedema present during life is evident.

Some of the tubules are filled with red blood cells. This is most frequently found in the junctional and collecting tubules but is also present to a less marked degree in the convoluted tubules and ascending loop of Henle. In many instances the red corpuscles are quite distinct, in other cases the blood has undergone coagulation with consequent diminution in the distinct~~ive~~ness of their outline. This blood in the tubules originates by direct haemorrhage from the intertubular vessels into the tubules and is not the result of bleeding into the capsular spaces of the Malpighian corpuscles, where, as already stated, blood cells are never found. This tubular haemorrhage is most probably the cause of the haematuria, which was so marked a symptom in these cases.

As has been already noted many of the convoluted tubules contain masses of granular material, which have originated from the disintegration of the epithelial cells lining the tubules, and in some cases blood corpuscles. In addition to these there are seen in some tubules masses of pale staining hyaline material, many poly-morphonucleated and a few lymphoid leucocytes and, when there has been

hyaline/

hyaline degeneration of the epithelial cells, small globules of hyaline protoplasm are also seen lying free in the lumen of the tubule. It is from these materials that tube-casts are formed. In considering the formation of tube casts it is necessary to bear in mind the small calibre of the descending lopp of Henle as compared with the size of the lumen of the convoluted tubules, for a cast having its origin in and completely filling a convoluted tubule would be unable to pass through the descending limb of Henle without undergoing considerable diminution in size. In the sections examined the most common situation for tube-casts is found to be the smaller junctional tubules and here they are seen in many varieties. In the larger collecting tubes of the medulla they are entirely absent, a fact difficult of explanation unless it be due to their being more easily displaced in this situation and having become so during the process of the preparation of the section. In case No. 8 (the sub-acute nephritis) the casts most frequently found are hyaline in character and are of large dimensions nearly completely filling the much dilated junctional tubules. They appear as masses of homogenous material and in most cases give the characteristic hyaline stains. In the remaining cases many hyaline casts are seen but they are always much smaller. The majority of these hyaline casts stain faintly with Eosin and Van Gieson and are not composed of true hyaline matter. They are not derived from the hyaline protoplasm of the epithelial cells but originate from the albuminous coagulate, which has transuded through the damaged tubular epithelium from the blood. They correspond with the hyaline casts found in the urine and frequently form the basis of epithelial casts. True hyaline casts are more rarely seen. They occur in specimens in which there is marked hyaline degeneration of the tubular epithelium and their manner of formation can occasionally be seen. The hyaline globules

lying/

lying free in the tubal cavity become joined together and compressed into the shape of the tubule and thus the tube cast is formed. Casts, having a granular appearance and staining like the protoplasm of the cells in the convoluted tubules, together with casts formed almost entirely of red blood corpuscle are also found, and in a few junctional tubes epithelial casts in process of formation are seen. In the latter pale hyaline material together with small masses of granular matter, in which are embedded numerous epithelial cells and leucocytes, are found, and it is by the coalescence of these masses that epithelial casts are formed. As regards the origin of the epithelial portion of these casts, it is important to remember that the cells of the convoluted tubules rarely become separated from their basement membrane while those of the ascending loop of Henle very frequently do and so in all probability the epithelial element of these casts is derived from the latter structures. From the appearances just enumerated and considering the peculiarities in structure of the different parts of the urinary trubules it is probable that all tube casts, which reach the urine, are formed in the smaller junctional tubes, and further that the granular material of these casts is mostly derived from the disintergrated cells of the convoluted tubules while the epithelial portion as already stated originates from the ascending loop of Henle. In conclusion it is to be stated that no casts having a fibrous structure are seen.

These degenerative changes in the tubules are largely dependent upon the circulatory obstruction through the Malpighian corpuscles. As regards their frequency, it is found that separation of the tubules is present in five cases and that the tubules are dilated in three, this being especially marked in case No. 2. Granular degeneration is present in every case and all the specimens show granular debris in the/

the tubules. Desquamation of the cells and disintegration of the cellular protoplasm are comparatively rare and granular and hyaline casts are generally present while epithelial casts are most numerous in case No. 7.

## TABLE OF CASES IN CLASS I.

| No. of Case. | Day of illness on admission. | Day of Death. | Duration of Nephritis. | Urine. | Oedema of tissues, | Fluid in serous sacs. | PATHOLOGICAL CHANGES IN THE KIDNEY. |
|---|---|---|---|---|---|---|---|
| 1. H.W. | ? | ? | ? | Much Albumen<br>Blood<br>Many Casts. | Marked. | Pleuritic effusion. | Capsular proliferation. Increase of Nuclei. Capsular debris. Destruction of capillary structure. Hyaline degeneration of capillaries. Granular and Hyaline degenerations of tubular cells. Granular and Hyaline tube casts. |
| 2. J.L. | 14? | ? | ? | No urine passed. | None. | Pleuritic effusion. ascites. | Capsular proliferation and thickening. Increase of nuclei. Dilatation of afferent vessels. Hyaline degeneration of capillaries. Rupture of capillaries, Capsular debris. Granular and hyaline degeneration of tubular cells. Granular hyaline and epithelial casts. Some separation of the tubules. |
| 3. B.T. | ? | ? | ? | Much albumen<br>blood.<br>Many Casts. | present | Pleuritic effusion. | Very slight capsular debris, No Capsular proliferation or thickening. Increase of nuclei. Dilatation of afferent vessels. Slight hyaline degeneration of capillaries. Granular degeneration of tubular cells. |
| 4. A.A. | ? | ? | 5? | No urine passed. | Marked | Pleuritic effusion. ascites. | Slight capsular proliferation. Increase of nuclei. Slight hyaline degeneration of afferent vessels and capillaries. Slight granular degeneration in the tubules. Granular and hyaline casts. |
| 5. G.G. | 19th | 20th | ? | Albumen blood | Marked | Pleuritic effusion. | Slight capsular proliferation. Increase of nuclei. Small quantity of epithelial debris. Necrosis of glomerular capillaries. Hyaline degeneration of capillaries. Hyaline thrombi in capillaries. Slight separation of the tubules. Granular degeneration of tubular cells. Granular hyaline and epithelial casts. |
| 6. J.S. | 11th | 36th | 11 | Albumen blood<br>numerous casts. | ? | Pleuritic effusion. | No capsular proliferation. Increase of nuclei. Peri-glomerular leucocytic infiltration. Granular and hyaline degeneration in tubules. Many granular and hyaline casts. |
| 7. A.W. | 2nd | 43rd | ? | Much albumen<br>blood<br>many casts. | Present | Pleuritic effusion. | No capsular proliferation. Marked capsular thickening. Increase of nuclei. Slight peri-glomerular infiltration of leucocytes. Hyaline degeneration of afferent vessels and capillaries. Slight granular degeneration of tubular cells. Few granular and hyaline casts. |
| 8. M.P. | 2nd | 73rd | 45 | Much albumen<br>blood<br>Numerous casts. | Marked | Slight pleuritic effusion. ascites. | Very marked capsular proliferation. Fibroid degeneration of capsule. Thickening of capsule. Marked destruction of glomerular capillaries. Very marked separation of tubule and large increase of intertubular tissue. Dilatation of collecting tubules and many very large hyaline casts. Granular degeneration of tubular cells. No hyaline change. |

N.B. Day of illness on admission refers to Scarlet Fever.

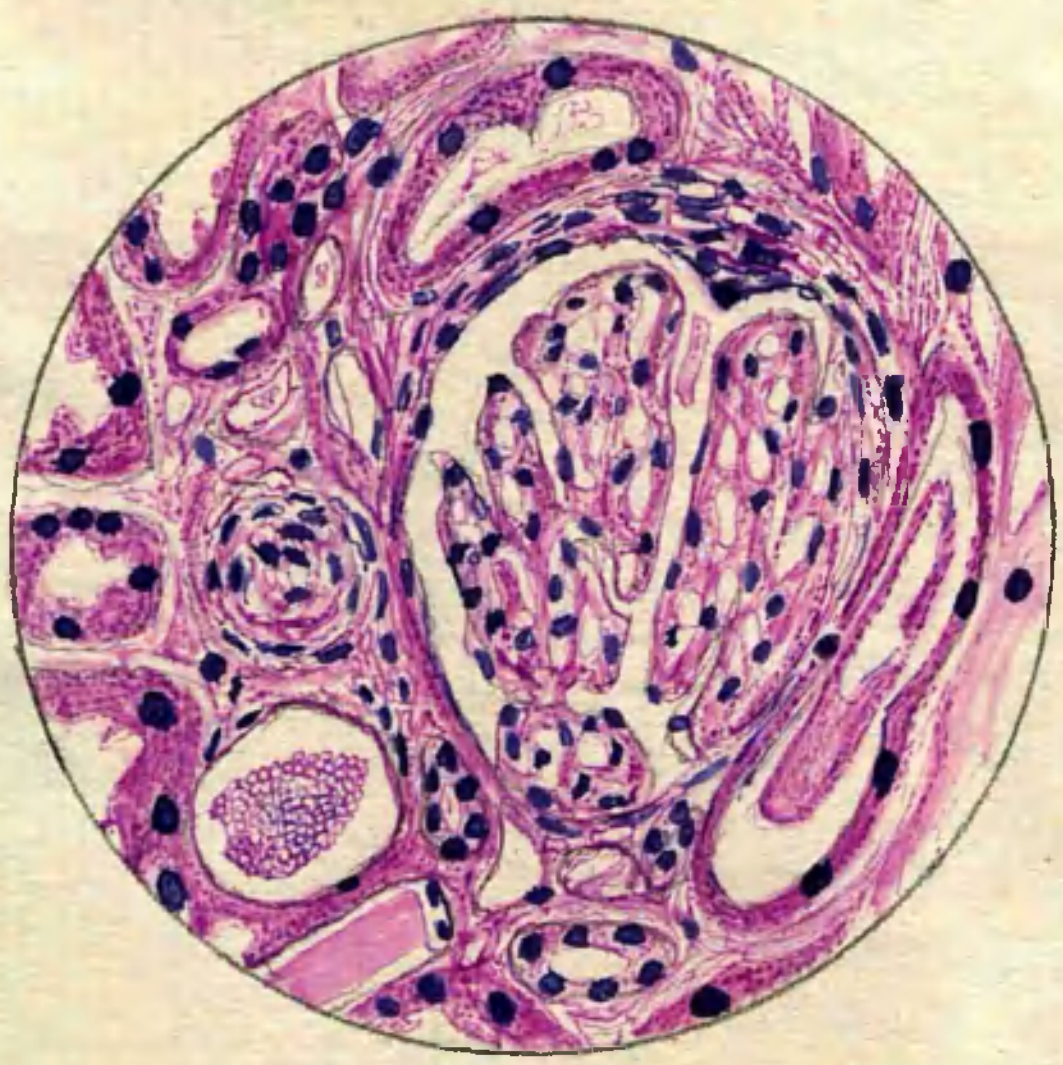

## PLATE I.

Section of glomerulus from Case No. 2. stained with Alum haematoxylin and Eosin. Proliferation of the cells in Bowman's capsule is seen in an early stage. The proliferation is most marked on the side of the glomerulus opposite to the entrance of the afferent vessel. The cells have not yet assumed a flattened appearance. On the right hand of the glomerulus there is seen a hyaline cast situated in a junctional tubule.

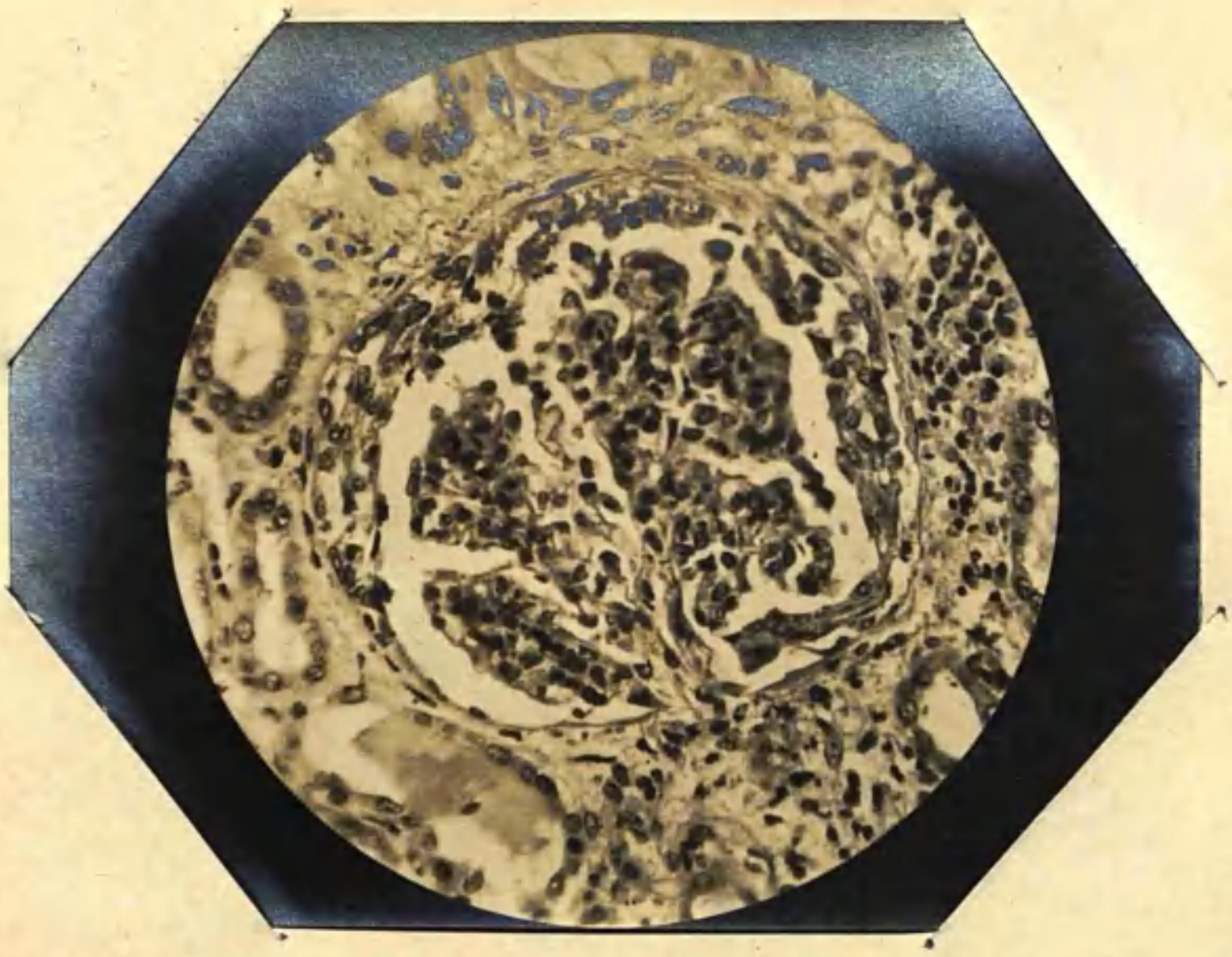

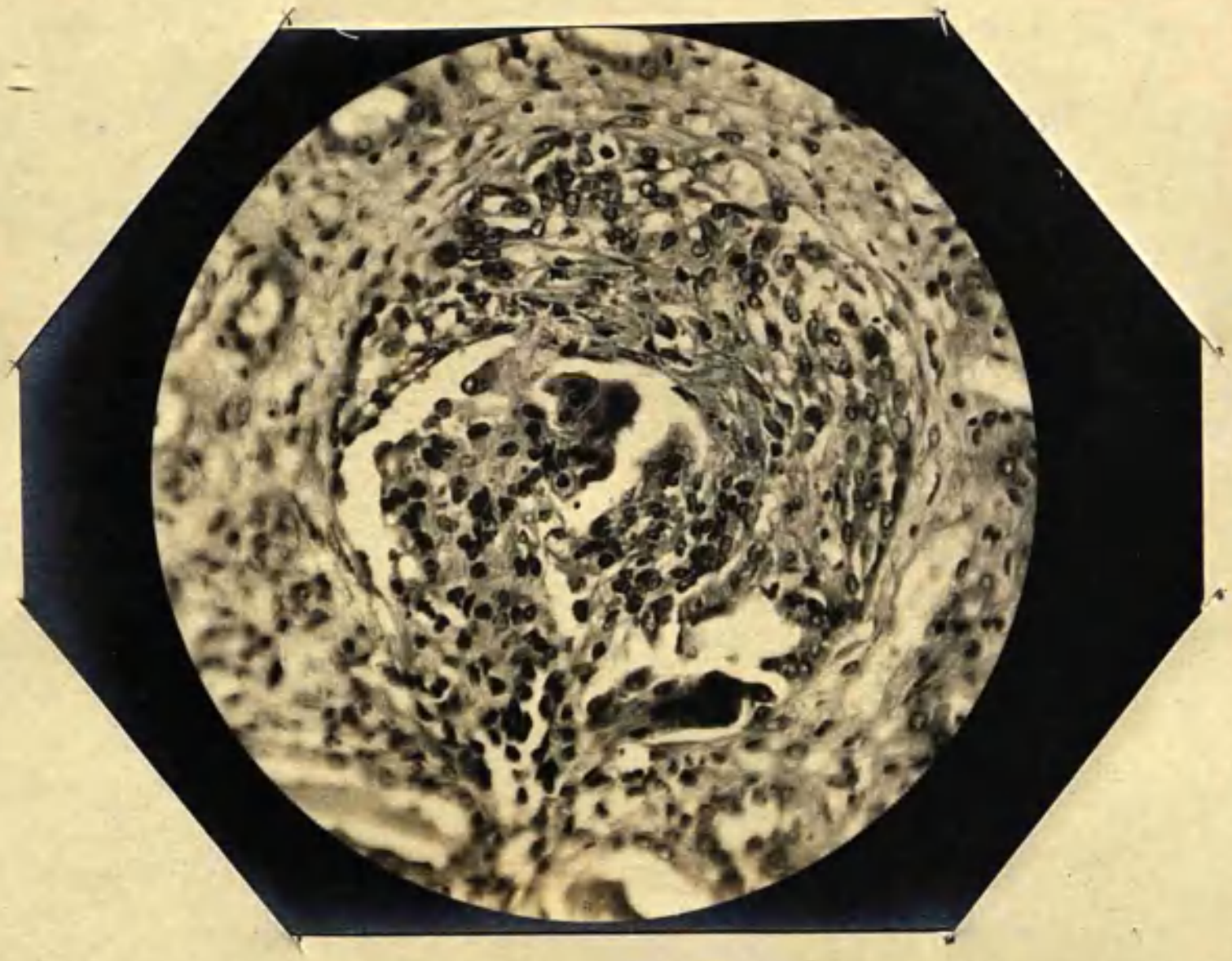

# PLATE II.

Fig. I. Section from case No. 8 showing proliferation of the cells in Bowman's capsule. The proliferation is most marked on the side opposite to the entrance of the afferent vessels and nearly extends round the entire circumference of the glomerulus.

Fig. II. Section of a glomerulus from the same specimen, showing a more marked degree of the proliferation. The cells, nearest to the glomerular tuft, have become flattened in shape and are separated from one another by connective tissue.



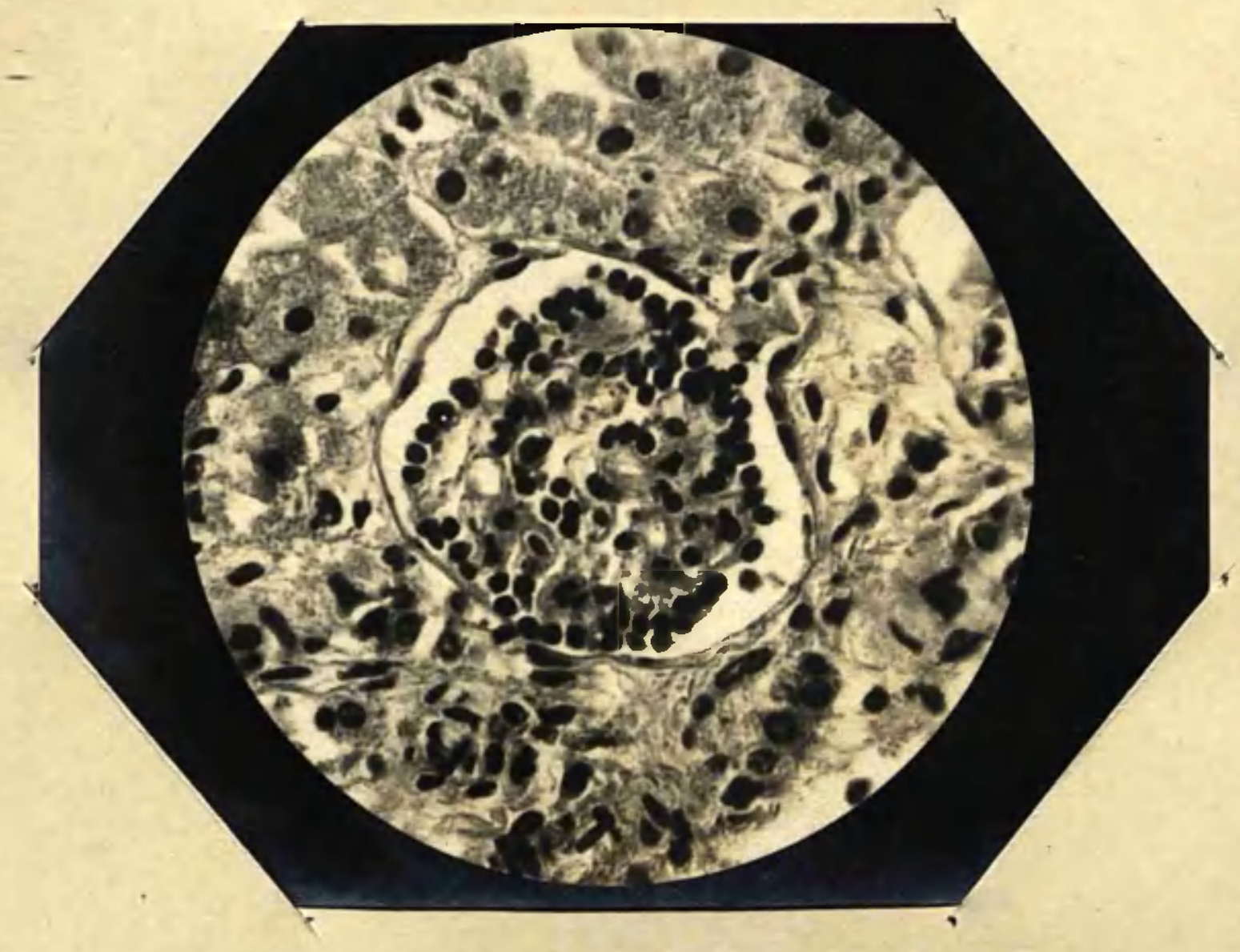

# PLATE III.

Fig.I. Section of a glomerulus from case No. 8. The whole of glomerular structure is replaced by dense fibrous tissue.

Fig. II. Section of an embryonic glomerulus. The nuclei belonging to the epithelial cells immediately covering the glomerular tuft are very prominent.

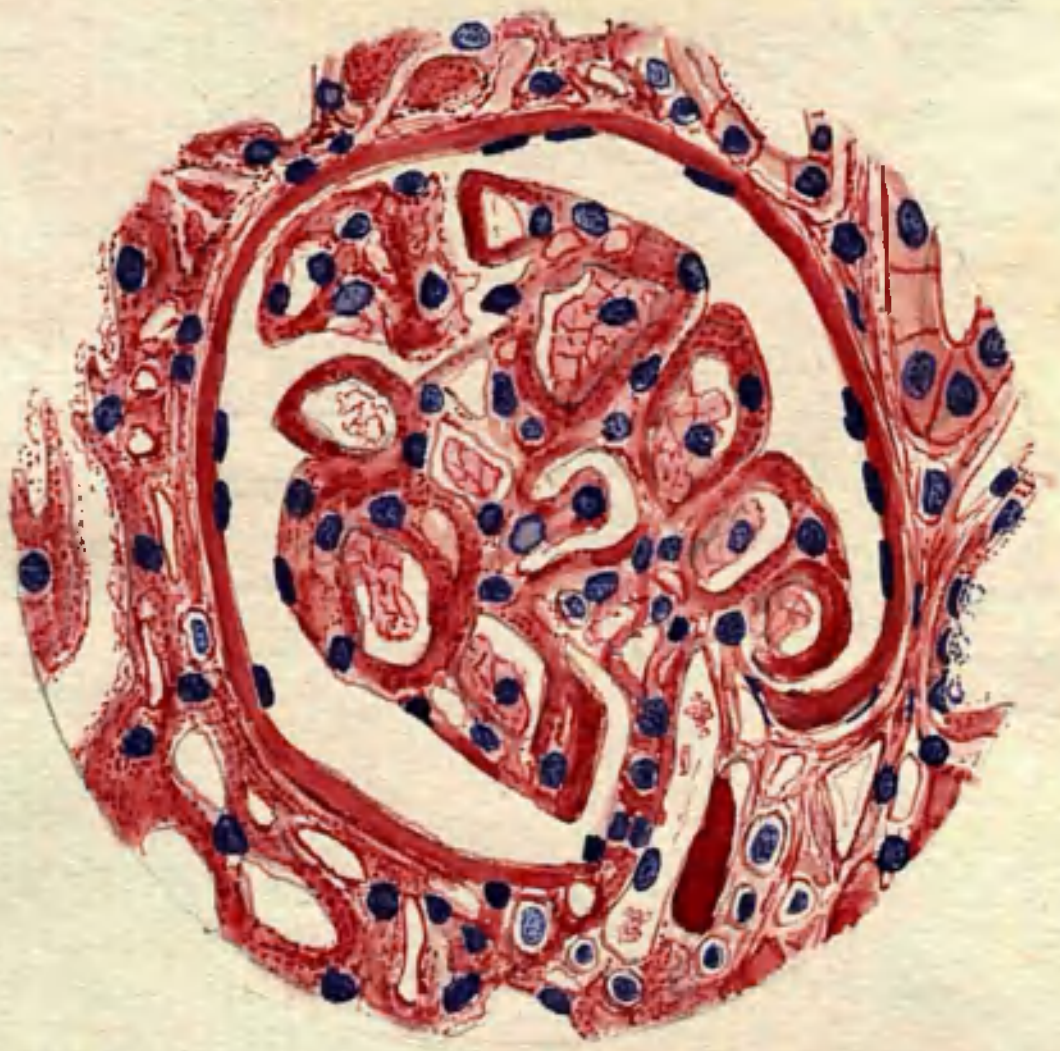

## PLATE IV.

Section of a glomerulus from Case No. 4 stained with Alum haematoxylin and Eosin. There is seen hyaline thickening of the basement membrane of Bowman's capsule, hyaline degeneration in the wall of the afferent artery and some hyaline swelling of a few of the capillary loops. The hyaline material is stained a deeper and brighter red than the surrounding tissue. In the interior of some capillaries are seen a few proliferated endothelial cells.

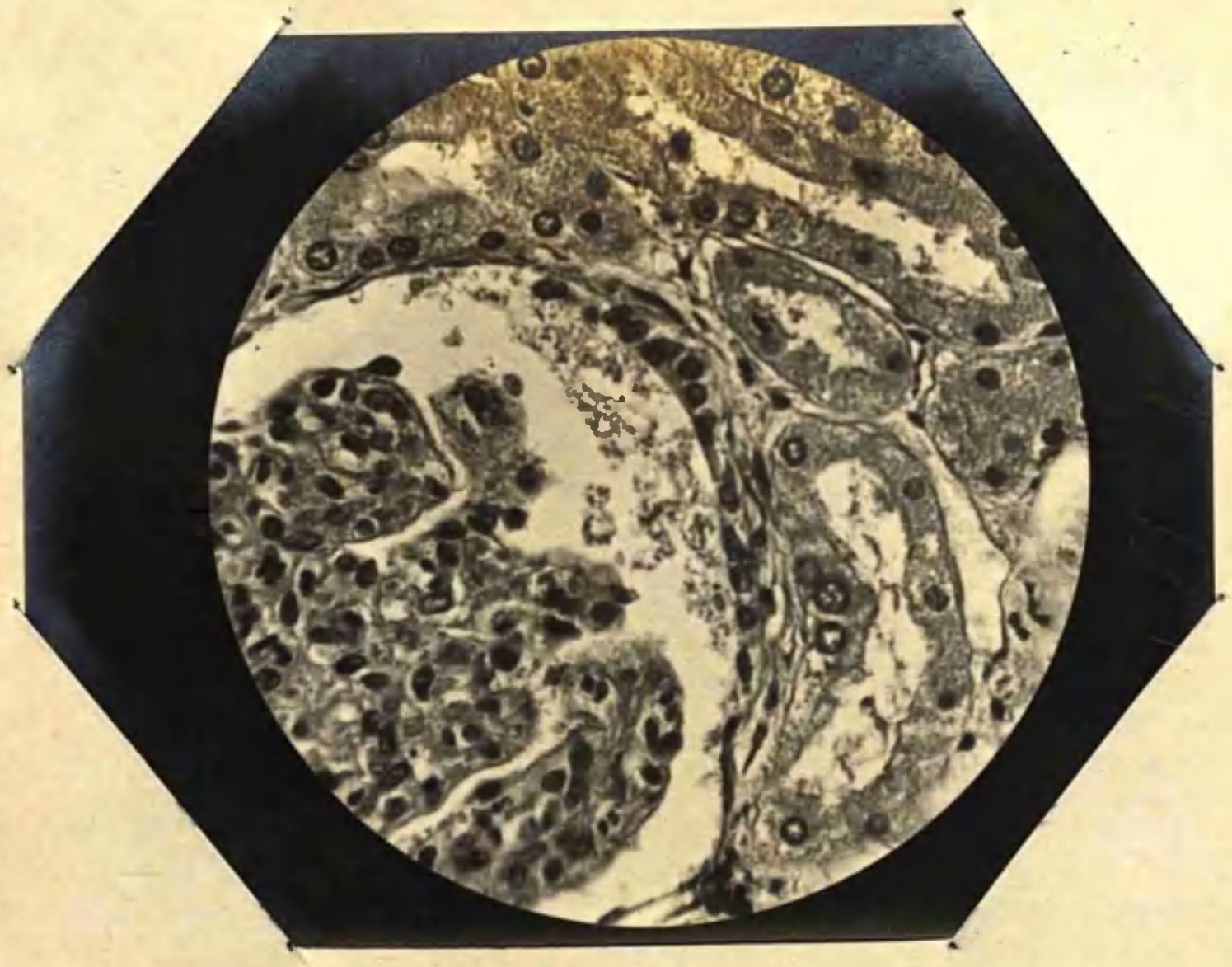

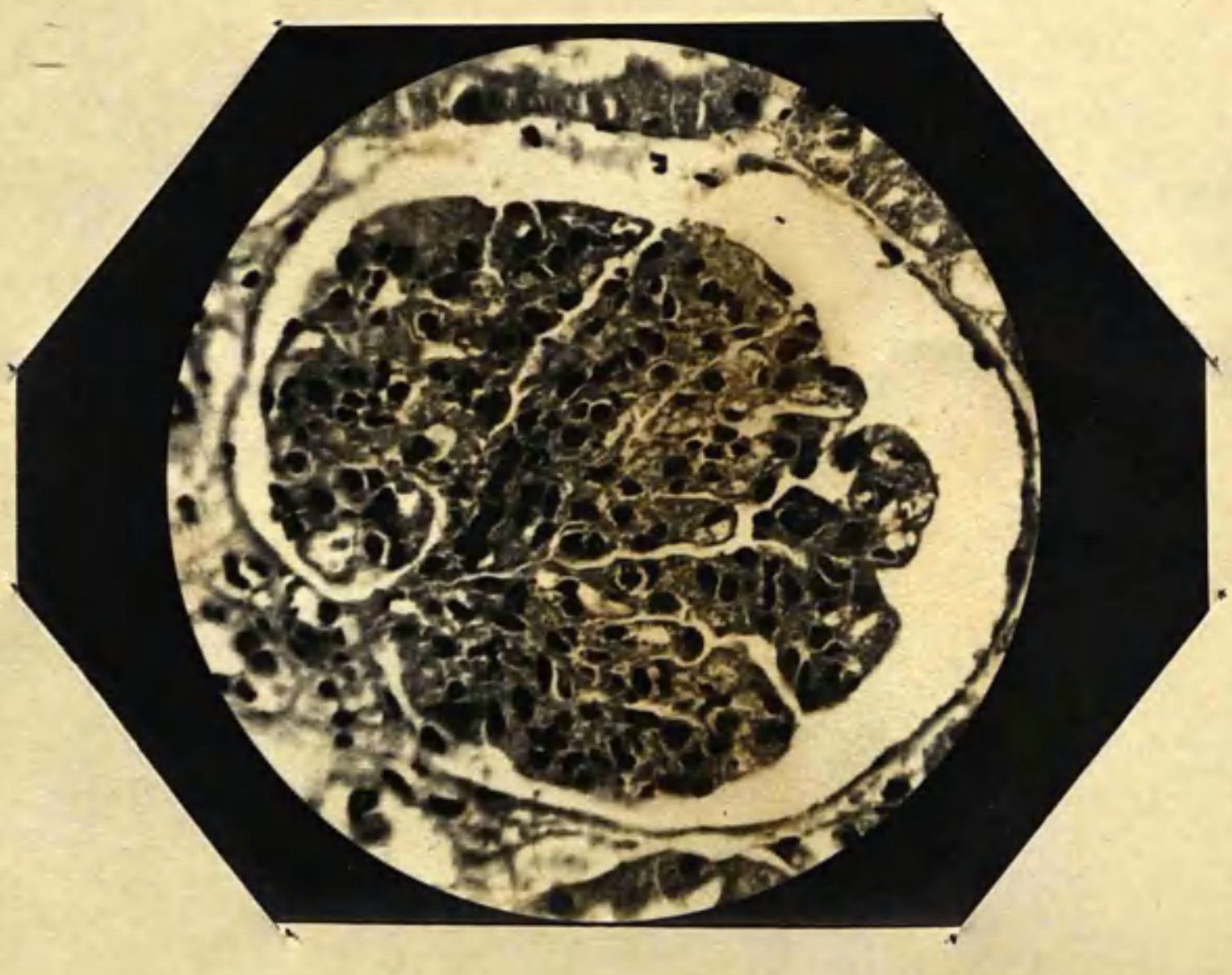

## PLATE V.

Fig. I. Section of portion of a glomerulus from case No. 18, showing granular debris in capsular space.

Fig. II. Section of a glomerulus from Case 1, showing the increase in the number of nuclei and general obscuration of capillary structure. The lobulations of the glomerular tuft are evident.

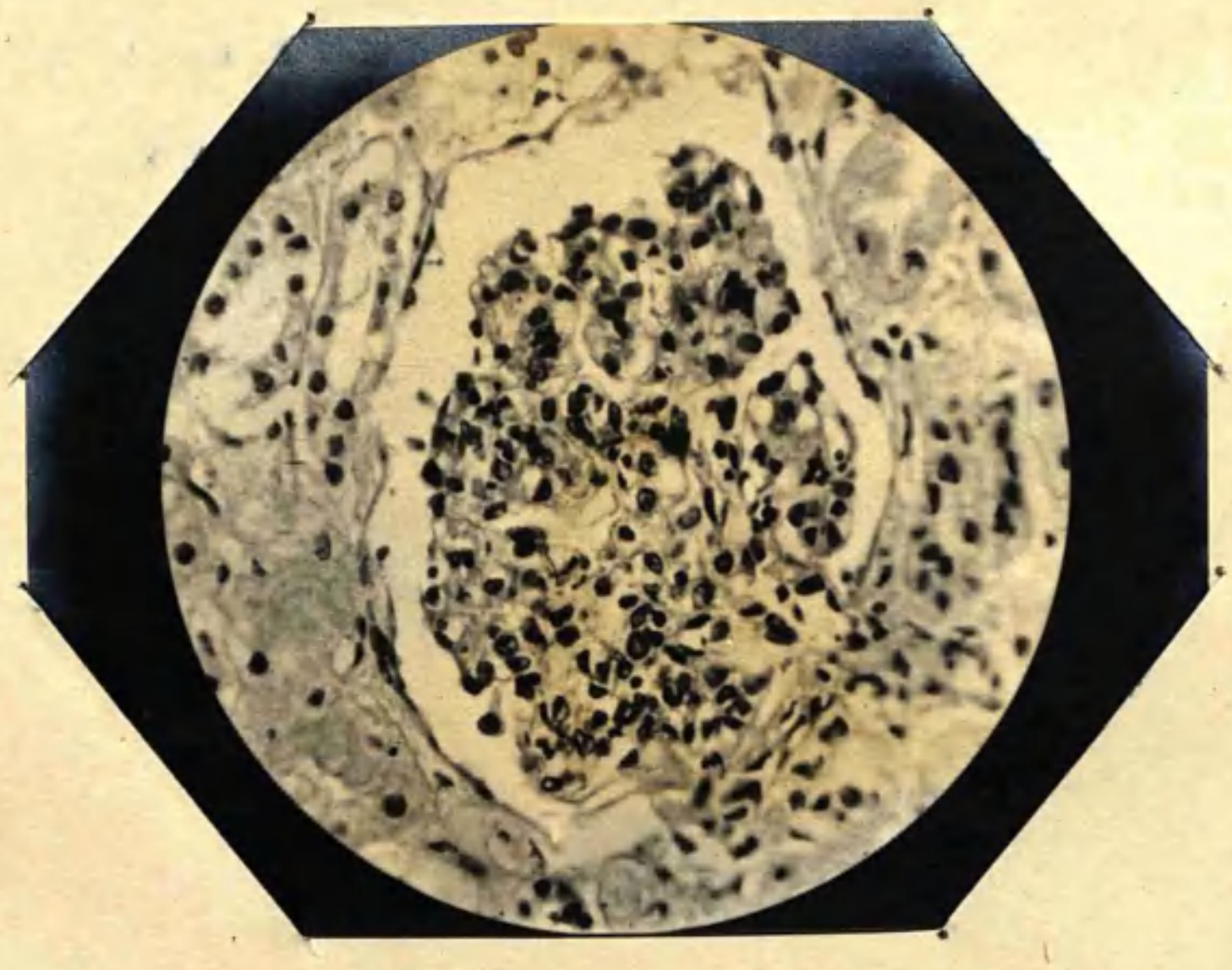

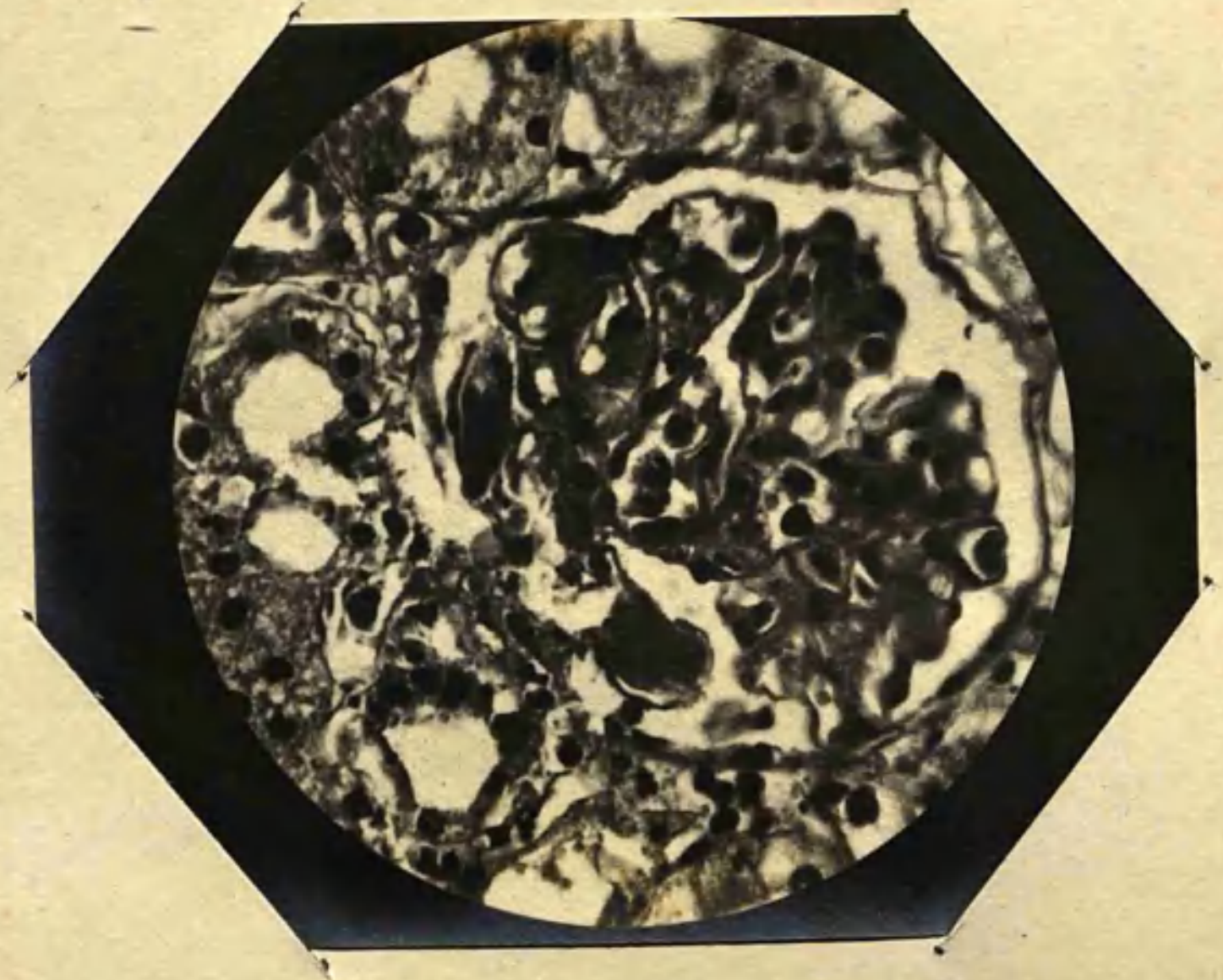

# PLATE VI.

Fig. I. Section of a glomerulus from case No. 3, showing the increase in the number of nuclei-proliferated endothelial cells.

Fig. II. Section of a glomerulus from Case No. 6, shewing hyaline thromli in capillary spaces.

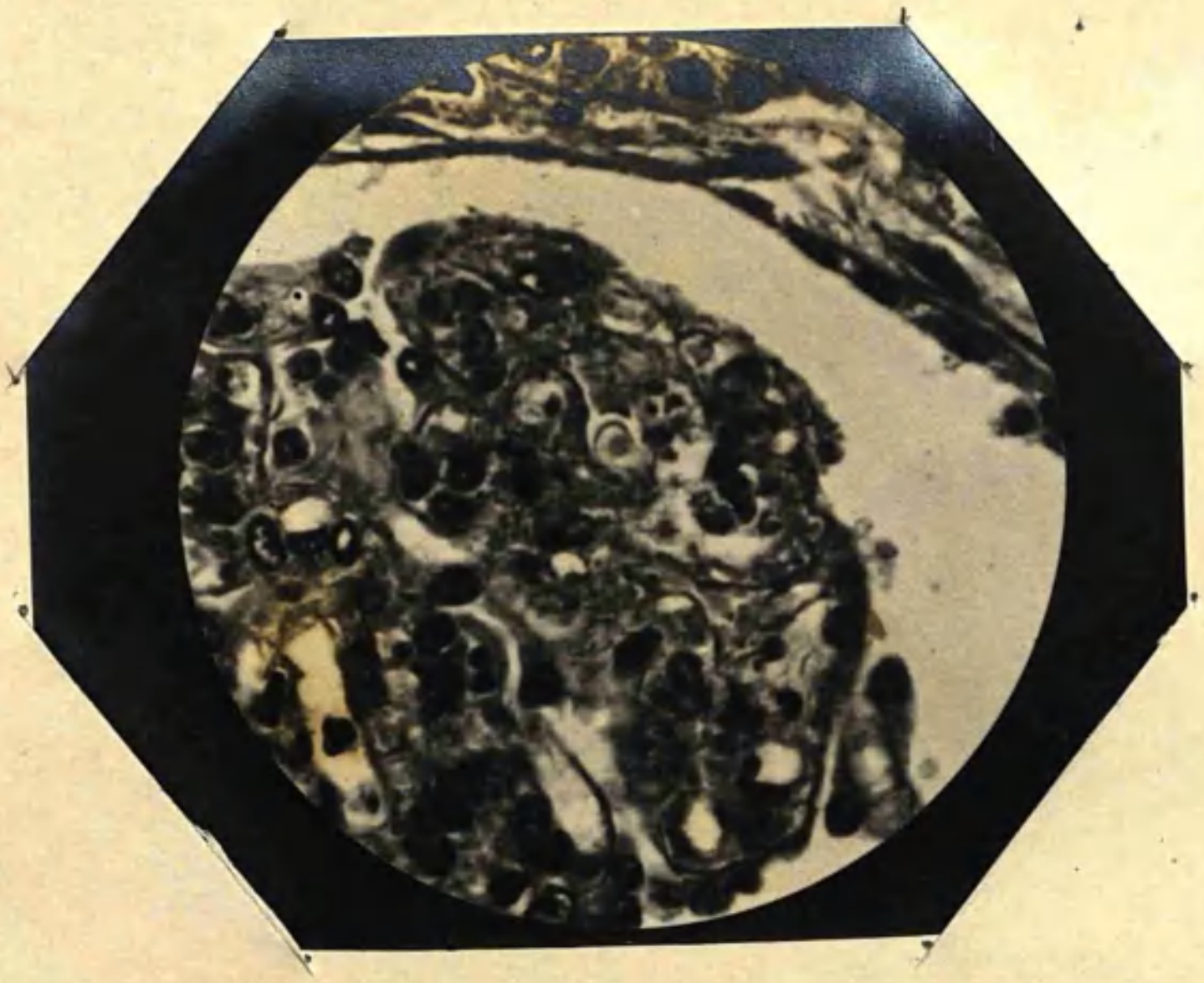

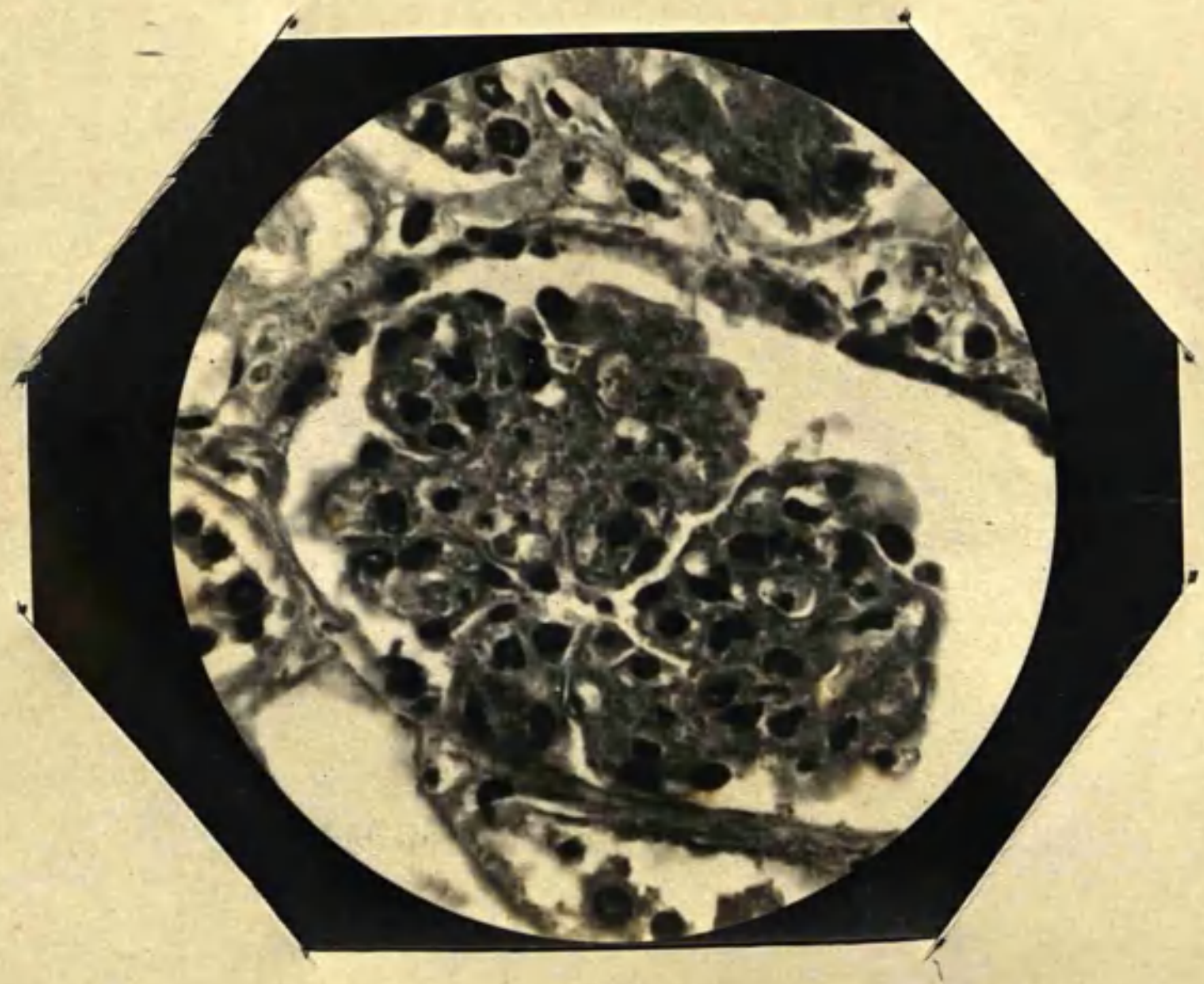

# PLATE VII.

Fig. 1. Section of part of a glomerulus, highly magnified, from case No. 5. There is seen a considerable quantity of granular material within the capillary spaces. The Nuclei of the endothelium are quite evident.

Fig. II. Section of a glomerulus from Case No. 2. There is seen necrosis of a portion of glomerular tuft of capillaries. In this situation there is complete absence of nuclear staining. Compare with Fig. I.

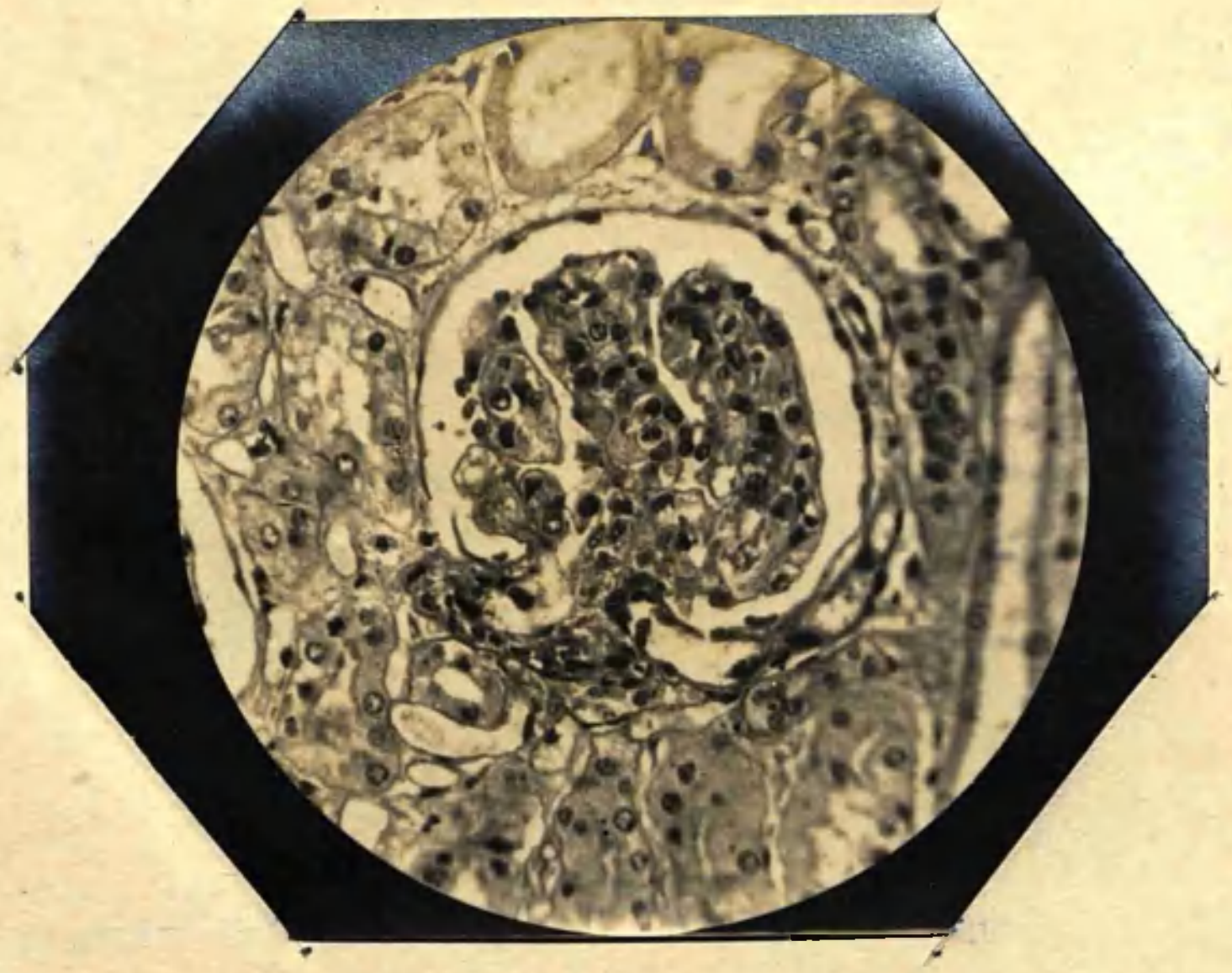

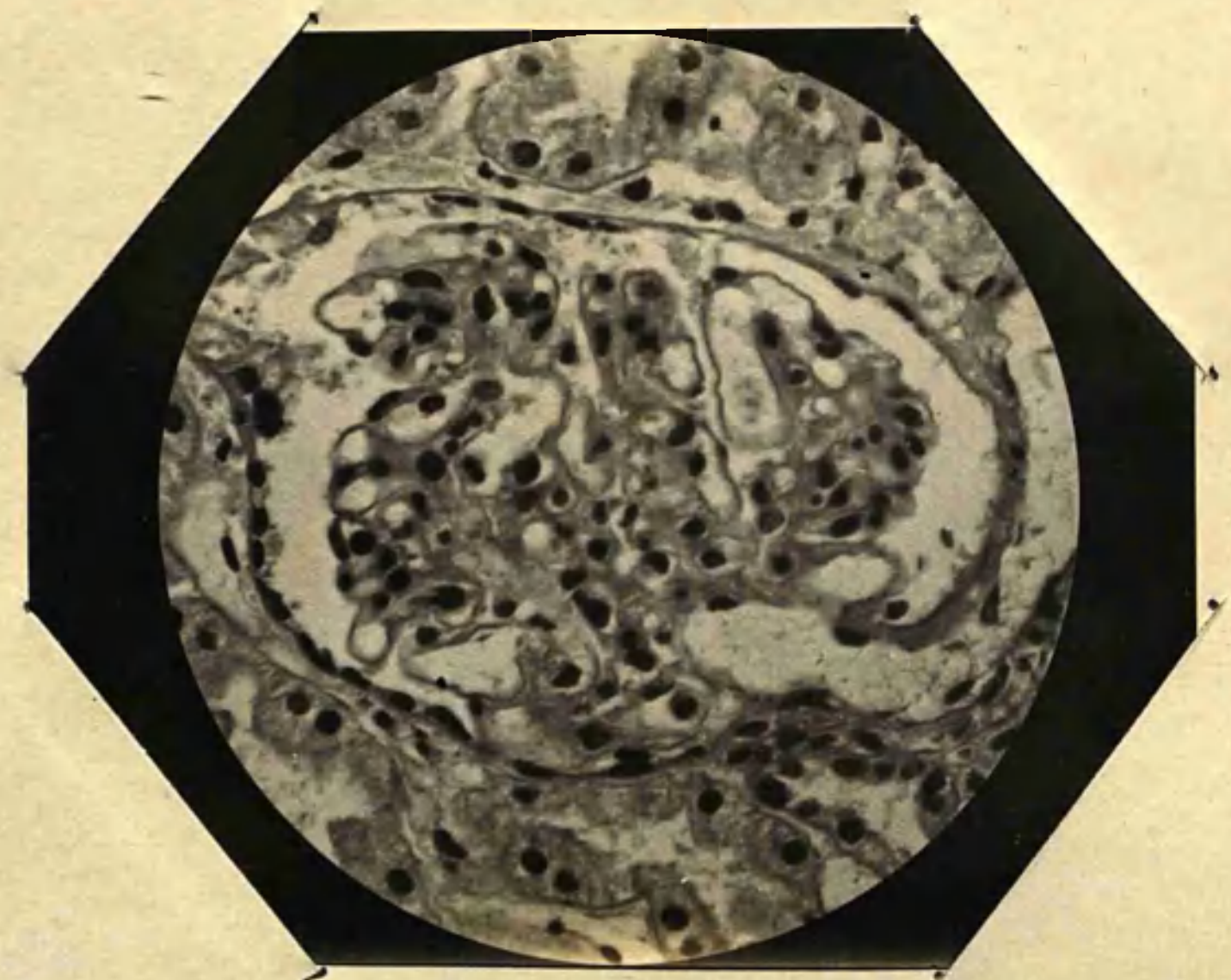

## PLATE VIII.

Fig. I. Section of a glomerulus from case No. 4, showing dilatation of the afferent and efferent vessels.

Fig. II. Section of a glomerulus from case No. 10, showing rupture of glomerular capillaries with consequent formation of large blood-containing spaces.

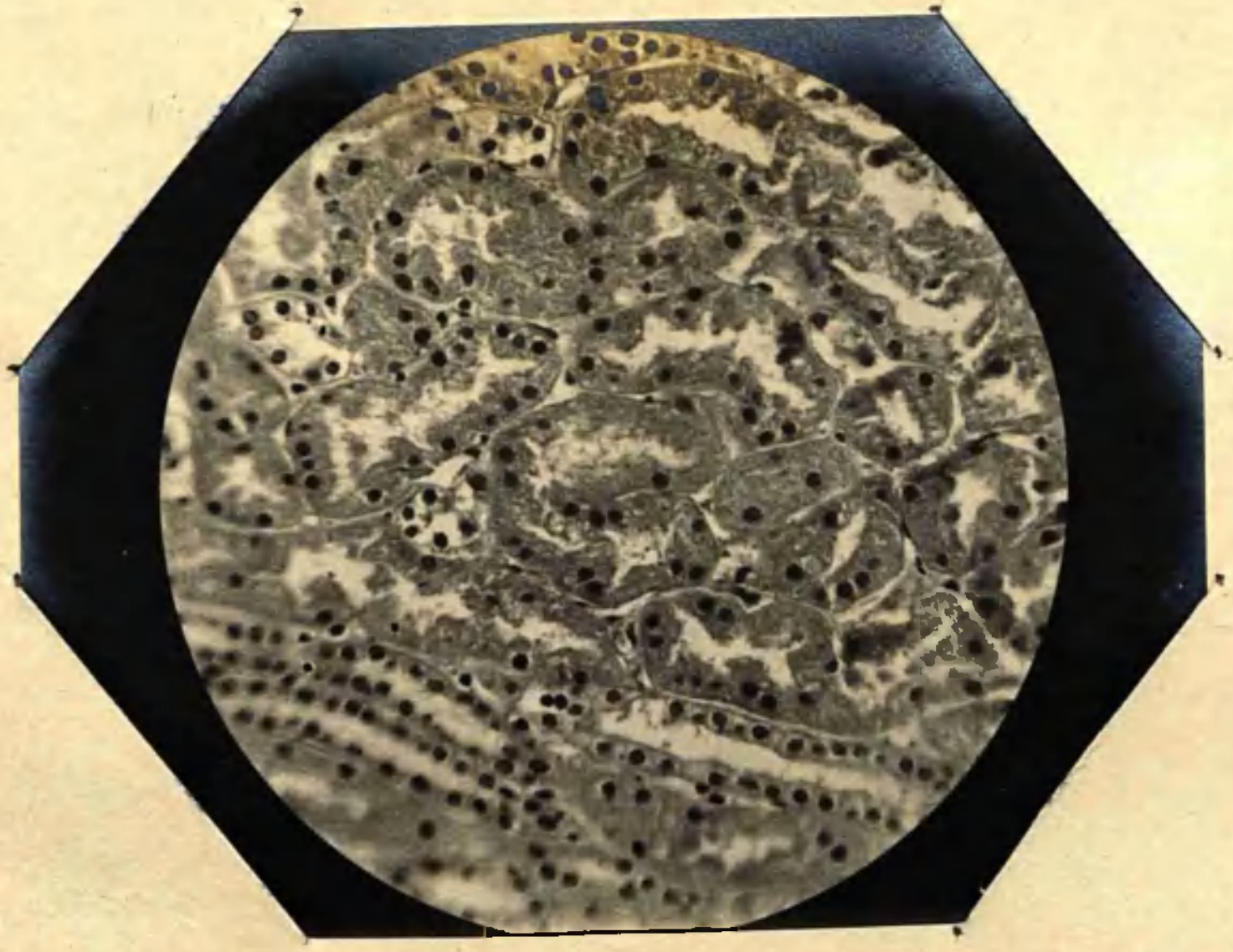

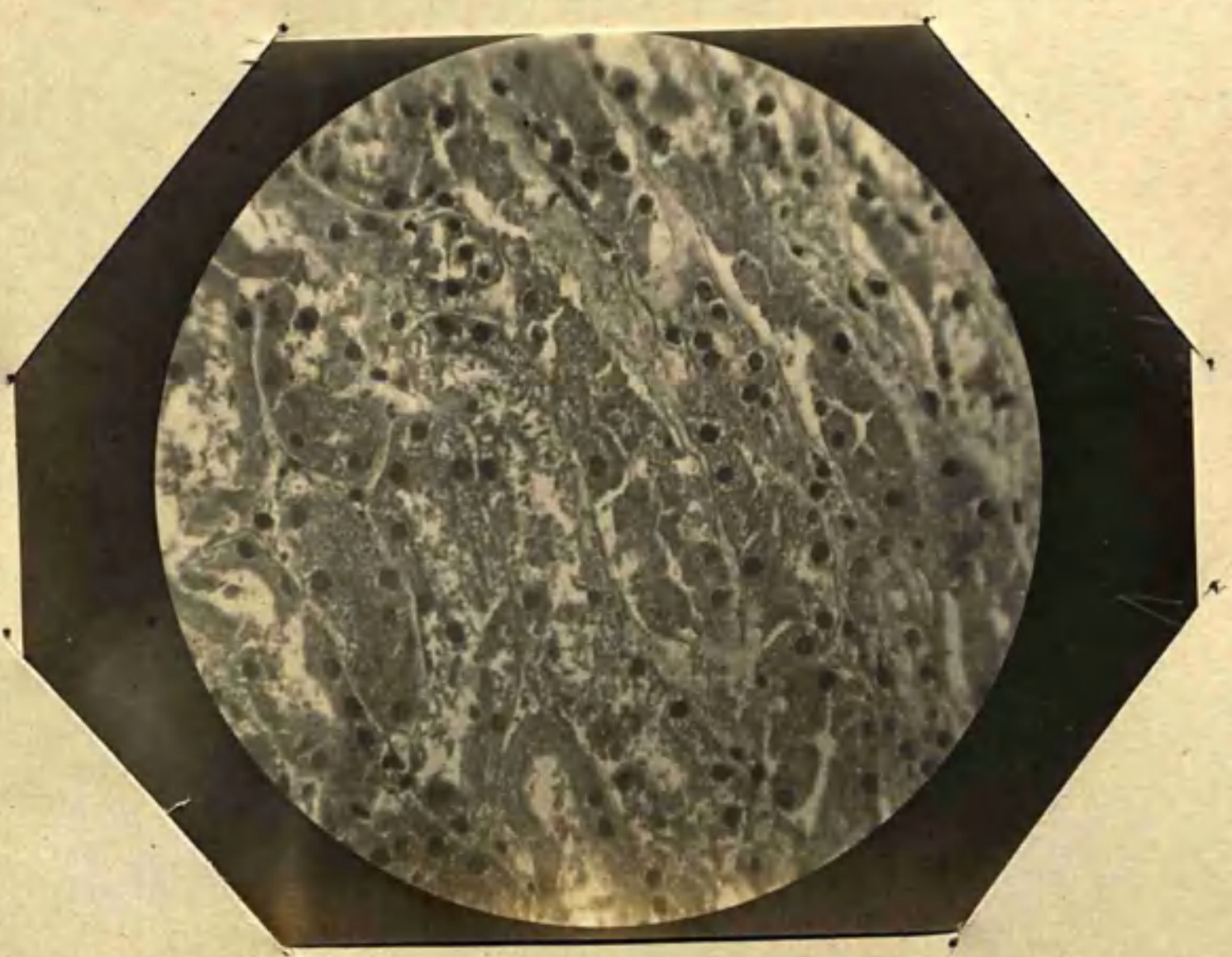

## PLATE IX.

Fig. I. Section of tubules showing granular degeneration in an early stage. The nuclear staining is still well marked.

Fig.II. Section of tubules showing marked granular degeneration. In some cells the nuclear structure is completely lost and in many of the tubules there is considerable disintegration of the cellular protoplasm.



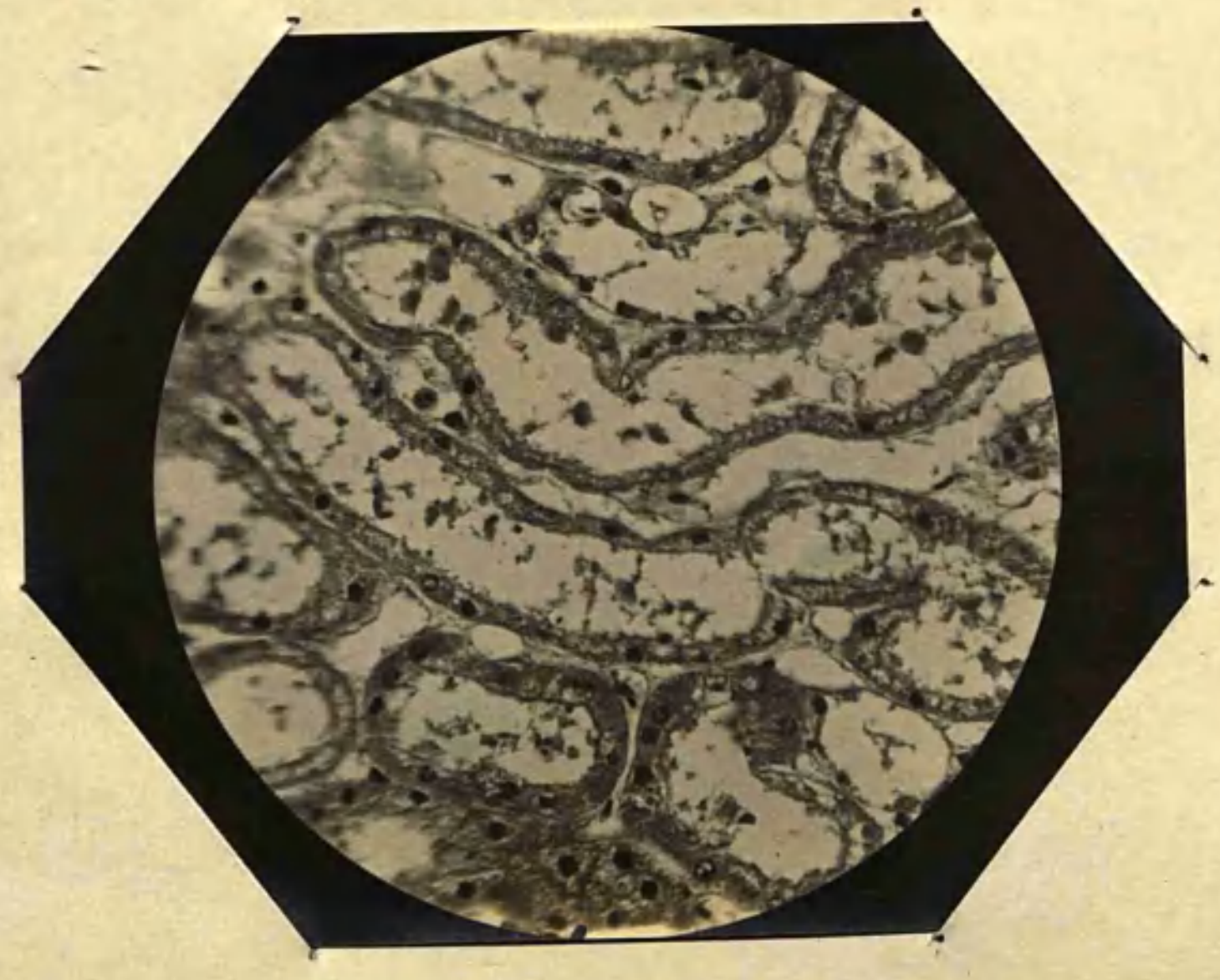

## PLATE X.

Fig. I. Section showing dilated intertubular vessels and haemorrhage into the tubules.

Fig. II. Section from case No. 2, shewing separation of the tubules from one another and diminution in the size of tubular epithelium.

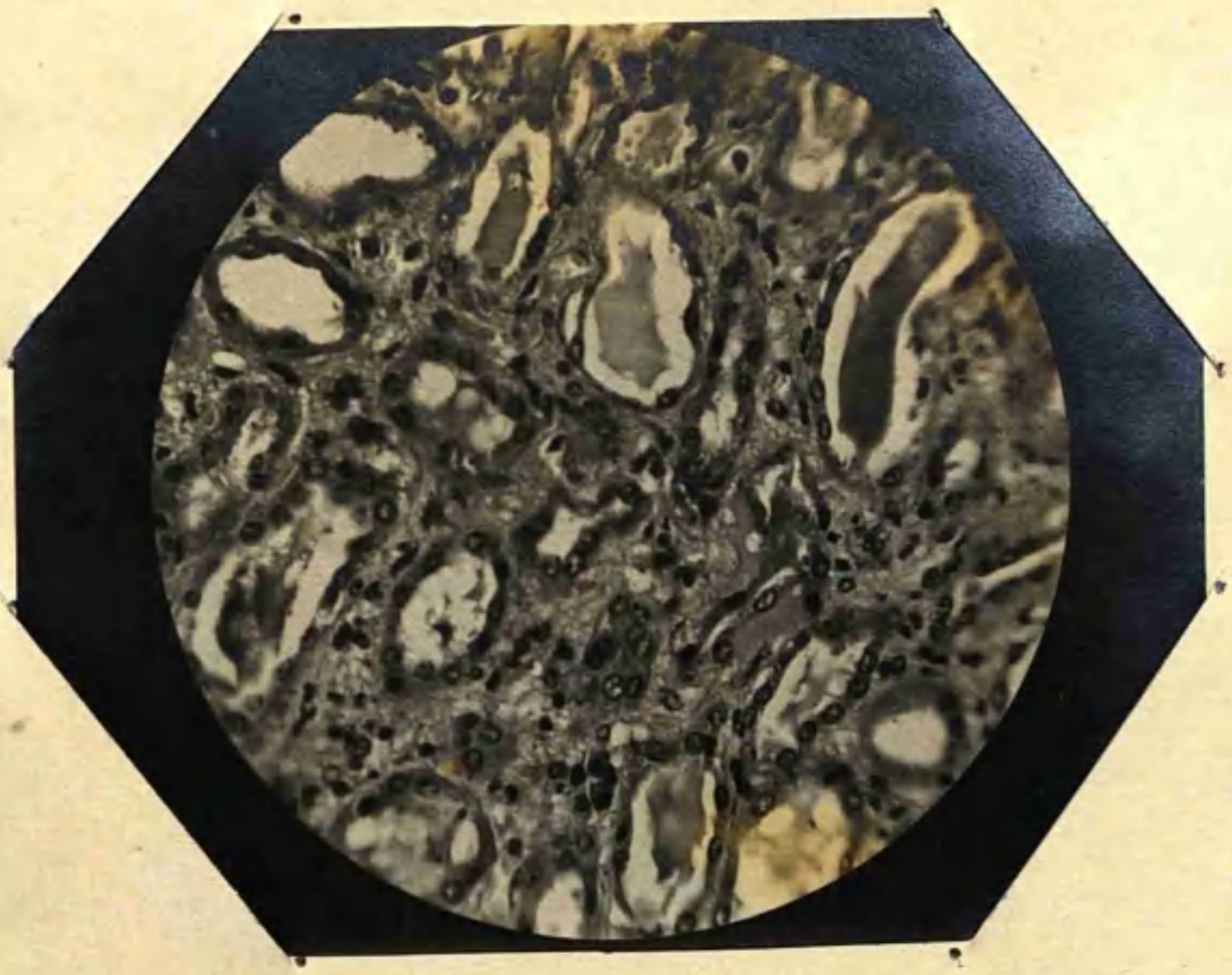

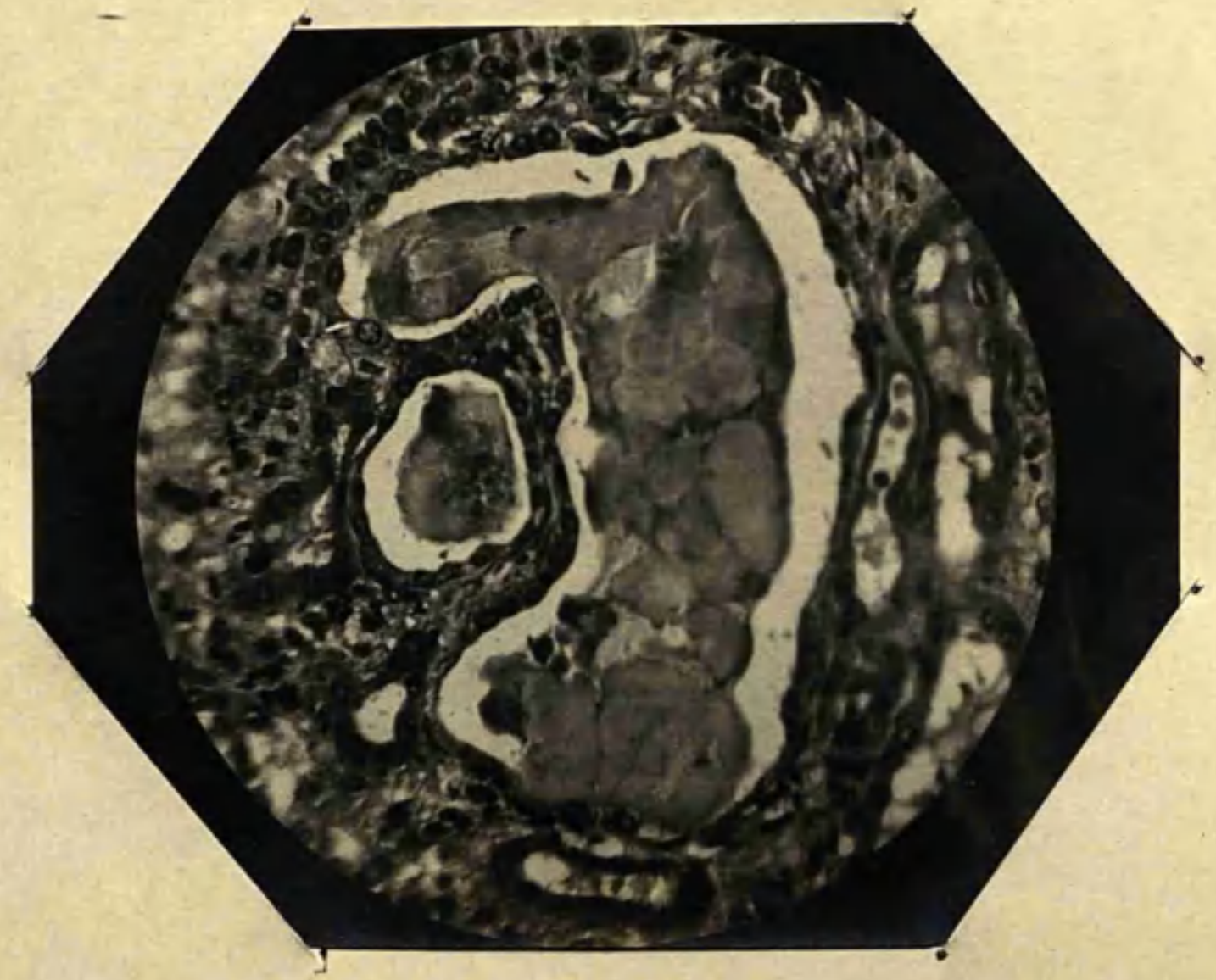

# PLATE XI.

Fig. 1. Section from Case No. 8, showing separation of the tubules from one another by the formation of intertubular connective tissue. Some of the dilated tubules contain hyaline casts.

Fig. II. Section from the same case showing an enormously dilated tubule containing a large hyaline cast.

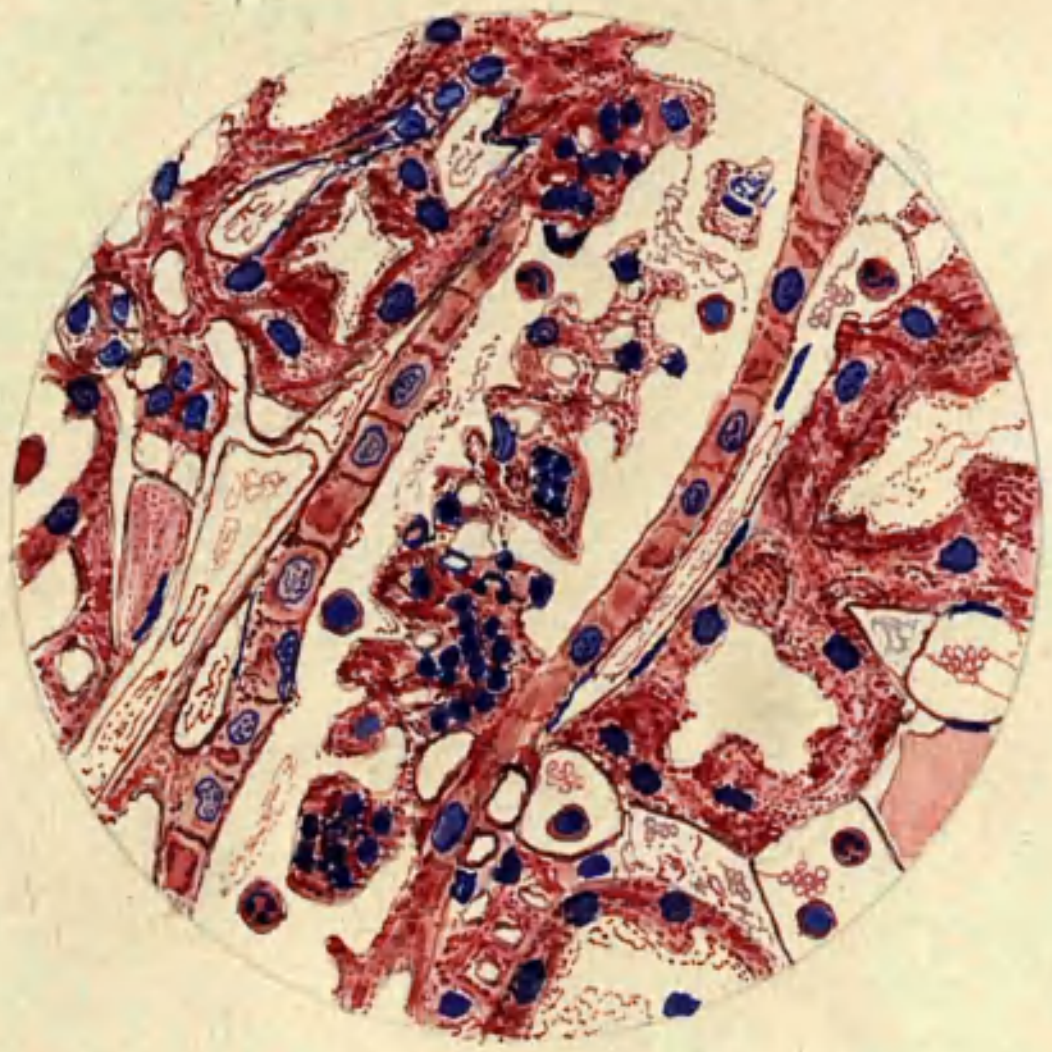

16 | 350 (22
32
30

16
2
13
2
2

# PLATE XII.

Section from case No. 7 showing the formation of a granular epithelial tube-cast in a junctional tubule.

## OBSERVATIONS UPON THE CASES OF CLASS II.

Class II. consists of very severe cases of Scarlet Fever dying, with the exception of the last three, within a few days of the onset of the disease. The last three cases of this group died on the 15th, 19th, and 21st days of the illness respectively and clinically would belong to Class III. but their pathological features make it necessary to include them in the present class.

Clinically the cases presented the symptoms usually found. The rash was either very scanty or if at all marked was very abundant and frequently of a livid tint. There was marked hyperpyrexia, great faucial and tonsillar congestion, glandular enlargement, frequently a muco-purulent discharge from the nose and very pronounced delirium. Most of the patients died within twentyfour hours of admission into hospital,and,excepting the last three, the day of death varied from the second to the sixth day of illness. Of the last three cases No. 17 was complicated with Meningitis and No. 19 suffered from Broncho-Pneumonia. In one case, namely No. 15, the patient had been confined six days before the onset of the fever and case No. 16 was complicated with Varicella.

The urine was obtained in seven out of the eleven cases. In one instance it was entirely free from albumen, in three cases it contained a trace and in the remainder the albumen was very abundant.

The post-mortem appearances were compatible with the type of the disease and consisted of congestion of the lungs and liver, enlargement and congestion of the Peyer's patches and solitary glands of the intestine, while in one case, namely No. X. there was a small ulcer of/

of one of the patches. There was some albuminoid degeneration of the cardiac muscle , enlargement and a semi-diffluent condition of the spleen and a marked hyperaemia of the kidney, most evident in the apices of the pyramids.

## Pathological alterations observed in the Kidney.

Microscopically the changes found in these kidneys are less marked than in Class I. and are certainly not so characteristic of Scarlet Fever. They chiefly affect the blood vessels and the tubular structures. Proliferation of the cells in Bowman's capsule is very rarely met with but in some cases the basement membrane of the capsule is distinctly thickened throughout its entire circumference. This thickening is evidently due to hyaline degeneration and in one case, namely No. 9, it is very well marked. In this instance in addition to a general hyaline swelling of the structure the membrane is divided into thin laminae, between which are seen a few flattened nuclei. The most important alterations however are found in connection with the blood vessels and urinary tubules.

## Blood Vessels.

As a rule all the larger blood vessels are unduly prominent and are filled with blood cells and in a few instances thrombi are seen although they never completely exclude the lumen of the vessel. Most of the afferent arteries are dilated and in sections, in which this is a very marked feature, it is generally associated with some dilatation of the intertubular capillaries. Only a few Malpighian corpuscles are so cut that they show the vessel entering the glomerulus and in these cases the section may be situated in any plane as regards the long axis of the vessel. While in all cases the dilatation is quite evident, the amount of it is best judged in these sections in which the plane has/

has the same parallel as the long axis of the vessel. Both the intertubular capillaries and afferent vessels together with the glomerular capillaries frequently contain blood cells in large numbers. This dilatation and congestion of the smaller vessels is part of a general hyperaemia and the dilitation of the afferent arteries is in no way dependent upon any obstruction in the glomerulus, for, in the first place, no gross lesion is discoverable in the glomerulus beyond some slight hyaline thickening of the capillary walls and secondly, if there was any obstruction to the blood flow through the glomerular capillaries, a condition of anaemia rather than hyperanaemia would in all probability be met with in the intertubular capillaries. In this respect this dilatation of the afferent vessels differs from that found in cases of class I, where it was directly due to the glomerular obstruction. Considering the large size of some of the capillary spaces in the glomerulus it is evident that some of these structures have ruptured and this is not an infrequent condition although in no case is there any evidence of rupture taking place into the capsular space.

Another pathological condition found in connection with the smaller vessels is hyaline degeneration of their walls. This was present in the former class of cases and, although not very marked in the present class, it is of frequent occurrence. It is most prominent in the afferent arteries but can also be seen in the intertubular capillaries. It is seen as a homogeneous thickening of the vessel wall and this thickening appears to be situated beneath the endothelium. It gives the characteristic stain with Van Gieson, and with Eosin it is coloured a deeper red than the surrounding tissue. In sections cutting the vessels at right angles it is seen to occupy only a portion of the circumference and in longitudinal sections it occurs as thin oblong masses not continuous with one another. There is also a slight amount of hyaline/

hyaline degeneration of the glomerular capillaries and in this position it causes a bulging of the wall into the lumen of the vessel. The capillary structure however, is for the most part distinct and only in a very few cases is there any increase in the number of nuclei in the glomerulus.

## Urinary Tubules.

In the tubules the same conditions are found as in Class I. A few of the specimens show slight separation of these structures, the intervening spaces being nearly always occupied by dilated capillaries. Many of the cells in the convoluted tubules and ascending loop of Henle are granular and a few of the former exhibit some disintegration. Many of the latter have become separated from their basement membrane and from one another. In some instances there is an excessive number of these cells, the whole space within the basement membrane being occupied by cells. In cases where this proliferation is not very marked the outline of the various cells is distinct and occasionally one cell is seen to contain two nuclei. In cases, however, where it is more marked, as it is in Case No. XV, the outline between the various cells is lost but the nuclei retain the same characters as formerly. No evidence of mitosis is found. This condition is found in both Class II. and III. but is most evident in the present group of cases where it occurs in seven out of the eleven cases. Clinically these seven cases represent types of a septic intoxication. There ~~are~~ was generally hyperpyrexia and a considerable degree of ulceration in the throat, and in Case XV, where it is found to be most marked, there was the probability of a septic infection through the uterus. In view of these facts it seems probable that this proliferation is dependent to a certain extent upon

a/

a septic infection apart from the action of the Scarlatiniform poison. It is strange that this condition should not up to the present have received more attention and considering the frequency of its occurrence and its very marked character in some of the present cases, it is necessary here to insist upon its importance.

A few of the cells in the convoluted tubules and ascending limbs of Henle have undergone hyaline degeneration, the protoplasm being divided up into highly refractive small globules, which are homogenous in structure and stain characteristically with Van Gieson and Eosin. In a few instances a further change has occurred, namely, that these cells have become broken up or disintergrated and the hyaline globules liberated into the interior of the tubules. These hyaline masses are met with in the interior of the convoluted, junctional and collecting tubules and occasionally in the capsular spaces, into which position they must have been pushed by pressure exerted upon the convoluted tubules.

The cells of the ascending loop of Henle and of the convoluted tubules show the same fatty degeneration as in the cases of Class I, only in a more marked degree and a few tube casts mostly of the granular and more rarely of the hyaline variety are seen in the junctional tubules.

## TABLE OF CASES IN CLASS II.

| No. of Case. | Day of illness on admission. | Day of death. | Urine. | PATHOLOGICAL CHANGES IN THE KIDNEY. |
|---|---|---|---|---|
| 9. A. A. | 1st | 2nd. | None passed. | Thickening of Capsules. Dilatation of afferent vessels. Hyaline degeneration of capillaries. Congestion of Blood vessels. Granular degeneration of tubular cells. Desquamation and proliferation in ascending loop of Henle. Disintegration of cells in convoluted tubules.. |
| 10. A. H. | 2nd. | 3rd. | None passed. | Slight Capsular thickening. Dilatation of afferent vessels. Hyaline degeneration of afferent vessels and capillaries. Slight separation of tubules. Granular degeneration of tubular cells. |
| 11. M. D. | 2nd. | 4th | Trace of albumen. | Slight capsular proliferation. Slight capsular thickening. Small quantity of capsular debris. Blood vessels congested. Hyaline degeneration of afferent vessels and capillaries. Granular degeneration of tubular cells. Desquamation and slight proliferation in ascending loop of Henle. |
| 12. E. M. | 2nd. | 4th. | No albumen. | Congestion of Blood Vessels. Slight hyaline degeneration afferent arterioles and capillaries. Slight separation of the tubules. Granular degeneration of tubular cells. |
| 13. C. C. | 3rd | 4th | Much albumen. | Capsular thickening. Dilatation of afferent vessels. Hyaline degeneration of afferent arterioles and capillaries. Granular and Hyaline degeneration of tubular cells and occasionally disintegration of cellular protoplasm. Desquamation in ascending loop of Henle. |
| 14. R. T. | 3rd. | 4th | None passed | Marked granular degeneration and some hyaline change in tubular cells, Desquamation in ascending loop of Henle. Hyaline degeneration of afferent vessels and capillaries, |
| 15. Mrs S.<br>Complicated with Puerperal Fever. | 2nd | 4th | Trace of albumen | Marked granular and pre-evident hyaline degeneration of tubular cells. Considerable desquamation and proliferation in ascending loop of Henle. Much granular debris in tubules. Slight hyaline degeneration in afferent arterioles and capillaries. |
| 16. M. M.<br>Complicated with Varicella. | 4th | 4th | None passed | Embryonic Malpighian corpuscles present. Dilatation and hyaline degeneration of afferent vessels. Granular degeneration of tubular cells. Desquamation in ascending loop of Henle. |
| 17. C. W.<br>Complicated with Meningitis. | 5th | 15th | Much albumen. | Capsular thickening. Small quantity of capsular debris. Rupture of capillaries. Granular degeneration and some disintegration of tubular cells. Desquamationnand proliferation in ascending loop of Henle. |
| 18. J. W. | 3rd | 19th. | Trace of albumen. | Hyaline degeneration of afferent arterioles and capillaries, Granular and hyaline degeneration in tubular cells. |
| 19. B. T.<br>Complicated with Broncho-pneumonia. | 5th | 21st | Much albumen. | Considerable capsular debris. Slighr capsular thickening, Very slight increase of nuclei. Hyaline degeneration of afferent vessels and capillaries. Considerable separation of the tubules. Granular degeneration and hyaline change in tubular cells. |



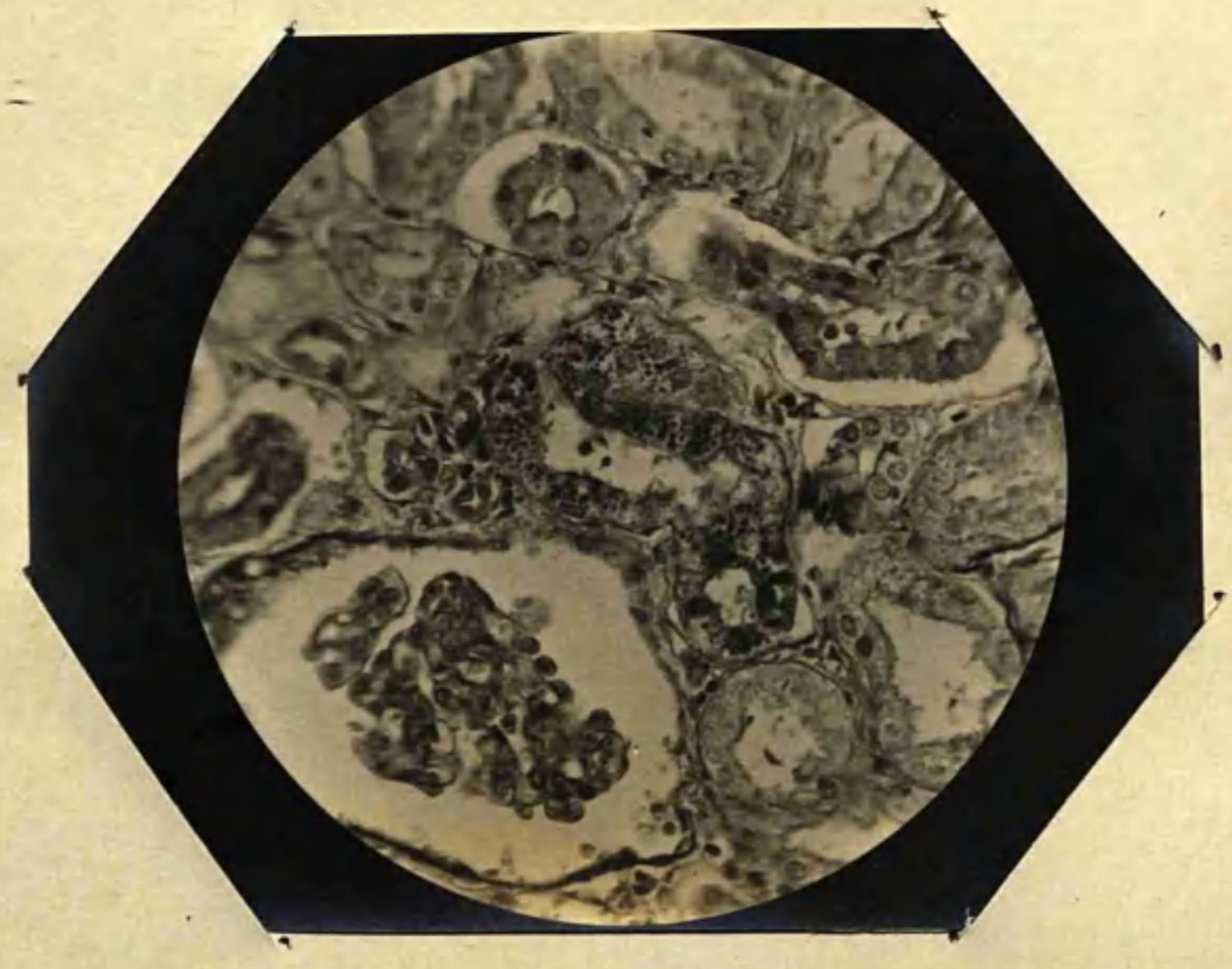

# PLATE XIII.

Fig. I. Section from Case No. 12, showing the distended and congested condition of the blood vessels.

Fig. II. Section showing hyaline degeneration of the tubular epithelium.

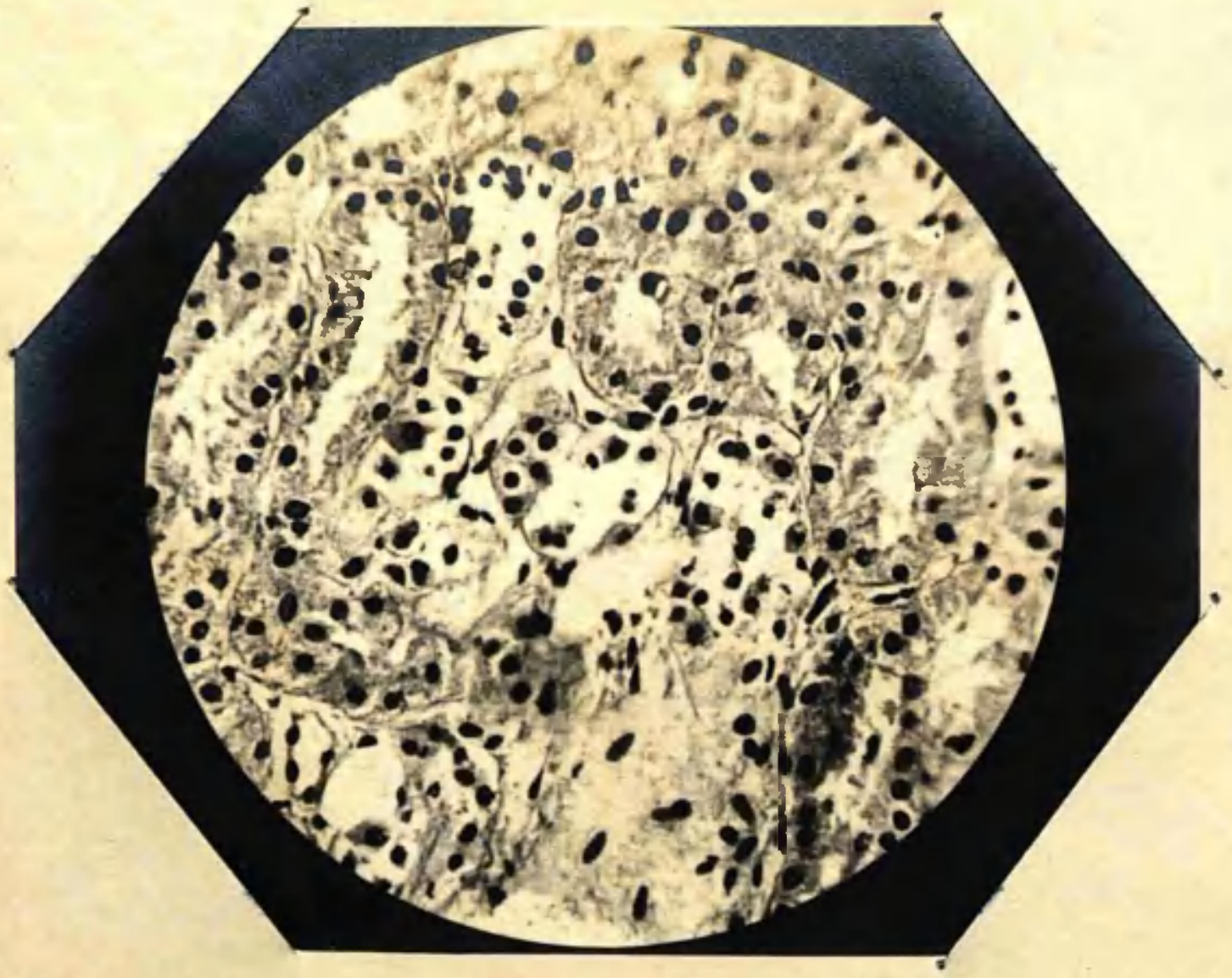

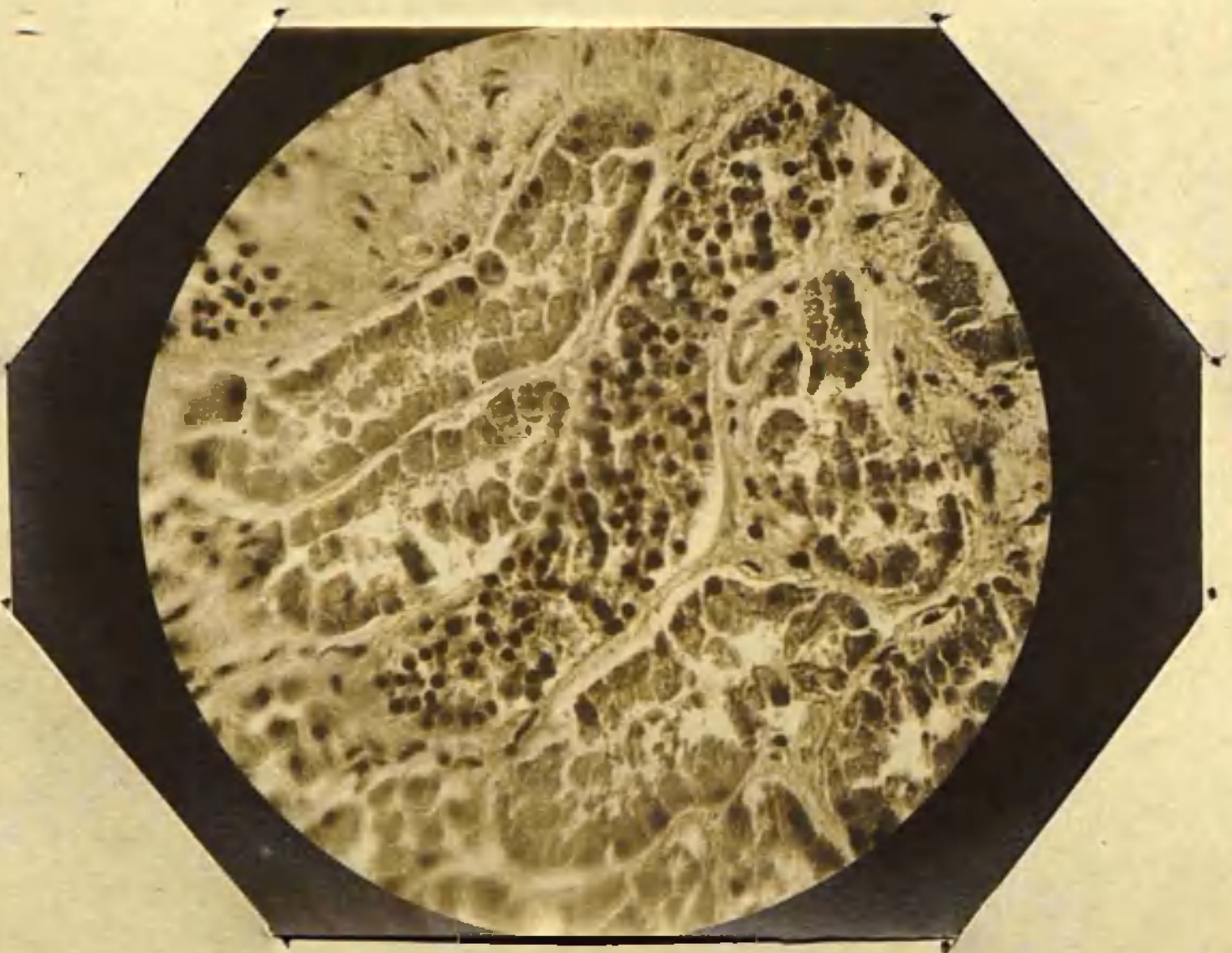

# PLATE XIV.

Fig. I. Section of tubules from Case No. 10, showing separation of the cells in the ascending loop of Henle both from their basement membrane and from one another.

Fig. II. Section of tubules from Case No. 15, showing a very marked proliferation of cells in the ascending loop of Henle.

## OBSERVATIONS UPON THE CASES OF CLASS III.

The cases of this class comprise severe cases of scarlet fever dying from the sixth day of illness onwards. They were all admitted to Hospital during the acute stage of the disease, except the last one, of which there is no previous history. In all the cases the rashes were well marked and in some instances were intensely developed. With five exceptions, in which there was a trace of albumen, the urine was clear, and it was only diminished in quantity in cases Nos 23 and 27. Glandular enlargement, ulceration of the throat, nasal discharge and otorrhoea were generally present. The temperature ran into high registers and in nearly all the cases there was considerable delirium and marked restlessness. Two of the patients suffered from Broncho-pneumonia, one had Eudocarditis and another was the subject of Puerperal Fever.

The post mortem macroscopical examination of the kidneys showed slight enlargement with a degree of fatty degeneration and some congestion of the pyramids. In addition there was generally present marked ulceration of the fauces and palate, some pulmonary congestion, swelling and injection of the Peyer's patches and solitary glands of the intestine and a varying degree of albuminoid degeneration of the cardiac muscle.

### Pathological alterations observed in the Kidney.

Microscopically the most marked features in the kidneys of these cases are an infiltration of the interstitial tissue with small cells and tubular degeneration. The cells found in these infiltrations are of various kinds but the majority consist of those, to which Councilman/

cilman has given the name of "Plasma Cells", the reason for this name being that they exhibit the same staining reactions as the plasma cells, which were first described by Unna[28].

## Cellular Infiltration.

The plasma cells are easily distinguished from their surrounding elements both by their characteristic staining and by their minute histological features. With alkaline methylene blue the protoplasm is quite deeply stained and this is maintained even after the use of some counterstain. The two stains most frequently used in the present work were Polychrome Methylene blue and a 1% solution of Orecin in absolute alcohol. With this combination the nucleus is stained a deep blue and the protoplasm a lighter blue while the protoplasm of other cells is coloured a purplish brown. They can also be differentiated by Ehrlich's triacid stain, with which the nuclei are coloured a faintly greenish blue and the protoplasm a lilac red. These cells are very irregular in shape and vary somewhat in size but are generally larger than a leucocyte. As will afterwards be shown these cells are found both in the interstitial tissue and in the smaller blood vessels. This is mentioned here in order to point out the facts that the irregularity in their shape is most marked after they have left the vessels and also that while they are situated within the capillaries they are smaller in size than subsequently. They usually have one nucleus but sometimes two and very occasionally three nuclei are seen in the one cell. The neucleus stains very deeply, especially round the periphery, and throughout its body there are seen many coarse chromation granules. It is generally eccentrically placed. The protoplasm stains characteristically, as already described, and is very/

very dense but does not contain free granules. Councilman has ascribed to the fully formed plasma cell the power of amoeboid movement and the great irregularity of shape, often exhibited by them is certainly very suggestive of this phenomenon. He also described and figured mitotic figures and considered that this process of division was of frequent occurrence but the most careful search has failed to detect any such appearances in the specimens examined.

In case No. XX1, which shews these cells in their earliest stage, they are found to be situated in the boundary zone and pyramidal portion of the section. They lie between the tubules, in groups of two or three together, and frequently are seen inside the smaller vessels but are never found within the tubules. In this case the cortical tissue is quite free from infiltration and the presence of these cells during the early stage is unassociated with any marked emigration of leucocytes or with any great degree of tubular degeneration. In the majority of cases however, these plasma cells are found, together with emigrated leucocytes and desquamated epithelial cells, in the form of small areas situated in the superficial cortex and having a distinct relationship to the Malpighian corpuscles, while in the most advanced cases large tracts of the cortical tissue are replaced by the infiltrating cells, and in the pyramidal portion the cells are seen lying between the tubules in large numbers.

There have been many opinions held as regards the origin of these plasma cells. Originally no distinction was made between them and the emigrated leucocytes and their presence was ascribed to a septic state dependent, in all probability, upon the throat condition. Subsequently they were looked upon as derivaties from the proliferation of the connective tissue cells and in 1897 Councilman enunciated the theory that they were derived by proliferation of the capillary/

capillary endothelium. In the following year, however, he changed his opinion and then concluded that they owed their origin to the blood and were mono-nucleated leucocytes in an altered condition and to this source their origin is at present ascribed. That they are distinct from the poly-morpho-nucleated leucocyte is quite evident when the differences in the structures of each are considered and there is no difficulty in differentiating them from the degenerated epithelial cells; but between them and the mono-nucleated leucocyte, the differences are not so marked and in the areas of infiltration there are frequently seen cells, which it is difficult to differentiate either as mononuclear leucocytes or plasma cells and which are in all probability transitional from between the two. In the case of their origin being due to proliferation of the connective tissue cells it is difficult to understand how so many cells could originate from so small an amount of tissue and also it must be remembered that in the adult kidney nearly all the connective tissue is limited to the pyramidal portion of the organ whereas these cells are found in very large numbers in the cortex. Further the absolute dissimilarity both as regards staining reactions and minute anatomy between these cells and the connective tissue corpuscles is a strong factor in opposition to this view. The former objection holds in regard to their origin by proliferation of the capillary endothelium and it is to be noted further that these cells are quite distinguishable and different in character from the cells, which are found in the glomerular capillaries in the cases of Class I. and which are undoubtedly derived from the endothelium lining the capillaries. On the other hand in support of the view that they originate from the blood are the facts that they are frequently seen in the interior of vessels and that, even when present in large numbers, they have a distinct relationship to the intertubular arteries./

arteries. Also as regards their origin from mono-nucleated leucocytes there is the similarity in structure between the two cells. They are both large cells with eccentrically placed nuclei and in each case the protoplasm forms a large part of the cell, is non-granular and is basophilic in its staining reactions while the only marked difference between them is in the staining power of their nuclei. Further the probability of their being possessed of the power of amoeboid movement is in favour of this origin and the fact that they are occasionally seen in the act of passing through the vessel wall strongly supports this view. Finally it is to be stated that this transformation from the leucocyte to the plasma cell takes place in the blood vessels as well as in the tissues, as is proved by the fact that fully formed plasma cells are found in both situations.

Although it has been definitely shown that the plasma cells are derived from the mono-nucleated leucocytes of the blood the significance of their presence in the interstitial tissue is still a matter of doubt. Considering their origin it would be expected that they would have a protective influence but this is very doubtful. That they are not acting as phagocytes is certain and some observers state that they are to be seen situated in the interior of other cells, apparently undergoing digestion, but this is not found in the present circumstances. Their migration from the blood vessels may be due to a positive chemiotaxis but, if this is the case, the chemiotoctic influence must arise from toxins as the presence of bacteria in any of the sections examined could not be demonstrated and no protozoan parasite was seen. In view of the fact that they only occur in late cases it has been suggested that they have a reparative function but this view is incompatible with their origin from mono-nucleated leucocytes/

cocytes and there is no evidence of their being able to form new tissue. On the other hand their presence in any number is always associated with great tissue destruction,and considering the close relationship between these cells and the degenerated tubules and also the fact that such a degree of tubular degeneration is never found in any of the specimens unless the cells are present in very considerable numbers, it seems most probable that they are an important factor in the production of this tubular degeneration. Beyond this the part played by the plasma cell is still a matter of doubt.

In addition to the plasma cells other elements are seen in the areas of infiltration. There are many polymorpho-nucleated leucocytes, which are found lying both between the tubules and sometimes inside these structures. Lymphocytes are present,and transitional forms between the leucocytes and plasma cells, as already described, are seen in much smaller numbers. Epithelial cells in various stages of degeneration, derived from the disintegrating tubules, are present in large numbers and frequently a few red corpuscles are found.

## Tubular Degeneration.

These areas of infiltration are the seat of very marked tubular degeneration, so much so that in the central portions no tubular structure is left. All the epithelial cells have become separated from their basement membranes and from one another and are seen lying separately among the other elements. Towards the periphery of these areas the degeneration is less marked but the tubules are unduly separated from one another, the intervening spaces being filled up with infiltrating cells. The degenerative changes,taking place in the tubular, epithelium are as follows:- Firstly, the cell protoplasm becomes granular. This is followed by swelling of the cell so that the lumen of the tubule is nearly or completely lost and at the same time the neucleus/

nucleus becomes denser and stains more deeply throughout its whole body while the chromatin granules, as individual elements, are lost. The cells next become separated from their basement membranes and from one another and so the basement membrane is the last remains of the tubular structure. The membrane remains for a time after the desquamation of the cells but eventually becomes broken up and thus the tubular structure is lost. Many of the cells remain in this stage of degeneration but in others there is a further destruction. The nuclear membrane appears to rupture and instead of the pyknotic nucleus there are seen scattered through the cell many deeply staining granules. This rupture of the nuclear membrane takes place on one side only so that,while a portion of the outline and body of the nucleus remain intact,the chromatin granules of the rest of it become scattered throughout the cell,and in places,showing the most marked degeneration,they are also scattered about in the intercellular spaces. Eventually the nucleus disappears entirely and only a mass of granular protoplasm is left. In these areas of degeneration no hyaline change of the cell protoplasm is ever found.

A few of these epithelial cells exhibit appearances very suggestive of phagocytosis, the cells that are being digested being most frequently red blood corpuscles and very occasionally polymorpho-nuccleated leucocytes. The corpuscle or leucocytes are seen to be situated inside the cell protoplasm and are surrounded by a distinct clear zone. The latter cells are always much degenerated. Lyon[29] has described phagocytosis in the kidneys of rabbits poisoned with Diphtheria toxin but in his cases it was always the cells of the collecting tubules that showed this phenomenon and the cells otherwise were apparently in a normal condition. In the present cases it is only seen in the cells of the convoluted tubules and only in these after they have become/

come separated from their basement membrane and from one another. This phagocytosis is always associated with considerable tubular destruction and is only seen in cases showing a marked degree of infiltration.

In addition to this marked destruction of the tubules in the areas of cellular infiltration there is considerable tubular degeneration of the granular variety in other parts of the section and many of the cells in the convoluted tubules and ascending loops of Henle show fatty degeneration. Also many of the smaller vessels exhibit a slight degree of hyaline degeneration while a few cases show hyaline thickening of Bowman's capsule and occasionally some very slight increase in the number of nuclei seen in the glomeruli. All these changes however have been fully described and do not require to be referred to in any detail here.

---

These pathological alterations of the kidney, which have just been described, are collectively known as acute intestitial nephritis and they occur with great regularity under certain circumstances. With the exception of three specimens ,all the cases examined in this work, which were not complicated with late Scarlatinal nephritis and,which survived for a period of six days or longer from the commencement of the fever, exhibited these conditions. And apart from these circumstances the cellular infiltration is never found. In some text books plates are given showing a marked degree of glomerular nephritis together with an interstitial infiltration and these conditions are represented as being those usually found in Scarlatinal nephritis. This seems entirely erroneous as the interstitial infiltration has never been found associated with any marked degree of glomerular nephritis and does not occur in cases which,during life,showed signs of nephritis. In some cases of glomerular nephritis there is a limited leucocytic infiltration of the tissue immediately surrounding the Malpighian corpuscles but the infiltrating cells are always leucocytes and never have the characters of plasma cells. The degree of development of this infiltration has a direct relationship to the duration of the fever, For in cases No. XXI to No. XXVI, which survived for periods of from six to thirteen days, it is seen to occur as small localized areas, while in the remaining cases, which died from the thirteenth day onward, it is more generalized and in the last two specimens examined the greater part of the cortex has been replaced by the infiltrating cells.

In spite of this very considerable destruction of the tubules it is a remarkable fact that the character of the urine was very little affected. In a few cases there was some diminution of the quantity passed and in five instances there was a very faint trace of albumen but in the remainder of the cases it was normal. Also it is to be noted that none of the patients showed any marked symptoms of uraemic poisoning beyond some restlessness and delirium. The former fact would point to the Malpighian corpuscles as being the structures through which the albuminous constituents of the urine are excreted, for in this class these structures showed only very slight degeneration, and this deduction is further supported by the fact that cases, which were associated with considerable albuminuria during life exhibited marked degeneration of the glomerular capillaries and proliferation of the capsular epithelium, as was shown in Class I.

## TABLE OF CASES IN CLASS III.

| No. of Case. | Day of illness on admission. | Day of Death. | Urine. | 7777 | Pathological changes in the Kidney. |
|---|---|---|---|---|---|
| 20. S. W. | 2nd | 8th | No Albumen. | | Plasma cells in pyramidal and boundary zone. Capsular debris. Hyaline degeneration of capillaries. Granular degeneration and disintegration of protoplasm in tubular cells. Desquamation in ascending loop of Henle. |
| 21. L. B. | 3rd. | 6th | Faint trace of albumen. | | Areas of plasma cells. Capsular thickening. Very slight increase of nuclei. Hyaline degeneration of afferent vessels and capillaries. Granular degeneration and disintegration of tubular cells. |
| 22. J. A.<br>Pneumonic consolidation of right lung found post mortem. | 3rd. | 9th. | No albumen. | | Small areas of infiltration and tubular degeneration. Capsular thickening and very slight proliferation. Dilatation of the afferent vessels. Hyaline degeneration of afferent arterioles and capillaries. Granular degeneration in tubules. Desquamation in ascending loop of Henle. |
| 23. C. S.<br>Complicated with Broncho-pneumonia. | 2nd. | 10th. | Trace of albumen.<br>Diminished in quantity. | | Small areas of infiltration and tubular degeneration Very slight increase in number of nuclei in glomeruli. Slight separation of tubules, and granular and hyaline degeneration in these structures. Hyaline globules in tubules, intestitial tissue and capsular spaces. |
| 24. L. D. | ? | ? | ? | | Small areas of infiltration and degeneration. Marked nuclear fragmentation. Hyaline degeneration of afferent vessels. Granular degeneration of tubular cells. |
| 25. Mrs. D.<br>Complicated with Puerperal fever. | 2nd | 10th | Trace of albumen. | | Large areas of infiltration and degeneration. Marked nuclear fragmentation. Some separation of tubules. Granular degeneration and disintegration of tubular cells Desquamation and proliferation in ascending loop of Henle. Slight quantity of capsular debris. |
| 26. E. M'C. | 3rd. | 24th | No albumen. | | Areas of infiltration and degeneration. Nuclear fragmentation. Phagycytosis. Capsular debris. Hyaline degeneration of afferent vessels and capillaries. Granular degeneration of tubular epithelium. |
| 27. J. D. | 3rd. | 18th | Trace of albumen.<br>Diminished in quantity. | | Considerable infiltration and degeneration. Nuclear fragmentation. Slight separation of tubules. Hyaline degeneration of afferent vessels, granular degeneration of tubular cells. |
| 28. J. M'K.<br>Commencing endocarditis found post mortem. | 3rd. | 20th | No albumen. | | Much infiltration and degeneration. Marked nuclear fragmentation. Phagocytosis. Very slight increase in number of glomeruli. Slight hyaline degeneration afferent vessels. |
| 29. L. W. | ? | ? | Very small amount of albumen. | | Marked infiltration and degeneration. Capsular debris. Granular degeneration of tubular cells. |

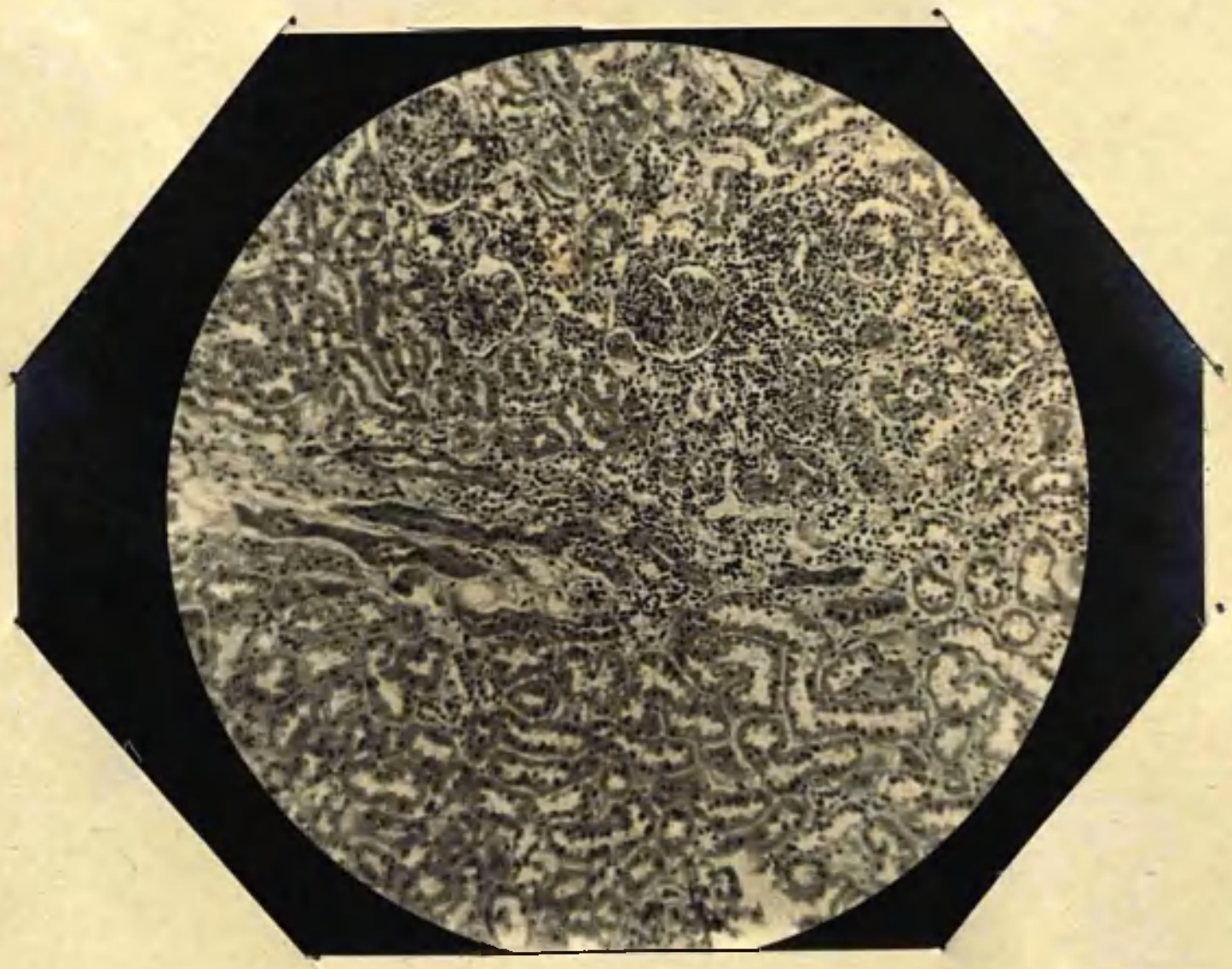

# PLATE XV.

Section from Case No. 22, showing an area of infiltrating cells. Low power.

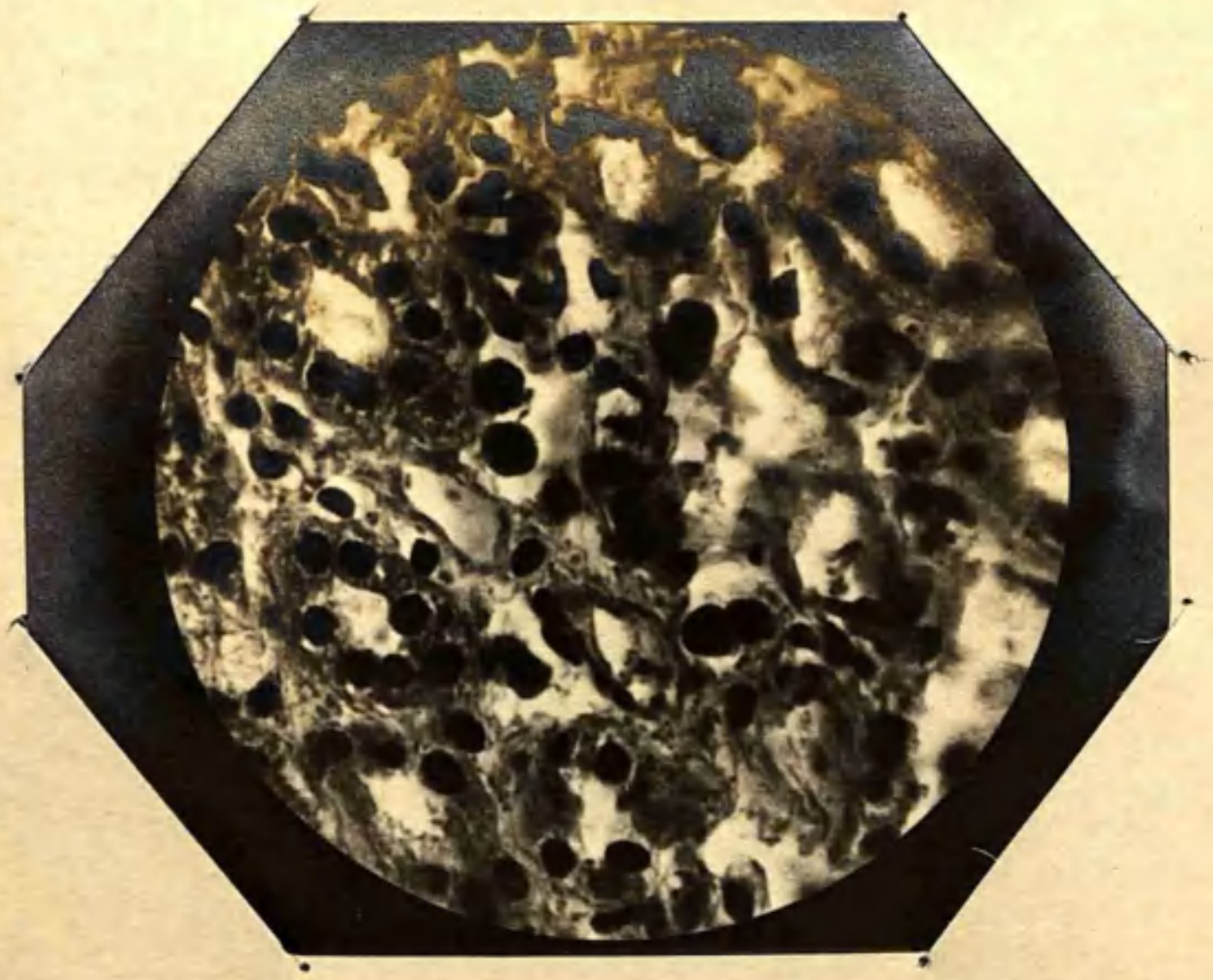

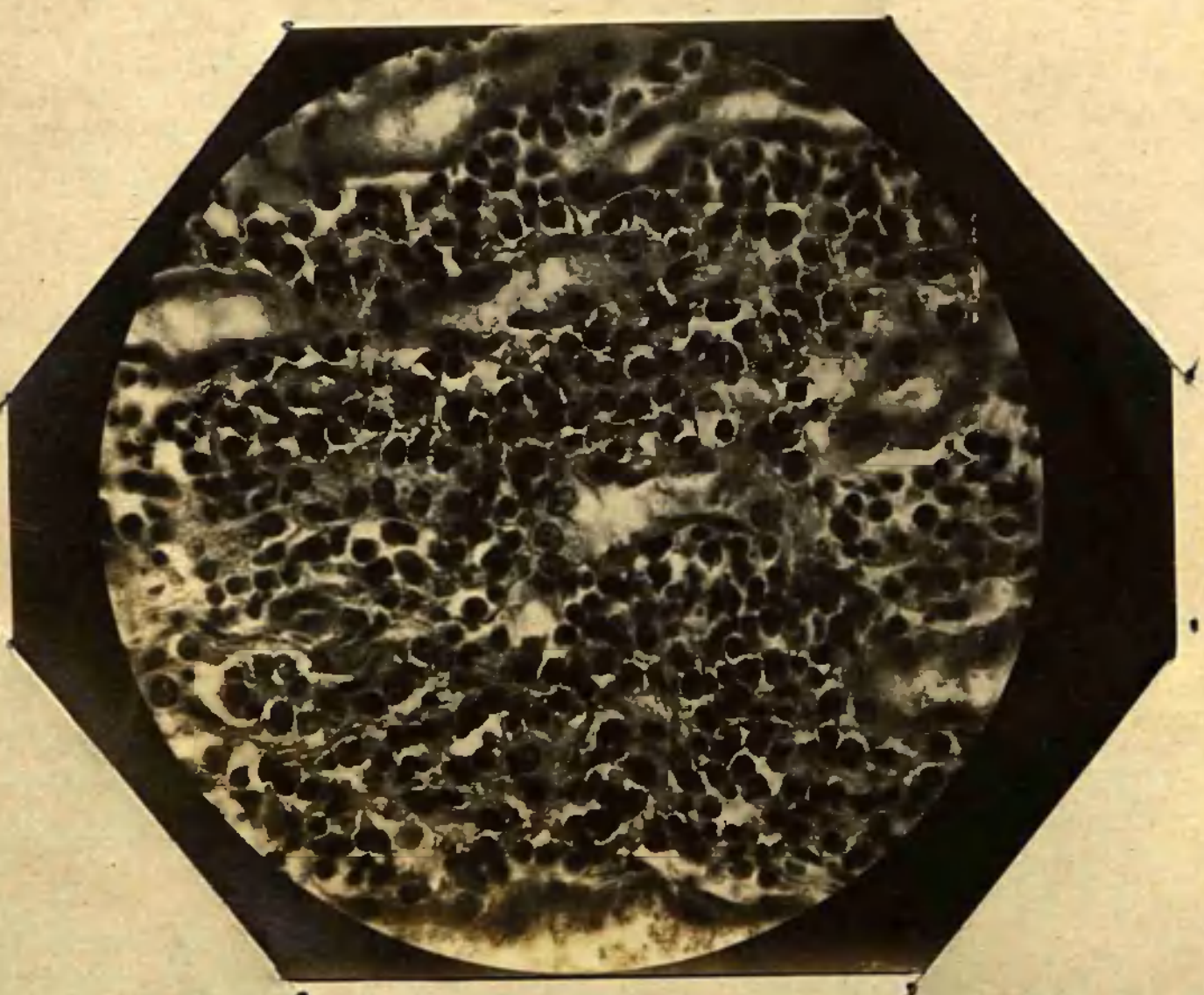

## PLATE XVI.

Fig. 1. Section through pyramidal portion of kidney from Case No. 20. High magnification. Between the collecting tubules are seen a few plasma cells in groups of two or three together.

Fig. II. Section through the cortex from Case No. 29, showing marked cellular infiltration and tubular degeneration. High power.

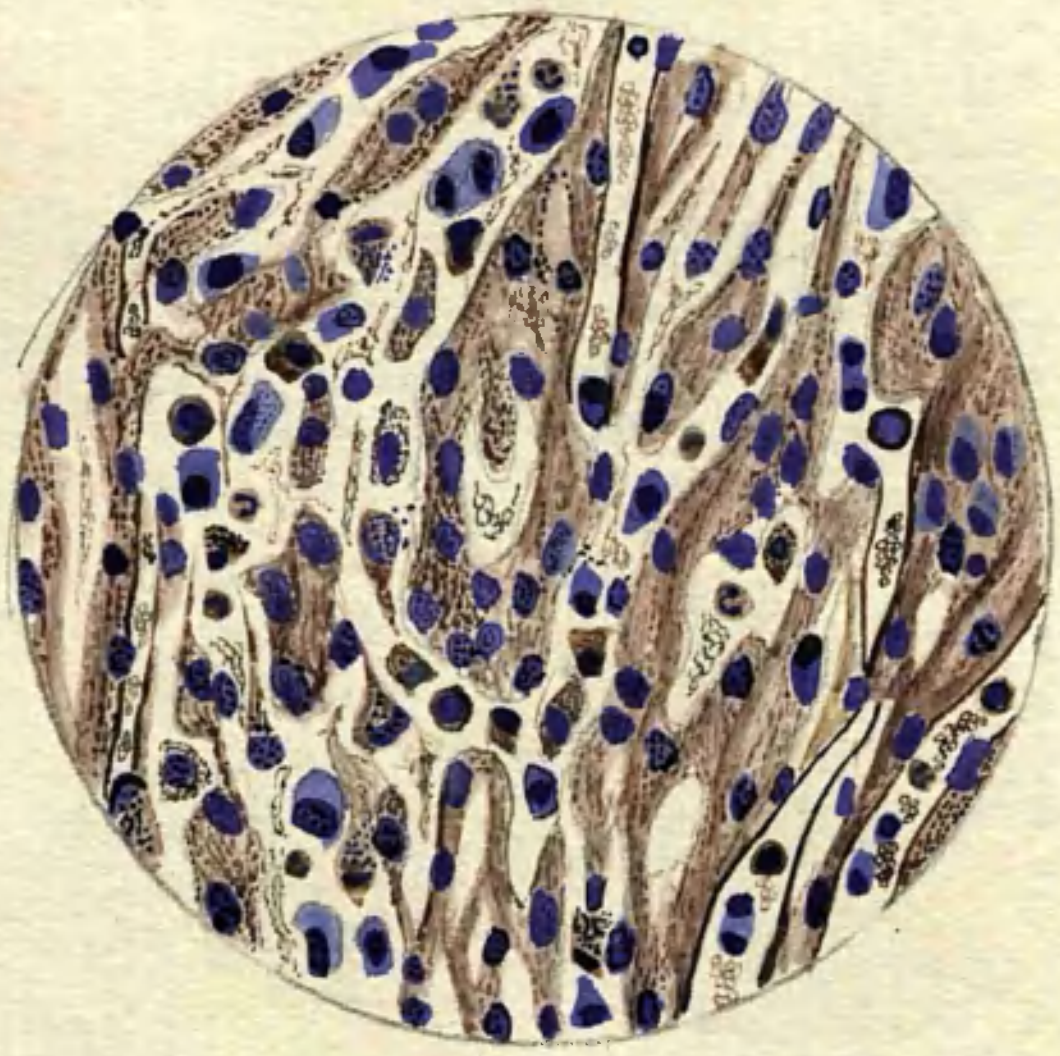

## PLATE XVII.

Section through cortical tissue of kidney from Case No. 28, showing cellular infiltration and tubular degeneration. The section was stained with Polychrome-Methylene Blue and Orcein. The staining reaction of the Plasma Cells and degenerating epithelial cells are well shown. The nuclear fragmentation of the degenerating cells is also represented.

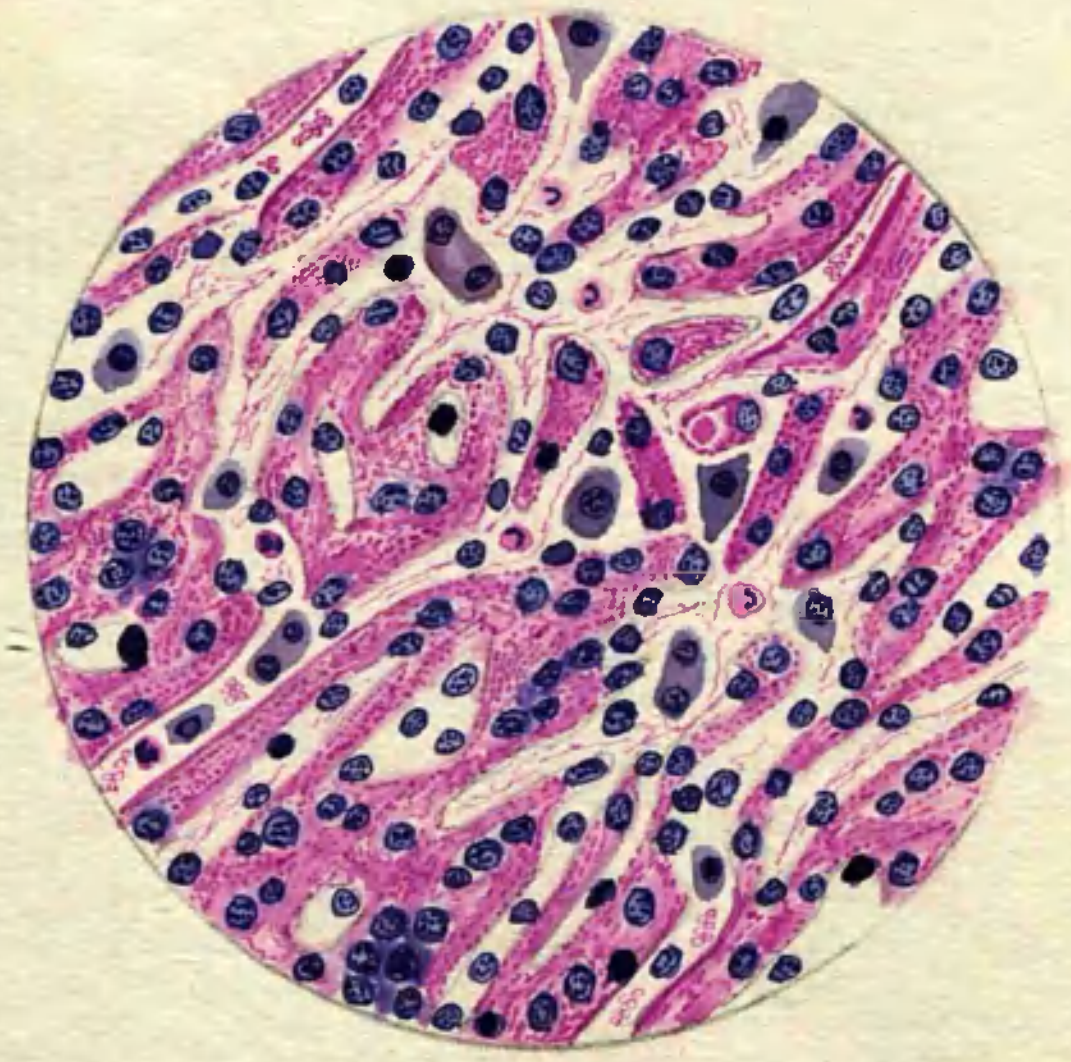

# PLATE XVIII.

Section through cortical tissue of kidney from Case No. 27, stained with Alum-haematoxylin and Eosin, showing interstitial infiltration and tubular degeneration. The plasma cells are seen both in the interstitial tissue and in the smaller blood vessels. Their staining reaction as compared with the degenerating epithelial cells is well shown. There is also seen a polymorpho-nucleated leucocyte in process of being digested by a degenerating epithelial cell.

# SUMMARY.

This examination of the renal tissue of patients, dying during an attack of Scarlet Fever, was undertaken with a view to ascertaining the various pathological alterations found at different stages in the course of the fever and of finding out how far some of the clinical features of the cases could be accounted for by the pathological changes. The cases were divided into three groups, the divisions being originally based upon their clinical features and it was found that the pathological changes coincided with this classification.

Under Class I. Cases, with a definite history of acute nephritis commencing about the third week, were discussed. In these the changes were always well marked and were most characteristic. They primarily affected the Malpighian corpuscles and consisted of proliferative and degenerative changes of the glomerular capillaries, of the afferent vessels and of the cells in Bowman's capsules. The tubular changes were less characteristic and were largely secondary to the alterations in the Malpighian corpuscles. In connection with the primary changes it was shown that all of them, if sufficiently advanced would cause a diminution in the quantity of urine excreted and this fact is fully borne out by reference to the clinical histories of the cases. It was found that the albuminuria was most probably ascribable to the changes in the Malpighian corpuscles and that the haematuria arose from direct haemorrhage into the tubules. Tube-casts, both in process of formation and in the fully formed state, were frequently found, and it was pointed out that all tube casts, reaching the urine, were most probably formed in the smaller junctional tubules and that their granular portions resulted from the disintegration of the cells of the convoluted tubules/

tubules and ascending loops of Henle while their epithelial elements were derived from the desquamated cells of the latter structure.

The second class included cases dying within a few days of the onset of the fever. In these specimens the pathological changes were neither so marked nor so characteristic. They consisted of granular and hyaline degeneration of the tubular epithelium,desquamation and proliferation of the cells in the ascending limbs of Henle and hyaline changes in the smaller blood vessels. Of these changes special reference is drawn to the hyaline degeneration of the tubules with the subsequent disintegration of the cells and the liberation of the hyaline globules into the interior of the tubules and into the interstitial tissue and also to the proliferation of the cells in the ascending portions of Henle's loops, neither of which conditions have been previously described in detail.

Under class III, cases, dying after a period of six days or more were described and in these the morbid changes consisted of an infiltration of the interstitial tissue with cells, derived from the blood, together with a high degree of tubular degeneration. It was found that this infiltration varied in its intensity according to the duration of the fever and was never present before the sixth day and was evident from that day onwards in all cases except three.

It is thus seen that although most of the structures in the kidney may be affected during an attack of Scarlet Fever, the pathological changes present are definitely related to certain clinical phenomena and occur at certain stages in the course of the disease. Firstly, there is a glomerular nephritis occurring in cases, which during life showed unequivocal evidence of adute nephritis; secondly, there is a degenerative nephritis found in very severe cases dying within a few days of the onset of the illness, and lastly, there is an/

an acute interstitial nephritis associated with severe cases, which survived for a longer period than six days from the commencement of the fever.

---

[illegible] 884. [illegible] sur la pathologie [illegible]
Paris page 148.

Virchow's Archiv. Bd. [illegible] S 107.

[illegible] Trans. Assoc. American Physicians, Vo[illegible]

[illegible] Virchow's Archiv [illegible]

[illegible] Surgical [illegible]

[illegible] Reports of the Medical Officer of the [illegible]
Council. Vol.VIII. Page [illegible]

1877. Trans.Path.Society, London. Vol. [illegible]

1874. British Medical Journal. Vol.II.

1874. Archiv de physiol [illegible] path. Paris.

1875. [illegible] Cyclopaedia of the Practice [illegible]
[illegible] Vol.II, page [illegible]

[illegible] Renal and [illegible] Affections. page

1877. Atlas of Pathology. New Sydenham [illegible]

1880. Trans.Path.Society London. Vol [illegible]

1882. [illegible] Medicine, [illegible]
[illegible] Principles of Medicine [illegible]

[illegible] Archiv. [illegible]
[illegible]

## REFERENCES.

1. BRISTOWE. Pathological Transactions. Vol.III. page 235.
2. KLEBS. 1869. Handbook Path. Anatomy. Vol.II. page 645.
3. RINDFLEISCH. 1873. Pathological Histology. Vol.II. page 152.
4. KLESH AND KEINER. 1882. Archiv. de physiol normet path.Paris, page 278.
5. CORNIL ET BRAULT. 1884. Etudes sur la pathologie du rein, Paris page 149.
6. LANGHANS. 1885. Virchow's Archiv. Bd. gg. S 193.
7. WELCH. 1886. Trans.Assoc.American Physicians. Vol. I.
8. RIBBERT. 1897. Virchow's Archiv. Bd. 150. S.391.
9. Councilman. 1897. Med.and Surgical Reports Boston City Hospital.
10. KLEIN. 1875. Reports of the Medical Officer of the Privy Council. Vol.VIII. Page 60.
11. KLEIN, 1877. Trans.Path.Scoiety, London. Vol. 28.
12. COATS. 1874. British Medical Journal. Vol.II.
13. KELSH. 1874. Archiv.de physiol norm et path.Paris.page 722.
14. THOMAS. 1875. Ziemsen's Cyclopoedia of the Practice of Medicine. Vol.II, page 230.
15. DICKENSON.1877. Renal and Urinary affections. page 94.
16. GREENFIELD. 1875. Atlas of Pathology. New Sydenham Society.
17. GREENFIELD. 1880. Trans.Path.Society London. Vol 31. page 157.
18. FRIEDLANDER. 1883. Fortschritte der Medicine. Bd.I. S.86. Nothnagel Practice of Medicine page 540.
19. WAGNER. Deutsches Archiv.fur Klinische Medicine Bd.25. S.529.
20. CROOKE 1886 Birmingham Medical Review. Vol.II.
21. COUNCILMAN 1898 Journal of Experimental Medicine. Vol.III.
22. HOCHE. 1904. Les lesions du Rein. Paris. page 40.
23. HERRING. Journal Path. and Bacteriol. Vol.VI.page 459.

24./

24. VON RECKLINGHAUSEN. Handbuck der Allgemeinen des Kreislaups Pathologie. page 404.

25. COATS. Manual of Pathology. page 813.

26. SCHAFER AND SYMINGTON. Quain's Anatomy. Vol III.part IV. page 192.

27. HEIDENHAIN. Handbook der Physiologie. Herman. Vol V. page 345.

28. UNNA. Histopathology of the diseases of the Skin. Plate I.

29. LYON. JOURNAL Path.and Bacteriol. Edin. and London Vol IX. page 426.

## Books and Papers consulted but not referred to in Text.

30. Barlow. Pathological Anatomy and Histology.

31. Beattie. Journal Path. and Bacteriol. Edin & London Vol. VIII. page 129.

32. Beattie. Brit.Med.Journal 1904 Vol II page 587.

33. Burmeister. Virchow's Archiv. 1894. Bd.137. S.405.

34. Corbett. Treatise on Acute Infectious Exanthemata page 200.

35. Davidsohn. Virchow's Archiv. 1897. Bd.150.S.16.

36. Da Costa. Clinical Haematology. Page 424.

37. Ehrlich and Lazarus. Histology of the Blood.

38. Fagge. Principles and Practice of Medicine. Vol.II page 447.

39. Gairdner. Glasg. Med. Jour. 1884.

40. Gull and Sutton. Path.Trans.London. 1877. Vol 28.

41. Handford. Path. Trans. London. 1890. Vol 41. page 156.

42. Von Jungensen. Nöthnagel System of Medicine. page 443.

43. Lindermann. Ann. de l'Inst Pasteur, Paris.1900. Tome 14, page 49.

44. Lubarsch. Virchow's Archiv. 1897. Bd.150 S.471.

45. MacCallum. Brit.Med.Jour.1904, Vol II.page 596.

46. Miller. Jour.Path.and Bact.Edin and London.Vol X. page 23.

47/

47. Muir. Jour.Path.and Bact.Edin. and London, Vol VII page 161.

48. Muir. Brit.Med.Jour.1904 Vol.II.page 585.

49. Munk and Leyden. Virchow's Archiv.1862. Bd.22 S.237.

50. Norvak. Ann.de l'Inst Pasteur. Paris.1898. Tome 12 page 369.

51. Papperheim. Virchow's Archiv. Bd.165. S.365.

52. Roberts. Urinary and Renal Diseases. 1885.

53. Rotch. Pediatries,, 1904. page 552.

54. Grainger-Stewart. Practical Treatise on Bright's Disease.

55. Thomson. Medico-Chirurgical Trans.London Vol 69.

56. Wilson. Cell in Development and Inheritance.

57. Ziegler. Lehrbruch der Pathologischer Anatomie, B and II.

# CLINICAL HISTORIES OF CASES WITH POST-MORTEM REPORTS AND INDIVIDUAL PATHOLOGICAL ALTERATIONS.

## CLASS 1.

CASE 1:-

H.W., aged 2. Admitted on June 17th, 1904.

No symptoms were observed until the day before admission into hospital, when it was noted that the patient's whole body was swollen. On the evening of the same day he complained of feeling sick and of a sore-throat, and vomited several times.

On admission the child was almost in a moribund condition. The temperature registered 101.4, the pulse numbered 144, and the respirations averaged 92 per minute. He was pale and anaemic and there was some swelling of the face, and also to a less degree of the feet and legs. There was some commencing desquamation of the skin on the toes. The respirations were very hurried and examination of the chest showed some impairment of the percussion sound over the left side behind; over this area the breath sounds were very tubular in quality and inspiration was accompanied by abundant mucous rales. Clear serous fluid was obtained by aspirating with a hypodermic needle. Over the rest of the chest the breath sounds were accompanied by coarse mucous rales. The heart was normal. Only a small quantity of urine was obtained and this contained a large deposit of albumen upon boiling and a trace of blood. Microscopical examination showed the presence of a large number of granular and of a few hyaline casts. There were numerous red blood cells and a considerable quantity of epithelial debris. The patient did not rally and died 25 hours after admission.

The most marked changes found in the kidney were situated in the Malpighian corpuscles. The glomeruli were prominent and for the most part filled the Bowman's capsules. In places, where there was any space/

space between the capsule and the capillary tuft,it was largely occupied by granular material. The number of nuclei in the glomeruli were excessive and the glomerular capillaries, when their outlines could be distinguished, were seen to contain many cells and small masses of non-nucleated granular material. The walls of the capillaries were swollen. In many of the glomeruli the capillary structure was nearly lost and the glomerular capsule appeared to be filled with a more or less structureless mass, in which were embedded numerous nuclei. Some of these nuclei had the characters of the polymorpho-nucleated leucocytes but generally they simulated the nuclei of the endothelial cells of the capillaries. There was some very slight hyaline degeneration of the afferent vessels. Most of the cells in the convoluted tubules showed some granular change and in a few of them the protoplasm had undergone hyaline degeneration. The majority of these tubules contained small quantities of granular material and some of the junctional and collecting tubules were filled with red blood corpuscles. Many of the cells of the ascending loop of Henle had become separated from the basement membrane. Casts in small numbers, consisting of the granular and hyaline varieties, were seen and these mostly occupied the junctional tubules.

---

Case. I.

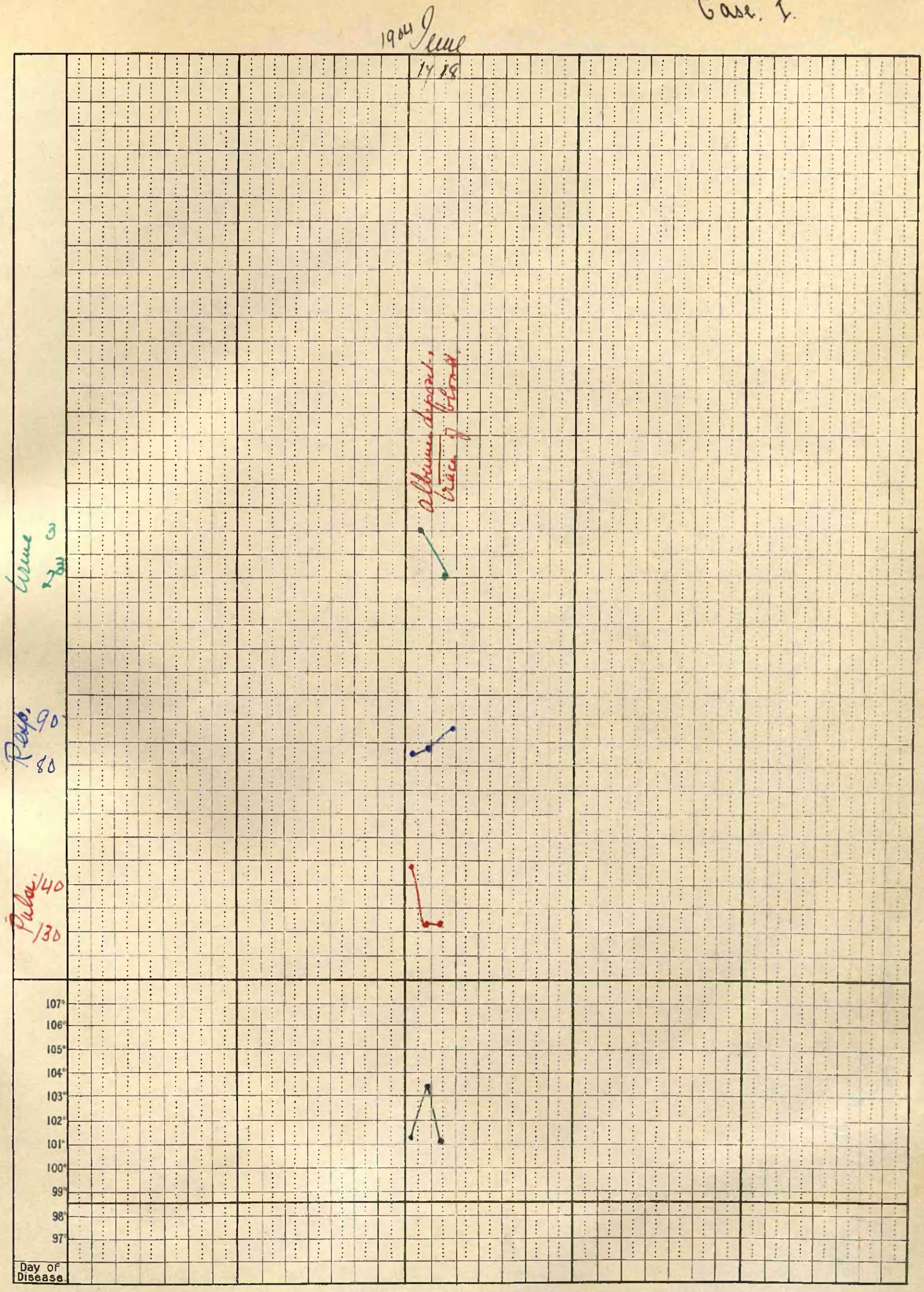
1904 June
17 18
albumin deposit, trace of blood.
Urine 3
℥iii
Resp. 90
80
Pulse 140
130
107°
106°
105°
104°
103°
102°
101°
100°
99°
98°
97°
Day of Disease

CASE 11:-

J.T., aged 6. Admitted on July 12th, 1904.

Patient's sister had been admitted suffering from Scarlet Fever on July 7th, and enquiry elicited the fact that about a fortnight before the onset of the present symptoms a slight rash had been noticed on the skin of this patient, but as he did not appear ill and made no complaint no notice was taken of it.

On admission he was extremely ill. The temperature registered 97.8, and the pulse was soft and numbered 152, and the respirations averaged 45 per minute. The face was pale and slightly puffy but no pitting on pressure was found in any region of the body. There was no visible desquamation. The only indication of a recent attack of Scarlet Fever was a somewhat congested throat, with slightly enlarged glands in the neck. The breathing was difficult and coarse rales were heard all over both lungs. There was relative dullness at the right base and all over this area the breath-sounds were diminished in volume. The abdomen was a little distended and there was slight dullness in both flanks. No urine was available for examination. The patient died on the morning following the day of admission.

Post-mortem examination revealed a considerable quantity of fluid in the right pleural sac and a smaller amount in the left. Both lungs were passively congested. The pericardial sac contained a little clear serous fluid and the heart was normal. Clear serous fuild was found in the peritoneal cavity and the abdominal glands were somewhat enlarged and congested, especially those which drained the ileo-caecal region of the gut. Some of the solitary glands and glands of Peyer were enlarged and the latter were in some instances markedly congested. In the kidney the pyramids were intensely congested, the cortices were not thickened but there were evidences of catarrh, this being most marked in/

in the right kidney.

The Malpighian corpuscles were the seat of the most marked change. There was some slight thickening of some of the Bowman's capsules owing to proliferation of their cells. The capsular spaces contained a little granular material. There was some destruction of the capillary structure and an excessive number of nuclei in the glomeruli. Most of these nuclei had the characters of endothelial cells, but a few were distinctly polymorpho-nucleated leucocytes. The afferent arterioles and some of the capillaries showed slight hyaline degeneration. Many of the afferent vessels and in some instances the glomerular capillaries were dilated and filled with blood corpuscles, and some of the glomerular capillaries had ruptured giving rise to large blood containing spaces. There was some slight separation of the tubules from one another and many of them appeared to be dilated. Most of the cells in the convoluted tubules exhibited some granular degeneration and in a few instances the cell protoplasm had undergone hyaline degeneration, this latter change being associated with loss of the nyclear staining. Some of the convoluted tubules contained small quantities of the granular matter, and hyaline and granular tube-casts were seen in some of the collecting tubules. Many of the collecting tubules and loops of Henle were filled with blood corpuscles, this being most marked in the boundary zone. In the pyramids and boundary zone the vessels were dilated and filled with blood cells.

---

## CASE 111:-

B.T. Admitted on Oct. 5th, 1904.

No symptoms were noticed until the day before admission into hospital when swelling of the face was observed. On admission the patient looked very ill, she was cyanosed and there was swelling of the face and considerable oedema of the body and limbs. The pulse was weak, irregular and numbered 140 and the respirations were laboured and registered 56 per minute. Examination of the chest showed that there was fluid in both pleural sacs. The heart was normal. Only one oz. of urine was obtained and this was dark in colour and smoky in appearance. It contained a considerable quantity of albumen and some blood. Microscopical examination showed numerous blood cells, granular casts, a few hyaline casts and some granular epithelial cells. She became steadily worse and died at 12.5 p.m. on Oct. 6th, thirty-two hours after admission into hospital.

Post-mortem examination showed the presence of some clear serous fluid in both pleural sacs and the lower lobes of both lungs were collapsed, firm in consistence and dark red in colour. The heart muscle was pale but the valves were normal. There was no fluid in the peritoneal cavity and the liver was passively congested. Both kidneys were of normal size. There was much congestion of the pyramids and the cortices were pale and slightly swollen.

Microscopical examination of the kidneys showed the chief lesion to be situated in the Malpighian corpuscles. The glomeruli were not so prominent as in the two preceding cases but there was some increase in the number of the nuclei present and the increase consisted in the most part of proliferated endothelial cells. The structure of the glomerular capillaries was in places indistinct. The capsular spaces were almost/

almost free from debris, and there was no proliferation of the capsular endothelium. There was some dilation of the afferent arteries and occasionally there was seen some slight hyaline degeneration of the vessels. The epithelium of the convoluted tubules showed a slight amount of granular degeneration and these tubules together with the ascending loops of Henle contained a small amount of granular looking debris. The collecting tubules were normal and did not appear to contain any casts. There were some large extravasations of blood around the intertubular vessels in the cortex.

---

Case. III.

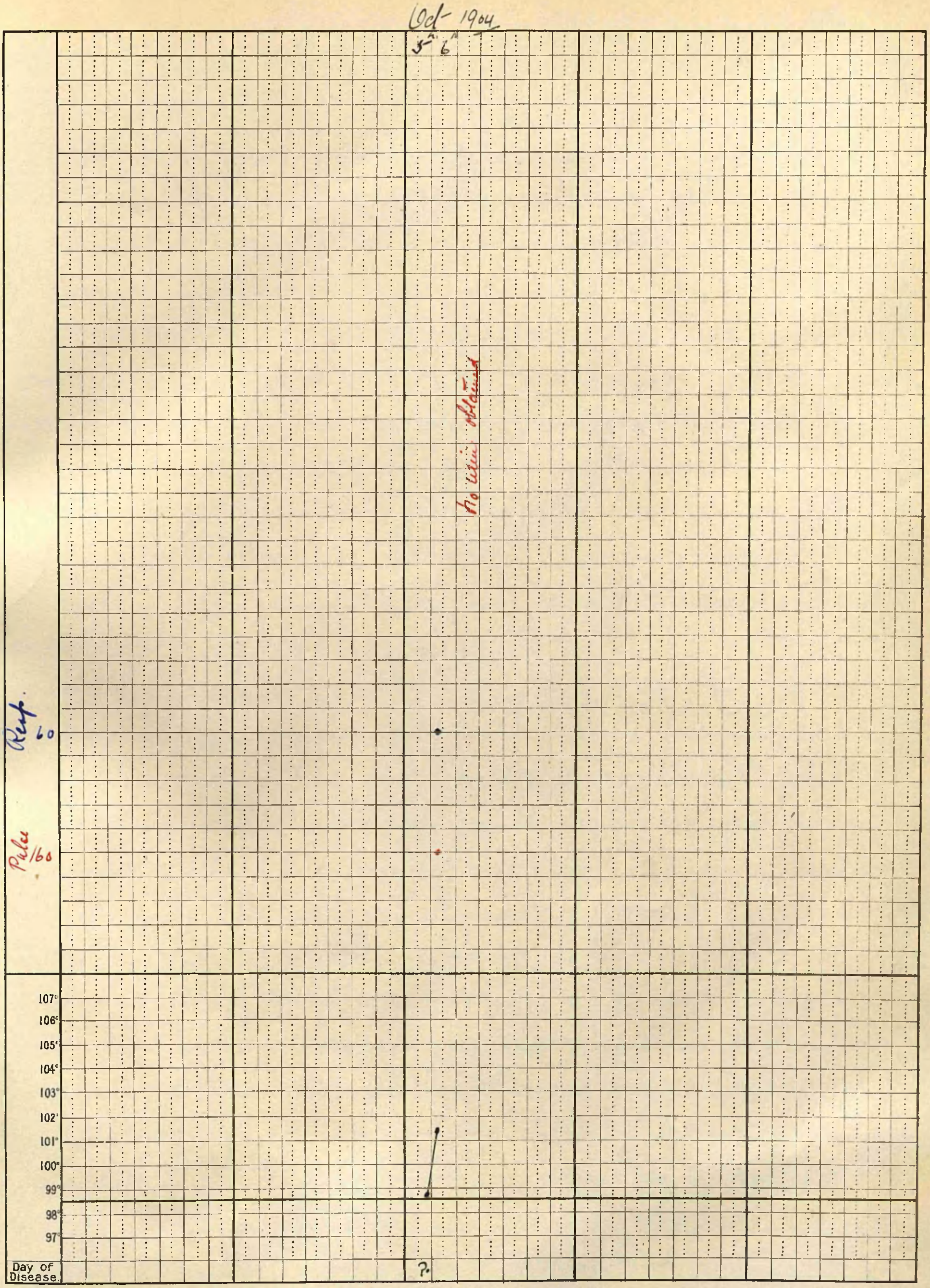
Oct 1904
5th
6th
No urine obtained
Resp.
60
Pulse
160
107°
106°
105°
104°
103°
102°
101°
100°
99°
98°
97°
Day of Disease.
?

CASE 1V:-

A.A., aged 6. Admitted on Dec. 2nd, 1901.

There was nothing noticed about this patient until four days before her admission into hospital when her mother observed that her face was swollen.

On admission the child was extremely ill. The temperature registered 100.6, the pulse was almost imperceptible and the respirations numbered 60 per minute. Her face was very puffy and pale and there was marked general oedema. There was a double cardiac murmur presystolic and systolic in rhythm, best heard over the apex. There was no enlargement of the area of pre-cardial dullness. There were signs of fluid in both pleural sacs. No urine was obtained. The child never rallied and died on the day after admission.

Microscopically some of the Bowman's capsules were swollen and some showed a slight degree of proliferation of the endothelium. There was an increase in the number of the nuclei in the glomeruli, most of them being endothelial in character, and the glomerular structure was in places indistinct. There was a slight amount of hyaline degeneration of the afferent vessels and to a less degree this change was seen in the glomerular capillaries. These vessels were not dilated. The cells in the convoluted tubules were granular but did not appear to be much swollen. The tubules contained a considerable quantity of granular material and in some instances it took the form of a reticulated network. There was some granular degeneration in the ascending loop of Henle and many of the cells had become separated from the basement membrane. Very few tube casts were found and these were mostly granular in character and were situated in the junctional tubes.

---

CASE V:-

G.G. aged 2. Admitted on Aug. 8th, 1904.

Illness began eighteen days before admission into hospital with sore throat and cough. The rash was first seen on the same day.

On admission the temperature registered 102.6, the pulse numbered 128 and the respirations averaged 54 per minute. There was commencing desquamation on the feet and the skin on the body and limbs was harsh and dry. There was some oedema of the body and limbs and some puffiness of the face. The urine, of which only a small quantity was passed, contained blood and albumen. On the day following admission the patient became worse, the temperature being higher, the respirations faster and more shallow and having the characters of the uraemic asthma type and the pupils being dilated. Examination of the chest revealed some fluid in the right pleural sac. The heart was found to be normal. The patient died on Aug. 10th.

Post-mortem examination showed that there was fluid in both pleural sacs and that there was some consolidation of the lower part of the lower lobe of the right lung. The kidneys were congested, especially in the pyramidal portions, and the cortices were swollen and showed some indistinctness of the normal markings.

Microscopically the chief lesion found in the kidney was situated in the Malpighian corpuscles. There was some very slight proliferation of the capsular epithelium and the capsular spaces contained a small amount of granular debris. The capillary structure was in some places indistinct and rarely was seen complete necrosis of a glomerular tuft of capillaries. There was a slight increase in the number of nuclei in the glomeruli. There was no dilation of the afferent vessels or glomerular capillaries. Both these structures however showed very slight/

slight hyaline degeneration. There was slight separation of the tubules from one another and the cells of the convoluted tubules had undergone some degree of granular degeneration while a few showed well-marked hyaline changes. In the ascending loops of Henle the cells had become separated from their basement membranes and in a few of the junctional tubules casts, hyaline, granular and epithelial in character, were seen. The vessels in the pyramidal zone were dilated and filled with blood corpuscles.

---

Case V.

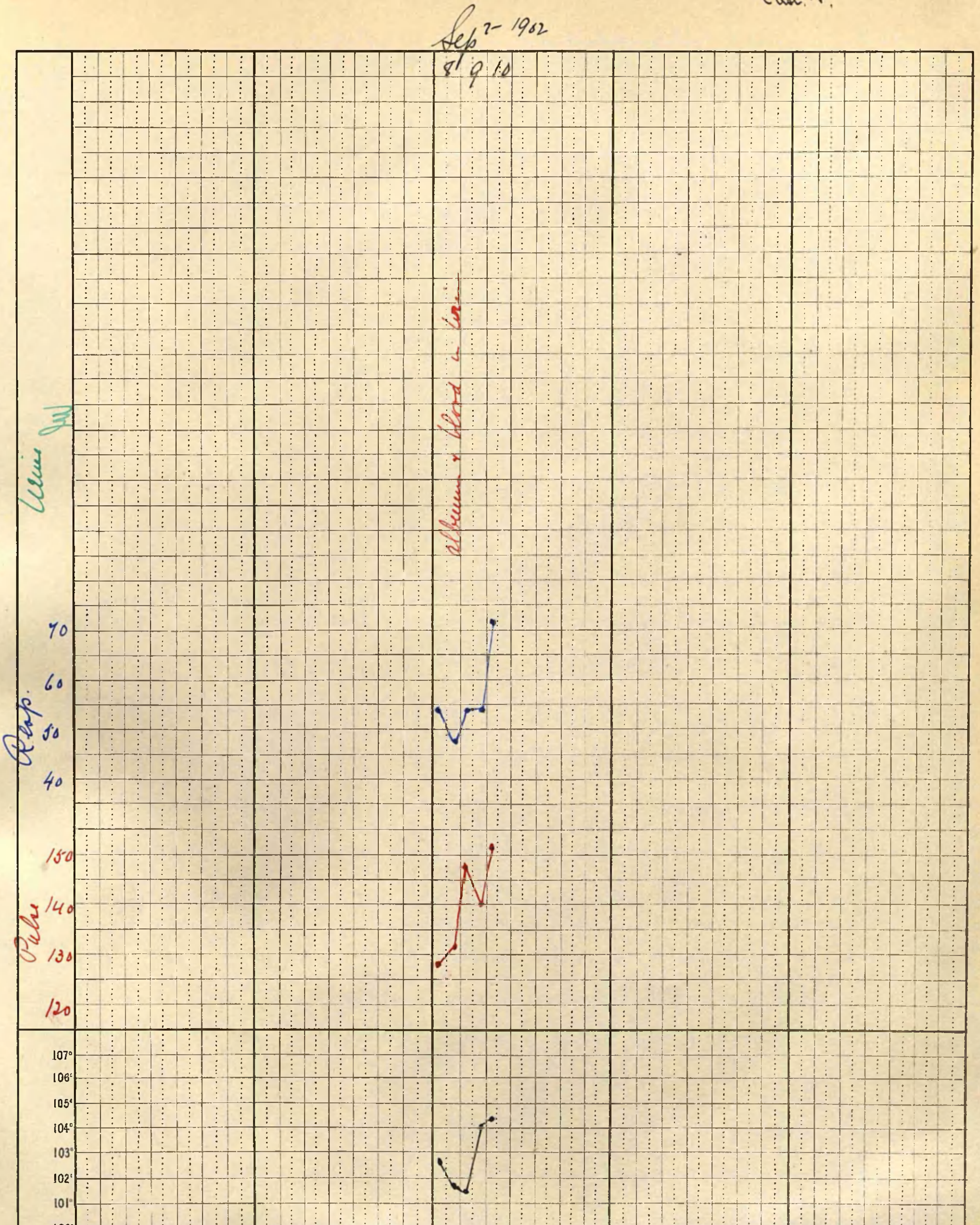
Sep 7 - 1902
8 9 10
Urine
albumen & blood in ur.
Resp.
70
60
50
40
Pulse
150
140
130
120
107°
106°
105°
104°
103°
102°
101°
100°
99°
98°
97°
Day of Disease.
9 10 11

CASE V1:-

J.S., aged 3. Admitted on November 19th,1902.

Illness began about ten days before admission into hospital with sore-throat, sickness and vomiting, and slight cough. The rash was noticed on the second day of illness.

On admission the temperature was 98, the pulse numbered 123 and the respirations averaged 34 per minute. There was no evidence of any previous rash and there was no desquamation. A marked smoothness of the skin on the hands and feet suggested the possibility of desquamation having been completed, There was nothing abnormal in the condition of the tongue or throat and there was no glandular enlargement. The heart and lungs were normal and the urine was free from albumen. The rest of the history of the case is incomplete but it appeared that the patient became the subject of acute nephritis about the 25th day of the illness, at which time there was a marked diminution in the quantity of urine excreted and the presence of albumen was detected. There was no rise of temperature until the day before death when it suddenly entered very high registers. She died about the 30th day of illness.

Microscopical examination of the kidney failed to reveal any proliferation of the capsular epithelium. There was some increase in the number of nuclei in the glomeruli and the glomerular capillary structure was indistinct. The vessels throughout the section were distended with blood corpuscles. Around most of the glomeruli and especially around those in the extreme cortex there was some slight leucocytic infiltration and in some instances there was formation of peri-glomerular connective tissue. Some of the afferent arterioles were dilated and had undergone slight hyaline degeneration. There was some separation of/

of the tubules, and ascending loops of Henle were marked granular and swollen. Some of them exhibited disintegration of the peripheral protoplasm and in a few places hyaline degeneration of the tubular cells was seen. All the tubules contained much granular debris and in some of the convoluted tubules this material had assumed a peculiar form, being found in small separate masses having very much the shape of a half-moon. The junctional and collecting tubules contained many granular and a few hyaline casts.

---

Case. VI.

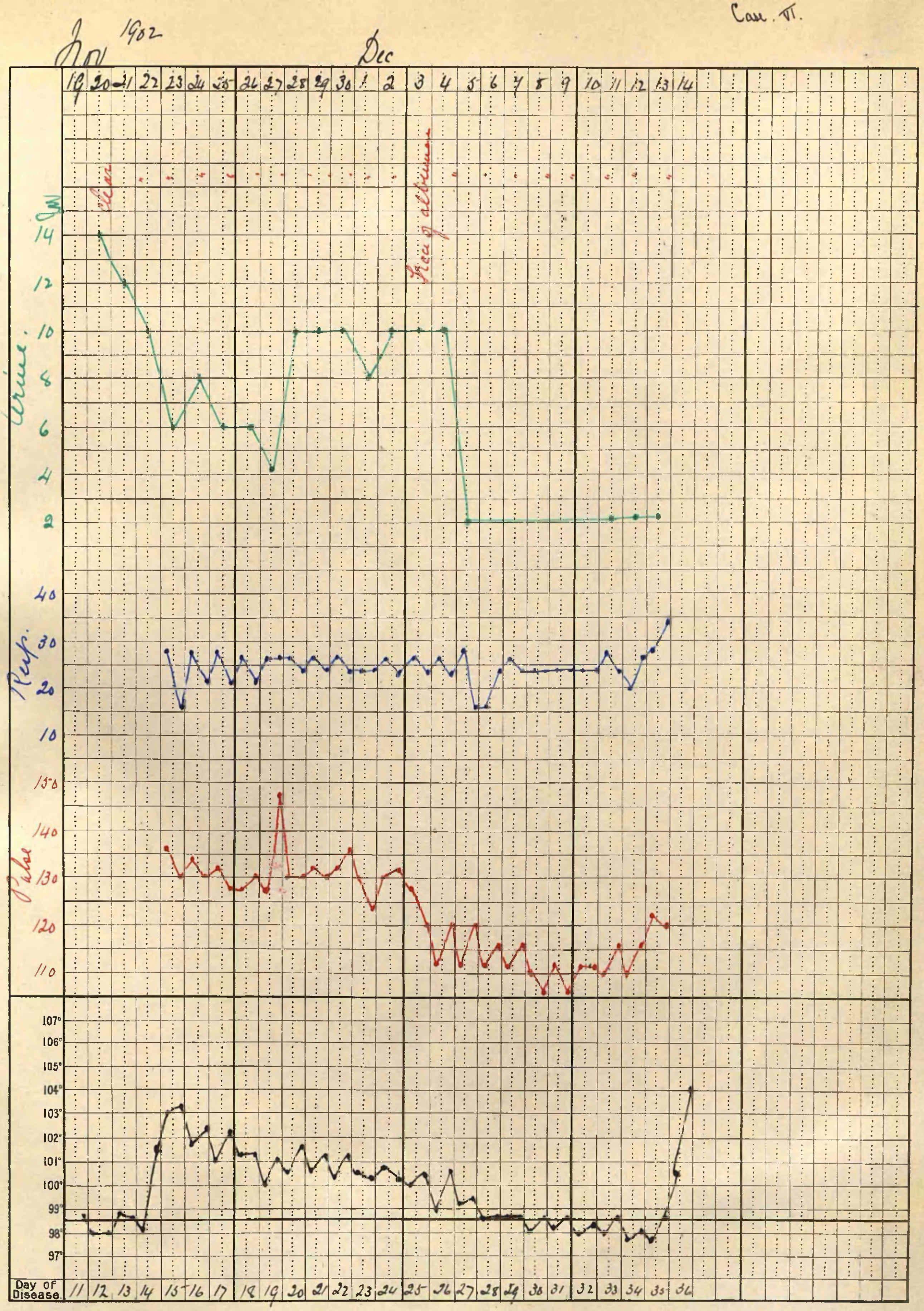
Nov 1902
Dec
19 20 21 22 23 24 25 26 27 28 29 30 1 2 3 4 5 6 7 8 9 10 11 12 13 14
Clear
Trace of albumen
Urine.
oz
14
12
10
8
6
4
2
Resp.
40
30
20
10
Pulse
150
140
130
120
110
107°
106°
105°
104°
103°
102°
101°
100°
99°
98°
97°
Day of Disease.
11 12 13 14 15 16 17 18 19 20 21 22 23 24 25 26 27 28 29 30 31 32 33 34 35 36

CASE V11:-

A.W. aged 6. Admitted on Jan. 23rd, 1903.

Illness began on the day before admission with headache, sickness, vomiting and sore-throat. The rash was first seen on Jan. 23rd.

On admission the temperature was 101.6, the pulse numbered 128 and the respirations averaged 28 per minute. There was a vivid and widespread scarlatinal rash. The tongue was furred and peeling at the edges. The fauces, palate and tonsils were congested and there was slight ulceration of the right tonsil. Examination of the chest and the abdomen was negative and the urine was free from albumen. On Jan. 29th it was noted that the temperature was still febrile and that there was some prolongation of the first sound at the apex but otherwise the patient's condition was satisfactory. The case ran an ordinary course up to March 19th at which time the patient was up and going about. During the afternoon of that day however he complained of headache and the evening temperature was found to be 102.8, while examination of the urine showed that it contained albumen and blood. In the next few days the temperature remained sub-febrile and the urine, which was diminished in quantity, still contained albumen and blood. Microscopical examination of the sediment showed that it contained numerous red and white blood corpuscles and many tube casts. The largest number of these were coarsely granular but there were also many epithelial and a few blood and hyaline casts. From this time onwards the patient steadily grew worse, the amount of urine passed diminished and the quantity of albumen was maintained. He died on March 27th, that being the 43rd day of illness.

Post-mortem examination showed that both the lungs were oedamatous and that the layers of the pleura over the lower lobe of the left lung were adherent. There was no fluid in the pleural sacs. The heart was normal. The spleen was enlarged, weighing 3 ozs., and on section showed/

showed numerous minute hemorrhages. The kidneys weighed 2¼ ozs. , and the capsules were non-adherent. The cortices were thickened and very catarrhal and the pyramids showed marked congestion.

On section it was seen microscopically that some of the Bowman's capsules were swollen and appeared to be thickened although there was no evidence of any proliferation of their cells. The structure of the glomeruli was somewhat indistinct, and there was some increase in the number of nuclei seen in the Malpighian corpuscles. These nuclei mostly had the characters associated with endothelium but there were also a few polymorpho-nucleated leucocytes and lymphocytes present. There was no evident dilation of the afferent vessels but some of them showed distinct hyaline degeneration and this change was also noticeable in some of the larger arteries. There was slight granular degeneration of the cells in the convoluted tubules and also to a more marked degree of the epithelium of the ascending loops of Henle. There was some vacuolation of some of the cells of the collecting tubules and a few granular casts were seen in this situation. Around some of the Malpighian corpuscles most affected there was a slight infiltration of the surrounding tissue with leucocytes and in some instances there appeared to have been some proliferation of the connective tissue cells themselves.

---

Case VII.

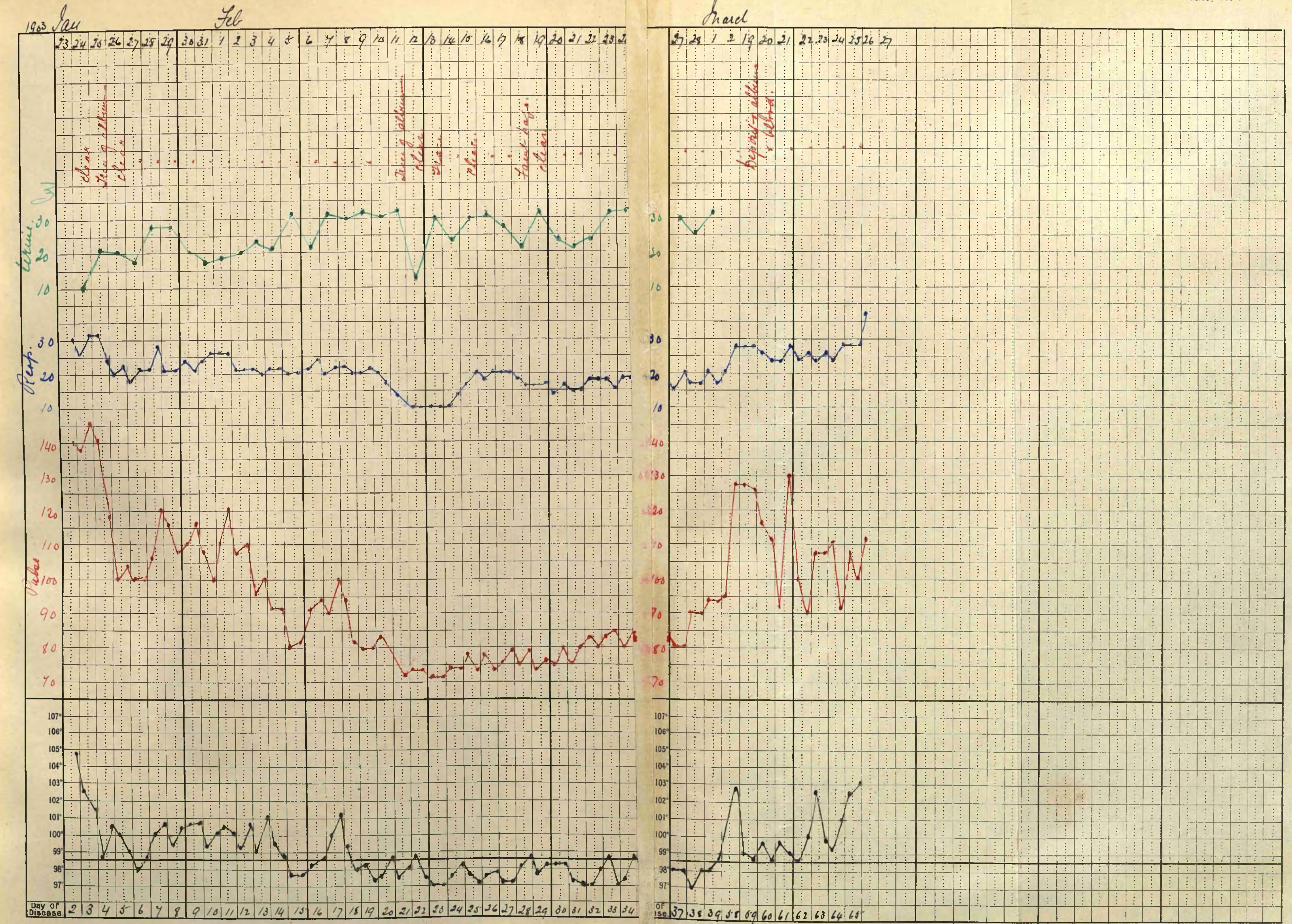
1903 Jan
Feb
March
23 24 25 26 27 28 29 30 31 1 2 3 4 5 6 7 8 9 10 11 12 13 14 15 16 17 18 19 20 21 22 23 2
27 28 1 2 19 20 21 22 23 24 25 26 27
clear
Trace of albumin
clear
Trace of albumin
clear
Trace
clear
faint trace
clear
Deposit of albumin & blood
Urine 30 20 10
Resp. 30 20 10
Pulse 140 130 120 110 100 90 80 70
107° 106° 105° 104° 103° 102° 101° 100° 99° 98° 97°
Day of Disease
2 3 4 5 6 7 8 9 10 11 12 13 14 15 16 17 18 19 20 21 22 23 24 25 26 27 28 29 30 31 32 33 34
37 38 39 58 59 60 61 62 63 64 65

## CASE V111:-

M.P., aged 20. Admitted on Oct. 1st, 1903.

Illness began on the day before admission into hospital with sickness, vomiting and sore-throat. The rash was noticed on the evening of the same day.

On admission the temperature registered 101, the pulse averaged 132 and the respirations numbered 30 per minute. A brilliant rash covered the whole of the body and limbs. The throat was much congested, the tonsils were enlarged and there was some superficial ulceration of the right tonsil. The glands at the angles of the jaw were slightly enlarged. The heart and lungs were normal and the urine did not contain any albumen. After a sharp attack of Scarlet Fever this patient made favourable progress up to Oct. 26th, on which day, that is during the fourth week of illness, she complained of headache and sickness and it was noticed that her face was swollen, both eyes being almost closed by oedema. The urine was slightly diminished in quantity and contained blood and albumen. On Nov. 11th, it was noted that the patient had grown steadily worse, the quantity of albumen had increased and the amount of urine passed was less. Vomiting was frequent and even small quantities of milk were retained in the stomach with difficulty. There was some commencing ulceration of the buccal mucous membrane. During the second week of December there was a slight improvement but it was not maintained and the patient died on Dec. 10th, that being the 73rd day of her illness.

Post-mortem examination showed that there were adhesions of the pleural surfaces over the lower posterior aspects of both lungs. Both lungs were congested but there was no consolidation. The heart was normal. The spleen was considerably enlarged, firm in consistence and the Malpighian bodies were very prominent. The liver was much enlarged, weighing/

weighing 3 lbs. 6 ozs. and showed considerable fatty change. The peritoneal cavity contained about 1½ pints of clear serous fluid. The left kidney weighed 7½ ozs. The capsule was non-adherent. The cortex was slightly shrunken and on section was yellowish-white in colour with many minute red points interspersed through it, the normal markings being lost. The pyramids were much congested. The right kidney weighed 9 ozs. and presented the appearances above described, excepting that the congestion of the pyramids was not so marked.

On microscopical examination all the structures showed pathological changes and the various degrees of degeneration, which were seen, were very numerous. There was great proliferation of the cells of Bowman's capsule. This proliferation took place on the internal surface of the capsule. In the early stages it was found to be situated only on one side and only in corpuscles showing a later stage in the degeneration was it found to be situated round the whole circumference of the capsule. It was always most marked on the side at which it commenced and this appeared to be at the opposite side of the corpuscle from that at which the afferent vessel entered. The outline of the newly formed cells could not, for the most part, be distinguished but the nuclei had the same characters as these found in the normal capsule. In those glomeruli showing an early stage in this degeneration, the cells were superimposed upon one another and were not flattened, while in those that had undergone a further degree of degeneration, the cells were flattened out as was shown by the more oblong shape of the nuclei. A later stage consisted in the replacement of these cells by fibrous tissue and this was present in some of the glomeruli to such an extent that in the most degenerated corpuscles there was seen a very small central portion, consisting of distorted glomerular capillaries, surrounded by a zone of dense fibrous tissue. This formation of fibrous tissue appeared to commence in the cells situated nearest to the glomerular tuft/

tuft as some glomeruli were seen in which the inner portion of proliferated cells had been replaced by the fibrous tissue, while the cells situated more externally were intact. Around most of the Malpighian corpuscles there was seen leucocytic infiltration of the tissues. The walls of the glomerular capillaries were ~~was~~ seen with difficulty and in some glomeruli no definite structure could be distinguished. Owing to the great distortion and compression of the glomerular tuft by the capsular proliferation it was difficult to say if there was any marked hyaline degeneration of the capillaries. There was some increase in the number of nuclei in the glomeruli and the cells, to which these belonged, appeared to be mostly proliferated capillary endothelial cells although there were a few polymorpho-nucleated cells present.

There was very marked separation of the tubules from one another and all of them showed an extreme degree of degeneration so much so that the different varieties could only be distinguished from one another by their respective positions in the section. Also it was found that there had been a marked diminution in the number of tubules, their place apparently being taken by newly formed connective tissue. The cells of the convoluted tubules appeared to be smaller than usual and exhibited marked granular degeneration. Some of the tubules, apparently the junctional and collecting tubes, were very much dilated and their cells were flattened, as if they had been subjected to abnormal pressure. All these dilated tubules contained tube-casts and some granular debris. These casts, which in some instances were of very large dimensions, were nearly all of the pale hyaline variety. These were homogeneous in appearance and stained faintly with the ordinary dyes. The granular debris was not very large in amount and no epithelial casts were seen. A few of the tubules contained blood cells and polymorpho-nucleated leucocytes/

leucocytes. No hyaline degeneration of any of the tubular cells was found.

The spaces between the tubules were occupied by new formed fibrous tissue and infiltrating cells. The cells were mostly lymphocytes together with a few polymorpho-nucleated leucocytes and degenerated epithelial cells. No plasma cells were seen. The cells were most numerous between the tubules and in the deeper parts of the section while around the glomeruli and especially around those situated in the superficial layers of the cortex the fibrous tissue predominated. In some places this fibrous tissue was very dense but in other situations it had more the characters of an open net-work.

Case VIII.

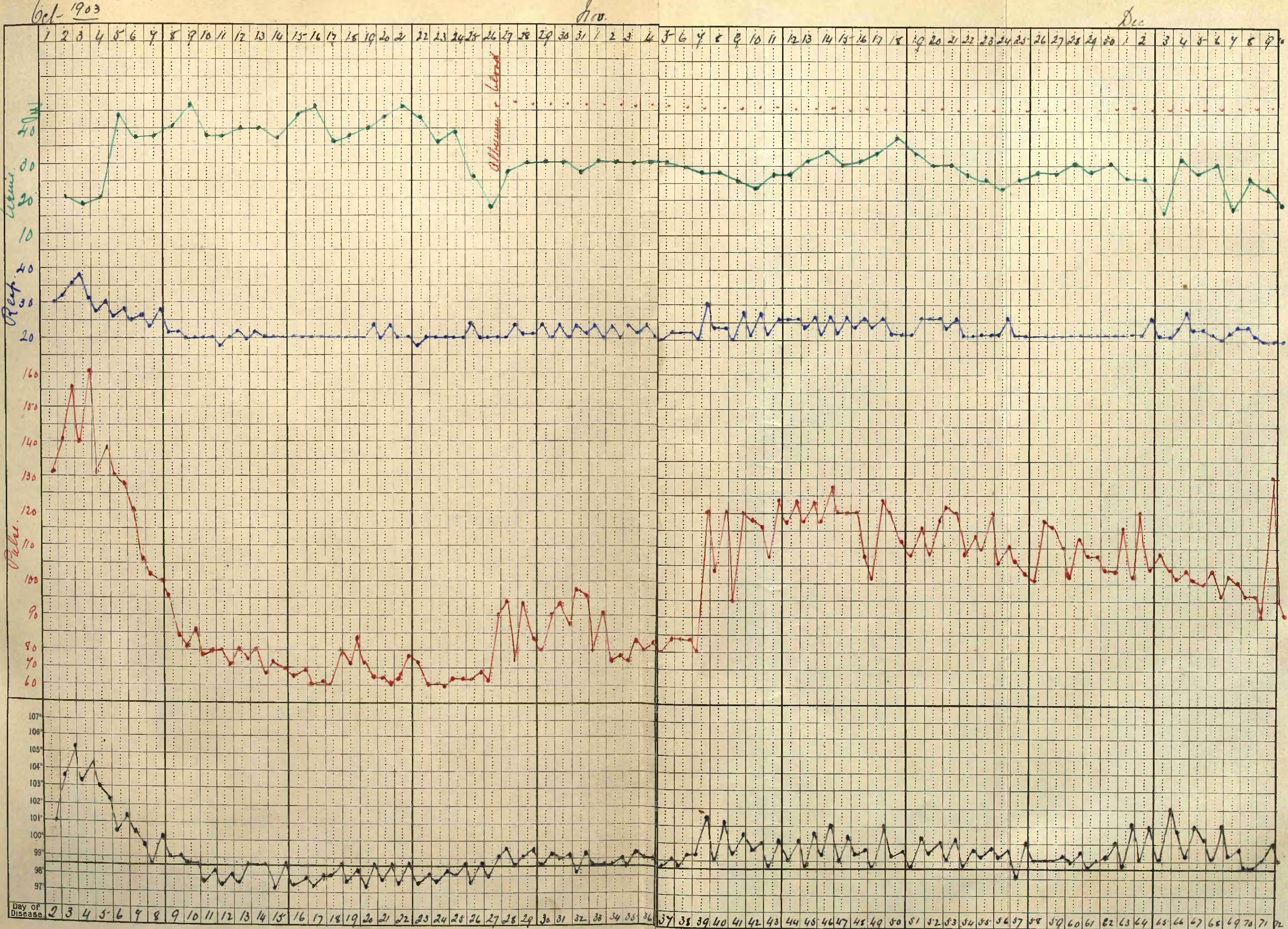
Oct. 1903
Nov.
Dec.
Urine.
Resp.
Pulse.
Albumen & blood
40
30
20
10
160
150
140
130
120
110
100
90
80
70
60
107°
106°
105°
104°
103°
102°
101°
100°
99°
98°
97°
Day of Disease

## CLASS 11.

CASE 1X:-

A.A., aged 17. Admitted on Feb. 7th, 1903.

Illness began on the day before admission into hospital with sore-throat, headache, sickness, vomiting, abdominal pain and pain in the limbs. The rash was seen for the first time on Feb. 7th.

On admission the patient was profoundly ill, the pulse, which numbered 140 per minute, being very feeble and irregular, the temperature registering 104.8, and the respirations being 33 per minute. There was a very dark, fully developed, scarlatiniform rash all over the body. The tongue was dry and swollen and there was considerable congestion and swelling of the fauces and tonsils. There was much restlessness and some delirium and both these symptoms increased up to the time of his death, which took place at 12.30 a.m. on Feb. 8th. Examination of the chest was negative, and no urine was obtained during life.

Post-mortem examination showed that the cardiac muscle had undergone some albuminoid degeneration and that there were some yellow fatty patches on the aortic wall just above the coronary arteries. Both lungs were intensely congested and their surfaces were studded with minute hemorrhages. There was no ecchymosis of the paristal pleura but a few petechiae were seen on the visceral layer. The liver weighed 3¼ lbs. and on section showed fatty and albuminoid degeneration. The mesenteric glands were enlarged and the Peyer's patches remarkably so, but there was no ulceration in the intestine. The spleen weighed 7½ ozs., was almost diffluent and the Malpighian bodies were not recognisable. There was marked congestion of the brain. The kidneys were somewhat small and on section markedly pale in appearance. The capsules were moderately adherent.

On/

On microscopical examination of the kidney most of the Bowman's capsules were seen to be thickened. In those least affected the thickening was regular all round the capsule and had a translucent homogeneous appearance. Where it was more advanced it appeared as if composed of several laminae, between which were seen a very few flattened nuclei. Most of the afferent vessels were considerably dilated and showed some hyaline degeneration. Some of the glomerular capillaries also had undergone hyaline degeneration, and in a few instances had ruptured. The tubules of all varieties contained considerable granular masses. The cells of the convoluted tubules were markedly granular, although they were not swollen so much as would have been expected considering their granular appearance. In some places the cells had undergone a certain amount of disintegration, and the masses of granular protoplasm would in all probability account for the large quantity of granular debris seen in the tubules. This granular degeneration and disintegration of cells was also marked in the ascending loop of Henle, and many of the cells had become separated from one another and were seen lying free within the basement membrane. In a few of these tubules there appeared to be an excessive number of cells but no evidence of mitosis was found.

CASE X:-

A.H., aged 13. Admitted on Nov. 7th, 1902.

Illness began on Nov. 6th with vomiting and sore-throat. The rash was first seen on the day of admission.

On admission the patient was extremely ill, and had the appearance, from his colour, his dull and somewhat stupid expression, together with the almost total absence of rash, of a malignant case of Scarlet Fever. After a hot bath there appeared an erythema of the trunk just sufficiently bright to be easily observed, and a patch of punctiform rash on the inner aspect of each thigh.. The tongue was moist, partially peeled, and showed enlarged papillae. The fauces and soft palate were much swollen and congested, and scattered over the most congested parts were numerous small white patches either of exudate or commencing ulceration. The cervical glands were much enlarged and tender. Nothing abnormal was found in the heart or lungs, and no urine was obtained during life. A few hours after admission vomiting commenced, and this persisted up to the time of death, which occurred on Nov. 8th.

Post-mortem examination revealed the presence of a small amount of albuminoid degeneration of the cardiac muscle and of some small yellow patches situated just above the openings of the coronary arteries in the aortic wall. The lungs were very oedematous, but presented no gross lesion. The liver was congested and fatty, and the spleen, which weighed 5¼ ozs., was very dark in colour and almost fluid in consistence. The mesenteric glands were enlarged, and the Peyer's patches were both congested and slightly ulcerated. The kidneys on section were found to be much congested, this being most marked in the pyramids.

Microscopical examination of the kidneys did not reveal any very marked changes. There was some slight thickening of some of the Bowman's/

Bowman's capsules, but there was no proliferation of the capsular epithelium. The capsular spaces contained very small quantities of granular debris, and there was no increase in the number of nuclei seen in the Malpighian capsules. Some of the afferent vessels were slightly dilated, and the majority showed some hyaline degeneration. The glomerular capillaries showed very slight hyaline degeneration, and a few of them had ruptured. There was some slight separation of the tubules from one another, and the cells of the convoluted tubules and ascending loops of Henle exhibited slight granular degeneration. The convoluted tubules contained a little debris, and a few casts were seen in the junctional tubes.

Case. X.

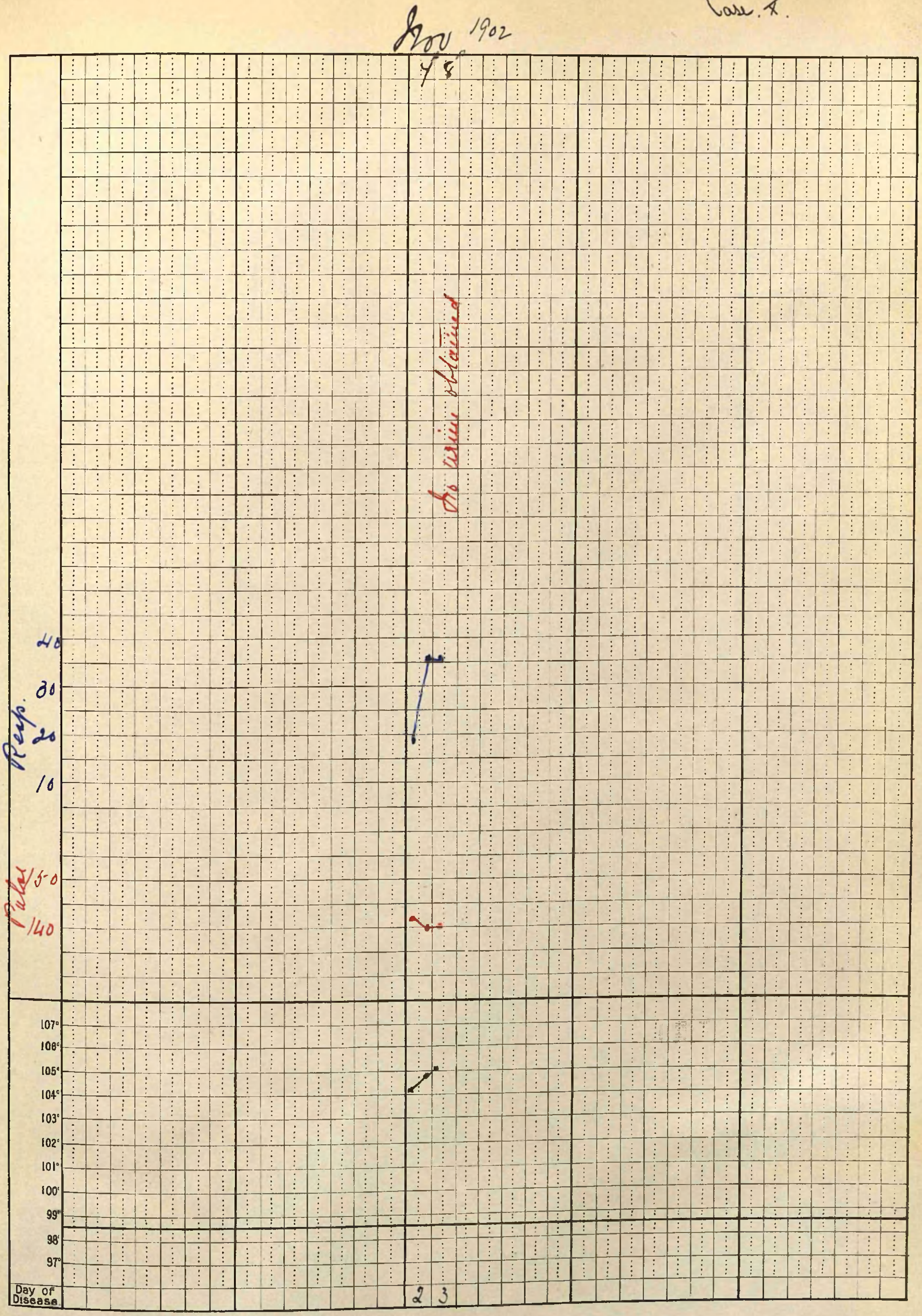
Nov 1902
4
5
No urine obtained
Resp.
40
30
20
10
Pulse
150
140
107°
106°
105°
104°
103°
102°
101°
100°
99°
98°
97°
Day of Disease
2
3

CASE XI:-

M.D., aged 6. Admitted on June 26th, 1902.

Illness began on the day before admission into hospital with sickness, vomiting and sore-throat. The rash was first seen on June 26th.

On admission there was very little rash to be seen, the arms and legs presenting only a slight erythema. The skin of the trunk was dry and harsh, and the child was distinctly ill. The temperature was 102.4, the pulse registered 108, and the respirations numbered 20 per minute. The tongue was deeply congested, much swollen, red in colour and dry, and the papillae were even more prominent than usual. The fauces, soft palate and uvula were congested and more or less covered with discharge, and the tonsils were enlarged and studded with numerous discrete patches of exudation. There was no ulceration in the throat. The submaxillary glands on each side were swollen, and there was a copious muco-purulent discharge from the nose. The heart and lungs were sound and the urine contained a trace of albumen. On June 27th, it was noted that the patient was much worse. She had been exceedingly restless, and at times delirious, and the temperature had risen to 105.4. On the following day her condition was even less satisfactory, the restlessness and delirium having continued, and the pulse having increased in rate and become weak and irregular. She died at 6.50 p.m. on June 28th, the temperature having registered 108 just before death.

Post-mortem examination showed that there was some albuminoid degeneration of the cardiac muscle, and that there was some slight thickening at the edges of the curtains of the mitral valve. The aortic valves were reddened, but otherwise normal. The lungs were intensely hyperaemic, but there was no consolidation and the pleurae were unaffected. The liver was congested and showed considerable fatty change and/

and the spleen, which weighed 2¼ oz., was fairly firm in consistence and congested with very distinct Malpighian bodies. The mesenteric glands were enlarged, and the Peyer's patches and solitary glands were very prominent, especially those at the ileo-caecal valve, but there was no ulceration. Both kidneys weighed 1¼ oz., and the capsules were non-adherent. On section the organs were found to be much congested, this being most amrked in the pyramidal portion. There was no diminution in the size of the cortex.

Microscopical examination showed that there was some slight proliferation of the capsular epithelium, the cells being in the new-formed condition and not flattened out. This proliferation was mostly unilateral, and in some instances had led to a junction of the capillary tuft and Bowman's capsule. In a few places hyaline thickening of the capsule was present. The capsular spaces contained a small amount of granular debris. Some of the afferent arteries and a few of the glomerular capillaries showed hyaline degeneration in an early stage, and all the vessels contained many blood cells. The cells of the convoluted tubules and ascending loops of Henle had undergone some granular change, this being sometimes associated with poor nuclear staining. The tubules contained small quantities of granular debris. In addition it was found that many of the cells in the ascending loops of Henle had become separated from one another, and occasionally they appeared to be increased in number.

---

Case. XI.

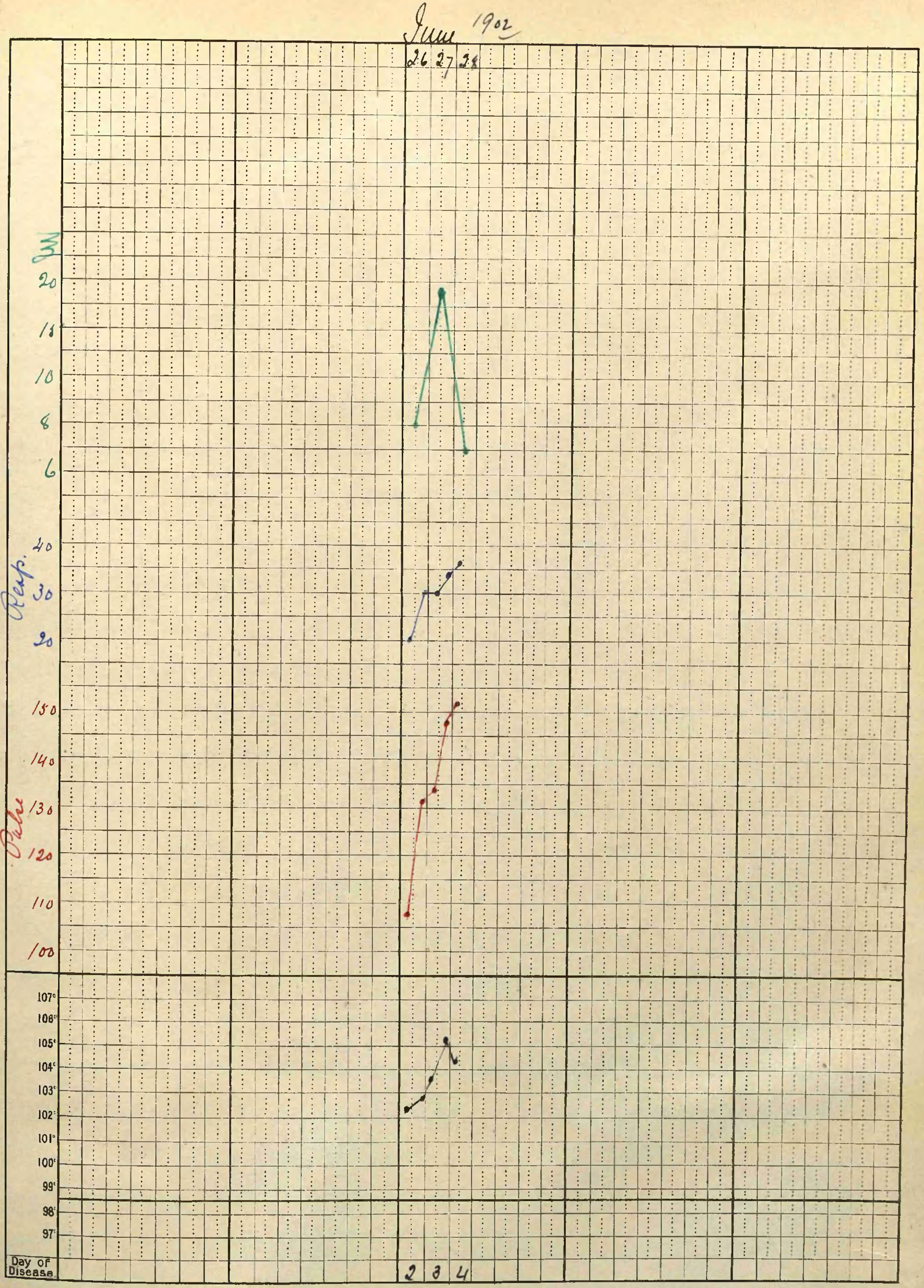
June 1902
26
27
28
20
15
10
8
6
Resp.
40
30
20
Pulse
150
140
130
120
110
100
107°
106°
105°
104°
103°
102°
101°
100°
99°
98°
97°
Day of Disease
2
3
4

## CASE XII.-

E. M., aged 2½. Admitted on May 30th, 1903.

Illness began on the day before admission into hospital with vomiting. The rash was seen for the first time on the evening of the same day.

On admission the patient was very ill, and the case appeared to be of a very severe anginous type. The rash was somewhat scanty and badly developed, and was present on the scalp, face, trunk and limbs. There was very marked congestion of the soft palate and both tonsils. The uvula and posterior wall of the pharynx were deeply ulcerated and covered with an abundant muco-purulent secretion. There was slight enlargement of the submaxillary glands on the right side of the neck, and the tongue was pallid. The child was very restless and was troubled with a frequent spasmodic cough. The respirations were rapid and shallow, numbering as many as 60 per minute, and examination of the chest, which was markedly rickety, showed the presence of a considerable amount of fine crepitant inspiratory rales at both bases. The heart was normal. The urine was free from albumen. On June 1st, it was noted that the patient since admission had become much worse, there being marked restlessness and some delirium, and an acceleration and weakening of the pulse, accompanied by a rising temperature. She died at 1 p.m. on June 1st, the temperature an hour before death registering 108.2.

Examination post mortem revealed considerable congestion at the free borders of the mitral and aortic valves, both of the structures, however, being competent, and some albuminoid degeneration of the heart muscle. The middle and lower lobes of the right, and the lower lobe of the left, lungs were much congested, but there was no consolidation. The liver showed some fatty degeheration and the spleen was hyperaemic. Both kidneys were much congested, and this was most apparent at the apices of the pyramids.

Microscopical examination of the kidney did not reveal any very marked /

marked changes. There was no protiferation or thickening of the Bowman's capsules, and the capsular spaces contained only a small quantity of debris. There was very slight hyaline degeneration of some of the afferent vessels and of a few of the glomerular capillaries. The vessels throughout the section were filled with blood cells. The cells of the convoluted tubules and ascending loops of Henle showed a degree of glanular degeneration, and there was some slight separation of the tubules from one another, the intervening spaces being occupied by dilated capillaries.

Case XIII.

May, June 1903.

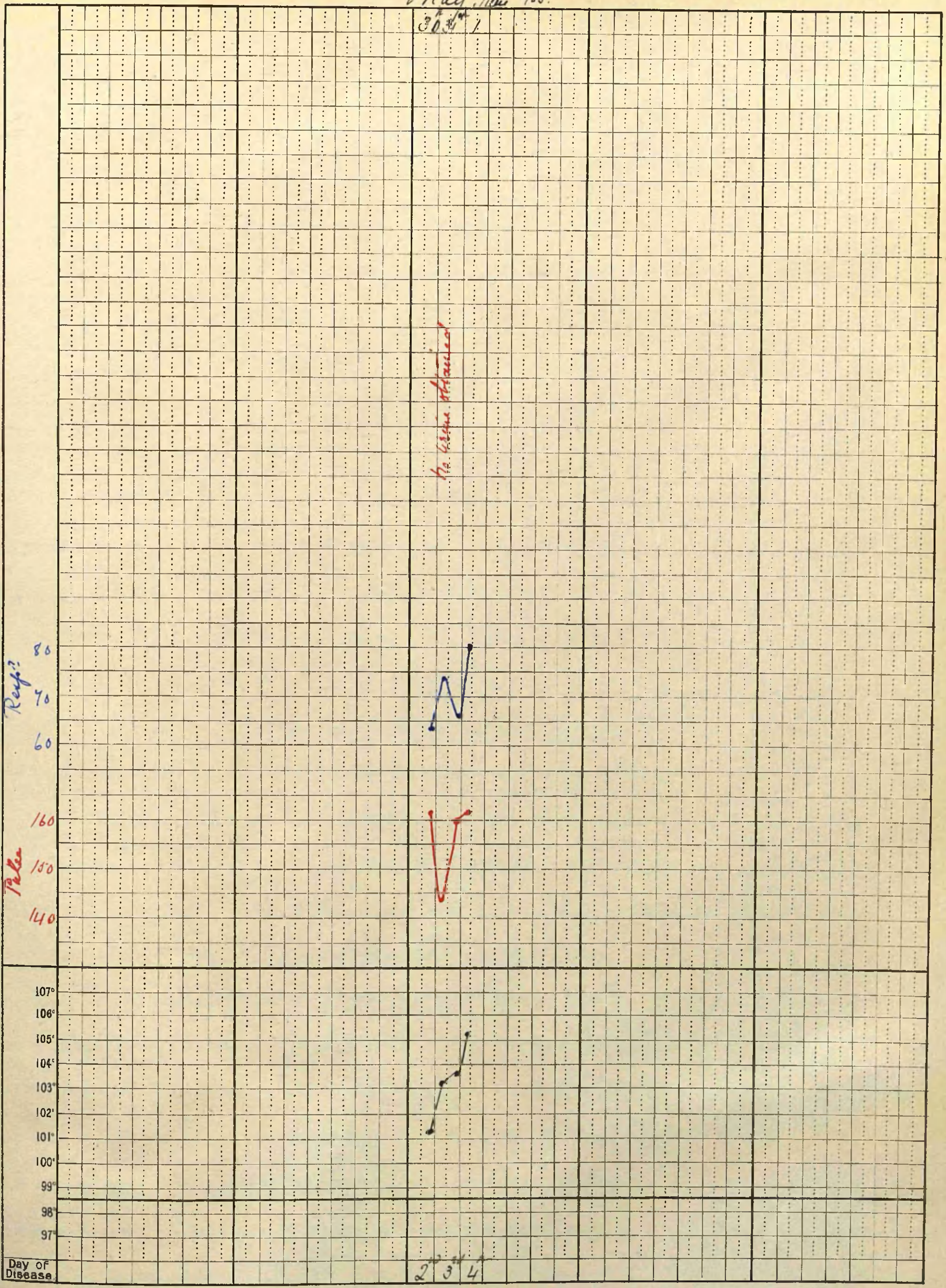

CASE XIII.-

C. C., aged 7. Admitted on Aug. 3rd, 1902.

Illness began two days before admission into hospital with vomiting, sore throat, and pain in the right ear. A slight rash was first noticed on the legs on Aug. 2nd.

On admission the temperature was 104.6, the pulse numbered 150 and was irregular in force although regular in rhythm, and the respirations registered 36. The patient looked extremely ill. The skin was very dry, and there was a scantily developed scarlatiniform rash, best marked on the calves of the legs. The throat was very dirty, and there was marked ulceration of the fauces and palate. There was some enlargement of the glands at the angle of the jaw on both sides, and the tongue was commencing to peel. The heart and lungs were normal. The urine contained a trace of albumen. The patient never rallied after admission, and died on Aug. 4th, that being the fourth day of the illness.

Post-mortem examination showed that the heart was normal and that the left lung was oedematous. The spleen weighed 1½ oz., was firm in consistence, and the Malpighian bodies were prominent. The liver was slightly fatty. Peyer's patches and the solitary glands were enlarged and prominent, but otherwise the intestines were normal. The capsules of the kidneys were non-adherent, and the cut section of this organ did not present any abnormal microscopic appearance.

Upon microscopical examination of the kidney it was found that most of the capsules showed some thickening, this thickening appearing to be a swelling of the basement membrane. In most instances this swelling gave the characteristic hyaline degeneration stain with Van Gieson and Eosin. There was no protiferation of the capsular epithelium, but in places some of the cells from the commencing convoluted tubules appeared to have been pushed into the capsular spaces. The capsular spaces also contained /

contained a small amount of granular debris. A few of the afferent arteries were somewhat dilated and showed slight hyaline degeneration, and the same change was occasionally found in the glomerular capillaries. The cells in the convoluted tubules had undergone some degree of granular degeneration, and in some of them there was disintegration of the peripheral protoplasm, while those in the ascending loops of Henle exhibited the same degeneration in a more marked degree. A few of the cells in both these situations showed hyaline degeneration, the cell protoplasm being broken up into small highly refractive homogeneous globules. These hyaline globules were also seen lying free in the tubules, and occasionally they were found in the capsular spaces. In many of the ascending loops of Henle the cells had become separated from their basement membranes and from one another, and were seen lying free within the basement membrane. A few granular and pale hyaline casts were seen in the smaller junstional tubules.

---

Case. XIII.

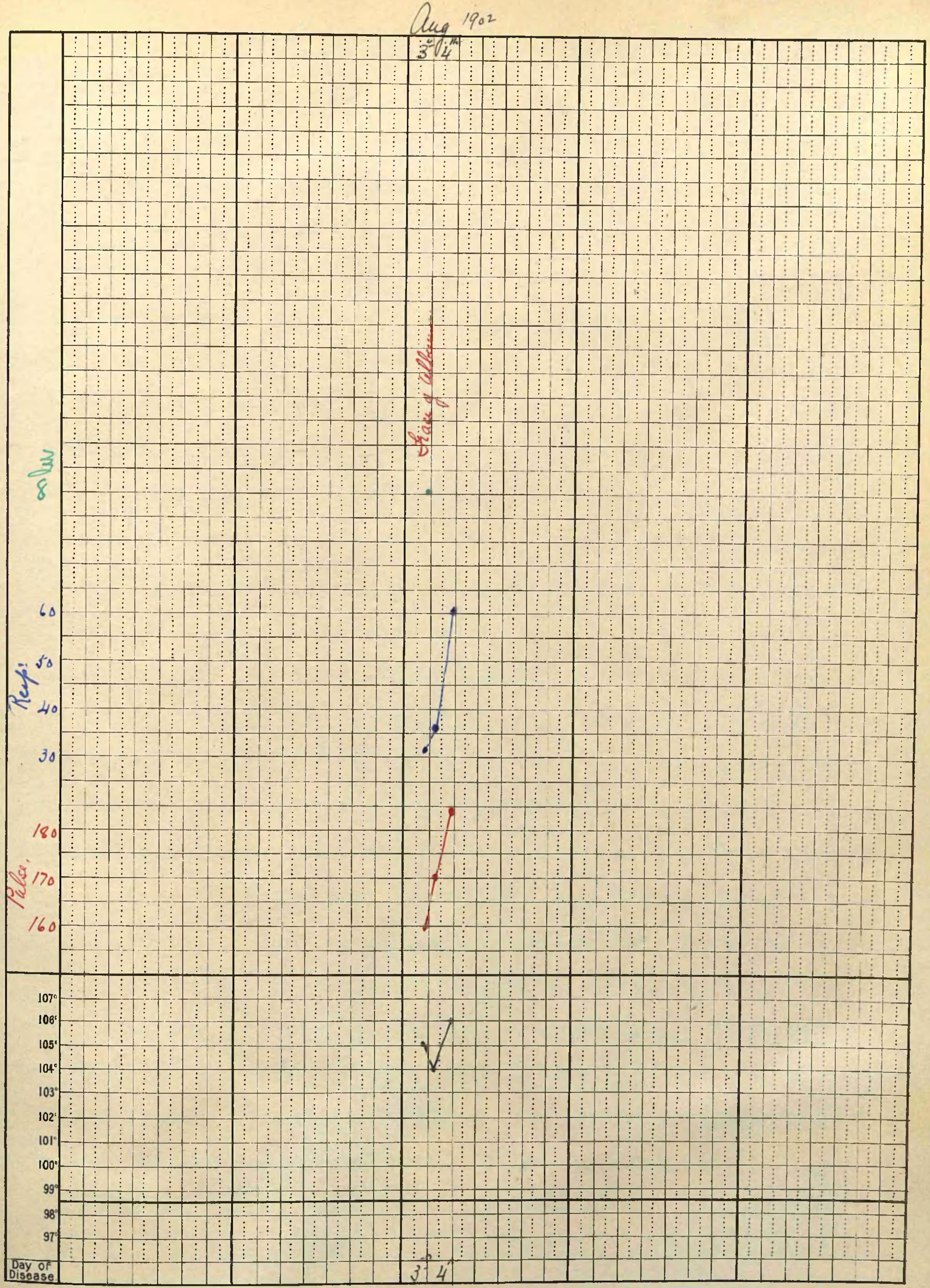
Aug 1902
3rd 4th
Trace of albumen
8 lw
Resp:
60
50
40
30
Pulse.
180
170
160
107°
106°
105°
104°
103°
102°
101°
100°
99°
98°
97°
Day of Disease
3rd 4th

CASE XIV.-

R.T., aged 17. Admitted on Dec. 10th, 1904.

Illness began on Dec. 7th with sickness and sore throat. The rash appeared on Dec. 8th.

On admission the temperature registered 106.4, the pulse was very irregular, weak, and could not be counted. The respirations numbered 36 per minute. The patient was in a moribund condition. He was semi-conscious and very restless. There was a deeply developed, very livid scarlatiniform rash over the body and limbs. The fauces and tonsils were congested, but there was no ulceration. All over the chest inspiration was accompanied by **mucous** ~~rales~~, but there was no alteration in the percussion sound and no tubularity of the breath-sounds. The heart's action was very irregular and weak, but no murmur could be detected. No urine was obtained. The patient never rallied and died on the afternoon of the day of admission into hospital.

Microscopically the most marked feature found in the kidneys was tubular degeneration. The cells of the convoluted tubules and ascending loops of Henle were very granular and swollen, and the tubes contained much granular debris. In places hyaline degeneration of these cells was present, and in the ascending loops of Henle the cells had become separated from one another and from their basement membranes. Tube-casts, both of the hyaline and granular variety, were seen in the junctional tubules. The glomerular structure was distinct, and there was no increase in the number of nuclei in the glomeruli. There was no proliferation of the capsular epithelium. The capsular spaces contained small quantities of granular material. The afferent vessels and some of the intertubular capillaries showed slight hyaline change.

---

CASE XV. -

Mrs S., aged 29. Admitted on June 3rd, 1903.

This patient was confined seven days prior to her admission into hospital, and made good progress for the first six days. On June 2nd, however, she complained of dryness of the throat, and a rash was noticed for the first time. On the morning of admission she suffered from sickness and vomiting, and by this time the rash had become more pronounced.

On admission the temperature registered 106.6, the pulse was feeble and soft, numbering 160 per minute, and the respirations averaged 34. The patient looked very ill. The face was flushed, the eyes were unusually bright, the tongue was dry and furred, and she was very restless and slightly delirious. There was a well developed scarlatiniform rash on the abdomen, chest and back, and the eruption was also present to a less extent on the upper parts of the arms and legs. The throat was deeply congested, and there was much secretion but no ulceration. The heart's sounds were of poor quality, but were otherwise normal. The lungs were free from rales. On June 4th it was noted that the rash had further developed and extended, and on the dorsum of the hands it had become almost papular in character. The delirium and restlessness were still marked symptoms. On June 5th examination of the chest revealed numerous rales audible over both lungs, and the patient, growing rapidly weaker, died at 3.30 p.m., that being the fourth day of the illness.

The most marked feature on the microscopical examination of this kidney was found to be the tubular degeneration. The cells of the convoluted tubules and ascending loop of Henle were much swollen and showed marked granular degeneration. A few of them exhibited hyaline degeneration. The cells of the ascending loop of Henle had become separated from the basement membranes and from one another, and were greatly increased in number, the whole space inside the basement membrane being filled with cells. In a very few of these cells two nuclei were found, but /

but there was no evidence of mitosis. The tubules were not separated from one another, but they contained granular debris, and in the junction tubules a few granular and pale hyaline casts were seen. Some of the small vessels showed hyaline degeneration, and this change was also present to a slight degree in the glomerular capillaries. The Malpighian corpuscles were otherwise normal.

---

Case. XV.

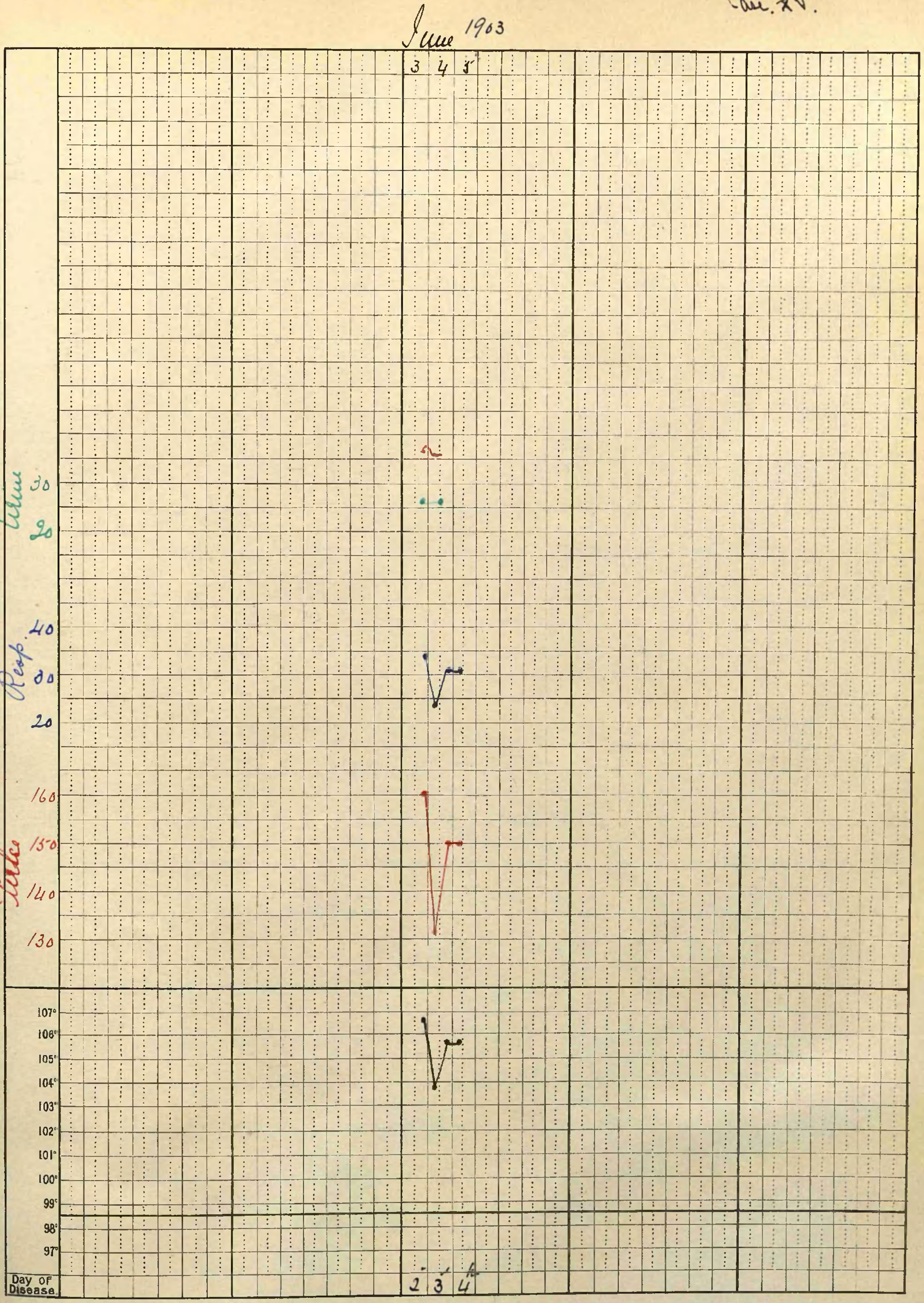
June 1903
3 4 5
Urine
30
20
Resp.
40
30
20
Pulse
160
150
140
130
107°
106°
105°
104°
103°
102°
101°
100°
99°
98°
97°
Day of Disease
2 3 4

CASE XVI. -

M. M., aged 2. Admitted on Feb. 26th, 1903.

This case was complicated with Varicella, the eruption of which appeared on the day before admission into hospital. She became ill on Feb. 22nd with sore throat, sickness and vomiting, and a slight cough. The scarlet rash was first noticed on Feb. 25th.

The child was acutely ill on admission. There was a badly developed scarlatiniform rash, which only slightly improved after several mustard baths. The temperature registered 103.6, the pulse was weak and irregular and numbered 160, and the respirations averaged 40 per minute. The throat was but little affected, and there was no glandular enlargement. There was a varicellar eruption in various stages, most marked on the face and neck. Examination of the chest was negative and no urine was obtained. The patient died on the evening of the day of admission, the temperature and respirations just prior to death having reached 107.6 and 72 respectively.

Post-mortem examination revealed some albuminoid degeneration of the cardiac muscle, and both lungs were found to be hyperaemic and oedematous in their lower lobes. The mesenteric glands and the Peyer's patches of the intestine were swollen and congested. The spleen was much enlarged, firm in consistence, and showed prominent Malpighian bodies. The kidneys were large, with very pale cortices and markedly congested pyramids.

Microscopical examination showed that there was no proliferation of the cells in Bowman's capsule and that the capsular spaces did not contain any quantity of granular matter. Excepting in a few glomeruli, situated in the extreme cortex, there was no increase in the number of nuclei normally found, and in these few so situated the condition was a physiological and not a pathological condition, inasmuch as the excessive number of nuclei belonged to the epithelial covering of the capillary /

capillary tuft, and were the remains of an embryonic stage of development. There was occasional dilation of the afferent vessels, and some of these vessels showed slight hyaline degeneration. There was some granular degeneration of the cells in the convoluted tubules, and in many of the ascending loops of Henle the epithelial cells had become separated from the basement membrane and from one another, and were seen lying free within the basement membrane.

Case, XVI.

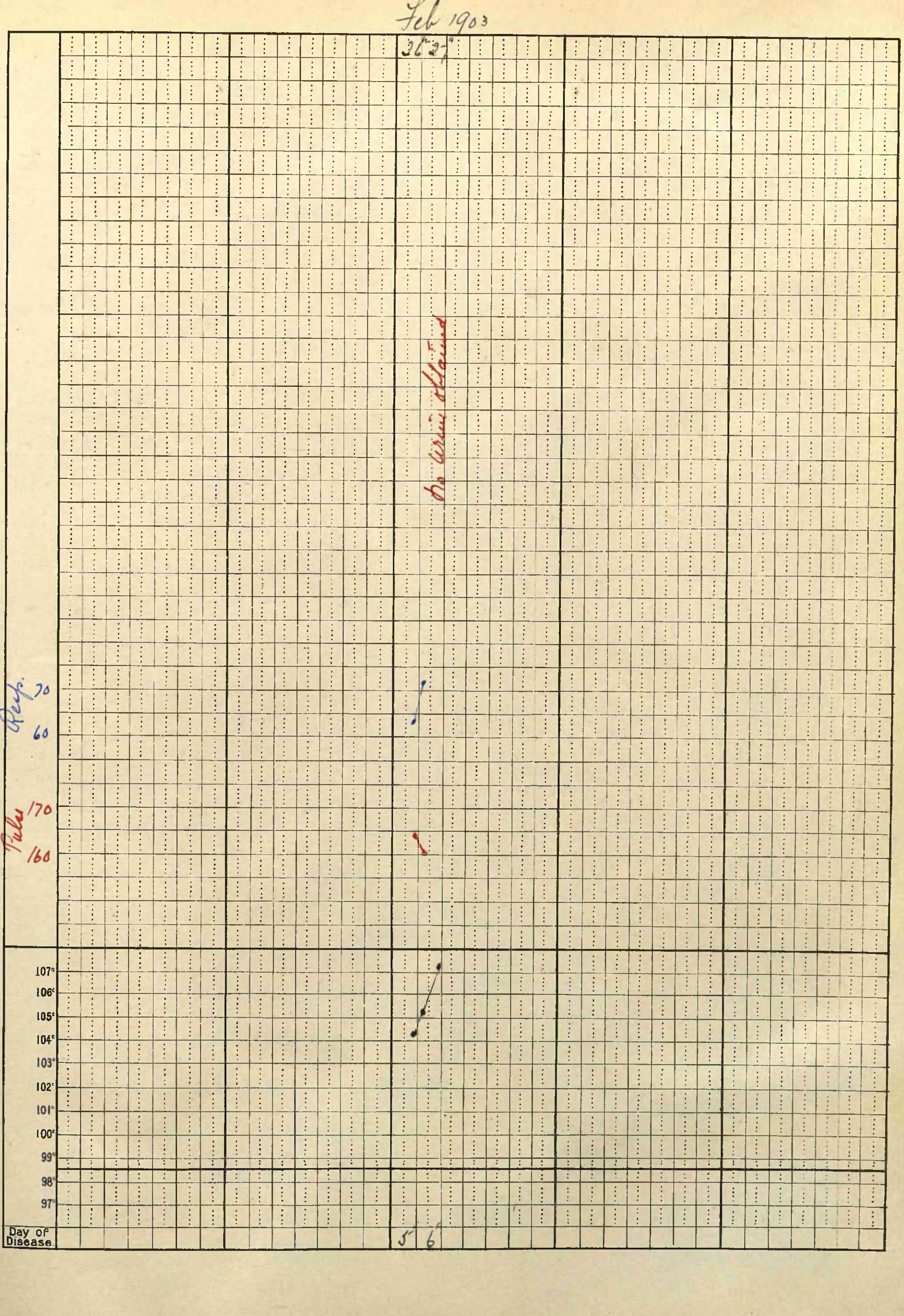
Feb 1903
26th
27th
Resp.
70
60
Pulse
170
160
107°
106°
105°
104°
103°
102°
101°
100°
99°
98°
97°
Day of Disease.
5
6
No urine obtained

CASE XVII. -

C.W., aged 3½. Admitted on Sept. 21st, 1902.

Illness began on Sept. 16th with sickness, vomiting and sore-throat.. On the following day there was swelling of the glands in neck, and complaint of pain in all the joints. There was no history of any rash.

On admission the child was very ill. The temperature registered 104, the pulse numbered 140, was very weak, and slightly irregular. The respirations averaged 40 per minute. There was a badly developed scarlatiniform rash on the trunk and limbs, having a somewhat purplish colour. The tongue was peeled. The whole throat was very much congested, the tonsils being greatly enlarged and almost meeting in the middle line. The glands in the neck were swollen. The heart and lungs were normal and the urine contained a trace of albumen. For a short time after admission the condition of the patient improved, but on Sept. 29th he became extremely restless, with rolling of the head and eyes and twitching of the mouth. At the same time he commenced to vomit, and later in the day became unconscious. Examination of the urine showed nothing beyond a slight trace of albumen. He died on Sept. 30th, that being the 15th day of illness.

Post mortem examination revealed some albuminoid degeneration of the cardiac muscle, but the heart was otherwise normal. There were a few old adhesions over the surface of the right apex, and a small patch of consolidation in the lower lobe of the left lung. The liver was fatty and the spleen enlarged with very prominent Malpighian bodies. The veins on the surface of the brain were engorged, and covering the convolutions,adjoining the longitudinal fissure throughout its entire length, there was an opaque gelatinous-looking exudate. There was a large quantity of this exudation at the base of the brain, and this extended up into the Sylvian fissure and glued the opposing surfaces of the fissure together. There was no distension of the ventricles, and no microscopical /

cal pathological changes in the brain substance. The kidneys were much congested, this being most marked at the apices of the pyramids.

Microscopically the changes found in this kidney were well marked. There was no proliferation of the cells in Bowman's capsules, but some of them showed a degree of hyaline degeneration of their basement mambranes. The capsular spaces contained a little granular debris and a few granular epithelial cells, which, from their appearance, were in all probability derived from the convoluted tubules. The capillary structure was very distinct, and many of the capillaries were dilated and filled with blood cells. Rupture of the capillary walls was occasionally seen. There was no proliferation of the capillary endothelium. Most of the afferent arteries were dilated and contained blood cells in large numbers and a few exhibited slight hyaline degeneration. The cells of the convoluted tubules showed granular degeneration, and in many instances this was very marked, the protoplasm being especially granular at the periphery and the nuclear staining being deficient. In some of the tubules the cells were much broken up and the lumen of the tube was filled with granular detritus. The cells of the ascending loop of Henle exhibited the same granular change, and occasionally all nuclear staining was lost and there appeared to be complete necrosis of the cells. Many of these cells had become separated from the basement membrane and from one another and in some tubules they were increased in number. The junctional tubules contained much granular material, but were otherwise normal.

---

Case. XVII.

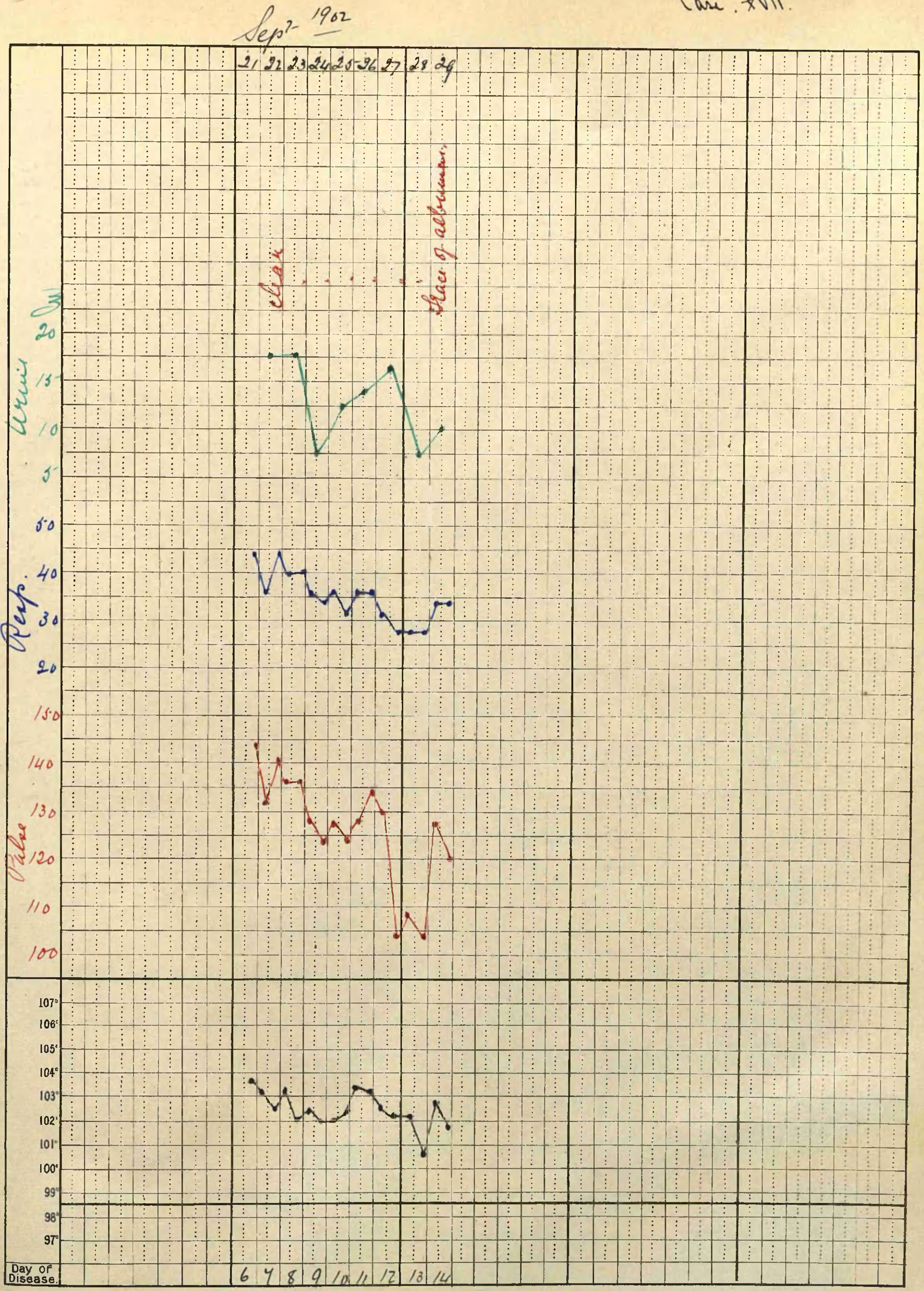
Sept 1902
21 22 23 24 25 26 27 28 29
Clear " " " " "
Trace of albumen.
Urine Oz.
20
15
10
5
Resp.
50
40
30
20
Pulse
150
140
130
120
110
100
107°
106°
105°
104°
103°
102°
101°
100°
99°
98°
97°
Day of Disease.
6 7 8 9 10 11 12 13 14

CASE XVIII. -

J.W., admitted on Aug. 26th, 1901.

Illness began on Aug. 23rd with sickness and vomiting. The rash was first seen on the same day.

On admission the temperature was 102.6, the pulse was soft and numbered 124, and the respirations averaged 42. There was a profuse typical scarlatiniform rash over the trunk and limbs, and there was a number of small pustules of various sizes distributed over the surface of the body. The throat was much congested and there was considerable swelling of the glands on both sides of the neck. At the cardiac apex there was a distinct systolic murmur, which was also heard, though less intensely, over the base of the heart. The area of precordial dulness was not increased, and there was no duplication of the second sound. The lungs were normal. The urine contained a trace of albumen. Shortly after admission ulceration of the uvula, palate and fauces commenced and steadily grew worse in spite of all treatment. The albuminuria increased, but there was no blood (~~and no diminution in the quantity of urine~~) passed. Patient died on Sept. 11th, that being the 19th day of illness.

Microscopically no proliferation of the capsular epithelium was found. The capsular spaces contained some granular debris. The glomerular capillary structure was not very distinct and the capillaries contained many blood cells, while their walls showed some hyaline degeneration. The afferent vessels were not dilated, but had undergone slight hyaline change. The tubules were not separated from one another. The cells of the convoluted tubules and ascending loops of Henle were distinctly granular and swollen, and in some places there was want of nuclear staining. Occasionally hyaline degeneration of these cells was visible, and the same masses of hyaline protoplasm as previously described under Case XIII. were seen in the tubules and capsular spaces. Many of the cells in the ascending loop of Henle had become separated from one another and from their basement membranes, and in a few tubules these cells were increased in number.

Case XVIII.

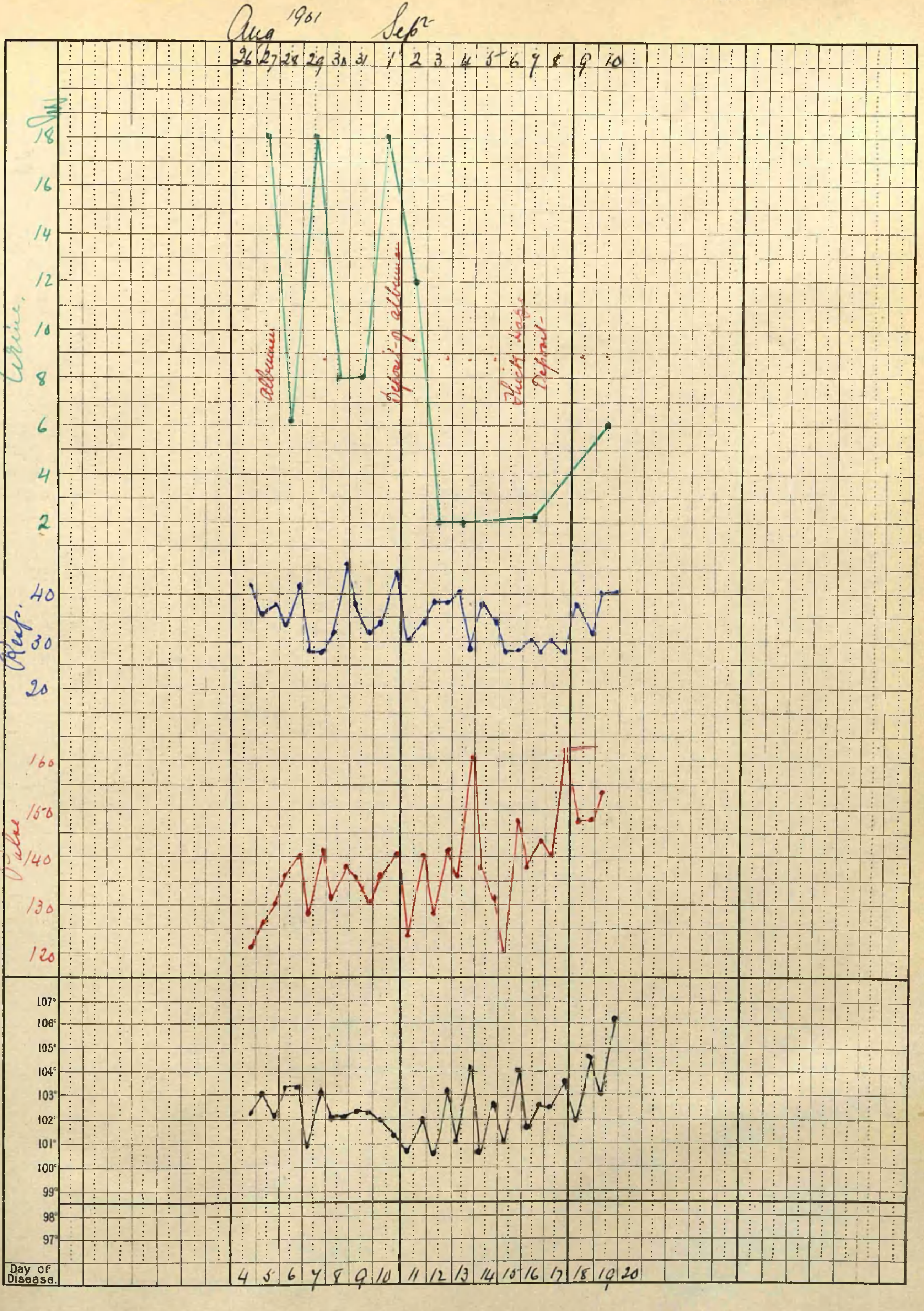

Aug 1901 Sep^r
26 27 28 29 30 31 1 2 3 4 5 6 7 8 9 10
Urine.
18
16
14
12
10
8
6
4
2
Albumen
Deposit of albumen
Thick uds.
Deposit
Resp.
40
30
20
Pulse
160
150
140
130
120
107°
106°
105°
104°
103°
102°
101°
100°
99°
98°
97°
Day of Disease.
4 5 6 7 8 9 10 11 12 13 14 15 16 17 18 19 20

## CASE XIX.-

E.L., aged 4. Admitted on July 7th, 1904.

Illness began on July 2nd with sickness and sore-throat. The rash appeared on the fourth day of illness. There had been a complaint of sore eyes for a fortnight.

On admission the temperature was 100.4, the pulse numbered 140, and the respirations averaged 38 per minute. There was a deep scarlatiniform rash on the body and limbs, which was commencing to fade, and on the legs the skin was rough. The throat was congested and there were some patches of ulceration. There was a purulent discharge from the left eye, but the cornea was unaffected. There was slight glandular enlargement on both sides of the neck. The heart and lungs were normal. The urine contained a trace of albumen. From the time of her admission the condition of this patient grew steadily worse. The temperature at first ran a continuous highly febrile course, and during the latter part of the illness showed considerable morning remissions with higher registers each evening. The pulse increased in rate and became weak and irregular. The ulceration of the throat extended and became deeper, and the glandular enlargement became more pronounced. The quantity of urine passed remained about the same, but on July 13th there was a marked increase in the amount of albumen, and this was present during the rest of her illness. She died on July 23rd, that being the 21st day of illness.

Post mortem examination showed much albuminoid degeneration of the heart muscle. The valves were normal. Both lower lobes of the lungs were markedly congested and showed many small areas of consolidation. There was no fluid in the pleural cavities. The bronchial glands were much enlarged and congested. The liver was fatty and the spleen was intensely congested. The whole of the soft palate above and below was much ulcerated, and on the left side there was a perforation about the size of a threepenny piece. There was likewise ulceration of the pharynx /

ynx and a few small ulcers were seen on the epiglottis. The kidneys were both enlarged and the cortices were somewhat thickened. There was no marked congestion and the pale cut surface suggested some fatty change. The adrenals were not enlarged, the medullae were darker in colour than normal. The intestines were normal.

On microscopical examination the Bowman's capsules were found to be distended and the capsular spaces contained a considerable quantity of granular debris. There was no proliferation of the capsular epithelium but occasionally some slight hyaline thickening of the basement membrane was seen. The afferent ateries and glomerular capillaries showed slight hyaline degeneration and there was a very slight increase in the number of nuclei in the glomeruli. The capillary structure was indistinct. There was some separation of the tubules and in places, where this was very marked, the cells of the tubules appeared to be flattened. The most marked separation was associated with the greatest distension of the capsules. The cells in the convoluted tubules and ascending loops of Henle were granular but not swollen. In a few instances these cells had undergone hyaline degeneration, the protoplasm having become divided up into small, highly refractive, homogeneous globules and some of these hyaline masses, having escaped from the cells, were found lying free in the tubules, capsular spaces, and occasionally in the interstitial tissue. All the tubules contained much granular debris and in the junctional and more rarely in the collecting tubes a few hyaline and granular casts were found.

---

Case. XIX.

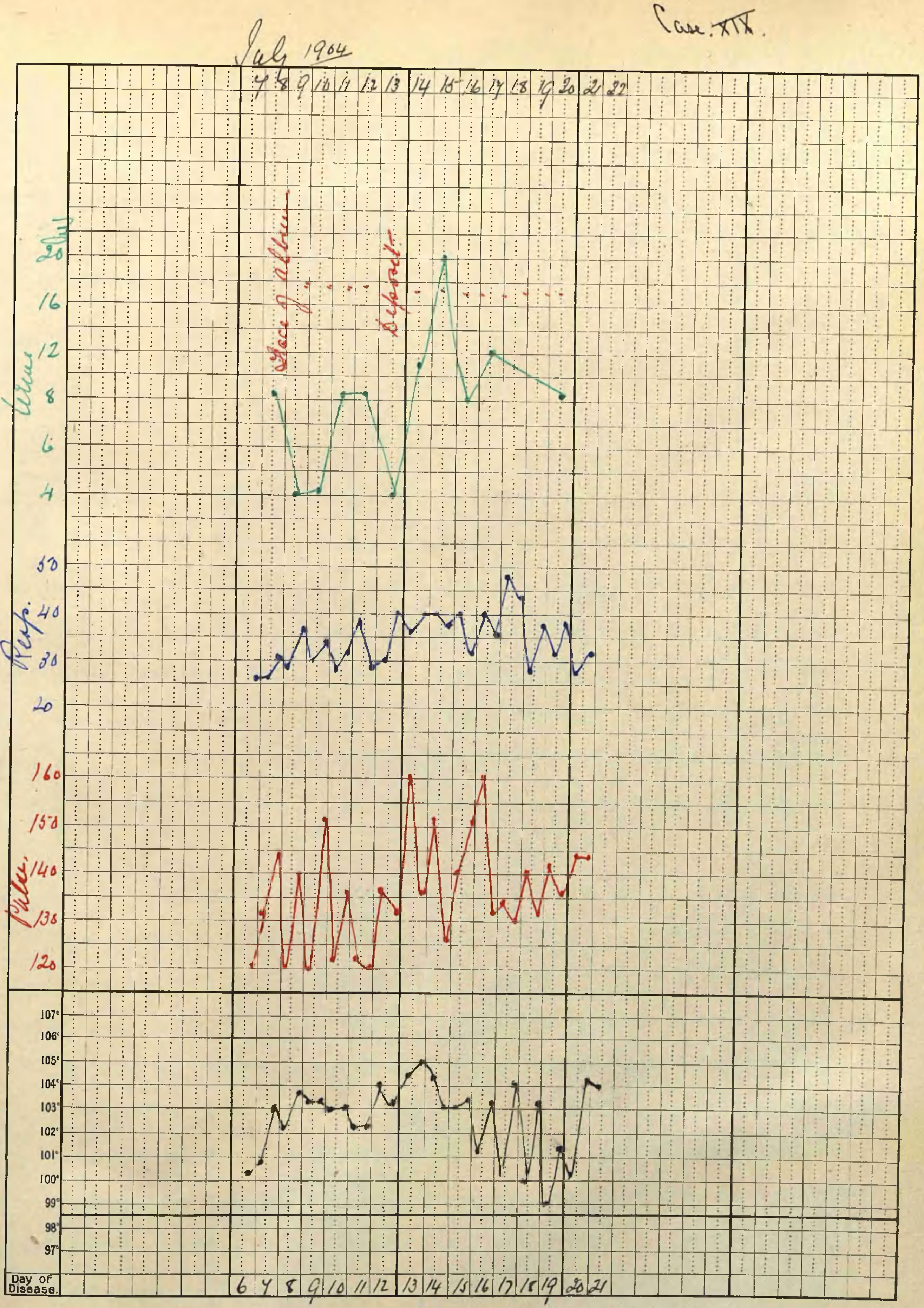
July 1904
7 8 9 10 11 12 13 14 15 16 17 18 19 20 21 22
Urine
20 oz
16
12
8
6
4
Trace of Albumen
Deposit
Resp.
50
40
30
20
Pulse.
160
150
140
130
120
107°
106°
105°
104°
103°
102°
101°
100°
99°
98°
97°
Day of Disease.
6 7 8 9 10 11 12 13 14 15 16 17 18 19 20 21

## CLASS 111.

CASE XX:-

S.W., aged 4. Admitted on June 11th, 1904.

Illness began on June 9th with sickness, vomiting and sore-throat. The rash was first seen on June 10th.

On admission the temperature was 105.2, the pulse averaged 136 and the respirations numbered 46 per minute. The child was acutely ill. There was a well marked scarlatiniform rash on the body and limbs and the face was flushed. The tongue was moist and furred and commencing to peel at the edges. Both tonsils were enlarged and congested but there was no ulceration in the throat. The heart and lungs were normal and the urine was free from albumen. After three days' residence in hospital ulceration commenced on the pillars of the fauces and this, conbined with the large size of the tonsils, rendered the breathing very difficult. The temperature ran a uniformly high course and the pulse rate was maintained with diminution in its tension and regularity. The patient died at 6.30 a.m. on June 16th, that being the eighth day of the illness.

Microscopically this specimen was of special interest as it showed the first stages of interstitial infiltration. Between the tubules in the pyramidal portion and also in the interior of the vessels in this region and in the boundary zone plasma cells were found. These cells were generally situated by themselves or at most in clumps of two or three and were so scarce as to be easily missed. They did not show any evidence of mitotic division and in this case were not associated with any marked degeneration. Their minute structure and probable origin have already been discussed. The capsular spaces contained granular debris and in some instances this was seen to be derived from/

from the disintergrated cells situated at the commencement of the convoluted tubules. The afferent arteries appeared to be normal but the glomerular capillaries were dilated, contained many blood cells and frequently showed some hyaline change. There was a slight increase in the number of nuclei in the glomeruli and these appeared to be derived from proliferation of the capillary endothelium. The tubules were not separated from one another. The cells of the convoluted tubules and ascending loops of Henle were granular and swollen, and there was frequent disintegration of the peripheral protoplasm. The convoluted tubules contained some granular debris and the cells of the ascending loop of Henle had become separated from one another and from the basement membrane. A few granular and pale hyaline casts were found in the junctional tubules.

Case XX.

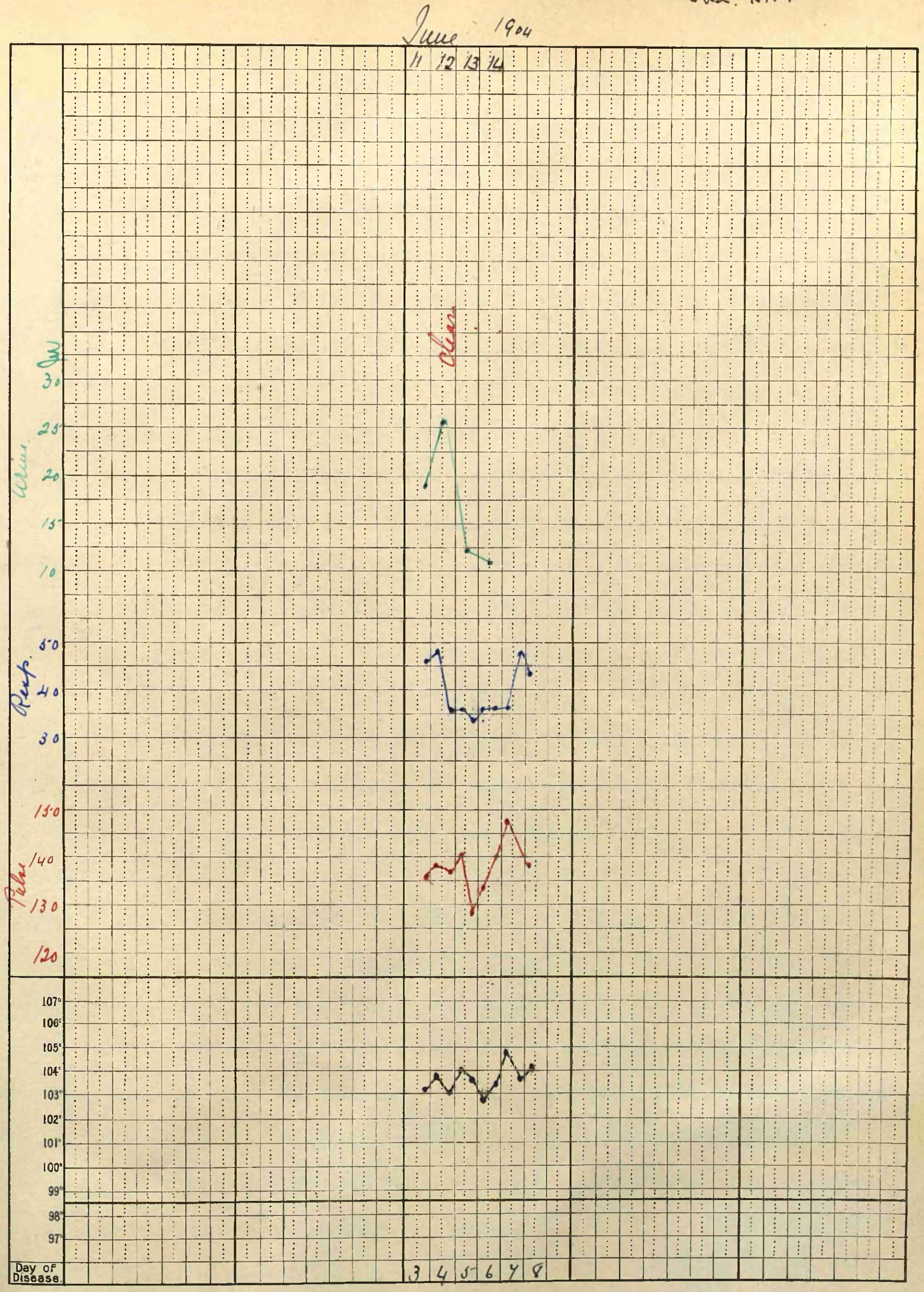
June 1904
11
12
13
14
Clear
Urine
Oz
30
25
20
15
10
Resp.
50
40
30
Pulse
150
140
130
120
107°
106°
105°
104°
103°
102°
101°
100°
99°
98°
97°
Day of Disease
3
4
5
6
7
8

CASE XXl:-

T.B., aged 10½. Admitted on April 23rd, 1904.

Illness began on April 21st with sore-throat and sickness. The rash appeared on the day of admission into Hospital.

On admissiom the temperature was 103.6, the pulse averaged 136 and the respirations numbered 36 per minute. The child was sharply ill, very restless and somewhat delirious. The rash was markedly developed and fairly uniform in its intensity over the trunk and limbs, and disappeared on pressure leaving a very pronounced yellow staining. The face was deeply flushed with very marked circumoral pallor. The tongue was dry, covered with dry mucous and showed enlarged papillae. The faucial structures were much swollen and covered with abundant discharge, and on the right tonsil there was a small patch of ulceration. The submaxillary glands on both sides were enlarged and tender. The heart and lungs were normal. The urine contained a trace of albumen. On the day after admission the child's condition became worse, the temperature rising, the pulse becoming more rapid and weaker and the restlessness increasing. She died on April 26th, that being the sixth day of her illness.

Post-mortem examination showed that there was considerable engorgement at the bases of both lungs. The heart muscle showed some albuminoid degeneration and there was some thickening along the edges of both mitral valves. The liver was fatty and the spleen was large with prominent Malpighian bodies. There was extensive ulceration of both tonsils and commencing ulceration on the surface of the soft palate while the whole of the throat was markedly congested and covered with a thick purulent exudation. The Peyer's patches were much swollen and the solitary glands were unduly prominent, and, about one foot from the/

the ileo-caecal valve in the small intestine, there was one Peyer's patch more congested than the rest, which showed commencing ulceration. The mesenteric glands were much enlarged and deeply congested. The kidneys were in a state of passive hyperaemia and there was some fatty degeneration of the cortex.

Microscopical examination of the kidneys showed that some of the capsules were slightly thickened but there did not seem to be any proliferation of the capsular cells. There was very slight, if any, increase in the number of nuclei in the glomeruli and the capsular spaces contained very little granular debris. The glomerular capillaries were dilated and their structure was distinct. Many of these capillaries contained red cells and some of them were completely blocked up by masses, which were homogeneous in appearance and which gave the characteristic hyaline stains. A number of the afferent arteries were dilated and frequently contained numerous red cells and there was fairly well marked hyaline swelling of their walls. The glomerular capillaries and other small vessels also showed some hyaline degeneration. For the most part the tubules were not separated from one another but throughout the section there were small areas in which there was marked separation as well as considerable degeneration and disintergration of the tubular cells, the intervening spaces being occupied by small infiltrating cells. In these small areas of degeneration many of the nuclei of the cells belonging to the convoluted tubules had become broken up and were distributed through the section in the form of small irregular deeply staining granules. The majority of the cells had the characters of plasma cells, already described, but there were also many polymorphonucleated leucocytes and some degenerated epithelial cells. These infiltrations/

infiltrations were only present in the cortex and there, in the intermedullary tissue, especially around the Malpighian corpuscles. There was some granular degeneration of the cells in the convoluted tubules, apart from this degeneration just described, and this was seen in a more marked degree in the cells of the ascending loop of Henle. The junctional and collecting tubes appeared to be normal.

Case XXI.

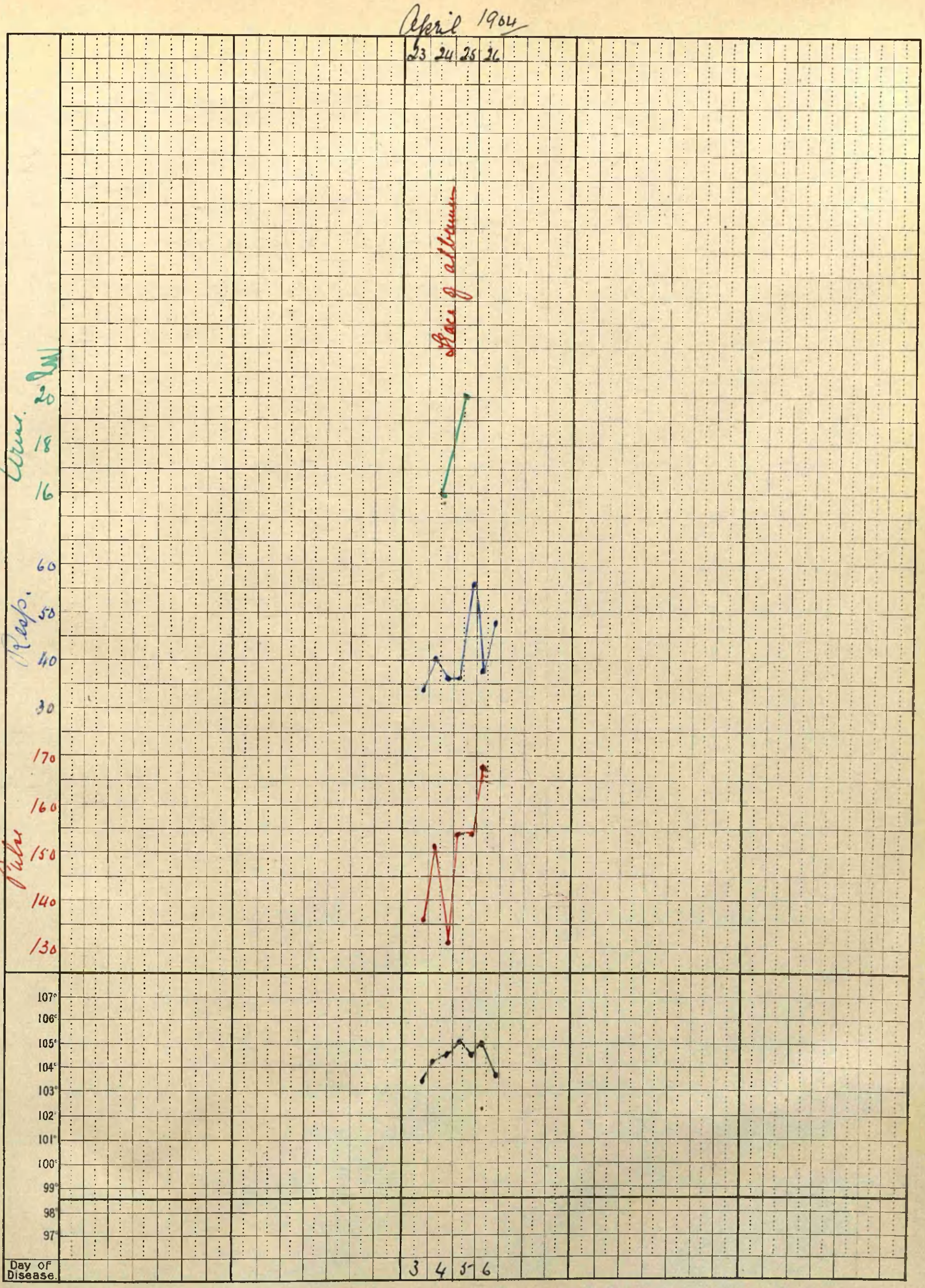
April 1904
23 24 25 26
Trace of albumen
Urine.
20 oz
18
16
Resp.
60
50
40
30
Pulse
170
160
150
140
130
107°
106°
105°
104°
103°
102°
101°
100°
99°
98°
97°
Day of Disease.
3 4 5 6

CASE XX11:-

I. A., aged 4. Admitted on May 15th, 1904.

Illness began on May 13th with sickness and vomiting. The rash was first seen on May 15th.

On admission the patient looked ill, the temperature was 103.6, the pulse numbered 140, was weak and irregular, and the respirations averaged 32 per minute. There was a fairly brilliant scarlatiform rash all over the body and limbs. The tongue was covered with a white fur, through which projected hypertrophyed papillae. The throat was much congested but there was no ulceration. All over the chest inspiration was accompanied by mucous rales, which had an articulate and liquid quality over the right base. There was no tubularity and no alteration in the percussion sound. The heart was normal. The urine was free from albumen. A few days after admission ulceration of the uvula, soft palate and tonsils commenced and rapidly extended. This was accompanied by a muco-purulent nasal discharge and great glandular enlargement. The child became very prostrate and died on May 21st,that being the ninth day of illness.

Post-mortem examination exhibited deep and extensive ulceration of the palate, tonsils and uvula,and much enlargement of the glands in the neck. There was extensive pneumonic consolidation,involving the lower lobe of the right lung,and the cut sections of the bronchioles exuded creamy pus. The left lung showed some hypostatic congestion in its lower lobe. The heart was apparently normal. The liver showed slight fatty change and the spleen was large with prominent Malpighian bodies. Peyer's patches and the solitary glands were prominent and both kidneys showed much passive congestion.

Microscopically/

Microscopically there was seen slight thickening of some of Bowman's capsules and, in a very few instances, there was some proliferation of the capsular epithelium, but these changes were not at all marked. The capsular spaces were free from granular debris. There was no increase in the number of cells in the glomeruli. The capillary structure was quite distinct and the afferent vessels, which in places appeared to be somewhat dilated, together with the capillaries contained numerous red blood cells. There was a slight degree of hyaline degeneration found in some of the arterioles and capillaries. Excepting in and around the areas of infiltration there was no separation of the tubules. The cells of the convoluted tubules and ascending loop of Henle were granular and swollen and some cells, in the latter situation, had become separated from their basement membrane. A few granular and hyaline casts were present in the smaller junctional tubules. The areas of infiltration were small and scanty. They were situated in the cortex, between the medullary rays in close proximity to the Malpighian corpuscles, and also in the boundary zone around the larger vessels. The central portions of these areas were occupied by plasma cells, leucocytes, degenerated epithelial cells and cellular detritus in the form of non-nucleated masses of granular protoplasm, together with many fragmented nuclei. Towards the periphery the remains of disintegrated tubules were seen, and still further from the centre, tubules, only slightly degenerated, were found. The plasma cells formed the majority of the infiltrating cells and neither mitosis nor phagocytosis was ween.

---

Case. XXII.

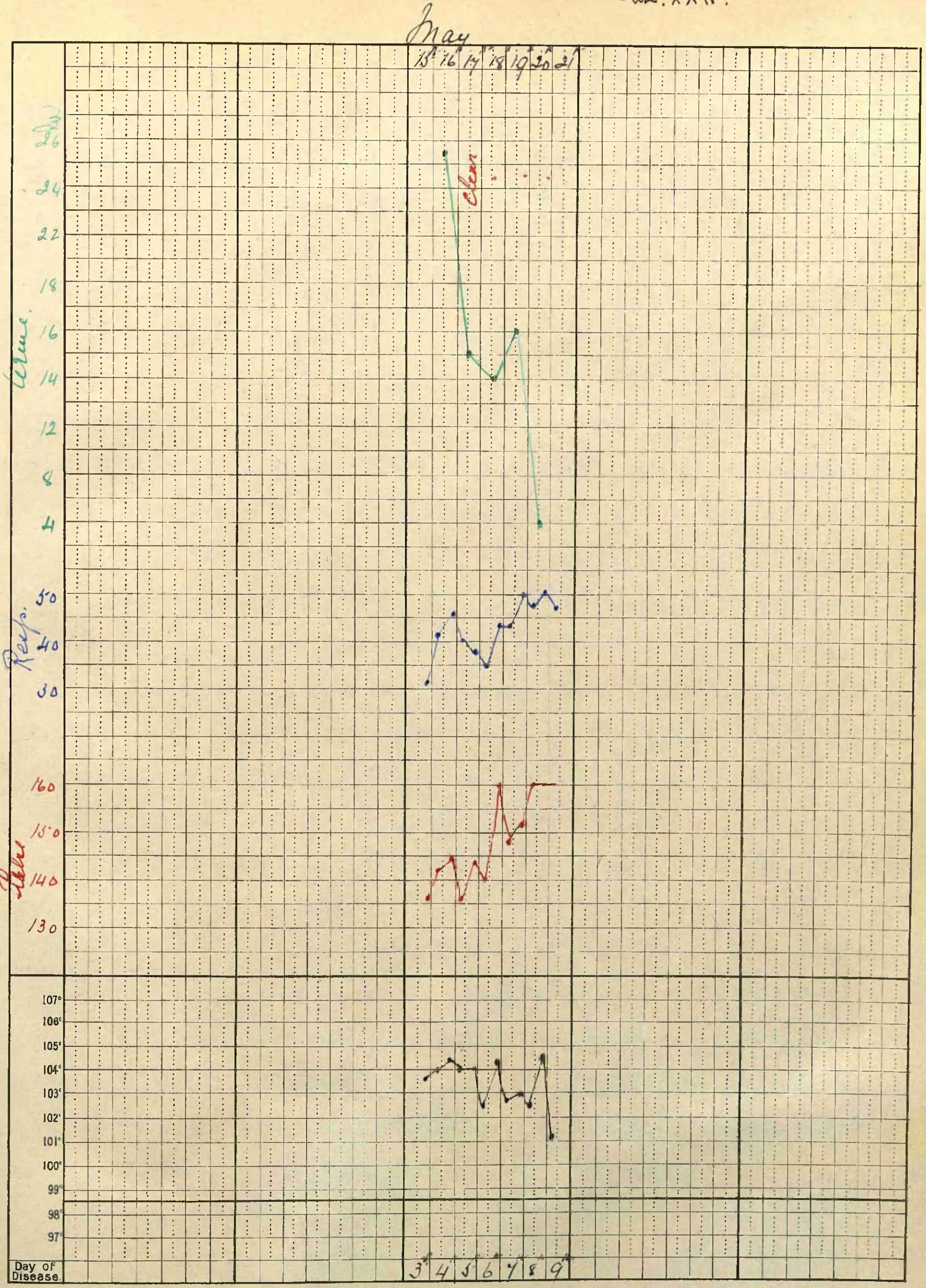
May
15
16
17
18
19
20
21
Urine
26
24
22
18
16
14
12
8
4
Clear
Resp.
50
40
30
Pulse
160
150
140
130
107°
106°
105°
104°
103°
102°
101°
100°
99°
98°
97°
Day of Disease.
3
4
5
6
7
8
9

CASE XX111:-

C.S. aged 2½. Admitted on March 30th, 1903.

Illness began on March 29th with sore-throat, sickness and vomiting The rash appeared on the same evening.

On admission the temperature was 103, the pulse registered 152, and the respirations numbered 46. There was a brilliant and intense punctiform rash of an almost orange tint on the trunk and limbs, and on the face there was a less abundant scarlatiform rash. The tongue was heavily coated and the papillae were not unduly evident. The fauces and soft palate were injected and both tonsils were moderately enlarged. There was no ulceration or exudation in the throat. The glands at the angle of the jaws on both sides were slightly enlarged. The heart and lungs were normal. The urine contained a trace of albumen. On the day after admission the rash became petechial and on the following day there was a copious muco-purulent nasal discharge together with further enlargement of the glands in the neck. On April 7th it was noted that the patient was much worse, and that physical signs of a broncho-pneumonia had become evident. She died on the evening of April 7th, that being the tenth day of illness.

On microscopical examination there was found to be no proliferation of the capsular epithelium and the capsular spaces contained very little debris. There was a slight increase in the number of nuclei in the glomeruli, the cells apparently being proliferated endothelial cells. The afferent vessels and capillaries of the glomeruli showed some hyaline change, and, for the most part, the capillary structure was distinct. There was some separation of the convoluted tubules from one another by dilated intertubular capillaries, this being most evident in the neighbourhood of the areas of infiltration. Patches of cellular infiltration were/

were seen in the cortex and were generally situated in close proximity to the Malpighian corpuscles. Examination of these patches showed that many of the cells belonged to degenerated tubules, and these structures were seen in all stages of degeneration. The infiltrating cells, however, were mostly plasma cells together with a few leucocytes, both of the lymphoid and polymorpho-nucleated variety. The plasma cells were sometimes seen to be situated inside the small blood vessels but were never found in the interior of the tubules. No mitosis or phagocytosis was evident. Most of the cells of the convoluted tubules and ascending loops of Henle were granular and a few showed hyaline degeneration. Many of the convoluted tubules contained numerous desquamated epithelial cells and occasionally polymorpho-nucleated leucocytes were present in their interiors. In addition there were seen throughout the section a few small rounded homogenous bodies, staining in the same way as the hyaline protoplasm of the cells, and in all probability derivatives of these. These bodies were seen in the capsular spaces, in the interior of the tubules, in the cells of the tubes, and also lying free in the areas of infiltration.

Case XXIII.

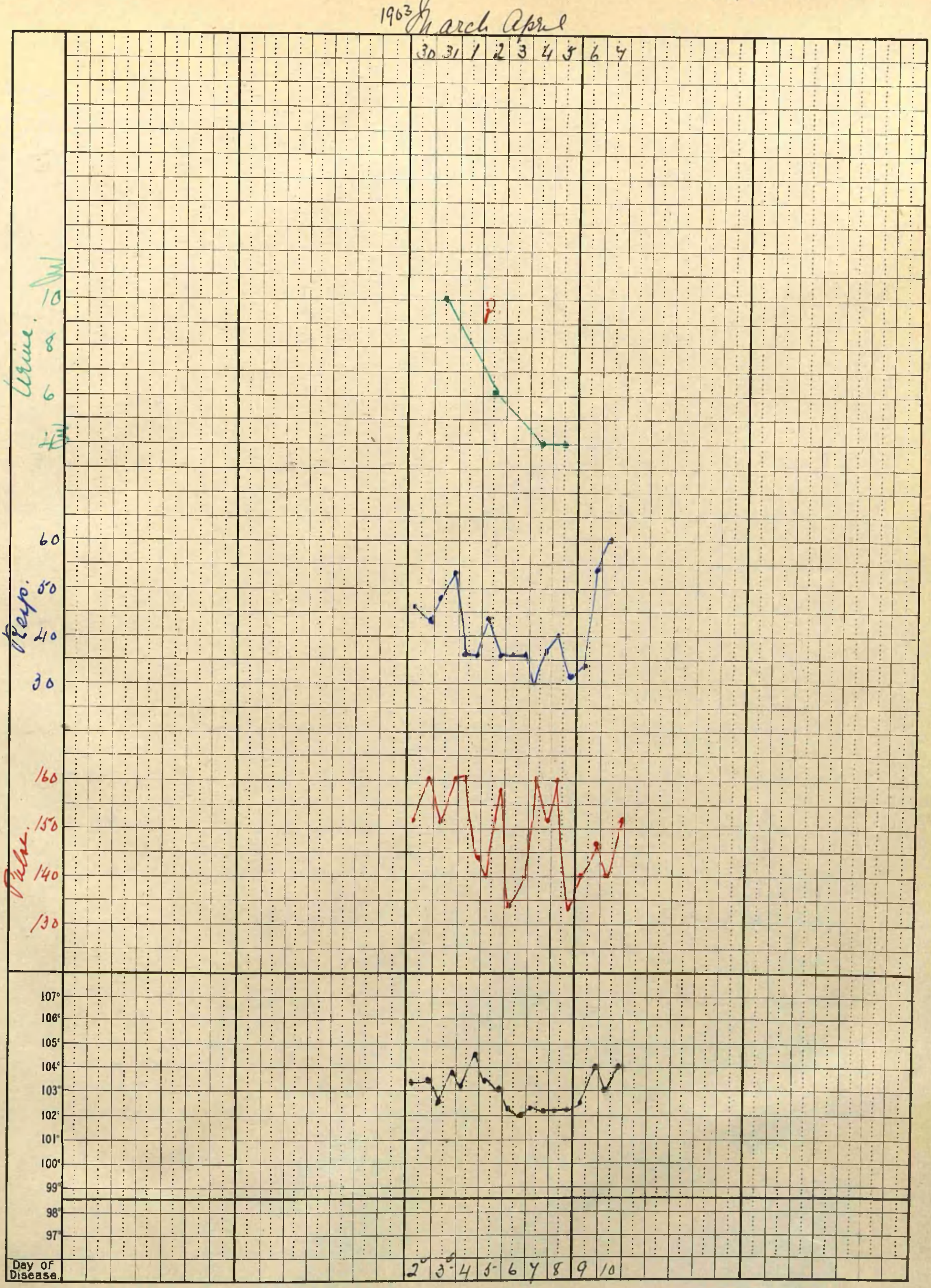
1903 March April
30 31 1 2 3 4 5 6 7
Urine.
10
8
6
P
Resp.
60
50
40
30
Pulse.
160
150
140
130
107°
106°
105°
104°
103°
102°
101°
100°
99°
98°
97°
Day of Disease.
2 3 4 5 6 7 8 9 10

## CASE XXlV:-

### L.D.

The report of this case unfortunately could not be found.

Microscopical examination showed that there was no proliferation of the cells in Bowman's capsules and no increase in the number of nuclei in the glomeruli. The capsular spaces contained small quantities of granular debris and also a few complete epithelial cells, which were derived from the commencement of the convoluted tubules. The glomerular capillaries were dilated and filled with blood cells, and the capillary structure was quite distinct. Some of the afferent vessels were dilated and a few showed slight hyaline change. There was no separation of the tubules. The cells of the convoluted tubules and ascending loops of Henle were granular and the former tubules contained some granular material, while ~~the~~ tube casts, both granular and hyaline in character, were found in the junctional tubes. There were small patches of infiltration, situated in the cortex around the Malpighian corpuscles and also in the medullary rays of the pyramidal portion. The majority of the infiltrating cells were plasma cells and these were found in and between the smaller vessels. The same degeneration of the tubular structures was found in and around these areas of infiltration, as has already been described, and the nuclear fragmentation was very evident. No mitosis or phagocytosis was seen.

---

## CASE XXV:-

### Mrs. D. aged 23. Admitted on Jan. 21st, 1903.

This patient was delivered of a male child on Jan. 19th, the labour being apparently normal. On the evening of Jan. 20th she began to experience headache and sore-throat and on the morning of Jan. 21st it was noticed that the lochia had a fetid odour. The rash appeared on the day of admission into hospital.

On admission the temperature registered 104, the pulse numbered 132 and the respirations averaged 28 per minute. There was a profuse and vivid scarlatiform rash over the trunk and limbs. The tongue was furred and commencing to desquamate, the papillae being considerably enlarged. The soft palate and fauces were congested and the tonsils were slightly swollen. There was no secretion or ulceration of these parts. Examination of the chest was negative. The urine contained a haze of albumen. Patient was the subject of puerperal fever. During her residence in hospital the temperature ran a very erratic course and at times was as high as 108, this in all probability being due to the septic absorption from the uterus. The symptoms associated with the puerperal condition grew steadily worse and she died on Feb. 1st, that being the tenth day after the onset of the Scarlet Fever.

Microscopically the kidney presented great tubular degeneration together with large areas of infiltration throughout the cortex. The majority of the infiltrating cells were plasma cells, and there were also many leucocytes and degenerating epithelial cells. The same arrangement of disintegrating tubules, as has been previously described, was seen. In the portion of the cortex, not affected by these infiltrations, the tubules were somewhat separated from one another. The cells of the convoluted tubules and ascending loops of Henle were swollen and granular/

granular and in a few places exhibited hyaline degeneration, while the tubules themselves contained much granular debris. The cells of the ascending loops of Henle had become separated from one another and from their basement membranes and in some of the tubules they were increased in number, but no evidence of mitosis was seen. There was no proliferation of the capsular epithelium and no increase in the number of nuclei in the glomeruli, but the capsular spaces contained considerable quantities of granular material. The smaller vessels and glomerular capillaries showed some hyaline change and most of them were filled with blood cells.

---

Case. XXV.

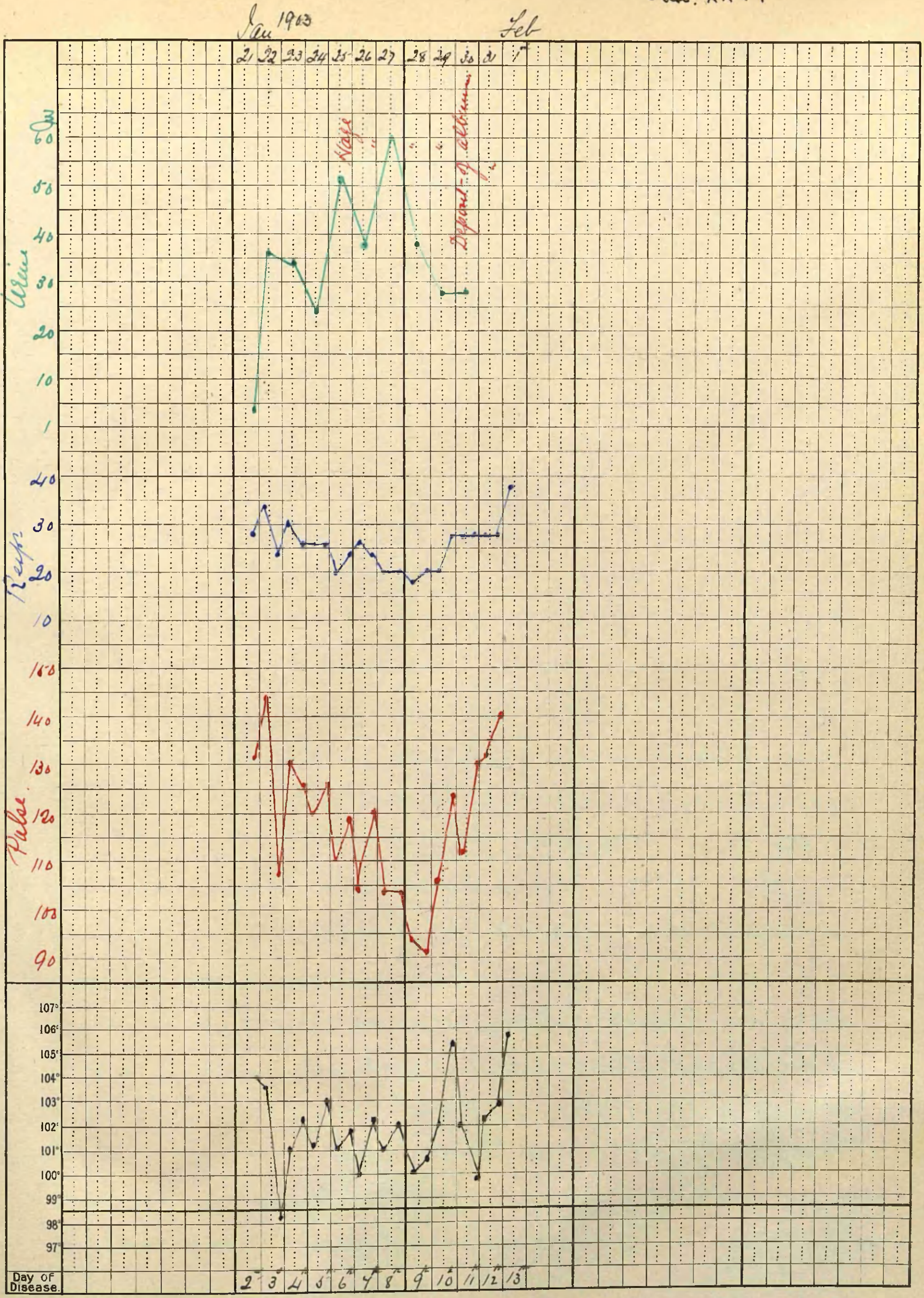
Jan 1903
Feb
21 22 23 24 25 26 27 28 29 30 31 1
Urine
60
50
40
30
20
10
1
Haze
"
"
"
"
Deposit of albumin
Resp.
40
30
20
10
Pulse.
150
140
130
120
110
100
90
107°
106°
105°
104°
103°
102°
101°
100°
99°
98°
97°
Day of Disease.
2 3 4 5 6 7 8 9 10 11 12 13

CASE XXVI:-

E.McC., aged 4. Admitted on May 22nd, 1903.

Illness commenced on August 20th, with sickness and sore-throat. The rash was noticed on Aug. 21st.

On admission the temperature was 102, the pulse numbered 132 and the respirations averaged 34 per minute. There was a very intense and abundant scarlatiniform rash, uniformly distributed over the trunk and limbs. It was almost of an orange colour and the yellow staining of the skin on pressure was very marked. The tongue was swollen, fairly moist and was peeling. The fauces and soft palate were congested and the tonsils were moderately enlarged. There was no exudation or ulceration in the throat. The glands at the angle of the jaw were tender and enlarged. The heart and lungs were normal. The urine was free from albumen. On Sept. 2nd, it was noted that the temperature had remained high and that the pulse had continued rapid but was fairly good in quality. There was a copious sero-purulent discharge from the nose, which had caused some excoriation of the alae nasi. The glands were much enlarged, both the submaxillary and those at the angle of the jaw, and there was ulceration of both tonsils with an abundant brownish secretion. From this time onwards the patient's condition grew steadily worse, the temperature still remaining highly febrile and the pulse rate increasing. The amount of urine passed fell during the last eight days of the illness, from 4 to 8 ozs. being the average daily out-put, but albumen was never detected. She died on Sept. 11th, that being the 24th day of illness.

Post-mortem examination showed the presence of about 20ozs of turbid blood/

blood stained fluid in the right pleural cavity. This fluid appeared to have made its way into the pleural cavity from the posterior mediastinum, and there was no evidence of any pleurisy. In the areolar tissue around the oesophagus there was some haemorrhage, and this space communicated by a small opening with the right pleural cavity. Both lungs were oedematous and on the sub-pleural surfaces of each there were numerous punctiform haemorrhages, The bronchial glands were much congested. The cardiac muscle showed some albuminoid degeneration, but the heart was otherwise normal. The liver was very fatty, and the spleen was a little enlarged and firm in consistence with not very prominent Malpighian bodies. The Peyer's patches in the last foot of the ileum were swollen, this being most marked in the immediate neighbourhood of the caecum. There was very extensive pharyneal ulceration and almost total loss of the tonsils from the same cause. The epiglottis and the crypts showed considerable ulceration but there was absolutely no involvement of the laryngeal structures. The kidneys were of normal size with non-adherent capsules. The cortices were pale and showed fatty degeneration and there was slight congestion of the pyramids.

Microscopical examination of the kidney showed that there was no proliferation of the capsular epithelium. The capsular spaces contained a small quantity of granular debris. There was no increase in the glomerular nuclei and the capillaries of the glomeruli were quite distinct. Some of the afferent vessels showed slight hyaline degeneration. There was some granular degeneration of the cells in the convoluted tubules and ascending loops of Henle but the nuclear staining was good. The junctional and collecting tubes contained a few casts of the granular and hyaline variety but were otherwise normal. In the cortex there were some localized areas of cellular infiltration and apart from these there was no tubular separation. These areas were fairly numerous and contained many disintegrating tubules as previously described. Plasma cells formed the majority of the infiltrating cells, and degenerated epithelial cells were seen playing the part of phagocytes. The cells that were being digested were generally red blood corpuscles and more rarely polymorpho-nucleated leucocytes, both of which were foun in the interiors of the degenerated epithelial cells surrounded by a clear zone. No mitosis was evident.

Case. XXVI.

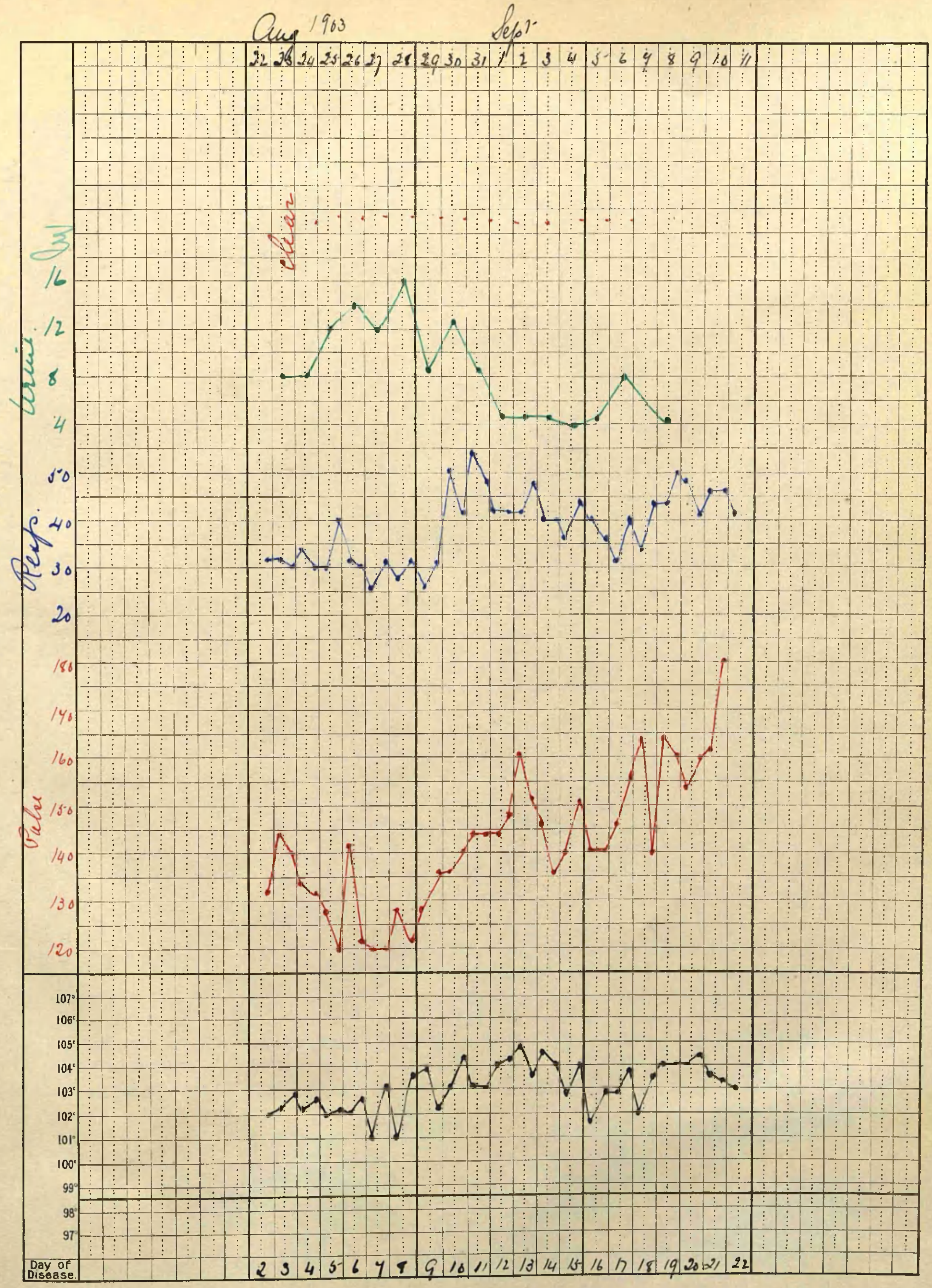
Aug 1903
Sept
22 23 24 25 26 27 28 29 30 31 1 2 3 4 5 6 7 8 9 10 11
Urine. Oz
16
12
8
4
Clear
Resp.
50
40
30
20
Pulse
180
170
160
150
140
130
120
107°
106°
105°
104°
103°
102°
101°
100°
99°
98°
97°
Day of Disease.
2 3 4 5 6 7 8 9 10 11 12 13 14 15 16 17 18 19 20 21 22

CASE XXV11:-

J.D., aged 1 year and 8 months. Admitted on April 5th, 1903.

Illness began on April 3rd, with sore-throat, sickness and vomiting. The rash appeared on the day of admission.

On admission the temperature was 101.4, the pulse numbered 144 and the respirations averaged 28. There was a well marked scarlatiniform rash covering the whole trunk, being very abundant over the legs but sparse on the arms. The fauces pharynx and soft palate were deeply congested. Both tonsils were much enlarged and there was a considerable amount of exudation over all these parts. There was no ulceration. The glands on both sides of the neck were slightly enlarged and tender. The heart and lungs were normal. The urine was free from albumen. On April 11th it was noted that since admission the temperature had remained febrile; that ulceration of the fauces and soft palate had commenced, and that the glands of the neck had become further swollen and painful. The urine had diminished in quantity, only from four to six ozs. being passed in the twenty-four hours, and it contained a trace of albumen. The patient grew steadily worse and died on April 20th.

Microscopical examination of the kidneys showed that the chief lesions consisted of an infiltration of the interstitial tissue with small cells, and of tubular degeneration, the former condition being very marked, the infiltrating cells being distributed widely throughout the cortex. The infiltrating cells were mostly plasma cells and leucocyte with which were found many degenerated epithelial cells from the disintegrating tubules. No mitosis or phagocytosis was seen. The same arrangement of tubular degeneration, as previously described, was present. The Malpighian corpuscles were normal except for a slight hyaline degeneration/

degeneration of the glomerular capillaries and of the afferent arterioles The tubules were not separated from one another except in the areas of infiltration. The cells of the convoluted tubules and ascending loops of Henle were granular and swollen but generally the nuclear staining was good. A few tube casts, mostly hyaline, were present in the smaller junctional tubes.

---

Case XXVII.

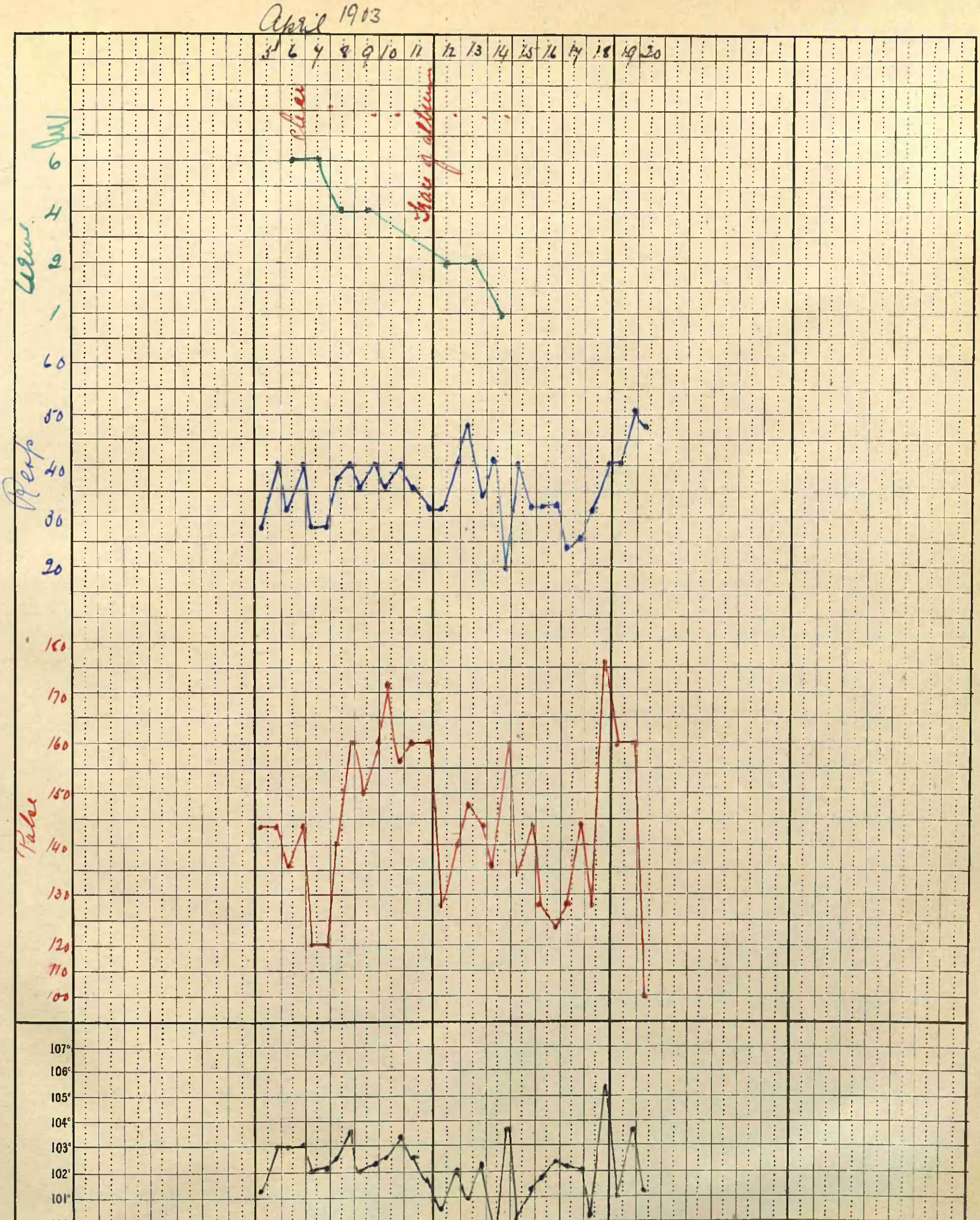
April 1903
3 6 7 8 9 10 11 12 13 14 15 16 17 18 19 20
Album. p.m.
6
4
2
1
Clear
Trace of albumin
Resp
60
50
40
30
20
Pulse
180
170
160
150
140
130
120
110
100
107°
106°
105°
104°
103°
102°
101°
100°
99°
98°
97°
Day of Disease.
3 4 5 6 7 8 9 10 11 12 13 14 15 16 17 18

### CASE XXV111:-

J. McK., aged 5. Admitted on May 13th, 1904.

Illness began on May 11th, with sore-throat, sickness and vomiting. The rash was seen on May 12th.

On admission the temperature was 103, the pulse numbered 146 and the respirations registered 40 per minute. All over the body and limbs there was a fully developed scarlatiniform rash, which had a bluish tint. The face was pallid. The tongue was peeled and dry and the mouth was in a dirty condition. There was much congestion of the throat but no ulceration, and the glands of the neck were slightly enlarged. The heart and lungs were normal. The urine was free from albumen. On May 21st, it was noted that sinceadmission the condition of this patient had not improved, the temperature having remained highly febrile, the pulse having maintained its rate and ulceration of the fauces and soft palate having commenced. There was no diminution in the quantity of urine passed and it was still free from albumen. There was a septic rash most marked on the knees and elbows. From this time onwards his condition grew worse and he died on May 30th, that being the 20th day of illness.

Post-mortem examination revealed the presence of a little serous fluid in both pleural cavities. The upper lobes of both lungs were normal, but in the bases of both lower lobes there was some hypostatic congestion. The heart muscle was the seat of much albumenoid degeneration. The left ventricle was in systole and the mitral valve showed commencing acute endocarditis. The tricuspid, aortic and pulmonary valves were normal. The liver showed some fatty change and the pancreas was enlarged but otherwise normal. The spleen was traversed by a band of firm fibrous tissue and the Malpighian bodies were very distinct. The Peyer's patches and solitary glands were all enlarged and prominent/

prominent but there was no ulceration. The kidneys were both very much enlarged with non-adherent capsules. The normal cortical markings were nearly lost and the cut surface of the organ exuded a large quantity of blood. The tissue around the kidney was extremely congested, being nearly black in colour.

Microscopically there was no proliferation of the capsular epithelium found and the capsular spaces contained only very little granular debris. The capillaries of the glomerules were distinct and in their interior were seen a few hyaline masses. There was a slight increase in the number of cells in the glomeruli, these being mostly derived by rpoliferation of the capillary endothelium, The tubules were separated from one another, the capillaries between them being distended with blood cells. All the cells of the convoluted tubules and ascending loops of Henle showed granular degeneration and were swollen, and in places the protoplasm was vacuolated. Occasionally some hyaline degeneration of these cells was evident. There were very large areas of cellular infiltration, in which there was great tubular degeneration. The infiltrating cells were mostly plasma cells together with lymphocytes, degenerated epithelial cells and a few polymorpho-leucocytes. No mitosis was seen but some of the epithelial cells were found to be acting as phagocytes, polymorpho-nucleated leucocytes and red blood corpiscles being seen in their interiors, surrounded by a clear zone, and evidently in process of being digested. In the degenerating tubules there was seen marked fragmentation of the epithelial nuclei, the deeply staining granules being scattered throughout the section, and in some places there had been complete distruction of the nuclei, thus leaving masses of very granular un-nucleated protoplasm.

---

Case. XXVIII.

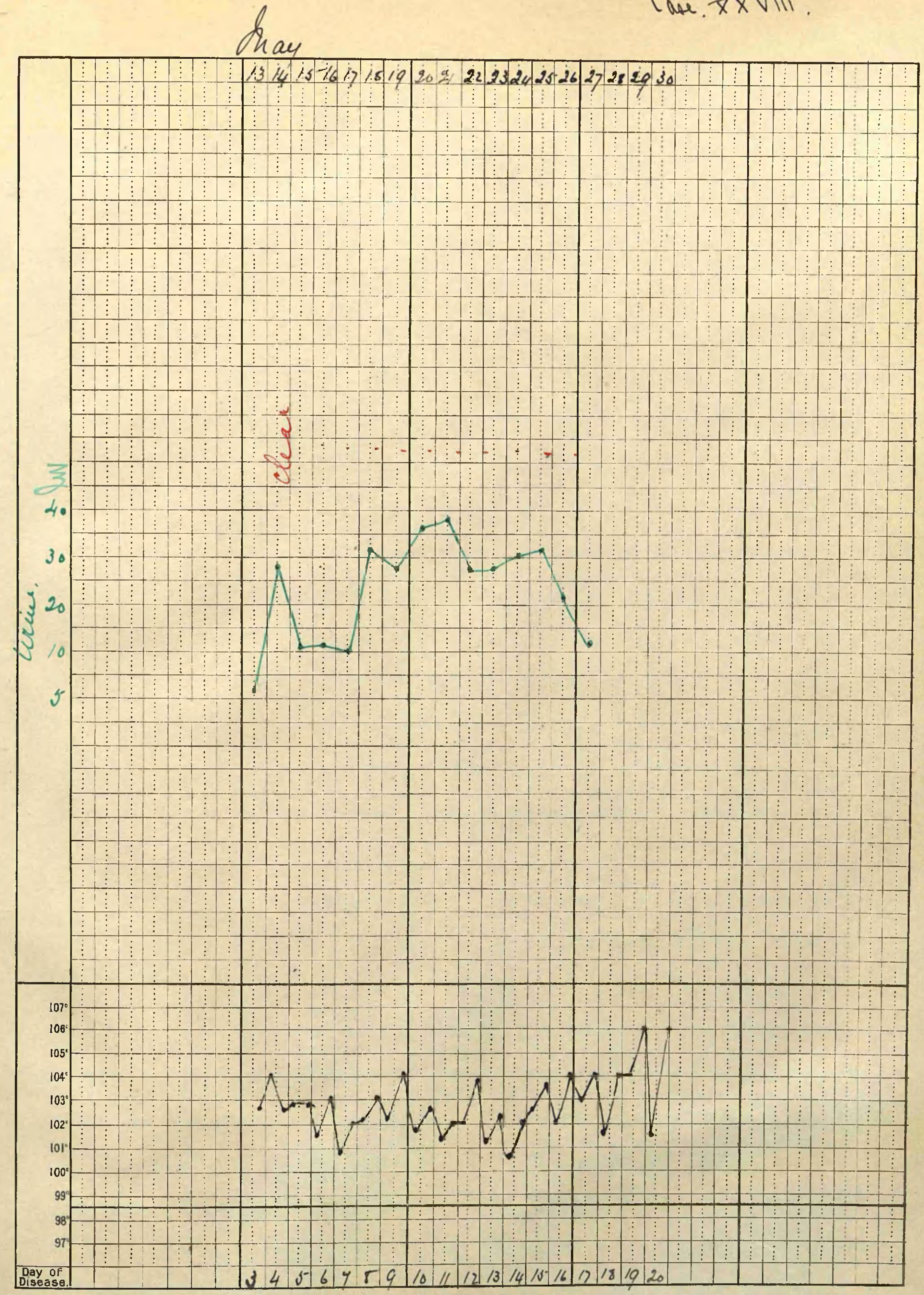
May
13 14 15 16 17 18 19 20 21 22 23 24 25 26 27 28 29 30
Urine. oz
40
30
20
10
5
clear
107°
106°
105°
104°
103°
102°
101°
100°
99°
98°
97°
Day of Disease.
3 4 5 6 7 8 9 10 11 12 13 14 15 16 17 18 19 20

## CASE XX1X:-

L.W., aged 4. Admitted on Nov. 14th, 1900.

There was no history regarding the onset of the illness.

On admission the temperature registered 105.2, the pulse numbered 160 and the respirations averaged 40 per minute. The patient was much collapsed, cyanosed and appeared to be very ill. There was no rash but all over the trunk the skin was dry and on the extremities there was commencing desquamation. The tongue was moist and coated with a thick white fur. The fauces and palate were much congested and both tonsils were swollen and covered with irregular areas of dirty white easily separable exudation. There was slight glandular enlargement. The heart and lungs were normal. The urine was free from albumen. Subsequent to admission the condition of the patient grew worse, ulceration of the fauces, uvula and buccal mucous membrane commenced and increased in spite of treatment, the pulse increased in rate and became irregular, and the patient was very delirious. The quantity of urine passed became less and there was a very small amount of albumen. Patient died at 4.30 a.m. on Nov. 18th.

Microscopically the chief lesion seen was interstitial infiltration. It occurred in the cortex in large patches, in the central portions of which all tubular structure was lost while in the periphery degeneration of the tubules in all stages was seen. The infiltrating cells were mostly of the plasma type together with a few polymorphonucleated and lymphoid leucocytes. There was no protiferation of the capsular epithelium and no increase in the number of nuclei in the glomeruli. The glomerular capillaries were distinct and the capsular spaces contained a small quantity of granular material. The cells of the convoluted tubules and ascending loops of Henle were granular and swollen, and the junctional tubules contained a few granular and hyaline casts.