https://theses.gla.ac.uk/

Theses Digitisation:

https://www.gla.ac.uk/myglasgow/research/enlighten/theses/digitisation/

This is a digitised version of the original print thesis.

Copyright and moral rights for this work are retained by the author

A copy can be downloaded for personal non-commercial research or study, without prior permission or charge

This work cannot be reproduced or quoted extensively from without first obtaining permission in writing from the author

The content must not be changed in any way or sold commercially in any format or medium without the formal permission of the author

When referring to this work, full bibliographic details including the author, title, awarding institution and date of the thesis must be given

Enlighten: Theses
https://theses.gla.ac.uk/
research-enlighten@glasgow.ac.uk

A Study of Pigmented Lesions of the Skin in vivo Using the Zeiss Operation Microscope and correlation of the surface appearances of these lesions with their histology

A Thesis Submitted for the

Degree of Doctor of Medicine

of The University of Glasgow

by

Rona McLeod MacKie

1969

ProQuest Number: 10868069

All rights reserved

INFORMATION TO ALL USERS
The quality of this reproduction is dependent upon the quality of the copy submitted.

In the unlikely event that the author did not send a complete manuscript
and there are missing pages, these will be noted. Also, if material had to be removed,
a note will indicate the deletion.



ProQuest 10868069

Published by ProQuest LLC (2018). Copyright of the Dissertation is held by the Author.

All rights reserved.
This work is protected against unauthorized copying under Title 17, United States Code
Microform Edition © ProQuest LLC.

ProQuest LLC.
789 East Eisenhower Parkway
P.O. Box 1346
Ann Arbor, MI 48106 – 1346

Acknowledgments

It is a pleasure to offer my thanks to those who have helped me in this study, in particular Professor John Milne for encouragement at all stages of the project. The work has been carried out in the Department of Dermatology, Anderson College and I am grateful to the technical members of staff for their assistance.

The patients included in this study have been referred to me by consultants in the West of Scotland. Without their interest and willing cooperation this work would obviously not have been feasible and I am therefore extremely grateful for their help. Many of the patients have been referred to me by the consultants of the West of Scotland Regional Plastic Surgery Service and I would like to thank them for their help.

I also wish to acknowledge the assistance of members of the pathology departments of the Royal, Western and Victoria Infirmaries, and The Southern General Hospital in supplying me with histological studies of lesions included in this study for examination.

Mr. Iain MacKie and Miss Ruby Brown of the photographic department of the Anderson College have given valuable assistance in the preparation of black and white prints and for this I am extremely grateful.

This work was carried out while in receipt of a research grant from The Scottish Hospitals Endowment Research Trust. I would like to thank members of the Trust for their interest and financial support.

Contents

Acknowledgments

Historical Background and Introduction 1

The Method 16

The Lesions Studied 17

Junctional Naevi 18

Comments on the Junctional Naevi 36

Compound Naevi 37

Comments on Compound Naevi 101

Malignant Melanomata 102

Comments on Malignant Melanomata 140

Blue Naevi 142

Comments on Blue Naevi 147

Intradermal Naevi 148

Comments on Intradermal Naevi 160

Cavernous Angiomata 161

Comments on Cavernous Angiomata 169

Sclerosing Angiomata 170

Comments on Sclerosing Angiomata 176

Basal Cell Papillomata 177

Comments on Basal Cell Papillomata 188

Basal Cell Carcinomata 189

Comments on Basal Cell Carcinomata 195

Discussion 196

Conclusions 220

References 222

Historical Background and Introduction

The first documented description of malignant melanoma was made by Hippocrates in the fifth century B.C. From this time there are apparently no well documented reports of melanomata or other pigmented lesions until the 17th century when Highmore, Bartholin and Bonet reported fatal lesions associated with metastatic black tumours. These early accounts were reviewed by Eiselt in 1861 and 1862. The medical literature of the early 19th century was much enlivened by an extremely acrimonious argument conducted in print between Laennec and Dupuytren; in 1805 Laennec read a paper to the Societe de L'Ecole de Medecine de Paris in which he included in a classification of tissue change in disease 'les melanoses' (the derivation of the name is from the Greek melas: black), and in 1806 he gave a clear account of pulmonary metastases from melanomata, emphasising that the condition must not be confused with phthisis as had previously been the case. Dupuytren in replying to Laennec's paper of 1805, stated most emphatically that he had given an identical classification of tissue changes in a lecture to the Societe in 1803. After several heated exchanges, the editor of the journal requested that the two gentlemen continue their discussion privately, and in reviewing the claims of both parties, Eiselt considered that Laennec was in fact the first to describe melanomata, although Dupuytren's clinical descriptions of the condition were clear, and he was credited with the first clinical description of generalised melanosis.

In 1833 Carswell used the term melanoma to describe a black fungating lesion observed on the skin, and in 1858 Pemberton published a monograph on melanosis in which he gave detailed clinical observations on 17 cases of cutaneous melanomata and 8 ocular melanomata. He emphasised the rapid progression of the disease once the primary lesion had metastasised, and as a result of thorough post-mortem examination drew attention to the fact that the secondary deposits from the tumour are frequently scattered widely throughout the tissues of the body.

The microscopic study of pigmented lesions was early and thorough in an attempt to find the origin and cause of the fatal pigmented growth which was by this time well documented. Heusinger in 1823 saw and described clusters of melanin granules in the cells of the epidermis, and in 1870 Paget in his lectures on surgical pathology included drawings of neoplastic melanocytes. The first recorded description of the normal melanocyte was made by Waldeyer in 1871 when he described dendritic cells in the epidermis containing dark pigmented granules. Five years before this Langerhans had, while still a medical student, demonstrated by the technique of gold impregnation the non-pigmented dendritic cells of the epidermis which he did not associate with the pigmentary system. These are the Langerhans cells which bear his name; their function has been much debated in recent years, as has their relationship to the melanocyte system. Breathnach by tissue culture studies has now

shown that the Langerhans cell system is not derived from the melanocyte system by proving that the Langerhans cells do not migrate from the neural crest (Breathnach 1968A). Theories as to their function have included such possibilities as their being effete or resting melanocytes or regulators of keratinization (Wolf and Winkelmann 1967). Current opinion, however, favours the view that they are a type of macrophage (Breathnach 1968B).

Improvements in methods of staining the epidermis to demonstrate the melanocyte were made steadily at the beginning of the 20th century. In 1906 Bizzozero described a method of silver impregnation of the epidermis which clearly demonstrated the dendritic configuration of the cell. Bloch in 1917 described the D.O.P.A. (dihydroxyphenylalanine) method for the specific demonstration of melanocytes; this method depends on the presence in the melanocyte of the enzyme dopa-oxidase which oxidises 3,-4-dihydroxyphenylalanine to dopa-quinone; this compound is then further oxidised to melanin protein. In 1935 Becker senior developed a variation of this dopa method using paraffin sections instead of frozen sections which gave more consistent results (Becker 1935).

The assumption that dopa was in fact the precursor of melanin in human skin was challenged by Raper and his colleagues who, as a result of their work on aerobic oxidases maintained that the true precursor was tyrosine which was oxidised to dopa by the enzyme tyrosinase, an enzyme discovered in 1895 by Bourquelot and Bertrand

Figure 1

The formation of melanin from tyrosine (Raper).

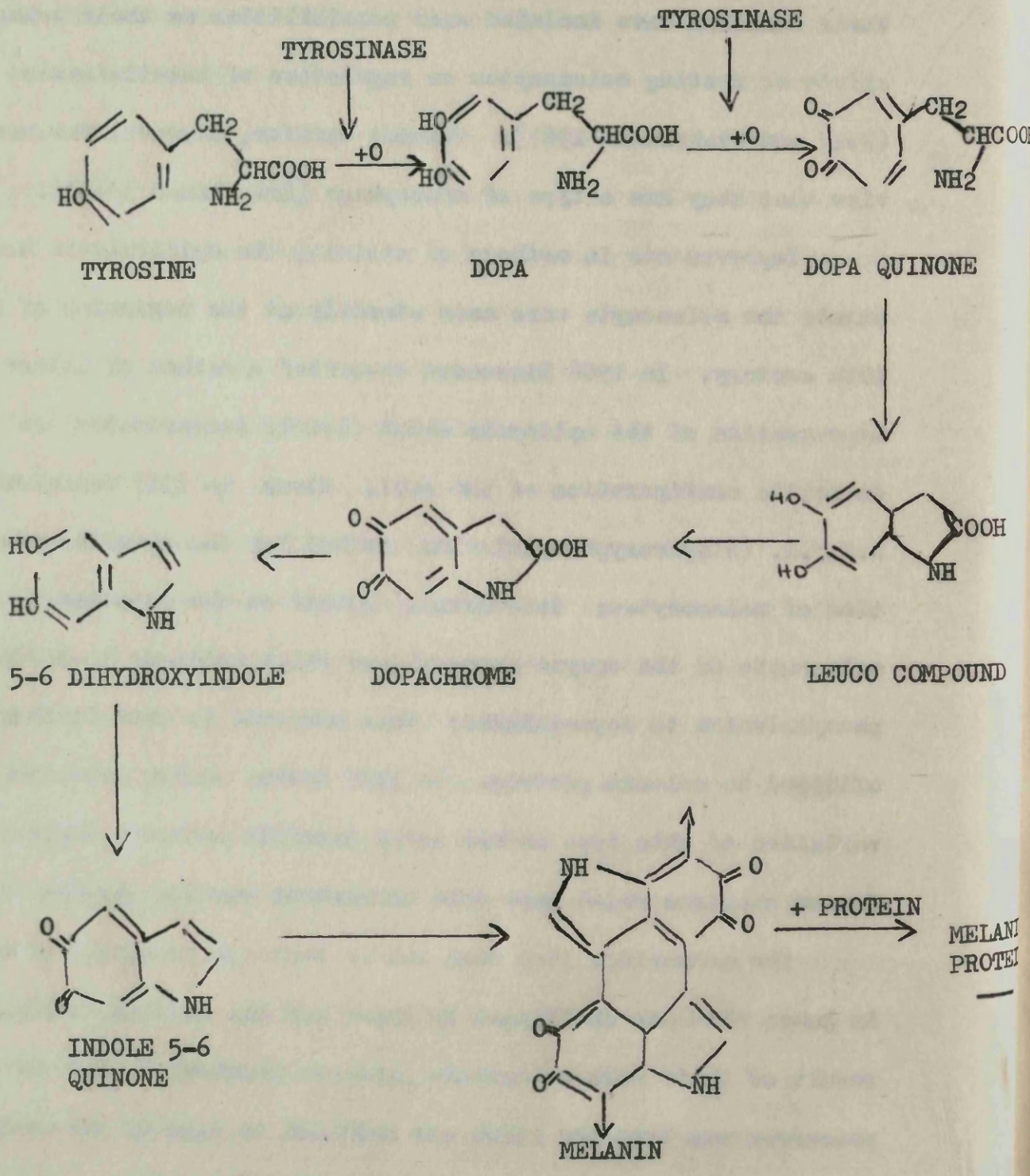

as a result of work on the fungus Russula nigricans. Shortly before this Biedermann had shown that oxygen is necessary for melanin formation after work on the mealworm beetle Tenebrio molitor. A theoretical pathway for the metabolism of tyrosine to melanin was put forward by Raper in 1928, and is shown in figure 1 (opposite). This pathway was accepted by biochemists, but disputed by histochemists who had misgivings about accepting a metabolic pathway for vertebrates in vivo which had been worked out on the basis of a homogenate obtained from invertebrates. Proof that this pathway was feasible in mammals was obtained from the work of Hogeboom and Adams in 1942 when they demonstrated the presence of tyrosinase in mammalian tissue. The controversy was settled in 1948 when Fitzpatrick and his colleagues irradiated epidermis with ultraviolet light thus activating the tyrosinase naturally present in the epidermal melanocytes, and thereby proving that tyrosine was indeed the naturally occurring melanin precursor in human skin (Fitzpatrick et al. 1950).

Recent work on the biochemistry of melanin formation has challenged Raper's assumption that melanins are composed entirely of indole 5-6 quinone units; Swan considered it more probable that there were also present hydrogenated 2-3 dihydroxyindole and dopachrome units (Swan 1963, Robson and Swan 1966). The most extensive work on this problem in recent years has been done by Nicolaus and Piattelli who have demonstrated conclusively that animal melanins are indole in type in contrast to the catechol type of melanins of

plant origin. They have also thoroughly investigated the nature of the linkage of melanin to the protein complex to which it is always joined in the natural state, and suggest that these linkages are formed by sulphur-containing amino acids, chiefly cysteine through a thioether linkage (Nicolaus et al. 1962, 1963, 1964, Nicolaus 1968).

The enzyme which Bloch utilized in developing his dopa method of staining he named 'dopa oxidase'. This enzyme is now known to be tyrosinase which acts at two points in the tyrosine to melanin reaction, firstly catalysing the oxidation of tyrosine to dopa and then dopa to dopa quinone. Tyrosinase is a copper-containing enzyme officially named o diphenol oxygen oxidoreductase with a formal enzyme classification number of 1.10.3.1. Details of the role of tyrosinase in melanin synthesis have been comprehensively reviewed by Lerner (Lerner 1953).

The work of Fitzpatrick and his colleagues in recent years has contributed many details to the knowledge of the ultrastructure of the melanocyte and as a result of their electron microscope studies detailed knowledge is now available concerning the ultrastructure of both the normal and the abnormal melanocyte (Fitzpatrick 1965A, 1967).

The embryological origin of the melanocyte is a subject which has been fiercely debated. In 1894 Unna and his colleagues described the phenomenon which they named 'abtropfung', the downward migration of naevus cells from the epidermis into the dermis. After making

this observation they postulated an epidermal origin for the melanocyte. Shortly after this, Eve in Britain supported Unna's theory, while Borcea offered opposition, maintaining that both melanocytes and naevus cells arose from neural elements (Eve 1903, Borcea 1909). Bloch then published evidence supporting an epidermal origin for the melanocyte, and in 1926 the French-canadian Pierre Masson published his views on this problem. Theories which, although not satisfactory proved until nearly 30 years later, have been shown to be remarkably prophetic; he suggested that the melanocyte was of neuroectodermal origin, and considered that the active secretion of melanin granules by the cells merited naming them the melanogenic system.

Proof of the neural origin of the melanocyte was obtained in 1936 when Dorris demonstrated the migration of melanoblasts from the neural crest to the epidermis in the chick embryo. In 1940 Rawles showed the mammalian melanocyte also to be of neural origin, after work on mouse embryos. Hu, in 1957, proved conclusively the neural origin of the human melanocyte as a result of her tissue culture studies and time lapse cinephotography. The controversy has not yet completely ended as in recent years Allen has continued to support the theory that the melanocyte arises from the epidermis, but the work of Rawles and Hu is now generally accepted as providing convincing evidence of the neural origin of this cell type.

It is indicative of the degree of interest and discussion aroused by the melanocyte that since 1948 six pigment cell conferences

Table 1

Junctional Naevus:	Increase of melanocytes in basal layer plus downward proliferation of basal layer melanocytes of epidermis towards the dermis.
Intradermal Naevus:	Packets of adult naevus cells in dermis; no epidermal abnormality.
Compound Naevus:	Features of both the junctional and intradermal naevus found together.
Malignant melanoma:	Neoplastic growth arising from melanocytes.
Blue Naevus:	Groups of elongated flattened melanocytes in lower half of dermis: Overlying epidermis normal.

have been held with the aim of drawing together workers investigating problems concerned with this cell. The published proceedings of these conferences, initiated by Myron Gordon, give a very good picture of the range and depth of current research problems in this field. One of the valuable results of the 6th International Pigment Cell Conference, held in May 1965 was the revision of the terminology of melanocyte organelles (Fitzpatrick et al. 1965B). It was agreed that all precursors of the fully formed melanin granule be termed premelanosomes, and that the end result of melanin synthesis, previously called the melanin granule, be renamed the melanosome.

Unfortunately the terminology of the histological features observed in microscopic study of pigmented lesions have not yet been as clearly laid down. Traub and Keil in 1940 gave clear definitions to the histological terms then used in the description of pigmented lesions, and following this Allen and Spitz further clarified the histological terms then in use (Allen 1949). In particular the work of Spitz in recognising as a distinct entity the juvenile melanoma has been of great value to other histopathologists (Spitz 1948). Before this time the juvenile melanomata had been considered to be malignant melanomata and this confusion had added to the already difficult problem of prognosis and treatment in both types of lesion. Table I opposite gives the definitions of histological descriptive terms as they will be used in this discussion. These are consistent with the terminology used by the majority of histopathologists in

this country although confusion can still arise in published material in which the terminology used is not initially clearly defined.

The criteria for considering histological evidence of malignant change to be present in a pigmented lesion have been widely discussed. In this series the criteria for malignant change cited by Lever will be used; he considers that an essential feature of a primary malignant melanoma is the presence at the dermoepidermal junction of areas of junctional activity, the melanocytes comprising these areas being larger than the surrounding basal cells. The nuclei of these melanocytes are generally larger and more darkly stained than normal, and occasionally aberrant mitotic figures may be observed. In the early stages of transition from a benign to malignant pigmented lesion an infiltrate may be observed high in the dermis composed chiefly of lymphocytes, with some histiocytes, plasma cells and eosinophils also present. This infiltrate is a transitory phenomenon and is destroyed as downward invasion of the malignant cells proceeds. More advanced stages of melanomata will show a streaming downward of malignant cells into the dermis and the likelihood of metastases is considered much higher once malignant cells are found at the depth of the sweat glands. In addition to this downward invasion of neoplastic cells, there is concomitant upward movement of identical cells through the layers of the epidermis, a feature which is commonly regarded as

indicating that the lesion is extremely active. The quantity of melanin present in a malignant melanoma is extremely variable and is no guide to the activity of the tumour.

There are lesions in which the differentiation between an active junctional naevus and an early malignant melanoma can be extremely difficult. Features in such lesions which suggest neoplasia include the size of the melanocytes relative to the surrounding Malphigian cells, and also the presence of mitotic figures, normal or abnormal within the lesion; it is not common for mitoses to be observed within melanocytes and if present suggests an abnormal degree of cellular activity. Where such changes are observed it is important to examine thoroughly the entire specimen received as in two cases received in this department in the last year the phenomenon has been observed of widespread areas of epidermis showing large active melanocytes with only one small focus of malignant change in each, found after serially sectioning the specimens.

Features indicating the rare occurrence of malignant change in a blue naevus are pleomorphic nuclei with many mitotic figures in the naevus cells, deep invasion of the naevus cells, and also necrotic foci within the lesion. The absence of junctional change in the epidermis overlying these lesions will distinguish them from a primary malignant melanoma (Lever 1967).

The Problem

All the pigmented lesions defined in table I may at various stages of their development may resemble each other clinically to such an extent that accurate diagnosis by naked-eye examination of the surface of the lesion is not possible. In addition to this there are several skin tumours whose primary anomaly is not related to the melanocyte system which may clinically resemble those lesions listed in table I and therefore further confuse the differential diagnosis; such lesions include cavernous angiomata, sclerosing angiomata, pigmented rodent ulcers, and pigmented foreign bodies. A common method of dealing with this dilemma is to advise removal of all pigmented lesions about which patients are sufficiently concerned to seek medical advice, and defer a definite diagnosis until the histology of the lesion is available. The obvious drawback to such an approach is that a lesion which is undergoing malignant change will obviously require much more radical surgery than one which is being removed because of inconvenience or for cosmetic reasons.

A second problem when confronted clinically with a pigmented lesion is not whether the lesion is frankly malignant, but whether or not the lesion has the capacity for malignant change. In adults these lesions are those which when examined histologically show junctional change in the epidermis, namely the junctional and compound naevi. As these lesions do have the potential for malignant

change their removal is commonly advised on prophylactic grounds. At present, however, there is no satisfactory method of determining whether or not a lesion does exhibit junctional activity before removal, and histological examination, and current practice is to remove pigmented lesions on the palms, soles and genitalia, and also on areas of friction such as the waistline as it is considered by some authorities that trauma is important in the initiation of malignant change. In children the problem is somewhat different in that pigmented naevi before puberty are commonly junctional in type, and therefore removal is generally not considered necessary. The exception to this pattern is the giant hairy pigmented naevi occasionally seen in children as these have recently been shown to have a high incidence of neoplastic change (Greeley et al. 1965).

Because of the low incidence of malignant change in the blue naevi of both adults and children prophylactic removal of these lesions is not considered necessary but because there is as yet no clinical method of satisfactorily distinguishing these lesions from other pigmented tumours, a common reason for removal is for diagnostic purposes.

The difficulties of accurate diagnosis of pigmented lesions of the skin are well demonstrated by the reports in the literature in which preoperative diagnosis is assessed in the light of subsequent histology. Sverdlow, reporting on 551 lesions in which the clinical diagnosis was pigmented naevus states that 338 cases

(61%) were accurately assessed. Of the 57 lesions in his series considered on clinical grounds to be melanomata only 16 (28%) were confirmed by histology. Conversely, of the 27 histologically proven melanomata only 16 (57%) had been accurately diagnosed on clinical grounds and received adequate initial treatment (Sverdlow 1952).

In another series of this type, Becker reporting on 169 specimens received at the University of Chicago dermatological laboratories with the preoperative diagnosis of malignant melanoma states that this diagnosis was histologically proven in 72 cases (43%). Of the 151 histologically proven malignant melanomata which he discusses in this series, only 72 (48%) had been diagnosed as such before removal (Becker 1954).

It can be seen from these figures that the record of accurate preoperative assessment of malignant melanomata is poor. The value of preoperative diagnosis cannot be overstressed as the patient's ultimate fate is considered by many to depend on prompt and adequate surgery initially (Royster et al. 1957). Block also considers the primary treatment to be the most important factor in arresting spread of the disease, and shows that a delay of one month significantly reduces a patient's chances of long-term survival (Block 1961). As adequate removal of a malignant melanoma of necessity demands removal of a minimum of 5 cm. of apparently normal skin around the lesion and repair of the resulting deficit by a skin graft, the risk exists on the one hand of inadequate primary treat-

ment of a malignant lesion and on the other of unnecessary mutilation in removal of a benign lesion.

Any method of improving the accuracy of preoperative diagnosis of pigmented skin lesions is therefore a welcome advance provided that it does not further accelerate what may already be activity of neoplastic cells. In the past the techniques of radioactive phosphorus counts, thermodifferentiation and biopsy have been advocated as preoperative guides, but all have definite disadvantages.

An early suggestion of such a test was made in 1955 when Bauer and Steffen advocated the use of the radioactive isotope P_{32}. They claimed that when this was administered intravenously as phosphate the radioactivity over the surface of a malignant melanoma was 2.5-3.85 times greater than over the contralateral normal skin (Bauer and Steffen 1955). Brauer repeated this study on 49 patients, studying 145 lesions in all. They found with this technique 20% false positive and 37% false negative readings (Brauer et al. 1960). This method has not been commonly used, possibly because of these reasons and possibly because of potential hazards in the administration of the isotope.

In 1962 Venkei and Bakos published evidence of the value of thermodifferentiation in the preoperative diagnosis of melanomata. This test is based on their finding that the skin temperature over a primary malignant melanoma is $1^{o}C$ or more higher than over the contralateral normal skin. In 80 cases of histologically proven

melanomata 61 or 76% gave positive results. Unfortunately they do not include in their cases other skin tumours which might be mistaken for melanomata or benign pigmented lesions which exhibit junctional activity. A disadvantage in the use of such a method is the fact that accurate skin temperatures are notoriously difficult to obtain, usually requiring a thermostatically controlled room and several hours acclimatisation beforehand.

Biopsy of a pigmented lesion before definitive surgical treatment is in general considered to be unwise because of the extreme friability of neoplastic melanocytes and the consequent risk of dissemination of tumour cells if the lesion in question is a melanoma. Andreev has advocated diagnostic biopsy of pigmented lesions preceded by radiotherapy to the lesion to lessen the risk of dissemination of malignant cells (Andreev 1968). To achieve this he suggests a dose of 4,000 to 5,000 rads. In this country the use of radiotherapy in the early treatment of melanomata has never been popular, because of the relatively high incidence of melanomata after x-irradiation for other dermatological conditions. Moir suggests that the place of radiotherapy in the treatment of a malignant melanoma is purely palliative once the disease has progressed to a stage where complete eradication of the tumour cells is not possible (Moir 1946), and Olsen, reporting from the Institute of Radiotherapy in Copenhagen has recently supported this viewpoint, showing that in melanomata subjected to irradiation the primary lesion may show initial

regression, but the incidence of early and widely disseminated metastases is very high indeed (Olsen 1967).

Biopsy of the pigmented lesion and immediate histological examination after frozen section, followed by definitive surgical treatment would seem to be a useful method of determining the treatment necessary for such a lesion. Unfortunately the friability of melanocytes is such that the differentiation between active junctional change and early malignant growth is often not possible by this technique; the melanocytes are often distorted or damaged and the histological appearance may be strikingly different from a paraffin section obtained from the same lesion. An additional risk in this method is also the possibility of dislodgment of tumour cells from the malignant lesion into the local lymphatic vessels.

From the foregoing it can be seen that there is a great need at present for a safe and reliable aid to preoperative assessment of pigmented lesions. The aim of this study is to decide whether or not the examination of the surface of these pigmented lesions at moderate magnifications will provide a consistent picture characteristic of a histological group. The obvious advantage of such a method is that it is harmless for the patient, that it can be quickly and easily carried out with no delay in obtaining results, and that the equipment used is portable and comparatively inexpensive.

Figure 2

The Zeiss Operation Microscope with Camera Attachment.



The Method

For this study the Zeiss operation microscope shown in figure 2 (opposite) was used. This is a binocular microscope with prismatic beam splitters adjusted to supply equal amounts of light to the eyepieces and to the camera body which is mounted on a side arm as shown. This arrangement enables material to be recorded while it is visualised and has none of the delay or risk of movement associated with systems where after focussing the material to be recorded, a camera is attached to an eyepiece.

The skin surface is covered with olive oil and examined at magnifications of 6, 10, 16, 25 and 40. The camera used for photographic recording is a Zeiss Robot which was found to be satisfactory, after initial trials with a House-Urban modification of this microscope had been unsuccessful. Photographs are taken, using Kodachrome II colour film, at magnifications of 6, 10, 16 and 25. After surgical removal of the lesions examined the histological appearances were studied and recorded using panatomic x film with a Zeiss photomicroscope.

Table 2

The Lesions Studied

Junctional Naevi	18
Compound Naevi	63
Malignant melanomata	38
Blue Naevi	5
Intradermal Naevi	12
Cavernous Angiomata	8
Sclerosing Angiomata	6
Basal Cell Papillomata	11
Basal Cell Carcinomata	7
	168

The Lesions Studied

The material used in this study was gathered from 1966-68 from hospitals in the West of Scotland. The majority of cases examined were seen in the dermatological department of the Western Infirmary Glasgow, or referred from the West of Scotland Regional Plastic Surgery Unit at Canniesburn after its opening in 1968. Cases have also been examined at the Royal Infirmary, Victoria Infirmary, Southern General Hospital, Philipshill Hospital and the Beatson Memorial Hospital. The machine, although heavy, is portable and therefore can be taken to the bedside of a patient who is elderly or seriously ill. As it requires only a normal domestic power supply, it is also suitable for domiciliary use. Initially the material consisted mainly of pigmented lesions referred to the dermatological outpatient department of the Western Infirmary and as clinicians became aware of the project and the possible benefits of this technique, the number of patients referred increased steadily. Included in this study are cases, and their histological nature is shown in Table 2.

The detailed results of this method now follow, showing in each case firstly the appearance of the pigmented lesion *in vivo* as seen with the operation microscope and secondly the histology of the same lesion. The cases are grouped histologically.

The Junctional Naevi

Case 1. Male aged 17 years.

Mole on instep present since birth.

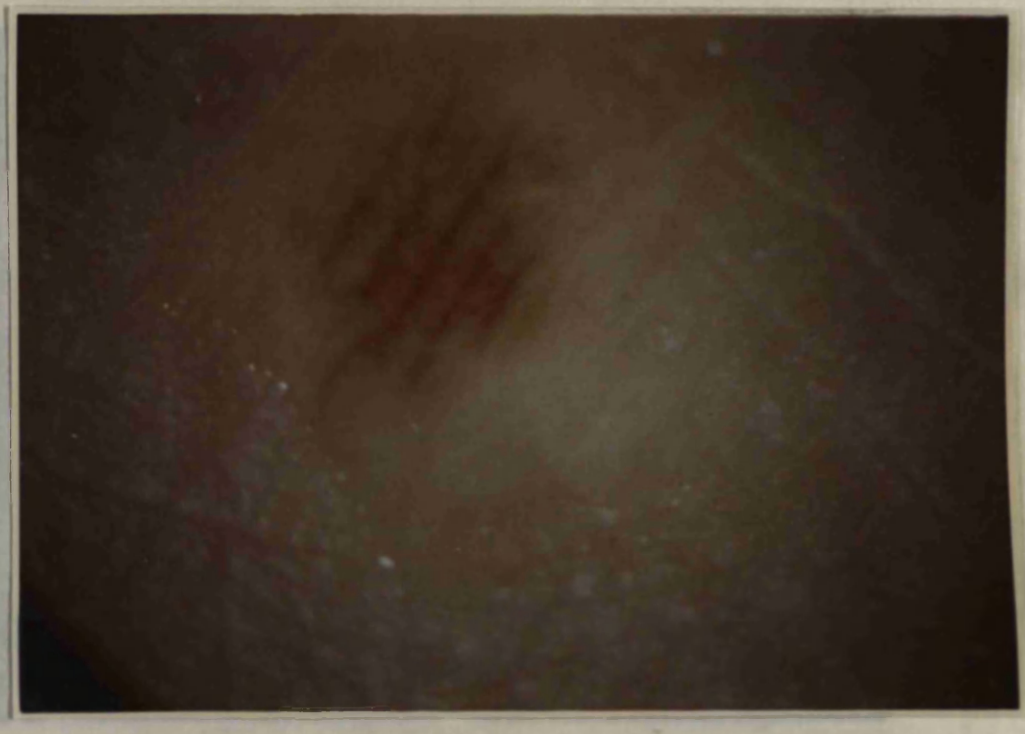

Histology: Junctional activity present in basal layer of epidermis.

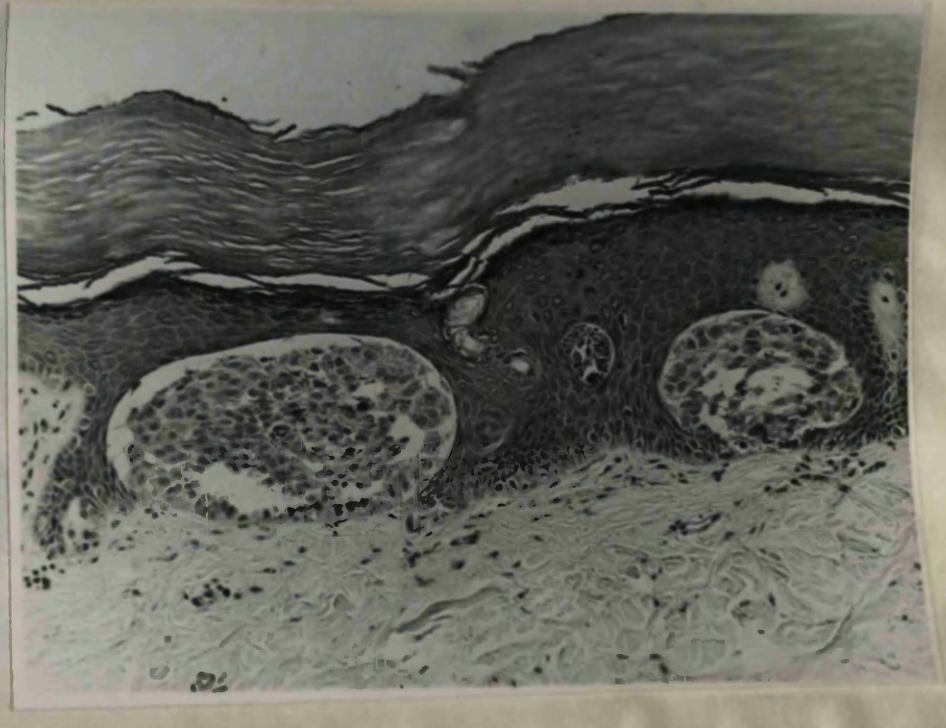

Case 2. Male aged 14 years.

Lesion on sole of foot present since birth.

No recent growth or colour change.



Histology: Area of junctional activity in basal layer of epidermis.

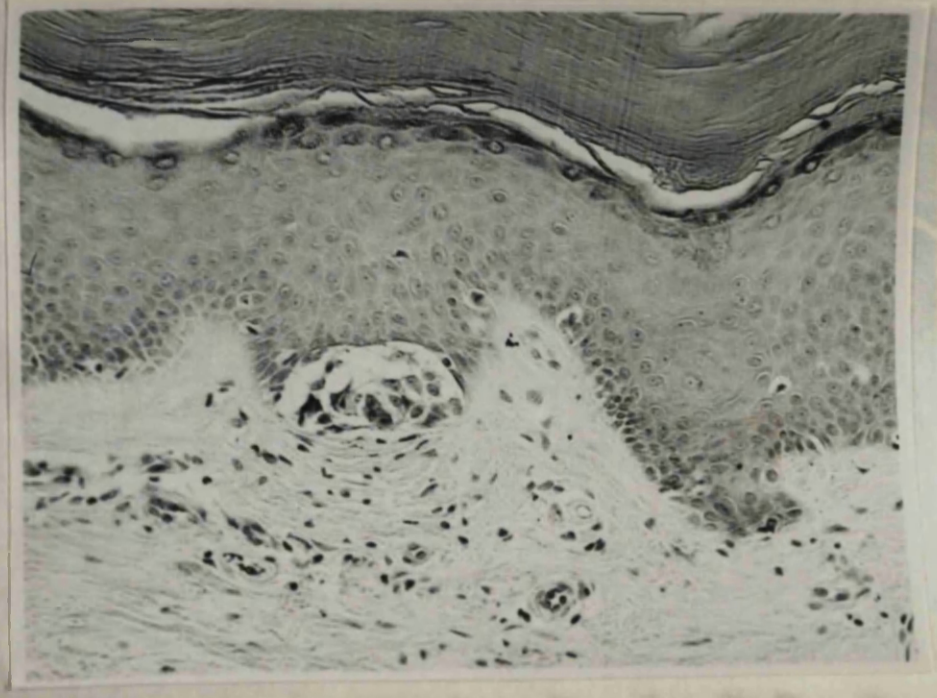

Case 3. Male aged 48 years.

Lesion on sole of foot, first noticed one year previously.

Enlargement and colour change since then.



Histology: Active junctional change present.

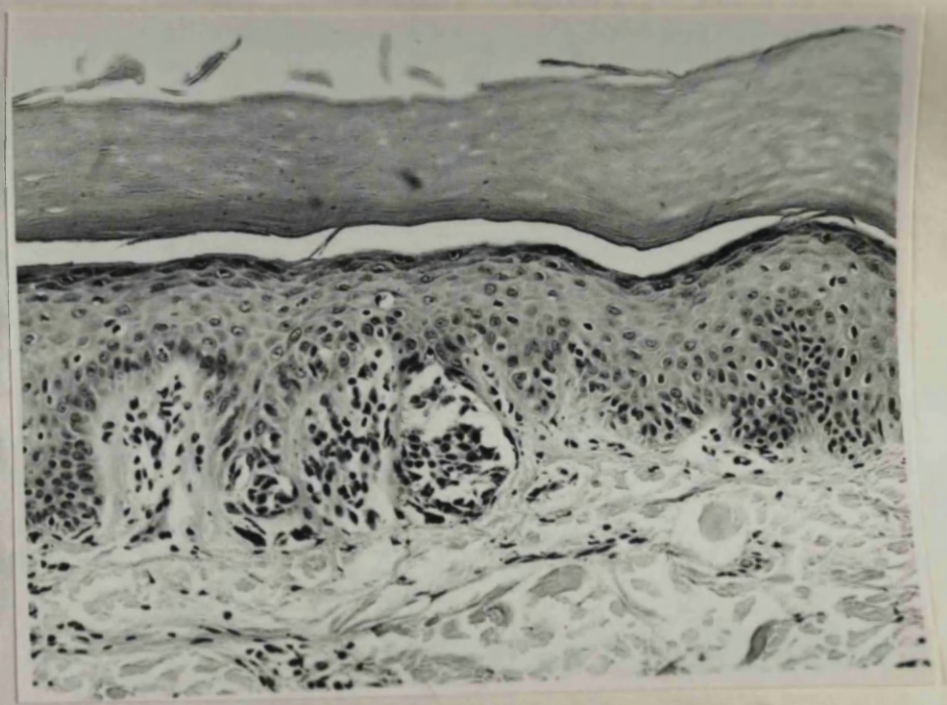

Case 4. Male aged 22 years (coloured).

Lesion on sole of foot, first noticed 3 weeks before photography.

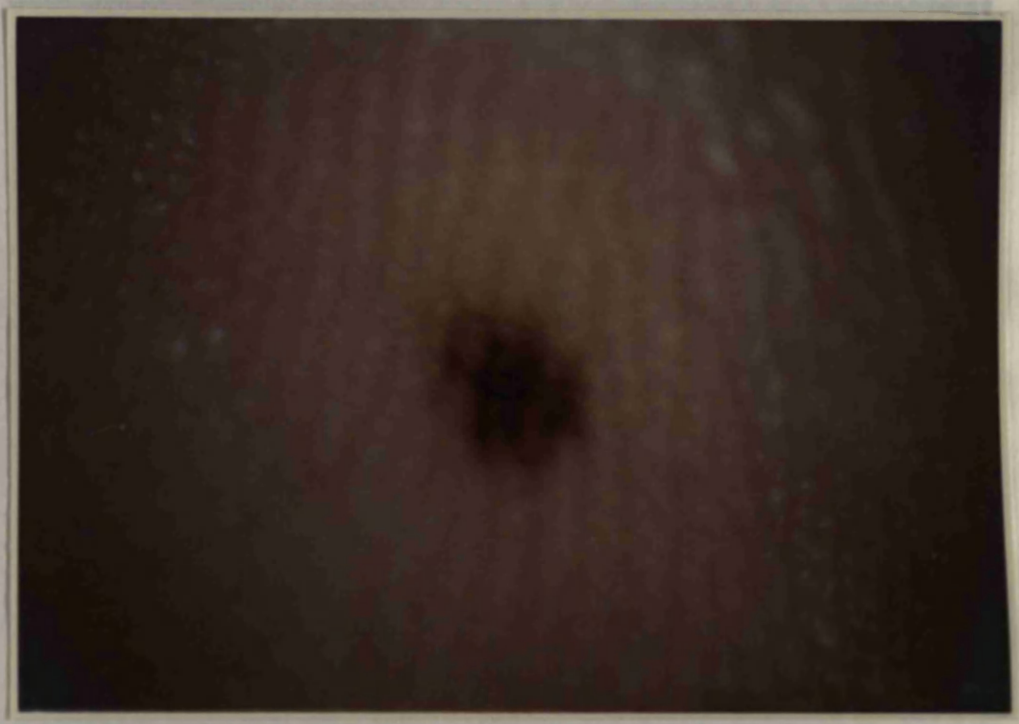

Histology: Junctional activity present in basal layer of epidermis.

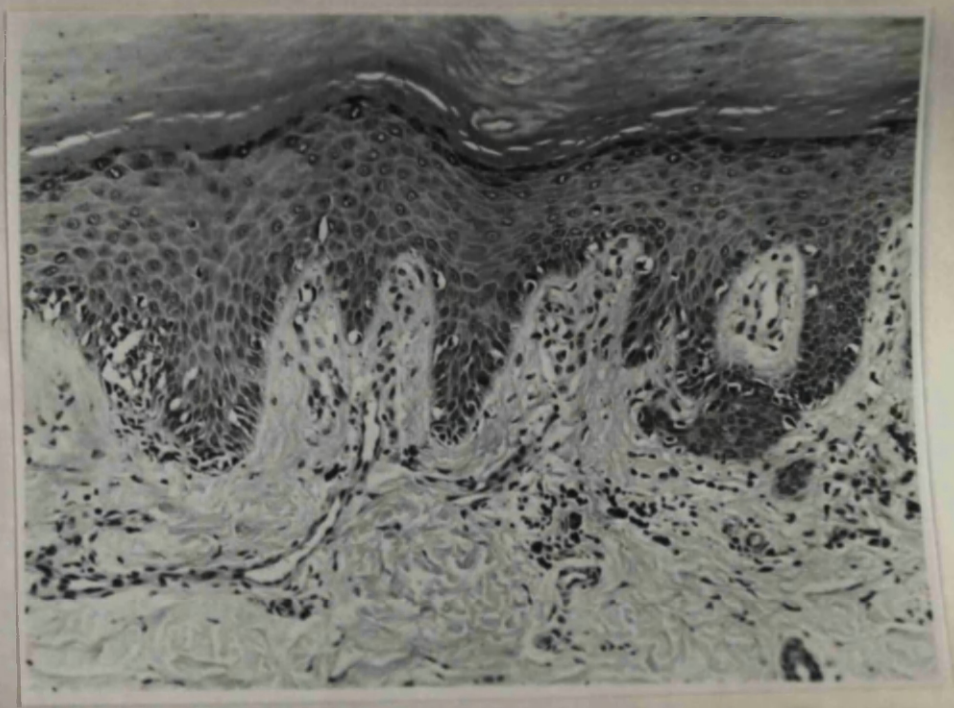

Case 5. Male aged 24 years (coloured).

Lesion on sole of foot, first noticed 18 months previously.



Histology: Large areas of very active junctional change present in basal layer of epidermis.

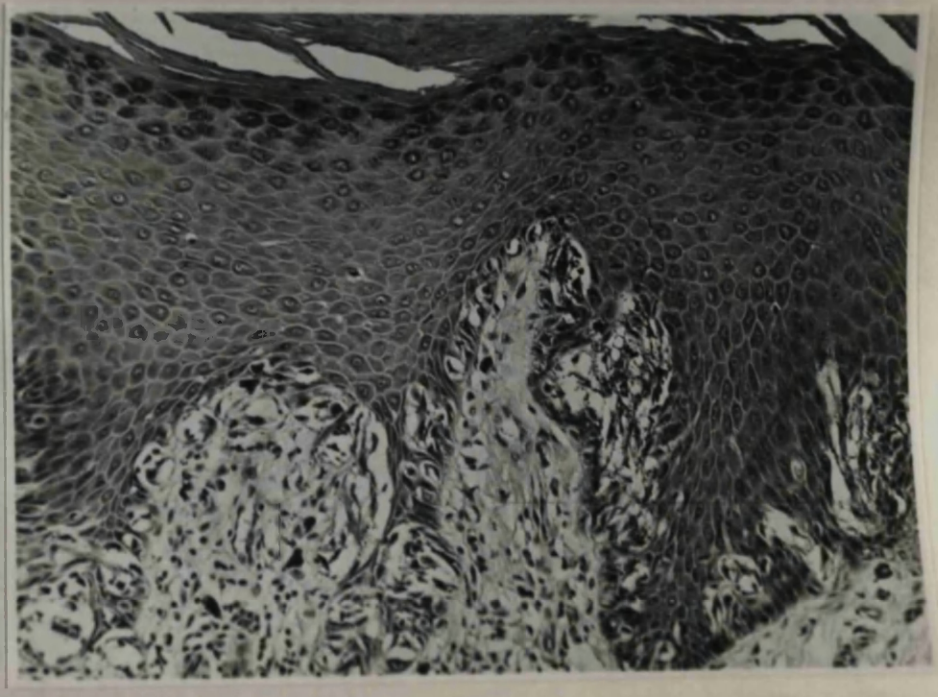

Case 6. Female aged 25 years (coloured).

3 weeks post-partum.

Lesion on sole of foot, first noticed 5 weeks before photography.



Histology: Active junctional change present in basal layer of epidermis.



Case 7. Male aged 16 years.

Lesion on palm of hand present since birth.

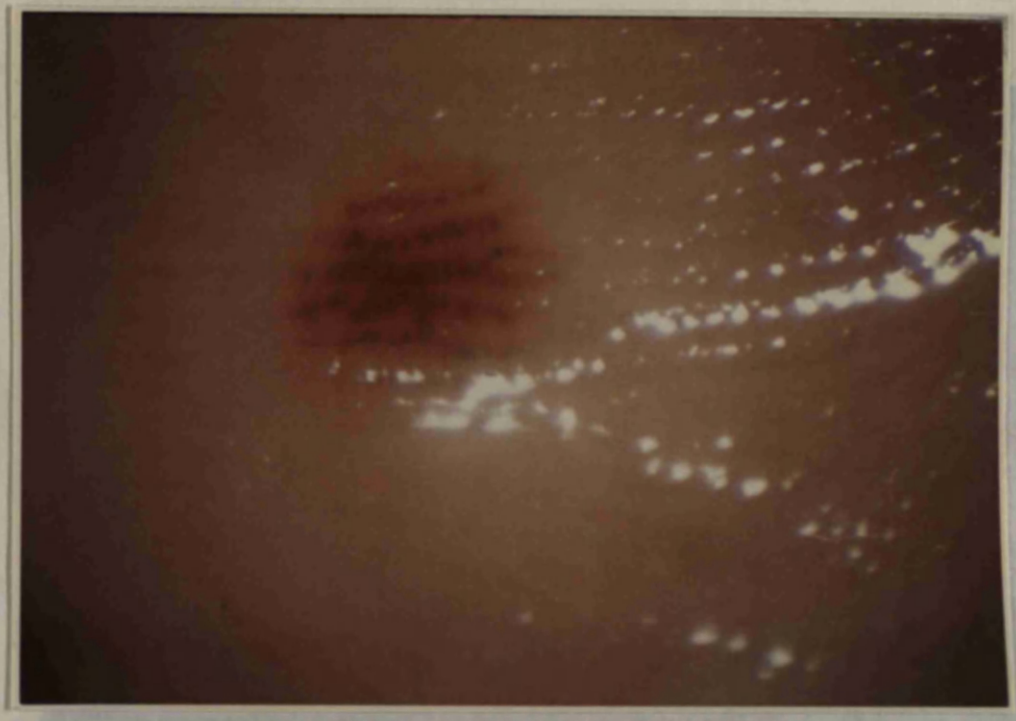

Histology: Two areas of junctional activity visible in basal layer of epidermis.

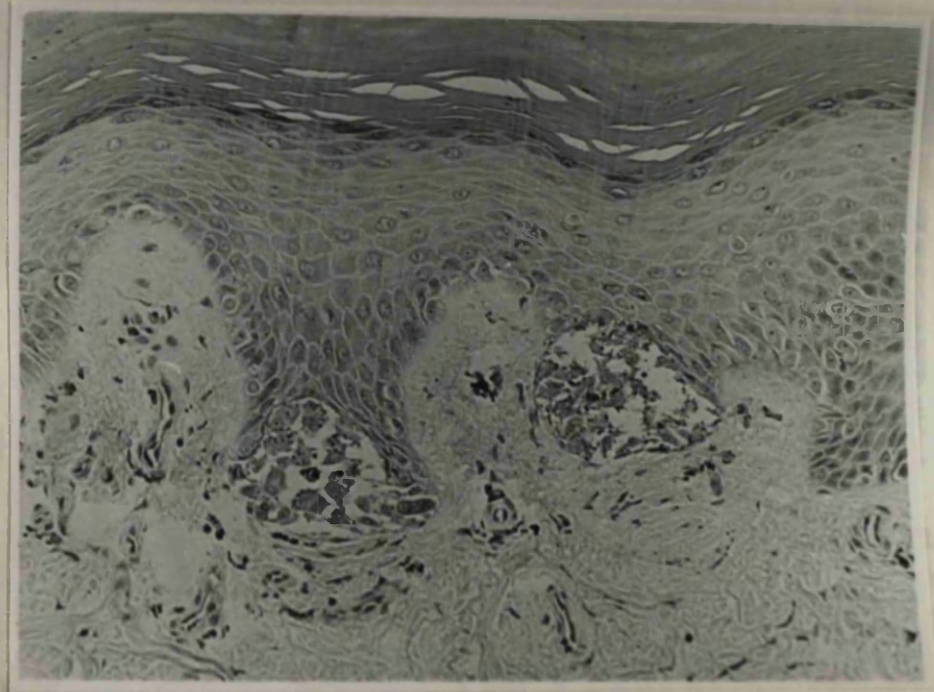

Case 8. Male aged 30 years.

Lesion anterior aspect right wrist present for at least five months.



Histology: Junctional activity present in basal layer of epidermis.

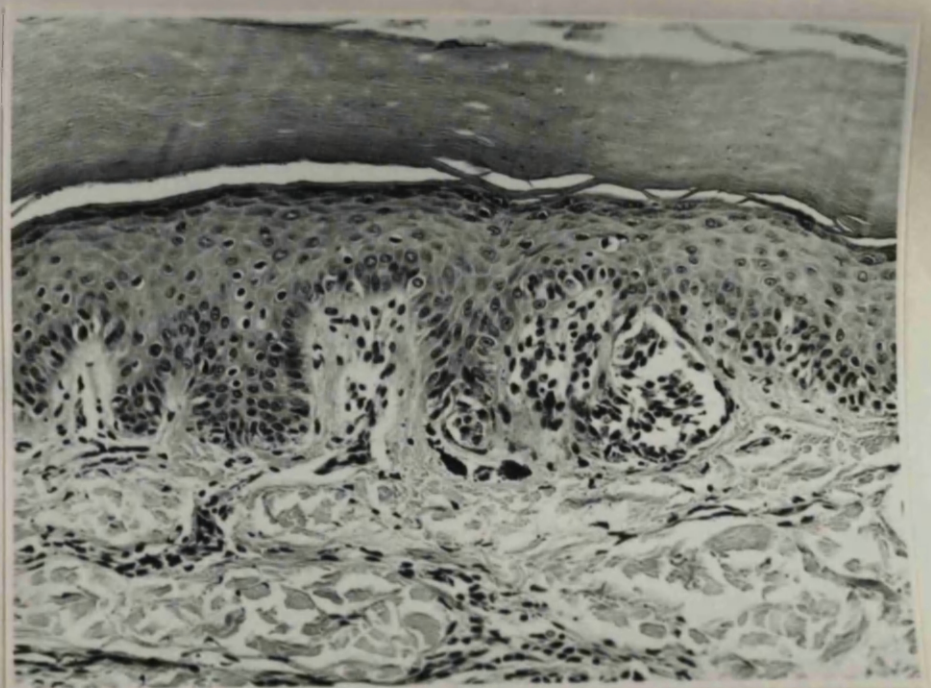

Case 9. Male aged 14 years.

Lesion on palm of hand present since birth.



Histology: Small areas of junctional activity present in basal layer of epidermis.

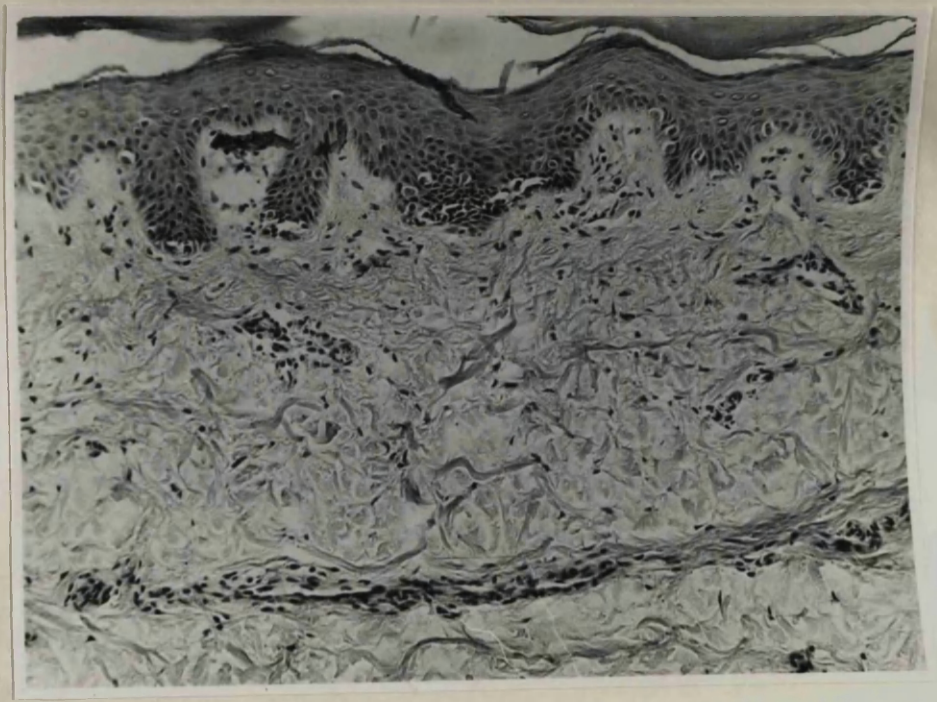

Case 10. Female aged 24 years.

Lesion on palm of hand present for two months.

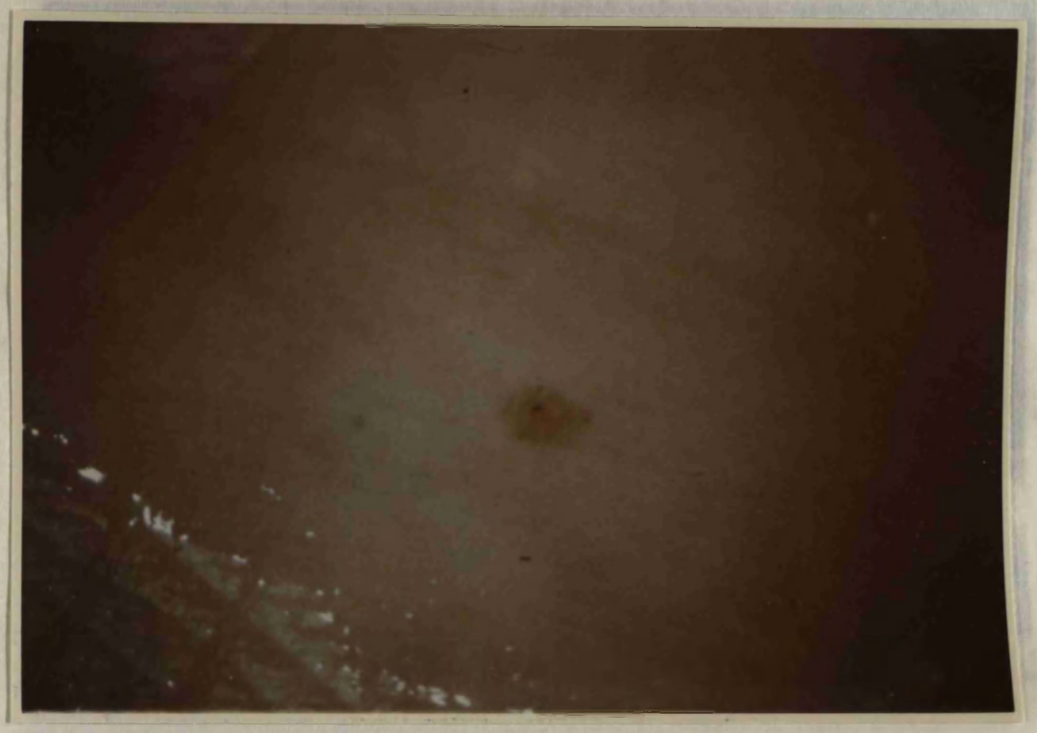

Histology: Areas of active junctional change present in basal layer of epidermis.

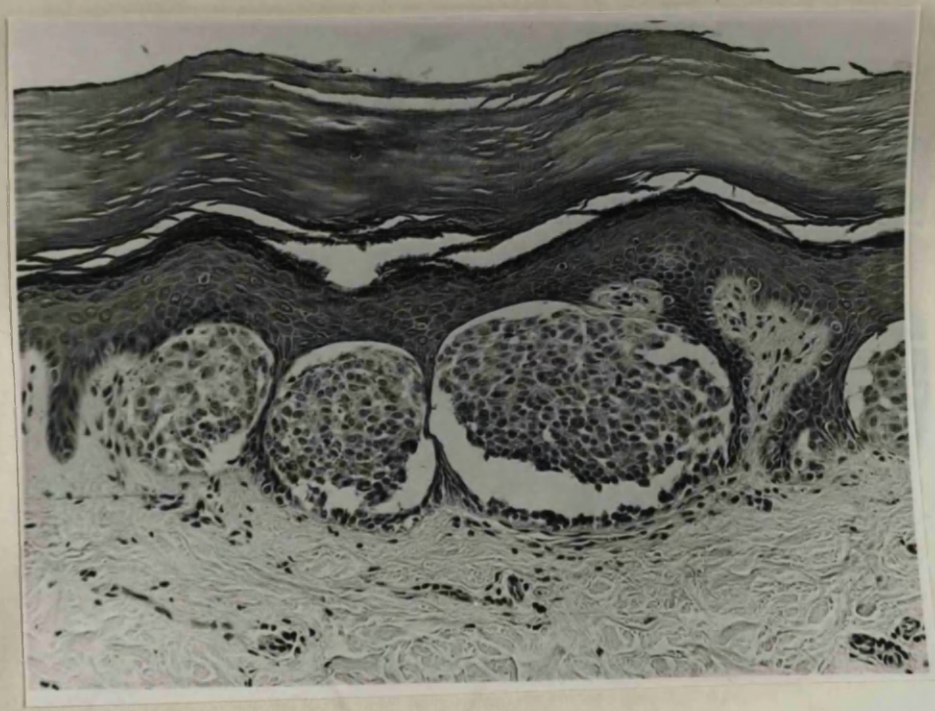

Case 11. Male aged 24 years.

Lesion on palm of hand present for three weeks.



Histology: One area of junctional activity present in basal layer of epidermis.

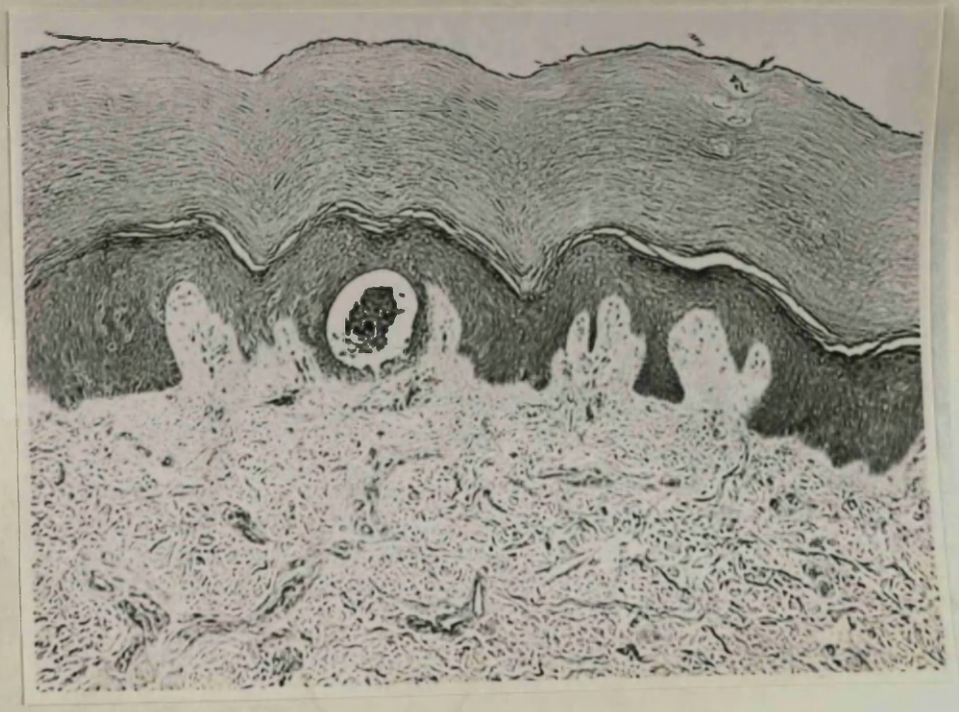

Case 12. Male aged 51 years.

Lesion inner aspect 4th finger noticed 9 months previously.

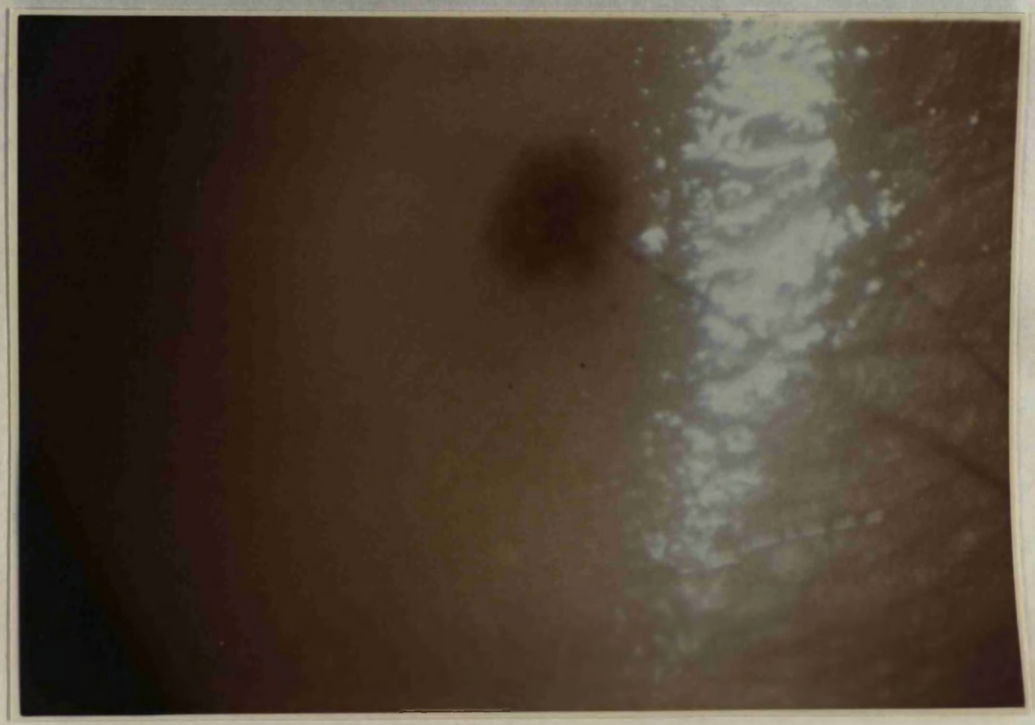

Histology: Junctional activity present in basal layer of epidermis.

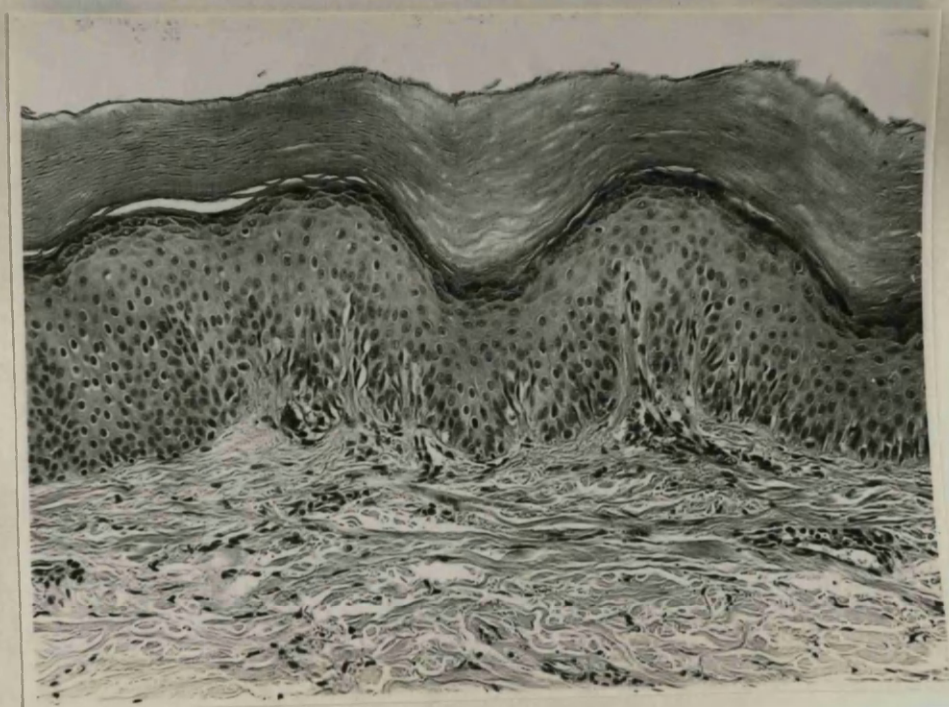

Case 13. Female aged 30 years.

Lesion on palm of hand present at least 10 years.

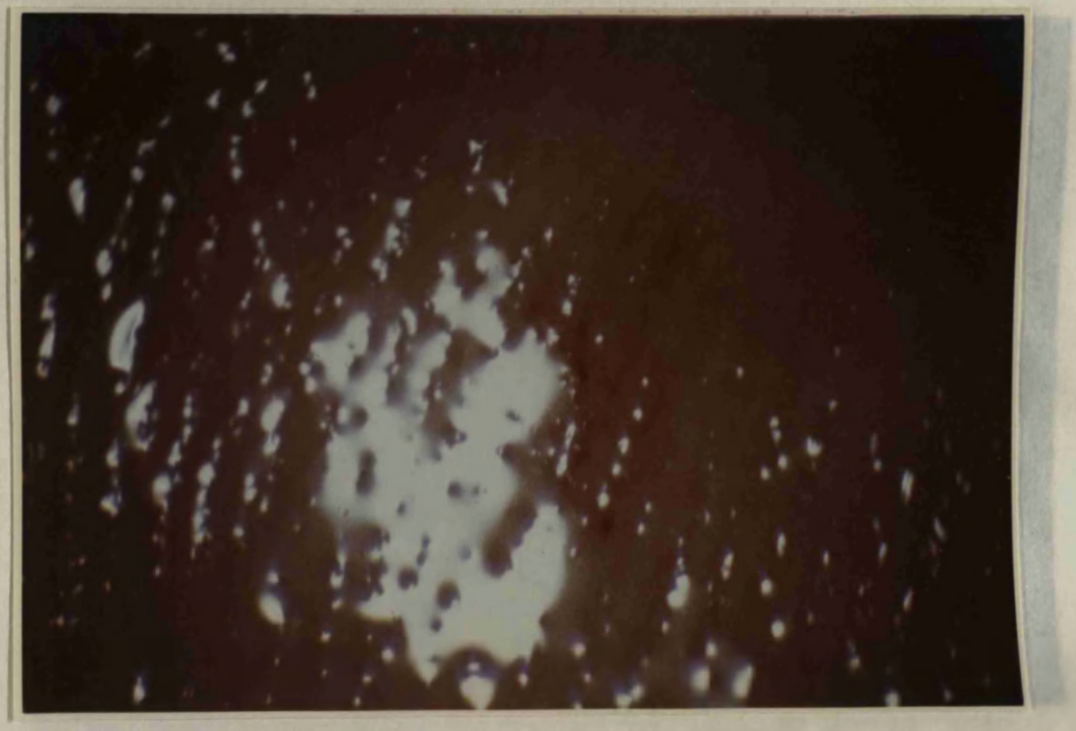

Histology: Active junctional change present in basal layer of epidermis.

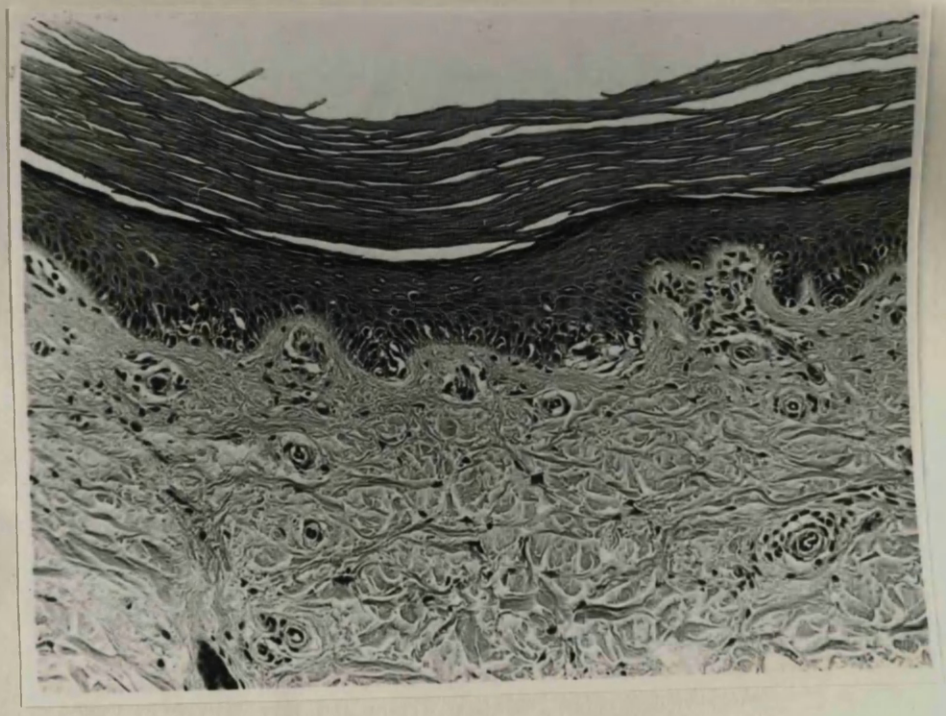

Case 14. Female aged 17 years.

Lesion on anterior forearm present since birth.

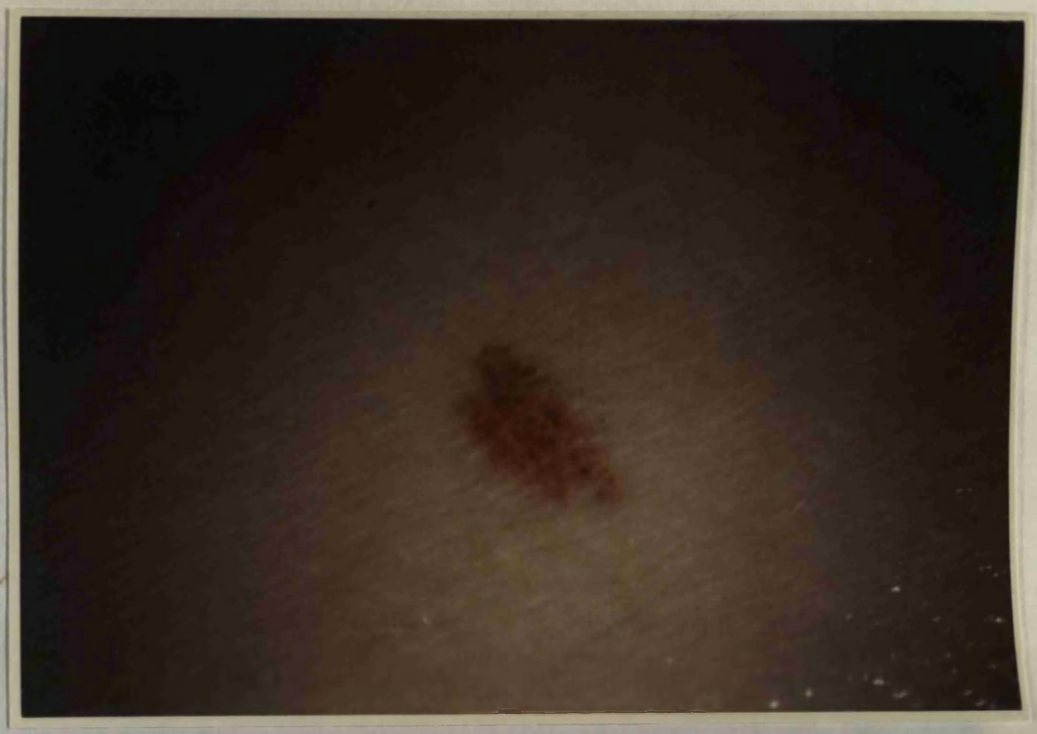

Histology: Junctional activity present in basal layer of epidermis.

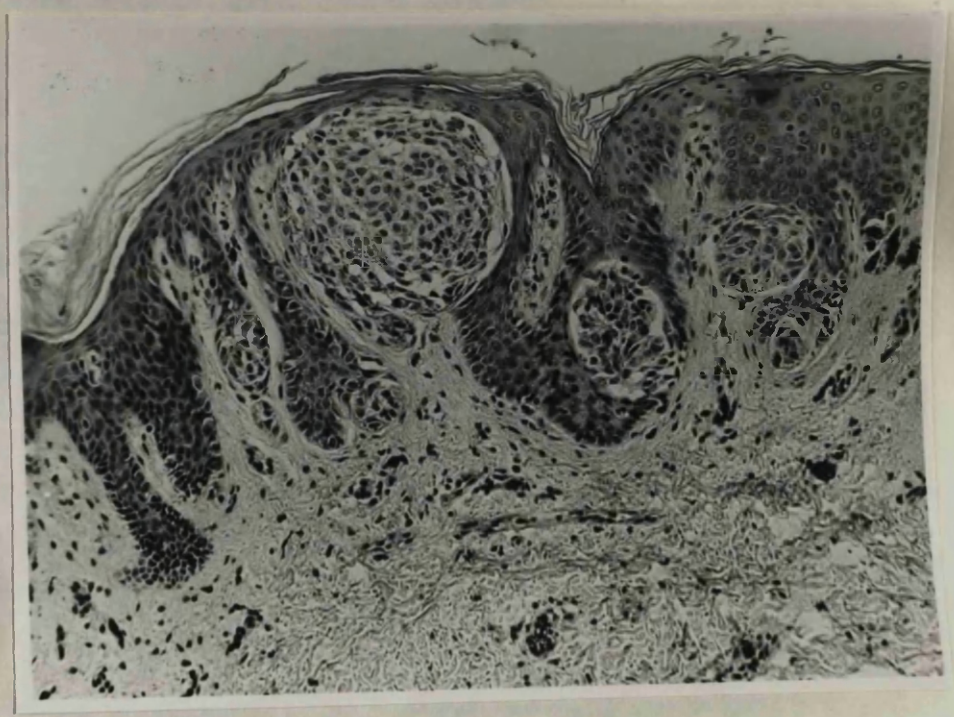

Case 15. Male aged 15 years.

Lesion on forehead at hairline, first noticed 6 months previously.



Histology: Very active junctional change.

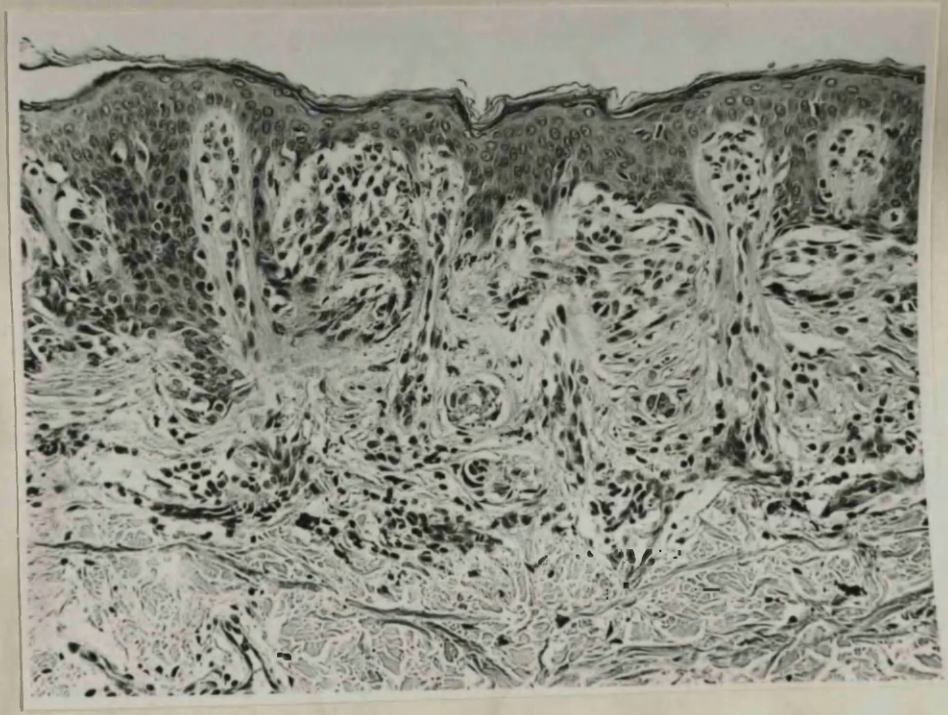

Case 16. Male aged 42 years.

Lesion on abdomen present for over 20 years.

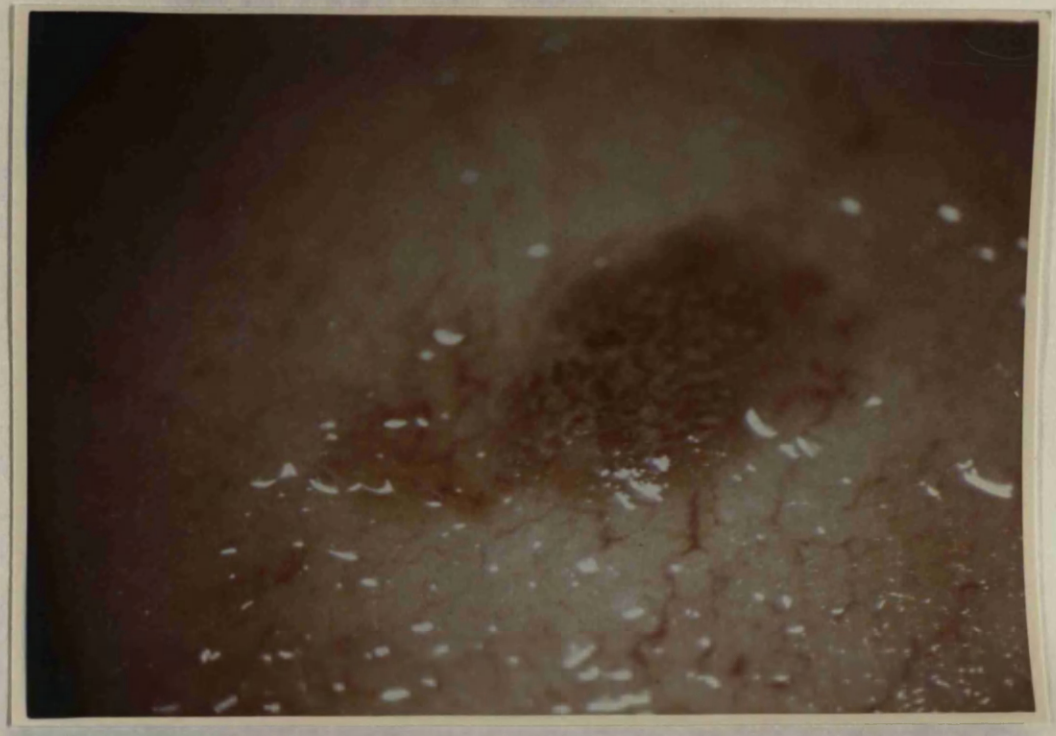

Histology: Active junctional change in basal layer.



Case 17. Female aged 28 years.

Lesion on outer aspect of lower leg present for at least five years.

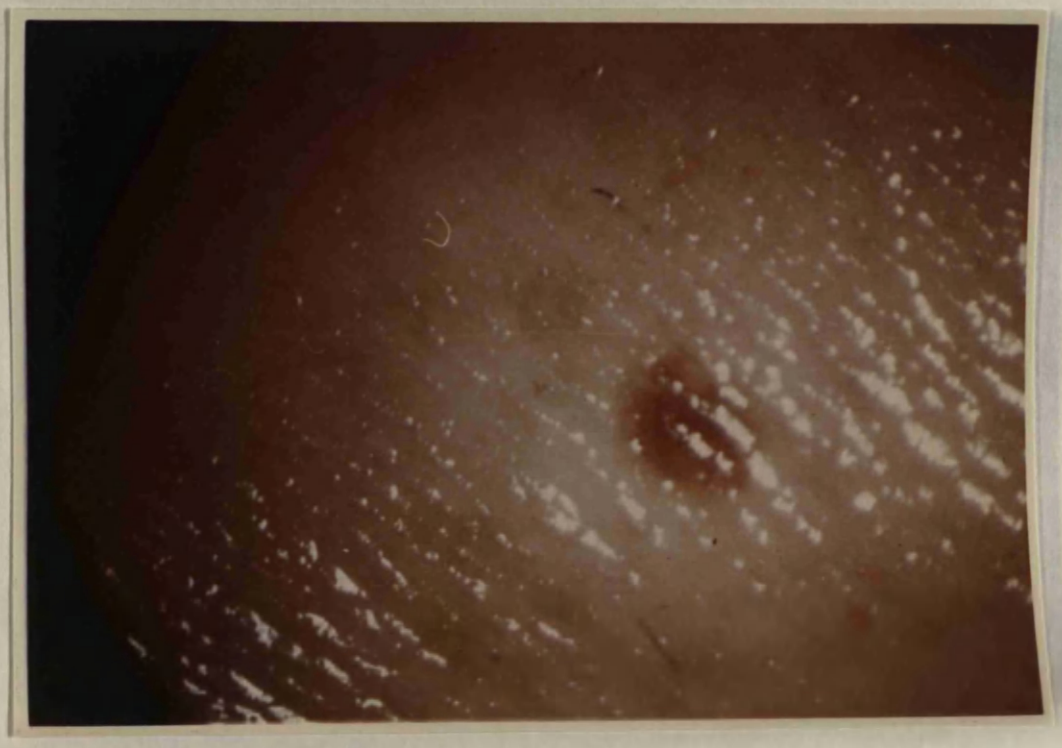

Histology: Active junctional naevus.



Case 18. Female aged 36 years.

Lesion of nail bed 3rd finger present for 2-3 months.

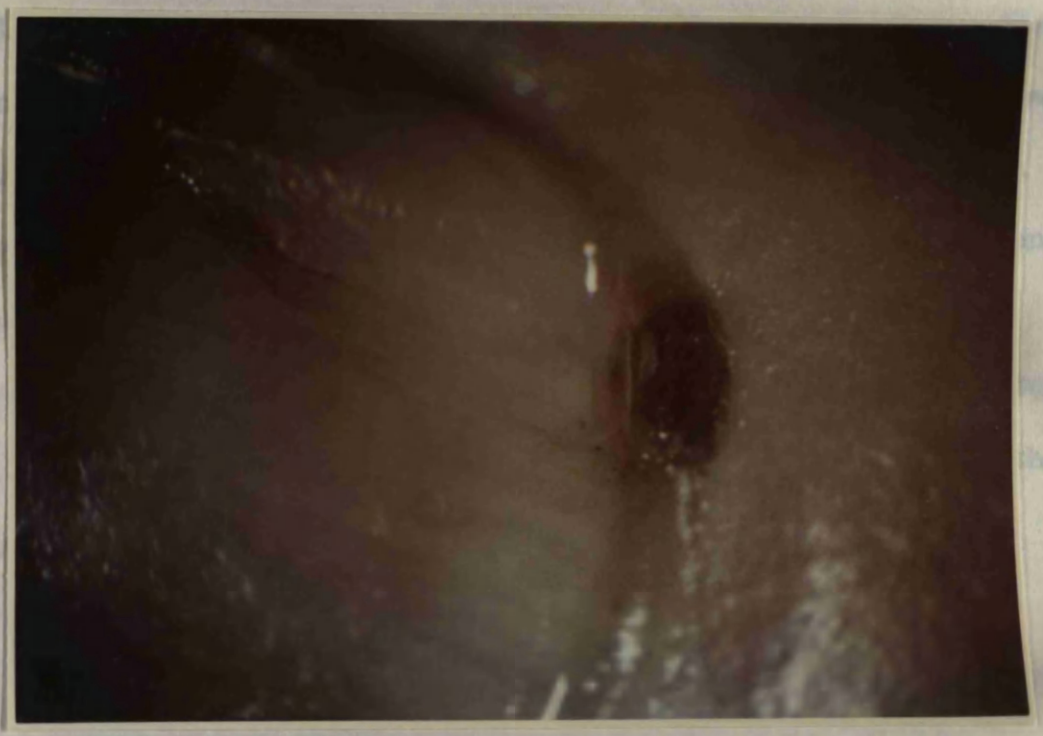

Histology: Junctional naevus of nail bed.

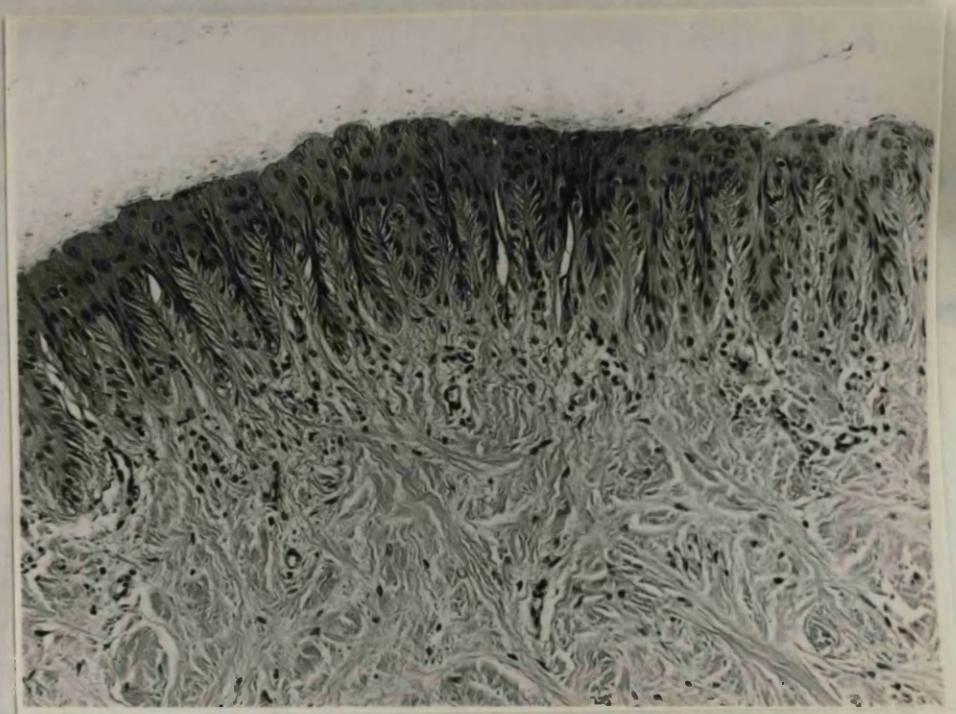

General comments on the junctional naevi group:

The colour photographs obtained by the operation microscope of the group of lesions which have been histologically proven to be junctional naevi show in general a mid-brown pigmented lesion. There are two components of this pigmentation; the first is a pale brown background pigmentation, and superimposed on this is a superficial darker highly irregular pigmentary pattern. The superficial pigmentation varies both in size of the pigment deposits and in depth of colour, and tends to form along the skin flexure lines; this feature is most clearly demonstrated in the cases where the lesion is on the heavily keratinized areas of the palms and soles. The depth of intensity of pigmentation does not correlate with the age of the lesion in question but the three cases shown of lesions on coloured skin are all more darkly pigmented.

In the case of the lesions on white skin the lateral margin of the lesion can be difficult to define as there is no clearly demarcated edge to the lesion, but it tends to fade into the surrounding normal skin.

A second pigment distribution pattern is also discernible on three of these lesions, cases 1, 5 and 7. This is a delicate regular network of mid brown pigment over a paler brown background. This is a pattern not unlike a spiders web.

The Compound Naevi

Case 19. Female aged 14 years.

Lesion of back first noticed 3 years previously.

Growing slowly.



Histology: Junctional and intradermal components of compound naevus present.

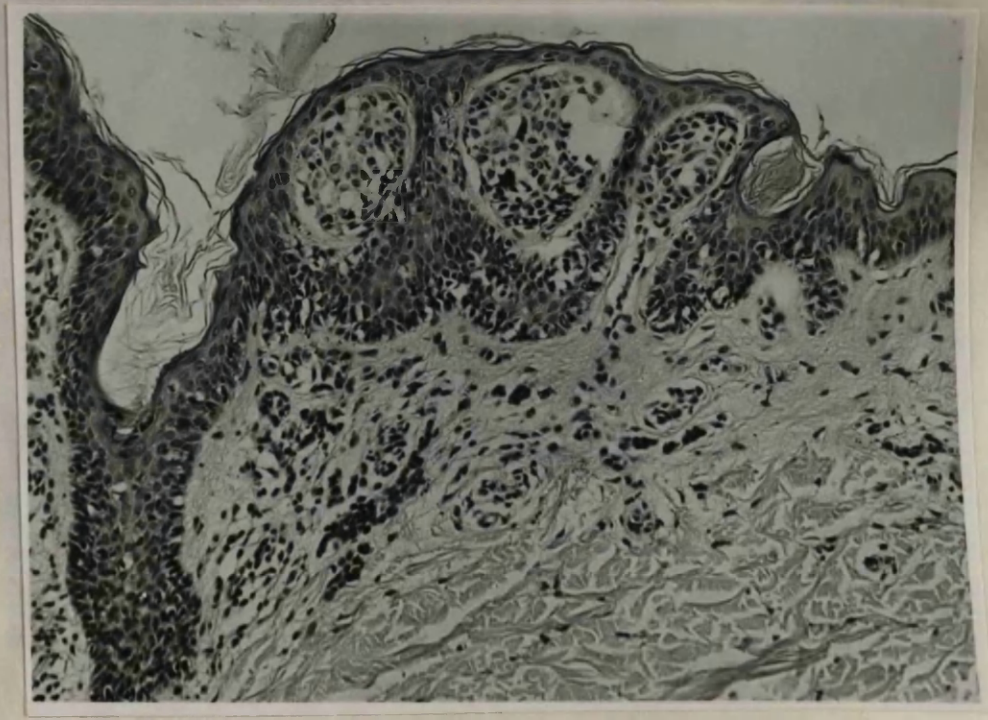

Case 20. Female aged 11 years.

Lesion on front of thigh present since birth.

Enlarging slowly.

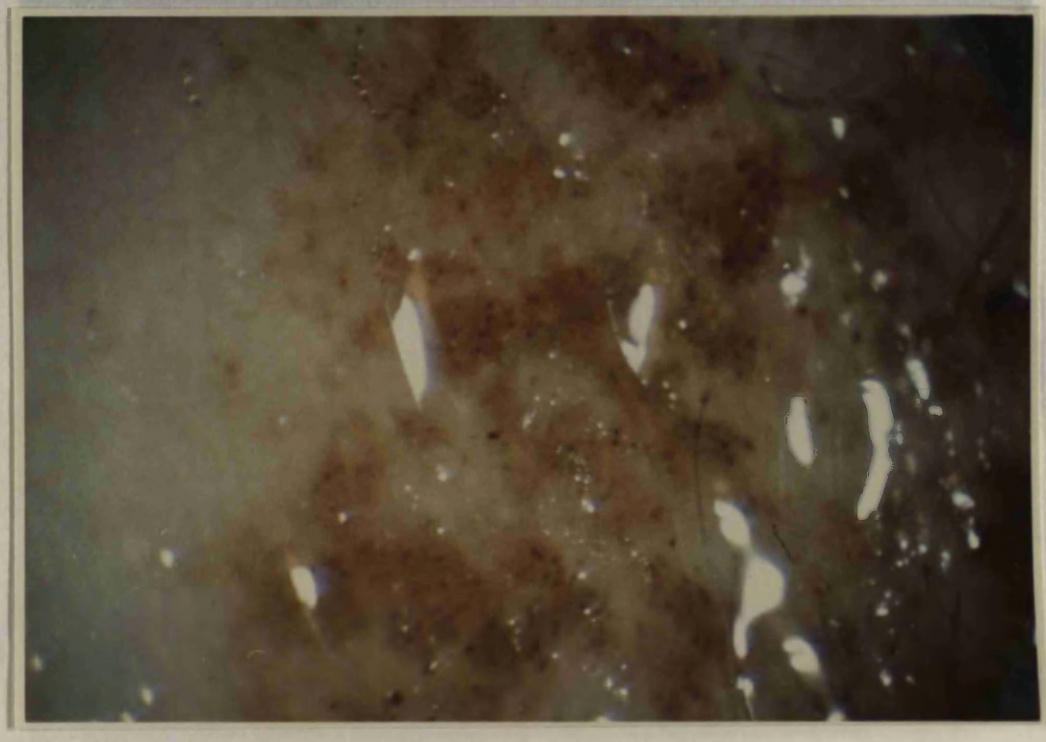

Histology: Compound naevus.

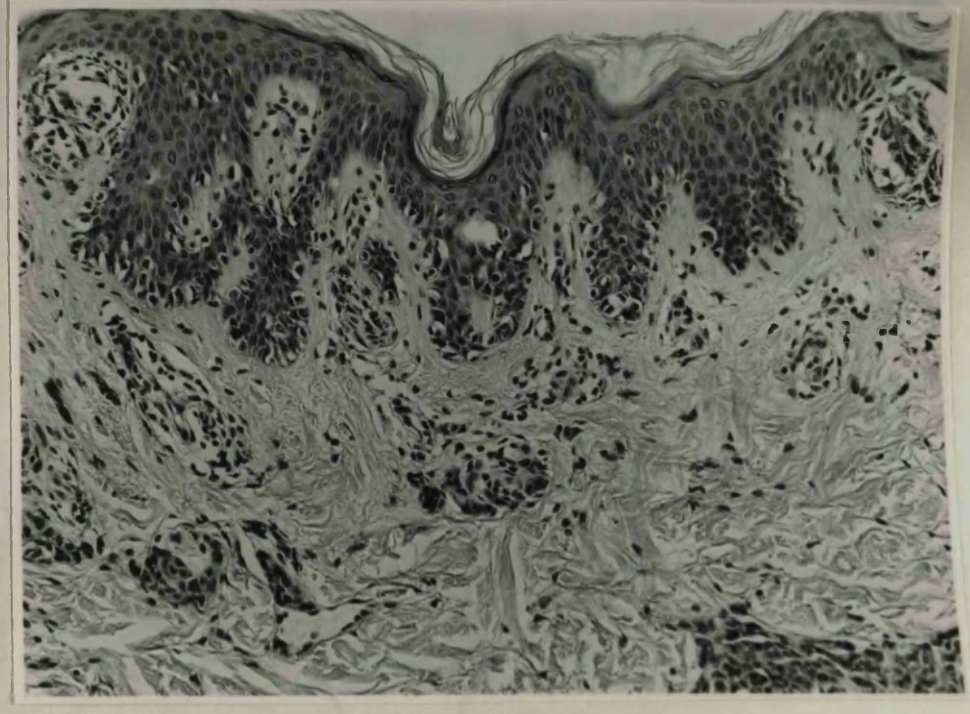

Case 21. Female aged 7 years.

Hairy pigmented lesion left forearm present since birth.

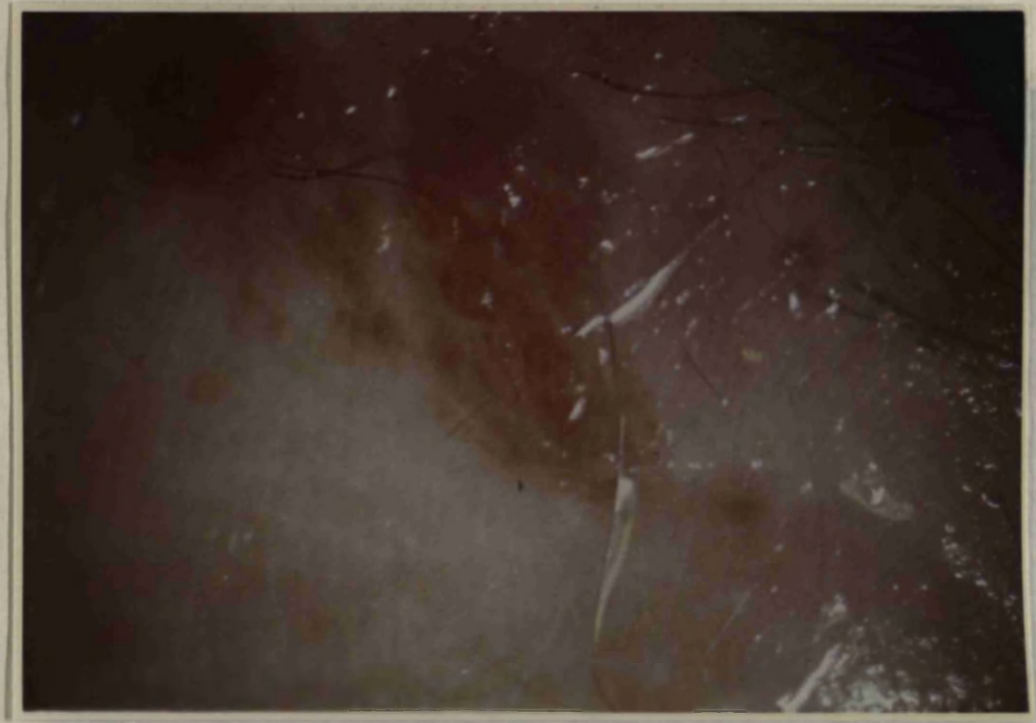

Histology: Junctional and intradermal components of a compound naevus.

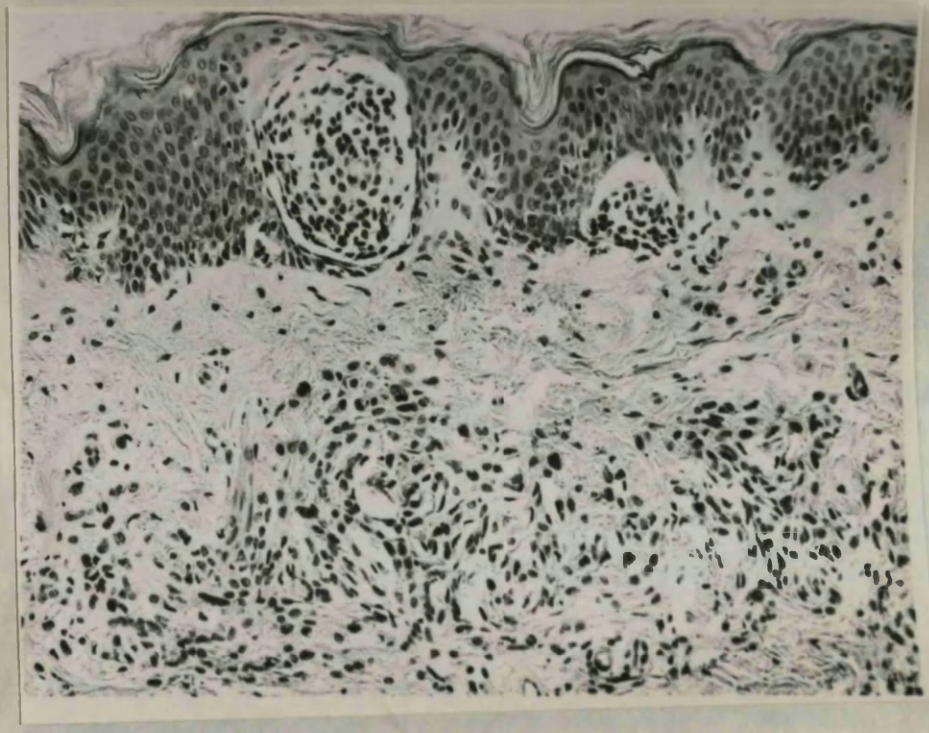

Case 22. Female aged 26 years.

Lesion on mid-back present since birth, growing slowly.

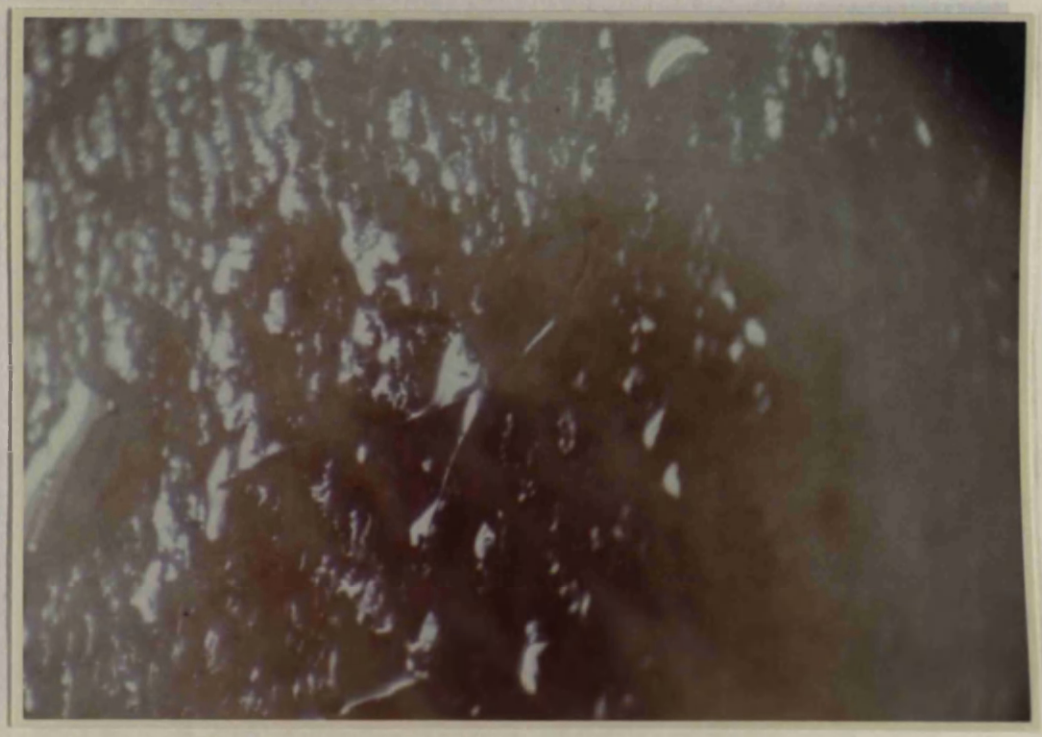

Histology: Compound naevus.



Case 23. Male aged 7 years.

Lesion of righ cheek present since birth.

Linear scab on lesion at time of examination.



Histology: Compound naevus.

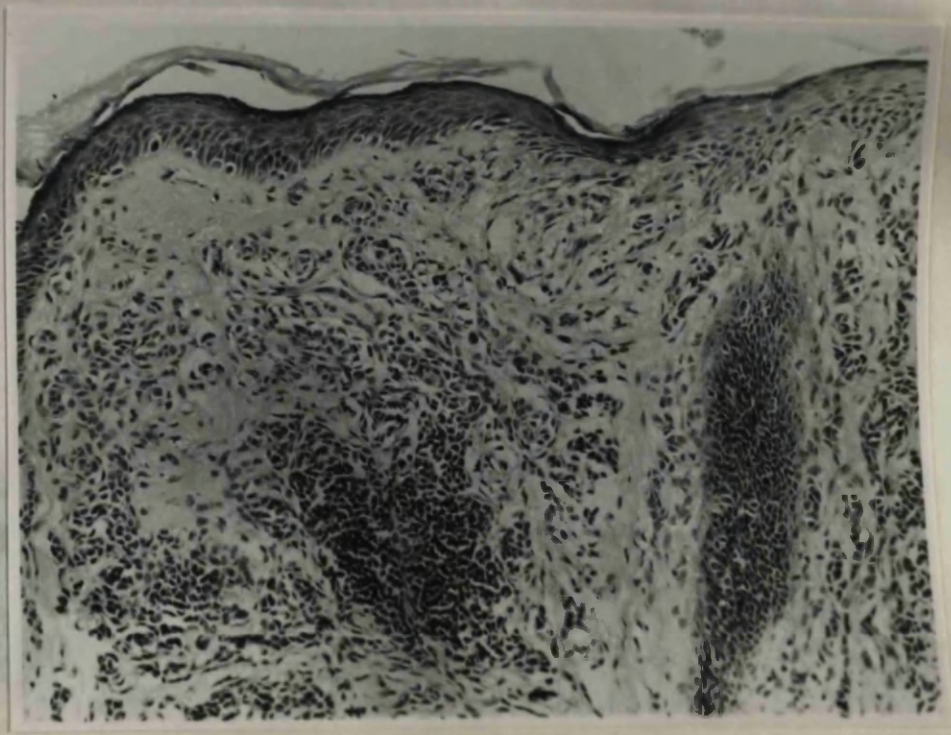

Case 24. Male aged 8 years.

Lesion on left shoulder present since birth.

Recent enlargement.

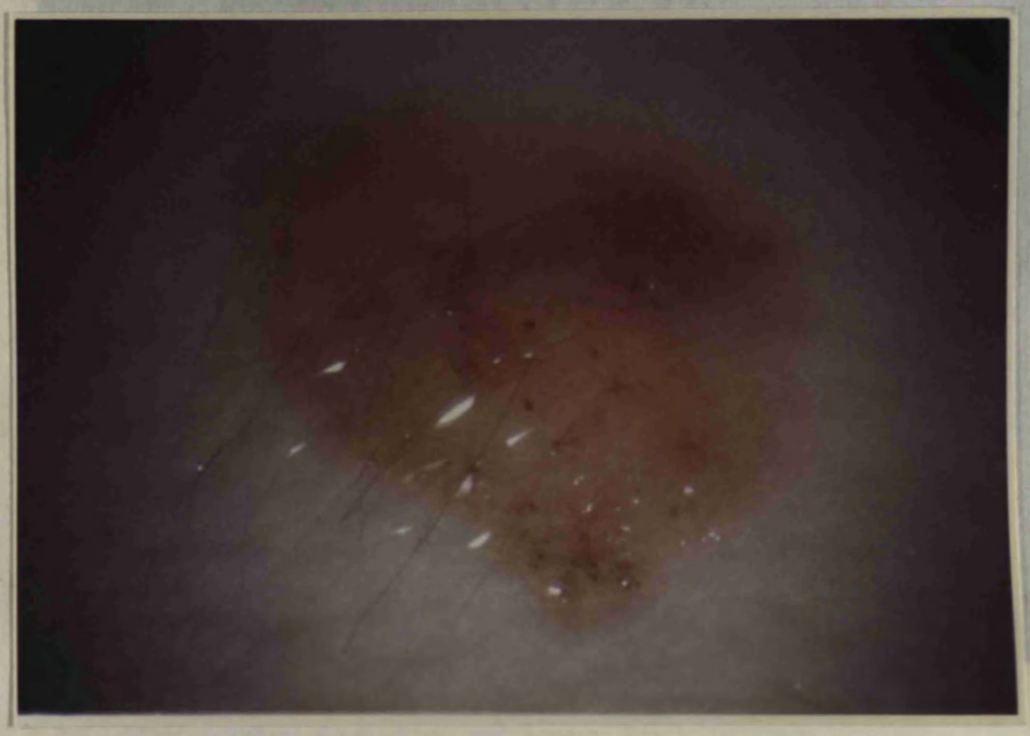

Histology: Junctional and intradermal components of a compound naevus.

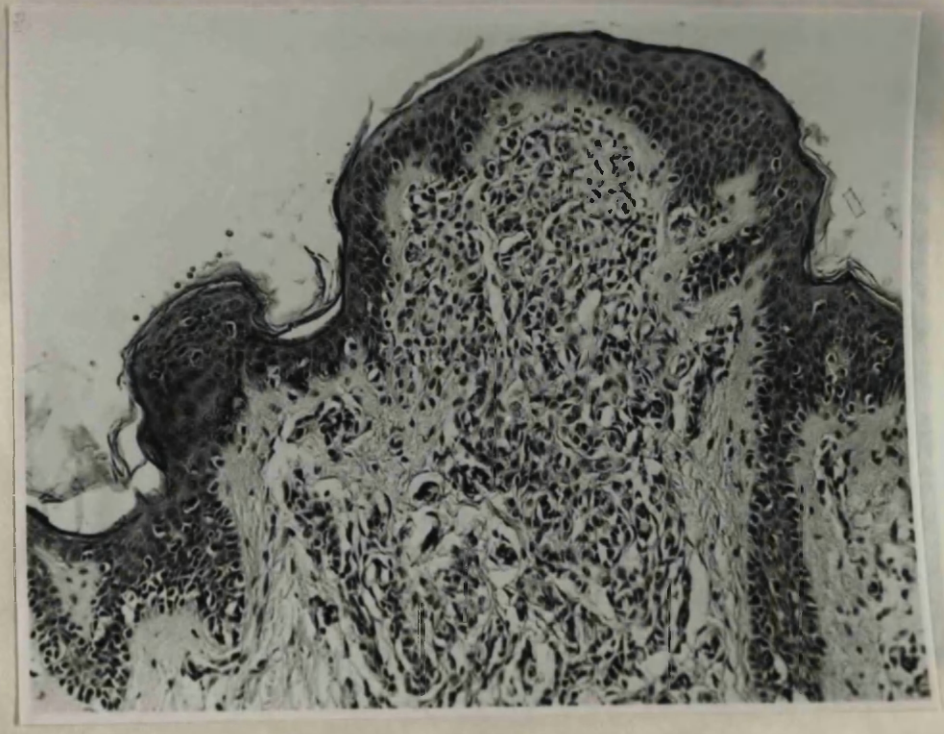

Case 25. Female aged 30 years.

Lesion on centre of forehead present for 3 months.

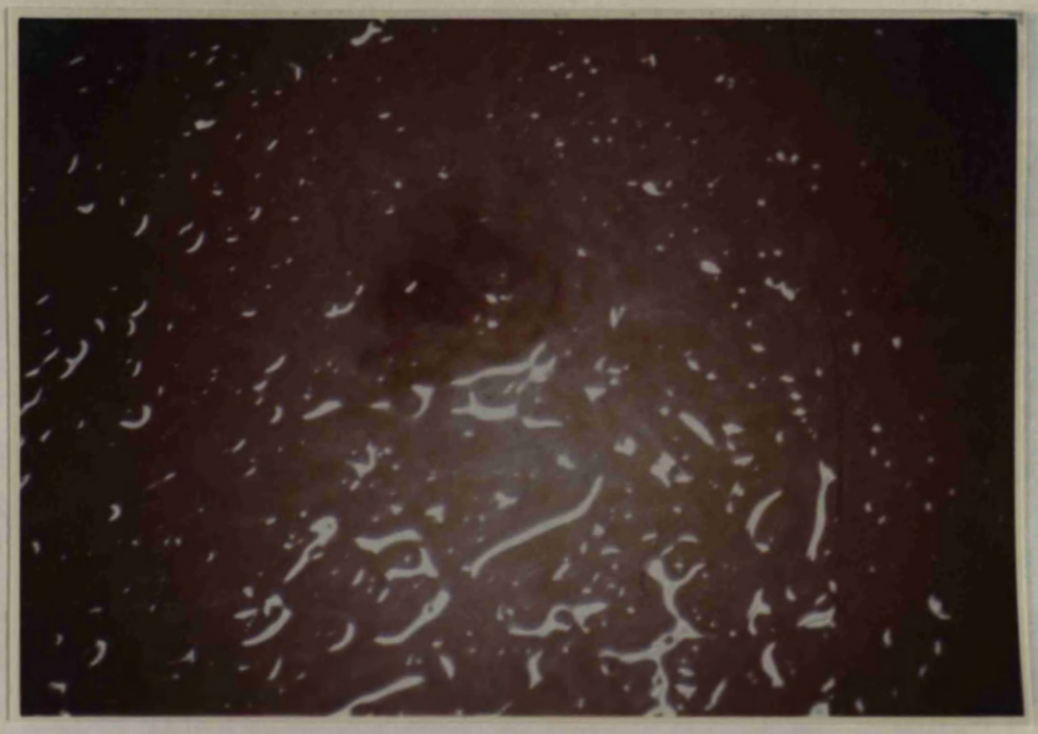

Histology: Compound naevus with active junctional component.

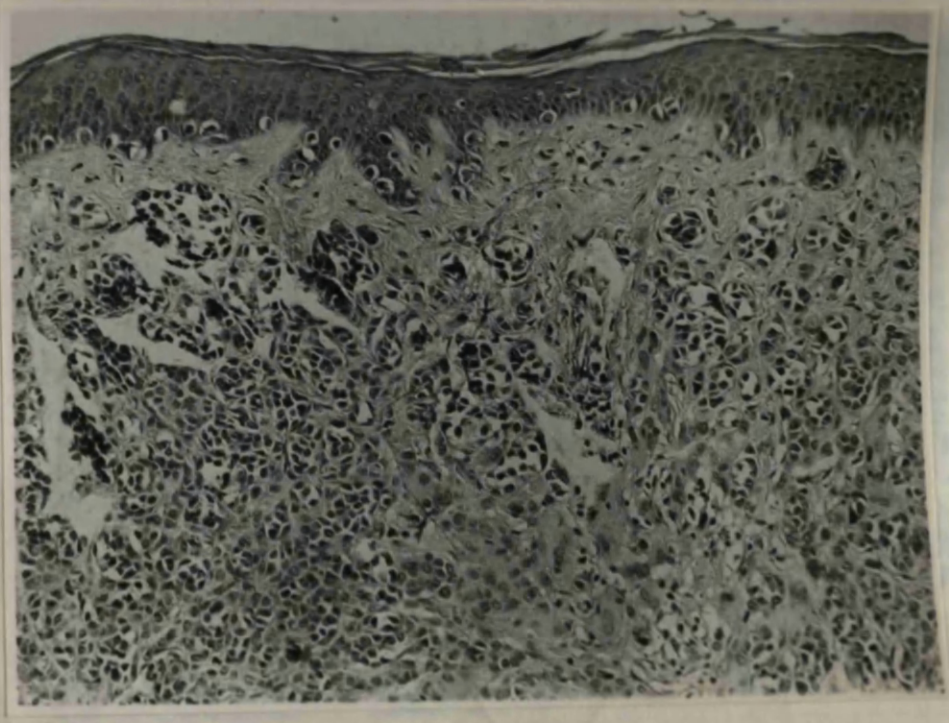

Case 26. Male aged 20 years.

Lesion on chest present since birth.



Histology: Compound naevus with active junctional component.



Case 27. Female aged 27 years.

Lesion on abdomen present for over 15 years.

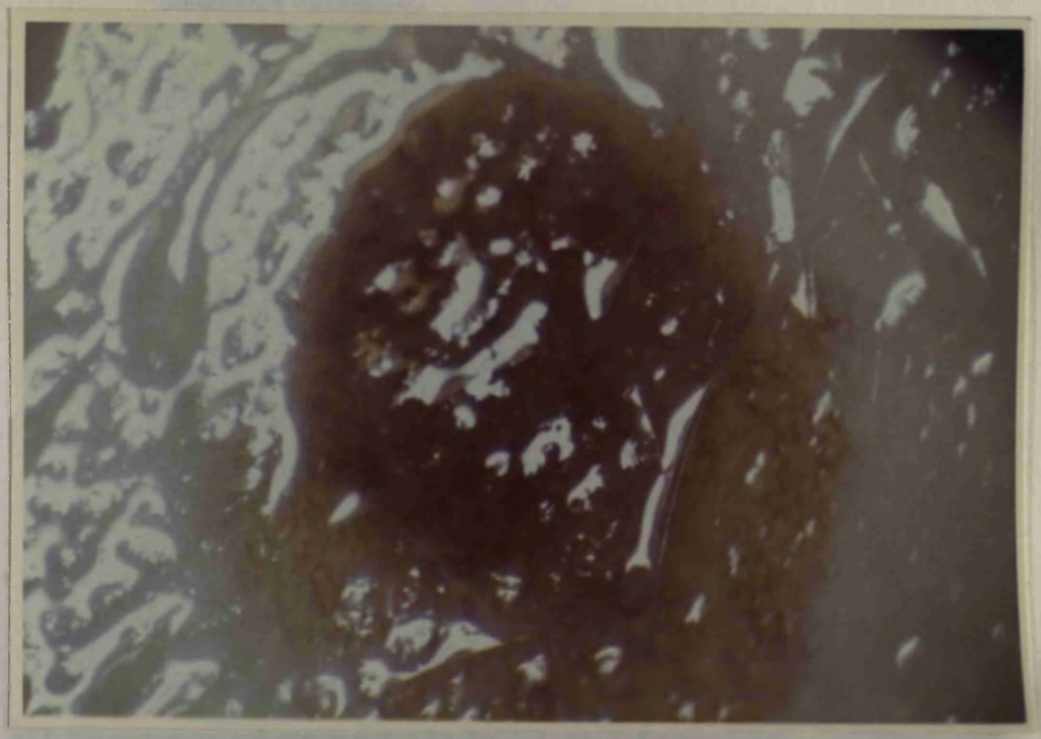

Histology: Compound naevus.

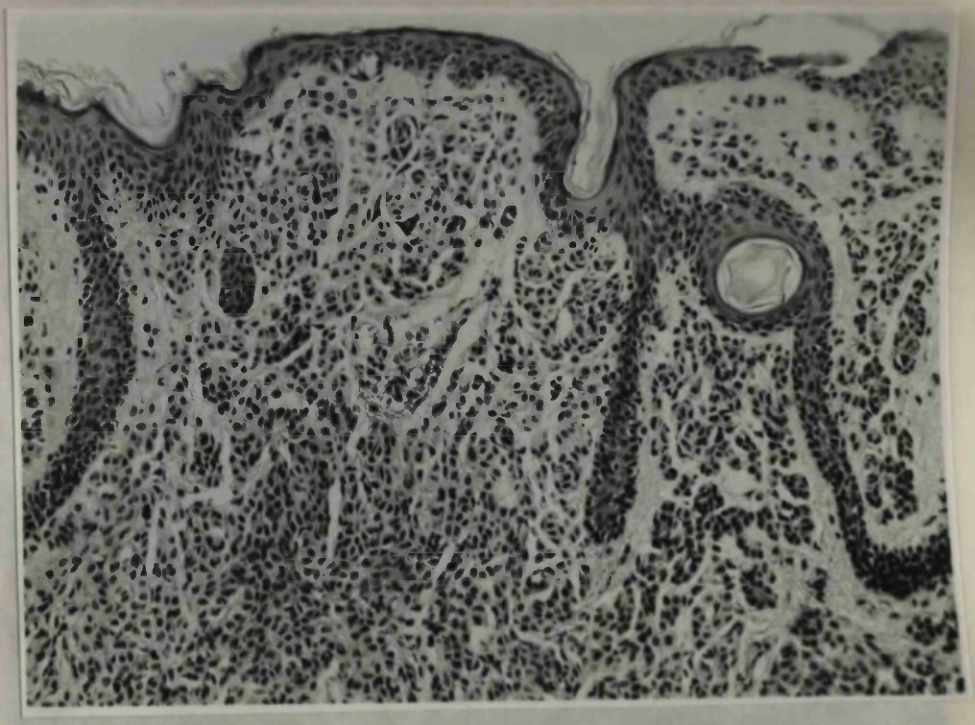

Case 28. Female aged 13 years.

Lesion on upper arm present since birth.

Growing slowly.



Histology: Compound naevus.

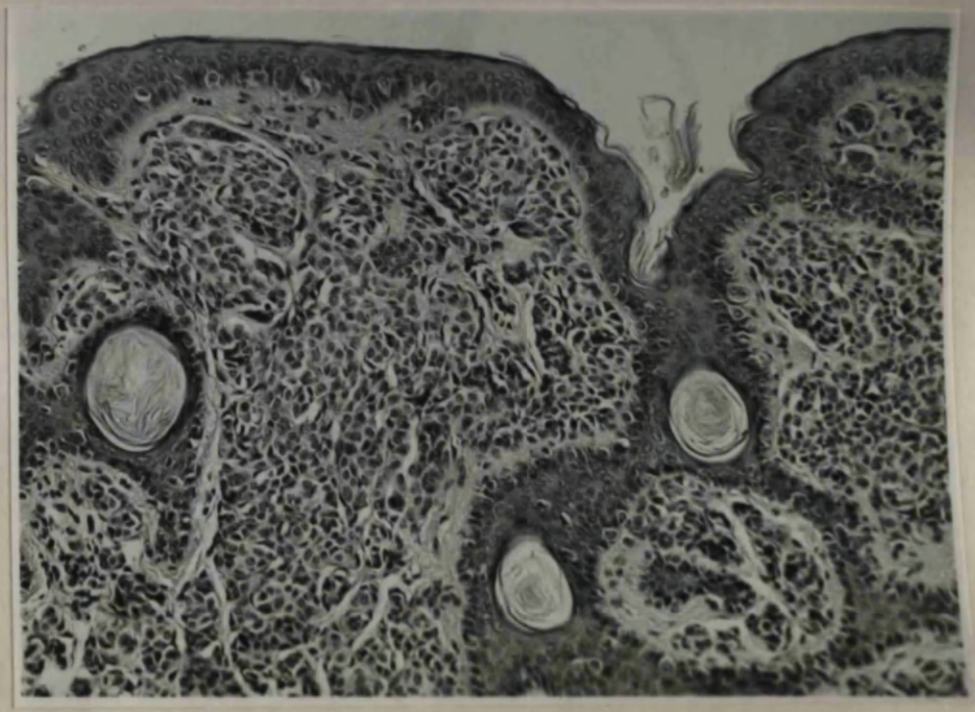

Case 29. Female aged 16 years.

Lesion on mid-back present since birth, traumatised by clothing.

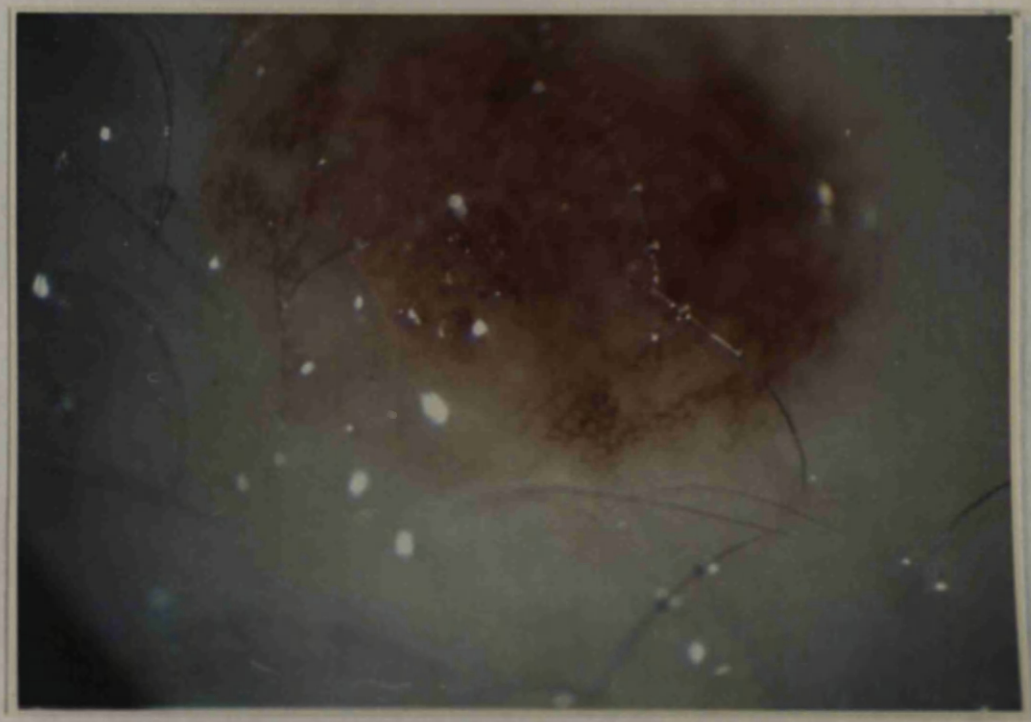

Histology: Junctional and intradermal features of compound naevus.

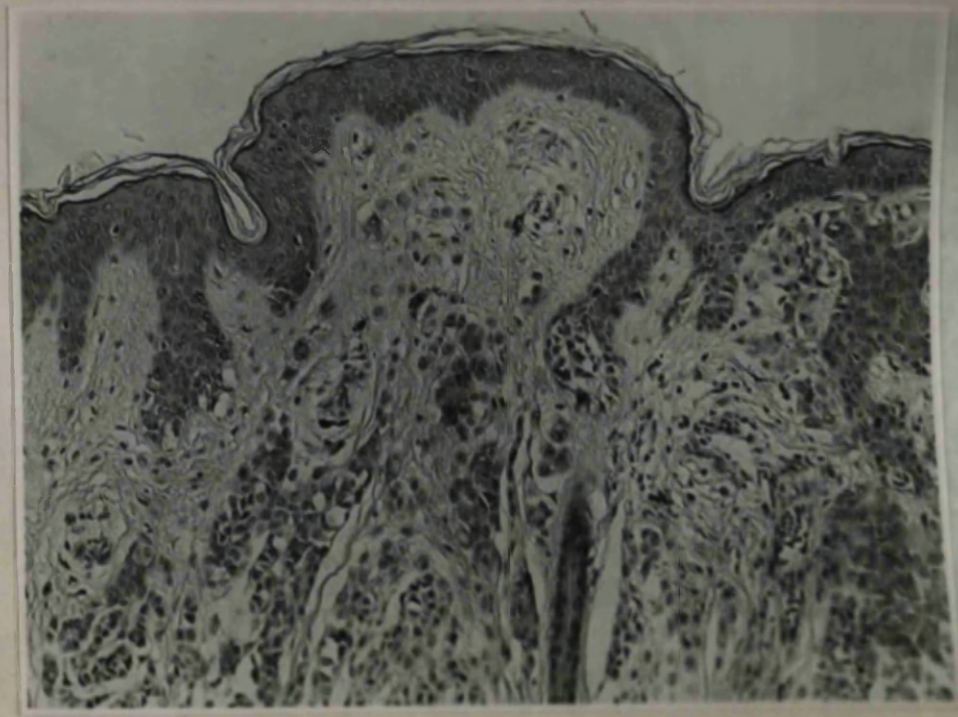

Case 30. Female aged 10 years.

Hairy pigmented lesion on chin present since birth, recent enlargement.



Histology: Compound naevus.

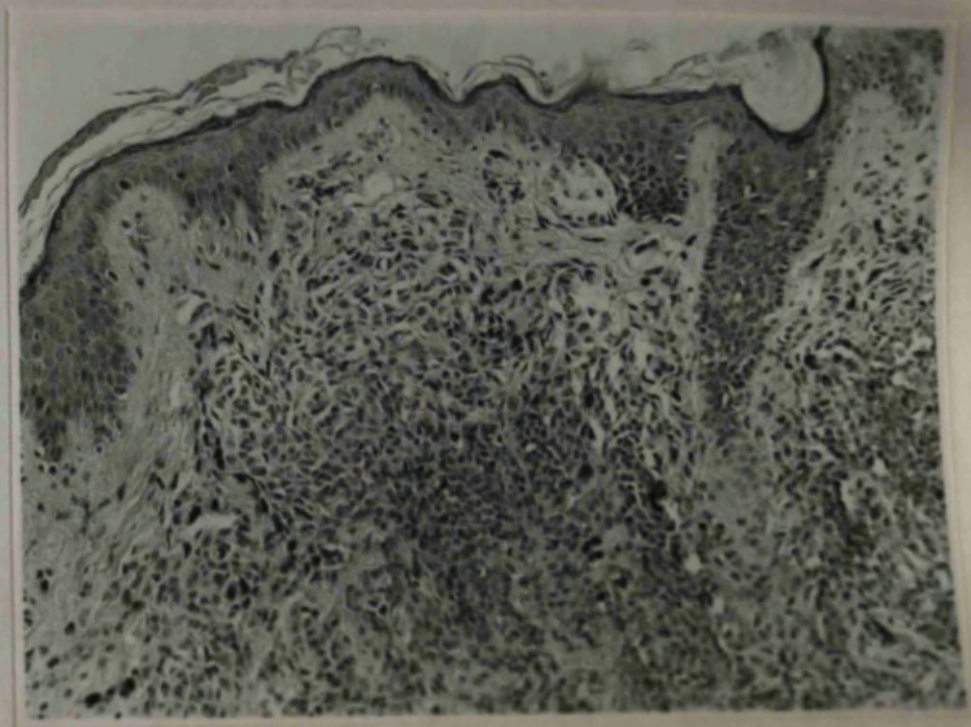

Case 31. Female aged 24 years.

Lesion on right lumbar area present since birth, recent enlargement.



Histology: Compound naevus with active junctional component.

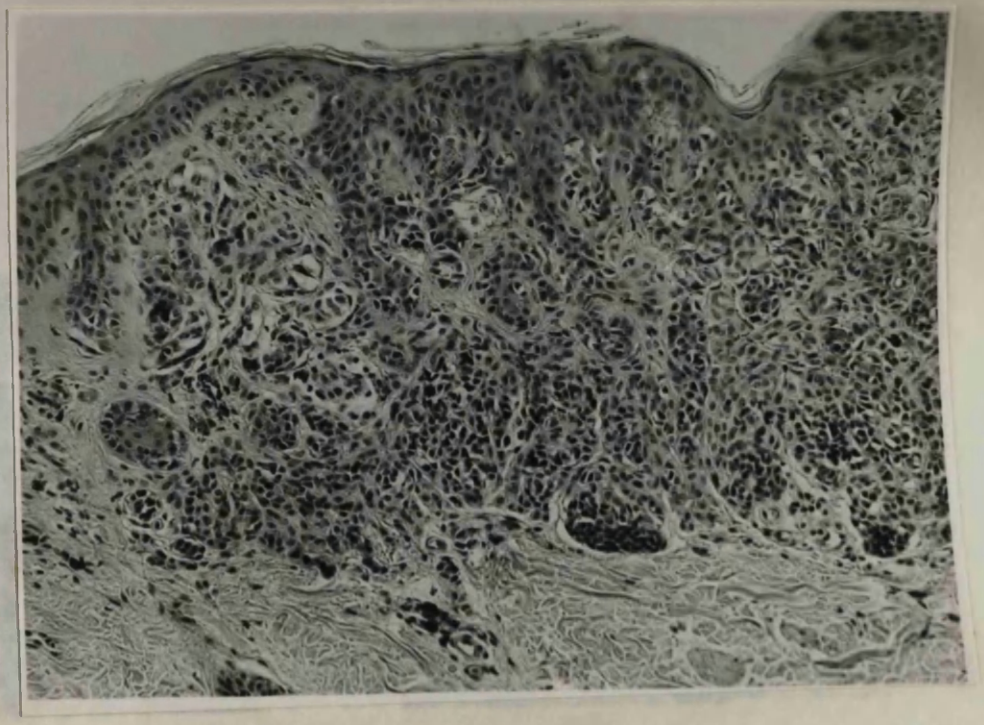

Case 32. Female aged 6 years.

Lesion on anterior chest wall present since birth.

Recent enlargement.



Histology: Compound naevus.



Case 33. Female aged 19 years.

Lesion on right cheek present since birth.



Histology: Compound naevus with active junctional component.

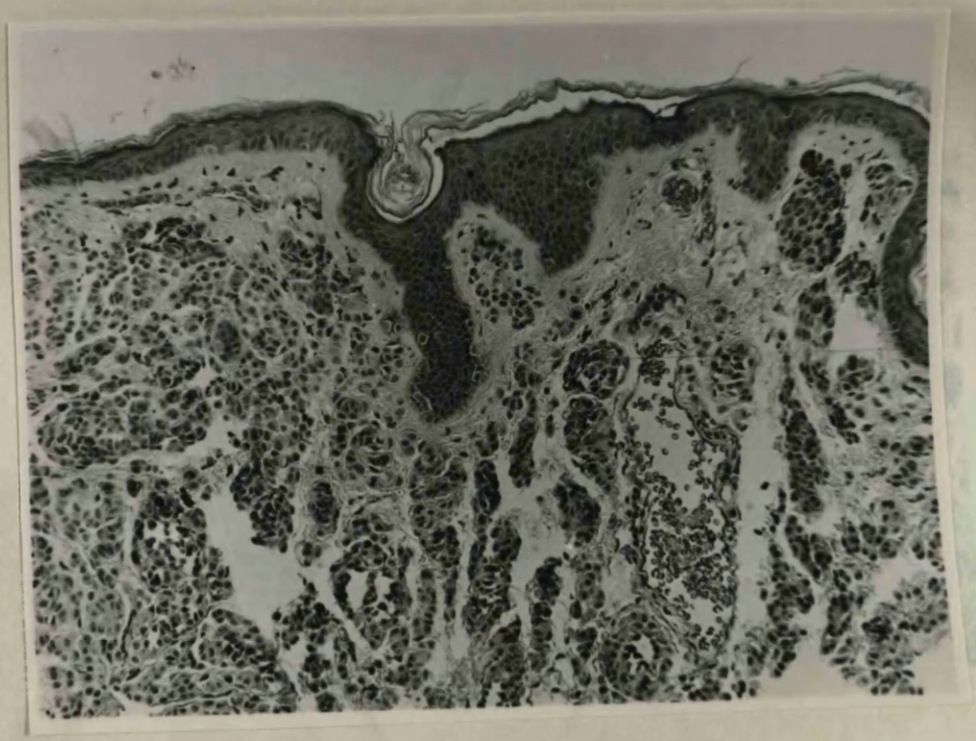

Case 34. (same patient as 33).

Lesion on right deltoid area present since birth.

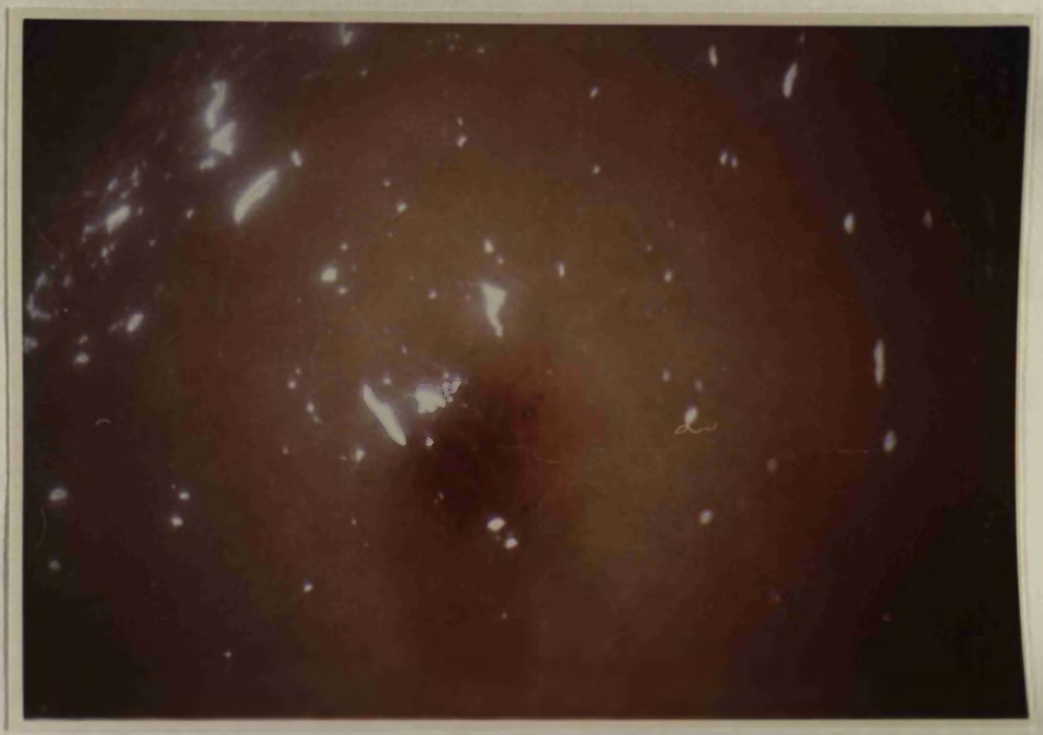

Histology: Compound naevus.



Case 35. Female aged 29 years.

Lesion on scapular area present since birth.

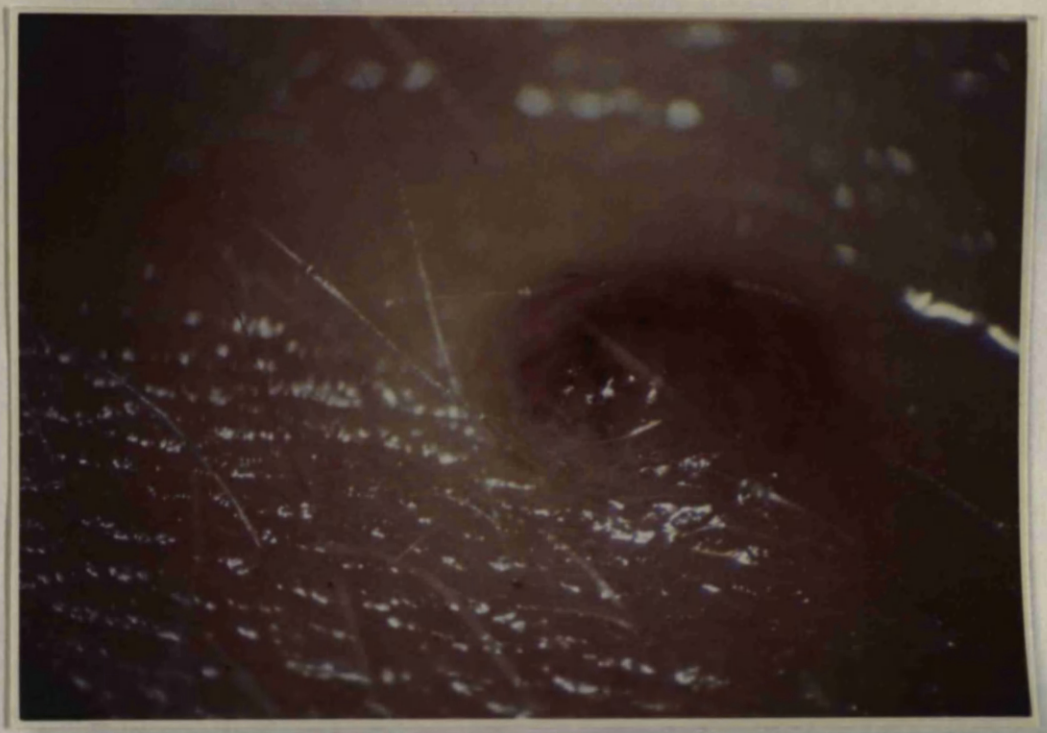

Histology: Compound naevus with minimal junctional component.

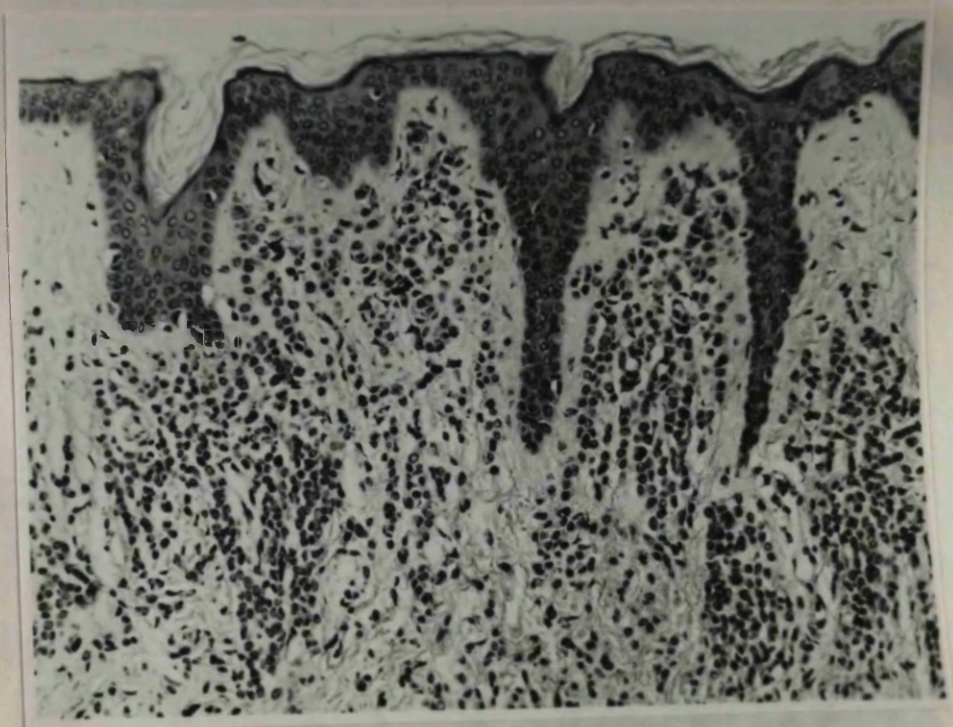

Case 36. (same patient as 35).

Lesion on upper anterior chest wall present since birth.

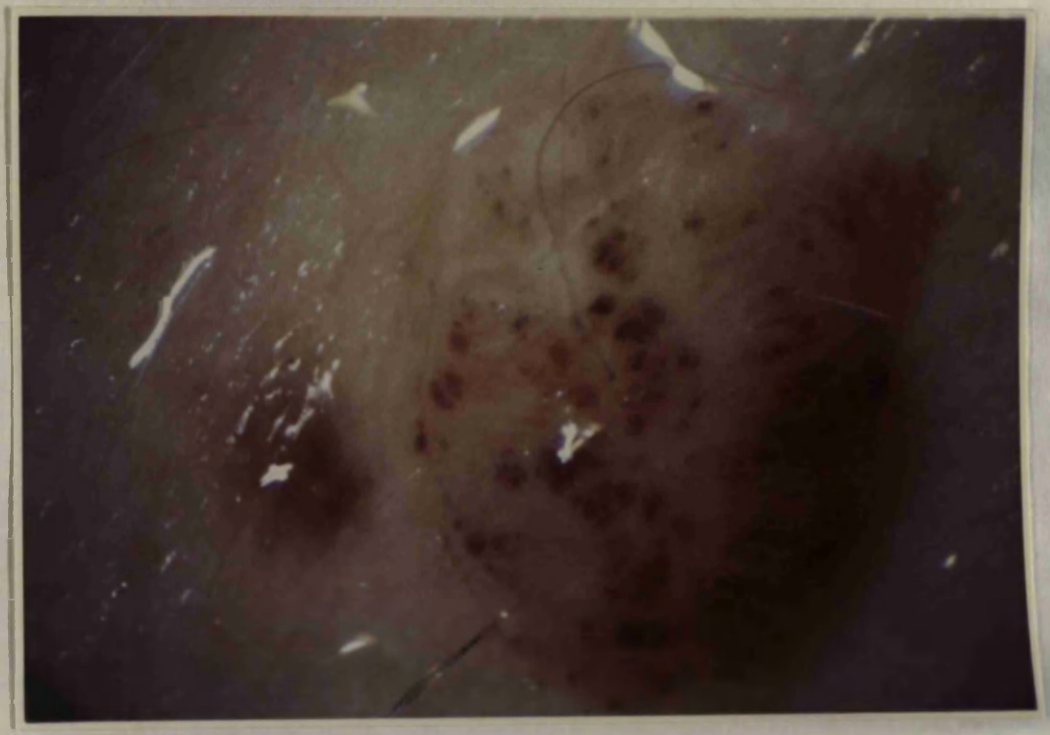

Histology: Compound naevus with minimal junctional component.



Case 37. Male aged 30 years.

Lesion on left deltoid area, present since birth, recent enlargement.

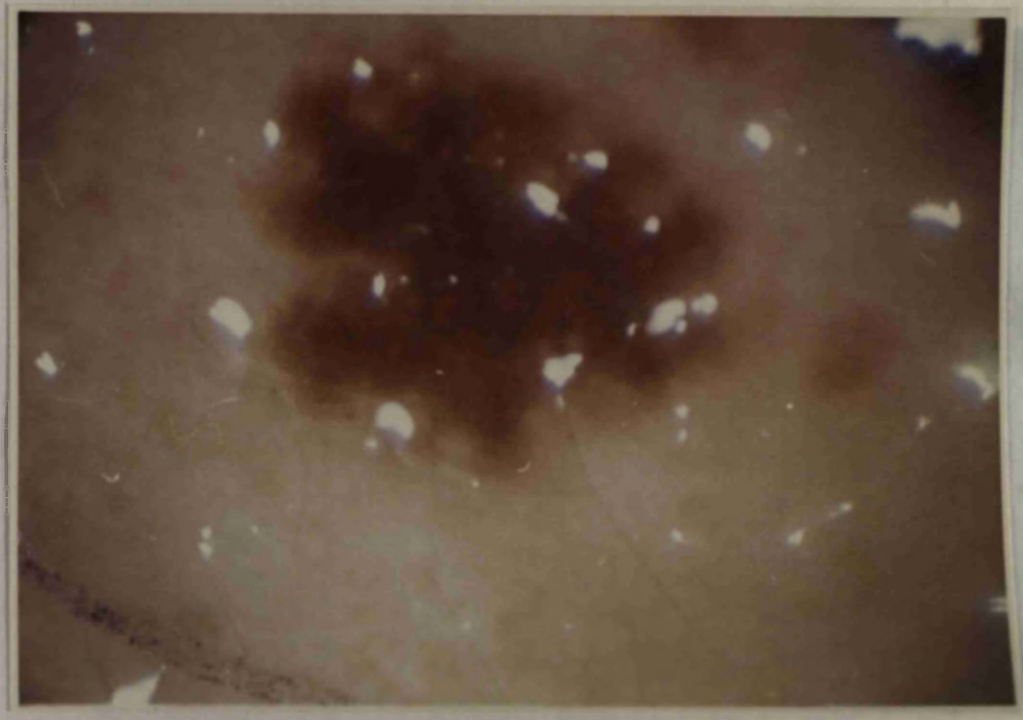

Histology: Compound naevus with very active junctional component.



Case 38. Female aged 14 years.

Lesion on upper arm present since birth.

Recent enlargement.

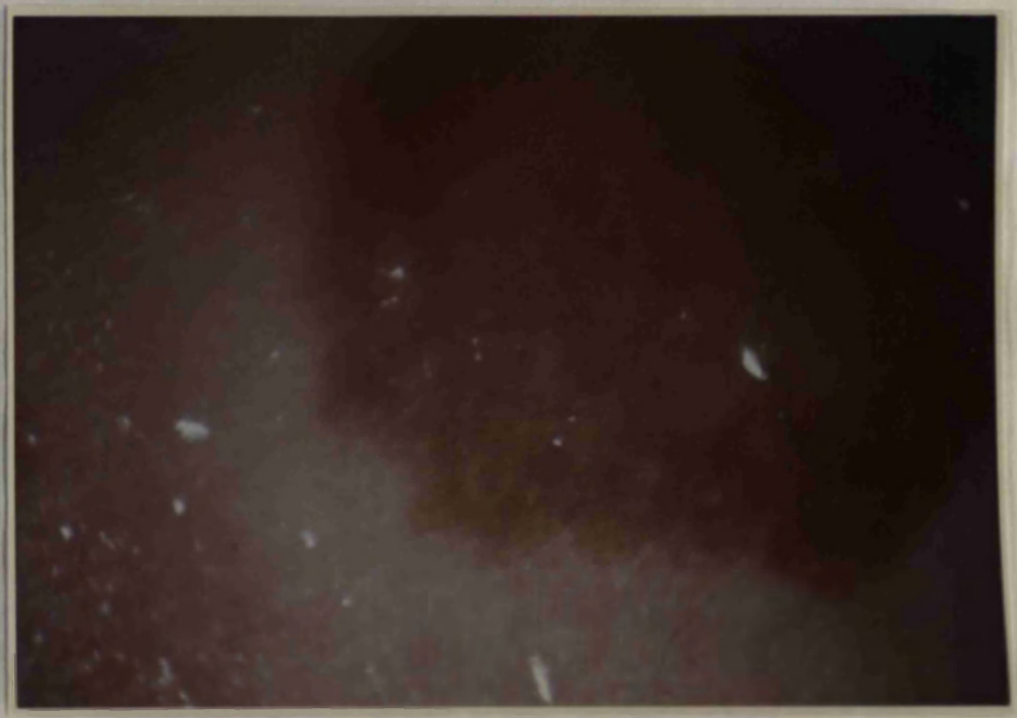

Histology: Compound naevus.

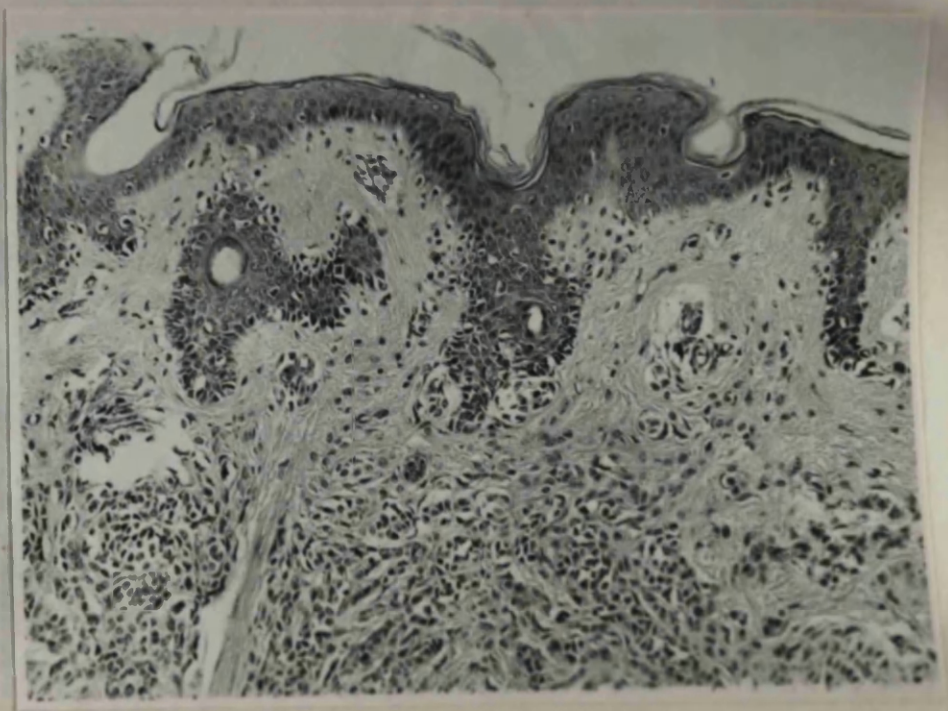

Case 39. Female aged 27 years.

Lesion on right breast present since birth.

Enlargement in year before examination.



Histology: Compound naevus with active junctional component.

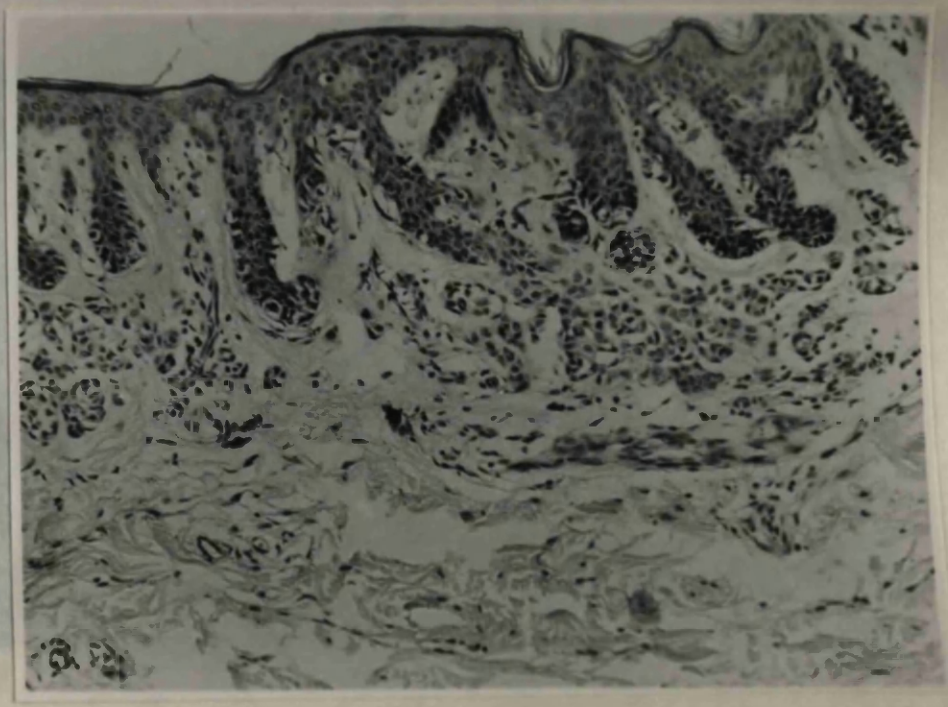

Case 40. Female aged 20 years.

Lesion on nape of neck present for at least 10 years.

History of recent bleeding.



Histology: Compound naevus with very active junctional component.

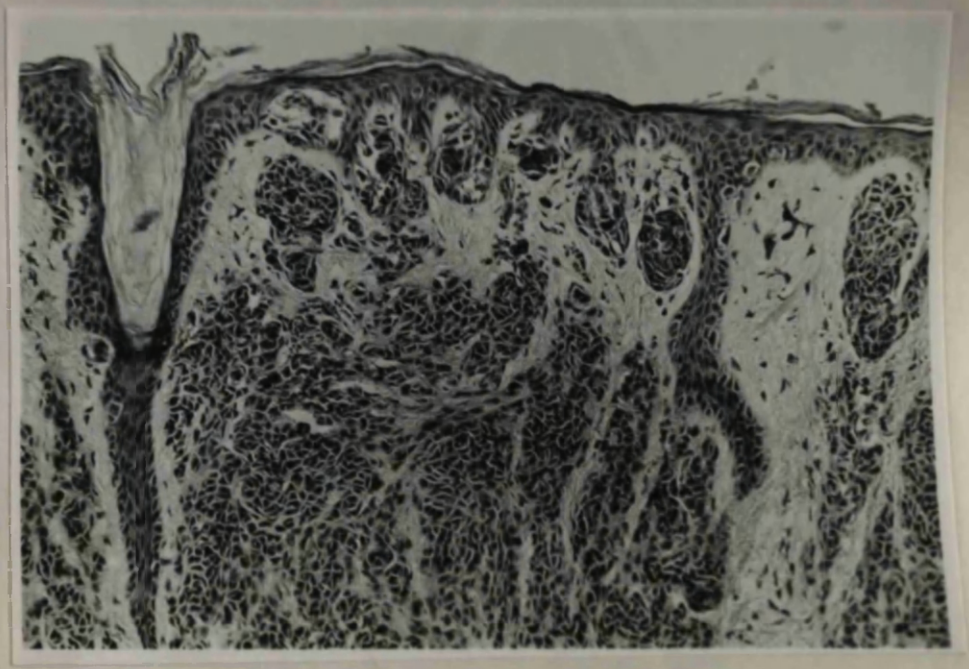

Case 41. Female aged 16 years.

Hairy lesion on right forearm present since birth.



Histology: Compound naevus.

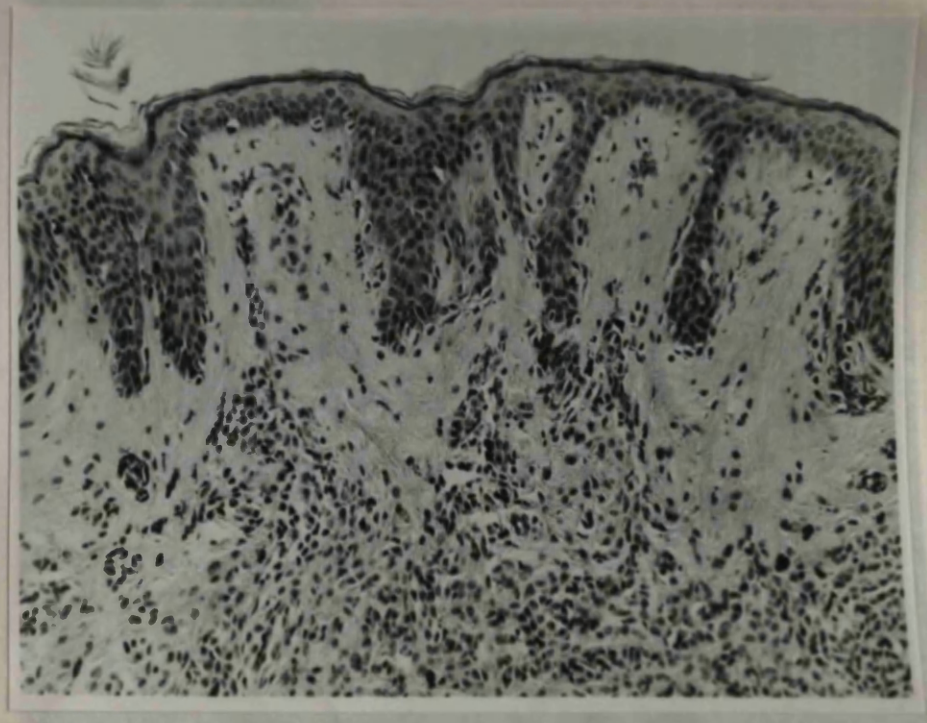

Case 42. Female aged 21 years.

Lesion on left upper arm present for at least 10 years.

Recent enlargement.

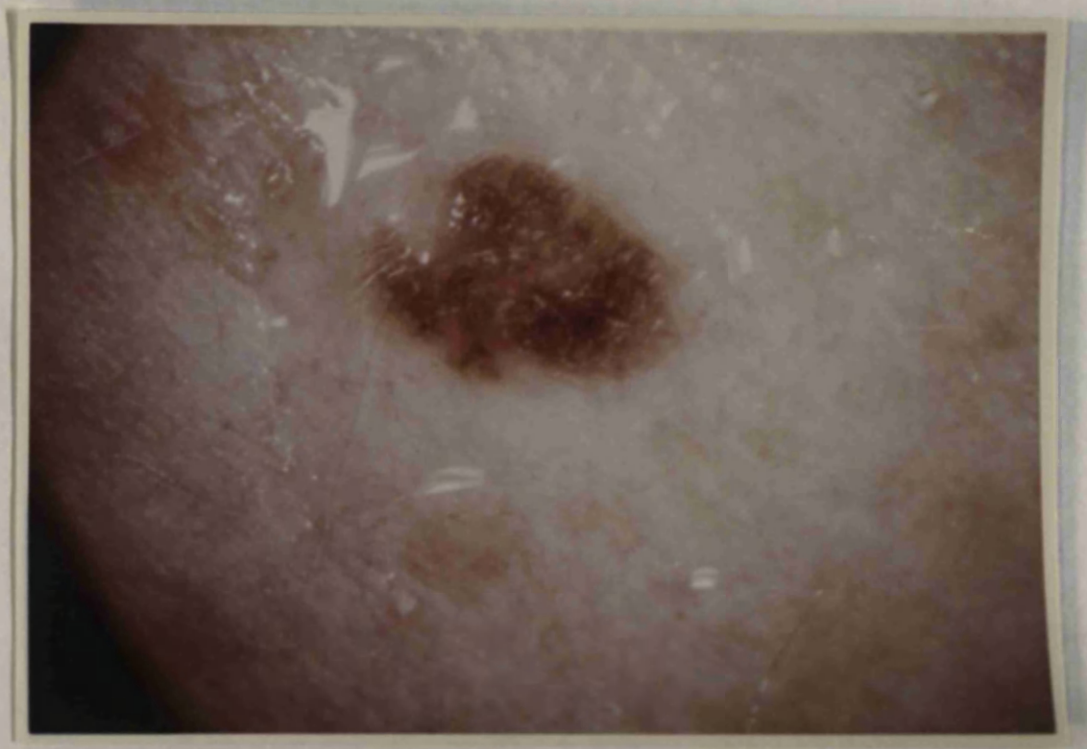

Histology: Compound naevus.

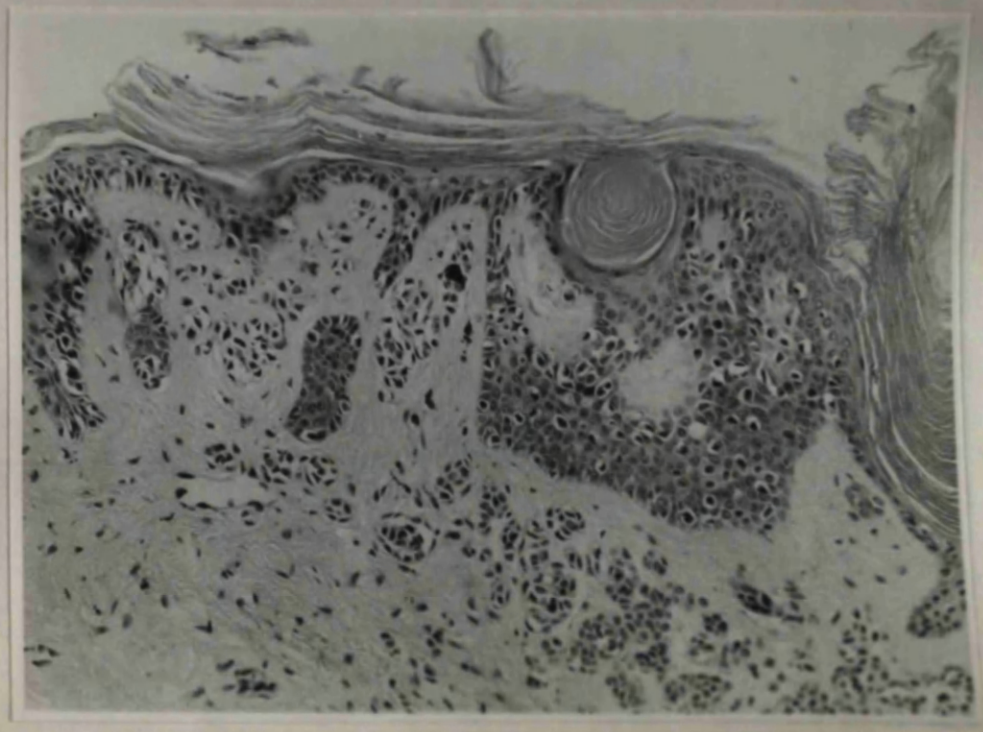

Case 43. Female aged 15 years.

Hairy lesion on left upper arm present since birth.

Recent enlargement.

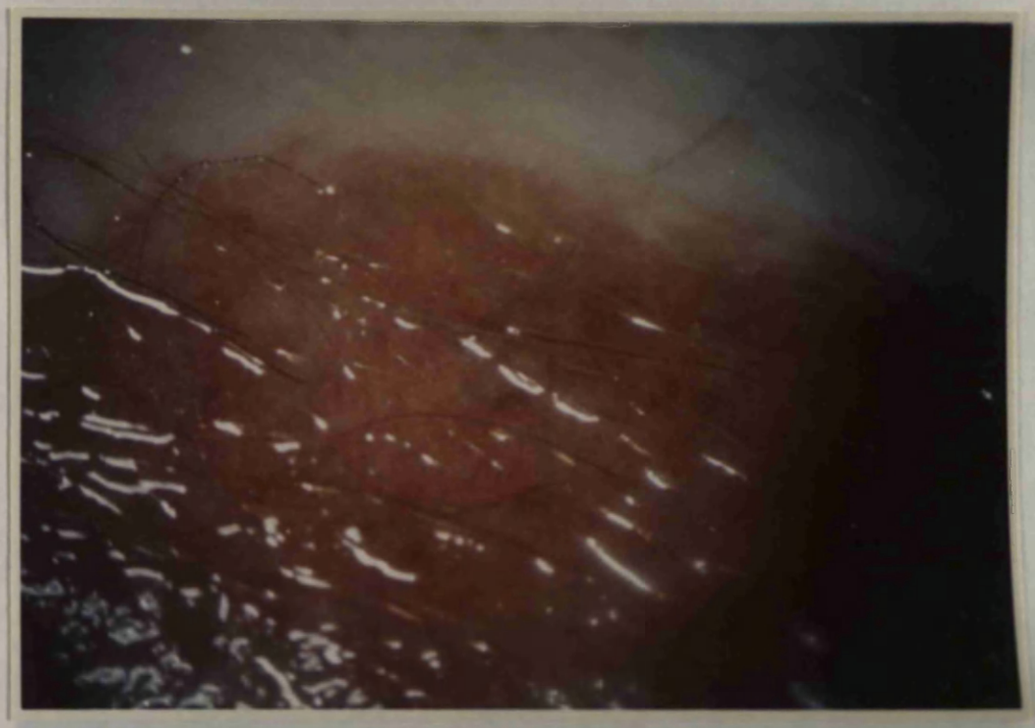

Histology: Junctional and intradermal components of compound naevus present.

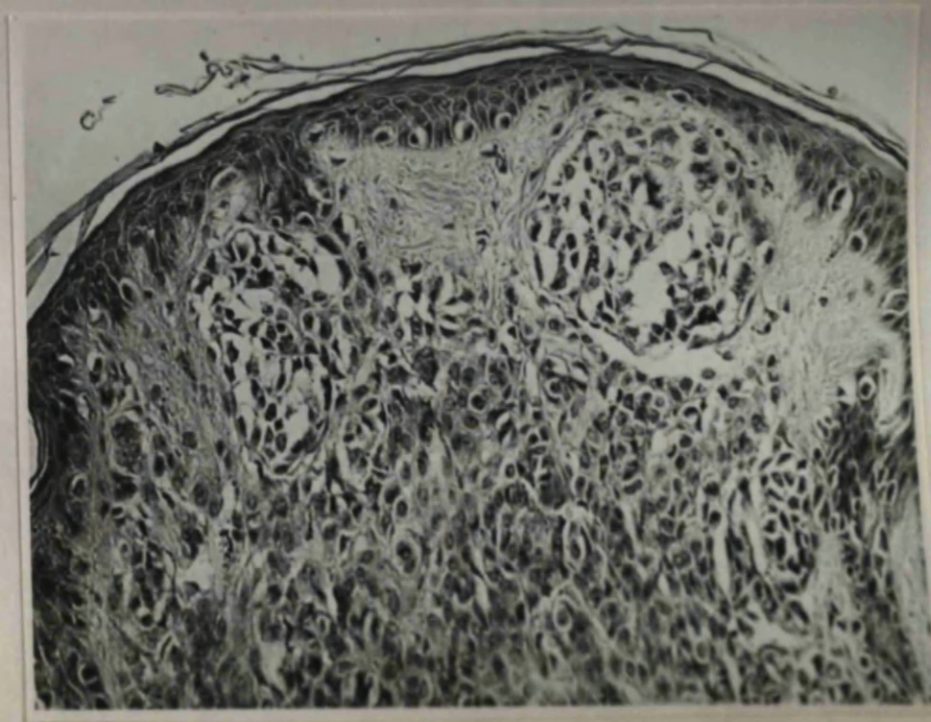

Case 44. Female aged 15 years.

Lesion on left shoulder present since birth.

Recent enlargement. Traumatised by clothing.

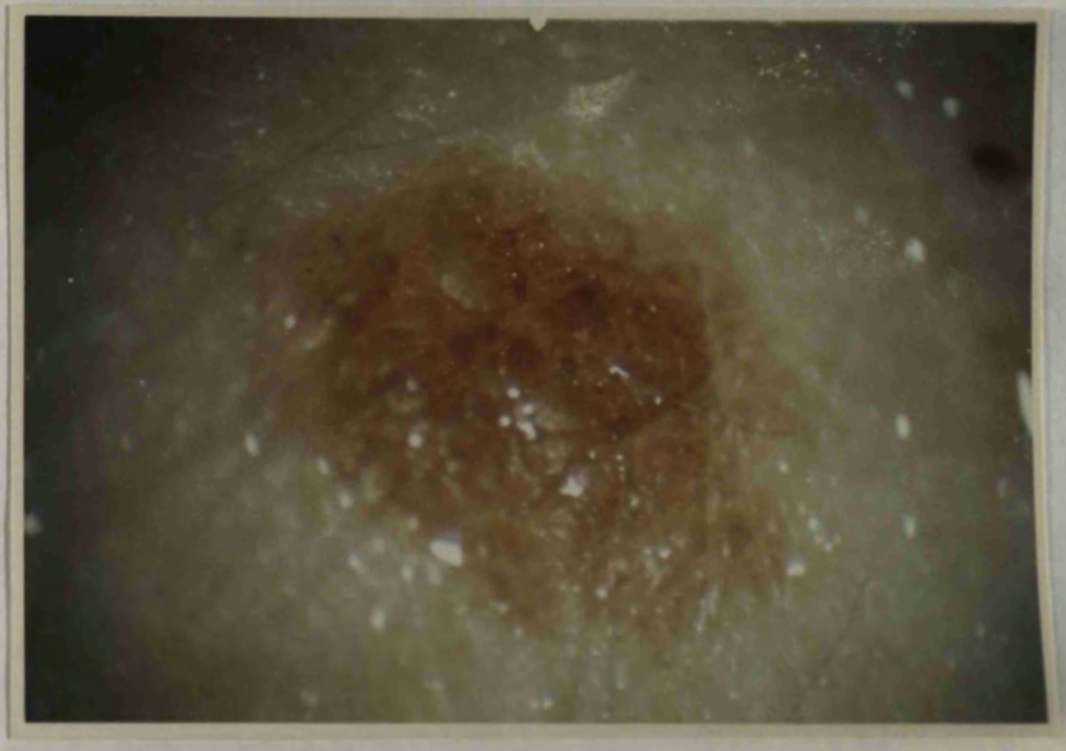

Histology: Compound naevus.

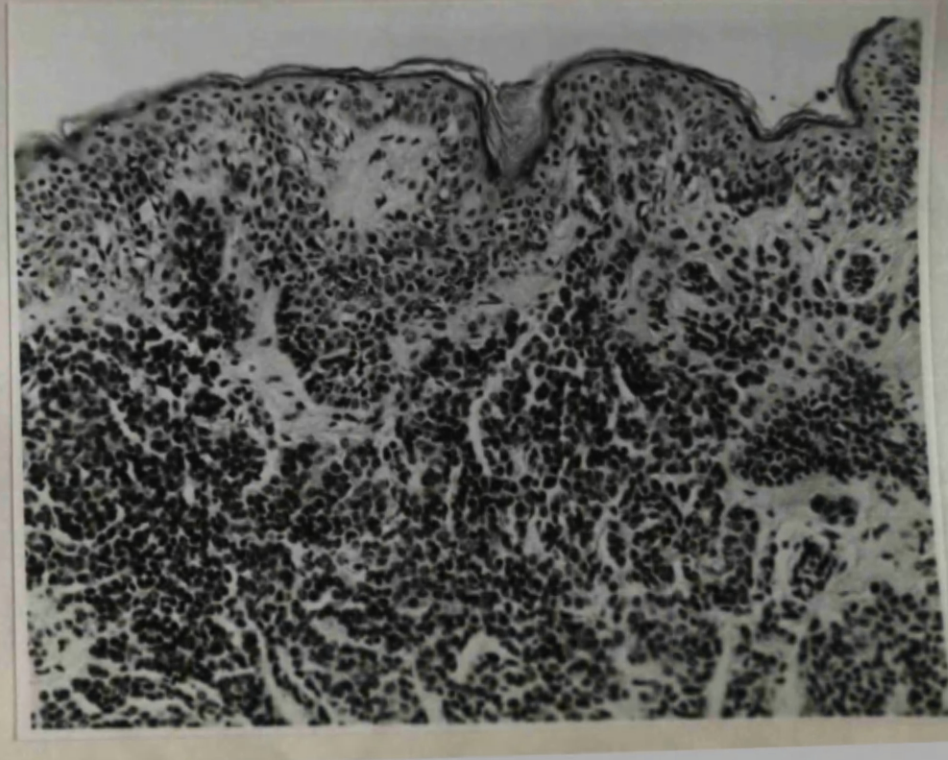

Case 45. Female aged 14 years.

Lesion on nose present since birth.

Recent enlargement.

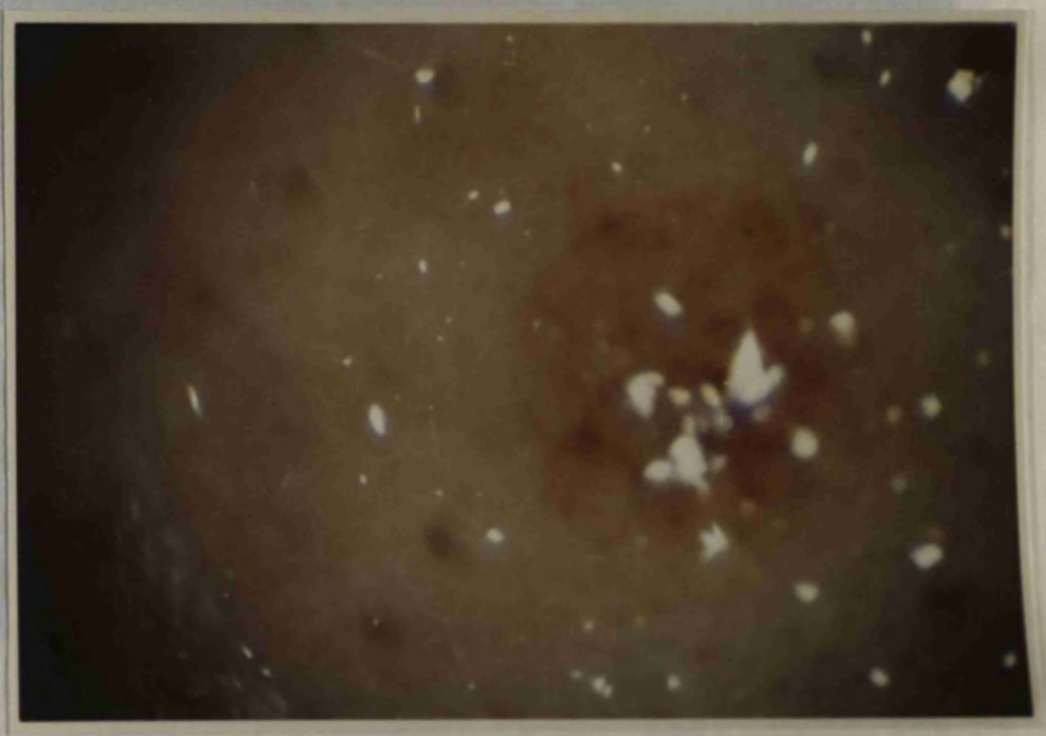

Histology: Compound naevus.

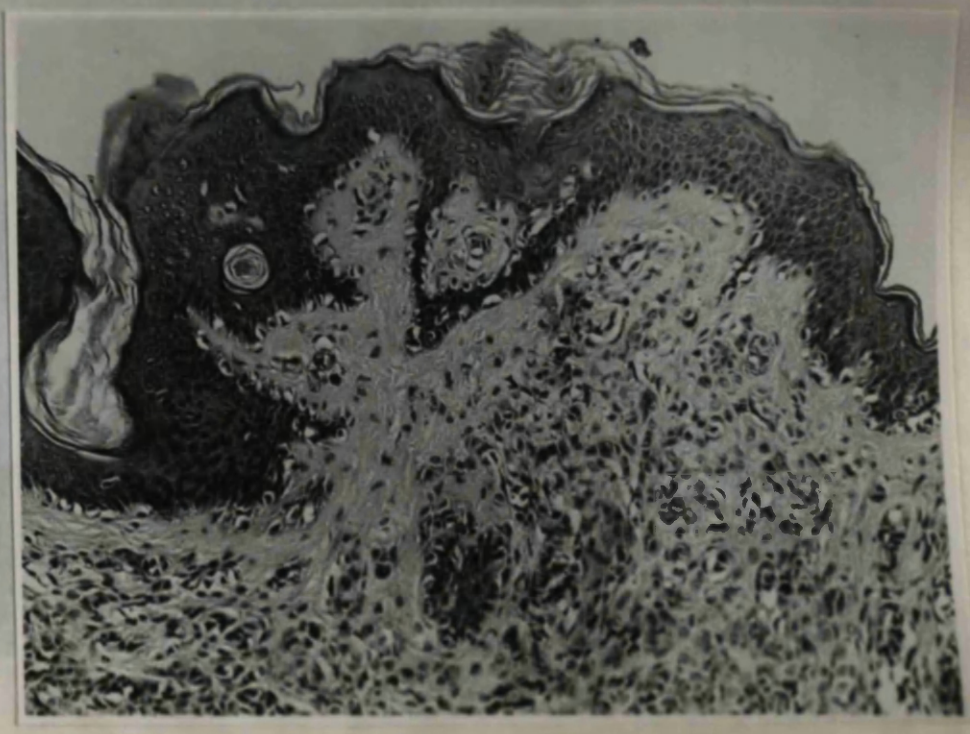

Case 46. (same patient as 45).

Lesion on left upper arm present since birth.

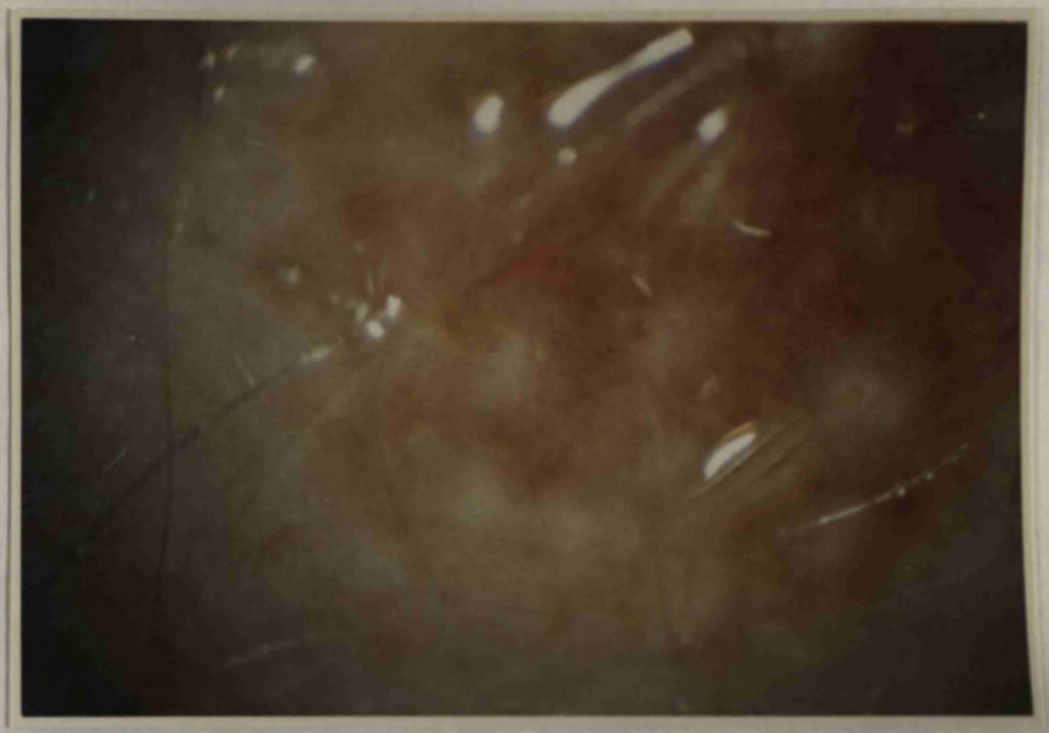

Histology: Compound naevus.

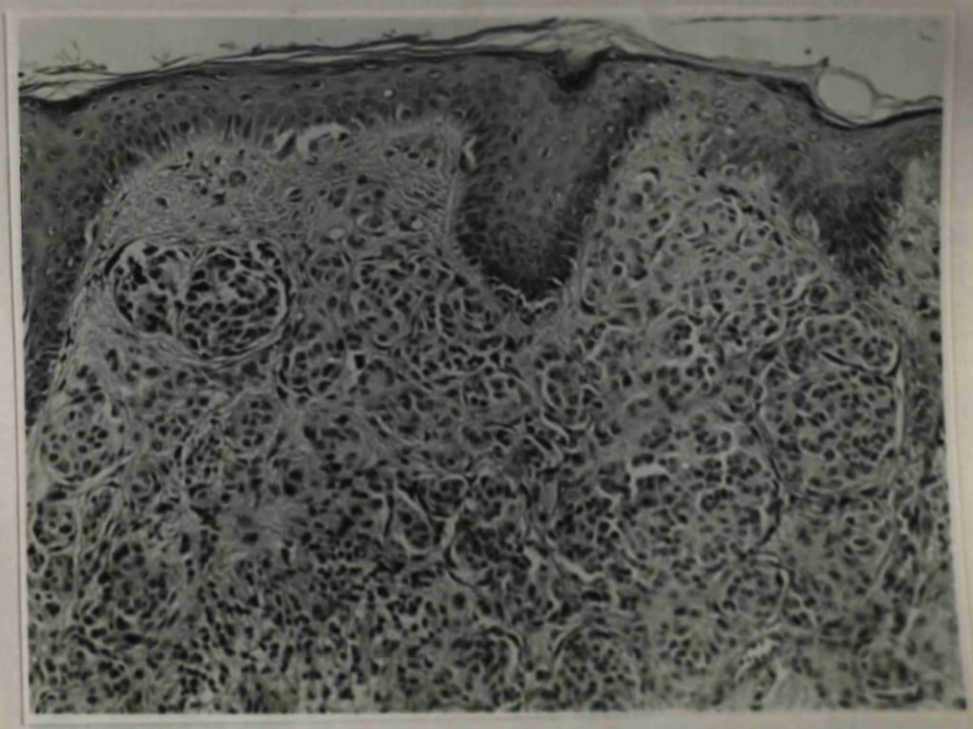

Case 47. Female aged 5 years.

Hairy lesion on left forearm present since birth.

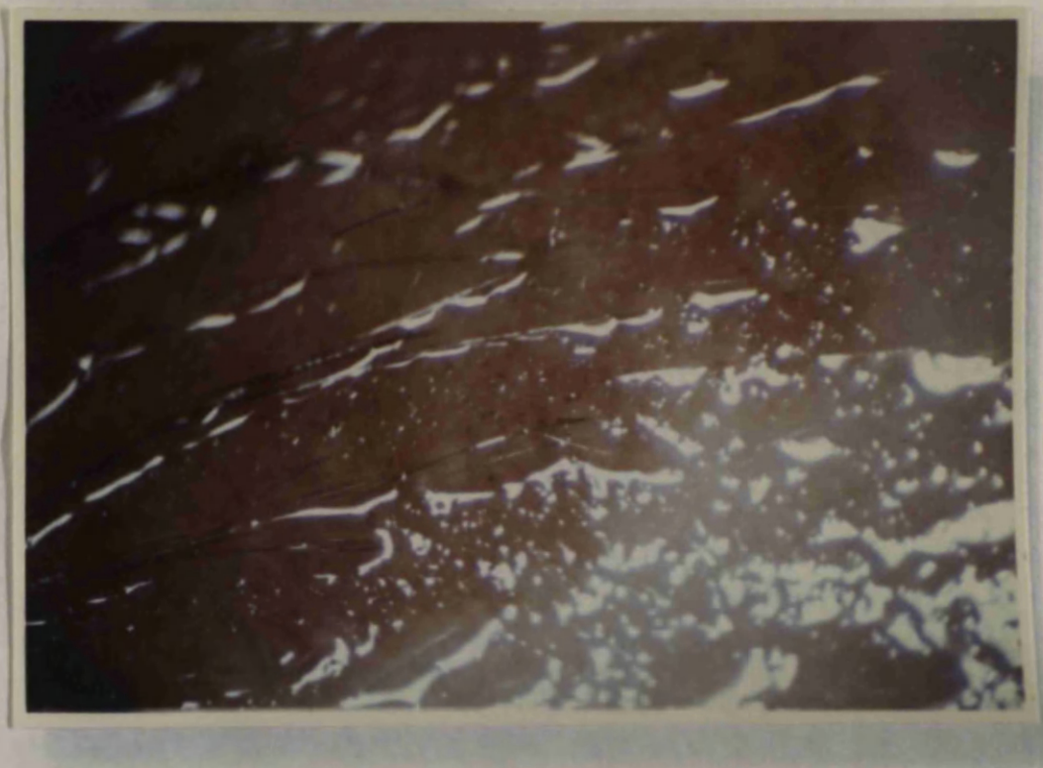

Histology: Compound naevus with active junctional component.

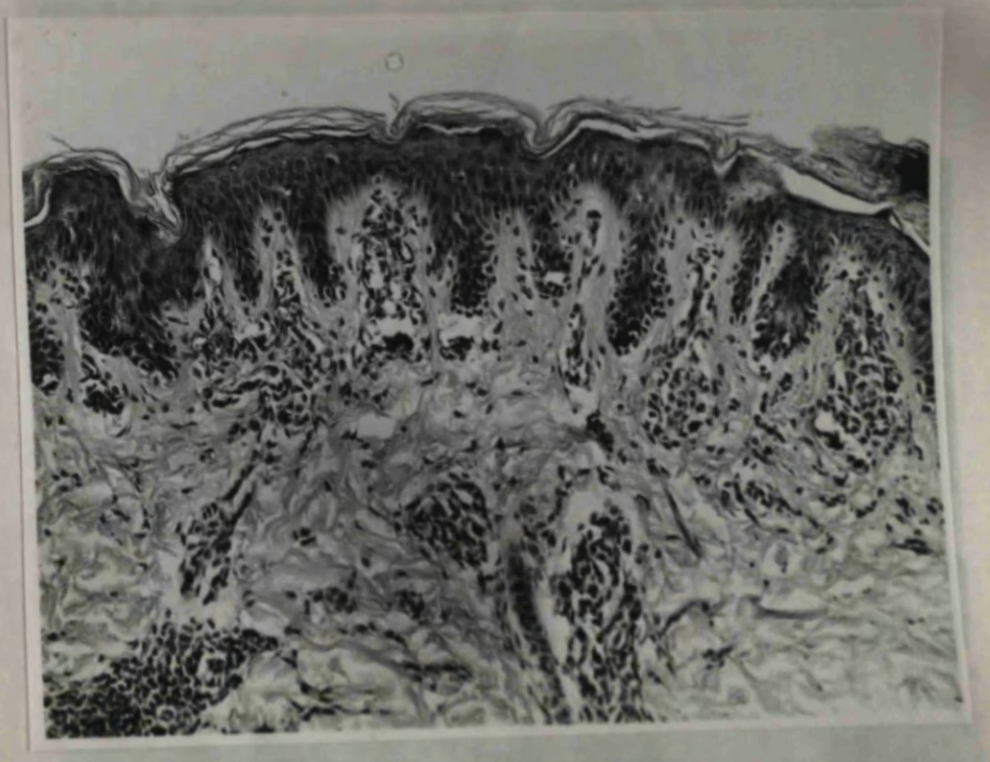

Case 48. Female aged 50 years.

Lesion on forehead present since birth.

Recent enlargement.



Histology: Compound naevus with minimal junctional activity.

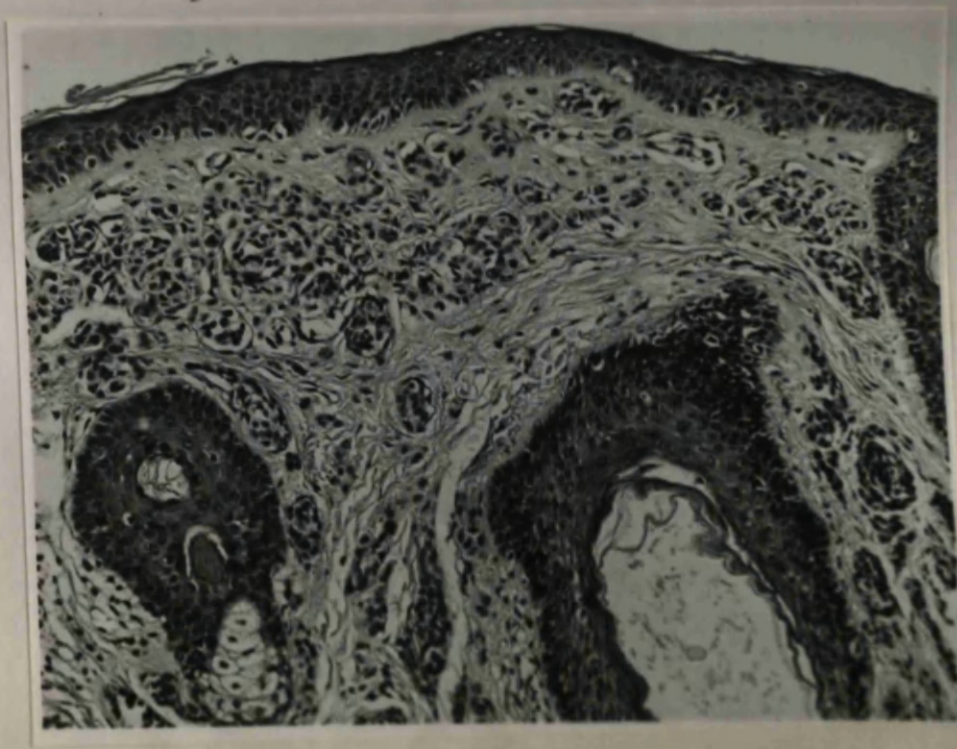

Case 49. Male aged 15 years.

Lesion on right scapular area present since birth.

Recent enlargement.



Histology: Compound naevus with minimal intradermal component.



Case 50. (same patient as 49).

Lesion on right deltoid area present since birth.

Recent enlargement.

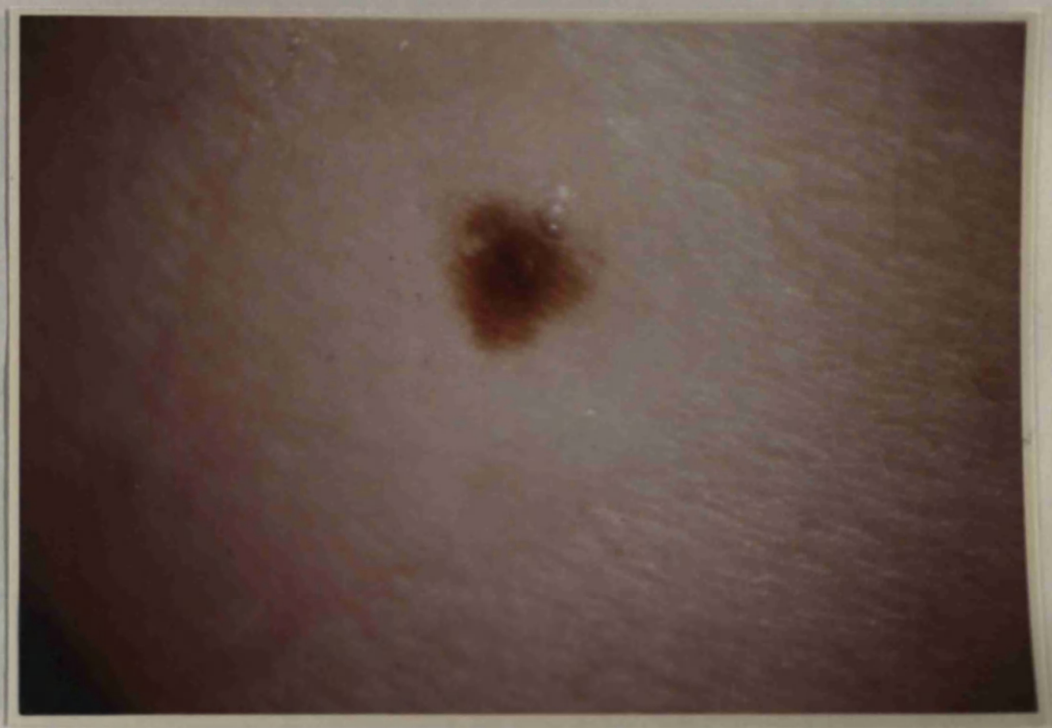

Histology: Compound naevus with minimal intradermal component.



Case 51. Male aged 20 years.

Lesion on mid-back present since birth.

The lesion was said to be painful.



Histology: Compound naevus.

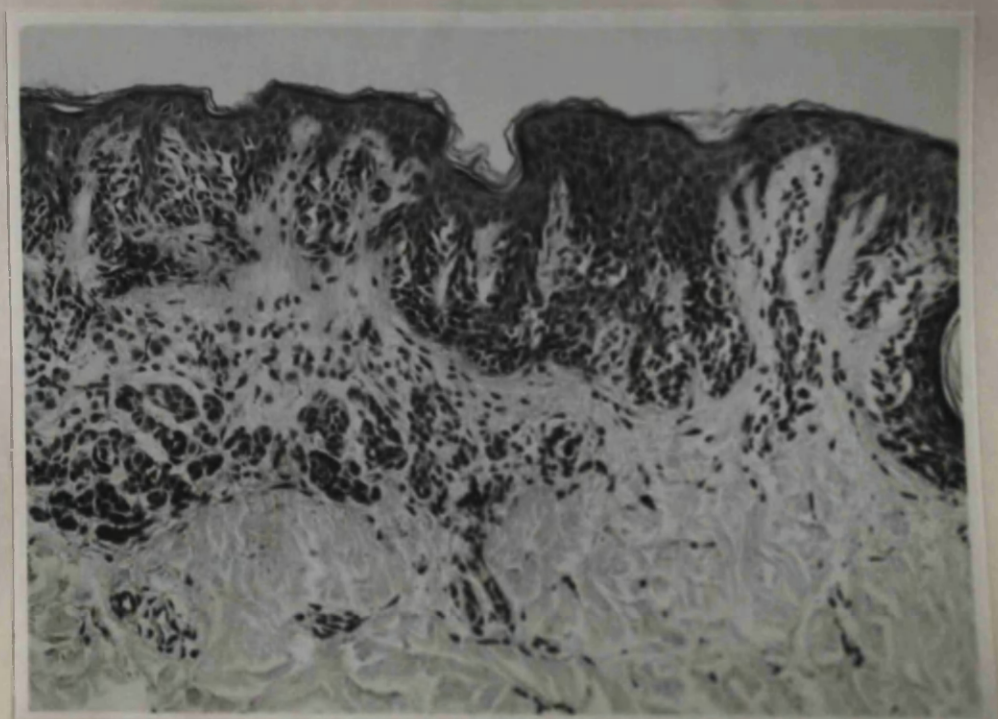

Case 52. (same patient as 51).

Lesion on infrascapular area present since birth.

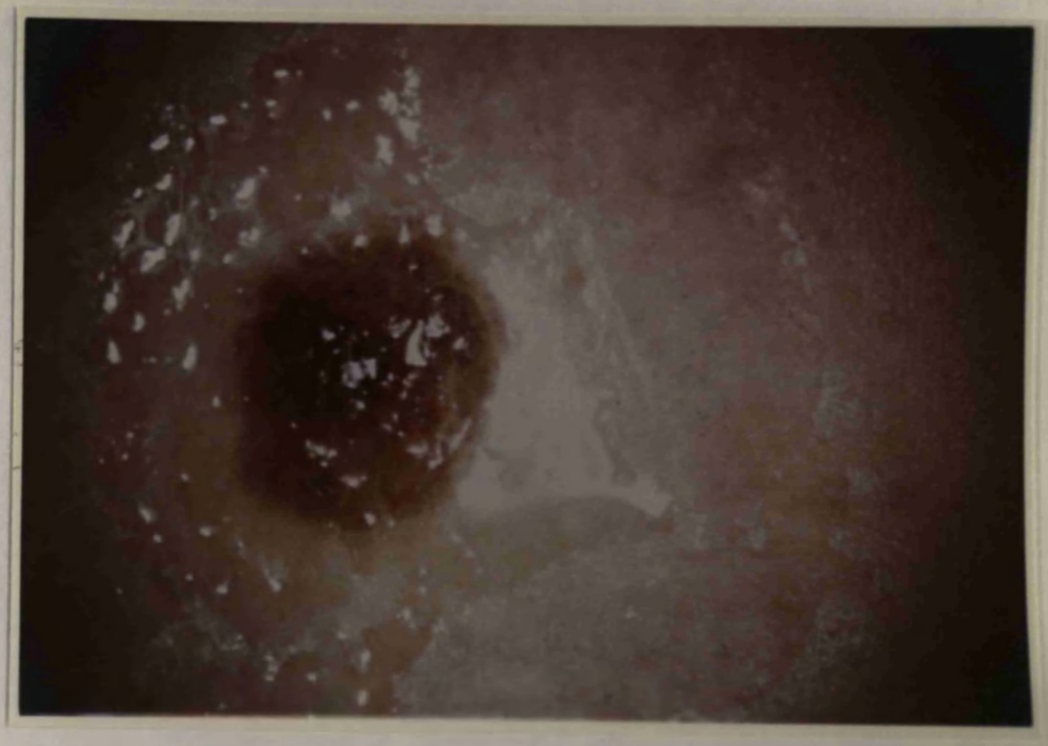

Histology: Compound naevus.

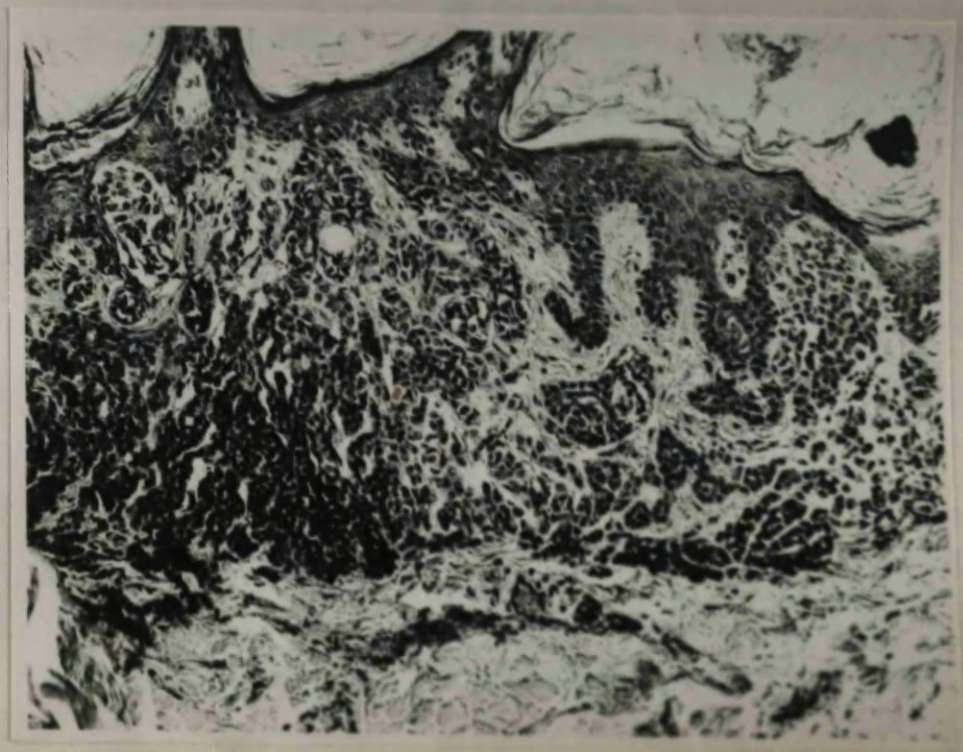

Case 53. Male aged 17 years.

Lesion on left lumbar area present since birth.

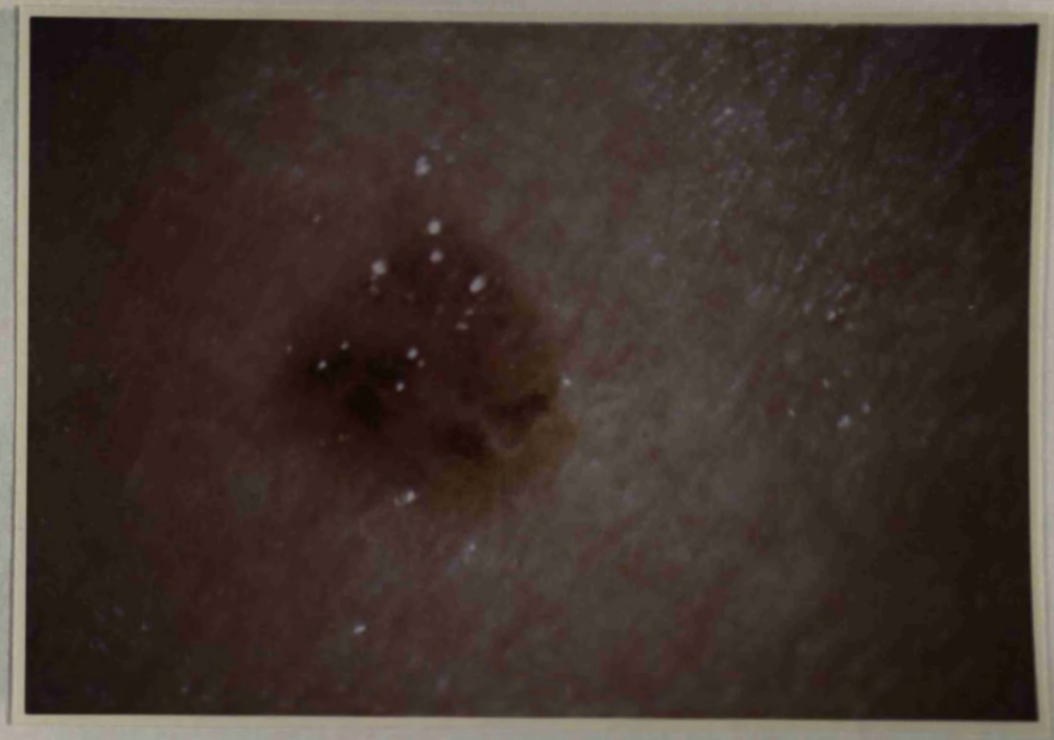

Histology: Compound naevus with active junctional component.



Case 54. (same patient as 53).

Lesion on lower abdomen present since birth.

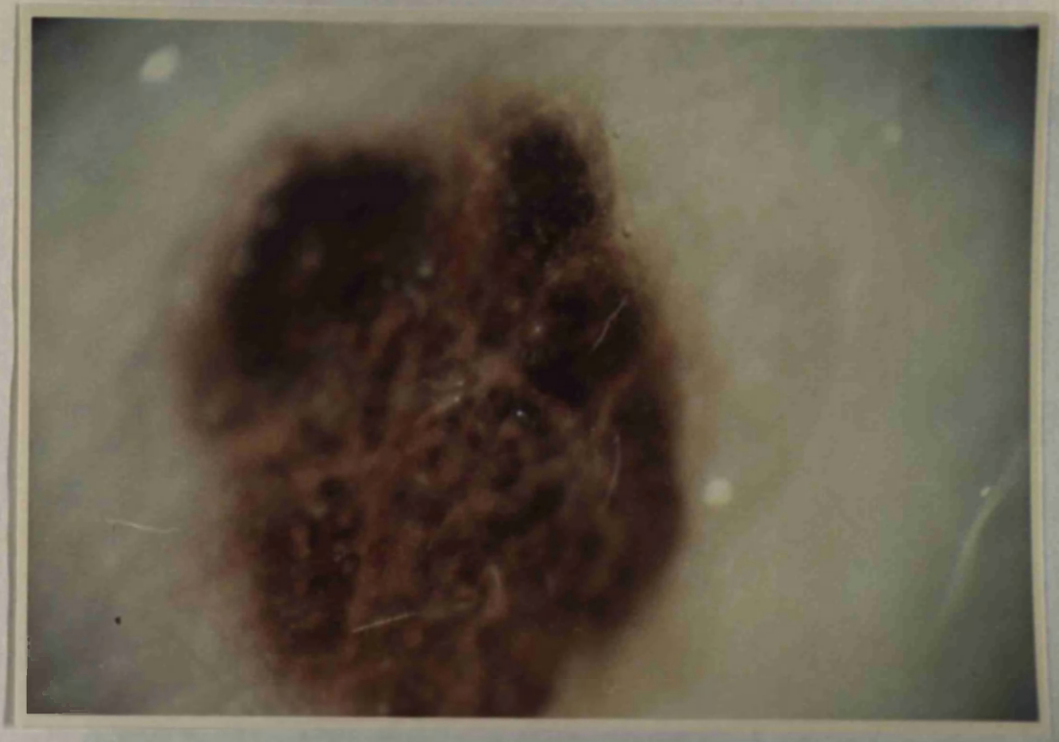

Histology: Compound naevus.

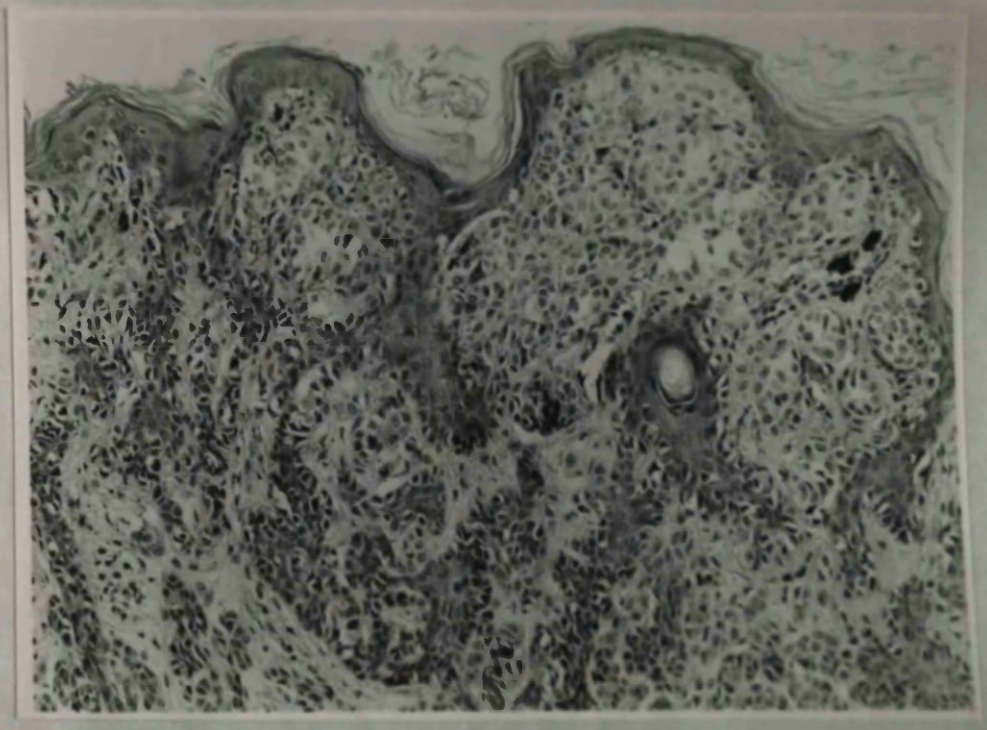

Case 55. Female aged 30 years.

Lesion on upper abdomen present since birth.

Recent enlargement of lesion.

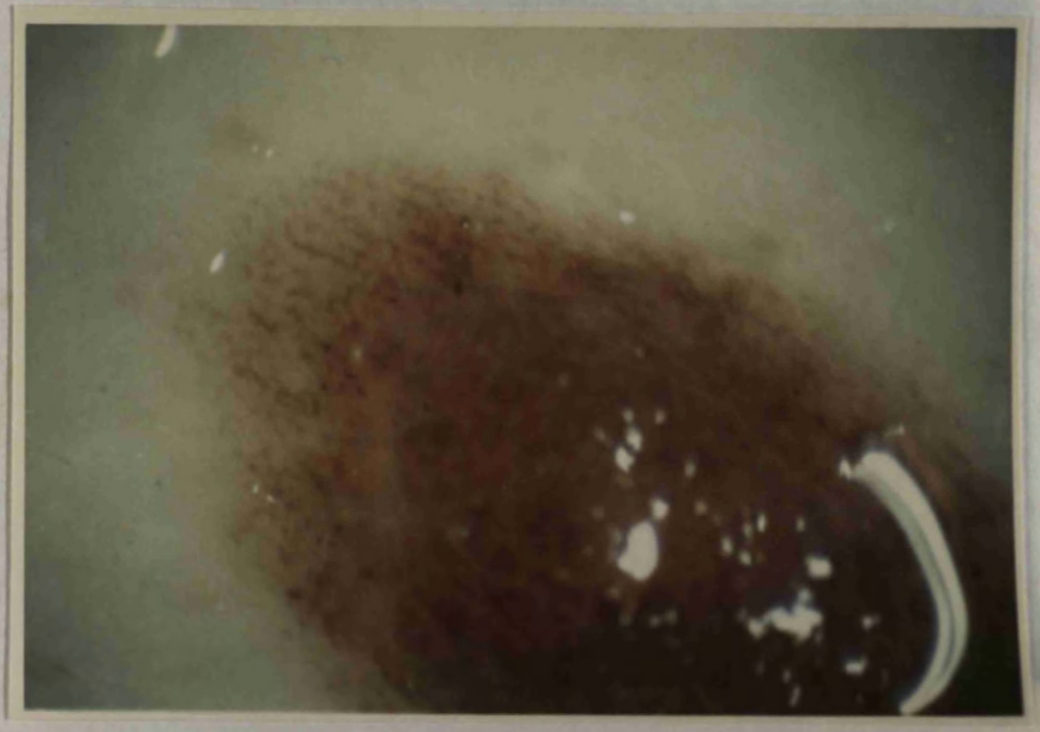

Histology: Compound naevus.



Case 56. (same patient as 55).

Lesion on abdomen at umbilical level present since birth.

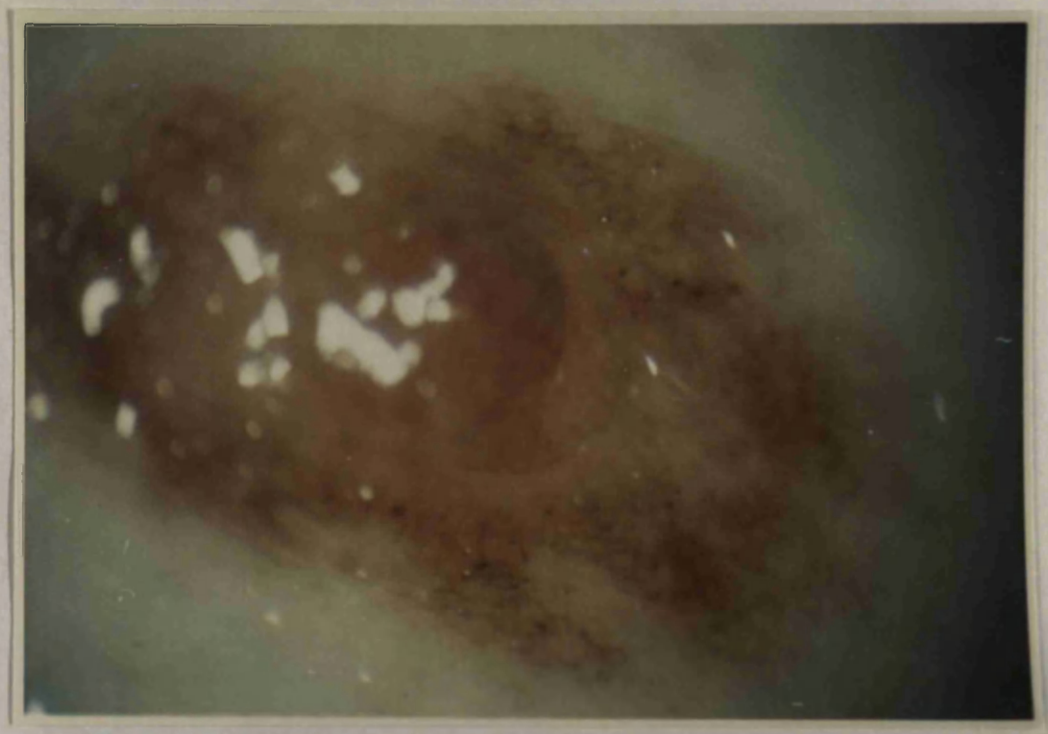

Histology: Compound naevus with active junctional component.

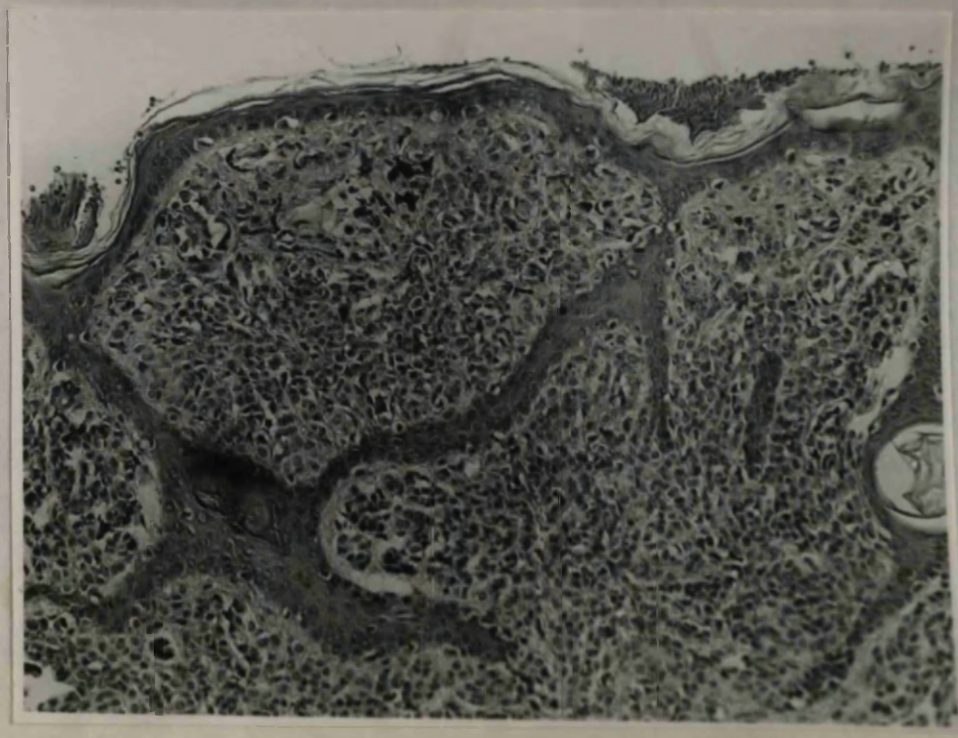

Case 57. Female aged 34 years.

Lesion on left axilla present since birth, recent enlargement and darkening.

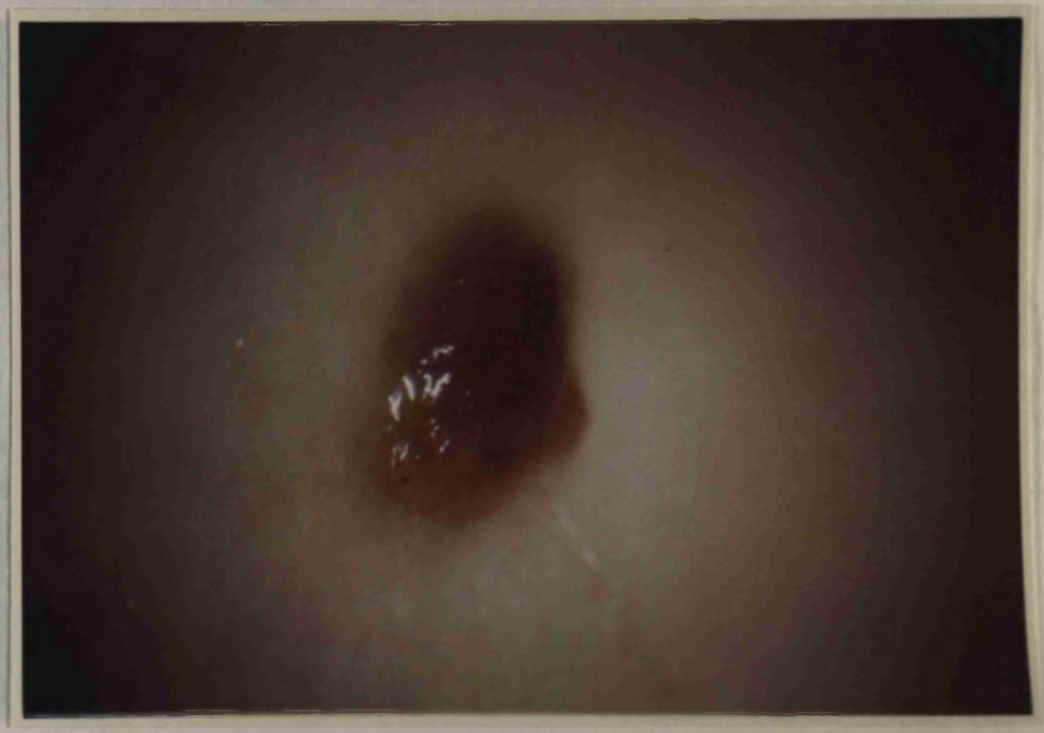

Histology: Compound naevus.

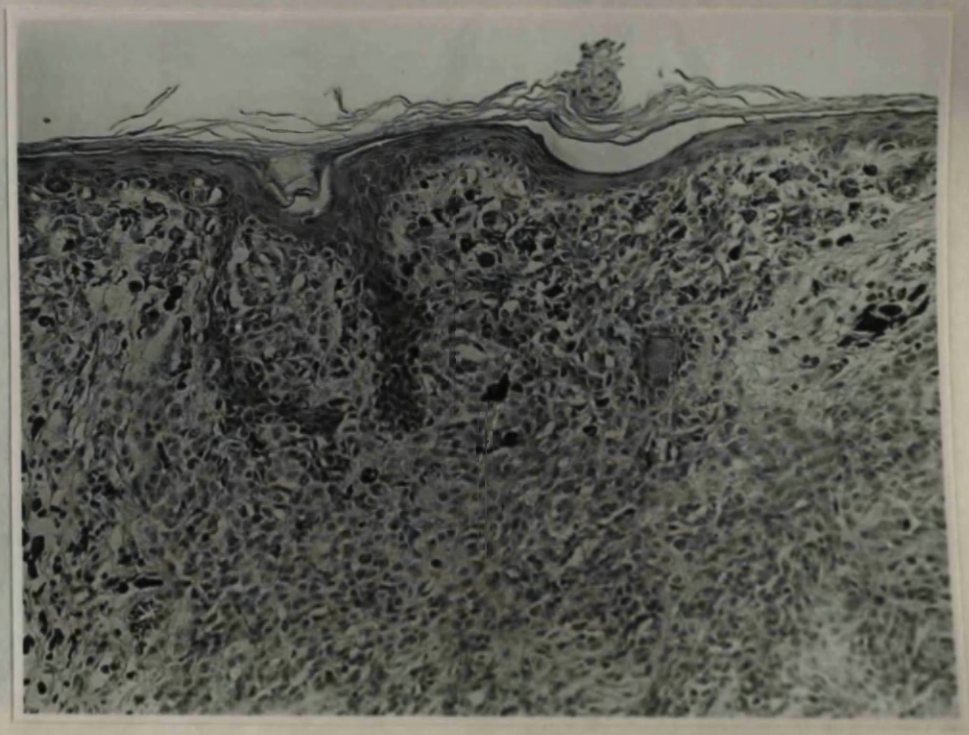

Case 58. (same patient as 57).

Lesion on mid-back first noticed one year before examination.



Histology: Compound naevus with minimal junctional activity.

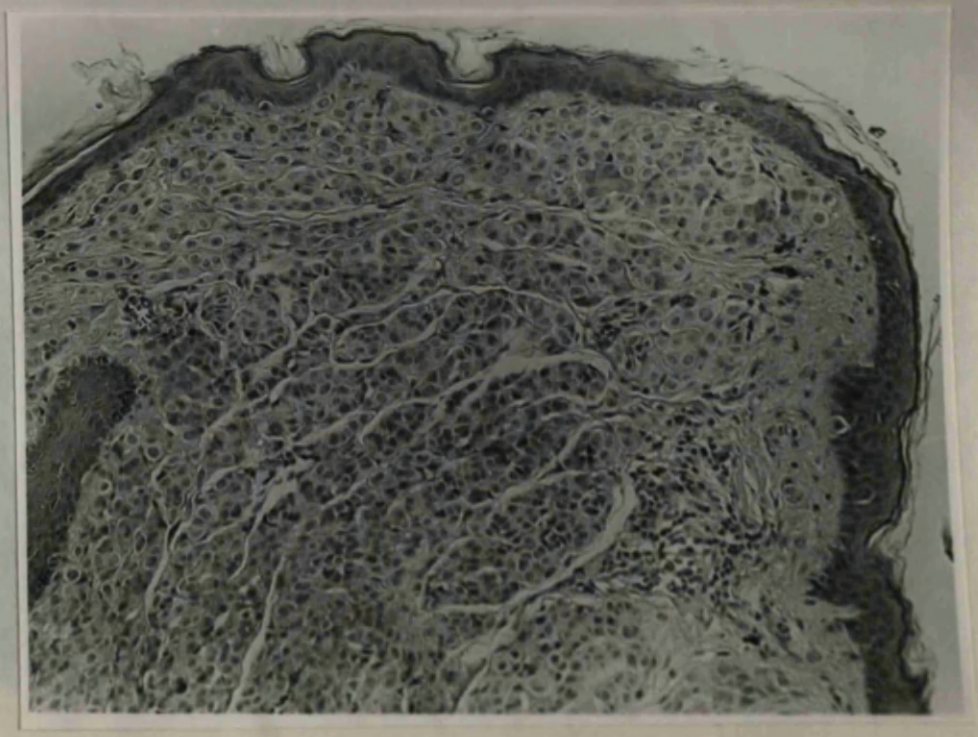

Case 59. (same patient as 57 and 58).

Lesion on right thigh present since birth.



Histology: Compound naevus.

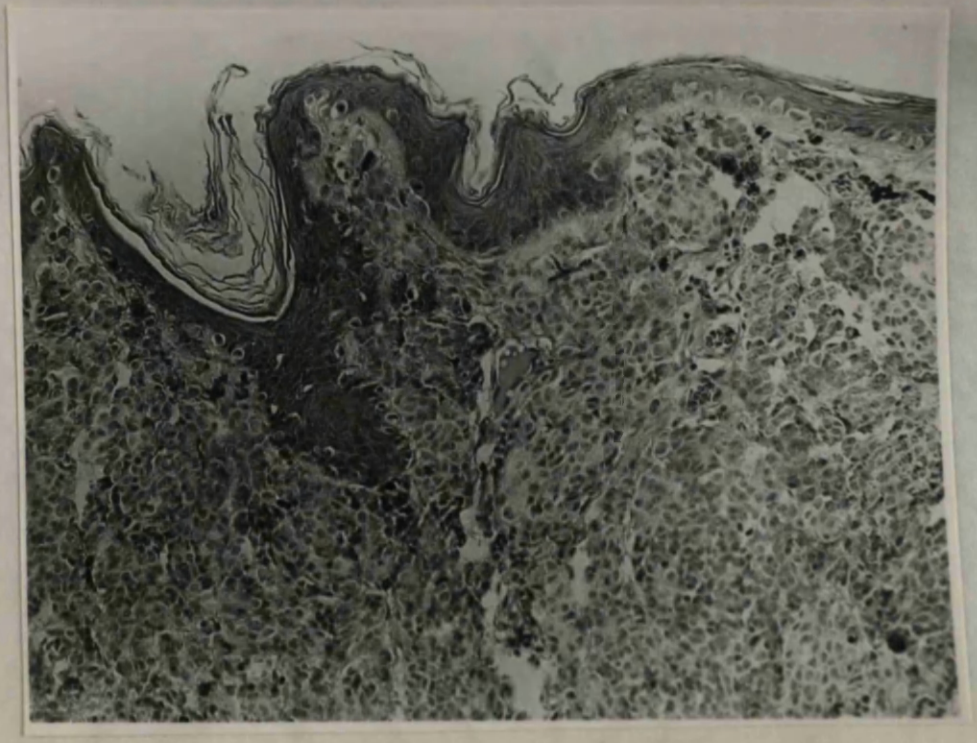

Case 60. Female aged 34 years.

Lesion in right popliteal fossa present since birth.



Histology: Compound naevus.

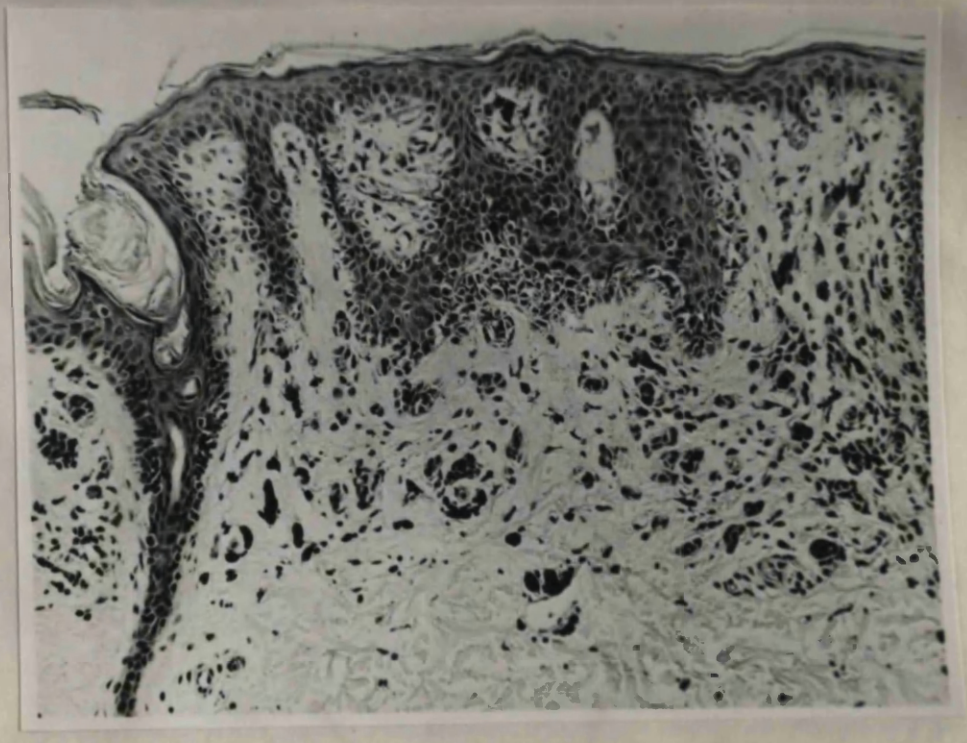

Case 61. (61-66 inclusive are all from the same patient).

Female aged 18 years.

Lesion of right antecubital fossa present since birth.

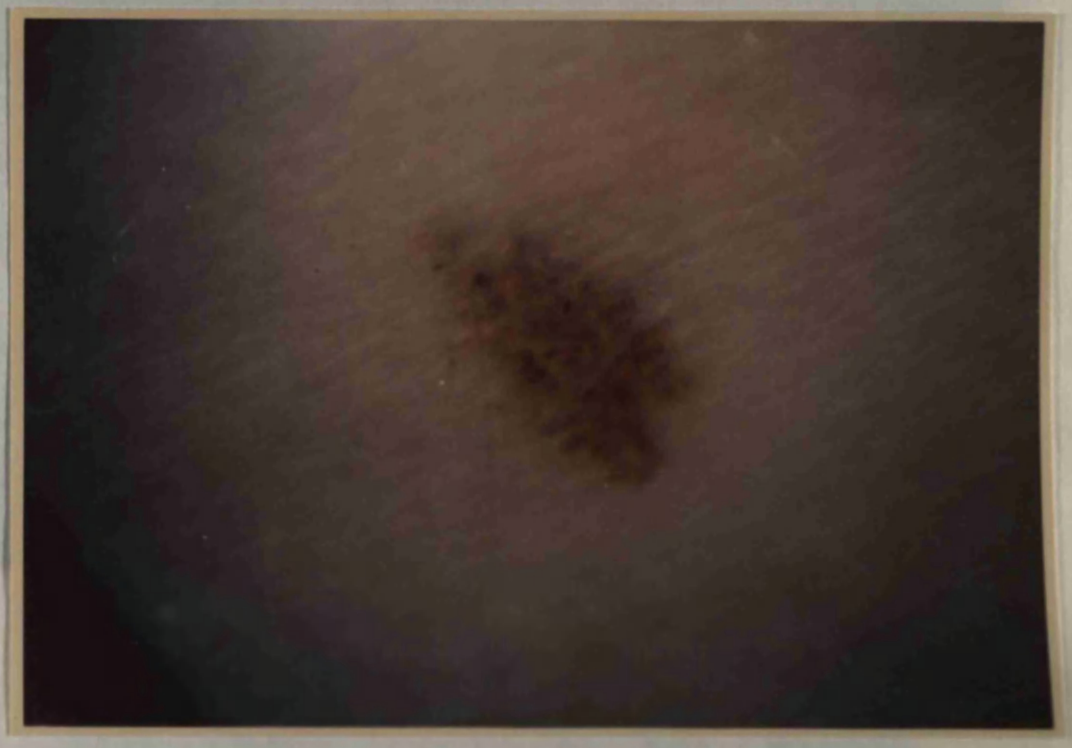

Histology: Compound naevus.

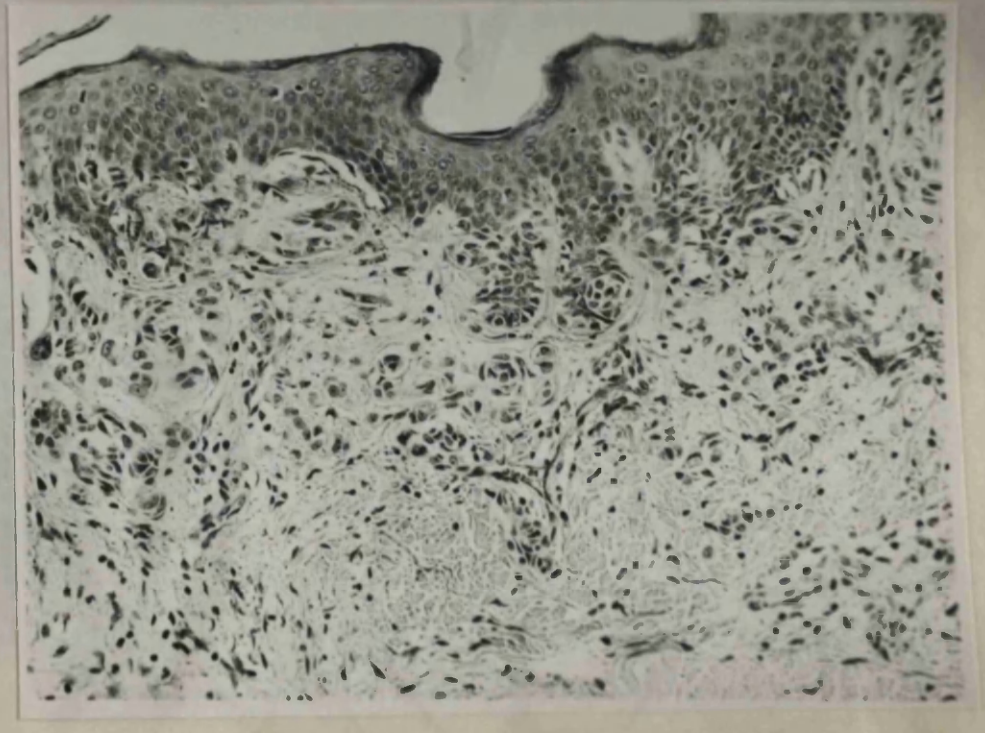

Case 62. Lesion of left iliac fossa, present since birth.



Histology: Compound naevus with large junctional component.

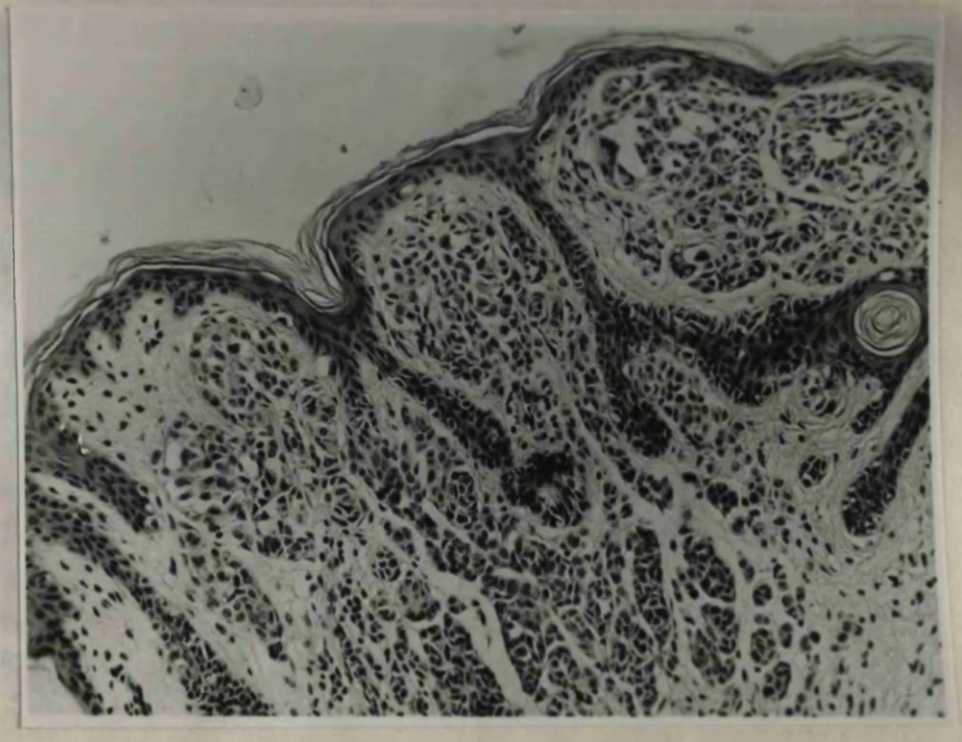

Case 63. Lesion also of left iliac fossa present since birth.



Histology: Compound naevus with large junctional component.



Case 64. Lesion of right iliac fossa present since birth.



Histology: Compound naevus.



Case 65. Lesion on right paraumbilical area present since birth. Traumatised by clothing.

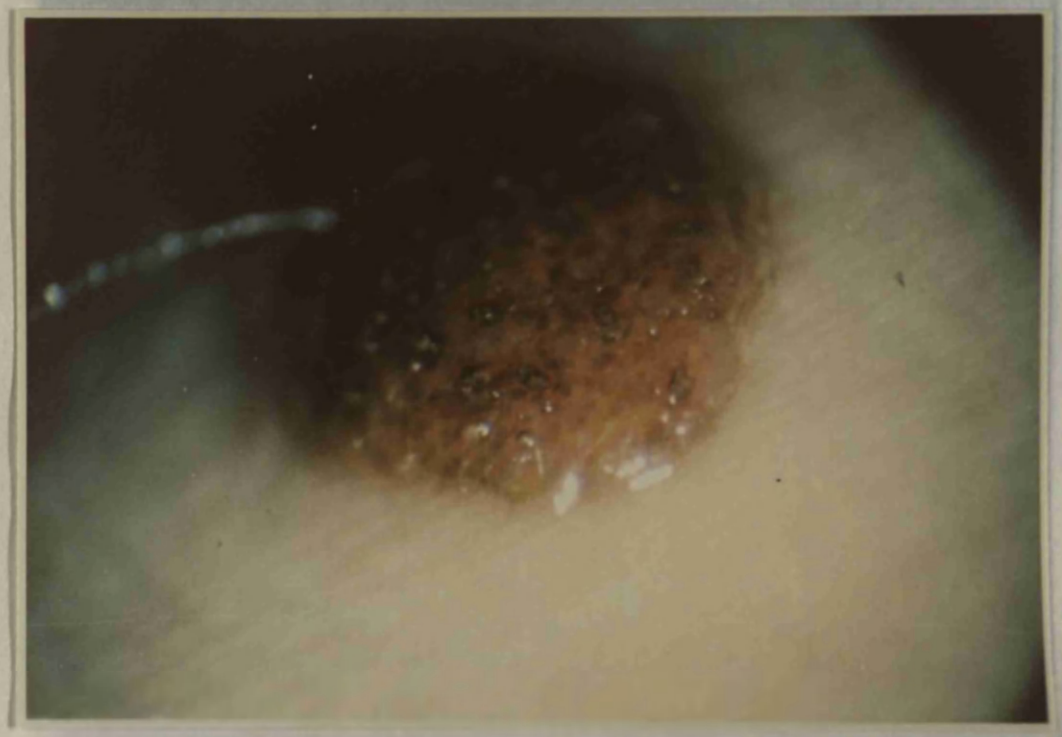

Histology: Compound naevus with large junctional component.



Case 66. Lesion on mid-back present since birth.

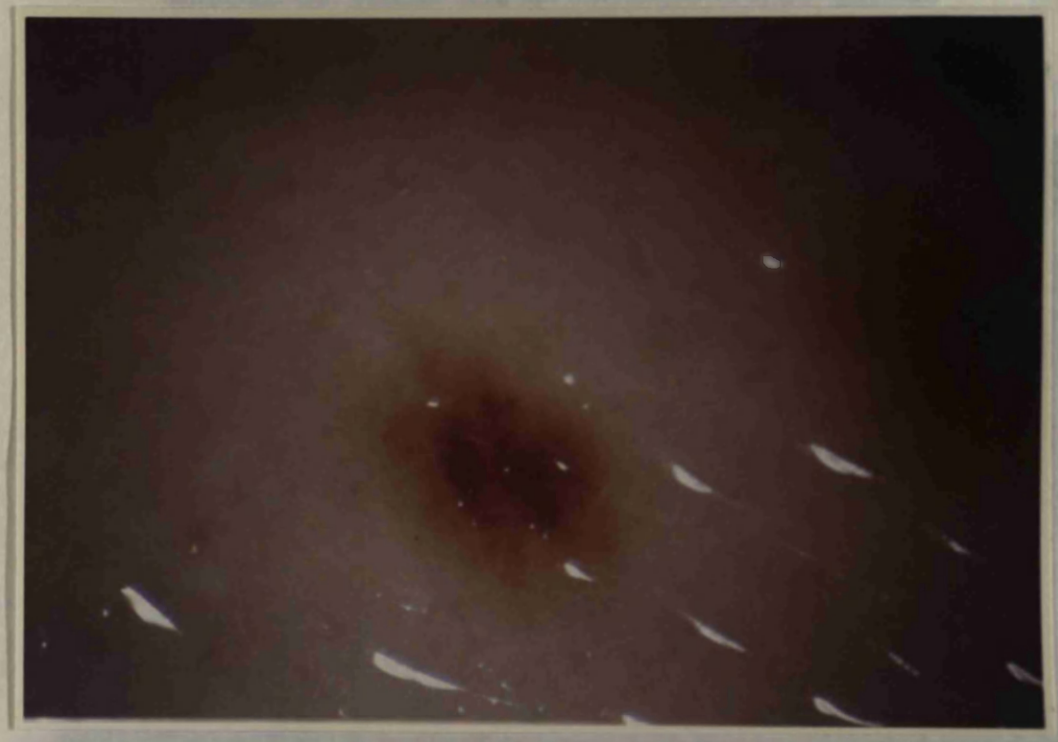

Histology: Compound naevus.

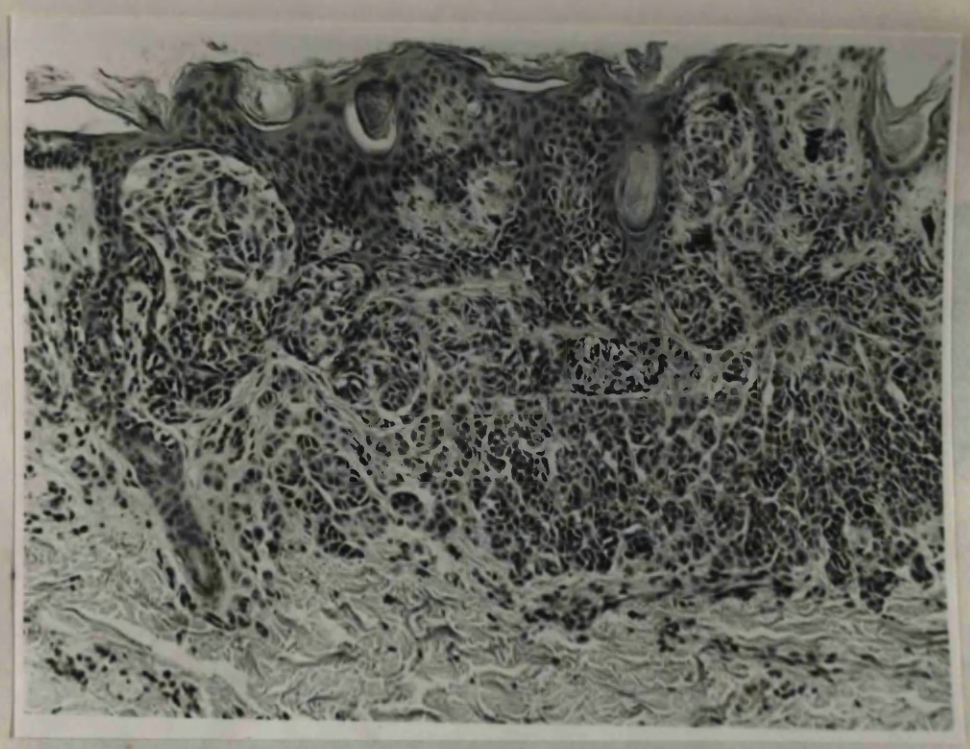

Case 67. Female aged 20 years.

Lesion on right cheek present since birth.

Recent sensation of irritation in lesion.

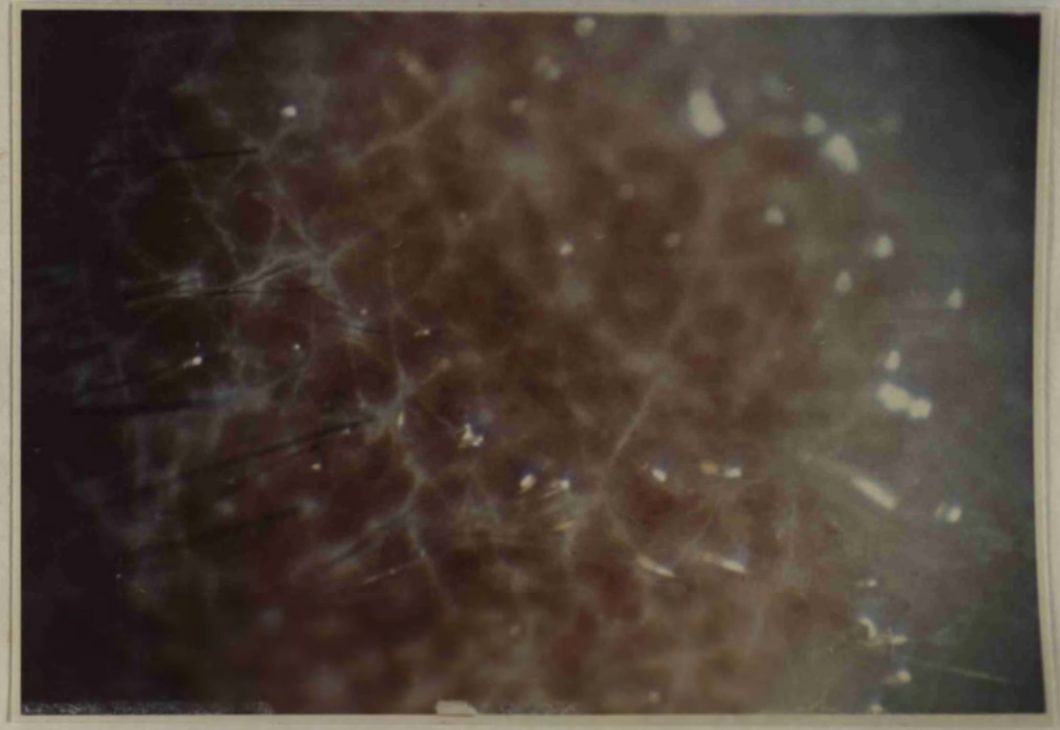

Histology: Compound naevus.

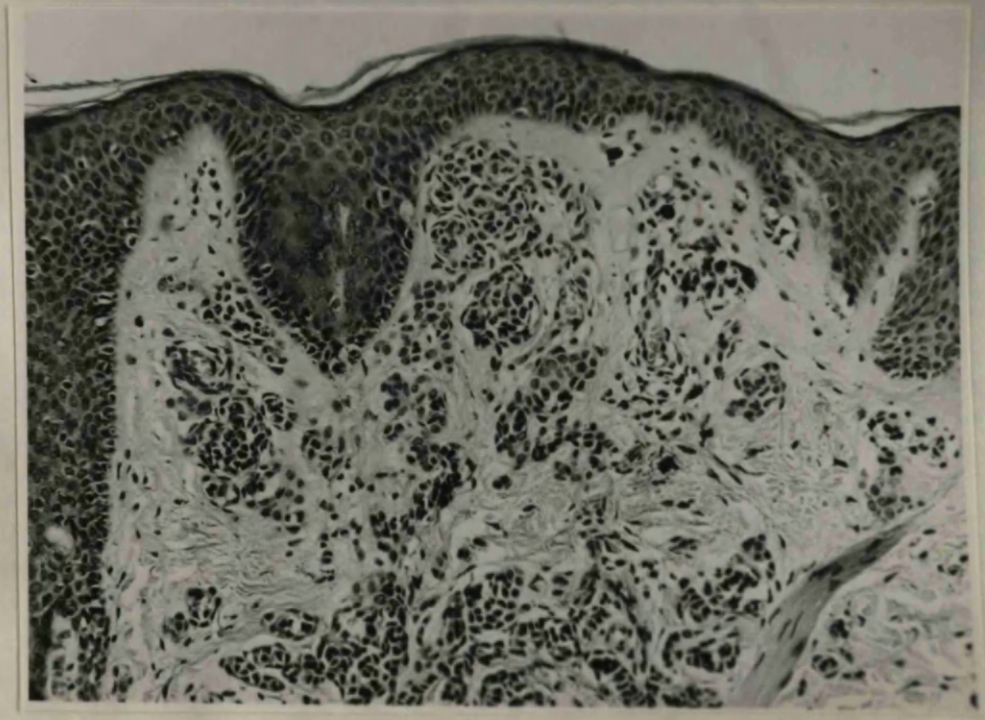

Case 68. Male aged 9 years.

Lesion on right side of neck present since birth.



Histology: Compound naevus.

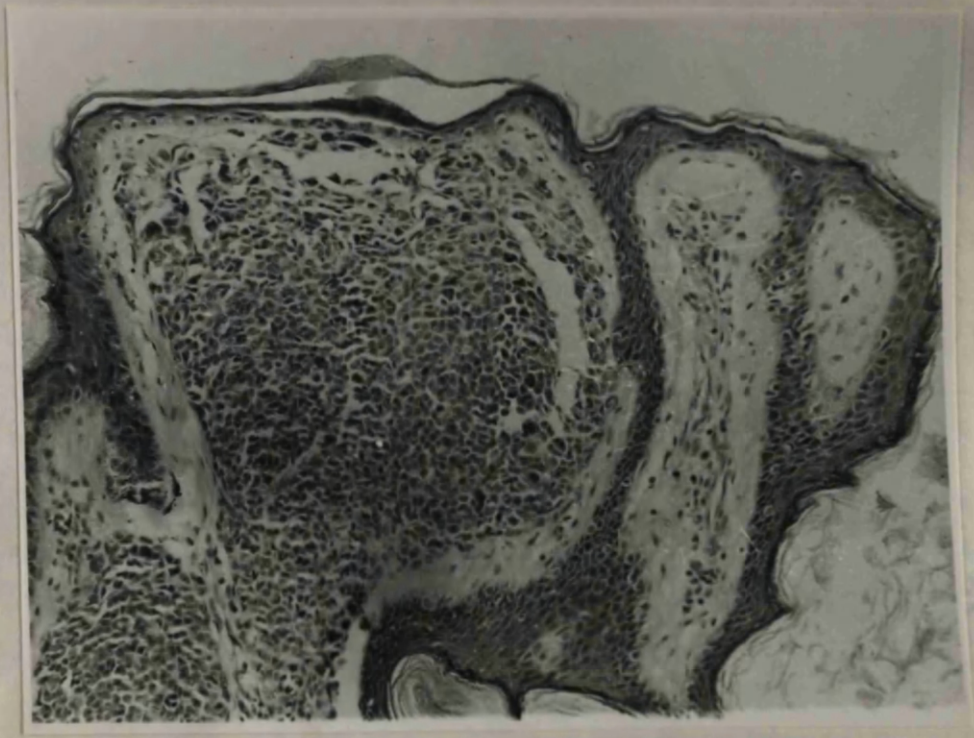

Case 69. Female aged 18 years.

Lesion on right lumbar region present since birth.



Histology: Compound naevus with large junctional component.

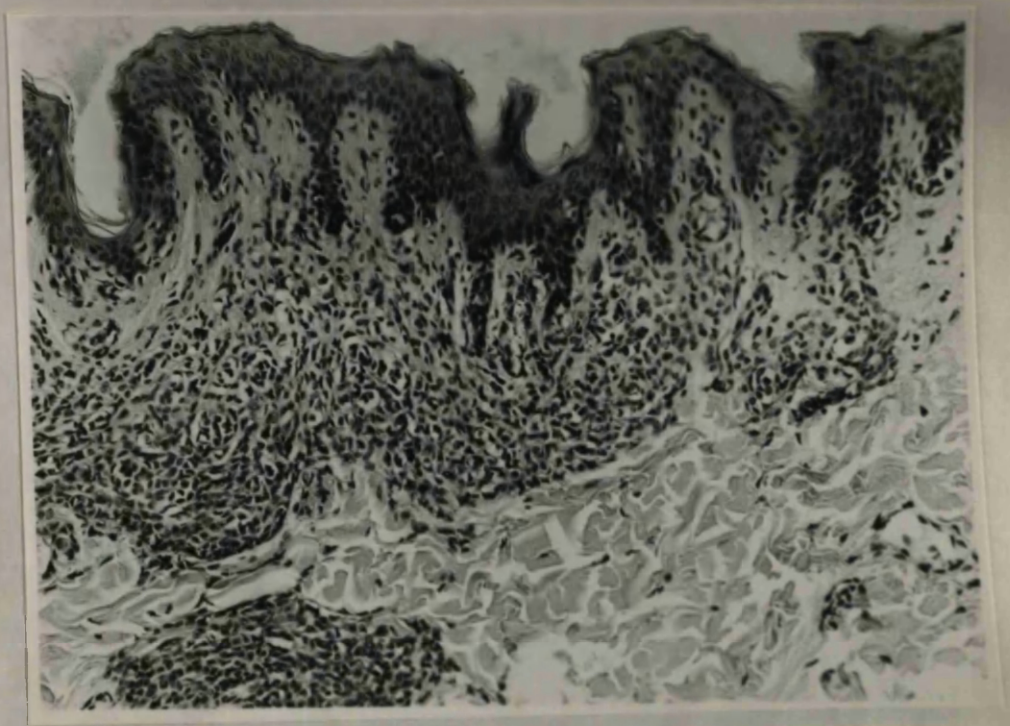

Case 70. Female aged 22 years.

Lesion on right thigh present since birth, recent enlargement.



Histology: Compound naevus.

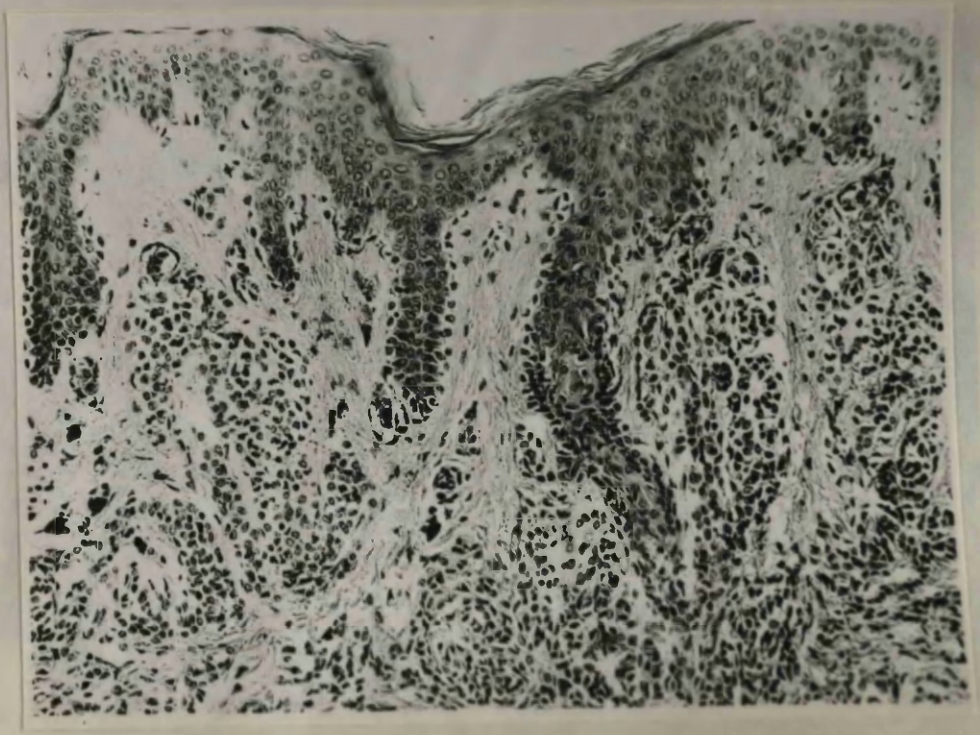

Case 71. Female aged 20 years.

Lesion on right scapular area present since birth.

History of bleeding shortly before examination.

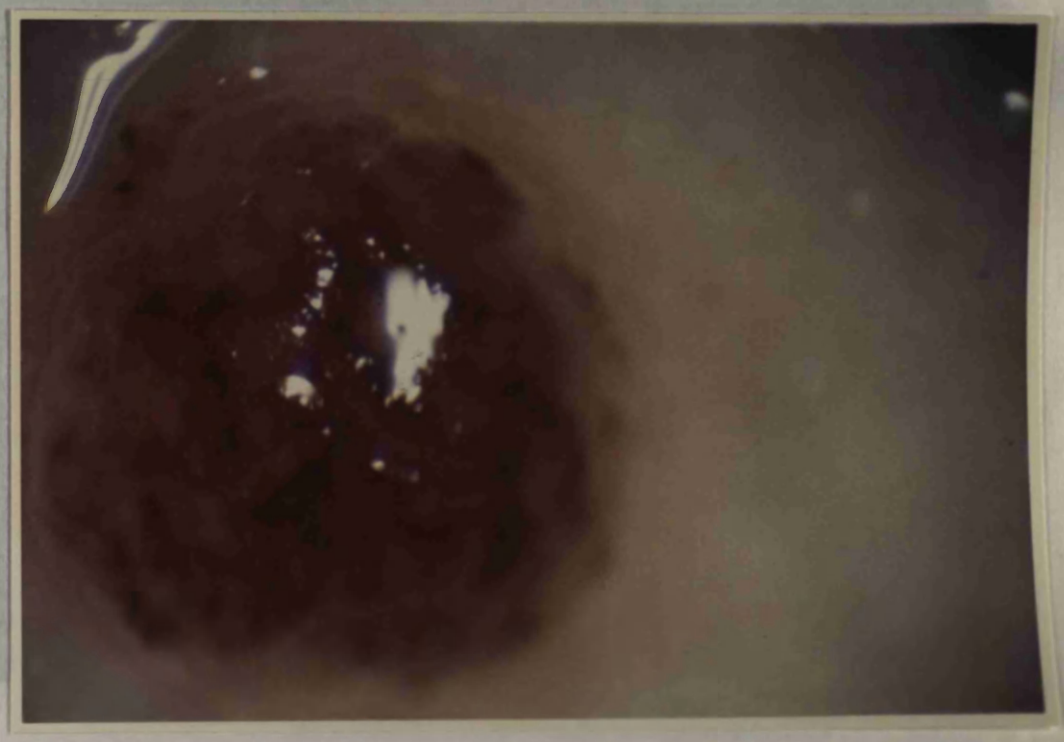

Histology: Compound naevus with marked junctional component.

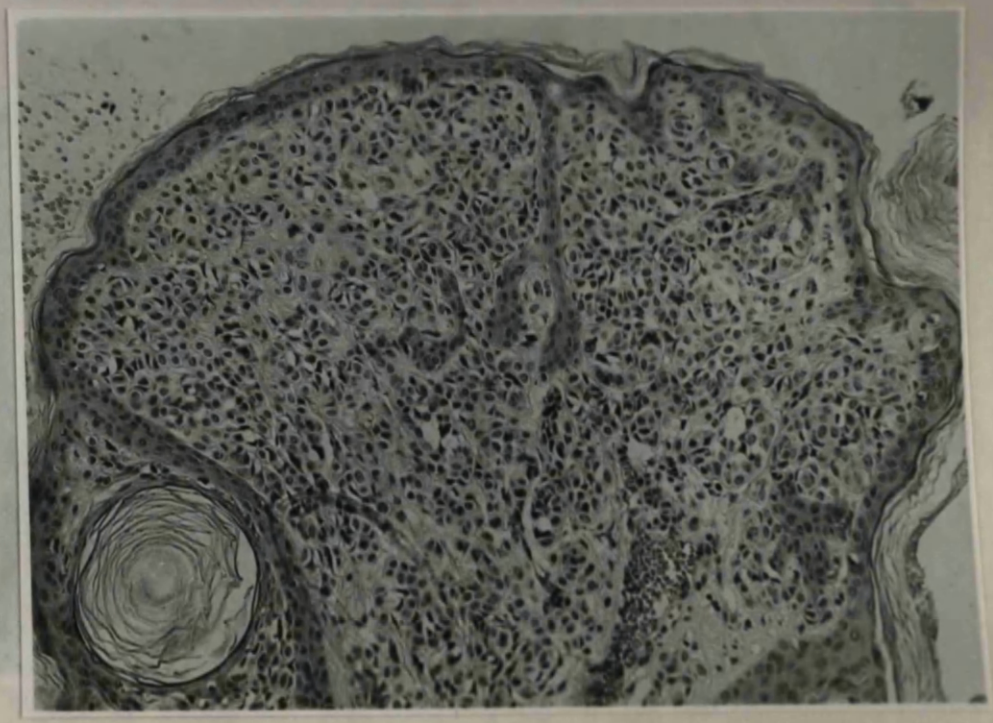

Case 72. (same patient as 71).

Lesion on centre back area present since birth.

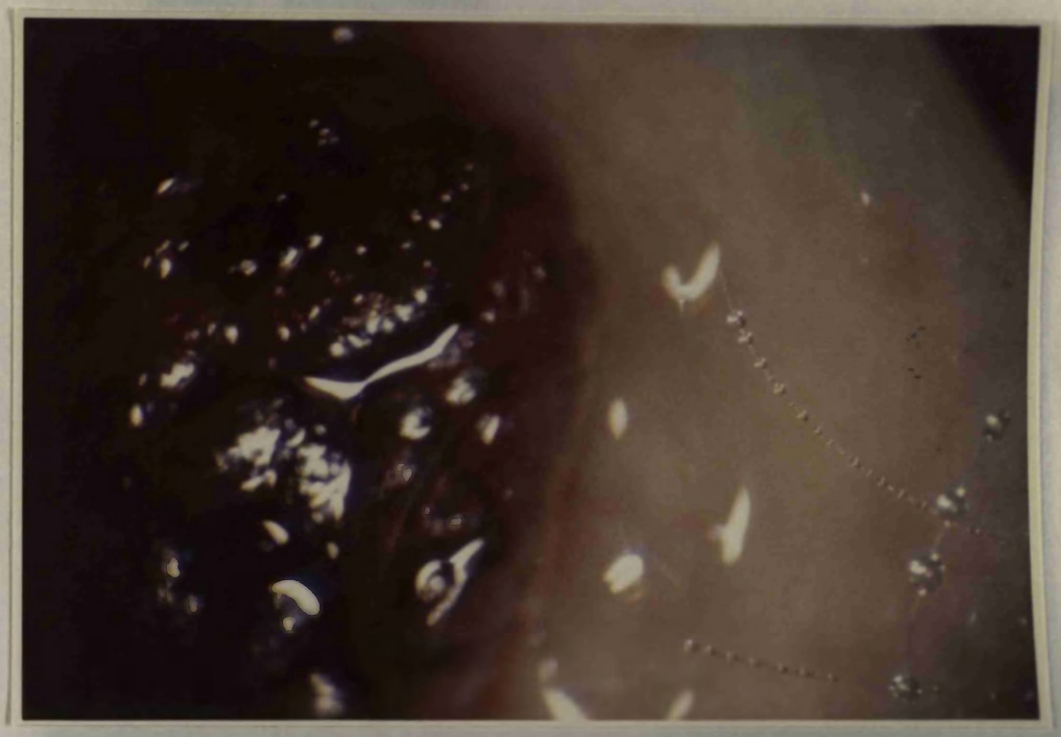

Histology: Compound naevus.

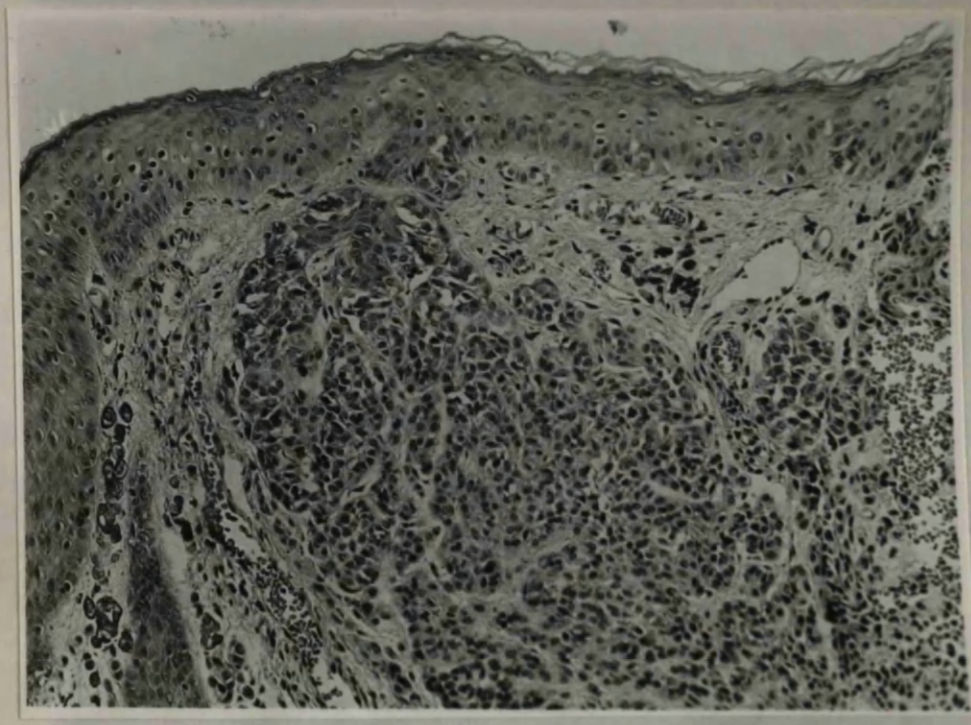

Case 73. Female aged 28 years.

Lesion on left lumbar area present since birth.

Recent enlargement.



Histology: Compound naevus.

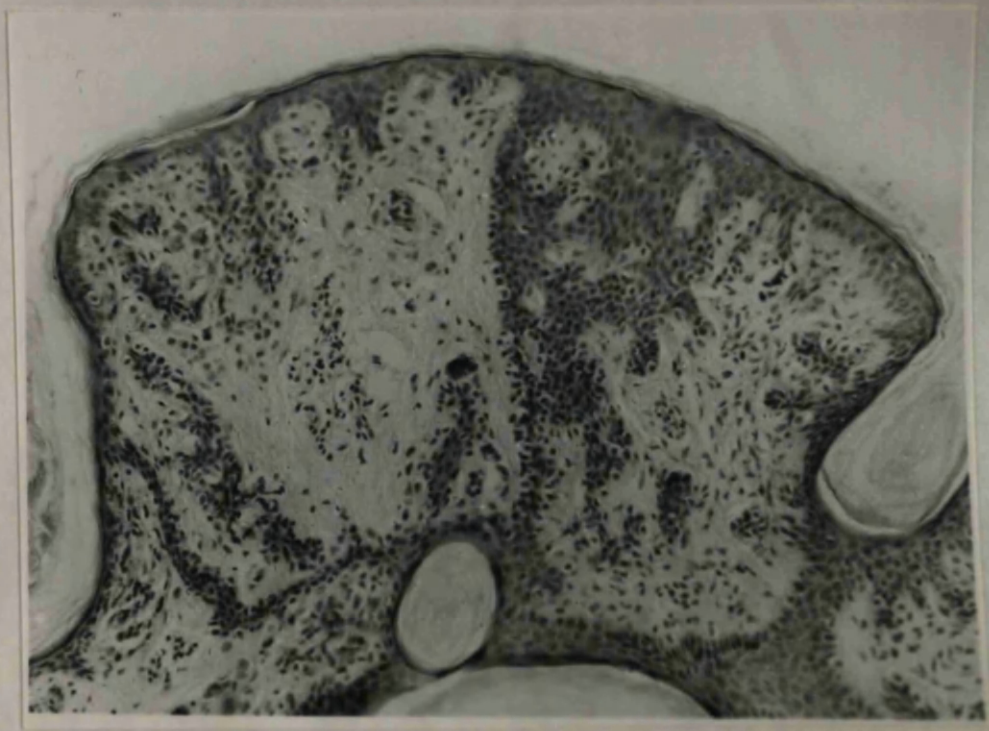

Case 74. Female aged 9 years.

Lesion on anterior chest wall present since birth.

History of recent enlargement.



Histology: Compound naevus with large junctional component.

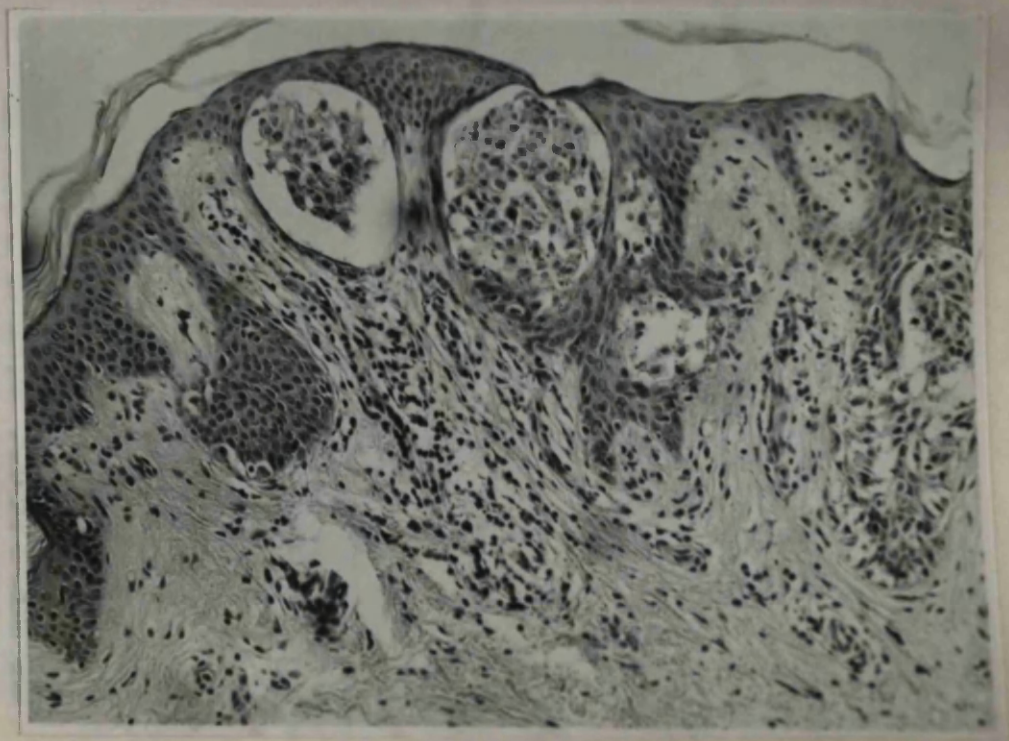

Case 75. (same patient as 74).

Lesion on skin of left iliac fossa present since birth.

Recent enlargement.

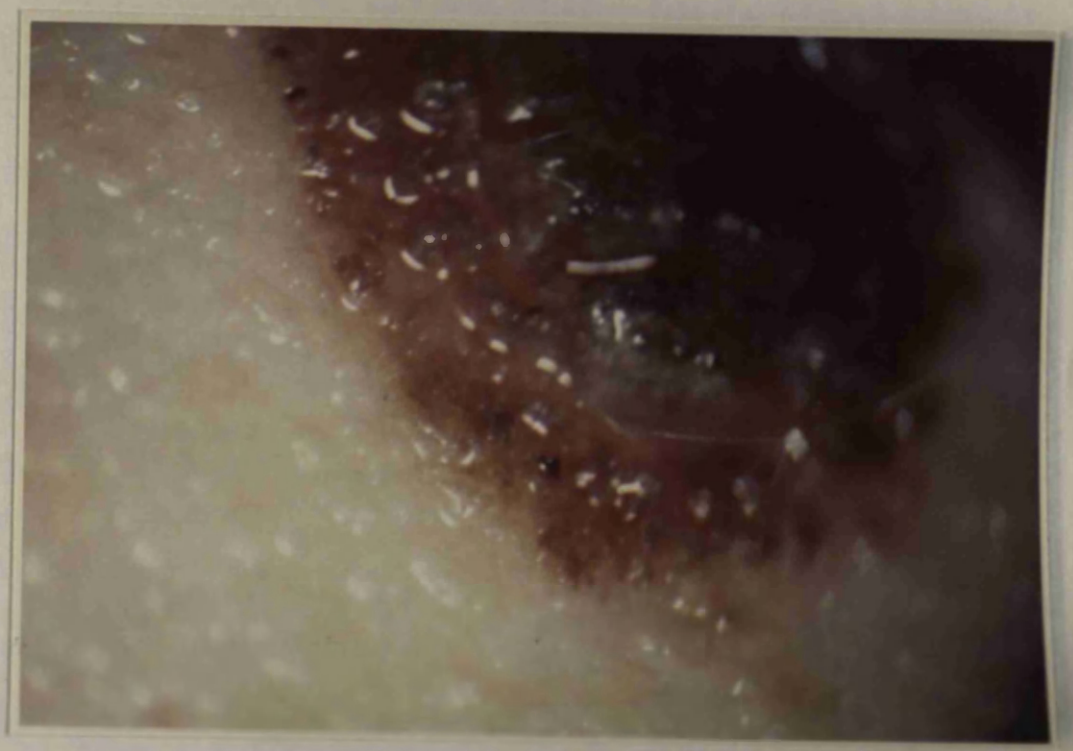

Histology: Compound naevus with large junctional component.

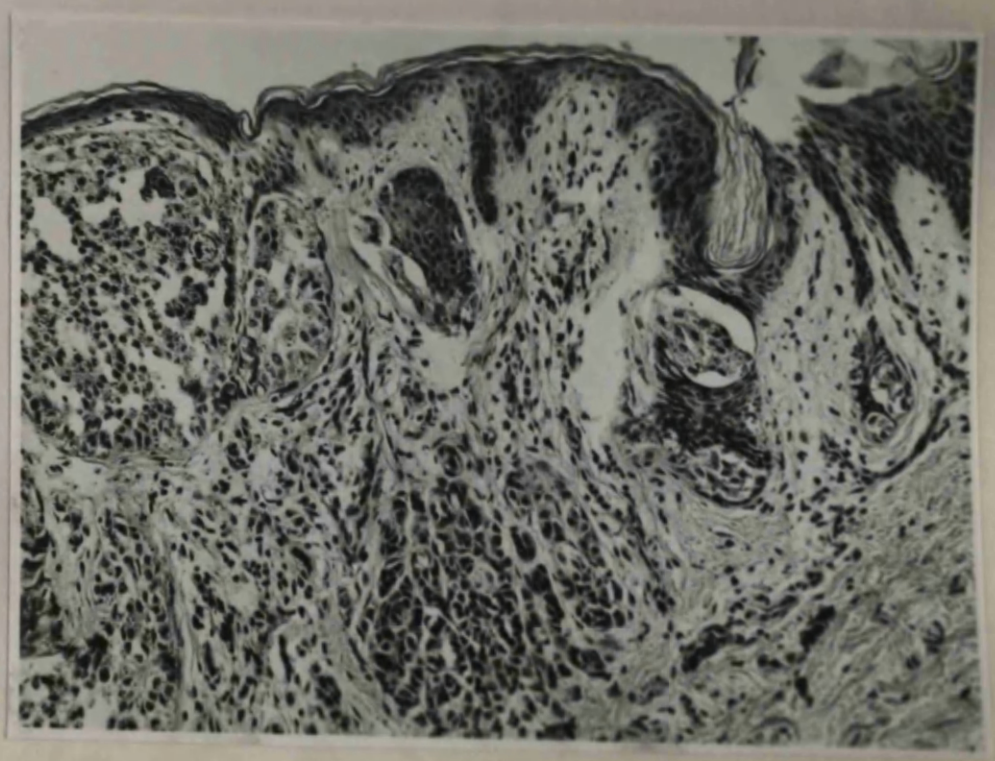

Case 76. Female aged 15 years.

Lesion on anterior chest wall present since birth.

History of recent enlargement and bleeding.

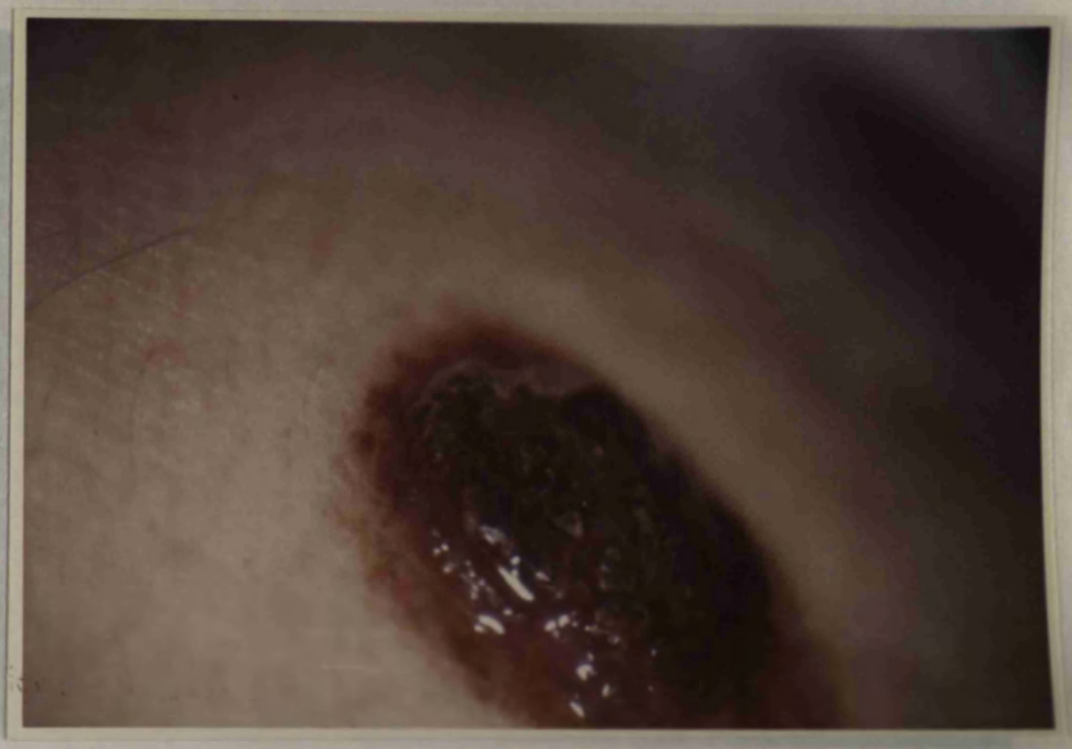

Histology: Compound naevus.



Case 77. Female aged 31 years.

Lesion on left breast present for at least 10 years.

Recent enlargement. Patient 3 months pregnant.

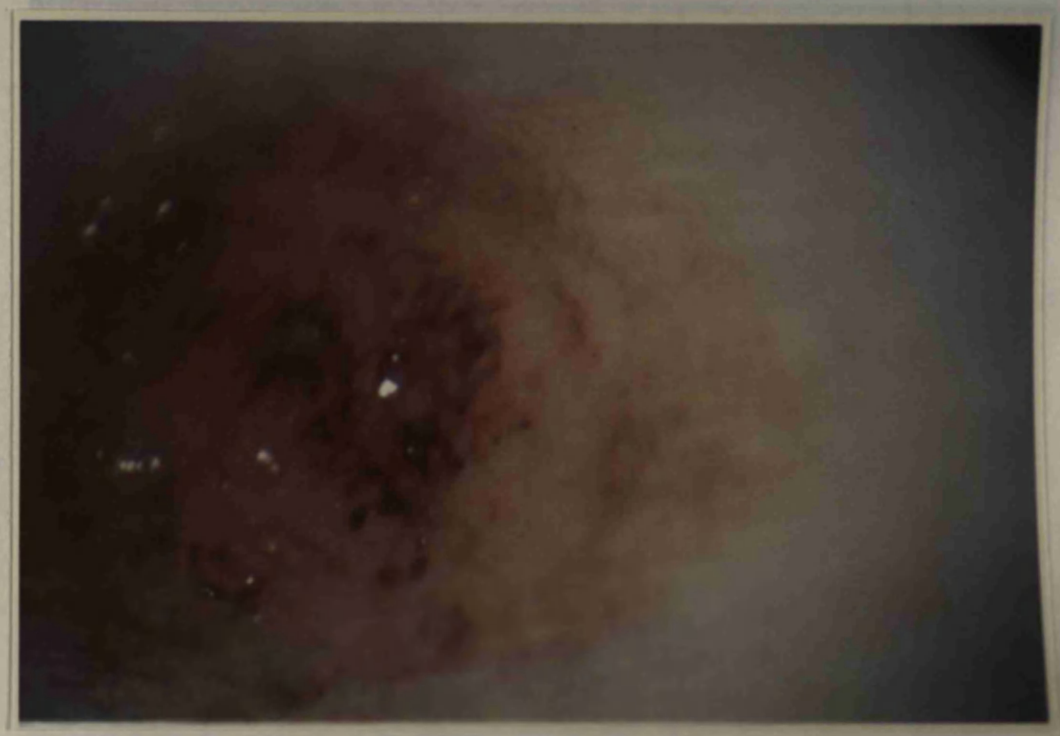

Histology: Compound naevus.

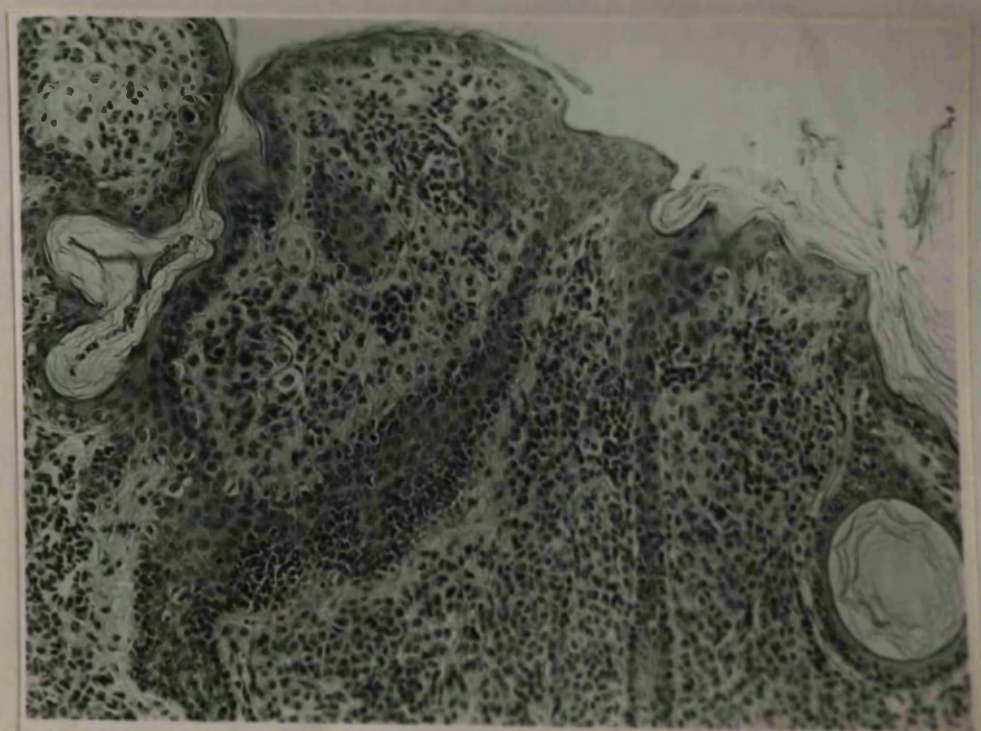

Case 78. Female aged 16 years.

Lesion on back present since birth.

History of recent bleeding.

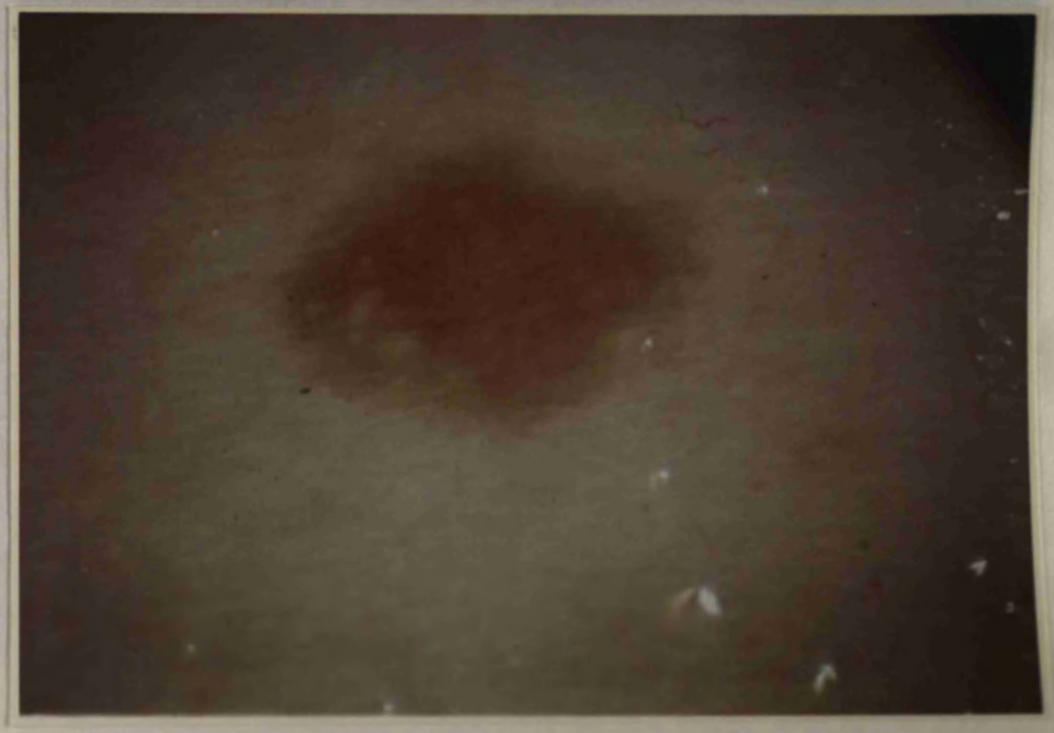

Histology: Compound naevus.

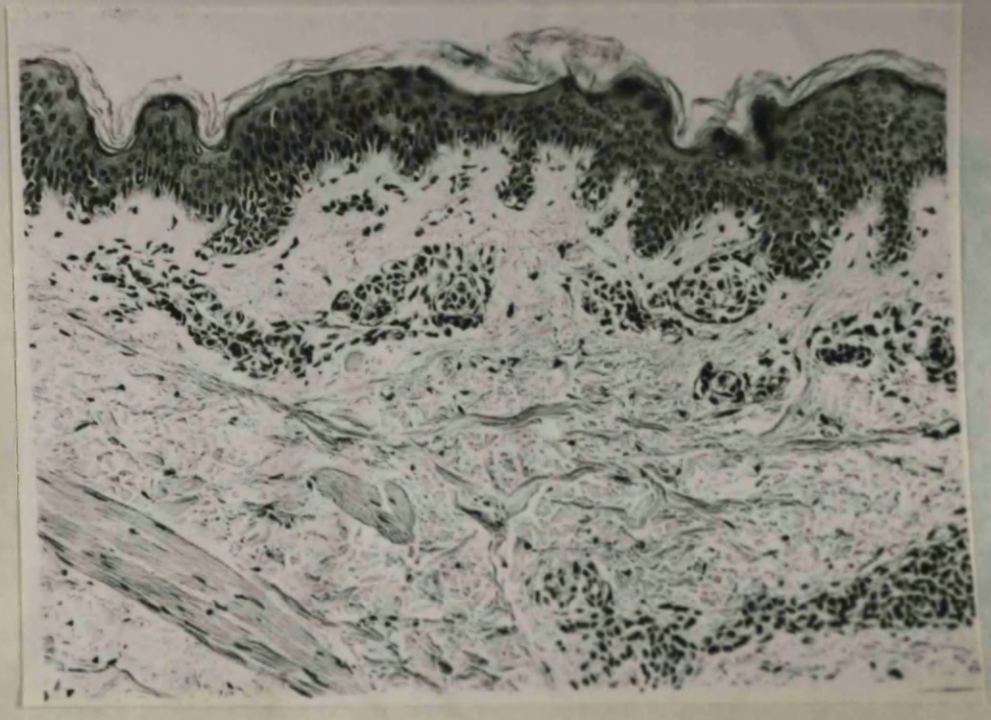

Case 79. (same patient as 78).

Lesion on right upper arm present since birth.



Histology: Compound naevus.

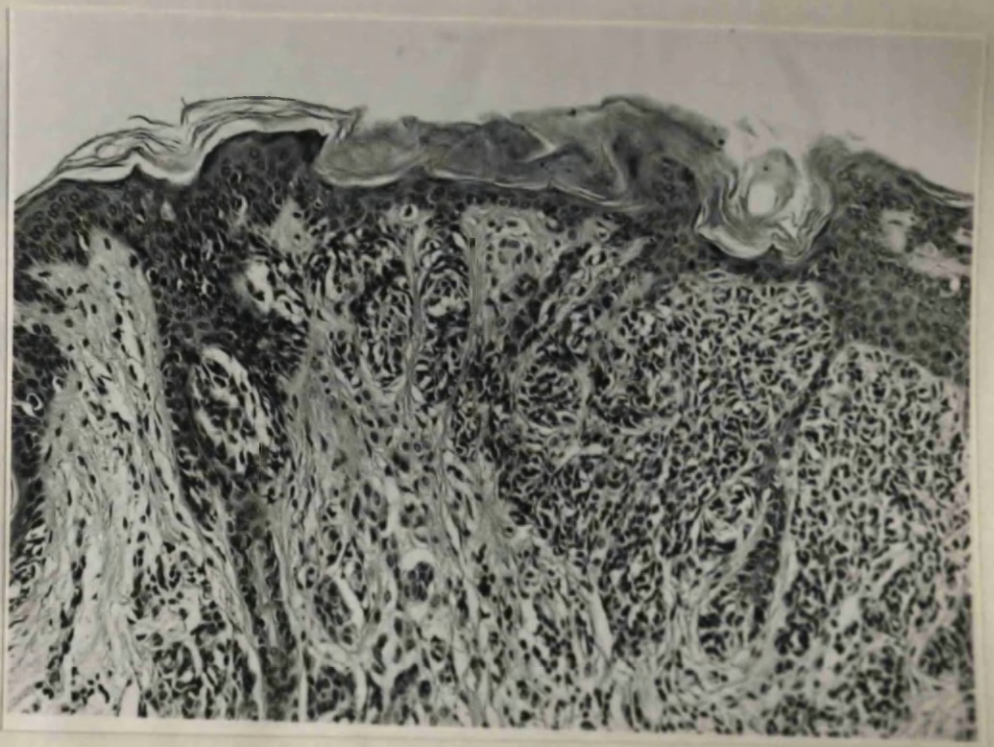

Case 80. (also same patient as 78).

Lesion on left deltoid area present since birth.

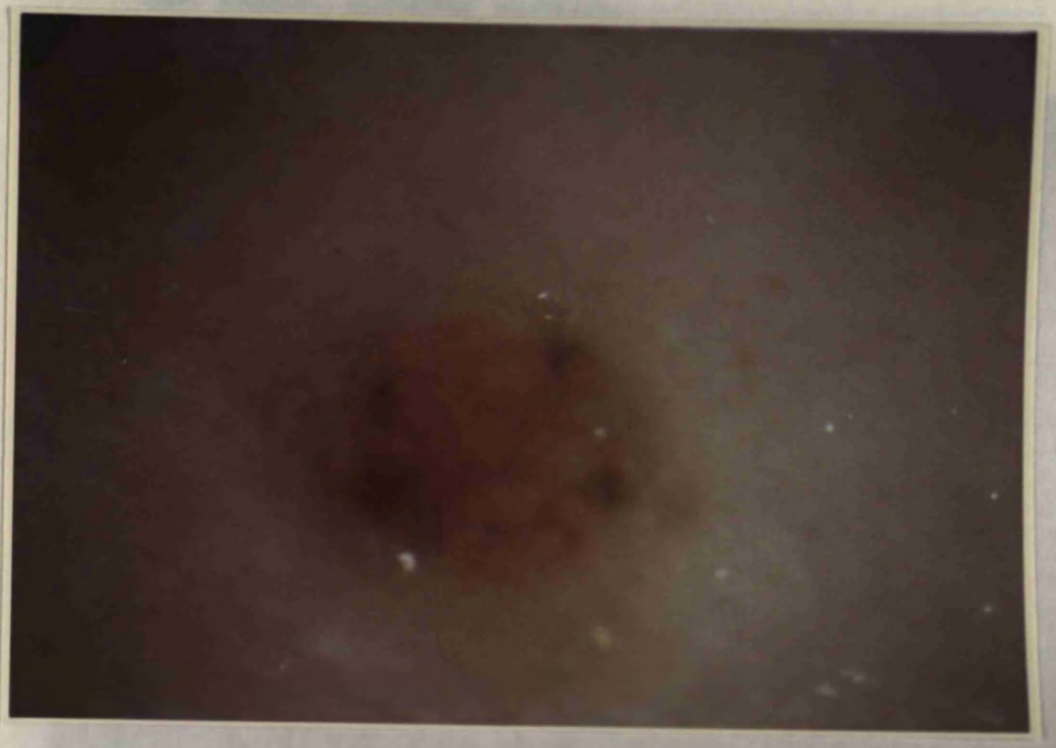

Histology: Compound naevus.

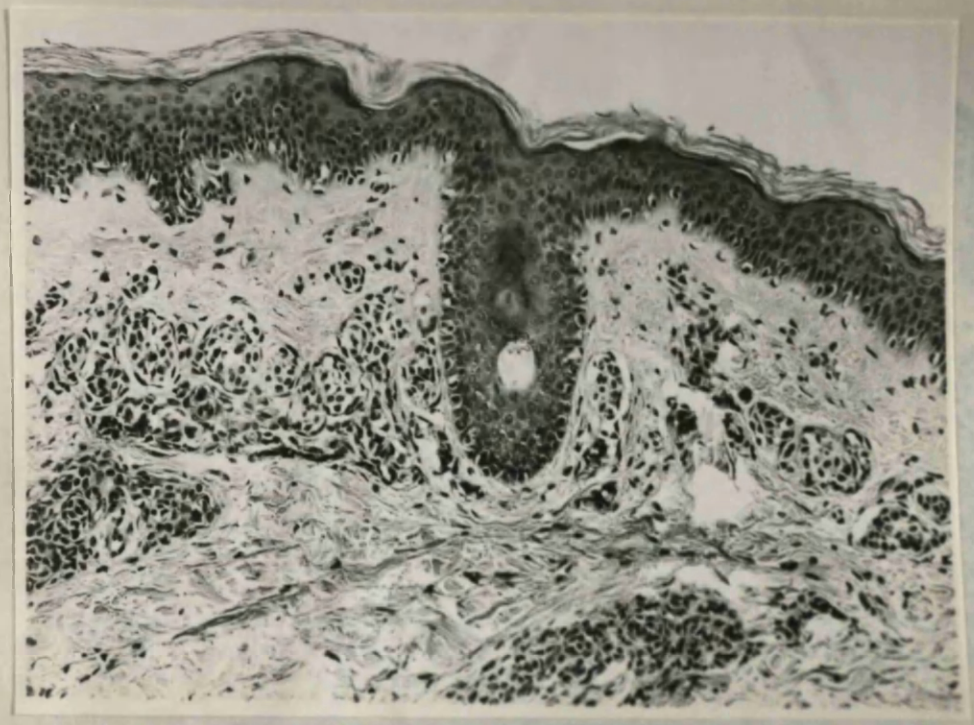

Case 81. Female aged 18 years.

Lesion on right lower eyelid, present for previous two years, growing slowly.

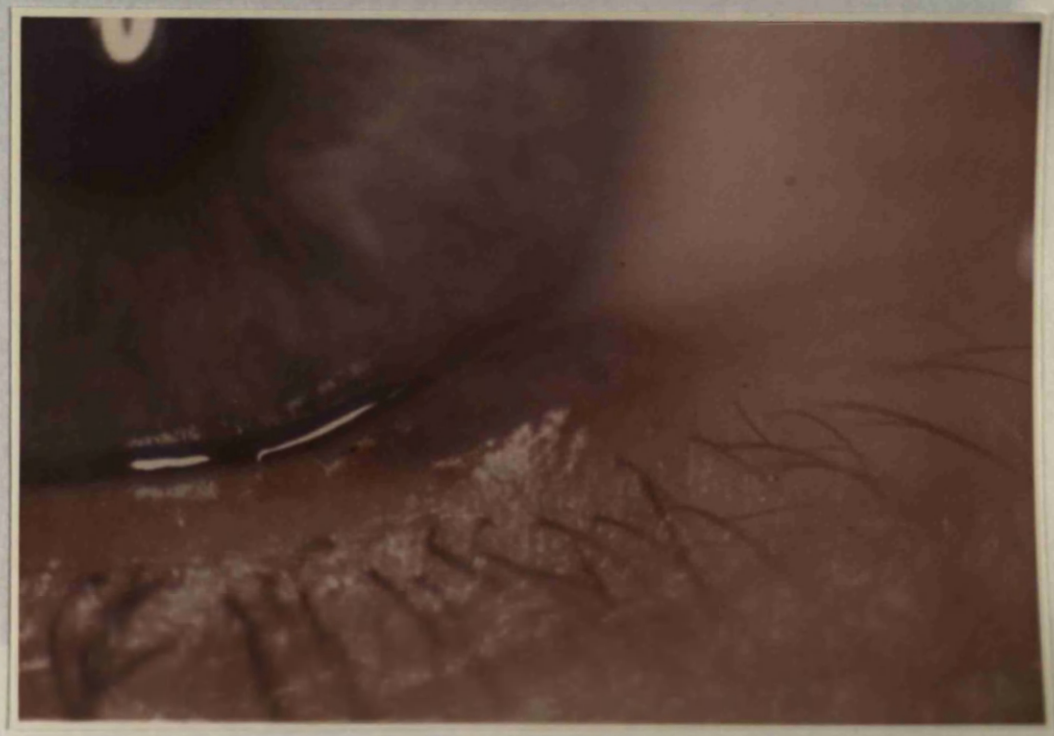

Histology: Compound naevus.

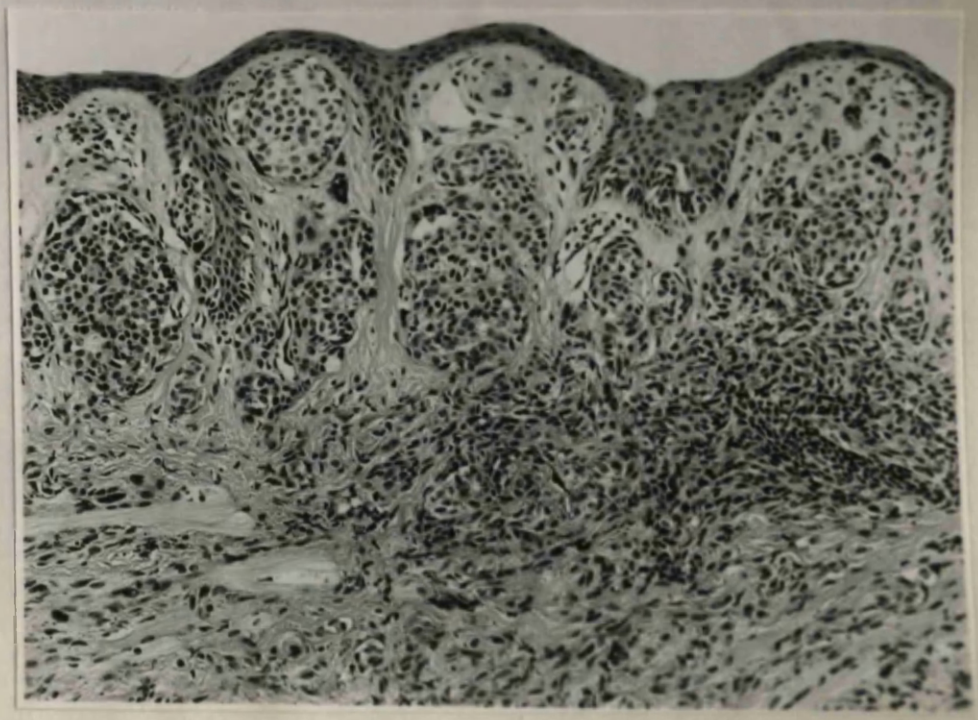

Case 82. Female aged 14 years.

Lesion in right naso-labial fold.

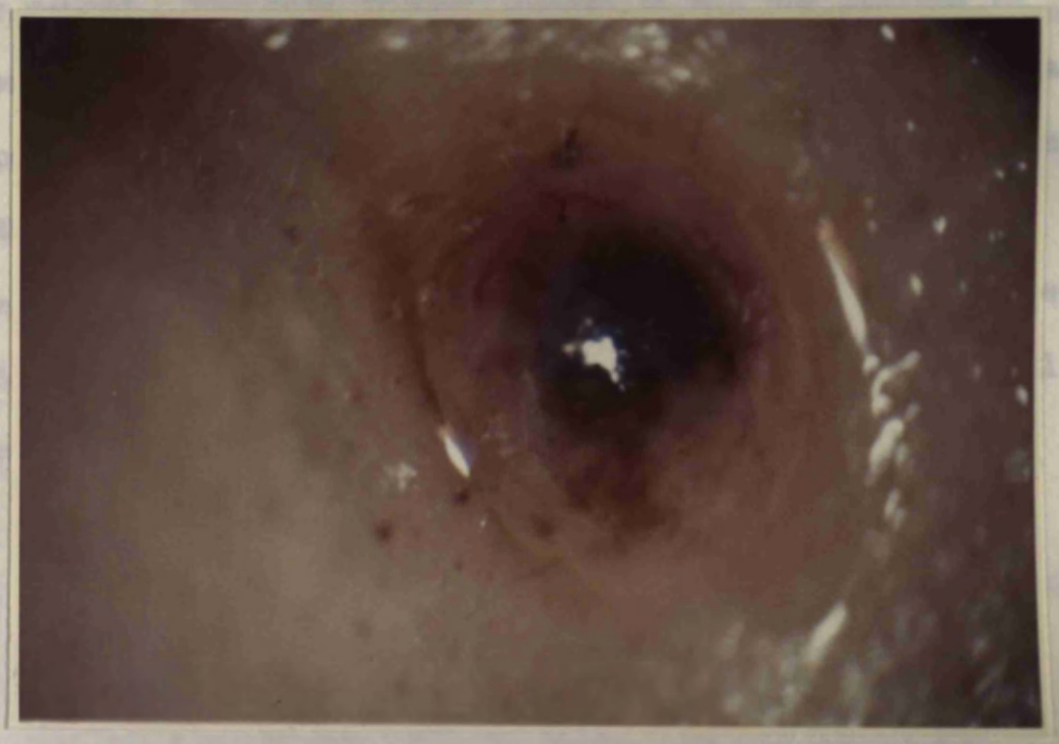

Histology: Compound naevus with very little junctional activity.

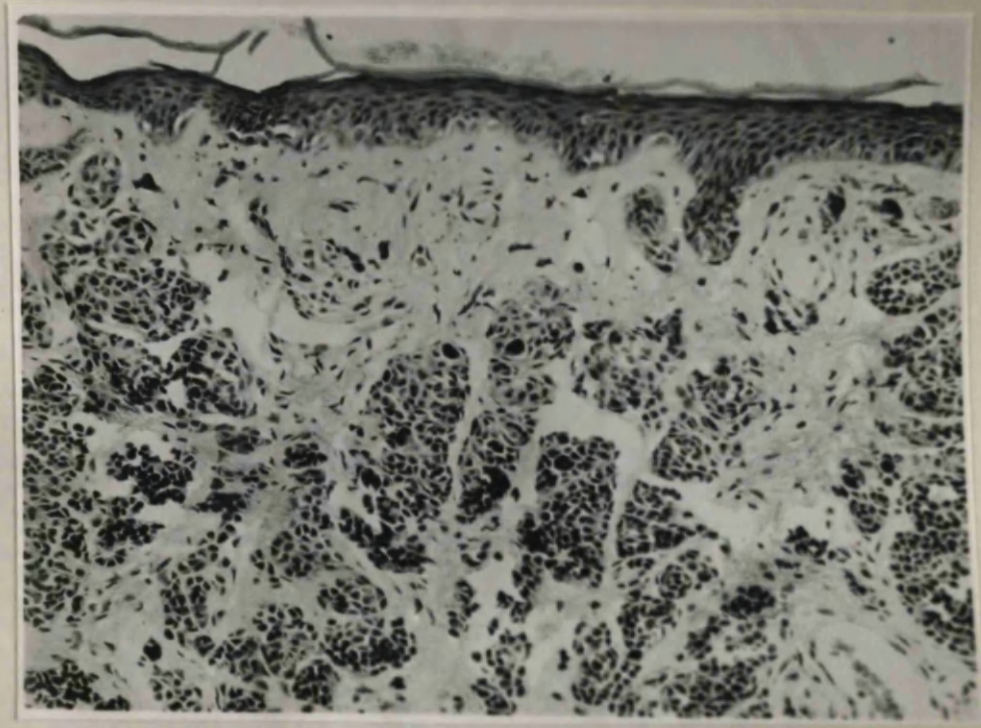

General comments on the compound naevi

The macroscopic appearance of the 63 lesions shown here are extremely varied. The only feature common to all the lesions is the presence of irregular dark brown pigment, found generally on a regular pale brown pigmented background. The intensity of pigmentation of the lesion is not directly proportional either to the junctional or the intradermal component of the lesion when examined histologically. When the lesion is lightly pigmented, its lateral margin can be difficult to define, although this is not the case with the more deeply pigmented lesions.

An additional factor present in cases 20, 27, 28. 29, 37, 39, 51, 55, 56, 69, 73 and 77 is the presence on the lesion of the spider's web pigment distribution pattern which was also seen on three of the junctional naevi.

The Malignant Melanomata

Case 83. Male aged 50 years.

Lesion on left side of abdomen present for six years.

History of steady growth, no ulceration.

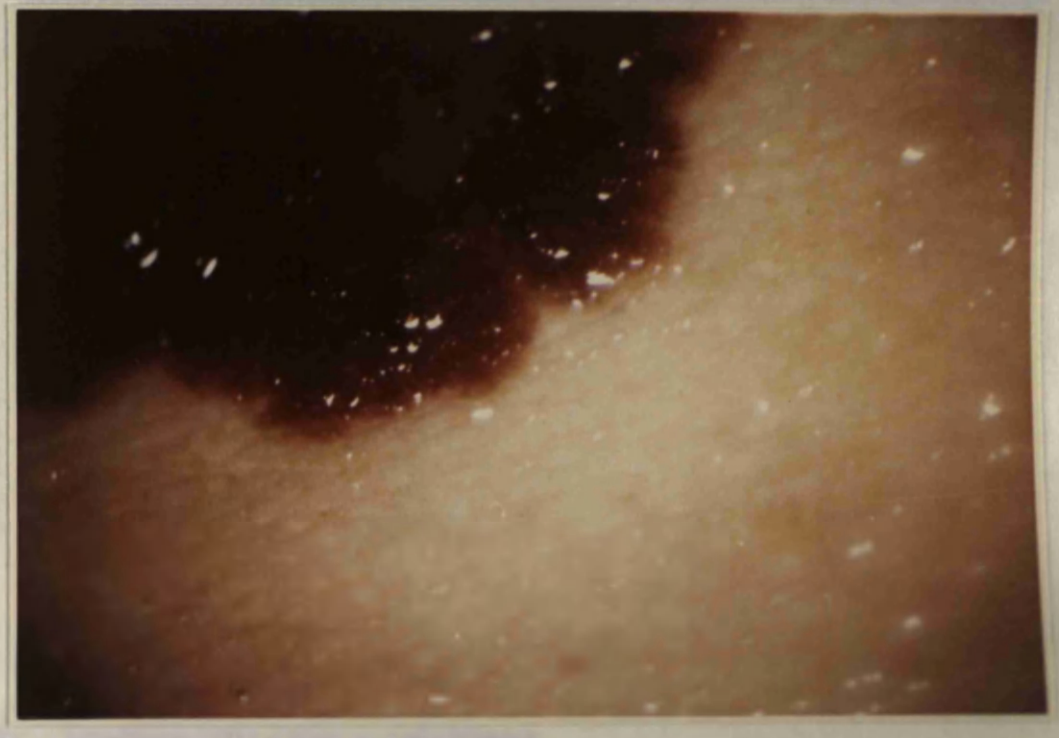

Histology: Primary malignant melanoma.

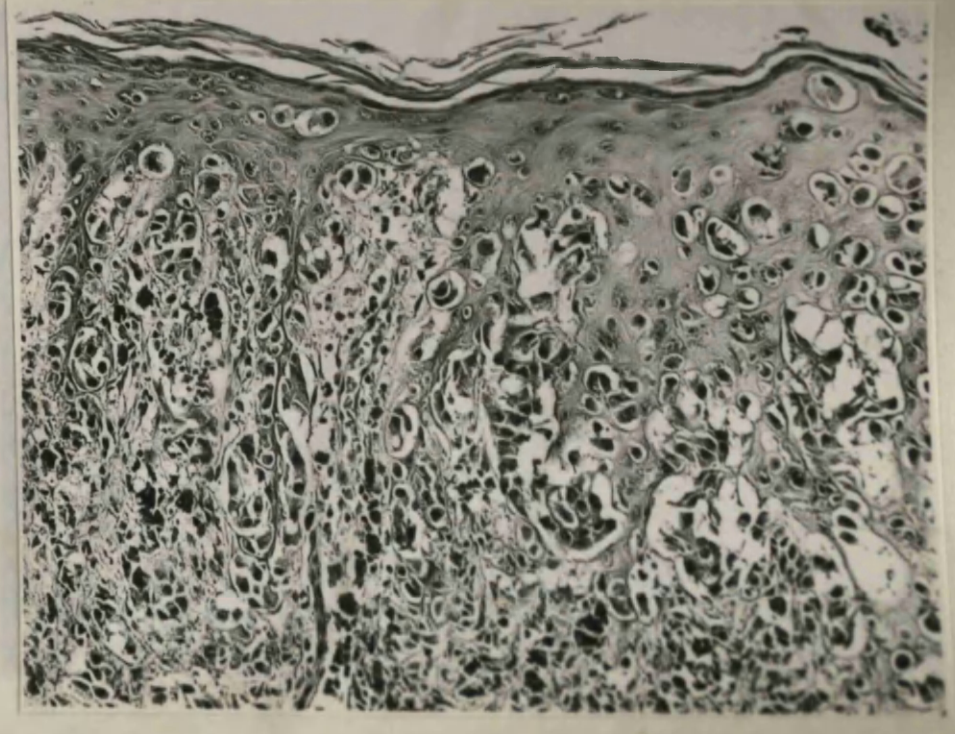

Case 84. Female aged 40 years.

Lesion on anterior aspect of neck, present for two years, growing slowly.

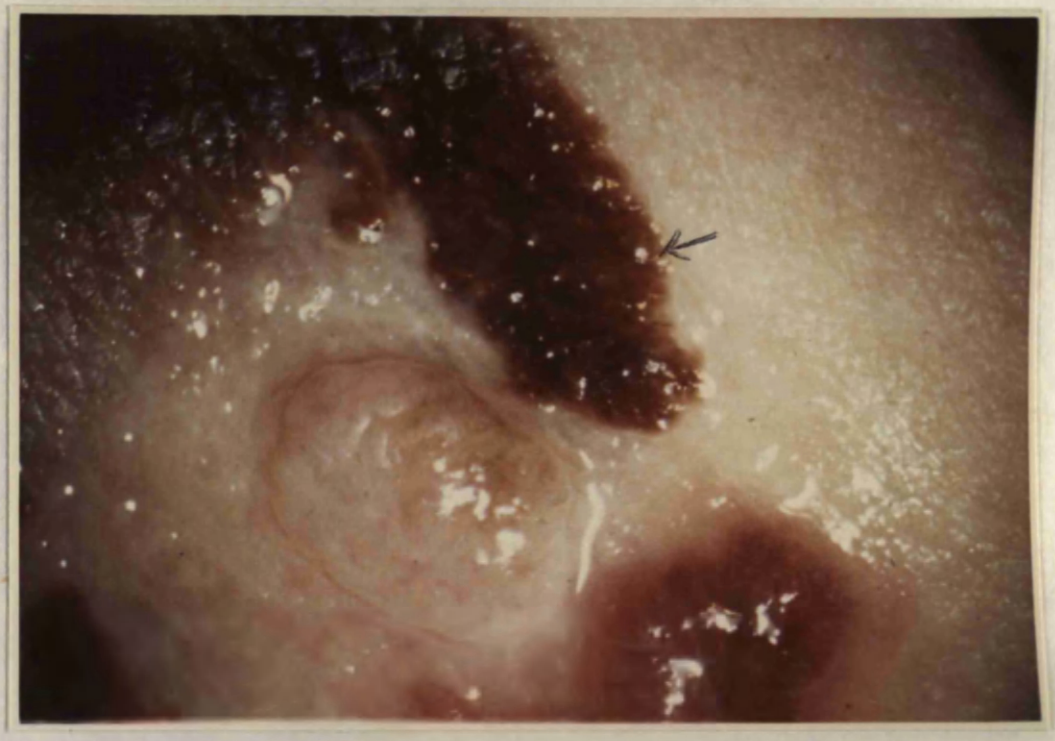

Histology: Primary malignant melanoma.

(Area from which histology is taken marked).



Case 85. Female aged 34 years.

Lesion on left upper arm present for one year.

History of steady growth.

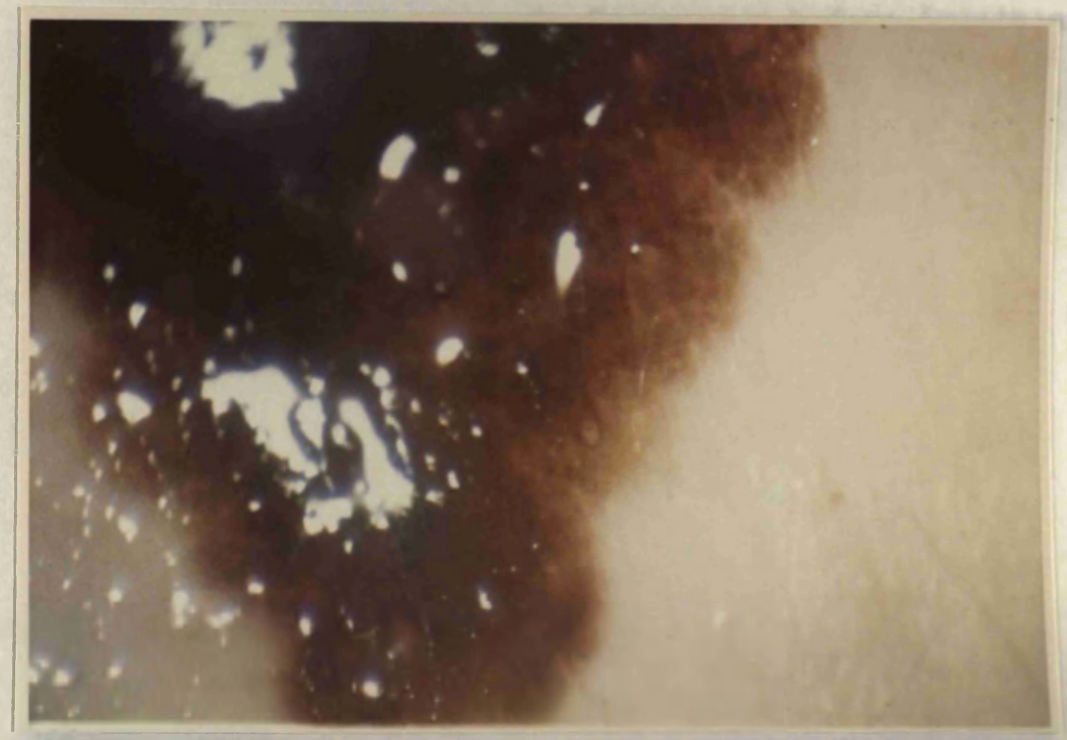

Histology: Primary malignant melanoma.



Case 86. Male aged 61 years.

Lesion behind left ear.

Mole present in this site since birth.

Growth and bleeding in four years before treatment.



Histology: Primary malignant melanoma.



Case 87. Female aged 55 years.

Lesion on left temple present for past six years, growing slowly.

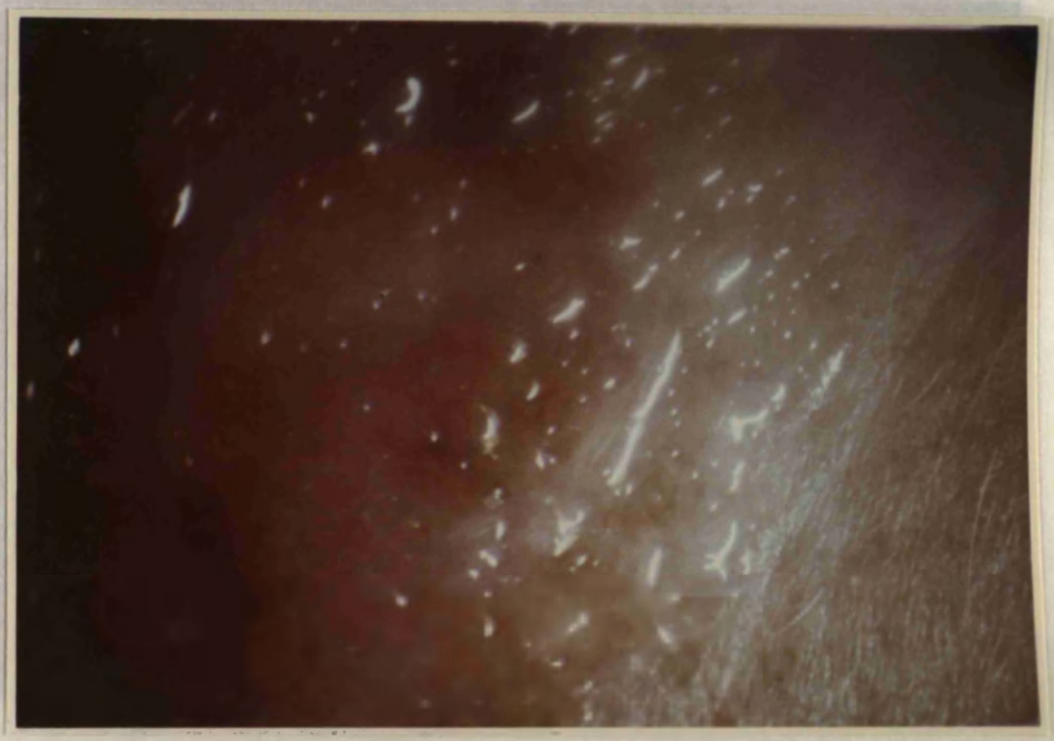

Histology: Early primary malignant melanoma.

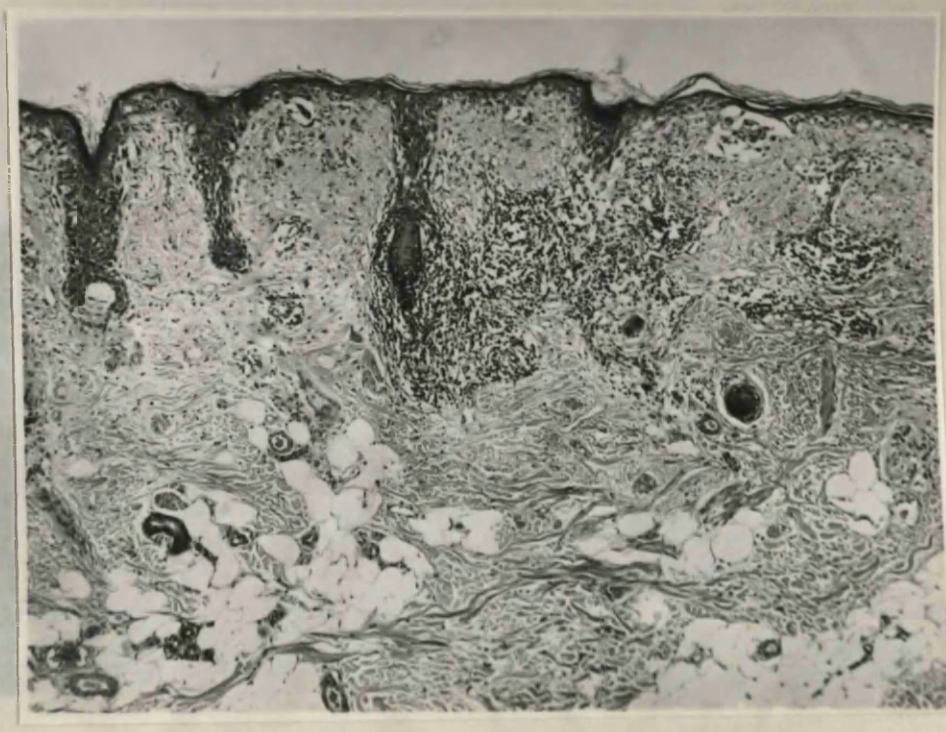

Case 88. Female aged 64 years.

Lesion on left lower leg. Bleeding and growth of mole in this site for past year.



Histology: Ulcerated primary malignant melanoma.



Case 89. Male aged 33 years.

Lesion right 4th toe present for 8 months, growing rapidly.

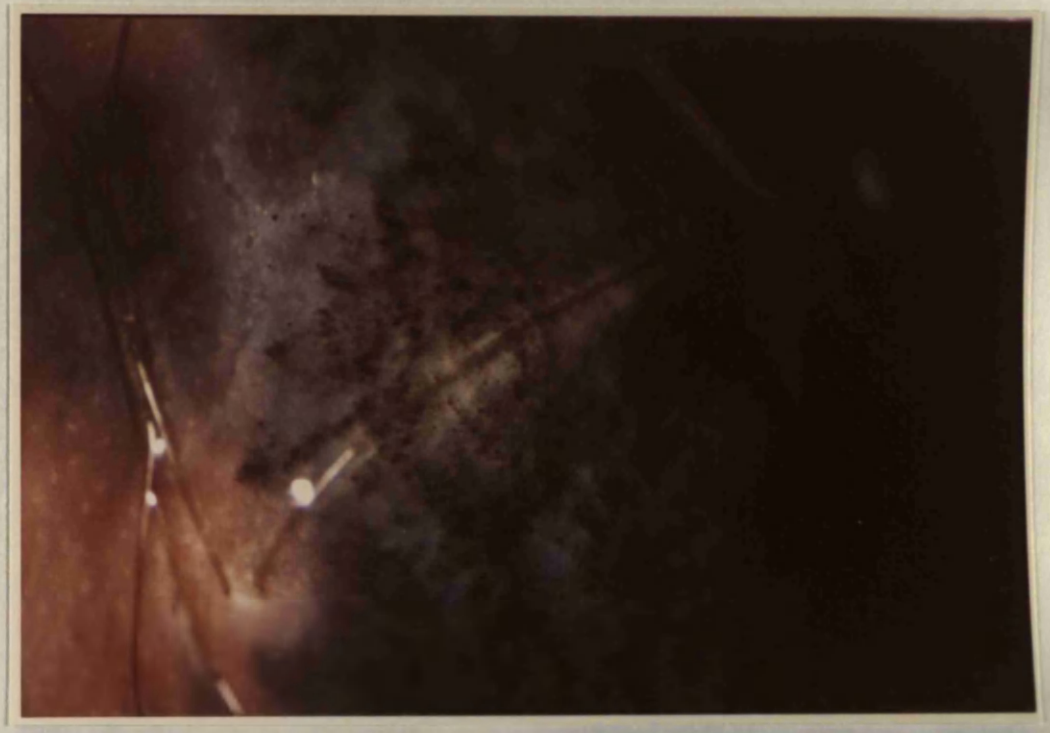

Histology: Primary malignant melanoma.



Case 90. Female aged 68 years.

Lesion on right forearm.

Mole on this site since birth, enlargement in previous year.

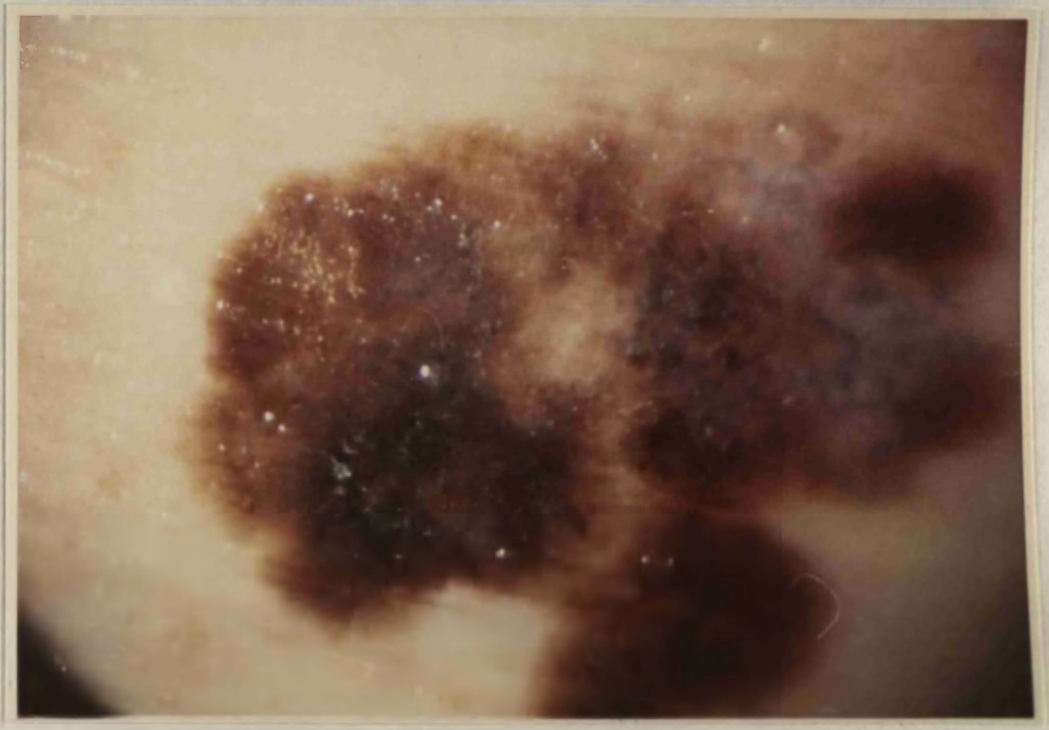

Histology: Primary malignant melanoma.

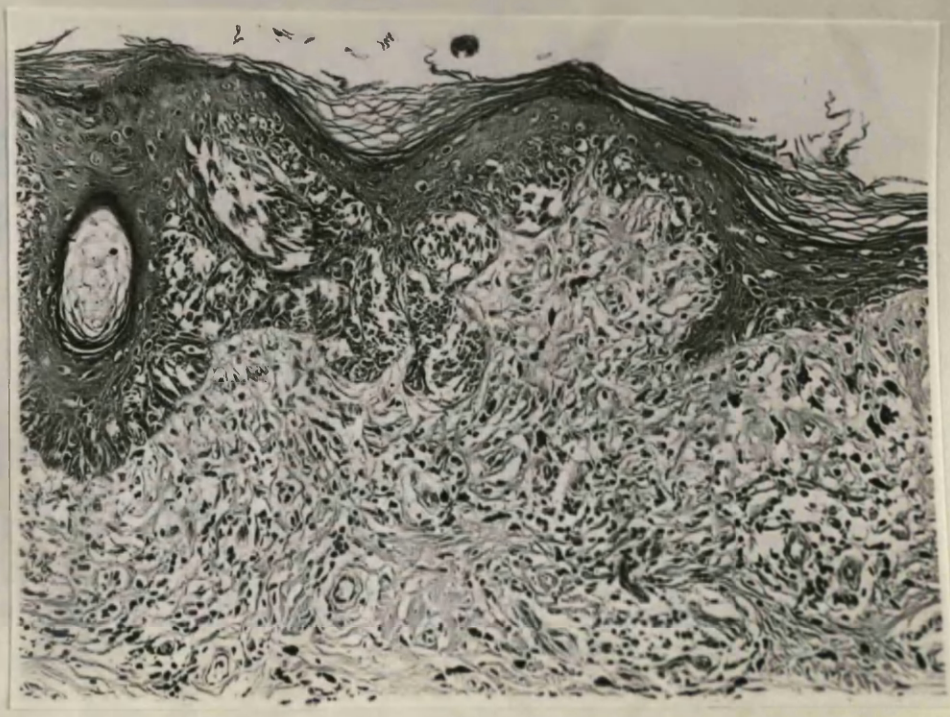

Case 91. Female aged 31 years.

Lesion on right instep present for two years, growing and darkening in colour in this time.

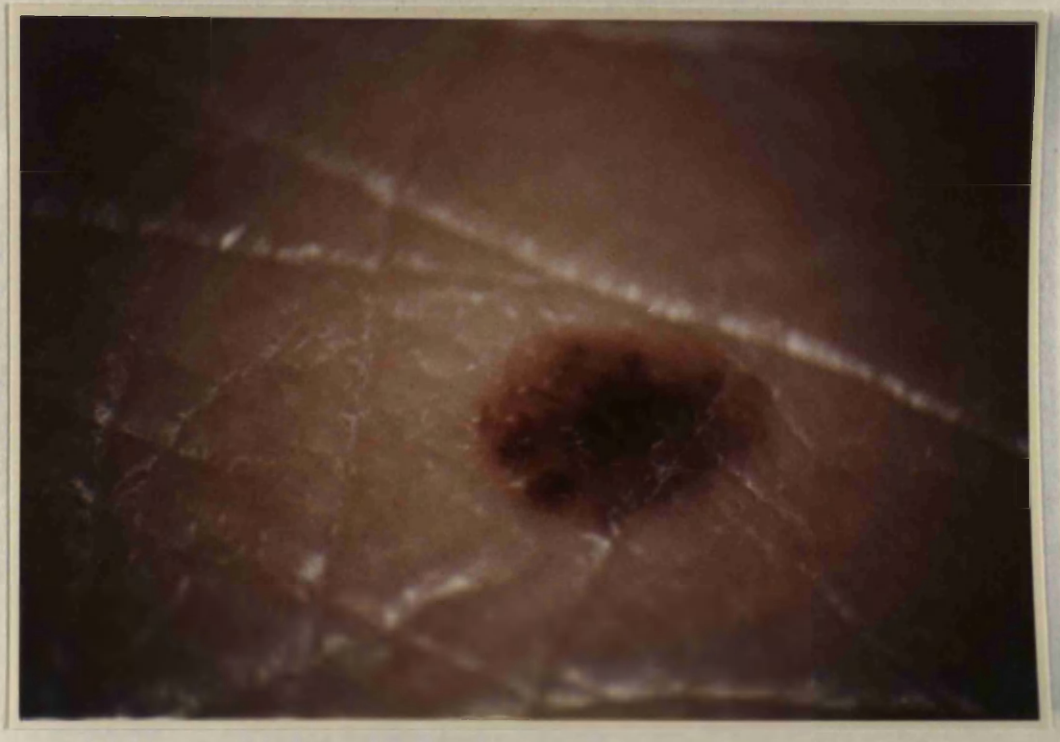

Histology: Early primary malignant melanoma.

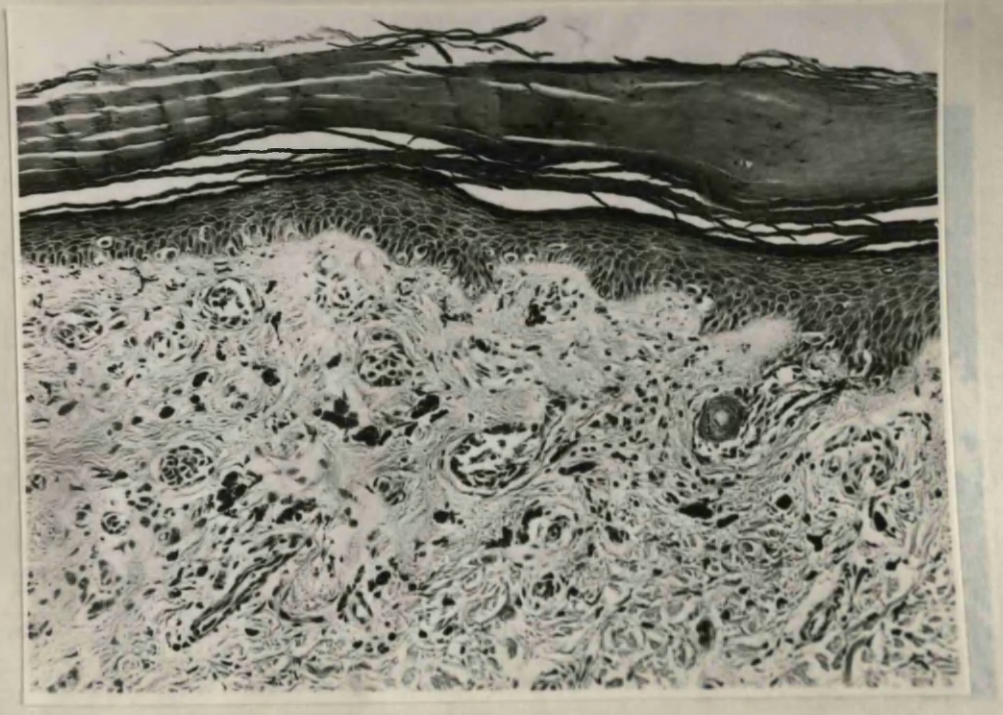

Case 92. Male aged 87 years.

Lesion on sole of right foot present for three years, growing steadily.

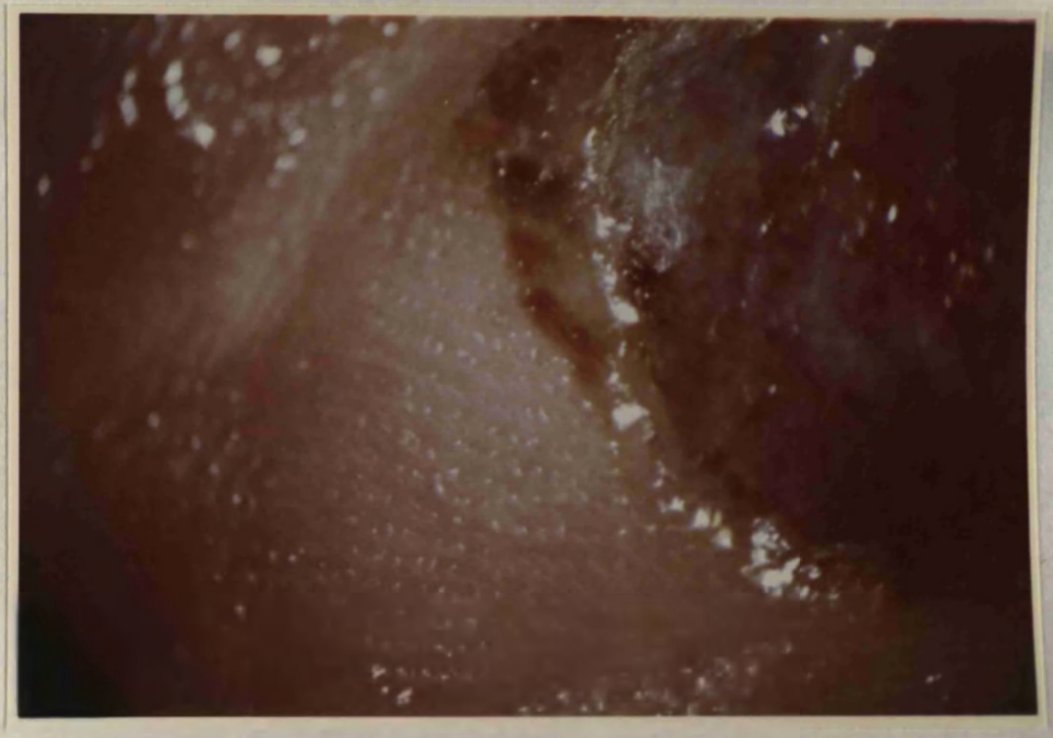

Histology: Primary malignant melanoma.



Case 93. Female aged 56 years.

Lesion on mid-back. Mole on this site since birth, growth and bleeding in 3 months before examination.



Histology: Primary malignant melanoma.



Case 94. Female aged 27 years. 4 months pregnant.

Lesion on mid-back present for past 10 years.

History of recent enlargement.

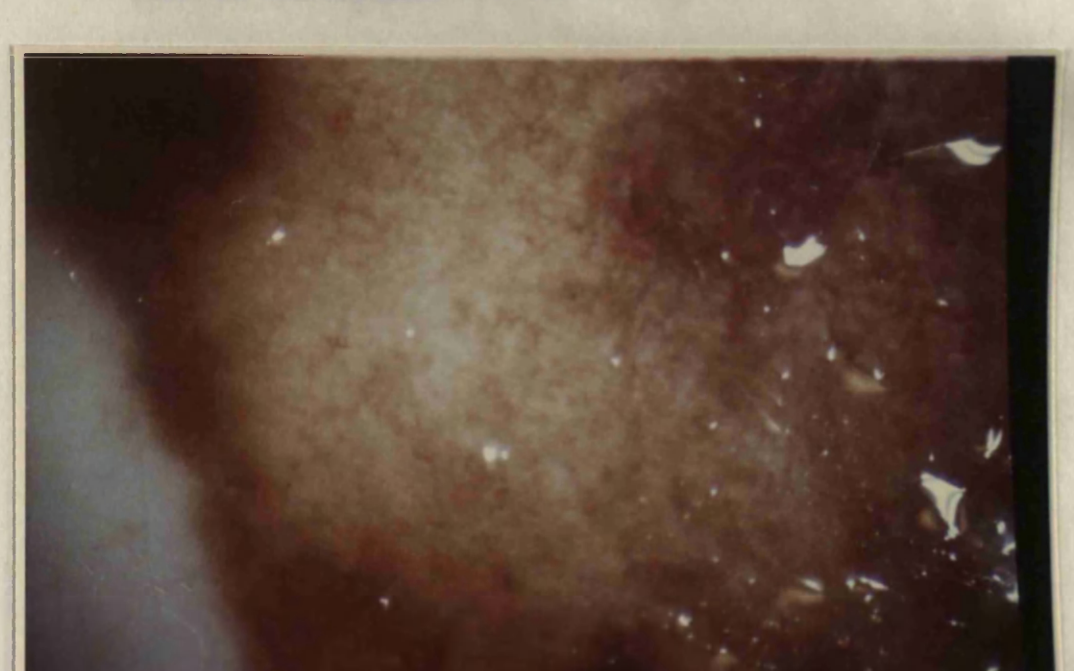

Histology: Primary malignant melanoma.

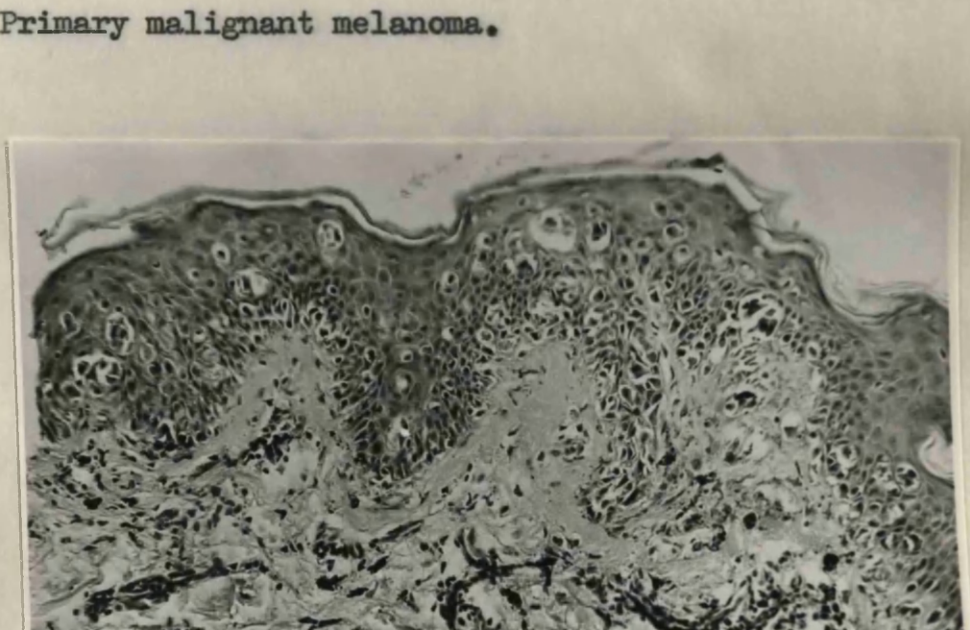

Case 95. Female aged 71 years.

Lesion on forehead present for past 5 years.

Recent bleeding.



Histology: Primary malignant melanoma.



Case 96. Female aged 65 years.

Lesion on left lower leg. Mole on this site since birth, enlargement in past 6-7 years.



Histology: Primary malignant melanoma.



Case 97. Female aged 58 years.

Lesion on left lower calf. Mole in this site since birth. Growth and darkening of pigment in Growth in past 4 years.

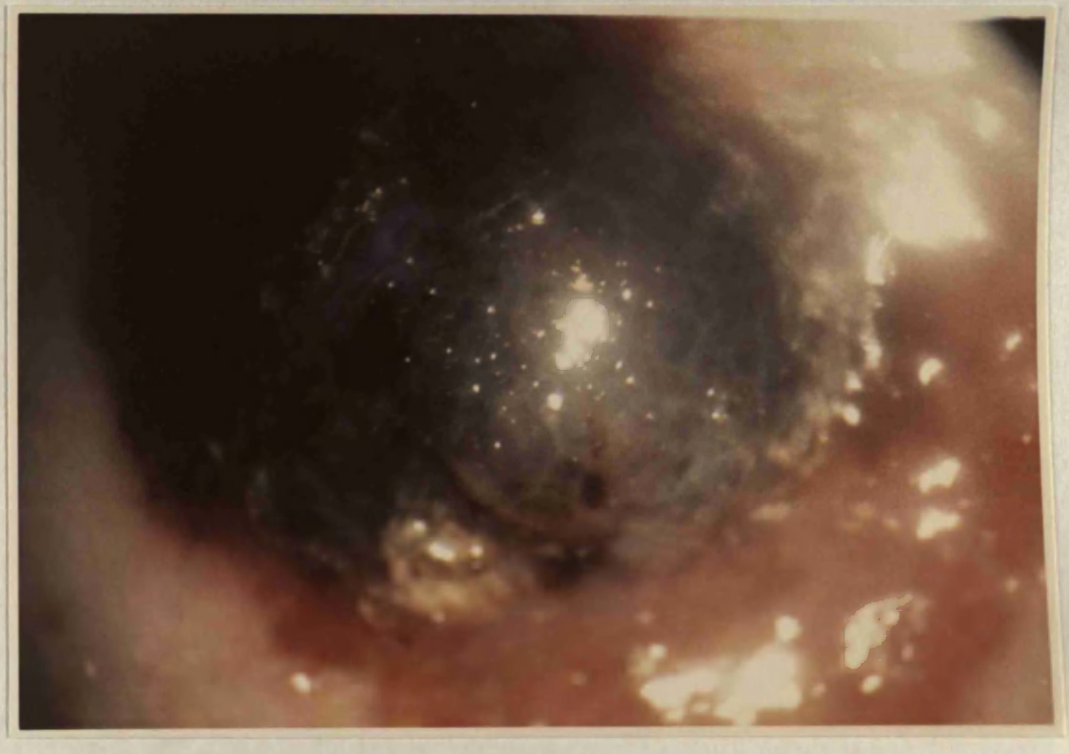

Histology: Primary malignant melanoma.

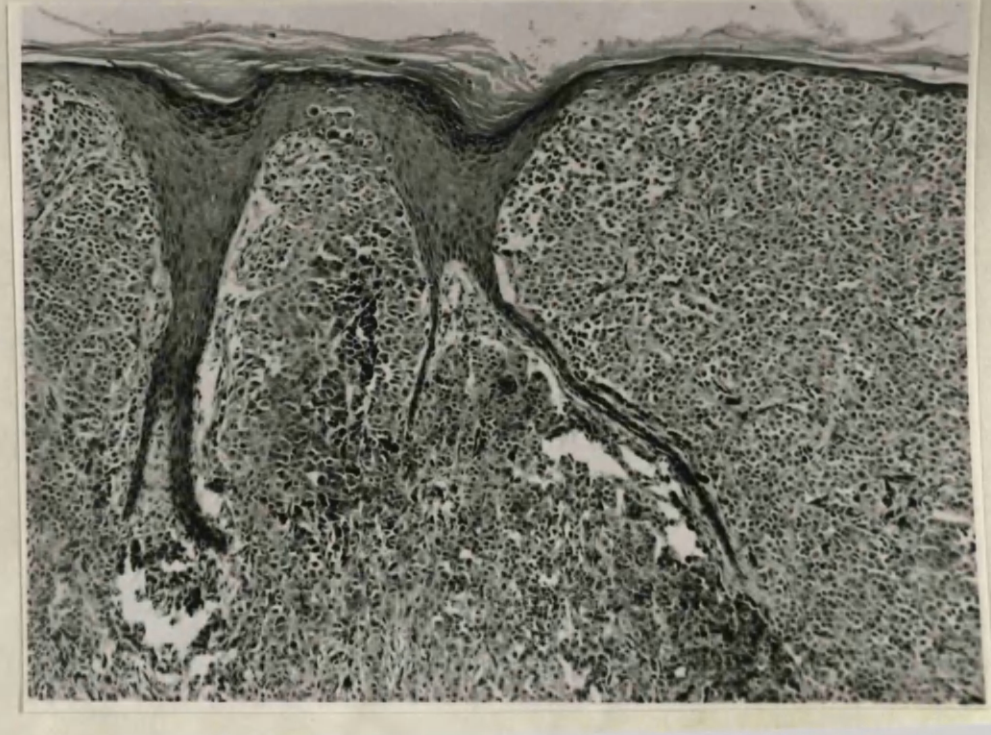

Case 98. Male aged 37 years.

Lesion on interscapular area. Mole on this site since birth. Growth and darkening of pigment in past year.



Histology: Primary malignant melanoma.

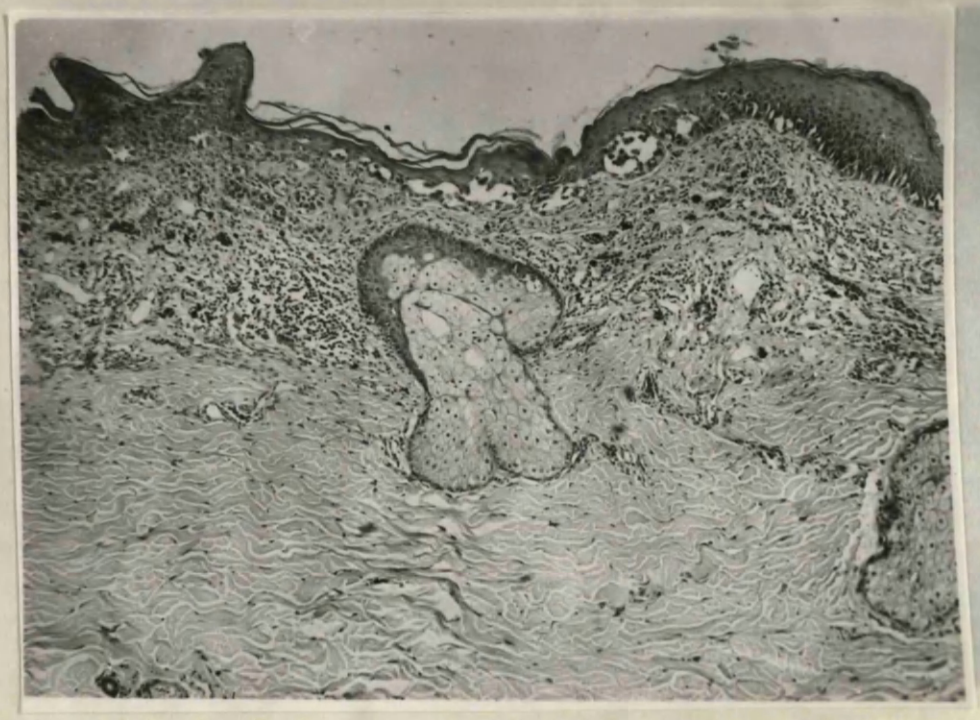

Case 99. Female aged 63 years.

Lesion on left infrascapular area present for many years, growth in past two years.

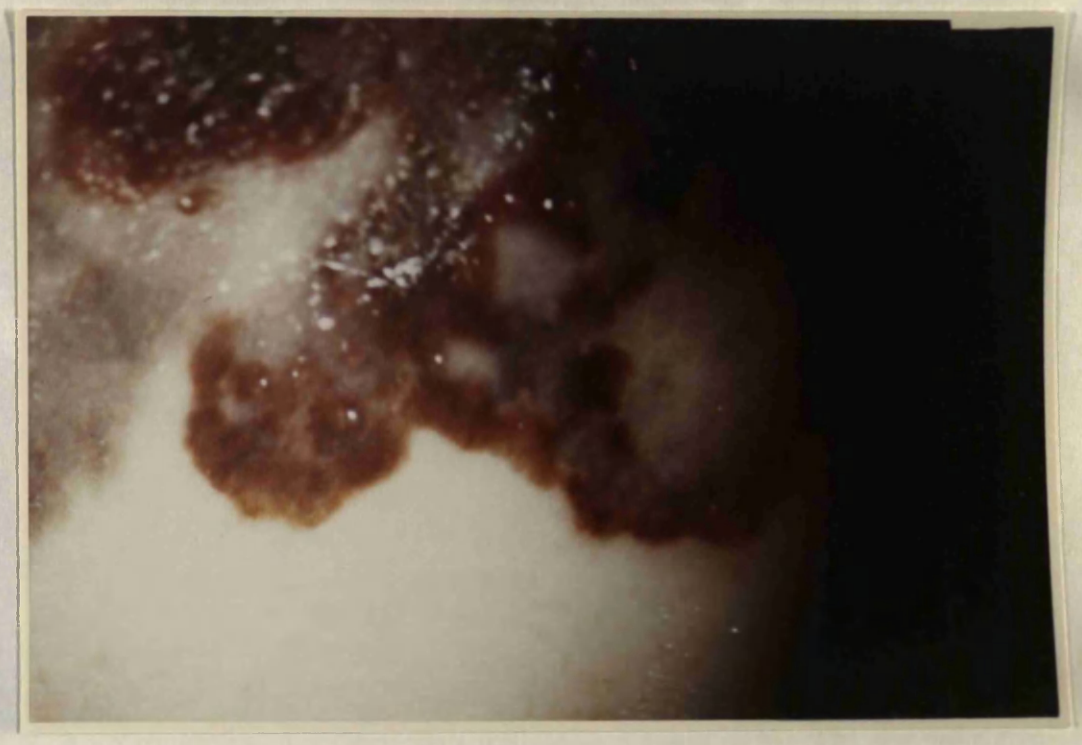

Histology: Primary malignant melanoma.



Case 100. Female aged 38 years.

Lesion on right deltoid area present since birth, growth in previous two months.

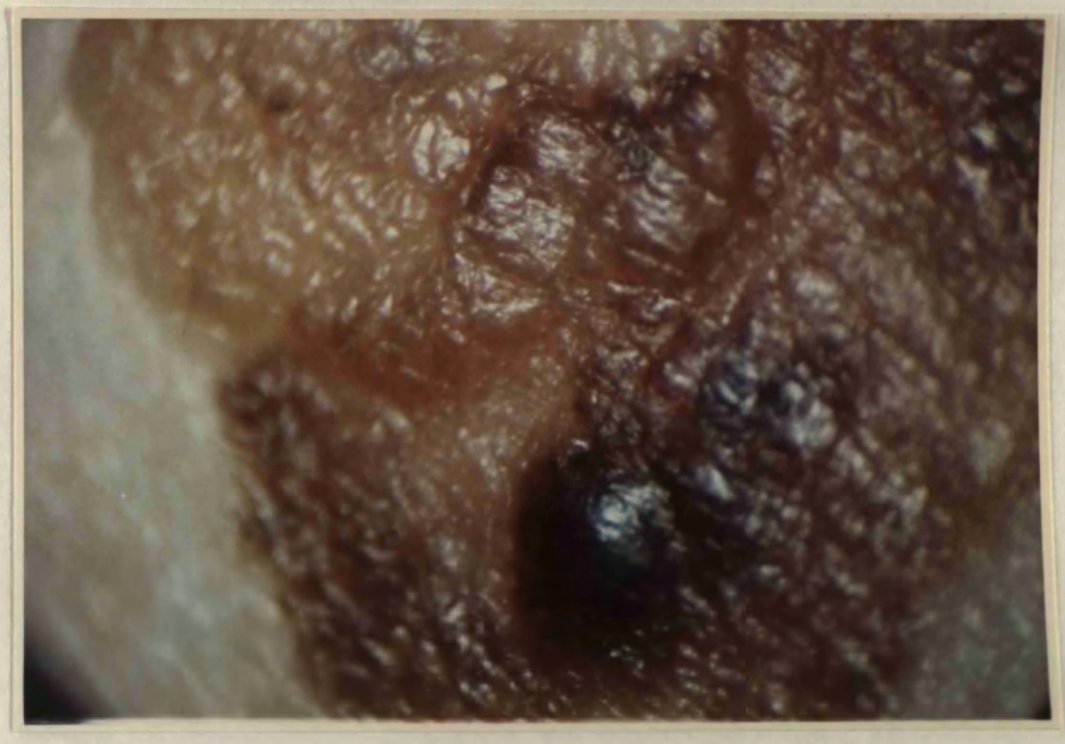

Histology: Primary malignant melanoma.



Case 101. Male aged 58 years.

Lesion over left Achilles' tendon, present and growing for at least two years.

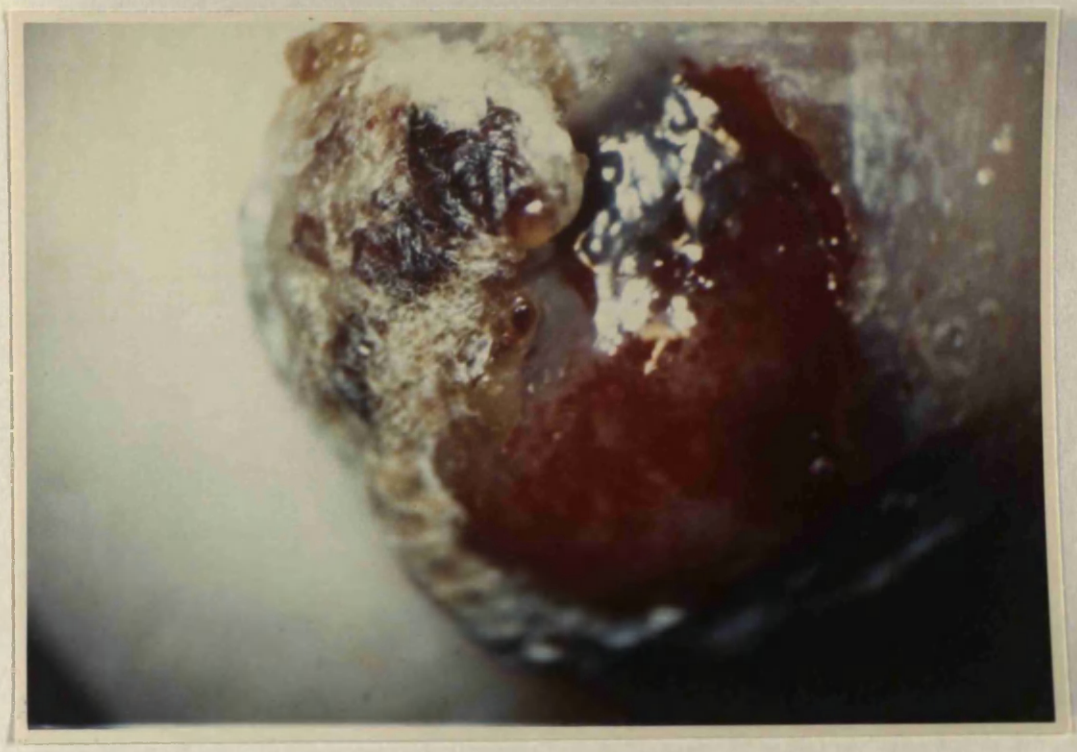

Histology: Primary malignant melanoma.

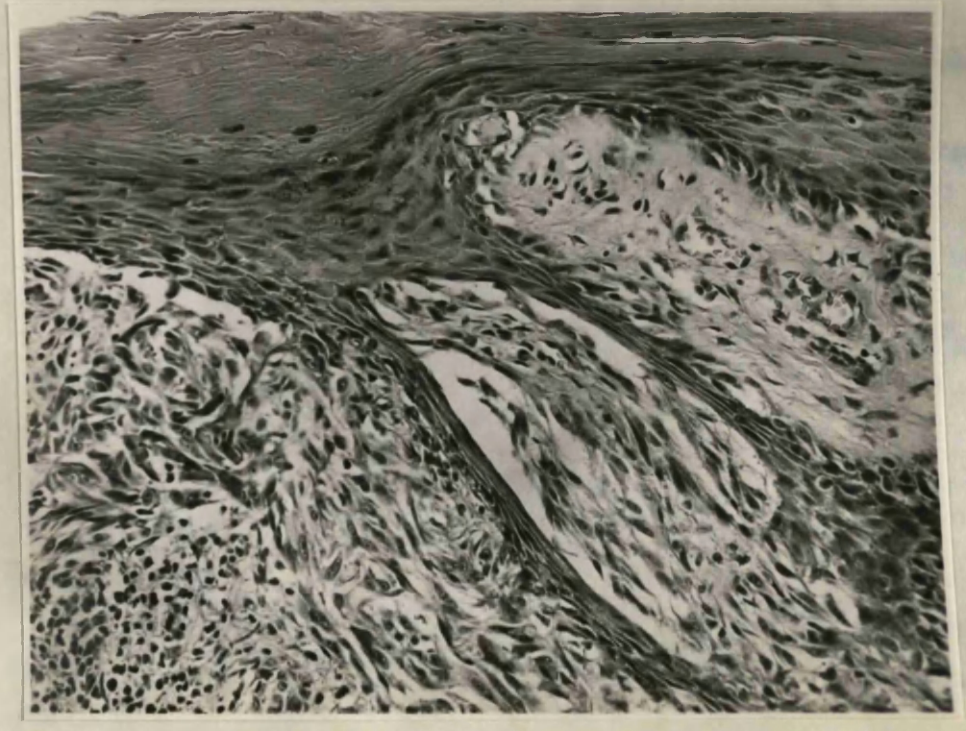

Case 102. Female aged 53 years.

Lesion on right lower leg present since birth, growth in past year.

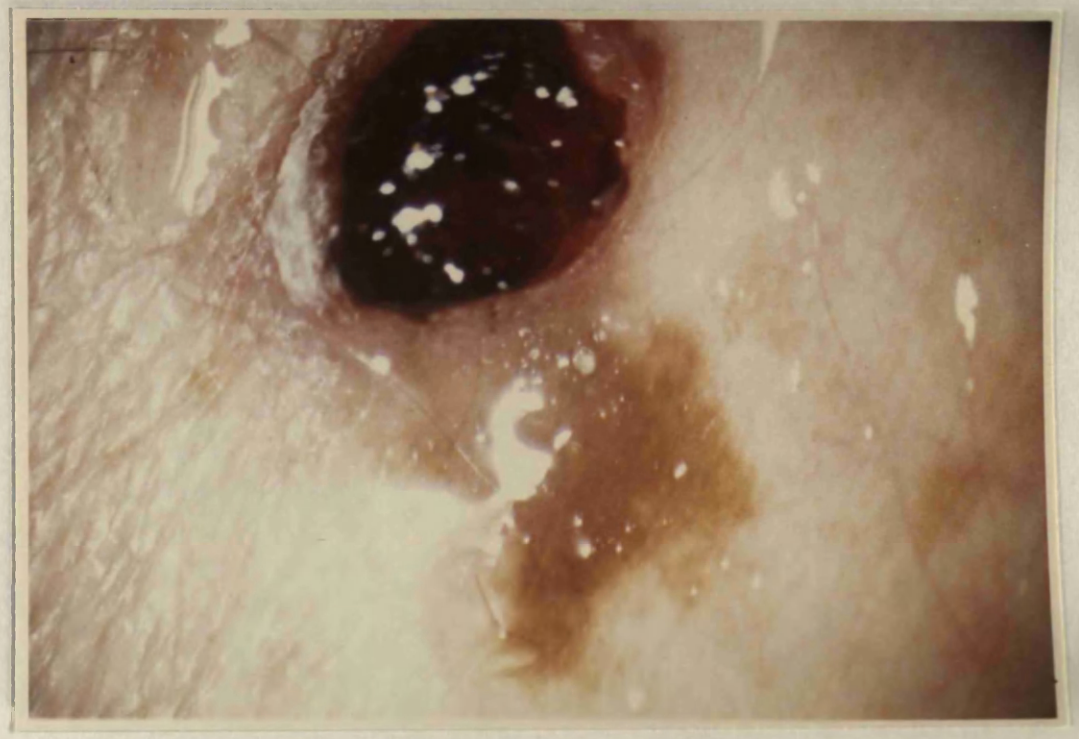

Histology: Early primary malignant melanoma.

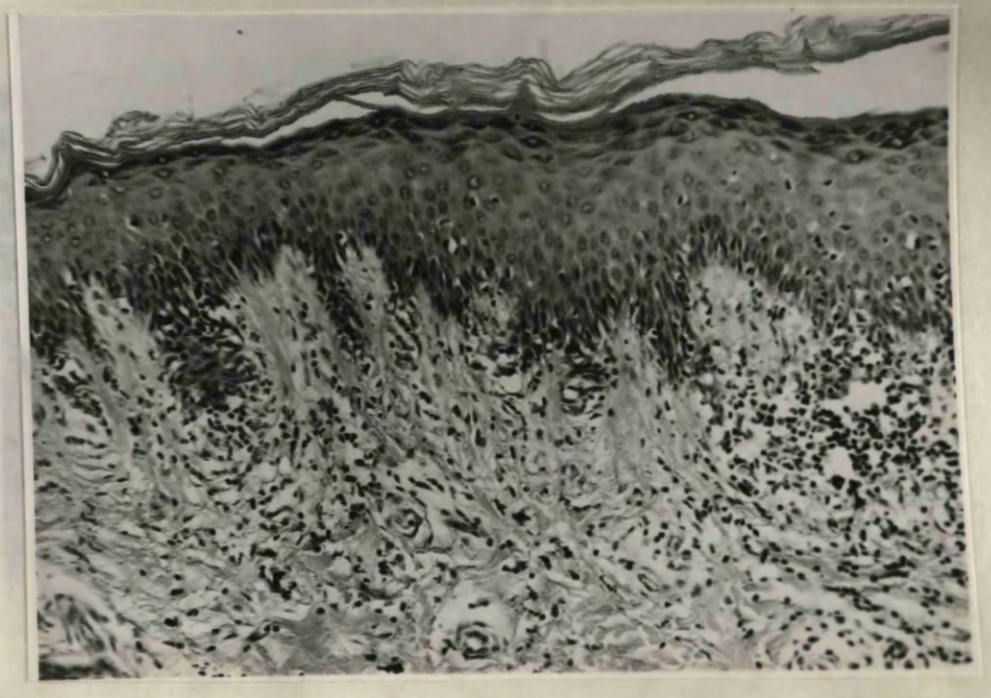

Case 103. Female aged 70 years.

Lesion on left forearm present for at least two years, growing steadily.



Histology: Primary malignant melanoma (axillary lymphnodes contained secondary tumour).

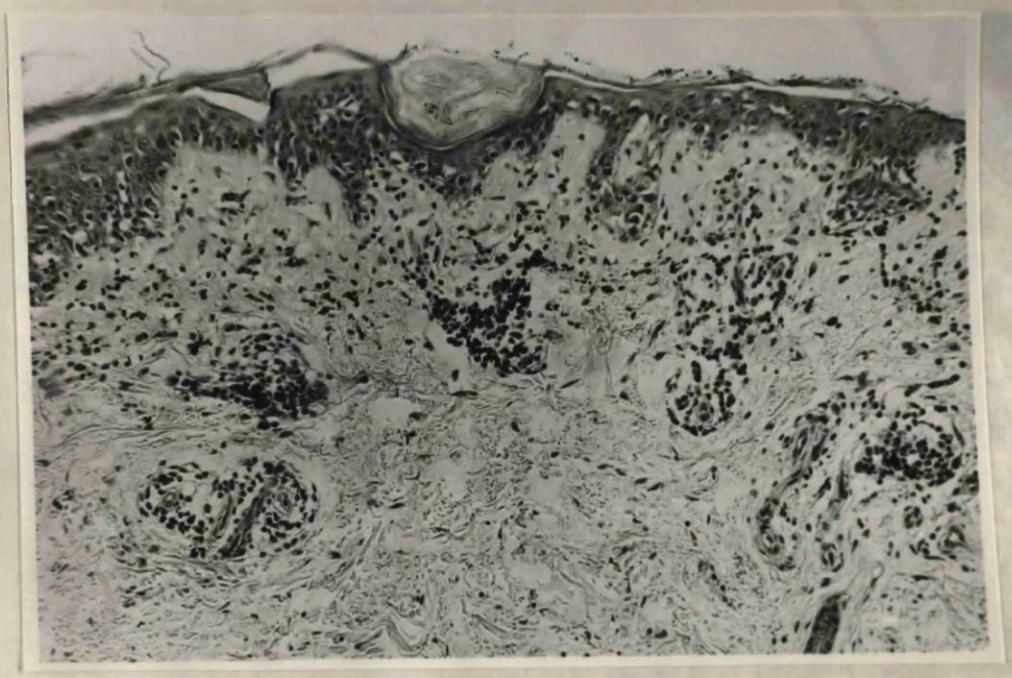

Case 104. Female aged 53 years.

Lesion on sole of left foot present for at least six months.

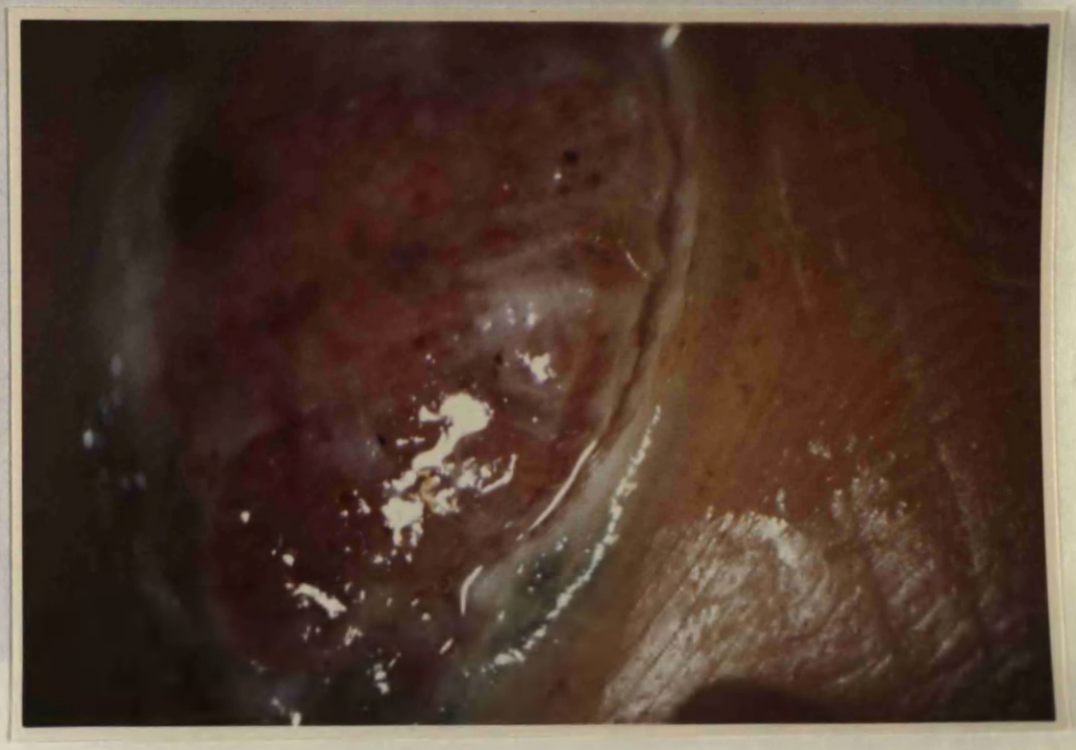

Histology: Ulcerated primary malignant melanoma.

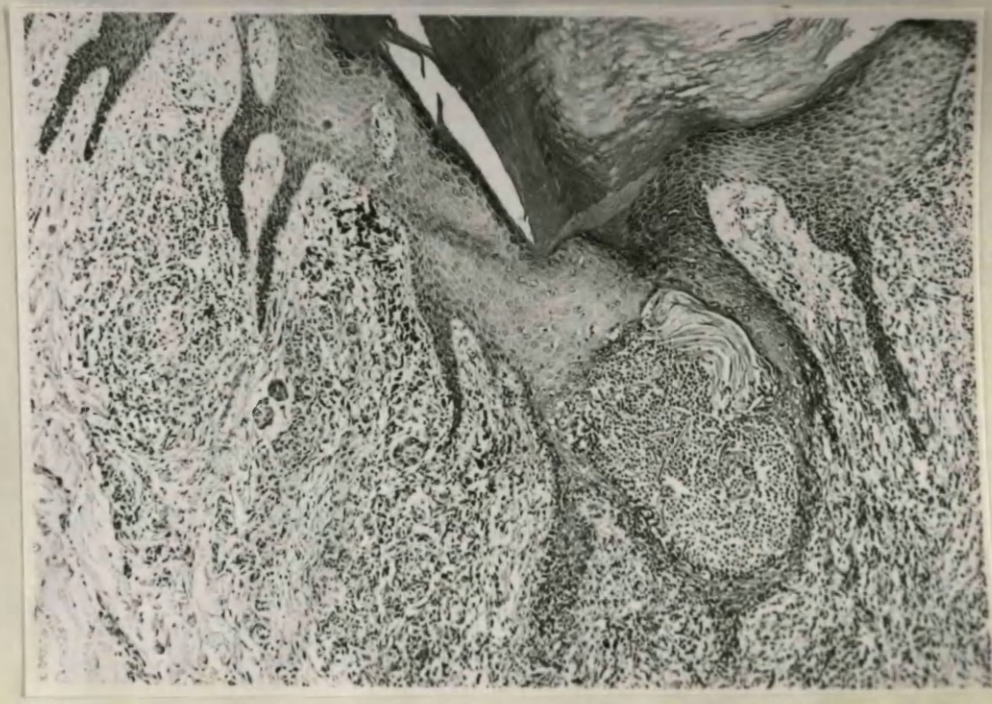

Case 105. Female aged 57 years.

Lesion on right great toe present for past six months.

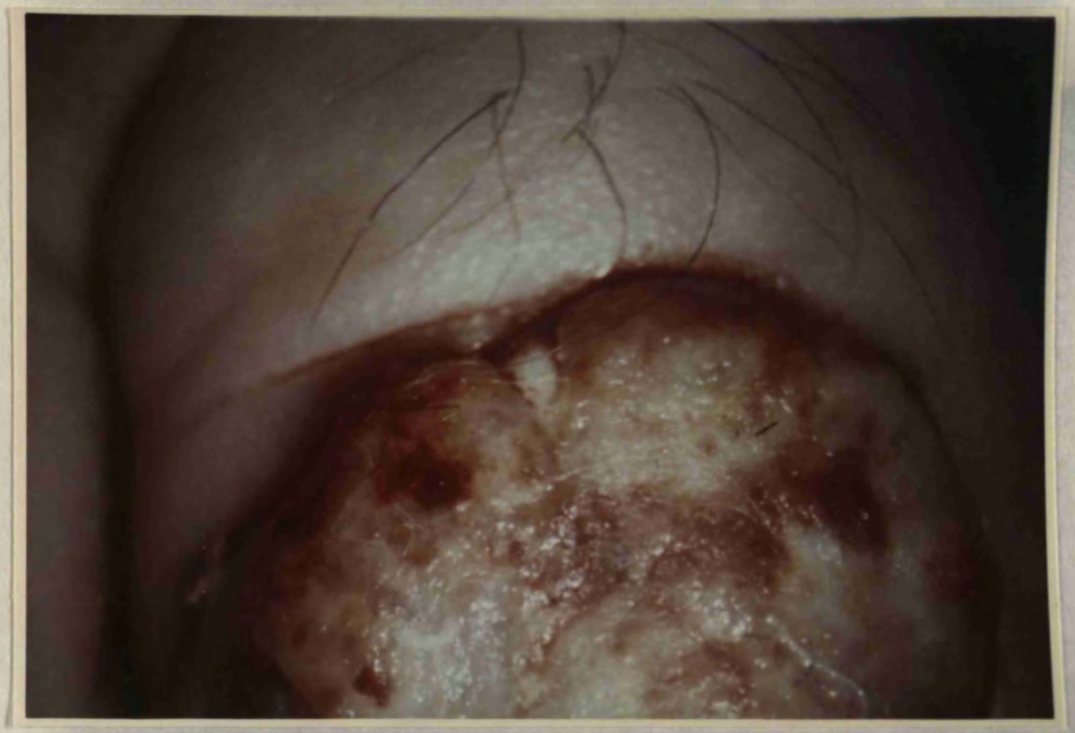

Histology: Primary malignant melanoma.

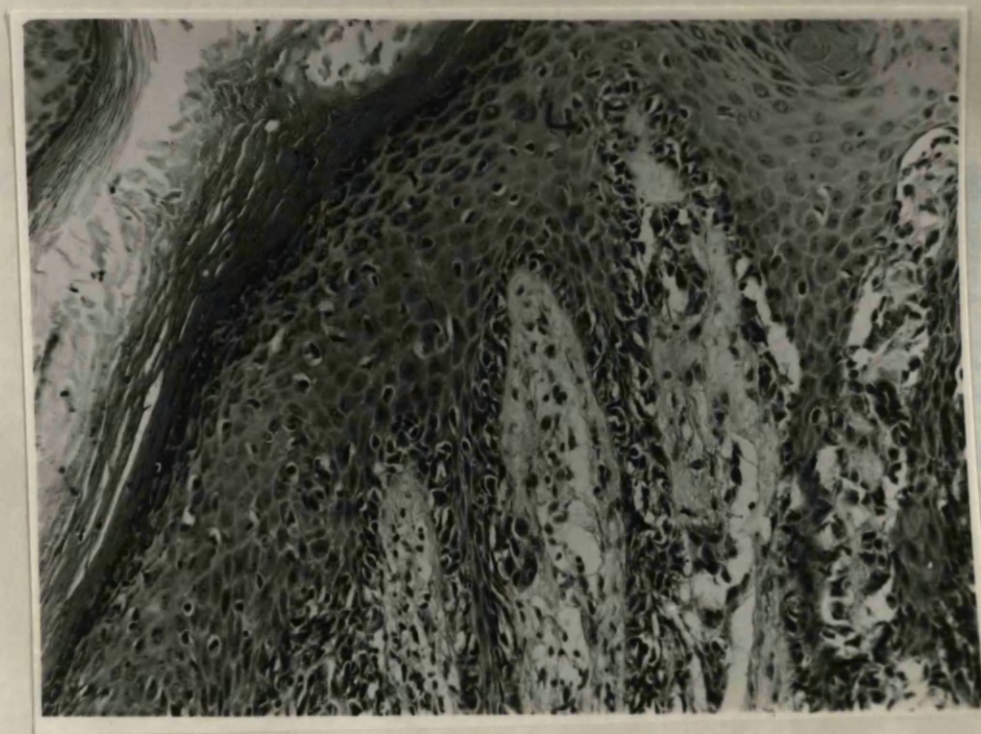

Case 106. Female aged 27 years.

Lesion on sole of left foot present for past three years, growing steadily. History of recent trauma.

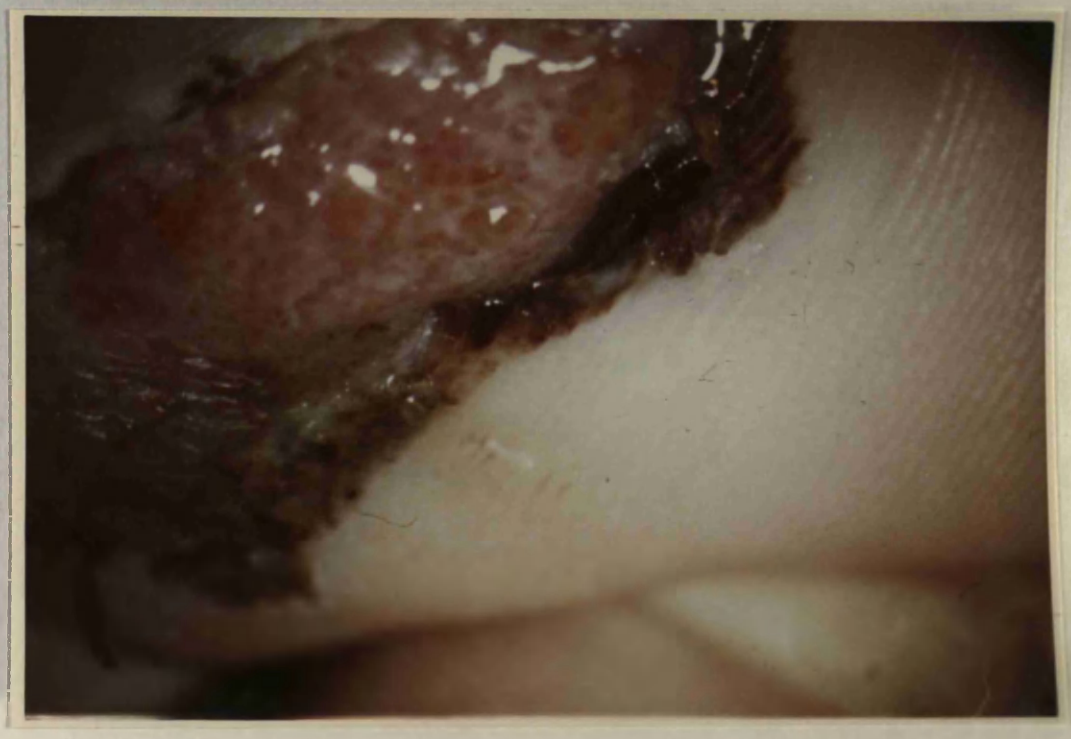

Histology: Primary malignant melanoma.



Case 107. Female aged 49 years.

Lesion on right heel present for past five months, growing steadily.



Histology: Primary malignant melanoma.

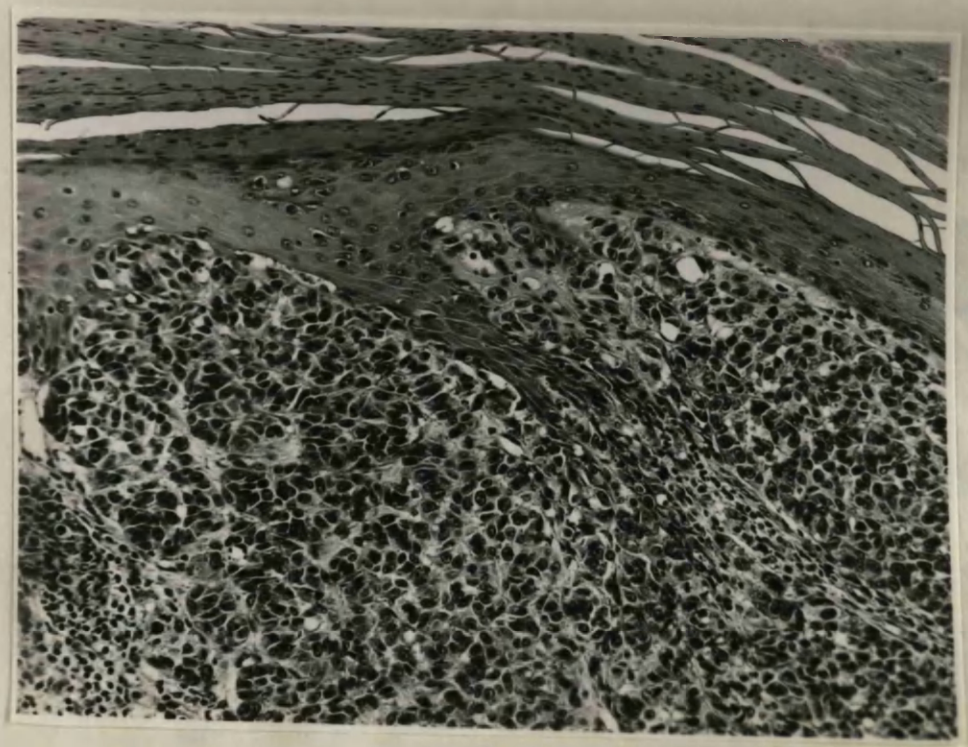

Case 108. Female aged 34 years.

Lesion on anterior aspect lower right leg present since birth, growing for past 6 months.



Histology: Primary malignant melanoma.

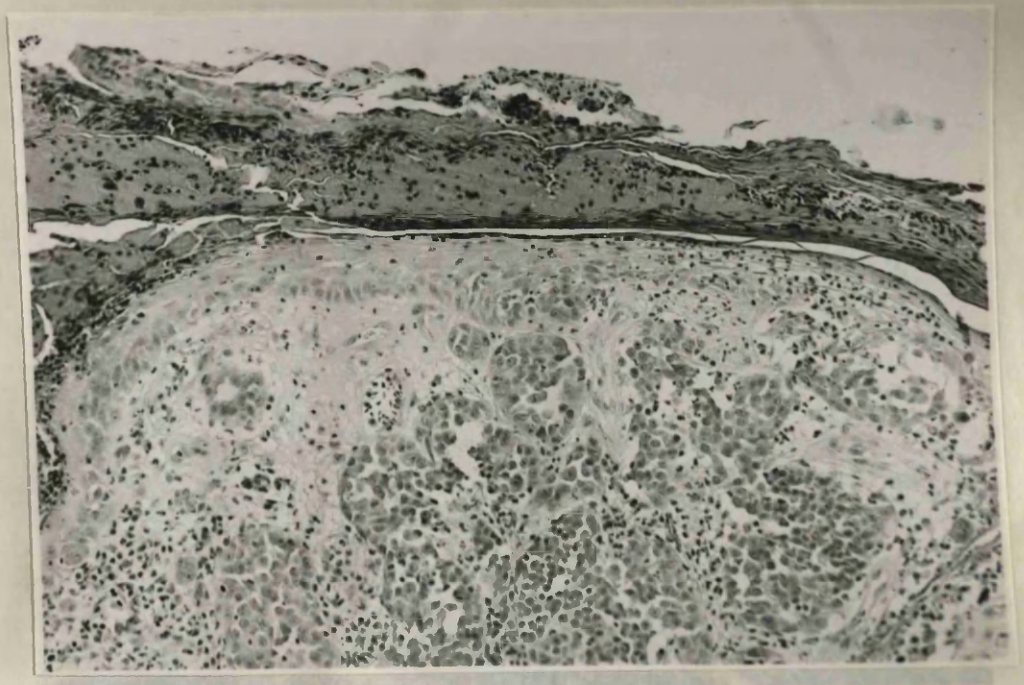

Case 109. Male aged 46 years.

Lesion on interscapular area present for at least 5 years, growth in past 6 months.

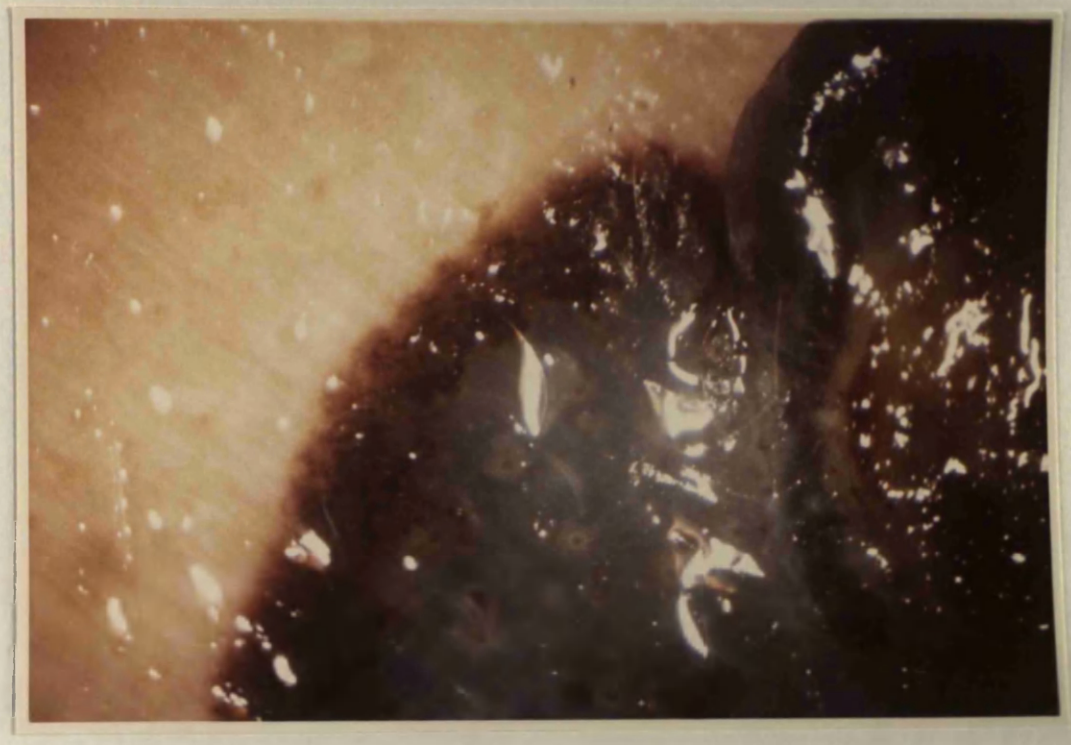

Histology: Primary malignant melanoma.

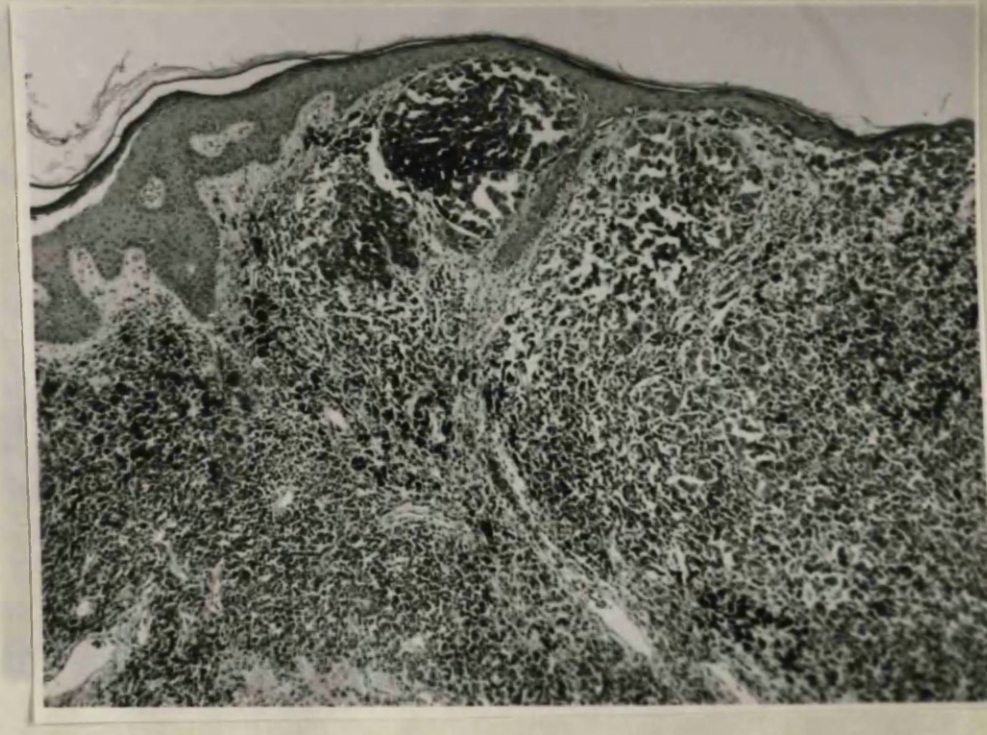

Case 110. Female aged 30 years.

Lesion on medial aspect of right calf present for at least 10 years, growing in past year.



Histology: Primary malignant melanoma.



Case 111. Female aged 58 years.

Lesion over right Achilles' tendon present for 15 years, growing slowly.



Histology: Primary malignant melanoma.



Case 112. Female aged 52 years.

Lesion on posterior aspect of left calf. Mole on this site since birth, growth and bleeding in past 4 months.



Histology: Primary malignant melanoma.

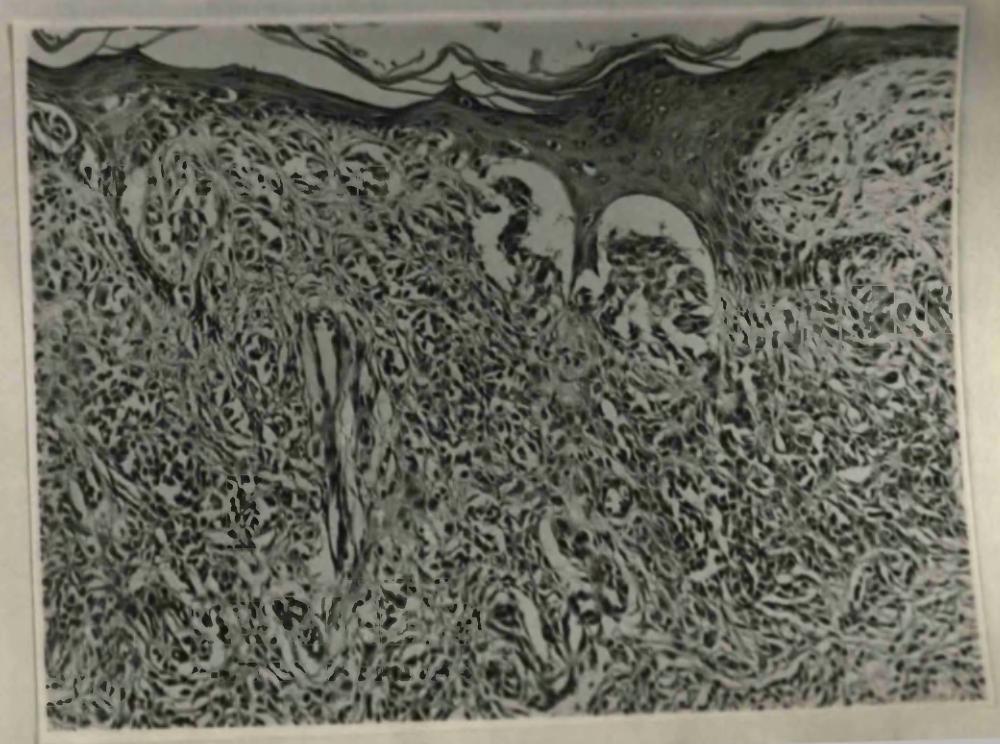

Case 113. Female aged 72 years.

Lesion on inner aspect left calf present for two years, growing steadily.

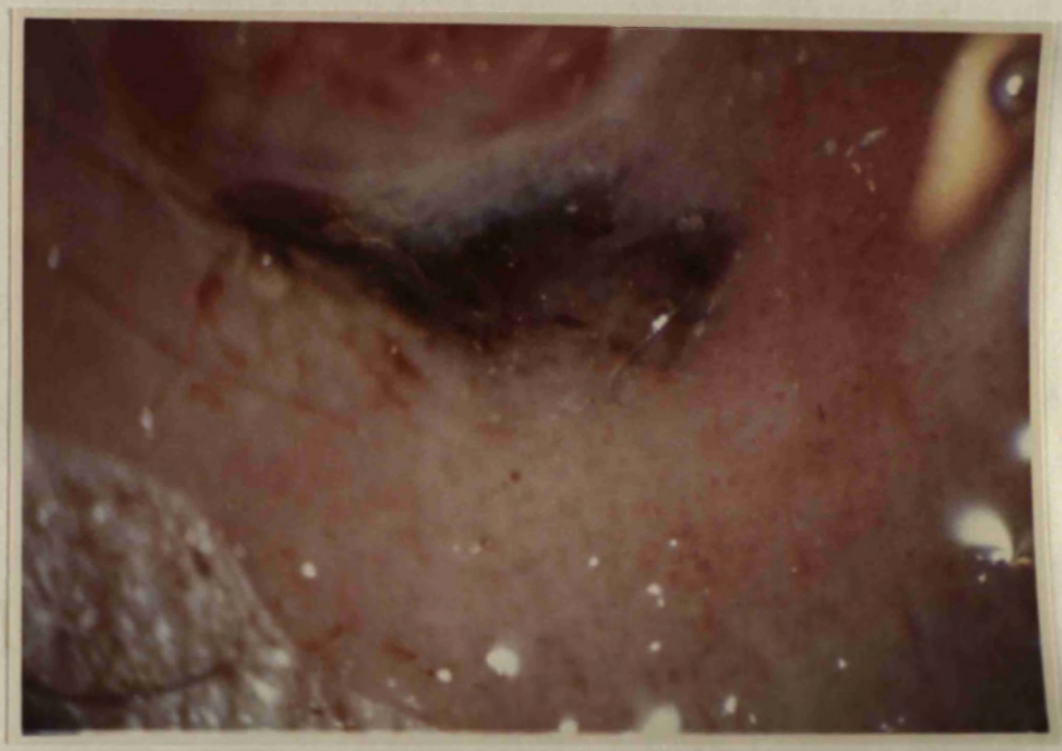

Histology: Primary malignant melanoma.

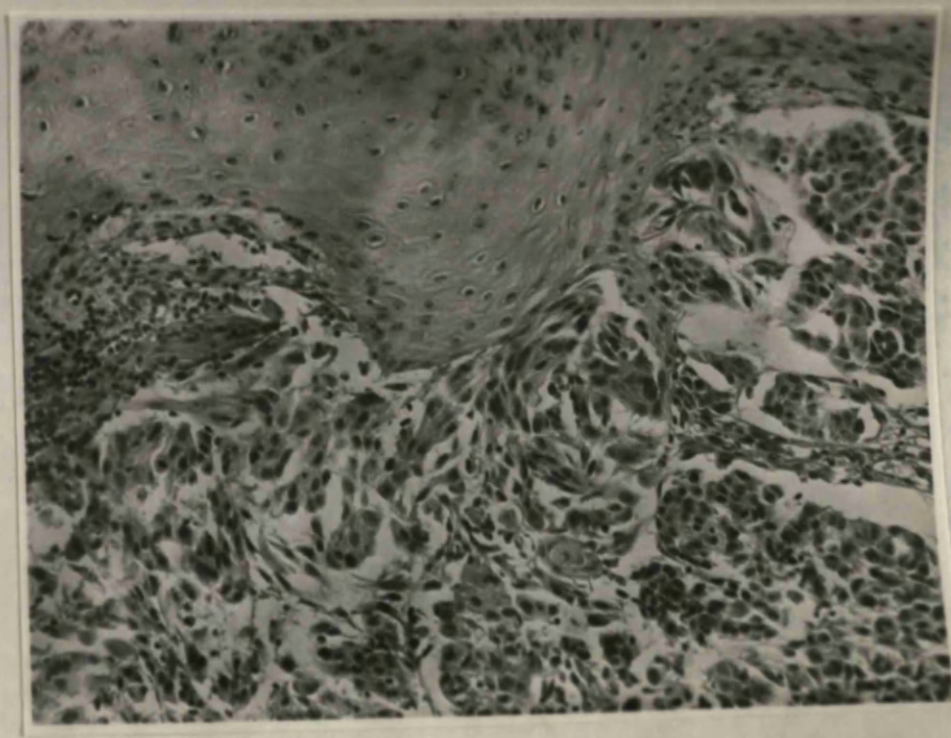

Case 114. Female aged 46 years.

Lesion on interscapular area present for one year.

Steady enlargement and bleeding in this time.

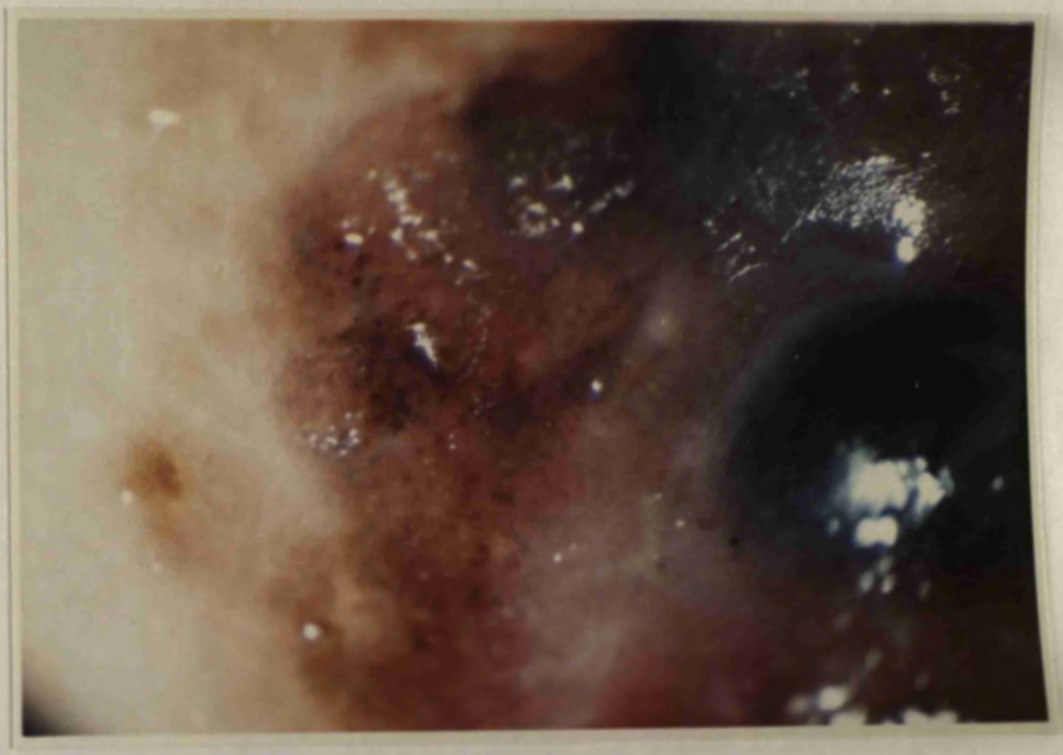

Histology: Primary malignant melanoma.

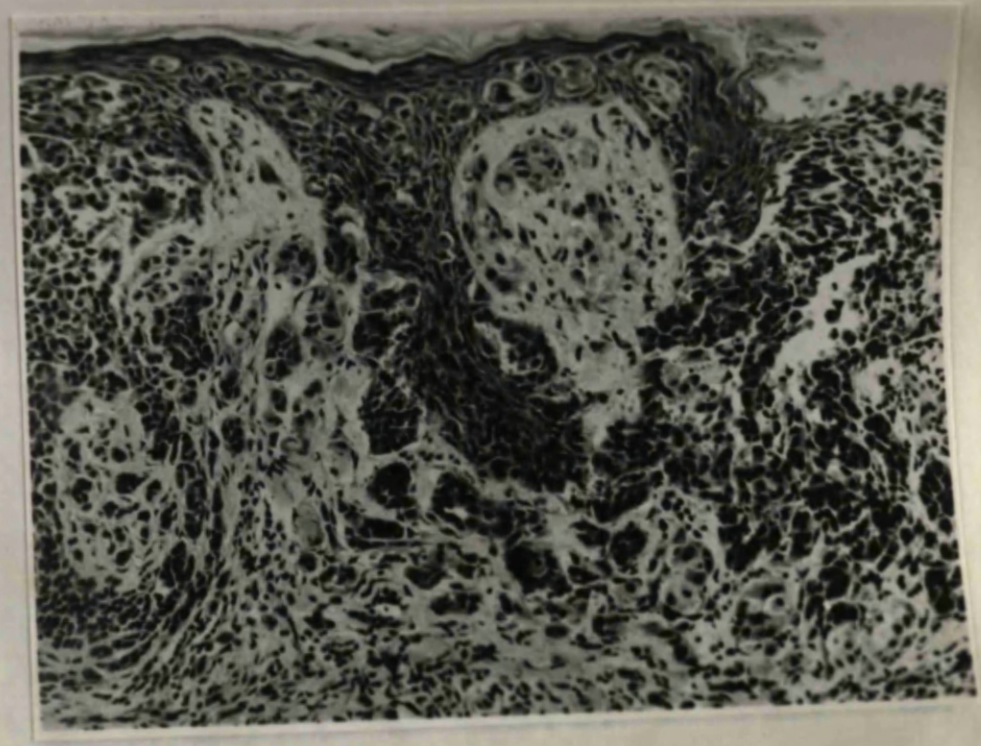

Case 115. Female aged 54 years.

Lesion on inner surface of right calf.

Present for seven years, growing steadily.



Histology: Primary malignant melanoma.

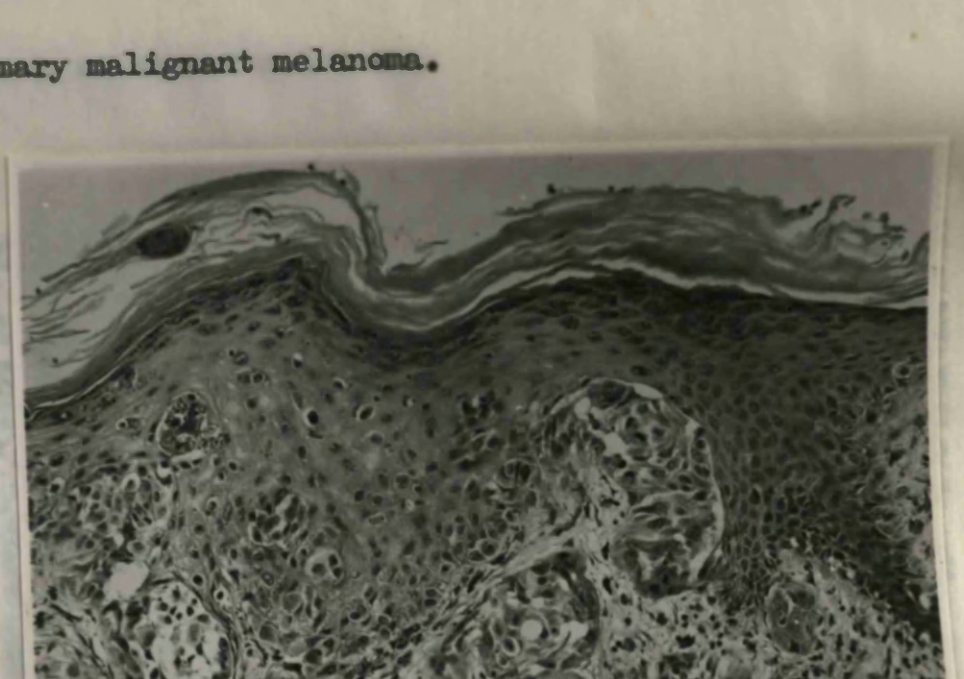

Case 116. Male aged 44 years.

Lesion on left infrascapular area present for 10 years, growing slowly.



Histology: Primary malignant melanoma.

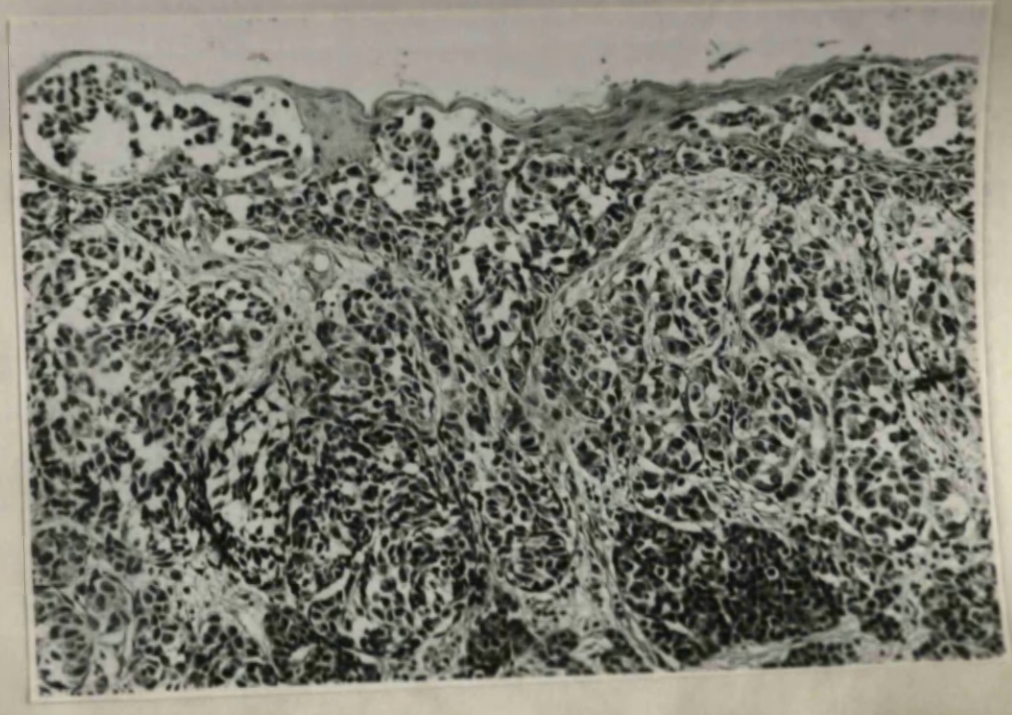

Case 117. Male aged 52 years.

Lesion on umbilical area.

Mole on this site since birth, gross enlargement and bleeding in past 6 months.



Histology: Primary malignant melanoma.

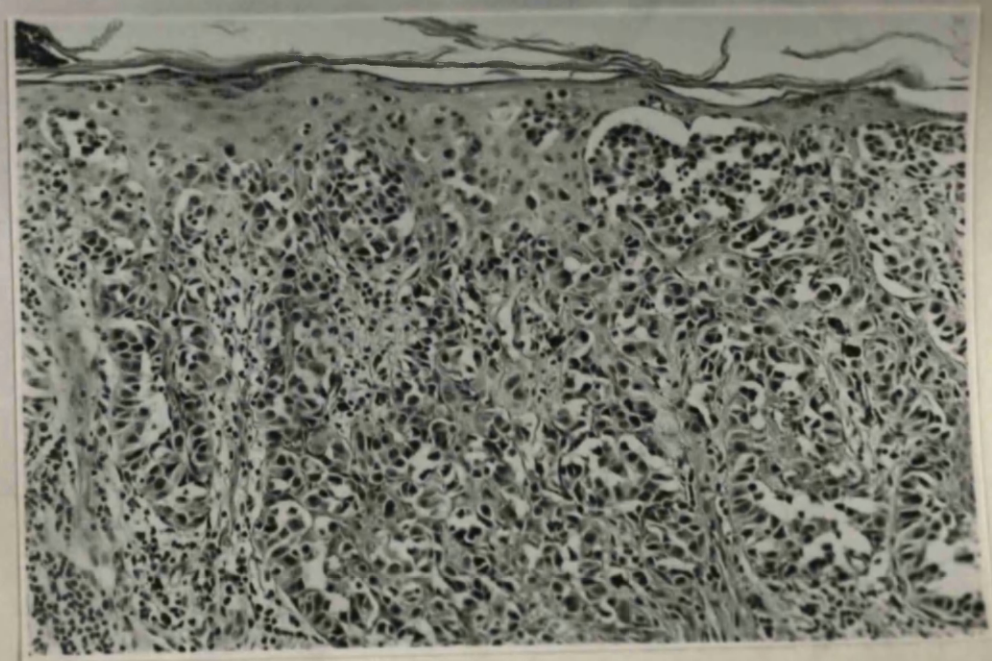

Case 118. Male aged 23 years.

Lesion on anterior chest wall present for at least 18 months.

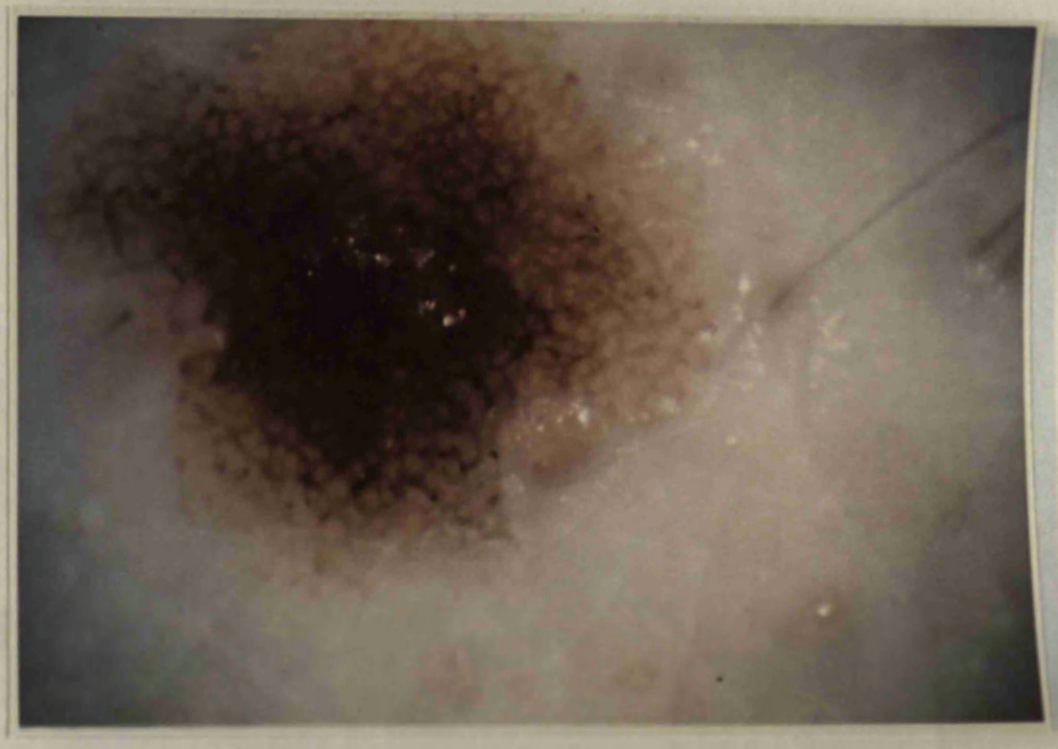

Histology: Early superficial melanocarcinoma.

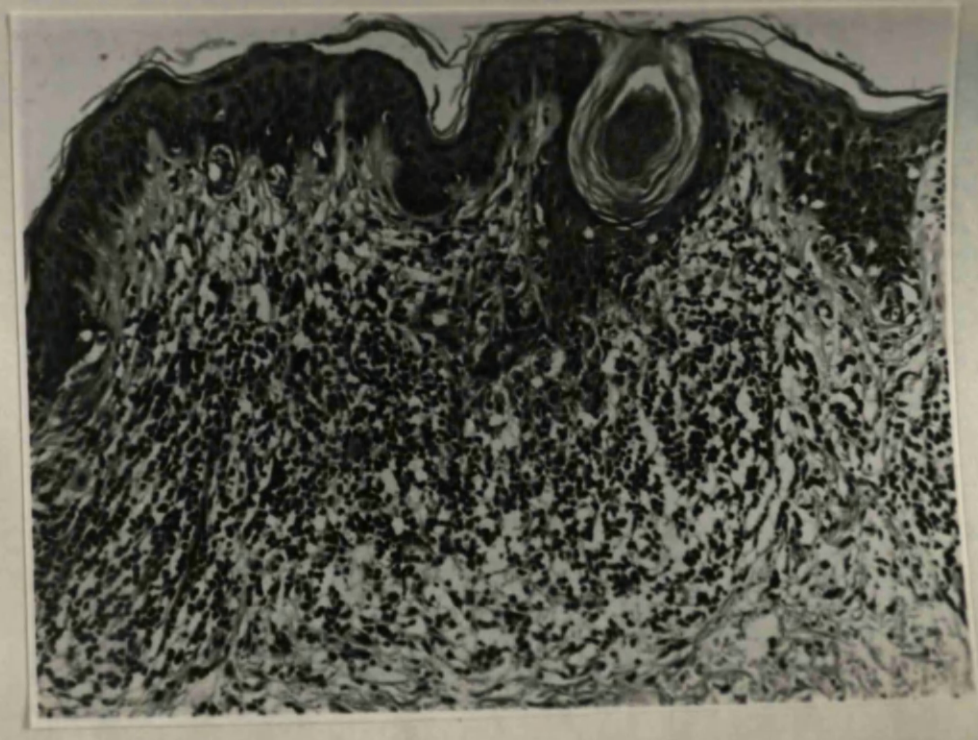

Case 119. Female aged 19 years.

Lesion on anterior chest wall present for past 2 years, recent enlargement.



Histology: Early superficial melanocarcinoma.

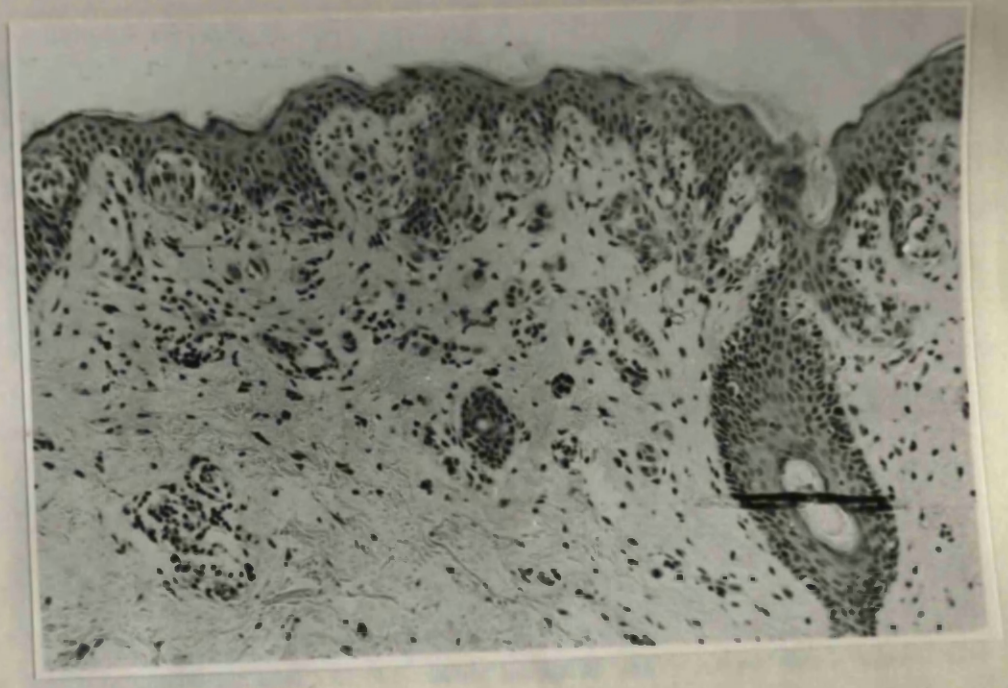

Case 120. Male aged 55 years.

Lesion on sole of right foot present for 4 months, treated with podophyllin.

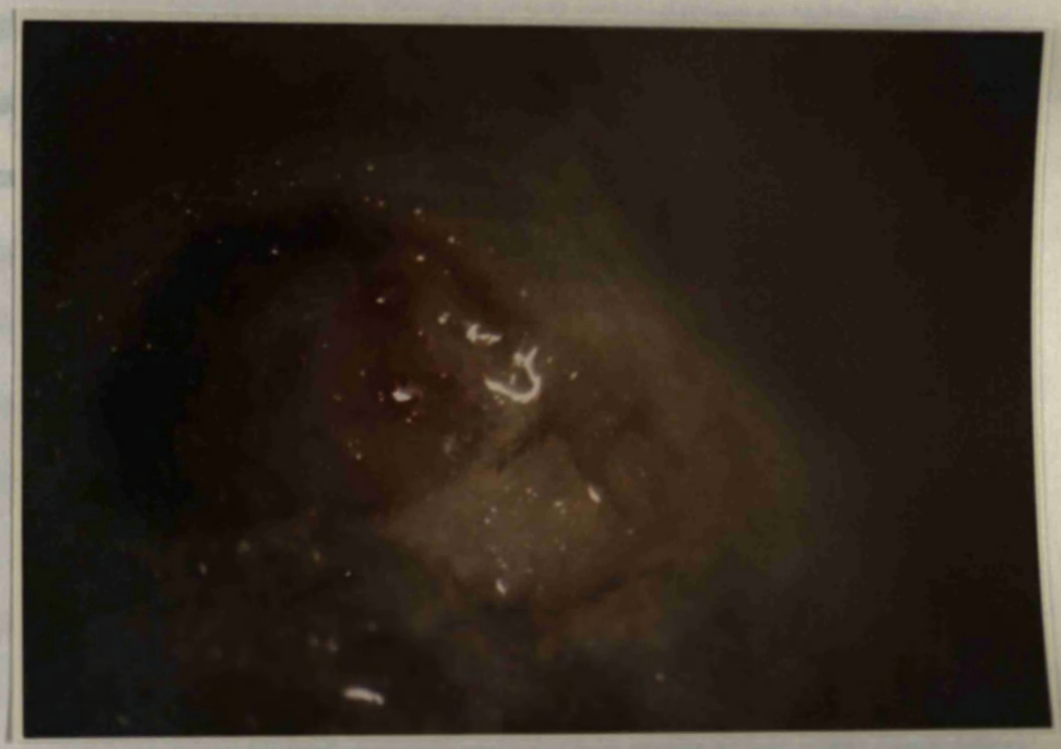

Histology: Ulcerated primary malignant melanoma.

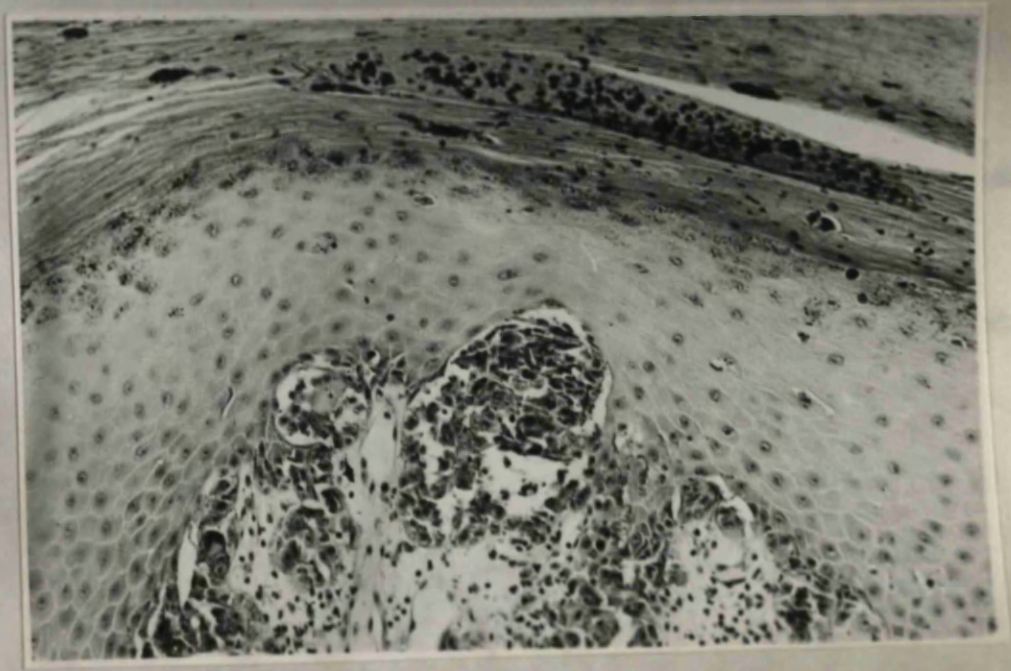

General Comments on the Appearance of the Melanomata

As can be seen, the lesions have illustrated very greatly in density and extent of melanin pigmentation, and comparison of the lesion in vivo with its histology shows no correlation between pigment density and neoplastic activity. There are however several features common to the melanomata in vivo which are useful pre-operative guides in this condition.

Firstly, the pigmentary pattern shows, in common with the junctional and compound naevi a highly irregular scattering of pigment deposits of varying sizes over a uniform paler pigmented background. An additional finding however common to all the melanomata, even those in which pigment is extremely sparse or even absent, is the fact that the surface of all the lesions is raised and irregular. Extreme examples of this are cases 88, 93, 95, 97, 105 and 109 but examination of the very early melanomata for example cases 118 and 119 shows that even in these cases the skin surface is raised. The use of olive oil on the lesions draws attention to this irregularity in addition to giving greater translucency to the epidermis.

A third feature commonly found in melanomata is great variation of colour tone with the one lesion. Cases 84, 89, 90, 98, 99, 114 and 115 all show this phenomenon particularly clearly. An important point in this colour variation is the fact that it is not, as is seen sometimes in compound naevi a lesion with a dark central area

which pales at the periphery, but areas of lack of pigmentation in the central area of the melanoma with a darker halo of melanin pigment at the outer margin of the lesion. This tremendous variation of intensity and distribution of melanin pigmentation in combination with the inflammatory areas which are so often found in these lesions makes it clear that the use of colour photography for recording these lesions is extremely valuable. Although black and white prints might convey some colour variation, and also the surface irregularity of the tumour, its true appearance could not be recorded by this method.

Cases 88, 104, 105, 107, 108 were clinically devoid of melanin pigment, but examination with the operation microscope showed in every one of these cases small amounts of melanin pigment, generally at the outer margin of the lesion. Additional features of these hypomelanotic lesions in vivo are the granulation tissue-like appearance of the central part of the lesion and the extreme friability of this area. As can be seen in cases 107 and 108 preliminary washing and oiling of the surface provoked bleeding.

Case 120 is included to show how badly masked the surface appearance of a melanoma can be with prior incorrect treatment. This lesion had been treated for two months with podophyllin as a plantar wart, and when the patient was eventually sent for examination repeated cleansing removed only some of the medicament.

The spider's web pattern described in the junctional and compound naevi is seen in cases 84, 86, 90, 94, 98, 109, 111 and 118.

The Blue Naevi

Case 121. Female aged 38 years.

Lesion on right forearm present for 15 years, enlarging in past year.

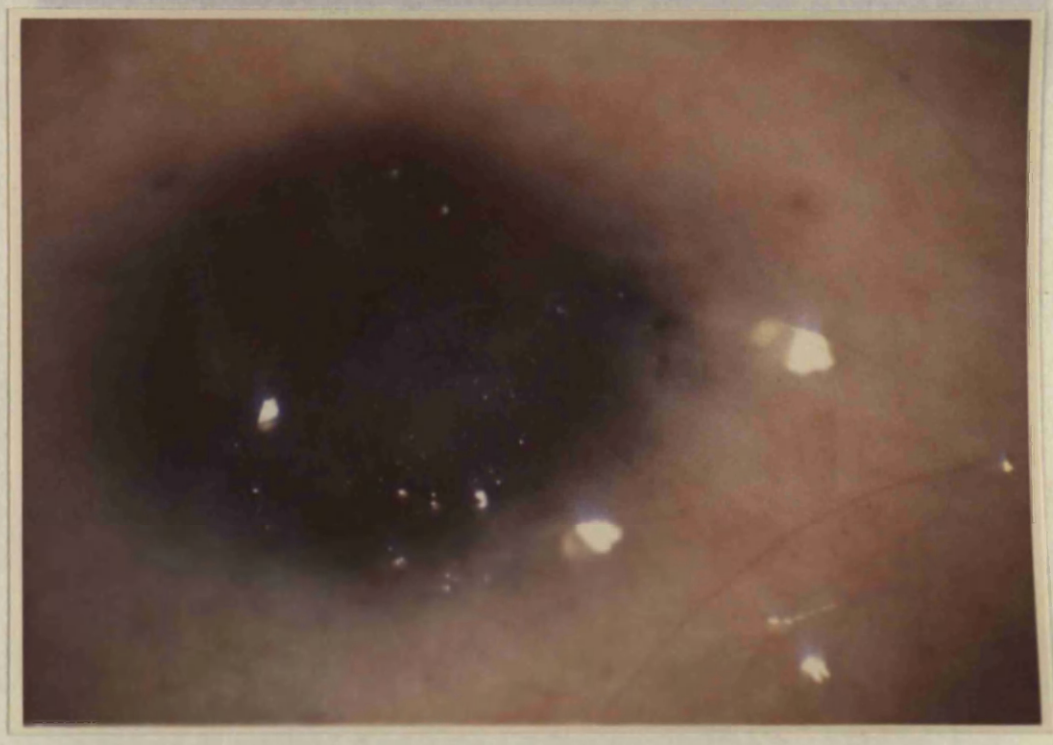

Histology: Epidermis normal. Blue naevus cells in underlying dermis.



Case 122. Female aged 18 years.

Lesion on left upper arm present since birth.

Enlarging in past year.

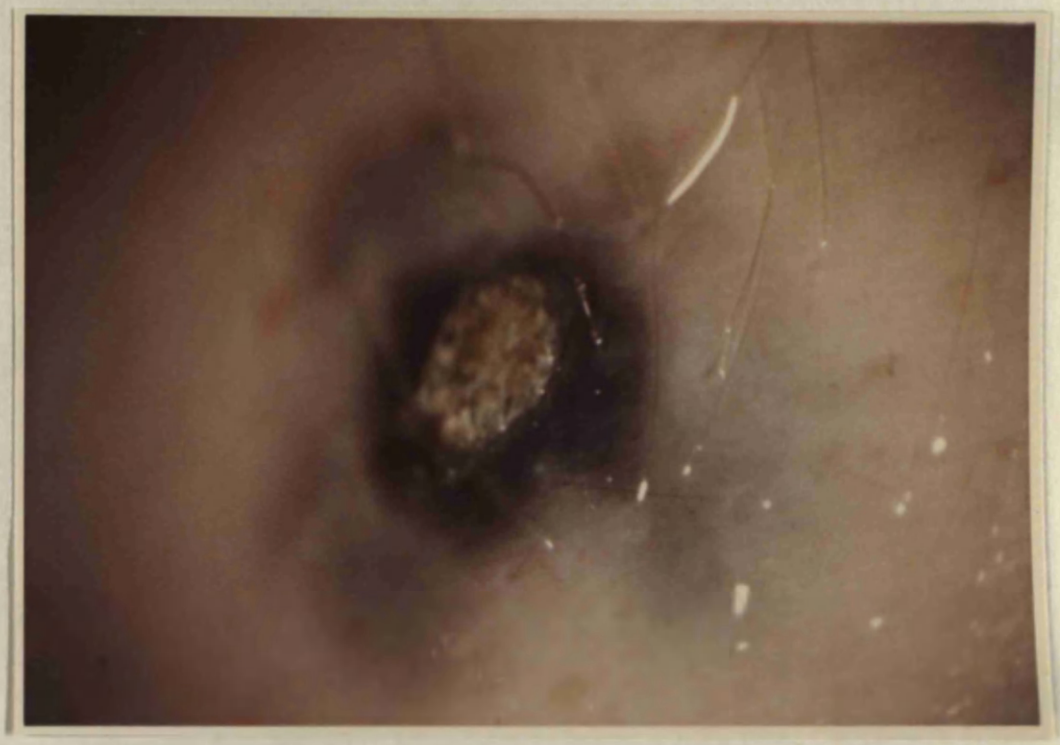

Histology: Sclerotic blue naevus.

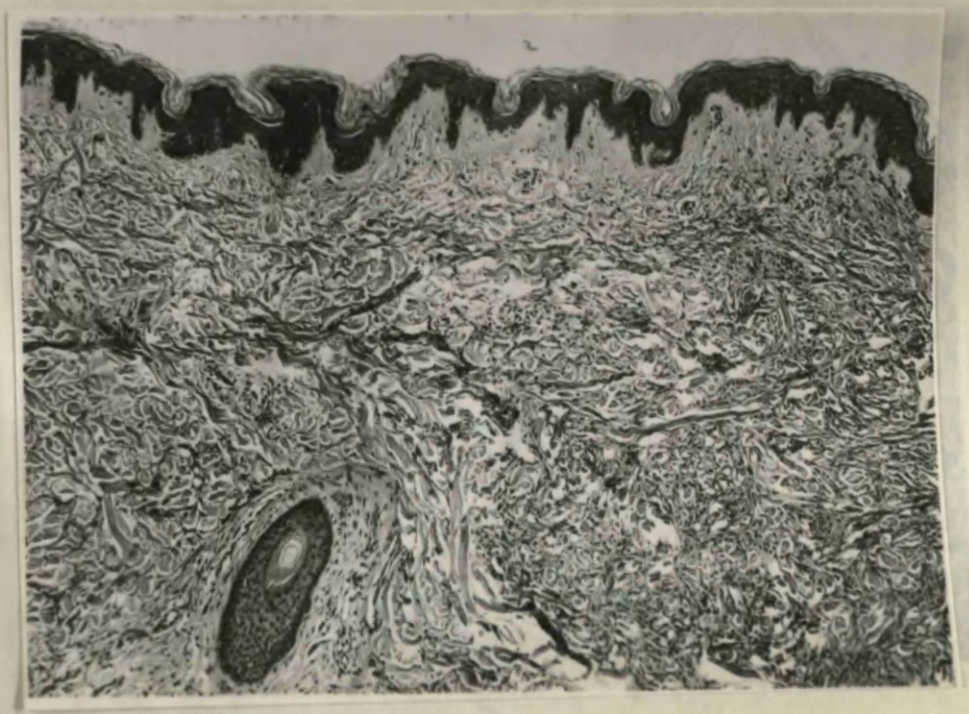

Case 123. Female aged 42 years.

Lesion on left side of chin, present since birth

enlargement in past 2-3 years.

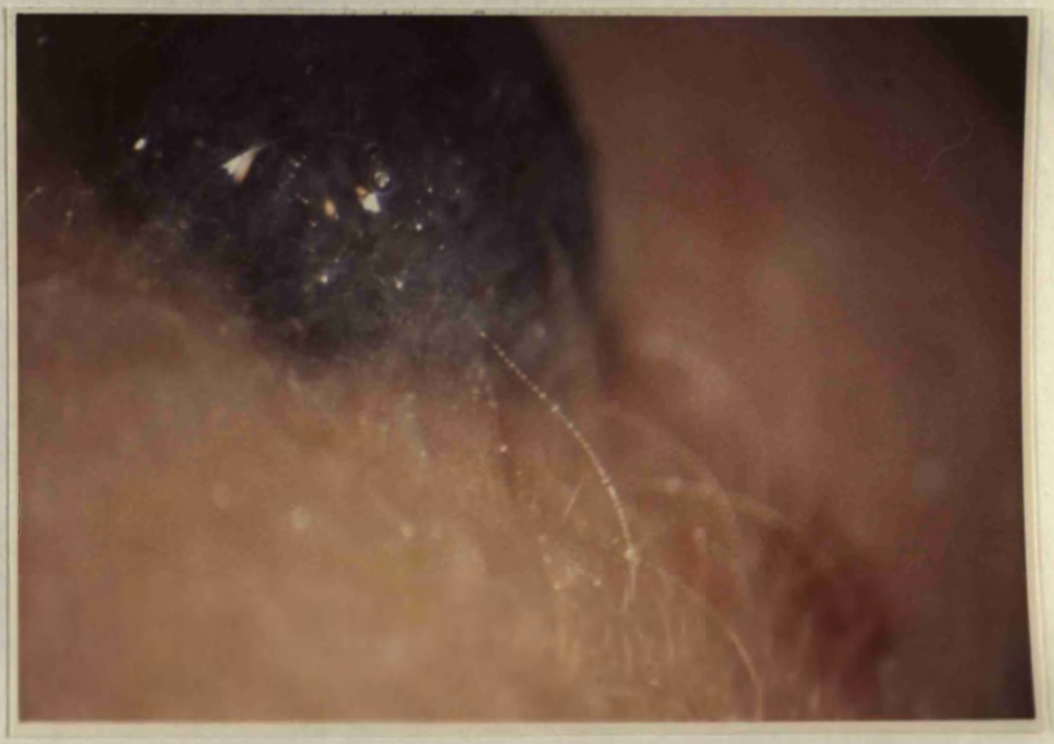

Histology: Heavily pigmented cellular blue naevus.

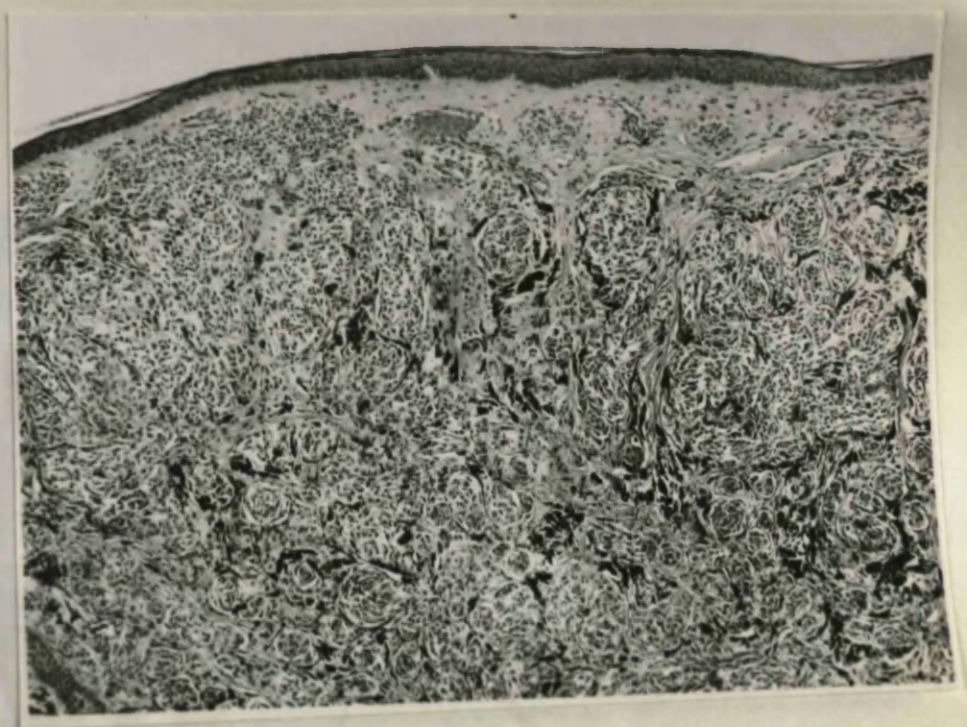

Case 124. Male aged 10 years.

Lesion on left cheek, first noticed one year before examination.

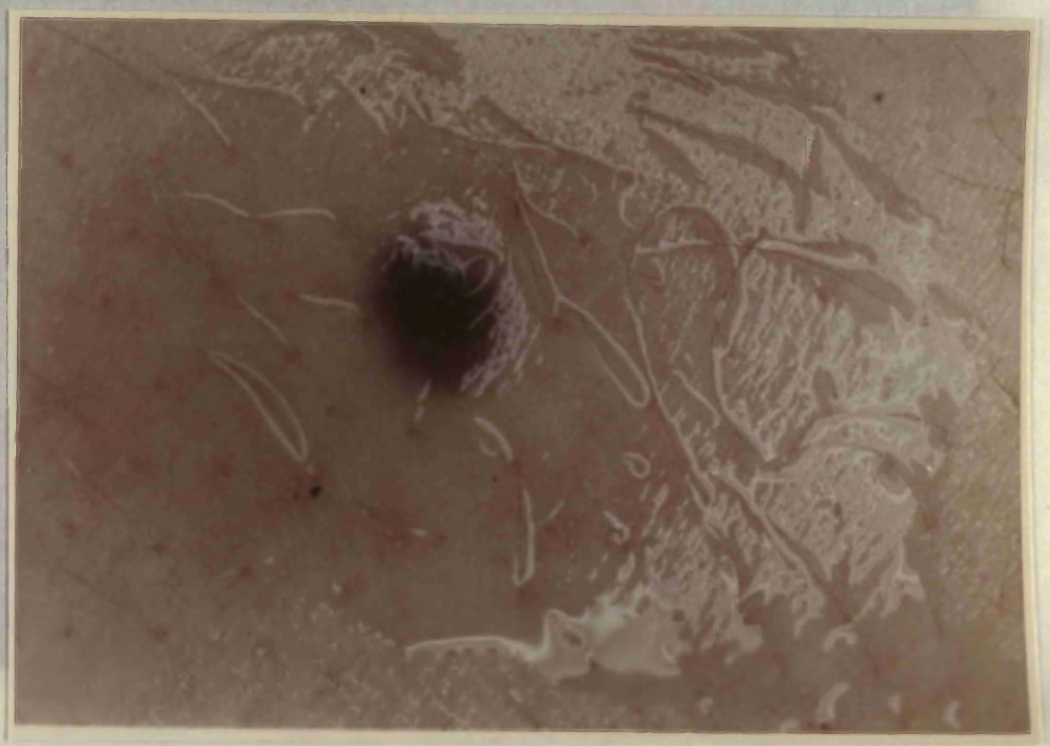

Histology: Normal epidermis. Blue naevus in underlying dermis.



Case 125. Female aged 15 years.

Lesion on tip of nose present for past two years.



Histology: Normal epidermis. Underlying blue naevus cells.

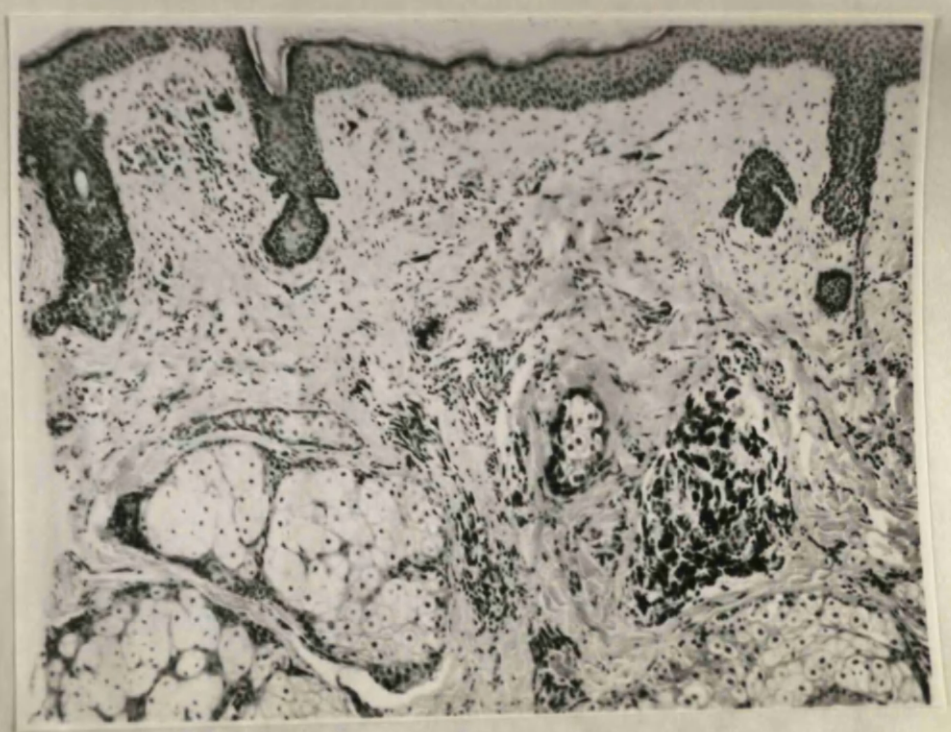

Comments on the Appearance of the Blue Naevi

The colour prints of the magnified blue naevi in vivo show lesions which contain blue-black pigment situated relatively deeply in the dermis; the reason for this statement is that while the highlights caused by the reflection of the flash on olive oil on the surface of the epidermis are crisply in focus, the pigment itself is not. The pigment is uniform in tone, with no superficial overlying darker pigment. The edges of the blue naevi are well defined, and there is no pigmentary irregularity or inflammatory reaction at their margins.

The Intradermal Naevi

Case 126. Female aged 30 years.

Lesion on chin, present since birth.

History of recent enlargement and bleeding.



Histology: Intradermal naevus.

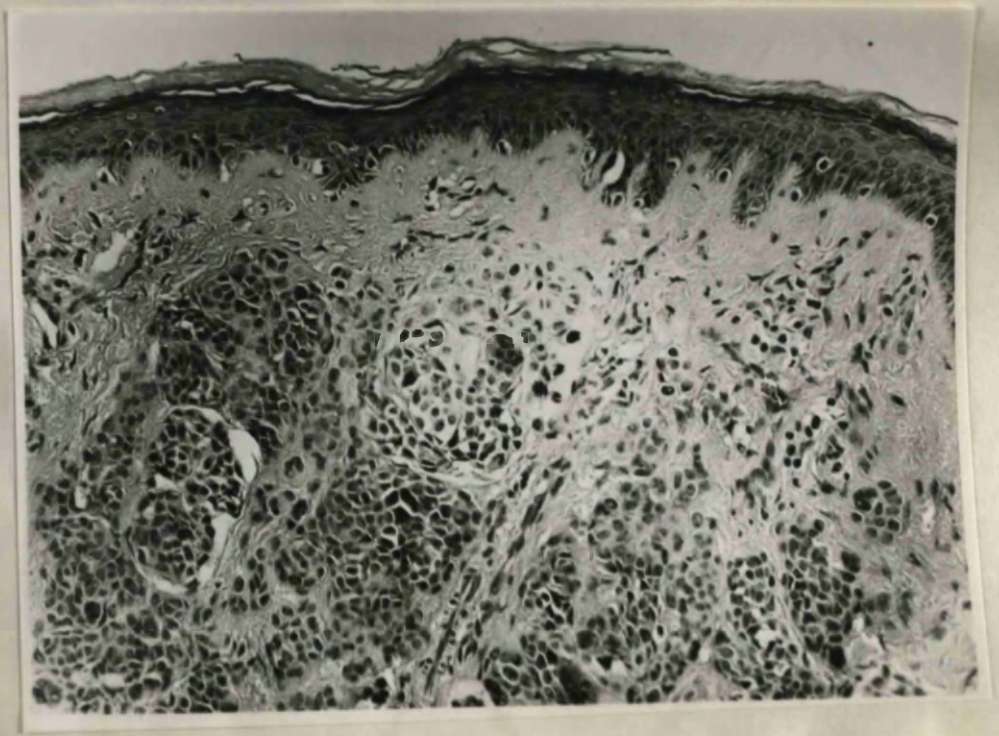

Case 127. Male aged 19 years.

Lesion above upper lip present since birth.



Histology: Intradermal naevus. There are many melanocytes in the overlying epidermis but no actual junctional change.



Case 128. Female aged 38 years.

Lesion on forehead, present for 20 years, growing slowly.

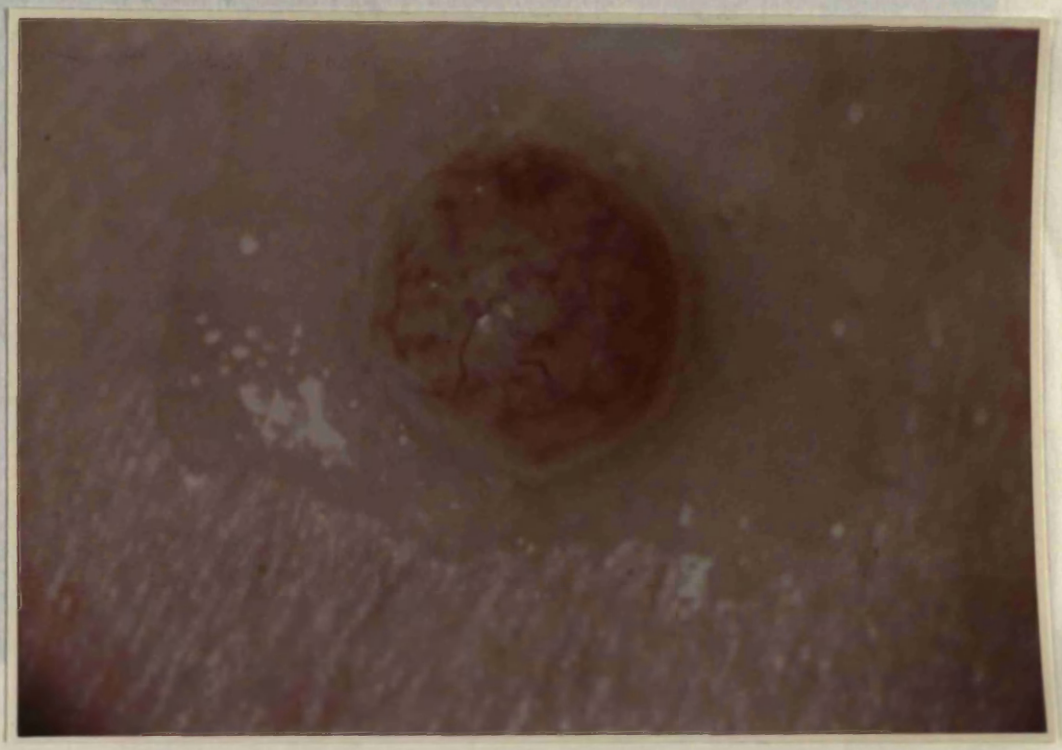

Histology: Intradermal naevus.

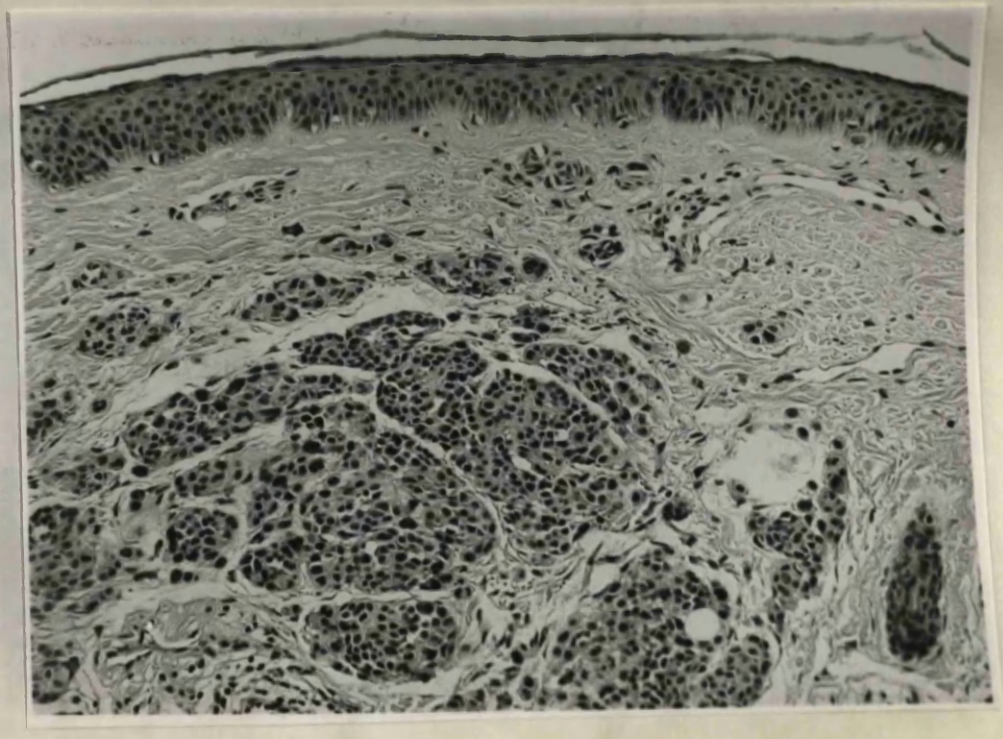

Case 129. Female aged 20 years.

Lesion above upper lip present since birth.

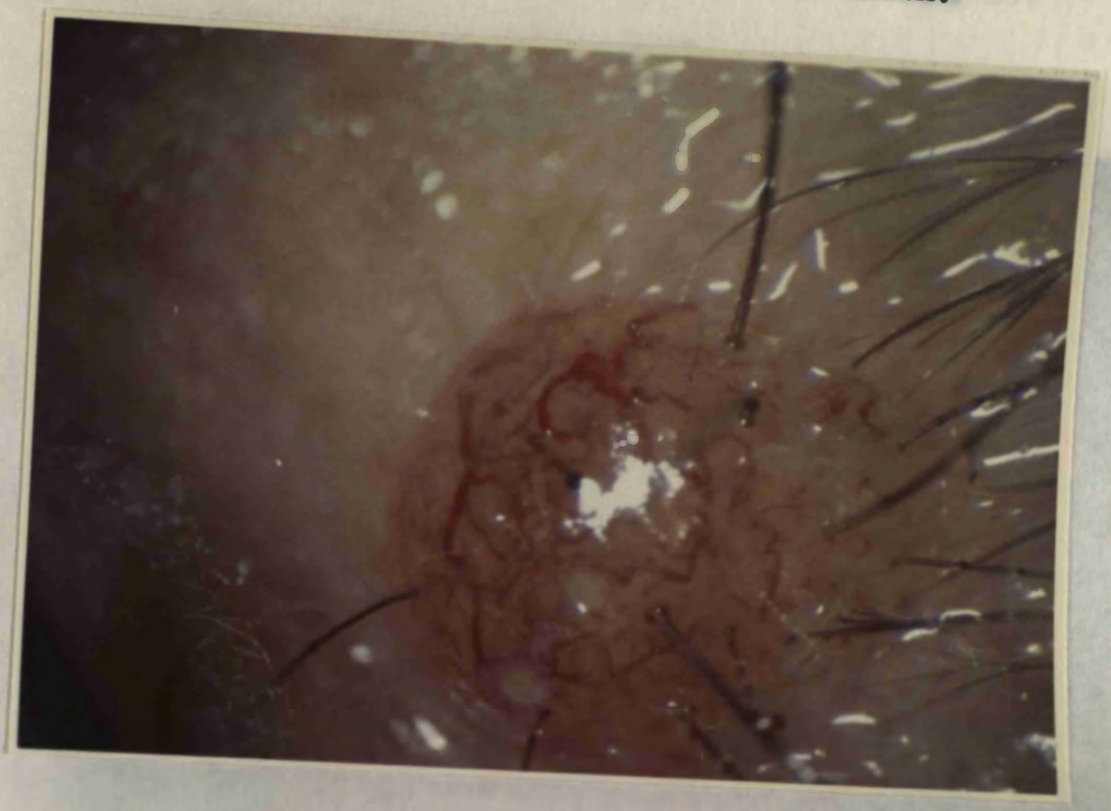

Histology: Intradermal naevus with many hair follicles present.



Case 130. (same patient as 129).

Lesion on left nostril present since birth.

History of recent enlargement.

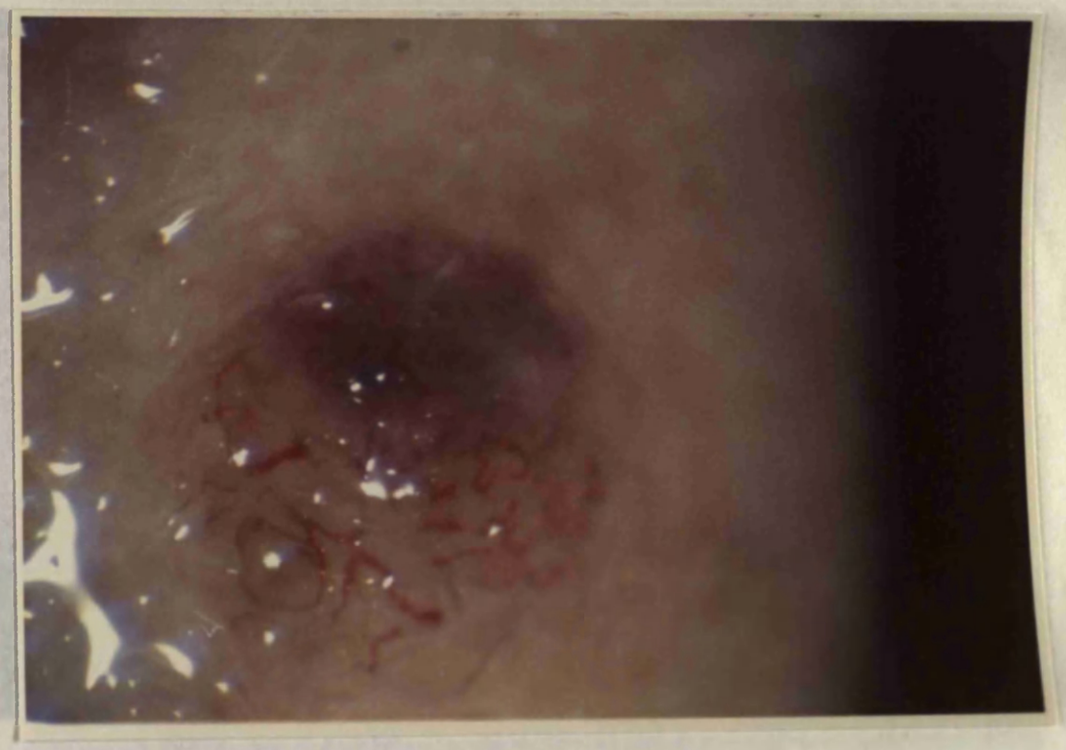

Histology: Intradermal naevus.

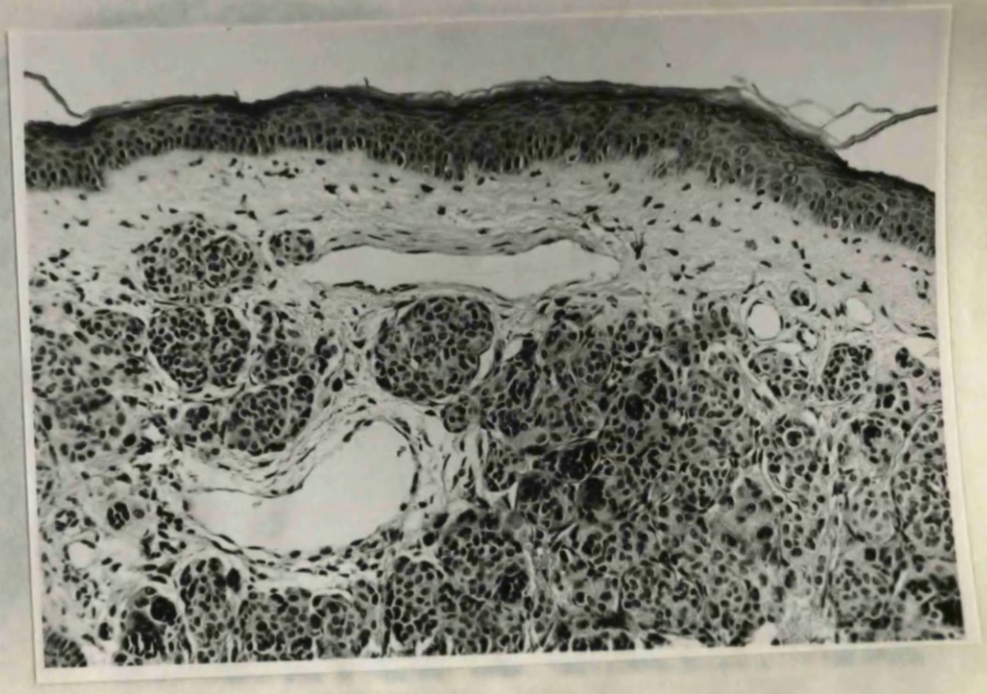

Case 131. Female aged 24 years.

Lesion above right eyebrow present for at least 15 years, history of growth in past year.

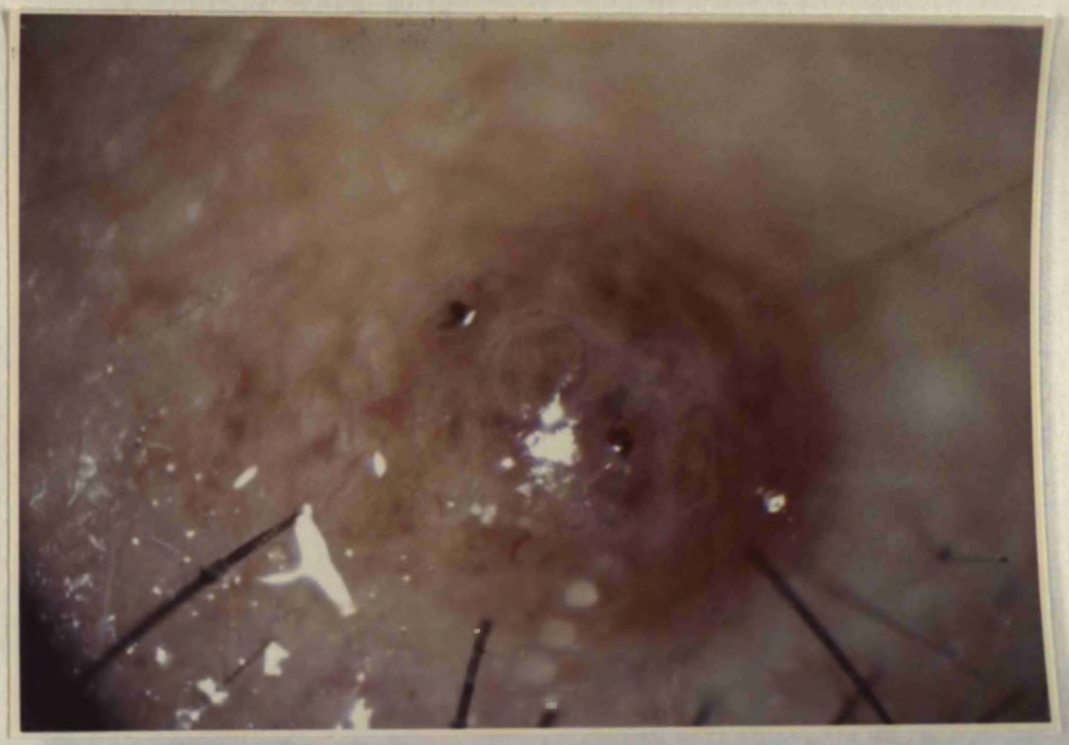

Histology: Intradermal naevus.

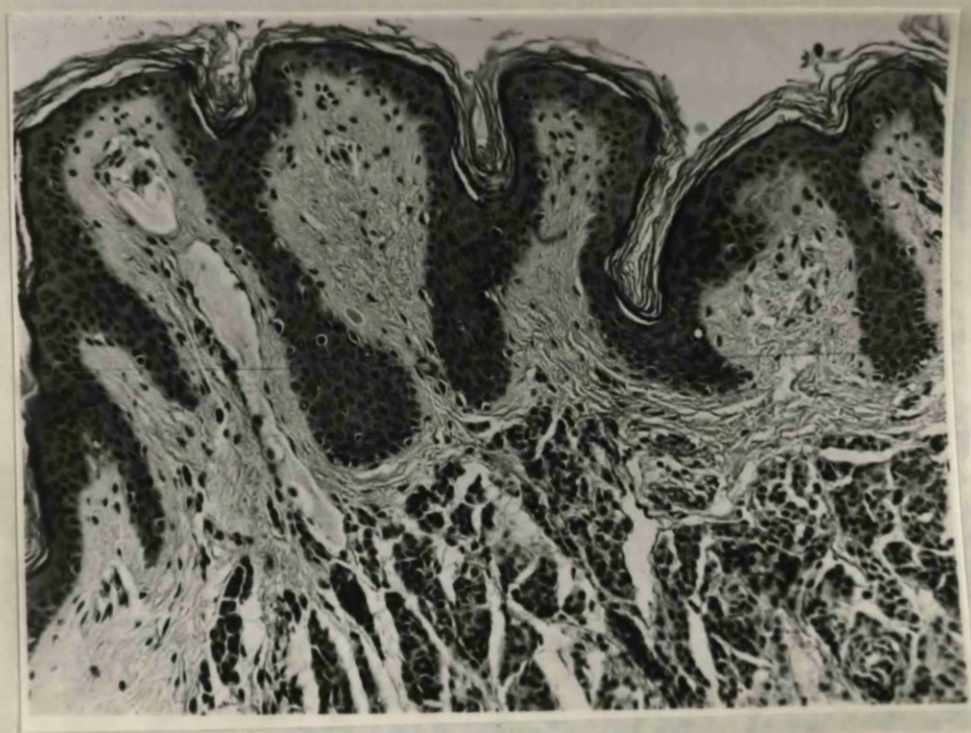

Case 132. Female aged 28 years.

Lesion on nape of neck present since birth.

History of recent irritation with comb and subsequent anxiety.

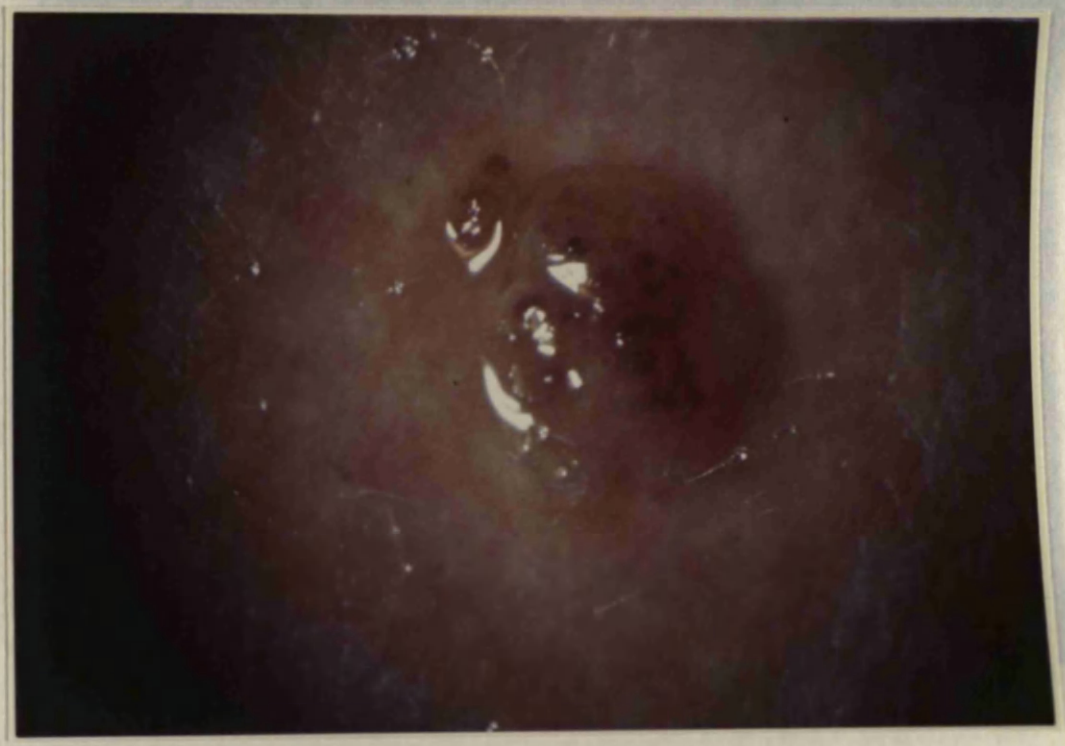

Histology: Intradermal naevus.

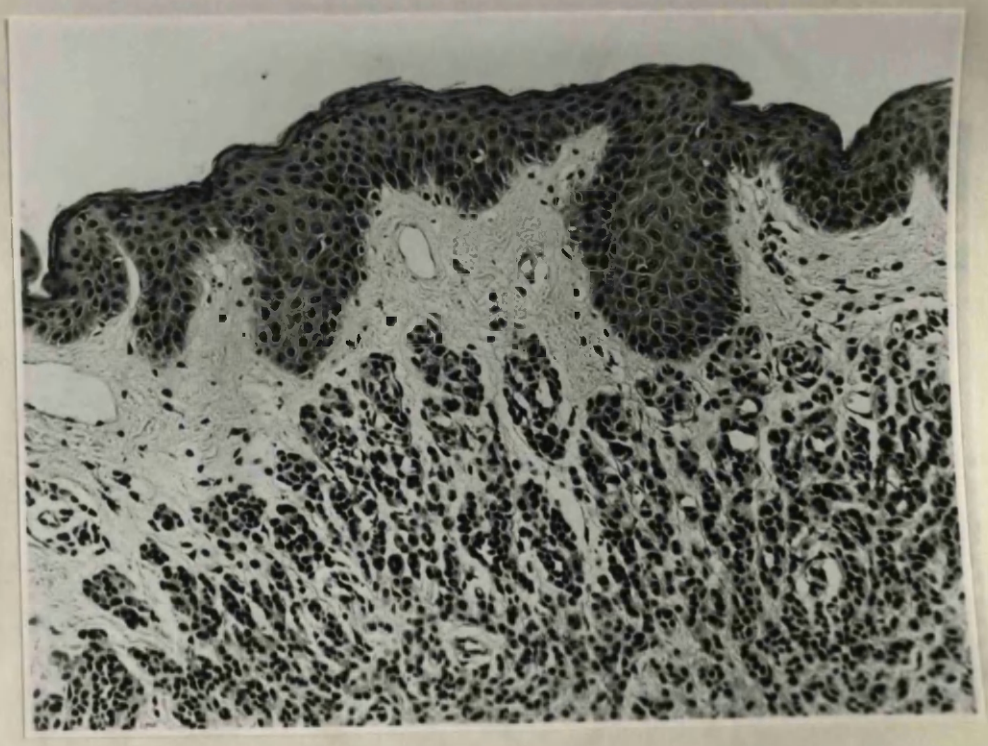

Case 133. Female aged 21 years.

Lesion on front of neck present since birth.

History of recent enlargement.



Histology: Intradermal naevus.

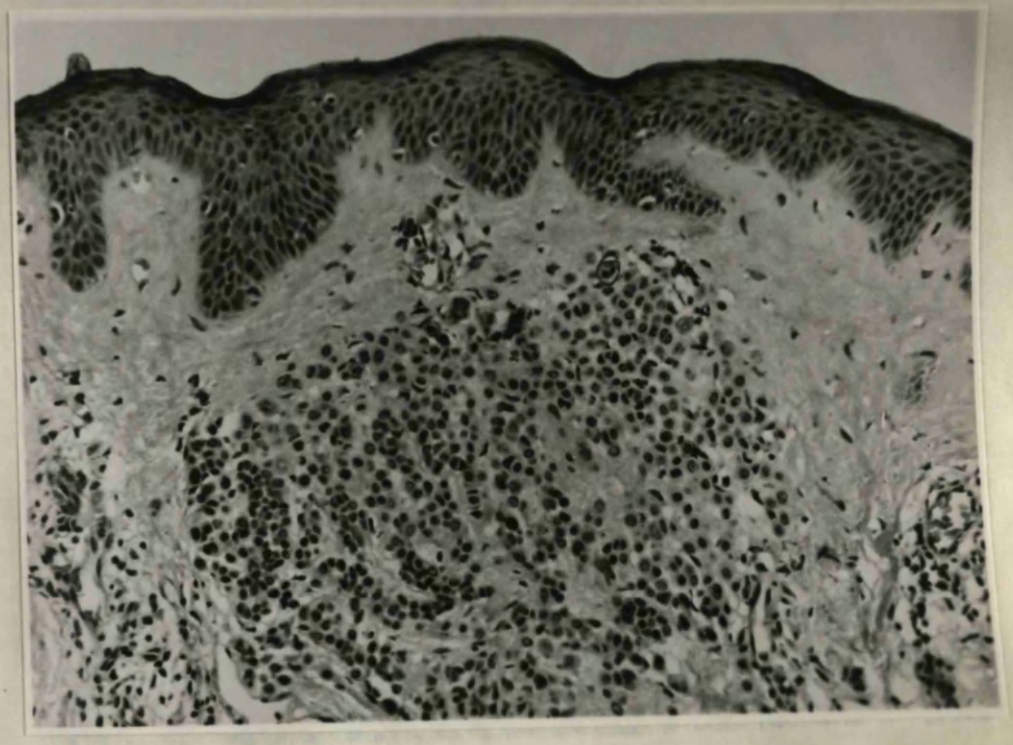

Case 134. Female aged 19 years.

Lesion on left side of forehead.

Present since birth, history of slow enlargement.

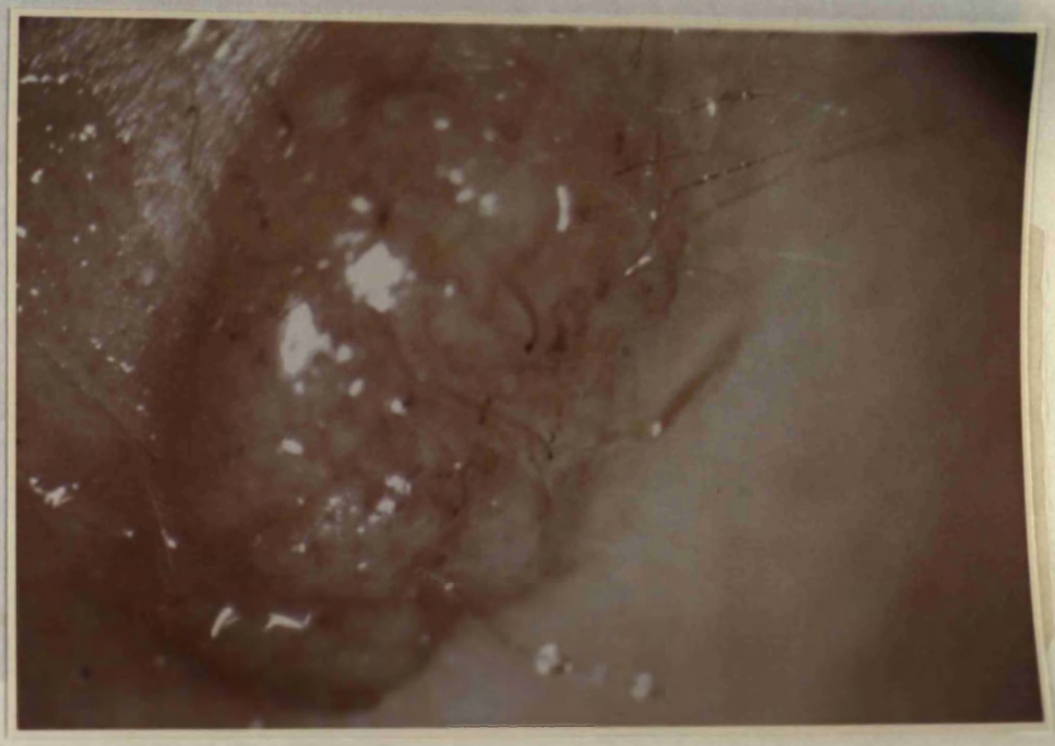

Histology: Intradermal naevus.

Many melanocytes in overlying dermis but no junctional change.

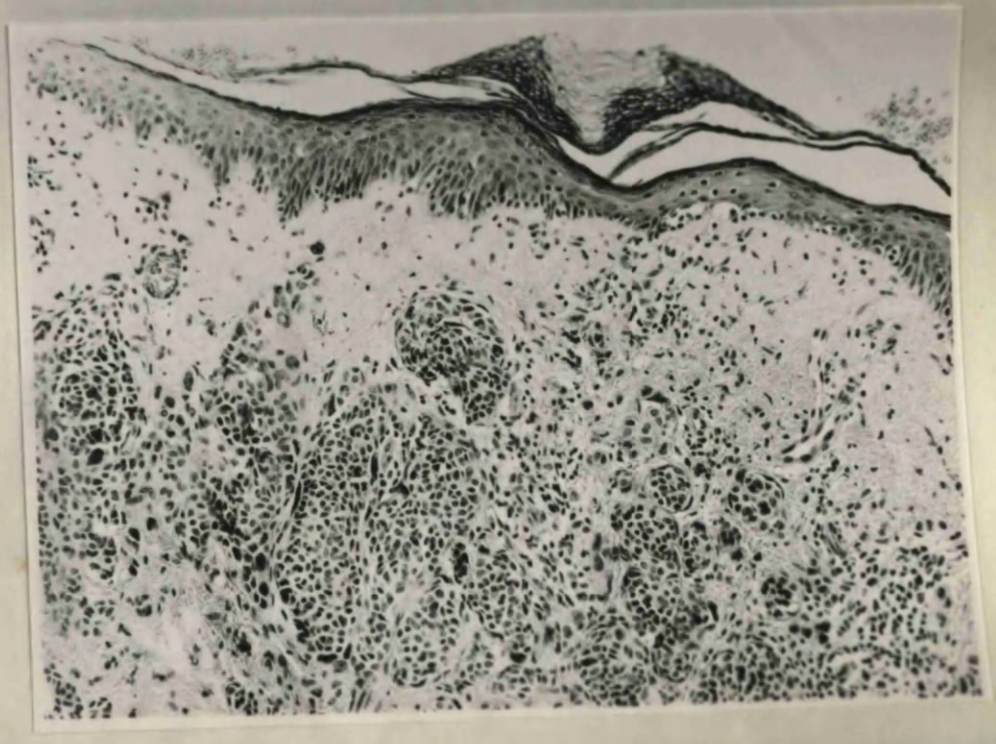

Case 135. Female aged 25 years.

Lesion on chin present since birth.



Histology: Intradermal naevus.

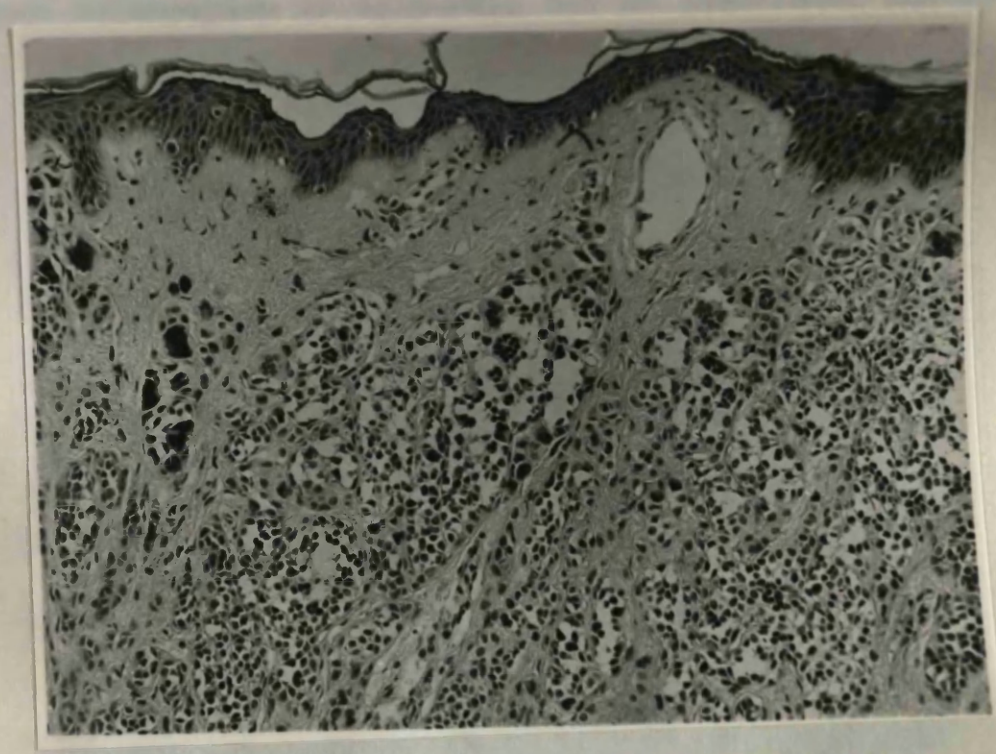

Case 136. Male aged 44 years.

Lesion on mid-forehead present since birth.

History of recent bleeding.

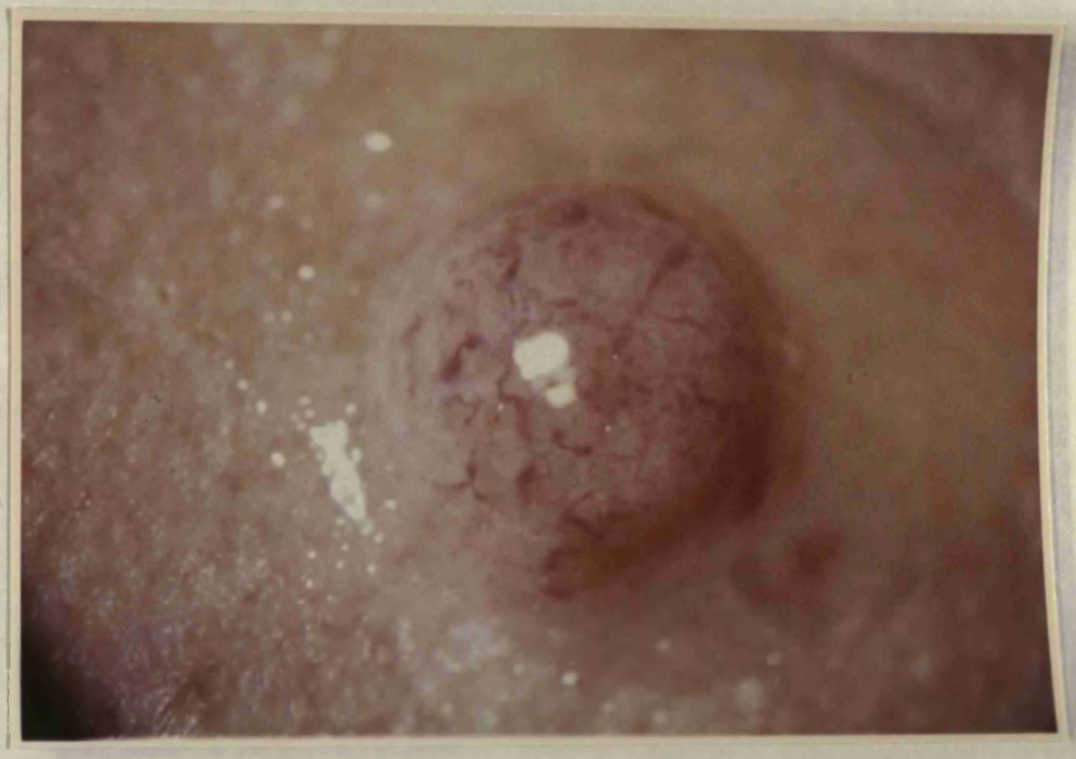

Histology: Intradermal naevus.

Large melanocytes in epidermis but no junctional change.

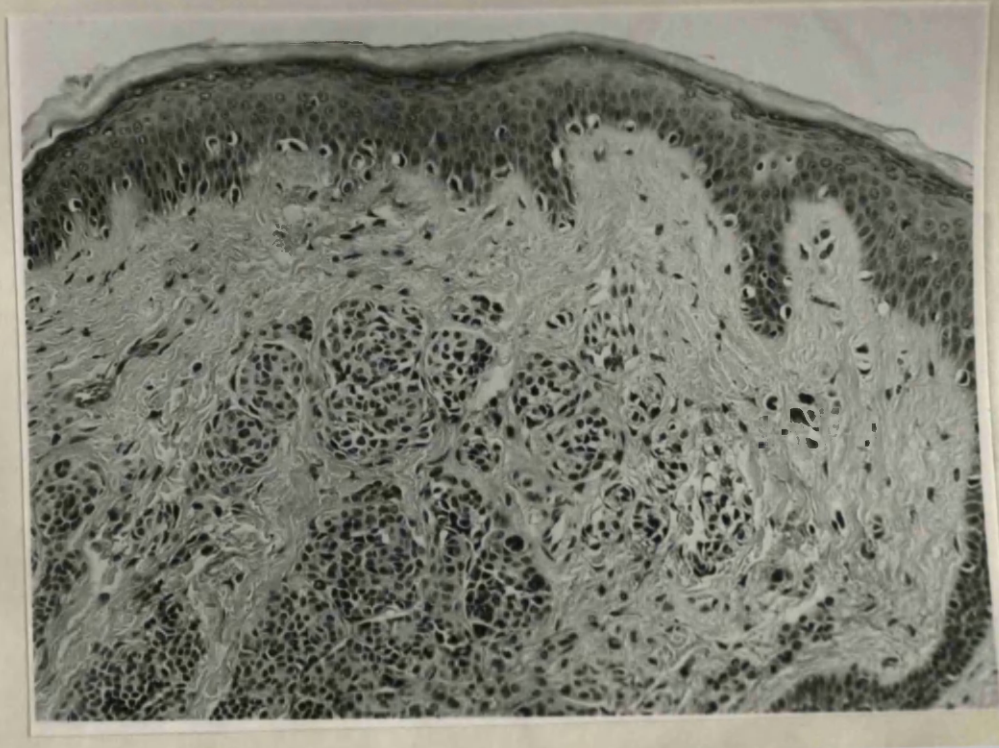

Case 137. Female aged 40 years.

Lesion on left cheek present for at least 5 years.

History of recent enlargement.

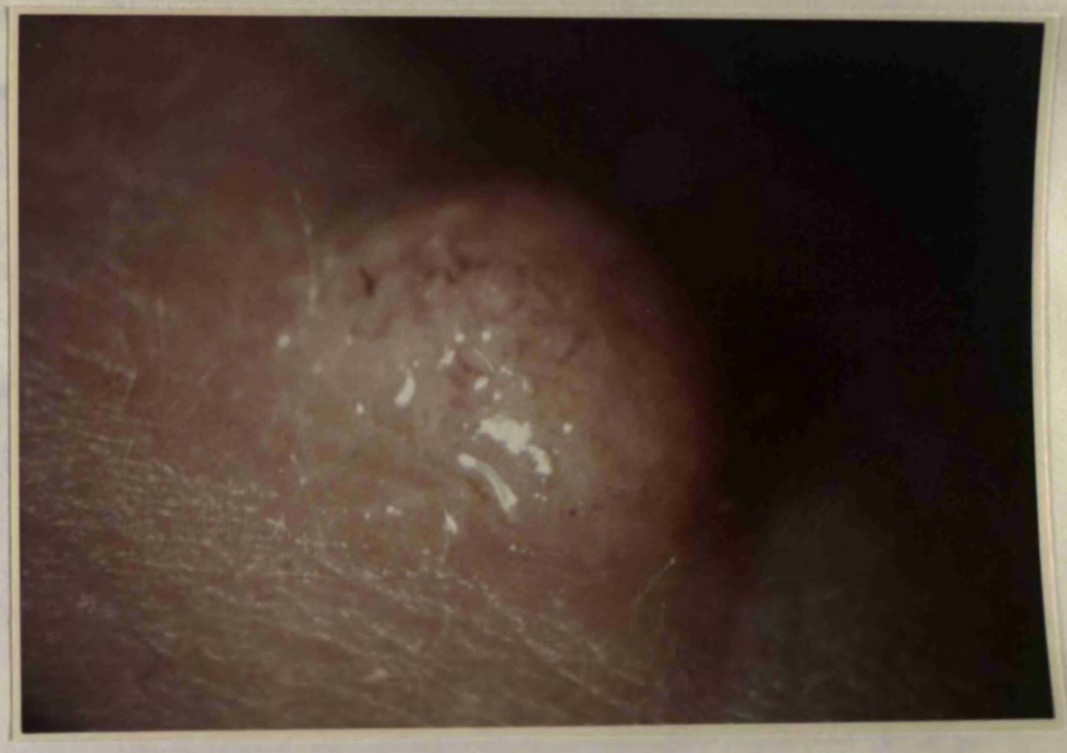

Histology: Intradermal naevus.

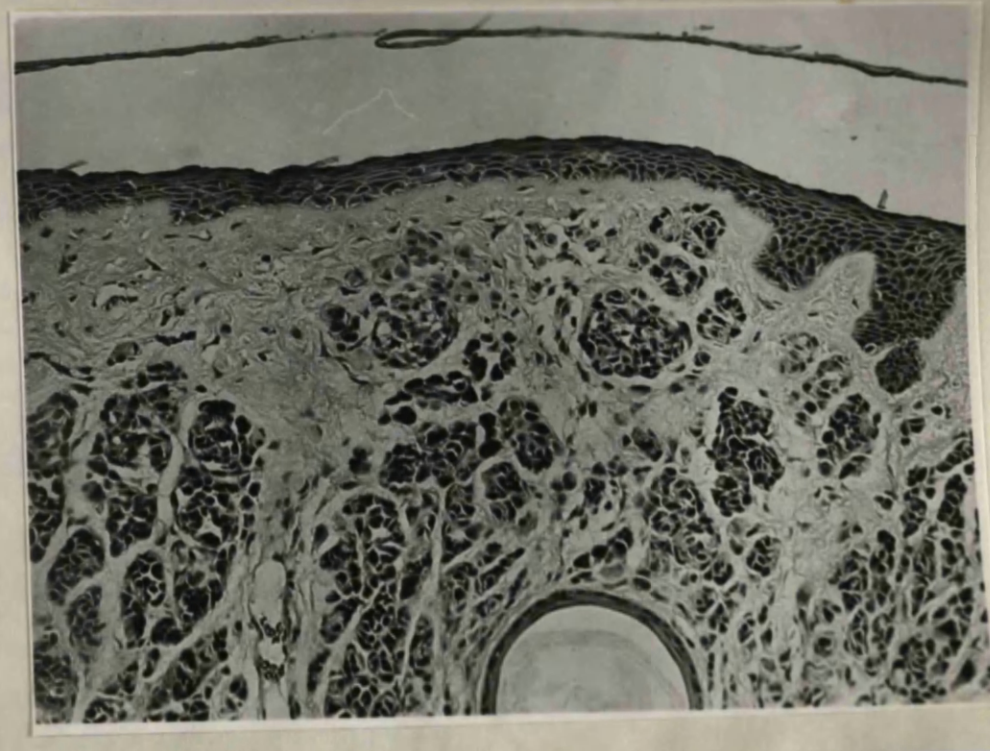

General Comments on the Intradermal Naevi

The intradermal naevus in vivo is a lesion clearly raised above the surrounding skin surface. Tortuous capillaries are clearly visible on the surface of the naevi, 5 of which show strong hair growth. None of the lesions are heavily pigmented, and in the 9 which do show some melanin pigmentation, the deposits are scattered and appear to be situated relatively deeply in the dermis as the reflections caused by the flash on the olive oil are crisply in focus while the pigment deposits are not. None of the intradermal naevi show the irregular superficial melanin pigment lying above more deeply deposited pigment such as is seen in those lesions exhibiting junctional activity.

The Cavernous Angiomata

Case 138. Male aged 24 years.

Lesion on right lumbar area first noticed one week previously.



Histology: Cavernous angioma.

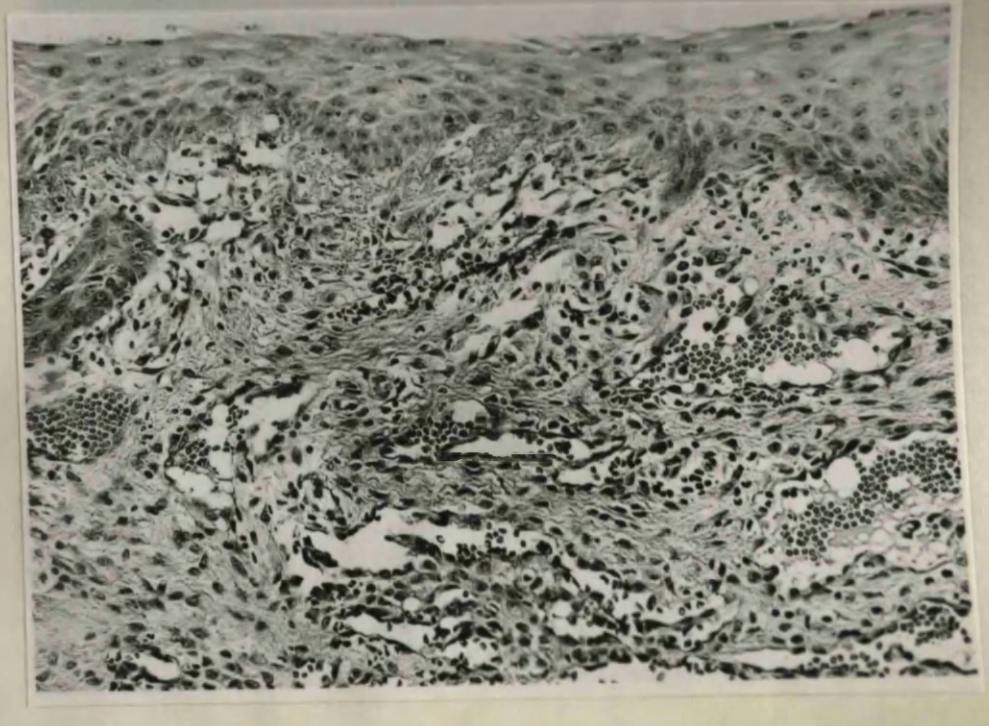

Case 139. Female aged 27 years.

Lesion on front of left wrist, present since birth.



Histology: Cavernous angioma.

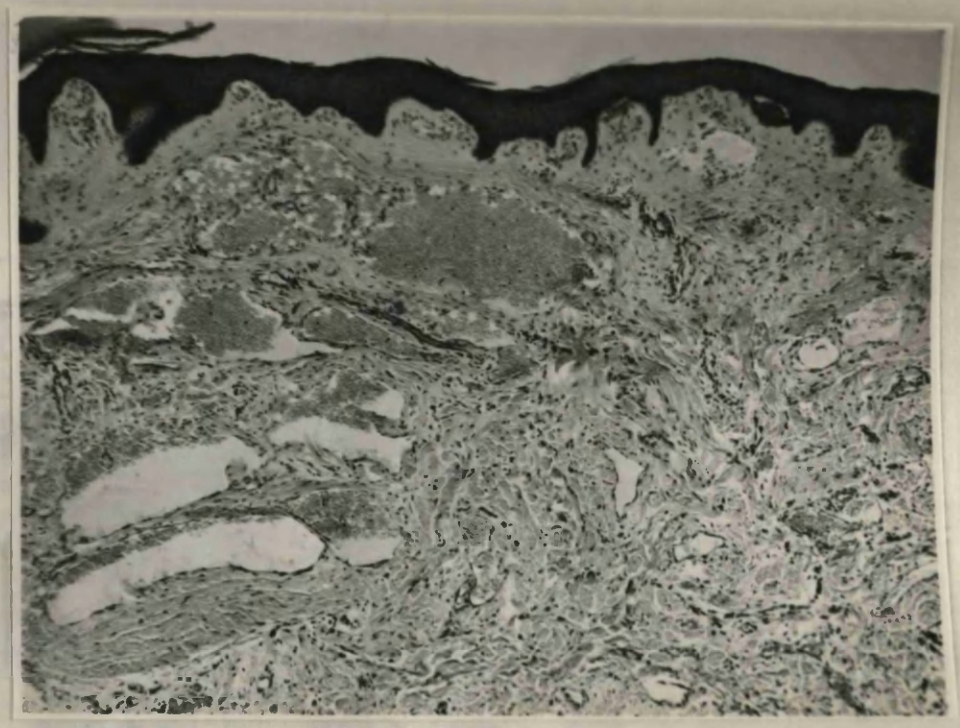

Case 140. Female aged 17 years.

Lesion on inner aspect of knee, present for at least 3 years.



Histology: Cavernous angioma.



Case 141. Female aged 44 years.

Lesion on posterior aspect of leg, present for two years. Patient has erythema ab igne.

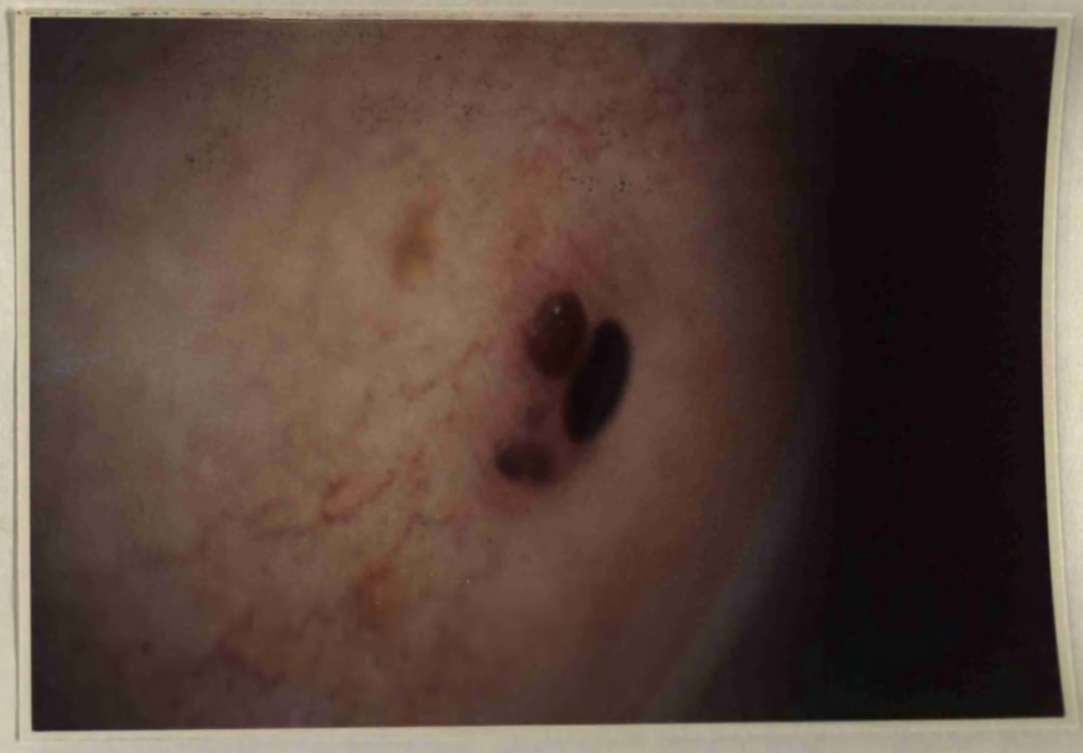

Histology: Cavernous angioma.



Case 142. Female aged 58 years.

Lesion on posterior aspect of right calf present for 3 years. History of frequent bleeding.



Histology: Cavernous angioma.



Case 143. Male aged 24 years.

Lesion on right eyelid, first noticed one week previously.



Histology: Cavernous angioma.



Case 144. Female aged 50 years.

Lesion at right outer canthus present for at least 20 years.

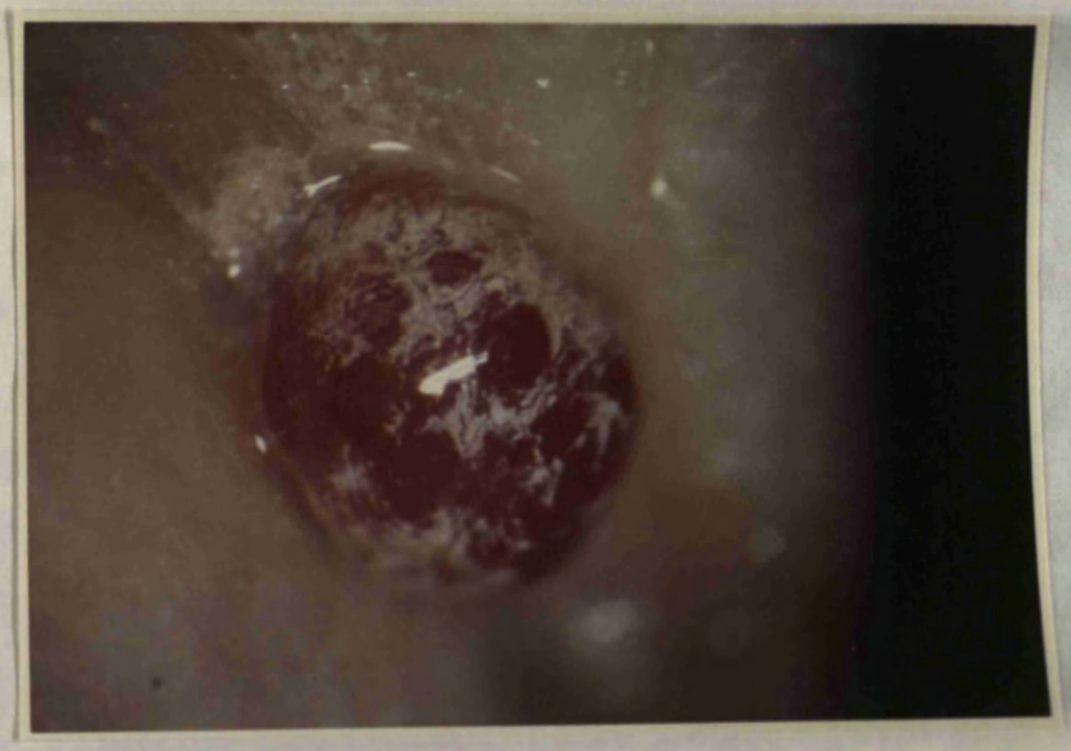

Histology: Cavernous angioma.

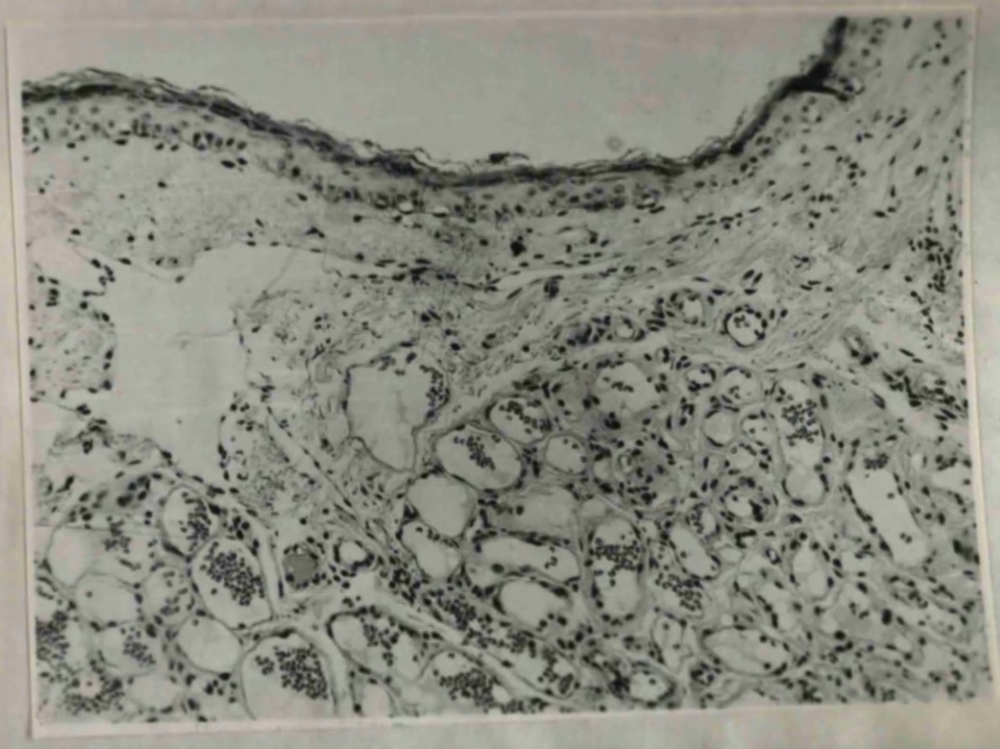

Case 145. Female aged 52 years.

Lesion present on centre of forehead for past three months.

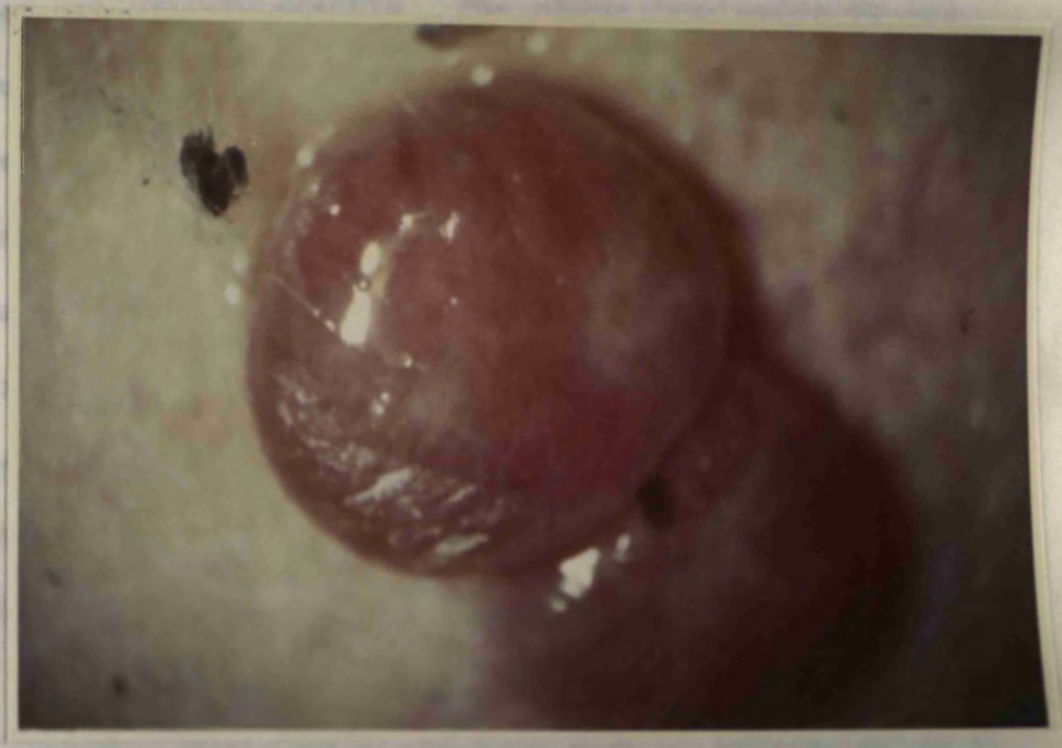

Histology: Cavernous angioma.

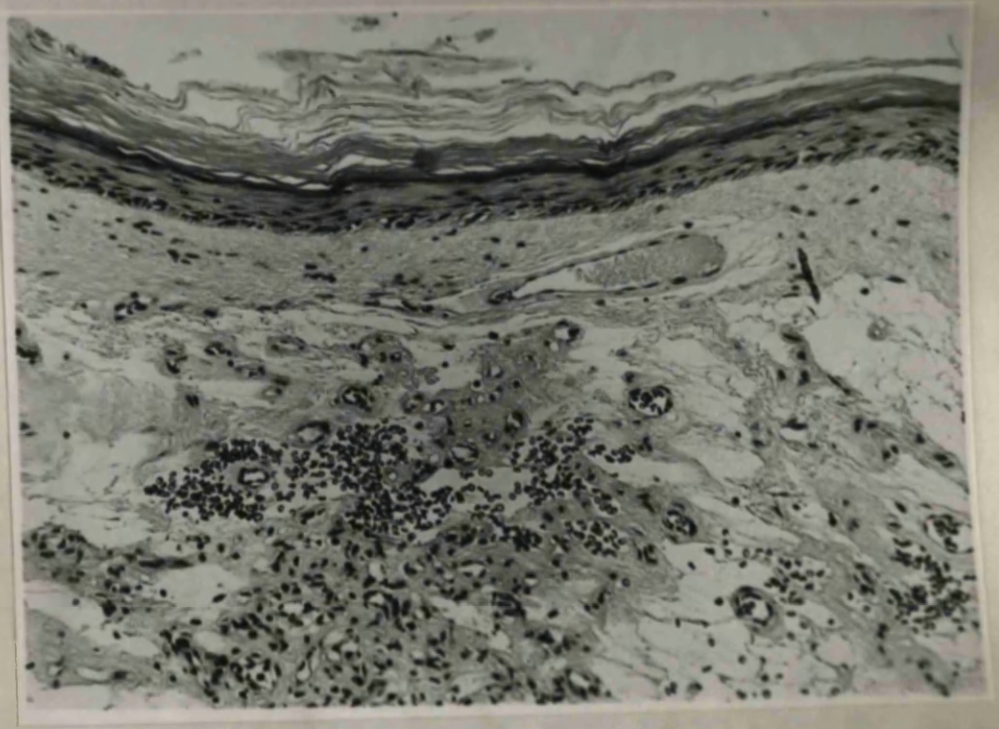

General Comments on the Cavernous Angiomata

In the first four cavernous angiomata here illustrated (cases 138-141) the blood clots lying high in the dermis in the cavernous spaces are clearly visible. The other four cases do not show this feature but appear as raised red lesions on the epidermal surface. There is a conspicuous absence of brown melanin pigmentation in the lesions, and with the exception of case 141 who had severe erythema ab igne there is a surprising lack of capillaries visible on or round the angiomata.

Cases 144 and 145 might on superficial examination be confused with amelanotic melanomata although the length of time for which the lesion had been present would be against this in case 144, but comparison of these two lesions with the hypomelanotic melanomata shows in the cavernous angiomata a complete lack of visible melanin pigment and also of the granulation-tissue pattern which is seen on the surface of the ulcerated melanomata with little pigment present.

The Sclerosing Angiomata

Case 146. Male aged 42 years.

Lesion in left popliteal fossa first noticed

10 weeks ago.



Histology: Sclerosing angioma.



Case 147. Female aged 47 years.

Lesion on right calf first noticed five years ago.

Hard on palpation.

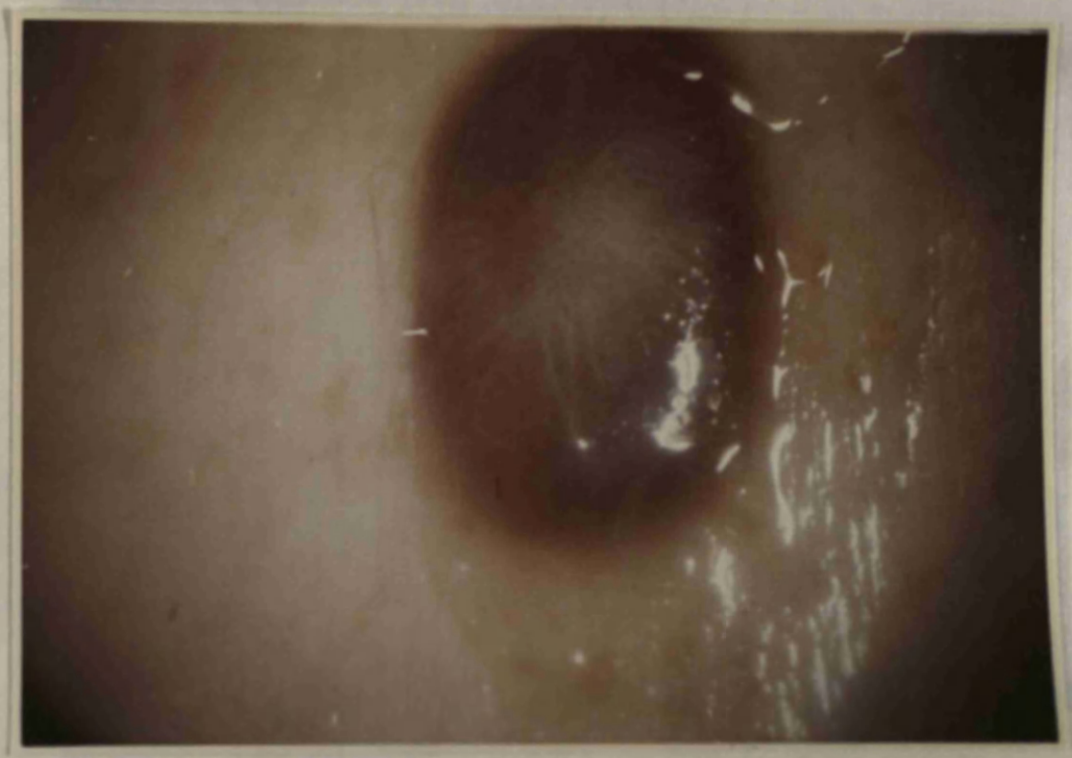

Histology: Sclerosing angioma.

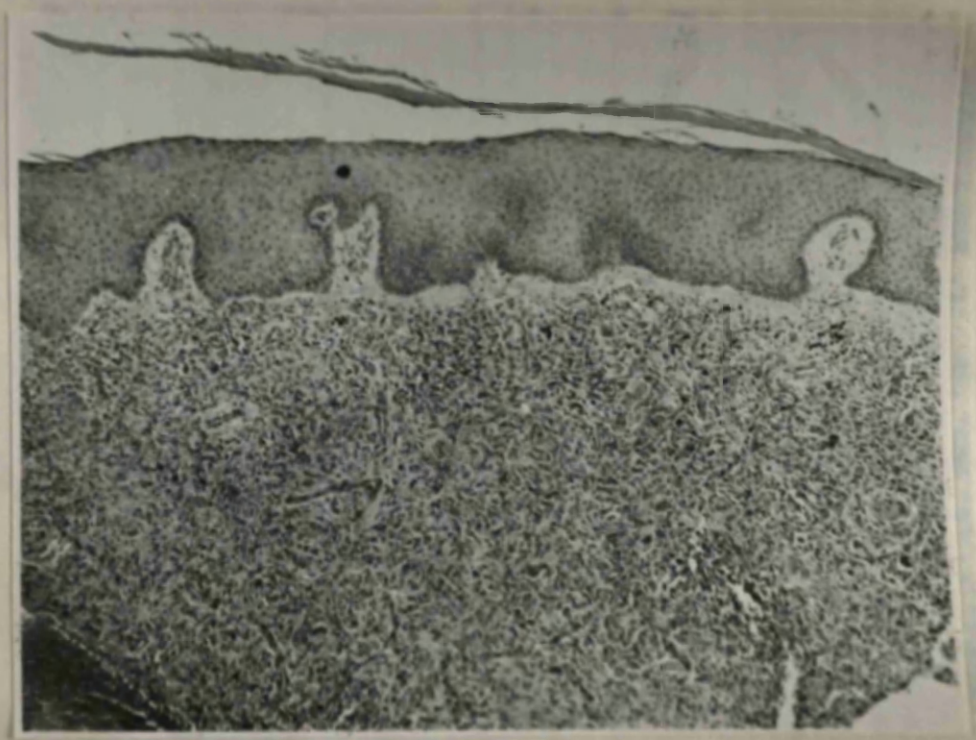

Case 148. Female aged 38 years.

Lesion on dorsum of foot present for past 3 years.

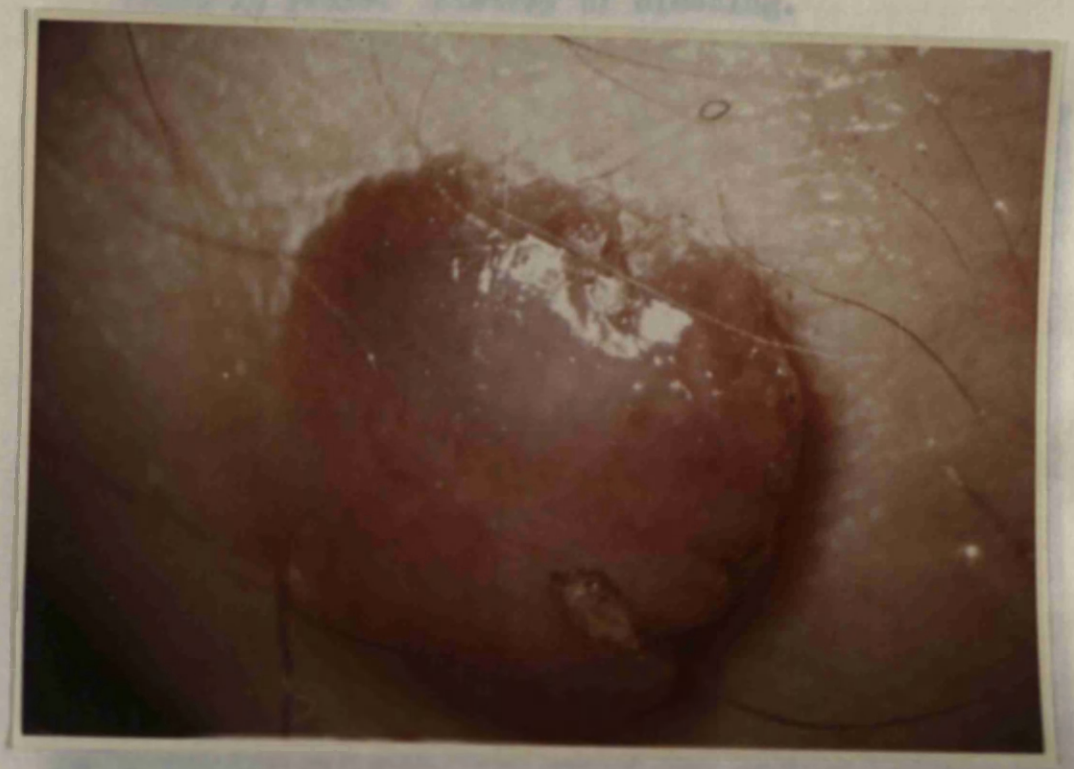

Histology: Sclerosing angioma.

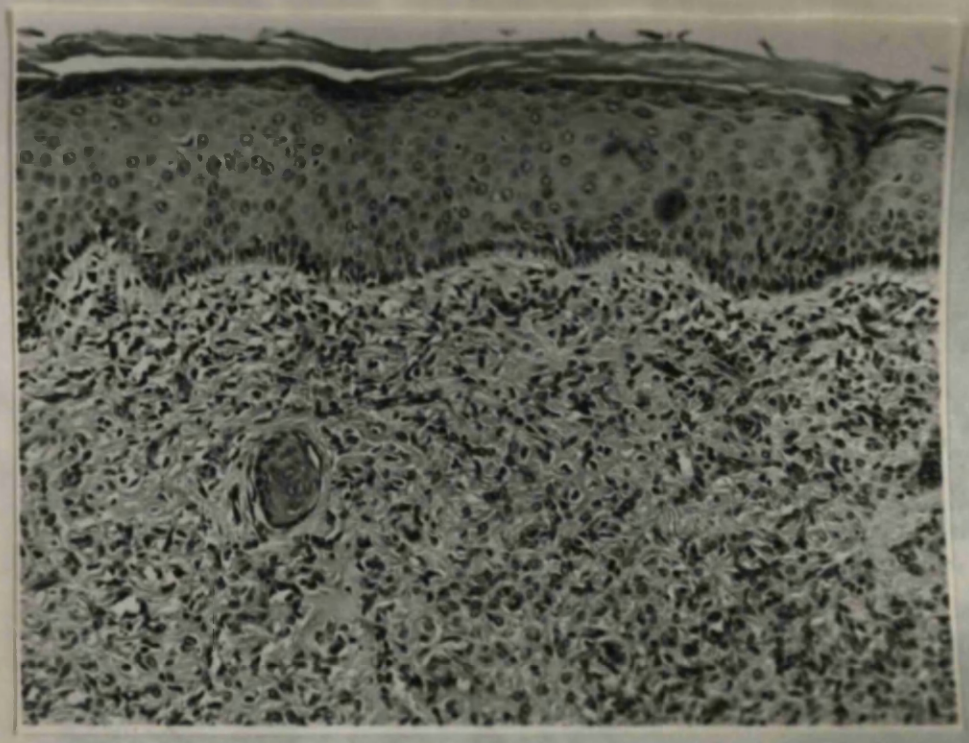

Case 149. Female aged 60 years.

Lesion on outer aspect lower leg present for at least 15 years. History of bleeding.



Histology: Sclerosing angioma.

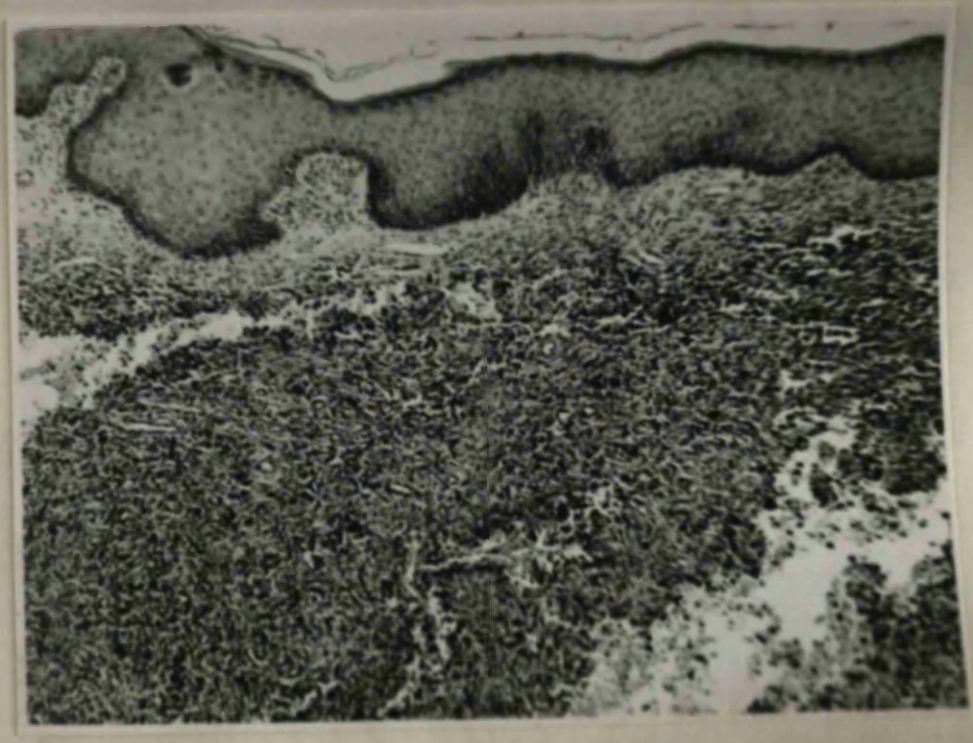

Case 150. Female aged 61 years.

Lesion on left upper arm present for at least 10 years. Hard on palpation.



Histology: Sclerosing angioma.

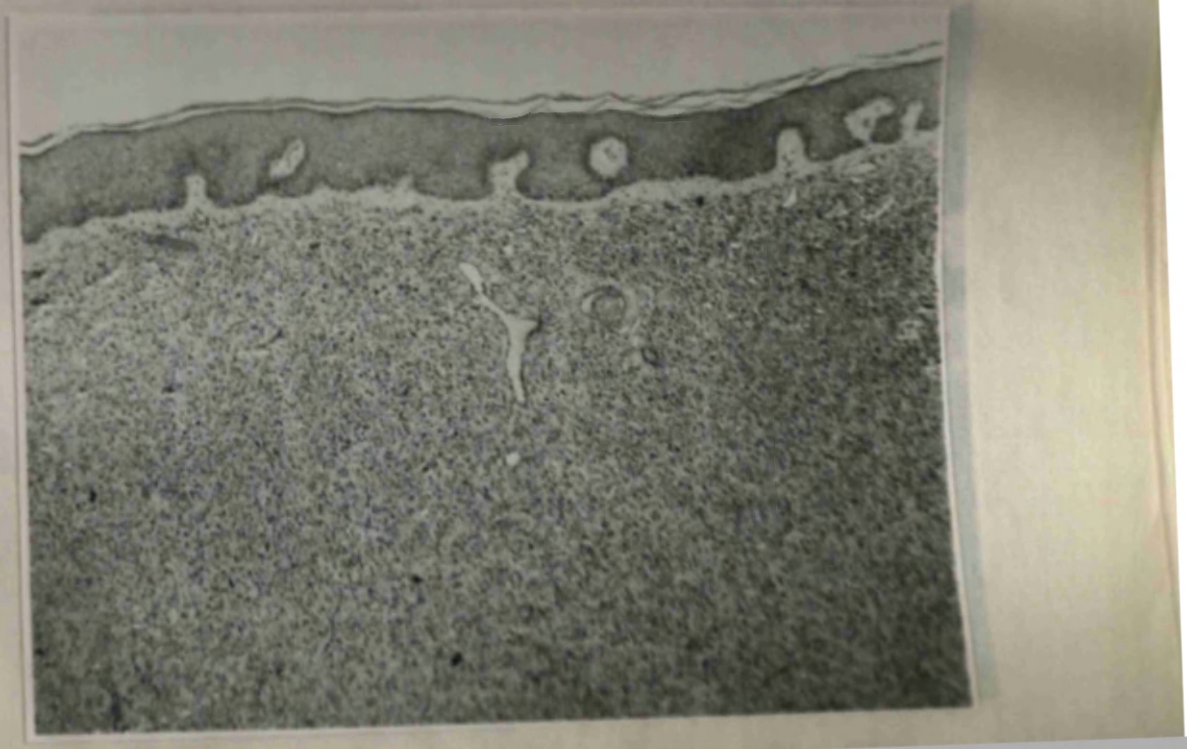

Case 151. Female aged 23 years.

Lesion on left deltoid area present for 13 months, growing slowly. Hard on palpation.

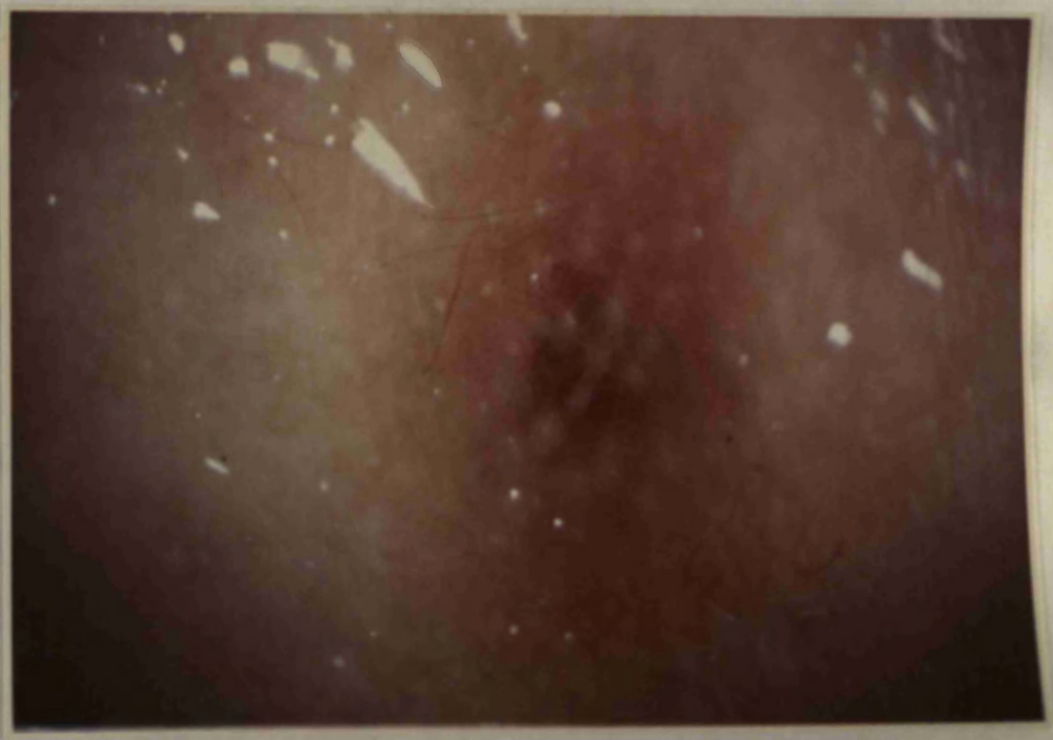

Histology: Sclerosing angioma.

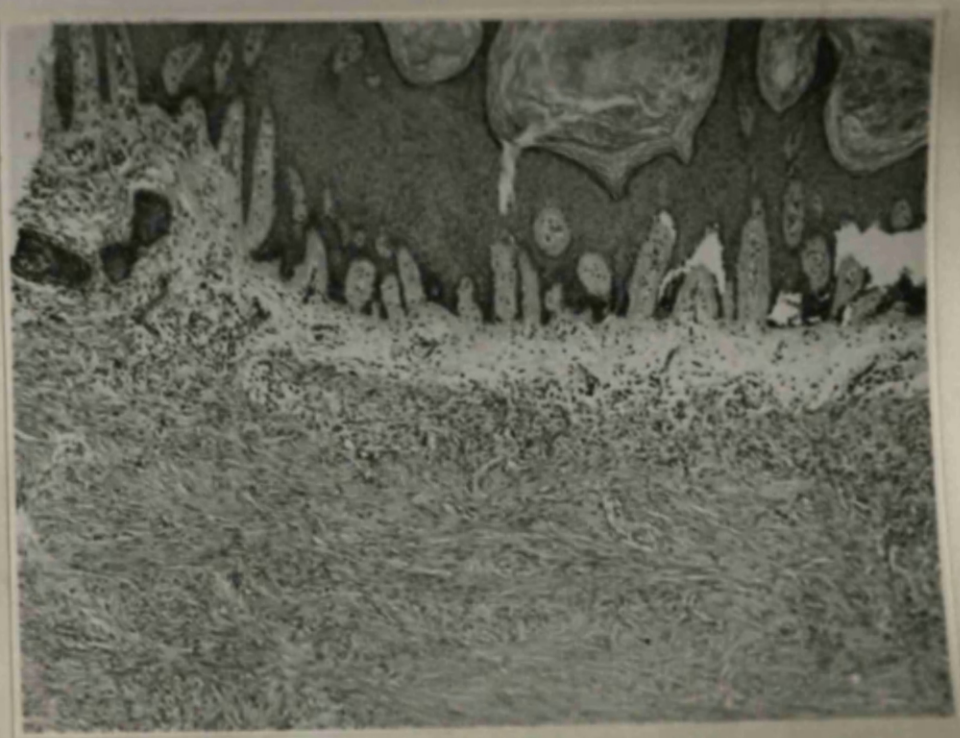

General Comments on the Sclerosing Angiomata

Of the six sclerosing angiomata here illustrated, four are raised lesions (nos 146-149). All the lesions show some pigmentation, mostly bluish-red in colour with the exception of 149 which has large quantities of dark red pigment due to ulceration and 151 which has regularly distributed spotting of brown pigmentation on its surface. In all of the lesions there are small red regular dots on the surface of the lesions which it is suggested might correspond with the rete pegs projecting down into the dermis.

None of the six sclerosing angiomata show the superficial irregular pigmentation seen in lesions exhibiting junctional activity, and the lesion in which melanin pigment is most obviously present, no. 151, shows a very different pattern of superficial pigment distribution, and is, in addition hard on palpation, a characteristic not found in junctional or compound naevi.

The Basal Cell Papillomata

Case 152. Male aged 64 years.

Lesion on anterior chest wall present for over 20 years.

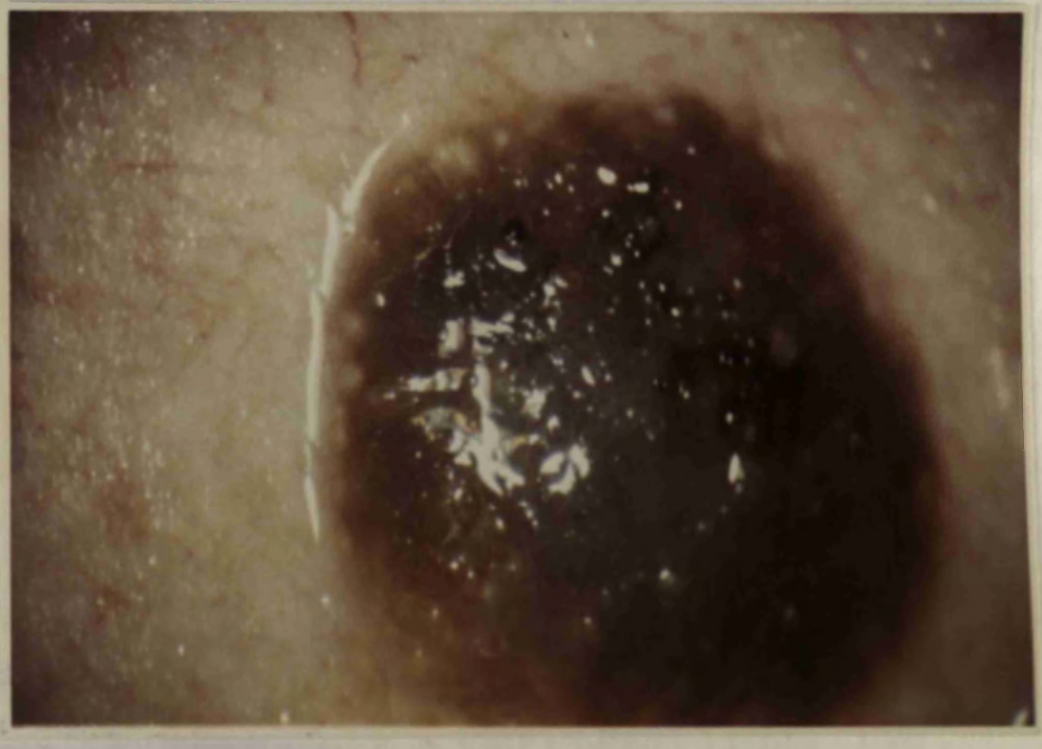

Histology: Basal cell papilloma.



Case 153. Female aged 40 years.

Lesion on right shoulder present since birth.

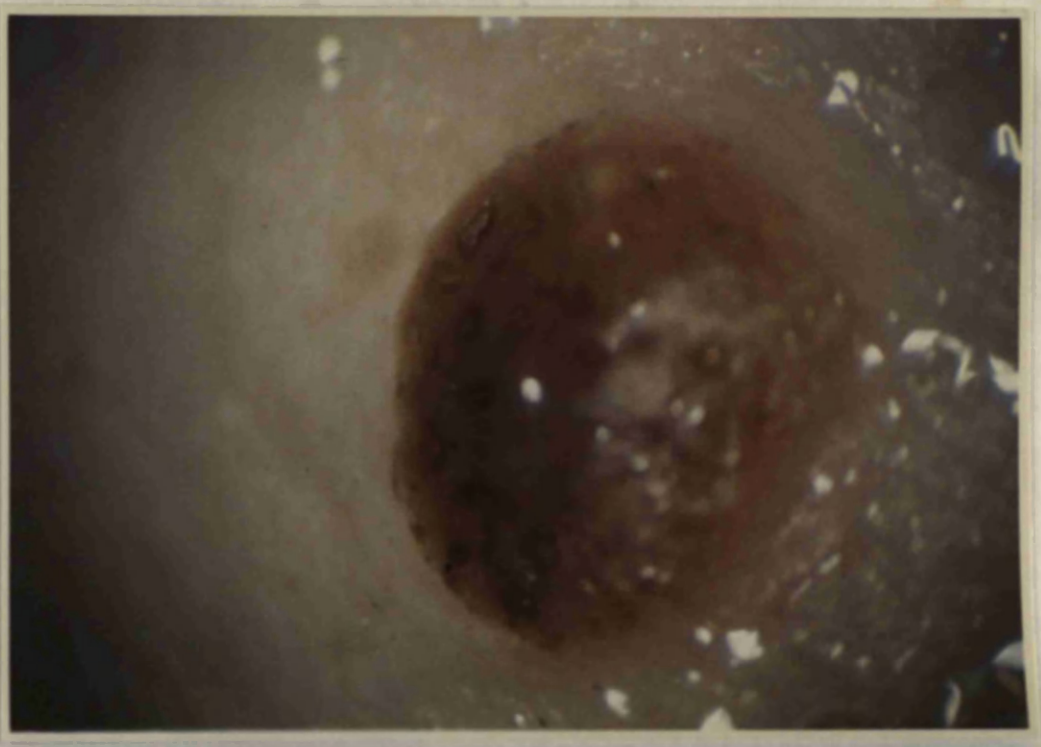

Histology: Basal cell papilloma.



Case 154. Female aged 38 years.

Lesion on left temple, first noticed six years previously. Traumatised by comb.



Histology: Basal cell papilloma.



Case 155. Female aged 42 years.

Lesion on right side of neck, present for at least 5 years. History of recent bleeding.

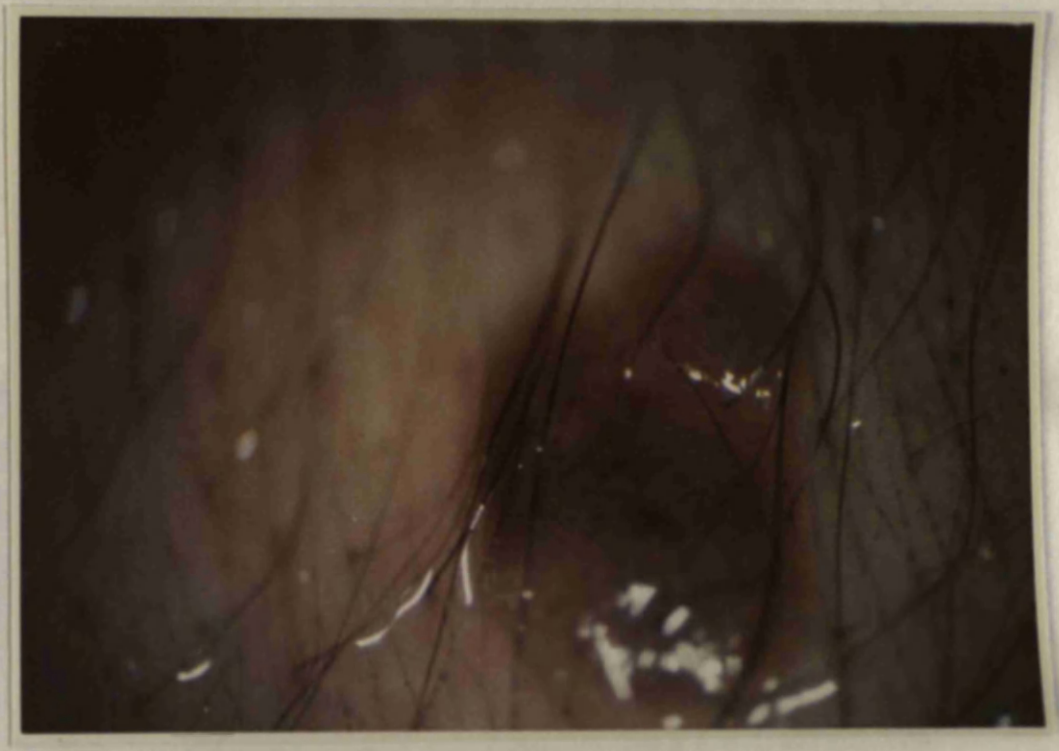

Histology: Basal cell papilloma.

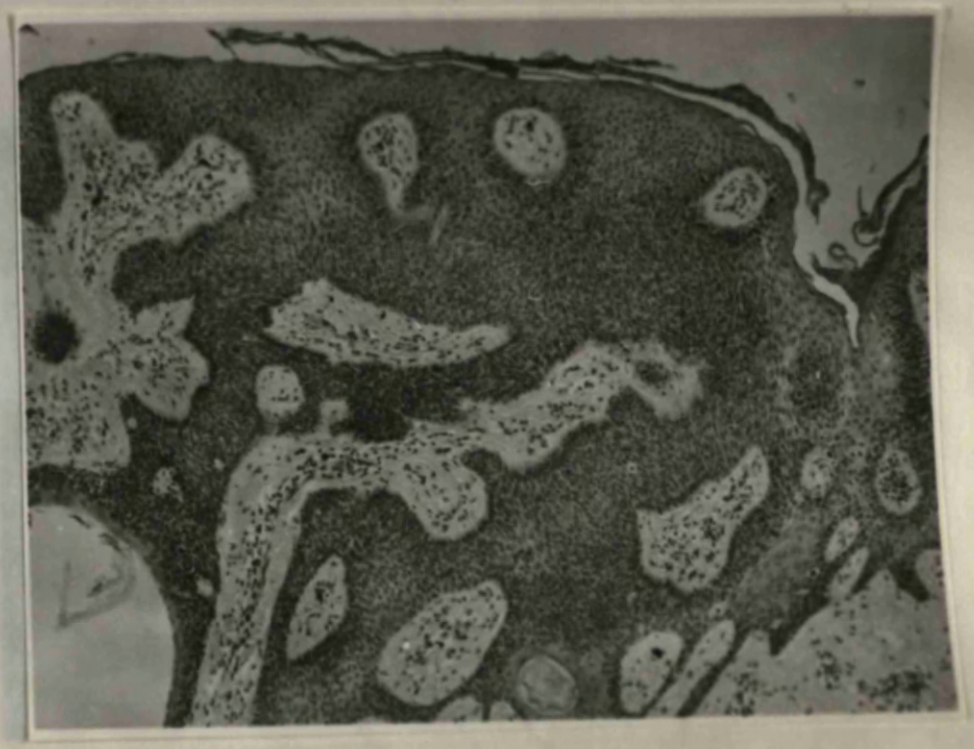

Case 156. Female aged 38 years.

Lesion on left shoulder first noticed 8 months previously. Growing steadily.

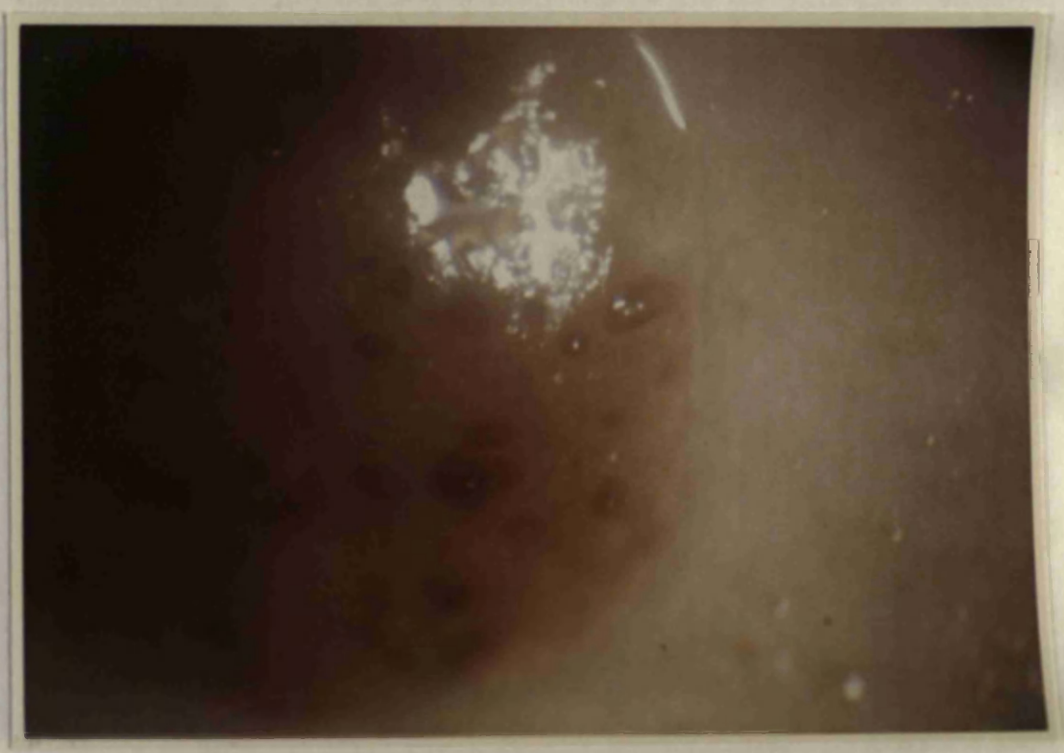

Histology: Basal cell papilloma.



Case 157. Male aged 34 years.

Lesion in left groin first noticed two years previously.

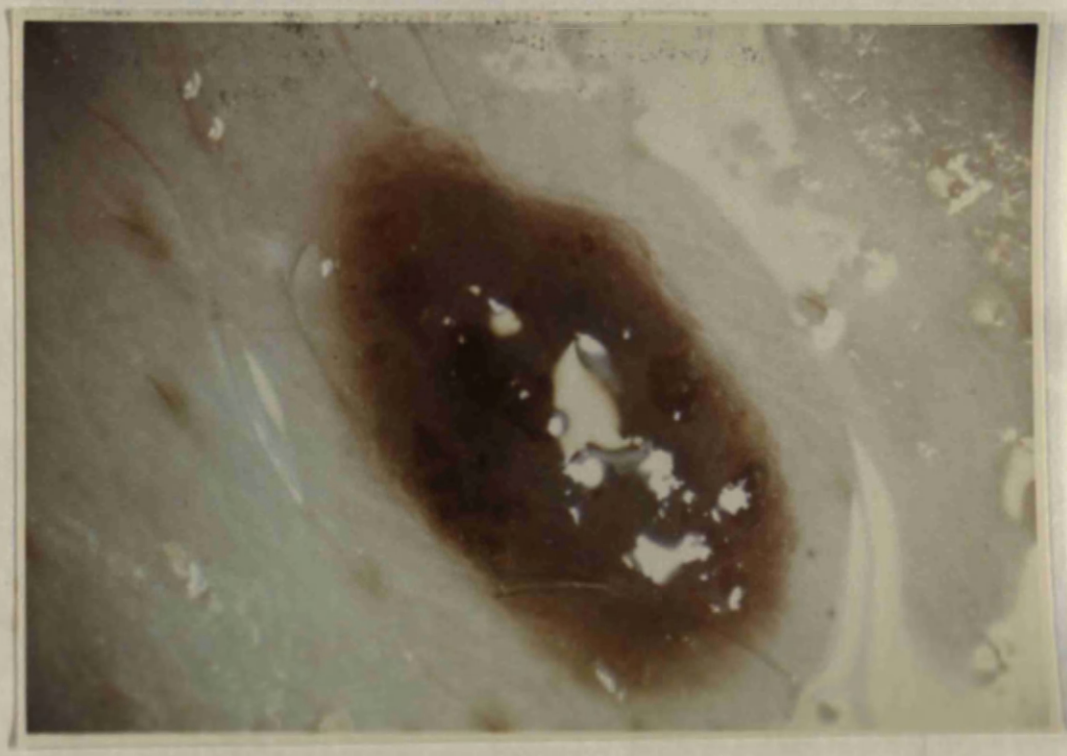

Histology: Basal cell papilloma.



Case 158. Male aged 53 years.

Lesion on anterior chest wall present since birth.

History of recent enlargement.



Histology: Basal cell papilloma.



Case 159. Female aged 61 years.

Lesion on mid-back present for at least 10 years.

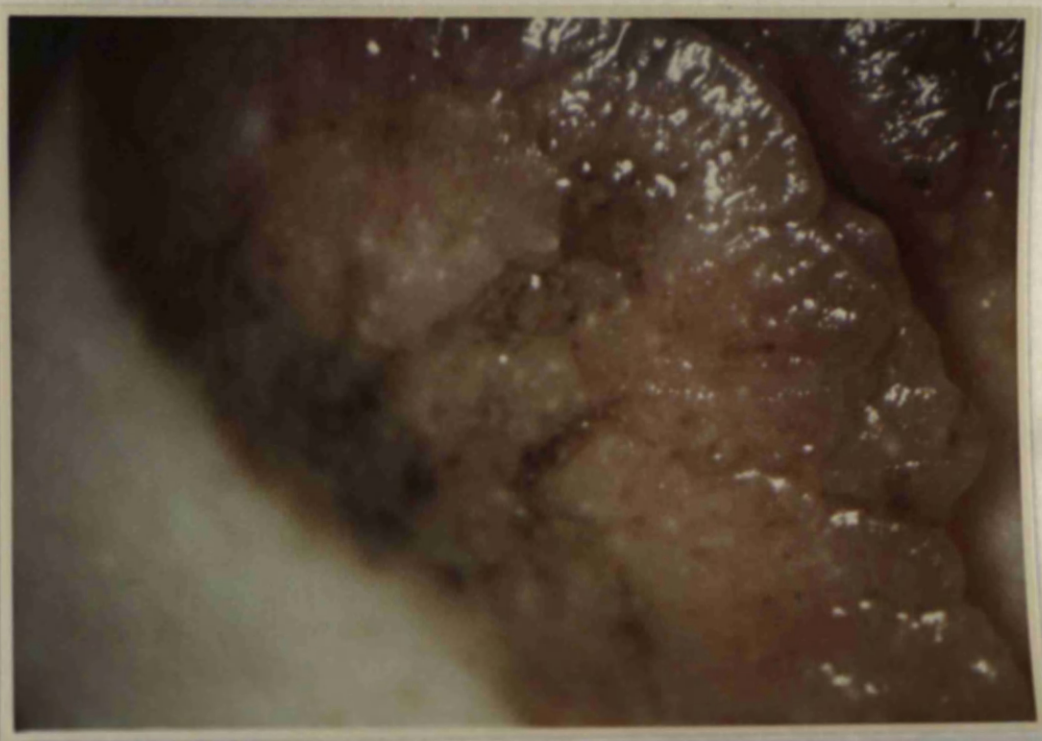

Histology: Basal cell papilloma.



Case 160. Female aged 74 years.

Lesion on mid-back present for at least 5 years, growing steadily.



Histology: Basal cell papilloma.



Case 161. Female aged 42 years.

Lesion on bridge of nose present for past 7 years, recent enlargement.

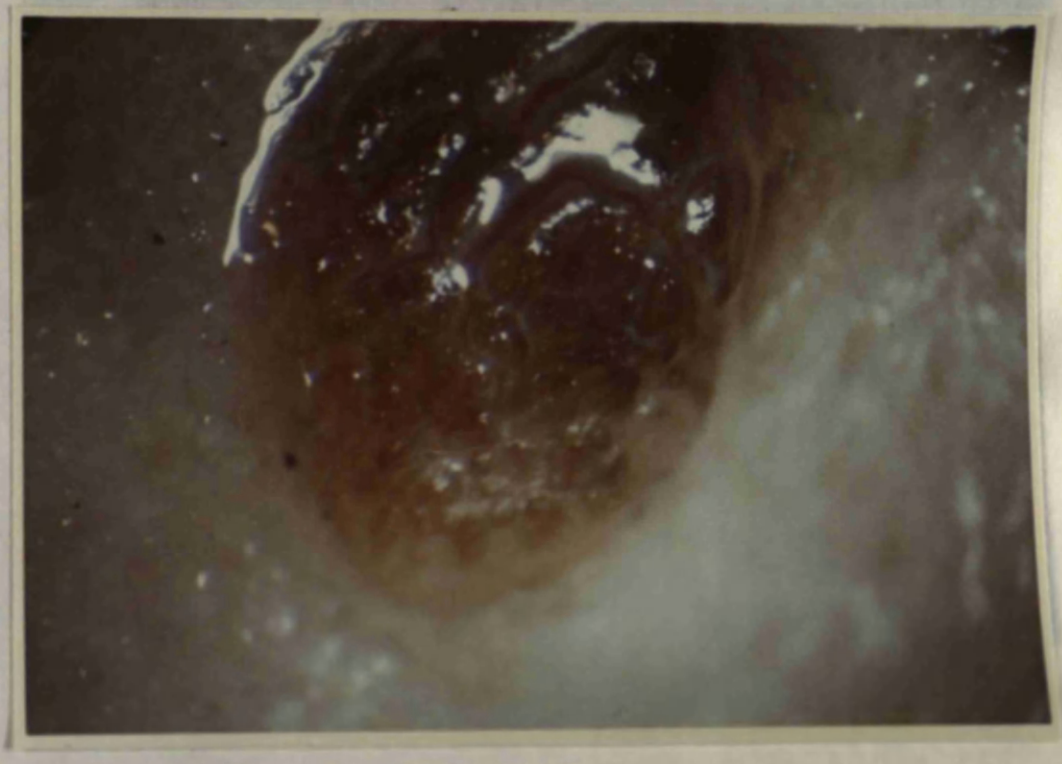

Histology: Basal cell papilloma.



Case 162. Female aged 61 years.

Lesion on abdomen, present for at least 5 years.

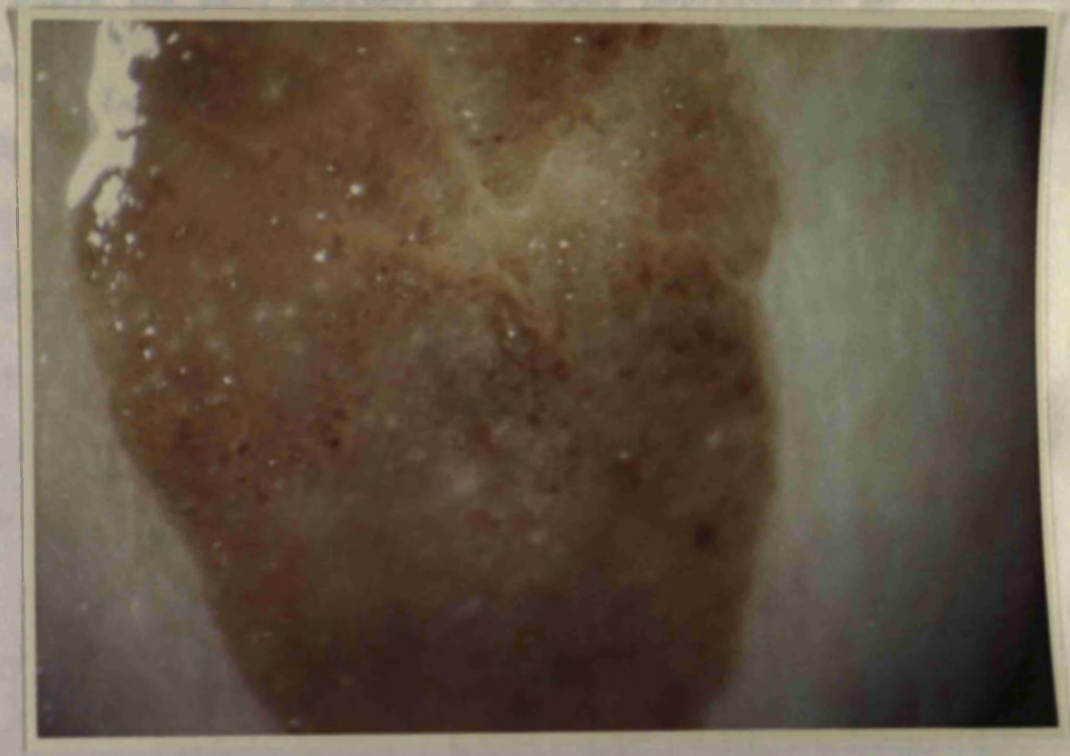

Histology: Basal cell papilloma.



General Comments on the Basal Cell Papillomata

The eleven basal cell papillomata here illustrated are all clearly raised above the skin surface. In those papillomata in which this is an extreme feature (cases 158-161) the surface of the lesion is deeply crevassed, and at times is cerebriform in appearance. The colour of pigment deposit varies from reddish brown (case 157) to blue black (case 154). Superficial pigment deposits are seen in these lesions, and seen commonly in a halo pattern, with a dark superficial ring of pigment surrounding a paler central zone (cases 152, 153, 154, 156). The irregularity of the superficial pigment deposit at no time resembles the grossly irregular pattern seen in lesions exhibiting junctional activity. The edge of every papilloma is clearly demarcated from the surrounding normal skin.

The Basal Cell Carcinomata

Case 163. Female aged 62 years.

Lesion on scalp, present for seven years,

growing slowly.



Histology: Basal cell carcinoma.



Case 164. Male aged 71 years.

Lesion on left cheek, present for two years, growing slowly.

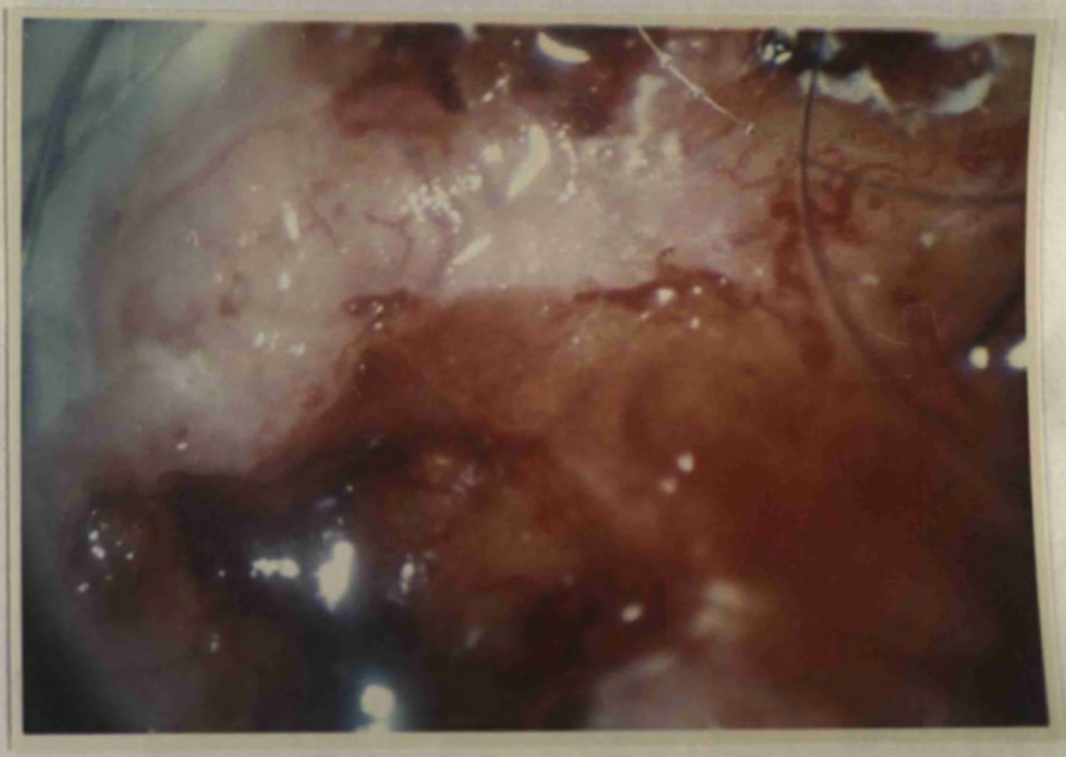

Histology: Basal cell carcinoma.

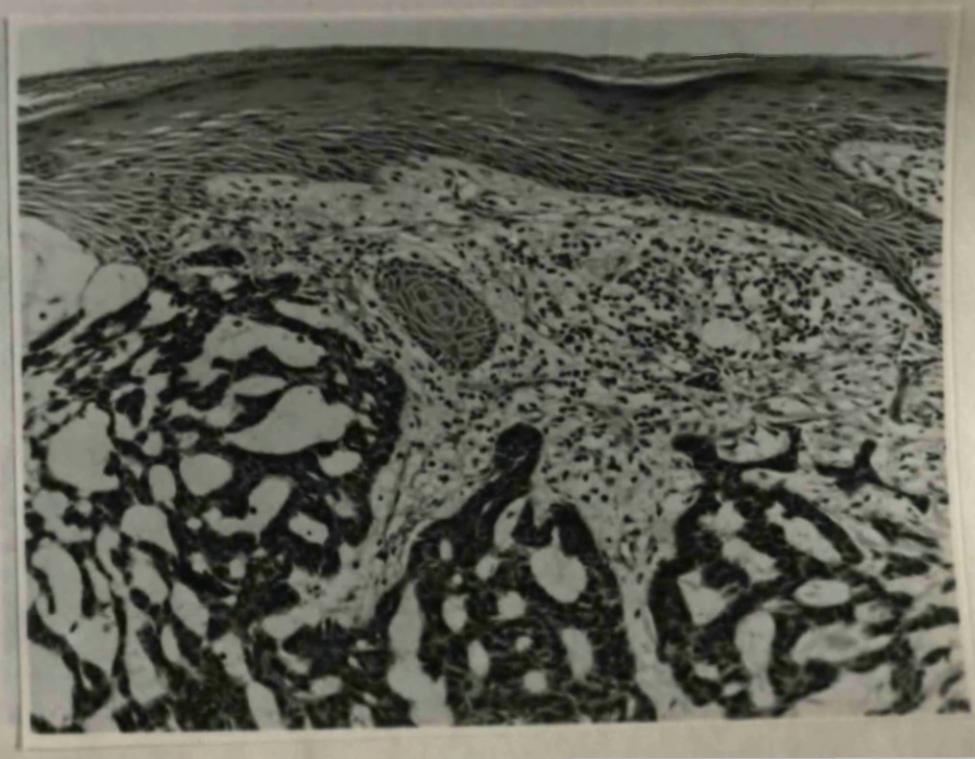

Case 165. Male aged 68 years.

Lesion on left cheek present for three years, growing slowly.

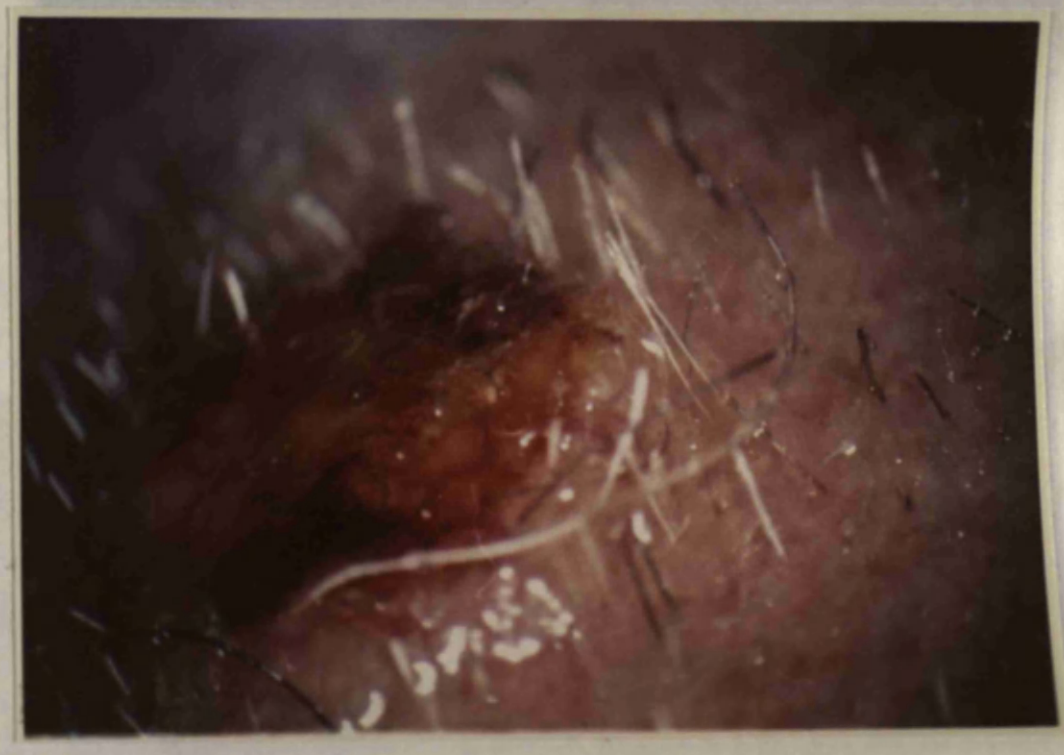

Histology: Basal cell carcinoma.

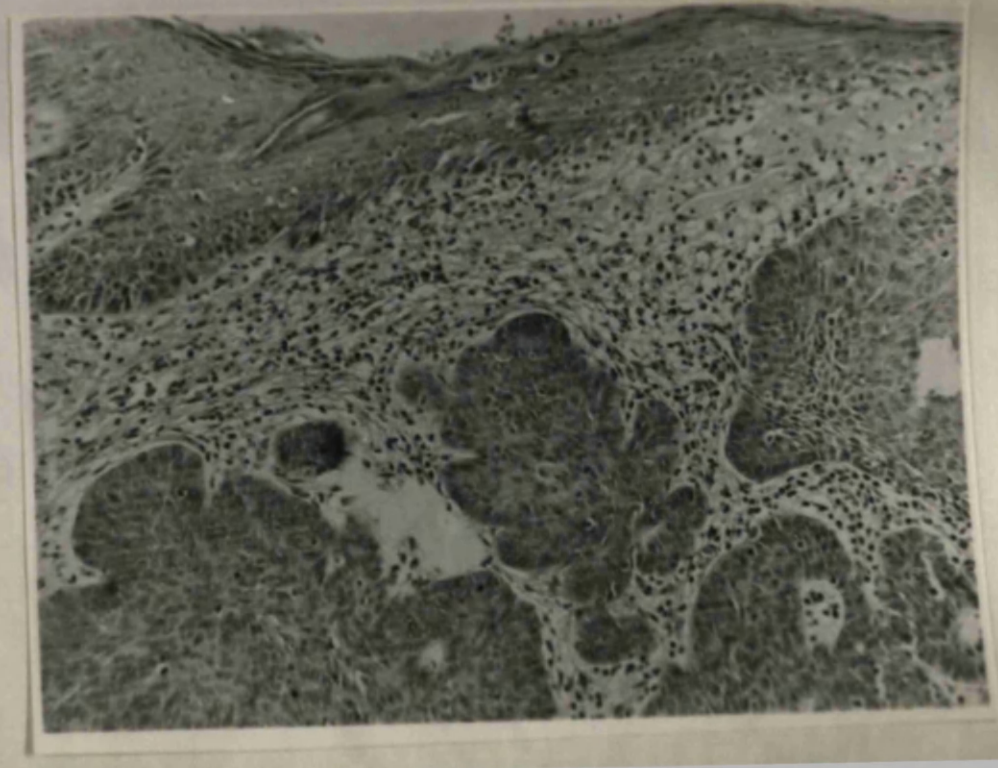

Case 166. Male aged 60 years.

Lesion on right cheek present for one year.



Histology: Basal cell carcinoma.

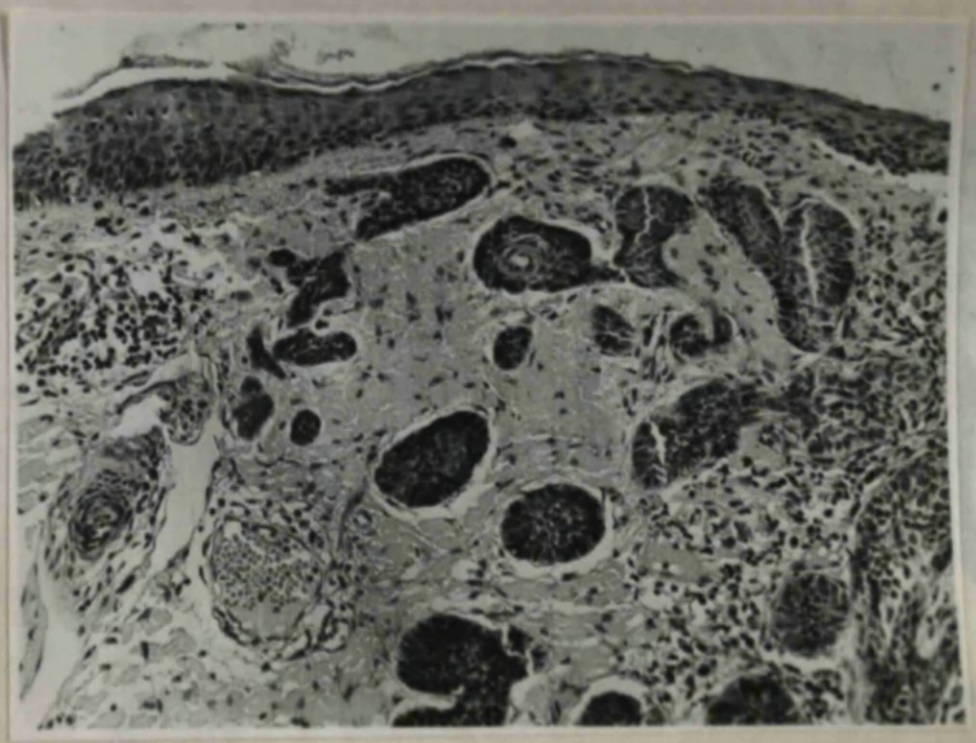

Case 167. Female aged 50 years.

Lesion on forehead present for two years, growing slowly.

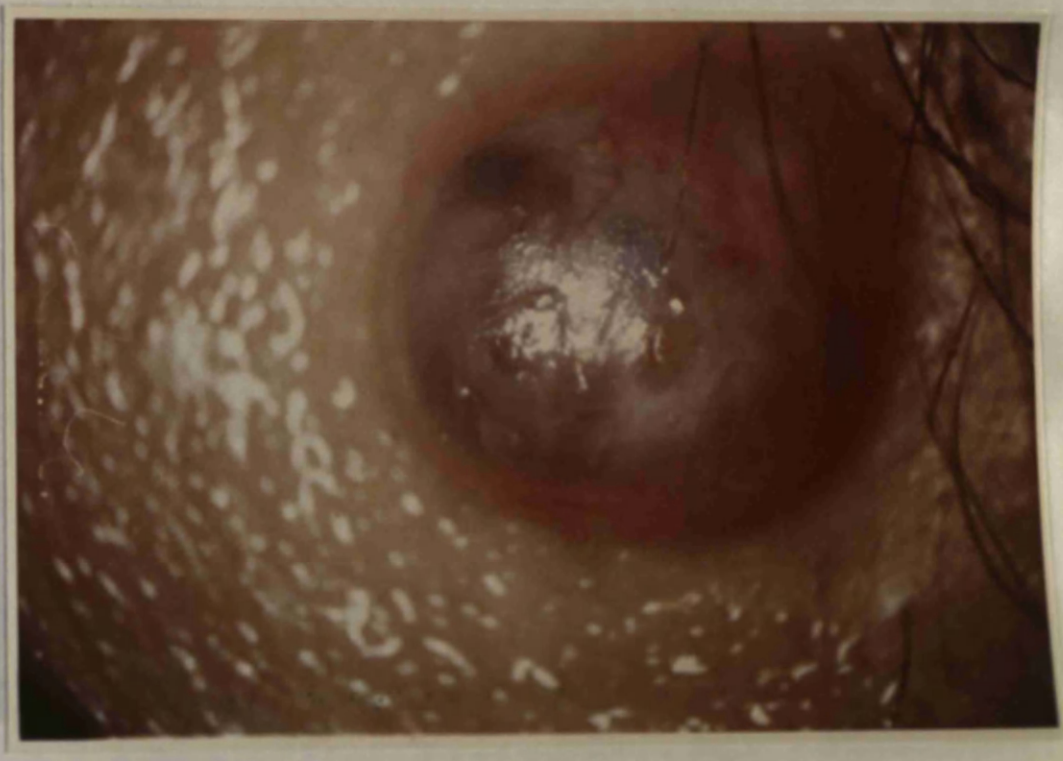

Histology: Basal cell carcinoma.



Case 168. Female aged 22 years.

Lesion of right ear first noticed 6 months previously.

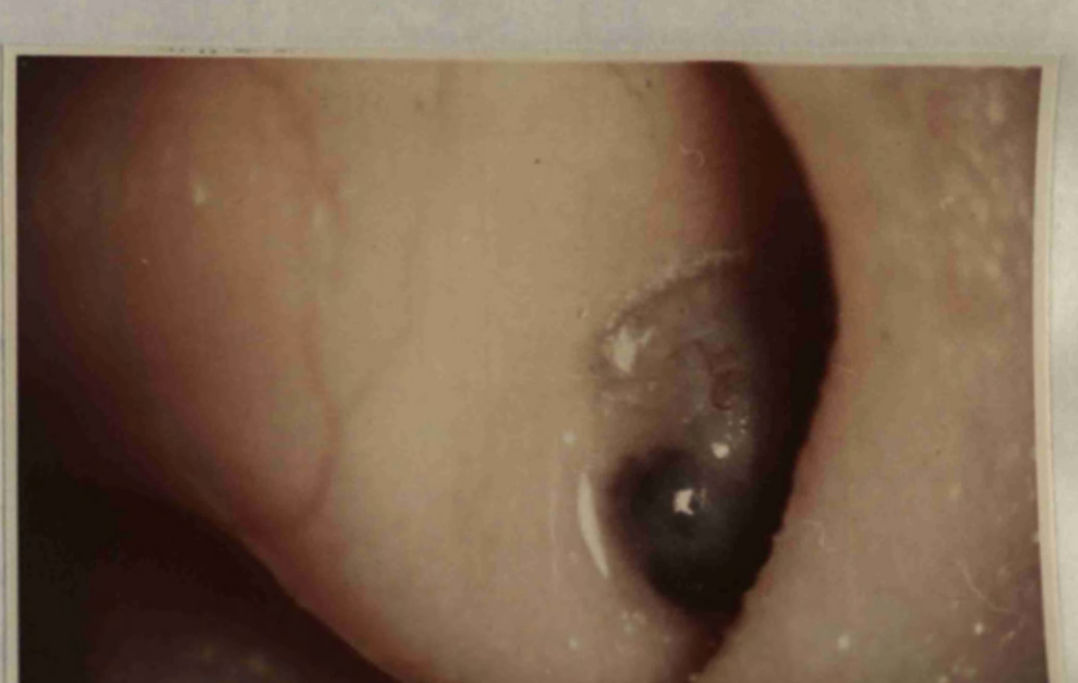

Histology: Basal cell carcinoma.

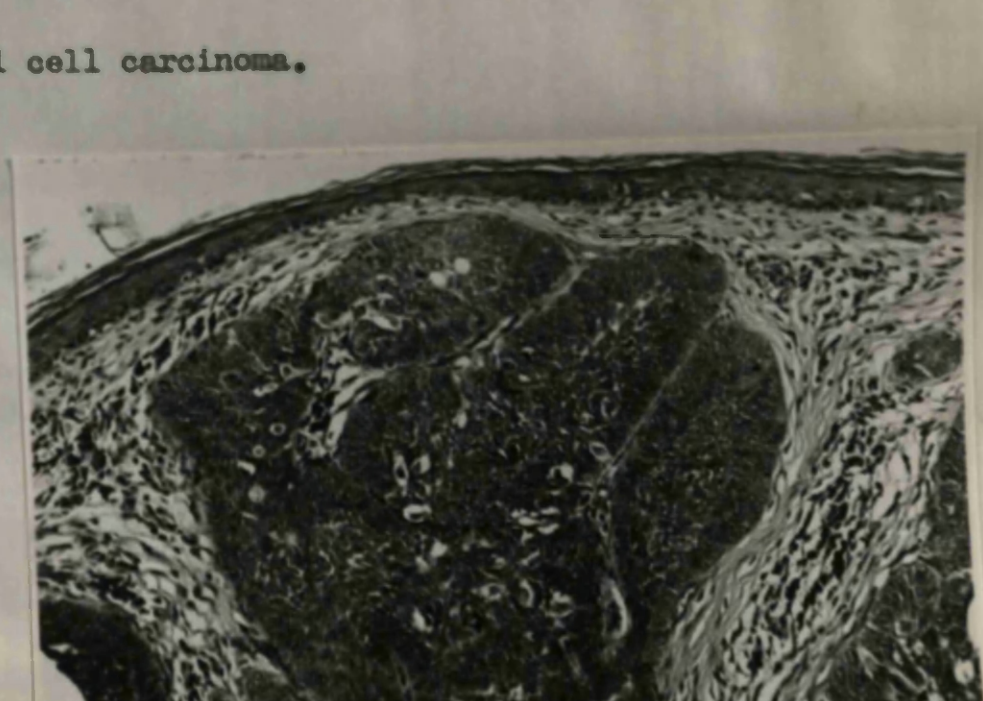

General Comments on the Basal Cell Carcinomata

The basal cell carcinomata here illustrated do not illustrate the typical textbook picture of the small ulcerated lesions with a raised pearly border; there is no need for special examination of such cases as clinical diagnosis is straightforward on naked-eye examination.

Cases 163-166 are ulcerated, show little pigment other than fresh or altered blood, and the magnification provided by this method does in fact demonstrate the classically described raised pearly border in cases 164-166. All four of the ulcerated basal cell carcinomata show dilated irregular capillaries on their surface.

Cases 167 and 168 are not ulcerated and appear as dome-shaped lesions with red and blue-black pigment deposits clearly visible. Dilated capillaries are also observed on the surface of both these lesions.

None of the pigment observed in any of these basal cell carcinomata has the superficial appearance of the melanin pigmentation seen in the earlier lesions, and the impression gained on naked eye examination that the pigment observed is fresh or altered blood correlates well with the histological appearance of the lesions.

Discussion

From the cases here illustrated, it will be seen that the *in vivo* magnified surface appearances of each group have several features in common which serve to distinguish them from other pigmented lesions which, although clinically similar, are of a different histological type and therefore require different surgical treatment.

There are two *in vivo* characteristic common features of the junctional and compound naevi and the malignant melanomata, all lesions in which junctional activity is present. The first feature commonly seen in these lesions is a superficial delicate spiders web pattern of pigment distribution, generally best observed at the edge of the lesion in question. This delicate regular pigment pattern is seen exclusively in the junctional and compound naevi and the malignant melanomata, but not every case in the above mentioned groups exhibits this feature.

The second commonly observed characteristic of these three groups is the presence of highly irregular areas of superficial pigment present on the surface of those lesions exhibiting junctional activity, generally with paler pigmentation lying immediately beneath them. The size and colour density of these superficial pigment deposits is extremely variable and is seen at its most irregular form in the melanomata. This pigment irregularity is found in all lesions exhibiting junctional activity.

Split-Skin Dopa Preparation

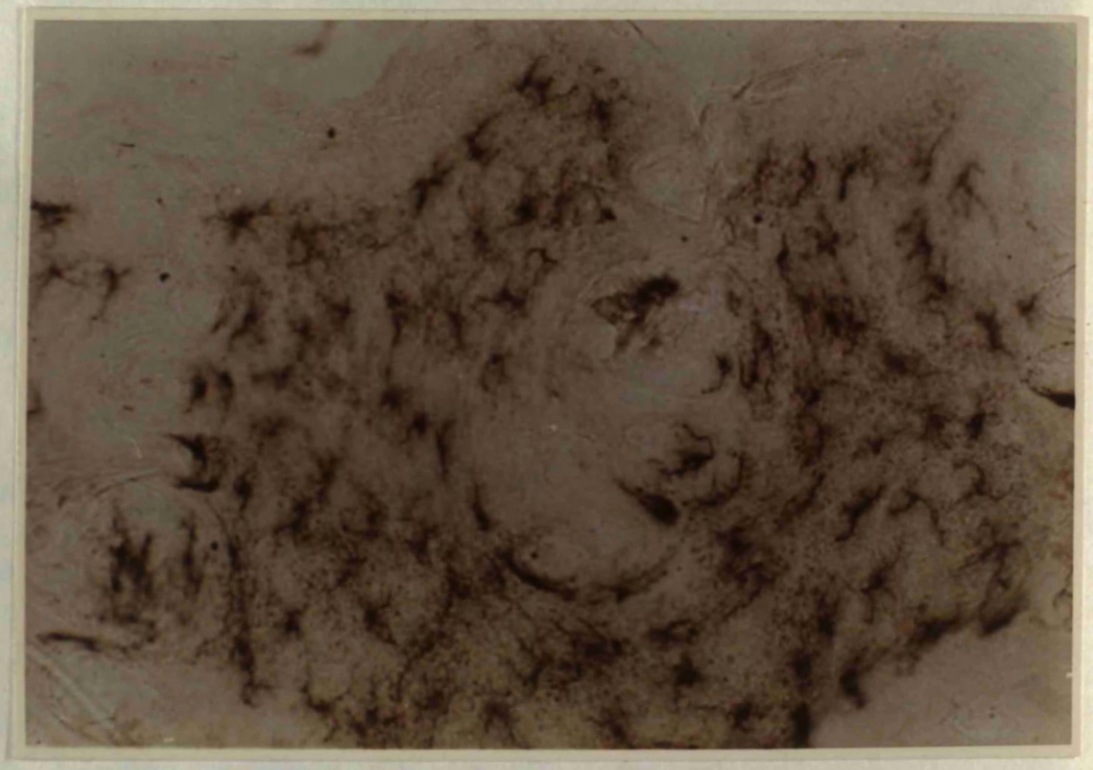

A reasonable explanation for the spider's web pattern observed in many of the lesions showing junctional activity may be that it is a reflection of the pattern of distribution of the melanocytes at the dermo-epidermal junction in relation to the surrounding basal cells; a split-skin preparation viewed from the basal layer is shown opposite with the melanocytes stained with dopa. From this it will be seen that the dendrites of any one melanocyte extend towards those of neighbouring melanocytes in such a manner that a very closely connected system is formed. These cells give such an appearance of an interlinked system that it is suggested that Fitzpatrick's term the epidermal melanin unit might be bettered by 'epidermal melanin network'. The fact that actual cytoplasmic connections have recently been demonstrated in the melanocytes situated at the limbus of the cornea gives some experimental evidence supporting this theory (Bart et al. 1969).

A comparison of the split-skin preparation of melanocytes here illustrated with some of the lesions demonstrating the spider's web pigment distribution pattern (cf. cases 29, 37, 39, 51, 98, 109) it will be seen that despite the difference in magnification of the two studies the pattern of pigment distribution in the magnified clinical pictures is comparable to the melanocyte network pattern. As it is the cells of this profuse and closely linked melanocyte system which are proliferating in lesions with junctional activity, it seems reasonable to suggest that the 'spider's web' pigmentary

pattern observed *in vivo* in these lesions is a reflection of the increased pathological activity of the system.

The second pattern of pigment distribution noted in those cases exhibiting junctional activity is the irregular superficial pigmentation which is observed without exception in all these lesions. Histological examination of them shows that the quantity and distribution of melanin within any given lesion is extremely variable; an explanation for the irregular superficial patches of pigmentation may therefore be that this is an indication of the irregularly distributed melanin granules, both in the melanocyte, and in the superficial intradermal macrophages.

The fact that a 'spider's web' pigment pattern is not universally seen in cases with junctional activity merits further discussion; as it is best observed at the edge of those lesions with junctional activity, it may be that the pattern in the central areas is masked by intradermal melanin clusters.

In the case of the melanomata it will be observed that while the majority of lesions show a much greater quantity of pigment than compound or junctional naevi of similar size, there are some notable exceptions, for example cases 92, 104, 105 and 107. In the past, such lesions have been termed amelanotic melanomata, but examination of these colour prints will show that the use of this term is not justified as in every case there are small deposits of melanin pigment present, most commonly at the edge of the lesion.

A more logical name for such tumours would therefore seem to be hypomelanotic melanomata, and it seems probable that although there may well be truly amelanotic lesions, the term is commonly used as a relative one in contrast to the tumours in which the abnormally large quantity of melanin present is an immediately outstanding feature.

In the melanomata the spider's web pattern of pigmentation when present is also best observed at the edge of the tumour, and this may be firstly because the central area of the lesion is often necrotic and ulcerated, and secondly because the junctional activity present in a melanoma is commonly maximal at its lateral limits.

The Differentiation of Junctional and Compound Naevi from Malignant Melanomata

As already described, the features of the magnified in vivo surface appearance of the junctional and compound naevi and the malignant melanomata are the two distinct types of irregularity of melanin pigment deposition, the first the regular spider's web pattern, and the second the gross irregular superficial pigmentation. These two features therefore are a preoperative clinical guide to those lesions which are both frankly neoplastic, and those which have the potential for malignant change. This knowledge, while extremely helpful in dealing with a patient with a pigmented lesion, would be even more valuable if by study of the surface of this group of lesions, it was possible to distinguish those in which early malignant change was in progress from those merely exhibiting increased melanocyte activity.

A study of those melanomata which appear to be at an early stage in their development and comparison with those naevi in which junctional activity, although present, is benign, indicates several features which are helpful when considering this point.

As was previously mentioned (page 140) in the section devoted to melanomata, every lesion in this group has a raised irregular epidermal surface; in some cases this will amount to a large dome-shaped area comprising the bulk of the tumour as in cases 97, 104, 107 and 108. While in others it is only an irregularity situated

at one point in the lesion, and not immediately apparent on clinical examination without the aid of magnification.

While some of the junctional and compound naevi show a raised epidermal surface the proportion in this series is 5 out of 18 or 28% for the junctional lesions, and 34 out of 63 or 54% for the compound naevi as against 100% for the melanomata. It therefore follows that a flat pigmented lesion with either a spiders web pigment or irregular superficially deposited pigment is likely to be a junctional or compound naevus, but not a melanoma.

A feature which gives a positive indication of active malignant change is gross colour variation within any given lesion. As has been noted previously, junctional and compound naevi commonly show peripheral paling and superficial pigment irregularity within the lesion, but in a melanoma the entire spectrum may be represented (case 114) as inflamed areas and may be adjacent to dense black areas which have a blue or green tint.

The Differentiation of Junctional from Compound Naevi

The junctional and compound naevi included in this study have in general a similar surface appearance. The most obvious differences are that the junctional naevi tend to be smaller and, with the exception of those arising in coloured skin, tend to be less heavily pigmented. However, as the potential of the two lesions for malignant change is considered to be the same, the same surgical treatment is therefore required for both types and preoperative clinical differentiation would be of academic rather than practical value.

The Differentiation of the Intradermal Naevi from other Lesions in this Study

One of the immediately striking features of the intradermal naevi here illustrated is the relative lack of melanin pigment present. The positive striking features of these lesions as a group are the presence of a strong superficial capillary pattern, the growth of terminal hairs and the fact that what pigment is in fact present within the lesions is not in focus at the same time as the epidermal surface, indicating that its situation is intradermal rather than intraepidermal. This is of course in keeping with the fact that there is no epidermal abnormality in the intradermal naevi.

The lack of melanin pigment present in this group makes it unlikely that the differential diagnosis of an intradermal naevus will include junctional or compound naevi, blue naevi, or the more heavily pigmented varieties of malignant melanoma or basal cell papilloma. Their intact epidermal surface with its smooth contour will distinguish them from the basal cell carcinomata. When compared with the hypomelanotic melanomata, it will be seen that the raw granulation-tissue appearance observed in these tumours is entirely absent in the intradermal naevi, and also that the pigment in the hypomelanotic melanomata is situated peripherally, whereas that in the intradermal naevi is more central.

Some cavernous angiomata may show superficial similarities to the intradermal naevus group, but while the capillary pattern

on the surface of the intradermal naevi is essentially normal, although the capillaries are larger than usual, the pattern on the angiomata is highly abnormal with blood-filled spaces and ulcerated areas.

The Differentiation of Cavernous Angiomata from Other Lesions in this Study

The chief distinguishing feature of the cavernous angiomata is the clearly visible blood-filled spaces lying immediately beneath the epidermal surface. The only pigment present is fresh or altered blood. The granulation-tissue appearance of the hypomelanotic melanomata is not found in these lesions, and neither are the small amounts of melanin previously noted at the edge of hypomelanotic melanomata. The differentiation of intradermal naevi from cavernous angiomata has already been discussed. Confusion should not arise between the basal cell carcinomata and this group of lesions as the angiomata appear essentially as a vascular abnormality arising in normal skin whereas the basal cell carcinomata show vascular abnormalities present in an area of raised abnormal epidermis which is in some cases (nos. 164, 165 and 166) clearly observed as the classically described raised pearly border.

The sclerosing angiomata do not as a group give an immediate superficial impression of being vascular in origin, but appear either as flat brown lesions with melanin pigment obviously visible, or as raised lesions with blue, grey or yellow tones.

The Differentiation of Sclerosing Angiomata from Other Pigmented Lesions Discussed in this Series

The sclerosing angiomata here illustrated do not present a uniform appearance but appear to be divided into those which are raised above the surface of the surrounding skin, and those which are flat. The flat lesions more obviously demonstrate the presence of melanin and could be confused with junctional or compound naevi, but the pigment in the flat sclerosing angiomata is distributed in a manner distinct from the two patterns already observed in those lesions exhibiting junctional activity; the pigment in the sclerosing angiomata is relatively deeply situated as it is not crisply in focus at the same time as the surrounding normal epidermal surface. It is however relatively sparse, and therefore does not give the blue appearance of lesions such as the blue naevi in which pigment, also deeply situated, is more abundant. There are regularly interspersed throughout the pigmented zones of these lesions small circular areas comparatively free of brown pigment. It seems likely that these paler areas correspond to the rete pegs projecting downward into the dermis, thereby masking the accumulations of pigment present in the sclerotic areas of the dermis.

The two features notably absent in both the flat and the raised varieties of sclerosing angiomata are the spiders web and grossly irregular superficial pigment patterns found in lesions which show junctional activity on histological examination.

Differentiation between the sclerosing angiomata and the intradermal naevi will be aided by the fact that the regular capillary pattern commonly seen in the intradermal naevi is not observed in any of the sclerosing angiomata. The highly abnormal vascular pattern observed on the surface of the cavernous angiomata is also absent in this group.

It must be stressed that this method of examination of pigmented lesions is not advocated as a substitute for other more commonly used methods of assessment, but as an additional guide; sclerosing angiomata are a good example of the importance of this approach as in addition to their characteristic features observed by the microscope, they frequently are hard on palpation and have been present with little change for long periods of time. It follows therefore that the patient's history and palpation of the lesion may yield additional valuable information.

The Differentiation of the Basal Cell Papillomata from Other Pigmented Lesions

Many of the basal cell papillomata show relatively large quantities of melanin pigmentation; those demonstrated in this series obviously show more pigment than would a random sample of these lesions, as those lesions with little or no melanin pigment were not referred for examination with the operation microscope.

Two features in the distribution of the melanin present in the pigmented basal cell papillomata are characteristic; firstly the presence of a uniform background of pigment, which appears to be relatively deeply deposited in comparison with the second feature, namely the presence within these lesions of small dark halos of pigmentation, several of which are commonly seen in the centre of each lesion. The reason for this halo pattern of superficial pigment distribution may be the presence in these lesions of enclosed hyperkeratotic horny cysts which will be observed on histological examination of the lesions. The presence of keratin debris in the central area as viewed from the epidermal surface explains the pale central zone, while the darker area of pigment at the periphery is due to the increased concentration of cells in this area.

Confusion between these lesions and the junctional or compound naevi or the melanomata is unlikely because of the typical pigment distribution pattern; an additional differential feature is the

crenellated surface of the basal cell papillomata. This highly irregular almost cerebriform appearance is not seen on the surface of the junctional naevi and although compound naevi may show a raised irregular surface, it is seldom as marked or as regularly irregular as in the basal cell papillomata. The melanomata may also show an irregular surface, but this is more commonly in the form of raised dome shaped areas rather than cerebriform pattern. Those melanomata in which the surface is most irregular tend also to show ulceration.

In addition to the halo pigmentation present on the surface of the basal cell papillomata, small apparently normal capillaries may be observed on the epidermal surface (cases 152 and 158); these are not found on the surface of the junctional or compound naevi, and when seen on the melanomata (e.g. case 58) they are commonly associated with areas of ulceration. As has already been mentioned, the presence of apparently normal capillaries on the surface of a lesion is typical of an intradermal naevus but whereas the majority of intradermal naevi in this series have a relatively large number of visible capillaries with little superficial pigment, the pigmented basal cell papillomata have, in contrast, large quantities of melanin pigment and only a few visible capillaries.

The Differentiation of Pigmented Basal Cell Carcinomata from Other Pigmented Lesions

If the frequently-described raised pearly border is seen on clinical examination of an ulcerated lesion, it is not likely to be confused with other epidermal tumours, even if melanin pigmentation is present. Unfortunately, however, the adenocystic basal cell carcinomata frequently do not show this type of lateral margin.

The lesions most likely to cause confusion with the pigmented basal cell carcinomata are the ulcerated hypomelanotic malignant melanomata, and the ulcerated sclerosing and cavernous angiomata. Examination of the pigmented basal cell carcinomata here illustrated will show the absence of the spiders web and gross irregular superficial pigment patterns commonly observed in lesions exhibiting junctional activity. The regular circular pigment free areas noted in the flatter types of sclerosing angiomata are not present in the pigmented basal cell carcinomata, and, as has been mentioned previously, although both cavernous angiomata and pigmented basal cell carcinomata may show thrombus formation, the cavernous angiomata shows this feature on a base of relatively normal skin, whereas the pigmented basal cell carcinomata show thrombus formation amid irregular abnormal tumour tissue.

The appearance of any pigmented lesion may vary according to its site and case 168 seems worthy here of special mention with regard to this problem. In such a position where the epidermis is

so closely connected to the underlying cartilage, it seems clear that any extravasated blood could not easily diffuse away and therefore that any lesion which involved intradermal haemorrage would appear in this manner.

Case 112. Compare with p.131.

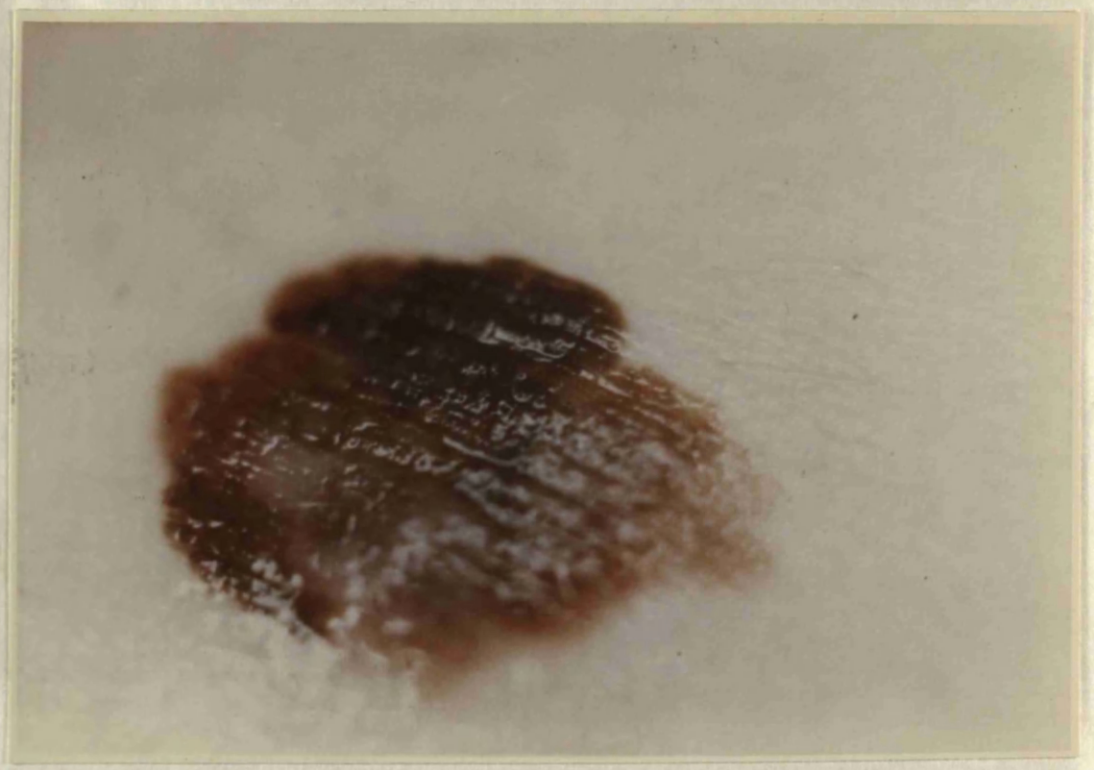

Case 7. Compare with p.24

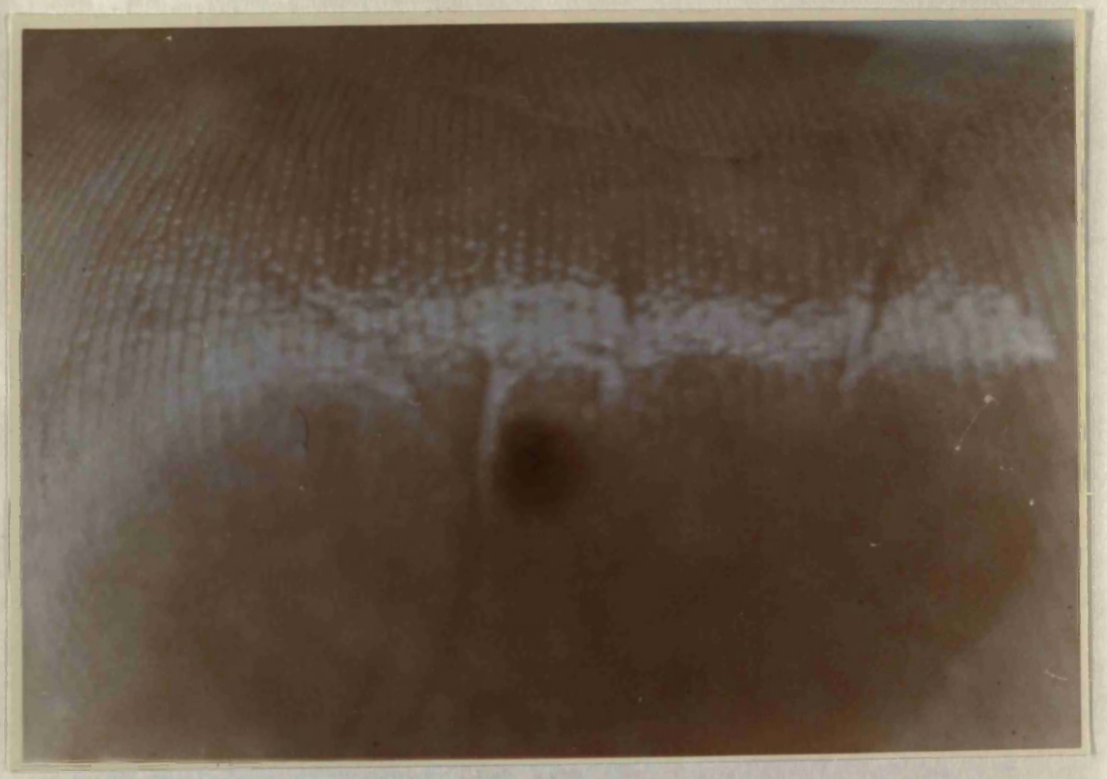

Case 32. Compare with p.50.

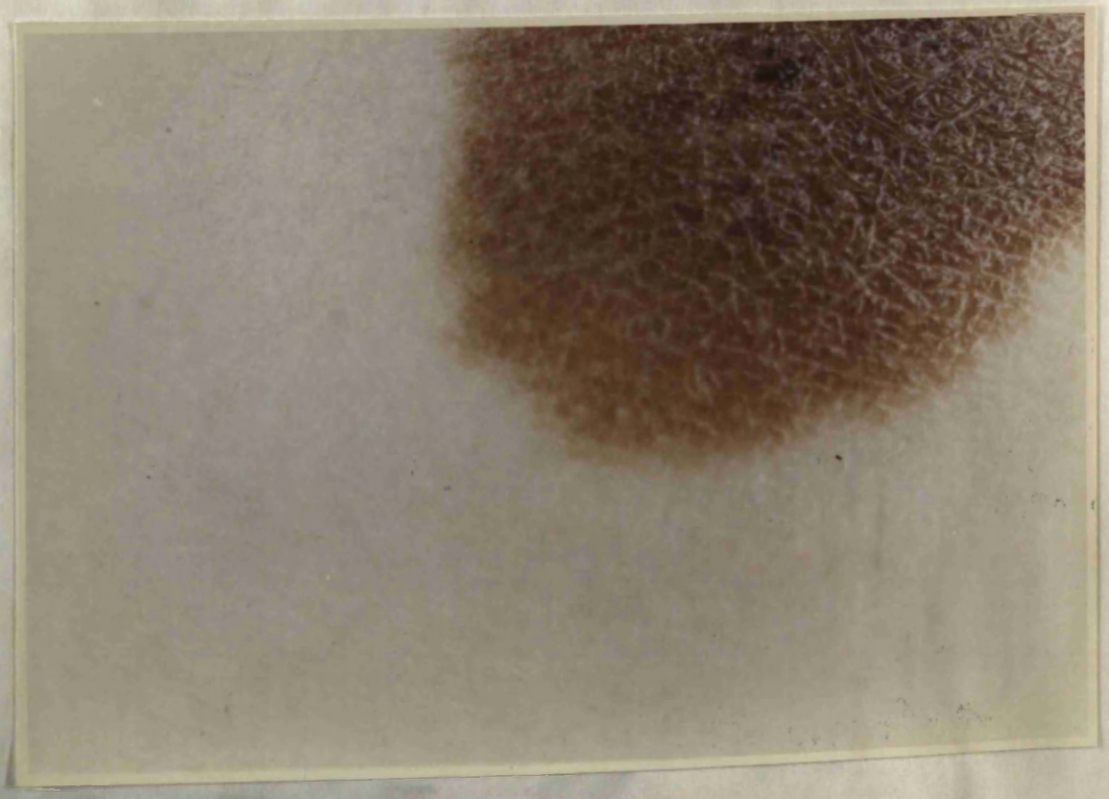

The Importance of Magnification in the Preoperative Assessment of Pigmented Lesions

The value of the magnification of the pigmented lesions is emphasised by the plates opposite.

These are of cases 7, 32 and 112 and are taken at 1:1 magnification. Comparison with the prints taken with the operation microscope at magnifications of 6 and 10 will show clearly the difference in the detail which can be noted. The compound and junctional naevi do not demonstrate the spider's web pattern or the gross irregular superficial pigment distribution pattern which are clearly seen in the magnified pictures. While the malignant melanoma would still be clinically diagnosed as such on examination of the 1:1 print, the particular features in the advanced case which are of value in spotting the early case are not obvious.

A simple magnifying glass is of value in a dermatological clinic in a preliminary assessment of a pigmented lesion, but the great drawback to this simple and inexpensive diagnostic instrument is that no record of the examination is obtainable. The importance of such a record cannot be overestimated, both for demonstrating to other workers the typical early appearance of rarer pigmented lesions and also as a method of measuring growth over a period of time. A subjective report by the patient that he thinks there has been growth in a particular lesion which is causing concern is obviously much less satisfactory than a magnified colour print or

transparency of the lesion in question two months previously. This system of regular examination and recording of a pigmented lesion has been found in the course of this study, to be of great value in the treatment of patients who are unduly concerned about pigmented spots, and also in lesions in which although there is some junctional activity the site is such that operative removal would involve surgical problems, for example the lower eyelid. Examination of such a lesion every two to three months, and comparison with previous pictures, will determine the presence or absence of growth of the lesion and therefore indicate whether or not operative removal is necessary.

The Importance of the Use of Colour in the Examination and Recording of Pigmented Lesions

A comparison of the black and white prints on pages 215-217 with the colour prints of the same lesions will clearly demonstrate the value of colour film in recording such conditions. While patterns of pigment distribution are observed as tonal variations the very great range of colour present, for example in case 114 is not represented at all. Clearly for teaching purposes black and white prints would be unsatisfactory and at times misleading. For example the black and white print of the hypomelanotic melanoma (case 92) makes the lesion appear much more benign than does the colour print (p. 111). The thrombus formation in the cavernous angioma is not as obviously demonstrated in the black and white print as in the colour print.



Case 27. Compare with p.45.

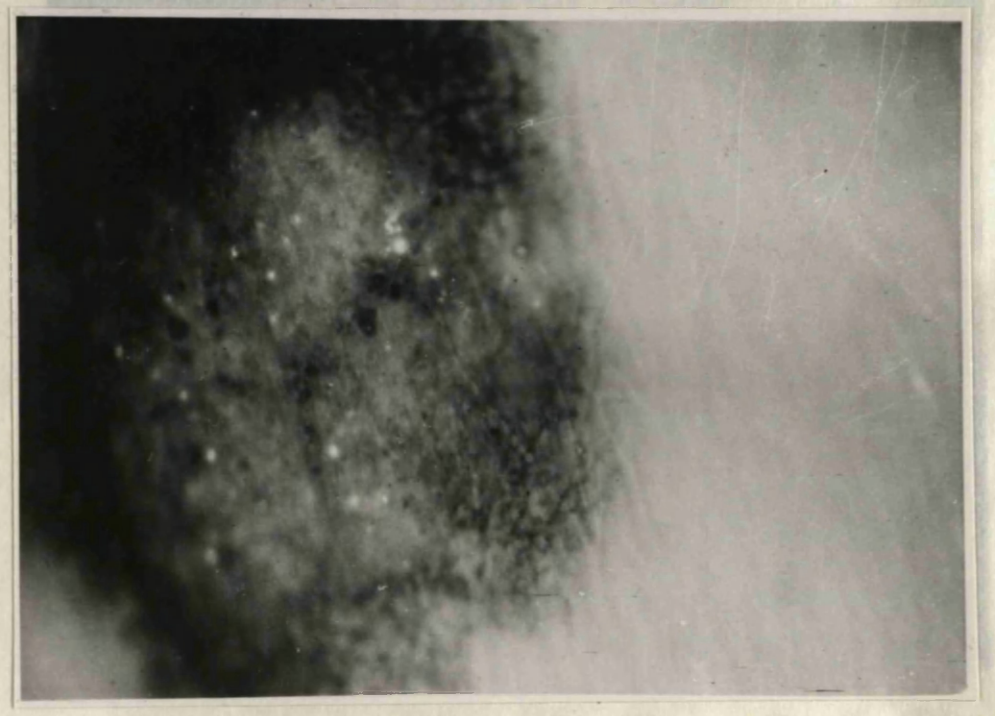

Case 32. Compare with p.50.



Case 92. Compare with p.111.

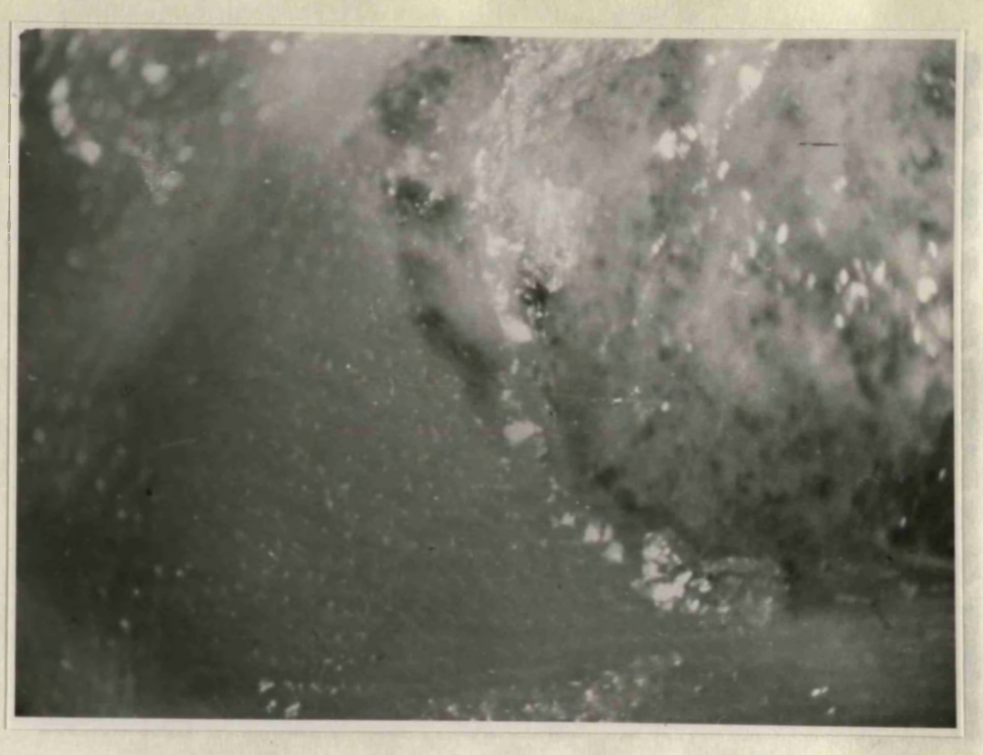

Case 114. Compare with p.133.



Case 129. Compare with p.151.



Case 138. Compare with p.161.

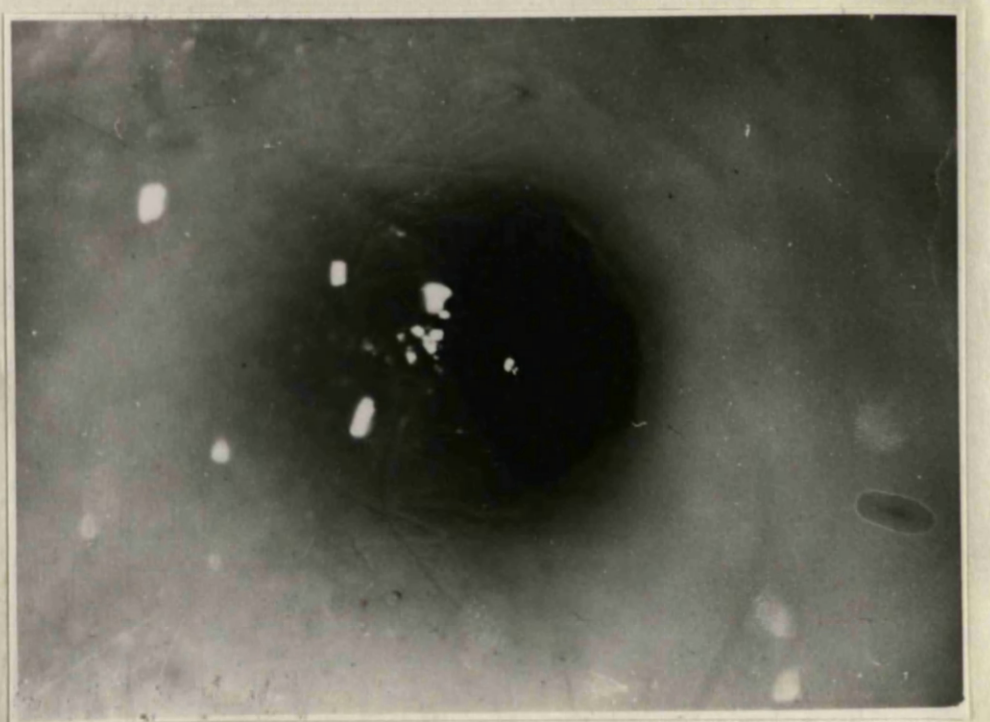

Felt tip pen mark (see opposite).

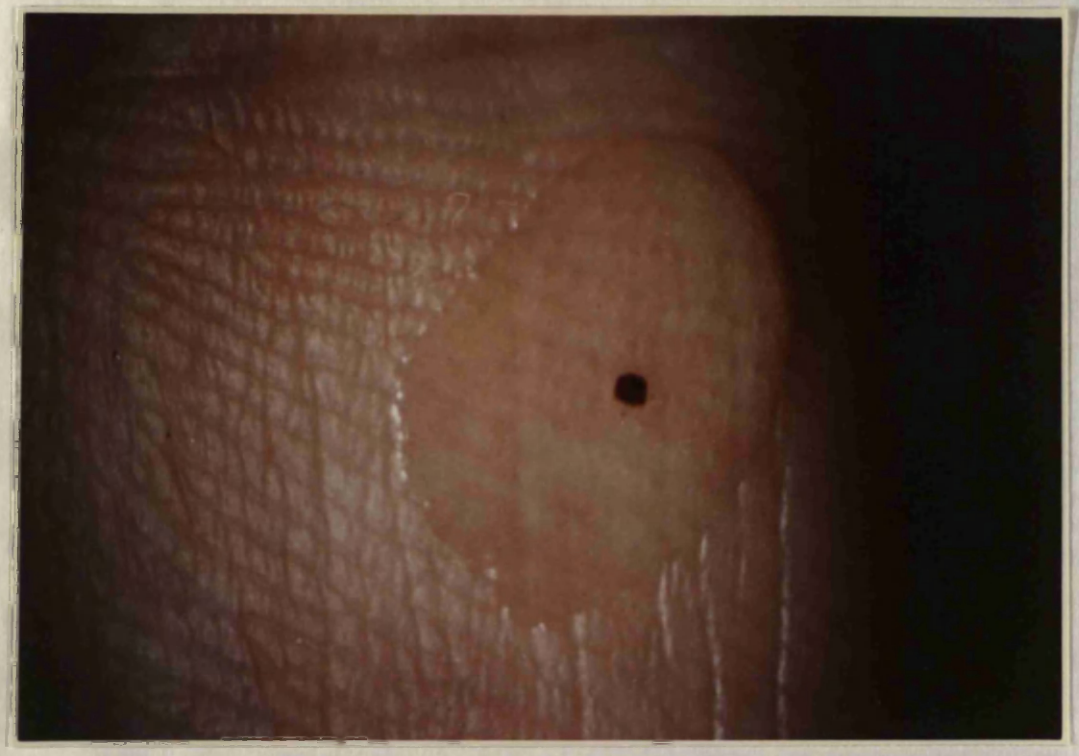

A Bruised Nail bed.



Other Pitfalls in the Differential Diagnosis of Pigmented Lesions

Another possible source of confusion in the differential diagnosis of epidermal pigmented lesions is the presence of foreign material on the epidermis. It is likely that many patients who seek medical advice as soon as they notice a new 'pigmented lesion' of this type will be aware of the potential dangers of rapidly growing pigmented tumours, and therefore need prompt and adequate reassurance.

The plate opposite illustrates a pigmented spot on the finger of a medical research worker, noticed 12 hours previously. Microscopy revealed that the lesion did not have the characteristic appearance of a rapidly-growing melanin-pigmented lesion in this site, namely a peripheral spiders web pigmentary pattern, central pigment irregularity, and distribution of the pigment along the skin flexure lines (see cases 2, 3, 4, 5, 6).

After this reassurance the patient agreed that this could be a foreign body on the surface of the epidermis, and discussion revealed that on the previous day he had been using a felt-tip test-tube marker. Application of this marker to the skin produced identical marks, and the dye removed by normal washing during the succeeding three days.

Another possible source of confusion is illustrated opposite. This is the toe of a patient who presented with a history of the sudden appearance of a blue black lesion at the nail base of his

big toe six days previously. Surprisingly he denied injury to the area. Microscopy of the lesion suggested that the pigment was altered blood, and the comparison of this case with case 18, the junctional naevus of nail bed, shows clearly the in vivo differences between the lesions. The lesion in case 18 is localised to a small area in the nail fold and is mid-brown whereas the lesion under discussion is present at the nail fold and under the entire width of the nail bed, and is blue-black in colour. There is no dystrophy of the nail in the illustration of altered blood whereas in the junctional naevus of nail bed there is a linear irregularity stretching distally from the area of pigmentation, indicating the presence of a lesion in the area of the nail bed for a minimum of 4 weeks.

Conclusion

From the foregoing it will be seen that several useful points have emerged from this experimental study of the use of an operation microscope in the preoperative assessment of pigmented lesions. The accuracy of such assessment has in the past been very erratic, as was discussed in the introduction, and it is suggested that a machine of this type can significantly improve clinical diagnosis in this field.

Two typical pigment patterns observed when junctional activity is present in lesions are described so that junctional and compound naevi and malignant melanomata can be differentiated from other pigmented lesions. There are as yet no absolute criteria for distinguishing the early melanomata from active compound naevi but a lesion which is absolutely flat although showing signs of junctional activity would appear from this study to be benign.

Other lesions which are commonly confused with malignant melanomata can, with relative ease, be identified by their magnified surface patterns. In particular the blue naevi cavernous angiomata and basal cell papillomata can fairly confidently be identified after examination with the microscope, while the sclerosing angiomata and basal cell carcinomata are slightly less consistent in their surface appearances but are generally able to be preoperatively identified.

In view of the increasing awareness of the public of the possible hazards of cutaneous pigmented lesions, and also the increasing incidence reported by plastic surgeons of cutaneous malignancies, it is suggested that an operation microscope of this type is a definite advantage. Few hospitals would have enough material at the present time to justify individual ownership, and it therefore seems eminently sensible for such machines to be supplied on a regional basis. As the machine can be carried in a private car and used anywhere that one power point is available, this is in fact a practical working suggestion. The complete safety and relative speed of the method are additional pointers in its favour.

References

Allen, A.C. 1949. The Histogenesis and Clinical Importance of Cutaneous Naevi and Melanomata. Cancer, 2, 28-56.

Andreev, V.C. 1968. The Diagnosis and Treatment of Malignant Melanoma in Bulgaria. Brit.J.Derm., 80, 149-152.

Bart, R.S. and Kopf, A.W. 1969. The Demonstration of Dendritic Bridges Between Migrant Limbal Melanocytes in the Cornea of the Guinea Pig. Abstracts VIIth International Pigment Cell Conference, Seattle, Sept. 1969.

Bauer, F.K. and Steffen, C.G, 1955. Radioactive Phosphorus in Diagnosis of Skin Tumours. JAMA, 158, 563-565.

Becker, S.W., Snr., Praver, L.L. and Thatcher, H. 1935. An Improved (Paraffin Section) Method for the Dopa Reaction. Arch.Derm. Syph., 31, 190.

Becker, S.W. 1954. Pitfalls in the Diagnosis and Treatment of Melanoma. Arch.Derm.Syph., 69, 11-30.

Biedermann, W. 1891. Ueber den Farbenwechsel der Frosche Pllauger. Arch.Ges.Physiol., 51, 455-508.

Bizzozero, E. 1906. Cellule cromatofore e di Langerhans nelle pelle. Archivio per le Saerize Medicine, 30, 611.

Bloch, B. 1917. Histochemische Studian in Ueberlebendem Gewebe ueber fermentive Oxydation und Pigmentbildung. Ztschr.f.t. Ges.Exp.Medizin., 5, 179-263, 1916-17.

Block, G.E. and Hartwell, S.W. 1961. Malignant Melanoma: A Study of 217 cases. Ann.Surg.Suppl., 154, 88-101.

Borcea, M.I. 1909. Sur L'Origine du Couleur des Cellules Vasculaires et des Cellules Pigmentaires Chez Les Teleosteens. Compt.Rend. Acad.Sci., 149, 688-689.

Bourquelot, E. and Bertrand, G. 1895. Le Bleuissement et le Nourassement des Champignons. Compt.Rend.Soc.Biol., 47, 582-584.

Brauer, E.W., Kopf, A.W., Witten, V.H., Berman, M. and Cave V.G. 1960. Radioactive Phosphorus in in vivo diagnosis of Melanoma of The Skin. J A M A, 172, 1753-1758.

Breathnach, A.S., Silvers, W.K., Smith, J. and Heyner, S. 1968A. Langerhans Cells in Mouse Skin Experimentally Derived of its Neural Crest Component. J.Invest.Derm., 50, 147.

Breathnach, A.S. 1968B. The Epidermal Langerhans Cell. Brit.J.Derm., 80, 688-689.

Carswell, R. 1883. Pathological Anatomy. Illustration of the Elementary Forms of Disease. Longman Orme Brown Green and Longman, London 1833.

Dorris, F. 1936. Differentiation of Pigment Cells in Tissue Culture of Chick Neural Crest. Proc.Soc.Exper.Biol.& Med., 34, 448.

Dupuytren, G. 1806. Nouvelles Observations. J.Med.Chir.Pharm., 10, 96-102. Ann. 13, 1806.

Eiselt, T. Ueber Pigmentkrebs Vierteljahrschr fur die praktische Halkunde. 70, 107, 1861.

76, 26, 1862.

Eve, F. 1905. A Lecture on Melanoma. The Practitioner, 70, 165.

Fitzpatrick, T.B., Becker, S.W., Jnr., Lerner, A.B. and Montgomery, H. 1950. Tyrosinase in Human Skin. Demonstration of its presence and of its role in human melanin formation. Science, 112, 223.

Fitzpatrick, T.B. 1965A. Mammalian Melanin Biosynthesis. Trans. St.Johns Hosp.Derm.Soc., 51, 1-26.

Fitzpatrick, T.B. 1965B. The Terminology of Vertebrate Melanin-Containing Cells. Science, 152, 88-89.

Fitzpatrick, T.B., Mijamoto, M. and Ishikawe, K. 1967. The Evolution of Concepts of Melanin Biology. Arch.Derm.Syph., 96, 305.

Greeley, P.W., Middleton, A.G. and Curtin, J.W. 1965. The Incidence of Malignancy in Giant Pigmented Naevi. Plast.Recons.Surg., 36, 26.

Heusinger, K.F. Untersuchungen ueber die Anomalie Kohlen und Pigmentbildung in dem Menschen Korper. In Eisennach System der Histologie Baerek, 1823.

Hogeboom, G.H. and Adams, M.H. 1942. Mammalian Tyrosinase and Dopa Oxidase. J.Biol.Chem., 145, 273.

Hu, F. 1957. Human Melanocytes in Tissue Culture. J.Invest.Derm., 28, 15.

Laennec, R.T.H. 1805. Sur L'Anatomie Pathologique. J.Med.Chir.Phar., 10, 370, ann 13, 1805.

Langerhans, P. 1868. Ueber die Nerven der Menschlichen Haut Virchow's Archiv f. Path. Anatomie und Physiologie, 44, 320.

Lerner, A.B. 1953. Metabolism of Phenylalanine and Tyrosine. Advances in Enzymology, 14, 73.

Lever, W.F. 1967. Histopathology of the Skin. Pitman Medical

Masson, P. 1926. Pigmented Naevi: Nerve Tumours. Ann.Anat.Path., 3, 417-453. 6, 657-696.

Moir, P.J. 1946. Discussion on Malignant Melanoma. Brit.J.Radiol., 19, 213-232.

Nicolaus, R.A., Piattelli, M., Magno, S. and Fattorusso, E. 1962. The Structure of Melanins and Melanogenesis II. Tetrahedron, 18, 941.

Nicolaus, R.A., Piattelli, M., Magno, S. and Fattorusso, E. 1963. The Structure of Melanins and Melanogenesis III. Tetrahedron, 19, 2061.

Nicolaus, R.A., Piattelli, M. and Fattorusso, E. 1964. The Structure of Melanins and Melanogenesis IV. Tetrahedron, 20, 1163.

Nicolaus, R.A. 1968. Melanins. Hermann, Paris.

Olsen, G. 1967. The Treatment of Malignant Melanoma of the Skin. Scand.J.Plast.Recons.Surg., 1, 12-21.

Paget, J. 1870. Lectures on Surgical Pathology, p.639. Longmans Green & Co., London 1870.

Pemberton, O. 1858. Observations on the Histology Pathology and Treatment of Cancerous Diseases. Churchill, London 1858.

Raper, H.S. 1928. The Aerobic Oxidases. Physiol.Rev., 8, 245-282.

Rawles, M.E. 1940. The Development of Melanophores from Embryonic Mouse Tissues grown in the Coelun of Chick Embryos. Proc.Nat. Acad.Sci., 26, 673.

Robson, N.C. and Swan, G.A. 1966. Symposium on Structure and Control of the Melanocyte. Springer-Verlag, Berlin.

Royster, H.P. and Baker, L.M. 1957. The Management of Malignant Melanoma. Ann.Surg., 145, 888-892.

Spitz, S. 1948. Melanomas of Childhood. Amer.J.Path., 24, 591-609.

Sverdlow, M. 1952. Pigmented Naevi: A Problem of Misdiagnosis. Am.J.Clin.Path., 22 (2), 1054.

Swan, G.A. 1963. Chemical Structure of Melanins. Ann.N Y Acad.Sci., 100, 1005.

Traub, E.F. and Keil, H. 1940. The Common Mole. Its clinico-pathological Relations and the Question of Malignant Degeneration. Arch.Derm.Syph., 41, 214-252.

Unna, P.G. 1896. Zur epithelalen Abkemft der Naevuszellan. Virchow's Arch.Path.Anat., 143, 224.

Venkei, T. and Bakos, L. 1962. The Early Diagnosis of Melano-blastoma by the Thermodifference Test. Acta Un Int.Cancer, 20, 833-835.

Waldeyer, Prof Dr. 1871. Xanthelasme Palpebrarum. Virchow's Archiv.f.path. Anatomie und Physiologie, 52, 318.

Wolff, K. and Winkelmann, R.K. 1967. Quantitative Studies on the Langerhans Cell Population of Guinea Pig Epidermis. J.Invest. Derm., 48, 504-513.